



# MEDICAL TERMINOLOGY

*An Illustrated Guide*

**NINTH EDITION**

Barbara Janson Cohen, MEd

Shirley A. Jones, MEd, MHA, MSN, EMT-P, RN



# MEDICAL TERMINOLOGY

*An Illustrated Guide*

**NINTH EDITION**

**Barbara Janson Cohen, MEd**

**Shirley A. Jones, MEd, MHA, MSN, EMT-P, RN**



JONES & BARTLETT  
LEARNING



World Headquarters  
Jones & Bartlett Learning  
5 Wall Street  
Burlington, MA 01803  
978-443-5000  
info@jblearning.com  
www.jblearning.com

Jones & Bartlett Learning books and products are available through most bookstores and online booksellers. To contact Jones & Bartlett Learning directly, call 800-832-0034, fax 978-443-8000, or visit our website, [www.jblearning.com](http://www.jblearning.com).

Substantial discounts on bulk quantities of Jones & Bartlett Learning publications are available to corporations, professional associations, and other qualified organizations. For details and specific discount information, contact the special sales department at Jones & Bartlett Learning via the above contact information or send an email to [specialsales@jblearning.com](mailto:specialsales@jblearning.com).

Copyright © 2021 by Jones & Bartlett Learning, LLC, an Ascend Learning Company

All rights reserved. No part of the material protected by this copyright may be reproduced or utilized in any form, electronic or mechanical, including photocopying, recording, or by any information storage and retrieval system, without written permission from the copyright owner.

The content, statements, views, and opinions herein are the sole expression of the respective authors and not that of Jones & Bartlett Learning, LLC. Reference herein to any specific commercial product, process, or service by trade name, trademark, manufacturer, or otherwise does not constitute or imply its endorsement or recommendation by Jones & Bartlett Learning, LLC and such reference shall not be used for advertising or product endorsement purposes. All trademarks displayed are the trademarks of the parties noted herein. *Medical Terminology: An Illustrated Guide, Ninth Edition* is an independent publication and has not been authorized, sponsored, or otherwise approved by the owners of the trademarks or service marks referenced in this product.

There may be images in this book that feature models; these models do not necessarily endorse, represent, or participate in the activities represented in the images. Any screenshots in this product are for educational and instructive purposes only. Any individuals and scenarios featured in the case studies throughout this product may be real or fictitious, but are used for instructional purposes only.

The authors, editor, and publisher have made every effort to provide accurate information. However, they are not responsible for errors, omissions, or for any outcomes related to the use of the contents of this book and take no responsibility for the use of the products and procedures described. Treatments and side effects described in this book may not be applicable to all people; likewise, some people may require a dose or experience a side effect that is not described herein. Drugs and medical devices are discussed that may have limited availability controlled by the Food and Drug Administration (FDA) for use only in a research study or clinical trial. Research, clinical practice, and government regulations often change the accepted standard in this field. When consideration is being given to use of any drug in the clinical setting, the health care provider or reader is responsible for determining FDA status of the drug, reading the package insert, and reviewing prescribing information for the most up-to-date recommendations on dose, precautions, and contraindications, and determining the appropriate usage for the product. This is especially important in the case of drugs that are new or seldom used.

21683-7

#### Production Credits

VP, Product Management: Amanda Martin  
Director of Product Management: Cathy L. Esperti  
Product Coordinator: Elena Sorrentino  
Senior Project Specialist: Vanessa Richards  
Digital Project Specialist: Angela Dooley  
Director of Marketing: Andrea DeFronzo  
Marketing Manager: Suzy Balk  
VP, Manufacturing and Inventory Control: Therese Connell

Composition & Project Management: Aptara Inc.  
Cover Design: Kristin E. Parker  
Senior Media Development Editor: Troy Liston  
Rights Specialist: Rebecca Damon  
Cover Image (Title Page, Part Opener, Chapter Opener): © Anatomy Insider/Shutterstock and © kentoh/Shutterstock  
Printing and Binding: LSC Communications  
Cover Printing: LSC Communications

Library of Congress Cataloging-in-Publication Data  
Library of Congress Cataloging-in-Publication Data unavailable at time of printing.

Library of Congress Control Number: 2019916641

6048

Printed in the United States of America  
24 23 22 21 20 10 9 8 7 6 5 4 3 2 1

For their ongoing, wholehearted love and support, I dedicate this ninth edition of *Medical Terminology: An Illustrated Guide* to my children, Jocelyn Hooven and Saul Janson.

—Barbara Janson Cohen

I dedicate this book to my parents Vivian and George Jones, to my sister Virginia E. Kelleher, and to Francis, who are all heroes in my life.

—Shirley A. Jones

# Brief Contents

*Preface* x  
*Acknowledgments* xi  
*Reviewers* xii  
*User's Guide* xiii

## **PART I Introduction to Medical Terminology 1**

- 1** Concepts, Suffixes, and Prefixes of Medical Terminology 2
- 2** Body Structure 38
- 3** Disease and Treatment 74

## **PART II Body Systems 123**

- 4** Integumentary System 124
- 5** Skeletal System 150
- 6** Muscular System 188
- 7** Nervous System and Mental Health 216
- 8** Special Senses: Ear and Eye 258
- 9** Endocrine System 292
- 10** Cardiovascular and Lymphatic Systems 314
- 11** Blood and Immunity 356
- 12** Respiratory System 390
- 13** Digestive System 424

- 14** Urinary System 460
- 15** Male Reproductive System 488
- 16** Female Reproductive System; Pregnancy and Birth 510

## Appendices:

- 1** Commonly Used Symbols 554
- 2** Abbreviations and Their Meanings 555
- 3** Word Parts and Their Meanings 564
- 4** Meanings and Their Corresponding Word Parts 571
- 5** Word Roots 579
- 6** Suffixes 584
- 7** Prefixes 586
- 8** Metric Measurements 588
- 9** Stedman's Medical Dictionary at a Glance 589
- 10** Drugs 590
- 11** Answer Key 595

*Glossary* 622  
*Figure Credits* 648  
*Index of Boxes* 654  
*Index* 655

# Contents

*Preface* x  
*Acknowledgments* xi  
*Reviewers* xii  
*User's Guide* xiii

## **PART I Introduction to Medical Terminology 1**

### **1 Concepts, Suffixes, and Prefixes of Medical Terminology 2**

**Introduction 4**

**Concepts of Medical Terminology 4**

**Word Parts 4**

Combining Forms 5

**Word Derivations 6**

Words Ending in *x* 6

Suffixes Beginning With *rh* 6

**Pronunciation 6**

Soft and Hard *c* and *g* 7

Silent Letters and Unusual Pronunciations 7

**Abbreviations 8**

Phrase Abbreviations 8

Symbols 8

**Medical Dictionaries 8**

**Suffixes 9**

Noun Suffixes 9

Adjective Suffixes 12

**Forming Plurals 15**

Some Exceptions to the Rules 18

**Prefixes 18**

### **2 Body Structure 38**

**Introduction 40**

**The Cell 40**

**Tissues 43**

Membranes 45

**Organs and Organ Systems 45**

**Word Parts Pertaining to Cells, Tissues, and Organs 47**

**The Body as a Whole 51**

Directional Terms 52

Body Cavities 54

Abdominal Regions 54

Positions 55

**Word Parts Pertaining to Body Structure 57**

### **3 Disease and Treatment 74**

**Introduction 76**

**Types of Diseases 76**

**Infectious Diseases 76**

Bacteria 78

**Responses to Disease 79**

Inflammation 79

Phagocytosis 79

Immunity 79

**Neoplasia 80**

**Word Parts Pertaining to Disease 82**

**Diagnosis 89**

Imaging Techniques 91

**Treatment 93**

Surgery 93

**Alternative and Complementary Medicine 95**

**Cancer 95**

**Word Parts Pertaining to Diagnosis and Treatment 98**

**Drugs 106**

Adverse Drug Effects 106

Drug Names 106

Drug Information 106

**Herbal Medicines 106**

**Drug Administration 107**

**Word Parts Pertaining to Drugs 112**

## **PART II Body Systems 123**

### **4 Integumentary System 124**

**Introduction 126**

**Anatomy of the Skin 126**

**Associated Skin Structures 126**

**Roots Pertaining to the Integumentary System 129**

**Clinical Aspects of the Skin 130**

Wounds 131

Dermatitis 133

Psoriasis 133

Autoimmune Disorders 134

Skin Cancer 134

### **5 Skeletal System 150**

**Introduction 152**

**Divisions of the Skeleton 152**

**Bone Formation 155**

**Structure of a Long Bone 155**

**Joints 156**

**Roots Pertaining to the Skeletal System 158**

**Clinical Aspects of the Skeleton 160**

Infection 162

Fractures 162

Metabolic Bone Diseases 162

Neoplasms 164

Joint Disorders 164

Disorders of the Spine 166

### **6 Muscular System 188**

**Introduction 190**

**Types of Muscles 190**

**Skeletal Muscle 190**

Muscle Structure 190

Muscle Action 190

Naming of Muscles 194

**Roots Pertaining to Muscles 197**

**Clinical Aspects of the Muscular System 198**

Muscular Dystrophy 198

Multiple-System Disorders Involving

Muscles 198

Stress Injuries 199

### **7 Nervous System and Mental Health 216**

**Introduction 218**

**Organization of the Nervous System 218**

The Neuron 218

Nerves 219

**The Brain 219**

Protecting the Brain 220

**The Spinal Cord 222**

The Spinal Nerves 222

Reflexes 222

**The Autonomic Nervous System 224**

**Word Parts Pertaining to the Nervous System 227**

**Clinical Aspects of the Nervous System 231**

Vascular Disorders 231

Head Injury 231

Confusion and Coma 232

Infection 232

Neoplasms 233

Degenerative Diseases 233

Epilepsy 234

Sleep Disturbances 234

Others 235

**Behavioral Disorders 235**

Anxiety Disorders 235

Mood Disorders 236

Psychosis 236

Attention Deficit Hyperactivity Disorder 236

Autism Spectrum Disorder 237

Drugs Used in Treatment 237

### **8 Special Senses: Ear and Eye 258**

**Introduction 260**

**The Senses 260**

**The Ear 262**

**Clinical Aspects of Hearing 266**

Hearing Loss 266

Otitis 266

Otosclerosis 266

Ménière Disease 266

Acoustic Neuroma 266

**The Eye and Vision 269**

**Word Parts Pertaining to the Eye and Vision 273**

**Clinical Aspects of Vision 276**

- Errors of Refraction 276
- Infection 276
- Disorders of the Retina 276
- Cataract 278
- Glaucoma 278

## 9 Endocrine System 292

### Introduction 294

### Hormones 294

### The Endocrine Glands 294

- Pituitary 296
- Thyroid and Parathyroids 296
- Adrenals 297
- Pancreas 297

### Other Endocrine Tissues 297

### Roots Pertaining to the Endocrine System 299

### Clinical Aspects of the Endocrine System 300

- Pituitary 300
- Thyroid 301
- Parathyroids 301
- Adrenals 301
- The Pancreas and Diabetes 302

## 10 Cardiovascular and Lymphatic Systems 314

### Introduction 316

### The Heart 317

- Blood Flow Through the Heart 317
- Blood Supply to the Myocardium 318
- The Heartbeat 318
- Electrocardiography 319

### The Vascular System 321

- Blood Pressure 321

### Roots Pertaining to the Cardiovascular System 326

### Clinical Aspects of the Cardiovascular System 328

- Atherosclerosis 328
- Thrombosis and Embolism 328
- Aneurysm 329
- Hypertension 329
- Heart Disease 330
- Disorders of the Veins 333

### The Lymphatic System 337

### Roots Pertaining to the Lymphatic System 340

### Clinical Aspects of the Lymphatic System 341

## 11 Blood and Immunity 356

### Introduction 358

### Blood 358

- Blood Plasma 358
- Blood Cells 358
- Blood Types 362

### Immunity 364

- Innate Immunity 364
- Adaptive Immunity 364
- Types of Adaptive Immunity 365

### Word Parts Pertaining to Blood and Immunity 367

### Clinical Aspects of Blood 370

- Anemia 370
- Coagulation Disorders 373
- Neoplasms 373

### Clinical Aspects of Immunity 374

- Hypersensitivity 374
- Immunodeficiency 374
- Autoimmune Diseases 375

## 12 Respiratory System 390

### Introduction 392

### Upper Respiratory Passageways 392

- The Nose 392
- The Pharynx 393

### Lower Respiratory Passageways and Lungs 394

- The Larynx 394
- The Trachea 394
- The Bronchial System 395
- The Lungs 395

### Breathing 395

- Inspiration 396
- Expiration 396

### Gas Transport 396

### Word Parts Pertaining to the Respiratory System 398

### Clinical Aspects of the Respiratory System 401

- Infections 401
- Emphysema 404
- Asthma 405
- Pneumoconiosis 405
- Lung Cancer 405
- Respiratory Distress Syndrome 405
- Cystic Fibrosis 405
- Sudden Infant Death Syndrome 405
- Pleural Disorders 405
- Diagnosis of Respiratory Disorders 406



**13 Digestive System 424****Introduction 426****Digestion 426****The Digestive Tract 426**

- The Mouth to the Stomach 427
- The Small Intestine 428
- The Large Intestine 429

**The Accessory Organs 429****Roots Pertaining to the Digestive System 432****Clinical Aspects of the Digestive System 436**

- Digestive Tract 436
- Accessory Organs 440

**14 Urinary System 460****Introduction 462****The Kidneys 462**

- Kidney Location and Structure 462
- The Nephrons 463
- Blood Supply to the Kidney 463

**Urine Formation 463**

- Transport and Removal of Urine 464

**Roots Pertaining to the Urinary System 466****Clinical Aspects of the Urinary System 469**

- Infections 469
- Glomerulonephritis 469
- Nephrotic Syndrome 470
- Renal Failure 470
- Urinary Stones 472
- Cancer 472
- Urinalysis 473

**15 Male Reproductive System 488****Introduction 490****The Testes 490****Transport of Spermatozoa 492****The Penis 492****Formation of Semen 492****Word Parts Pertaining to the Male Reproductive System 494****Clinical Aspects of the Male Reproductive System 496**

- Infection 496
- Benign Prostatic Hyperplasia 497

- Cancer 497
- Cryptorchidism 498
- Infertility 498

**Erectile Dysfunction 498**

- Inguinal Hernia 498

**16 Female Reproductive System; Pregnancy and Birth 510****Introduction 512****The Female Reproductive System 512**

- The Ovaries 512
- The Uterine Tubes, Uterus, and Vagina 512
- The External Genital Organs 512

**The Mammary Glands 512****The Menstrual Cycle 514**

- Menopause 515

**Contraception 515****Roots Pertaining to the Female Reproductive System 518****Clinical Aspects of Female Reproduction 521**

- Infection 521
- Fibroids 522
- Endometriosis 522
- Dysfunctional Uterine Bleeding 523
- Premenstrual Syndrome 523
- Polycystic Ovarian Syndrome 523
- Cancer of the Female Reproductive Tract 523
- Breast Cancer 523

**Pregnancy and Birth 528**

- Fertilization and Early Development 528
- The Placenta 528
- Fetal Circulation 530
- Childbirth 531
- Lactation 532

**Roots Pertaining to Pregnancy and Birth 534****Clinical Aspects of Pregnancy and Birth 535**

- Infertility 535
- Ectopic Pregnancy 535
- Preeclampsia 536
- Abortion 536
- Rh Incompatibility 536
- Placental Abnormalities 536
- Mastitis 536

**Congenital Disorders 537**

- Diagnosis of Congenital Disorders 539

**Appendices:**

<b>1</b>	<b>Commonly Used Symbols 554</b>	<b>7</b>	<b>Prefixes 586</b>
<b>2</b>	<b>Abbreviations and Their Meanings 555</b>	<b>8</b>	<b>Metric Measurements 588</b>
<b>3</b>	<b>Word Parts and Their Meanings 564</b>	<b>9</b>	<b>Stedman's Medical Dictionary at a Glance 589</b>
<b>4</b>	<b>Meanings and Their Corresponding Word Parts 571</b>	<b>10</b>	<b>Drugs 590</b>
<b>5</b>	<b>Word Roots 579</b>	<b>11</b>	<b>Answer Key 595</b>
<b>6</b>	<b>Suffixes 584</b>		<i>Glossary 622</i>
			<i>Figure Credits 648</i>
			<i>Index of Boxes 654</i>
			<i>Index 655</i>

# Preface

Knowledge of medical terminology is fundamental to a wide variety of healthcare fields. This text is designed to satisfy the basic learning requirements needed to practice in any health career setting. In the course of your training and future careers, you will need to learn thousands of new terms. The job might be overwhelming if not for learning the skills of dividing the words into their component parts. These roots, suffixes, and prefixes appear over and over in different terms but retain the same meanings. Knowing these meanings will help you define and remember a host of words. This process is like using a set of building blocks to assemble different structures. Using a more scientific example, it is like using the four bases in DNA to code for all the amino acids needed to make proteins.

The text opens with a general introduction to word parts and the human body as a whole, followed by an overview of diseases and treatments. Each subsequent chapter on the individual body systems begins with an illustrated overview of the system with definitions of key terms relevant to that system. Tables of word parts and exercises on using them follow. Turning to the abnormal, a section on diseases and treatments is included, followed by definitions of related key terms. The section of enrichment terms includes words and phrases that are “good to know”

if time allows or if someone is particularly interested in that specialty. The sequence of the systems chapters follows the same order as that found in traditional anatomy and physiology books. Thus this text easily can be used simultaneously with study of A & P. We have tried to make this text easy to use and full of reinforcing drills. We have also included many phonetic pronunciations so you can recognize technical terms when they are spoken and can comfortably use them yourself. Each chapter is enlivened with a short opening case study. These may have some words and abbreviations that are unfamiliar to you, especially at the start of the text. They are included to spark your interest in the chapter material, and give you a sense of medical situations and language. Don’t be concerned if you don’t understand them completely. Return to them after you study the chapter, or even later chapters, and see if they are more understandable.

You are probably at the beginning of a long journey to gain accomplishment in your chosen field. We hope that this text will aid you in that endeavor and provide a basis on which to build your career.

—*Barbara Janson Cohen  
and Shirley A. Jones*

# Acknowledgments

In our constant quest to improve the quality of *Medical Terminology: An Illustrated Guide*, we rely on the advice and talents of many people. First, we want to acknowledge the observant instructors and students who take the time to suggest improvements in the text. Also we thank the reviewers, who make many valuable suggestions for revisions. As always, we are grateful to the dedicated publishing staff; especially for this edition, Jonathan Joyce, Michael Kerns, Julie Vitale, Jeremiah Kiely, Cody Adams, Leo Gray, and Jennifer Clements.

—*Barbara Janson Cohen  
and Shirley A. Jones*

# Reviewers

**Cynthia Bowers, MS**  
Adjunct Instructor  
Department of Allied Health  
City College of Montana State University-Billings  
Billings, Montana

**Gerard Cronin, MS**  
Associate Professor  
Department of Health Sciences  
Salem Community College  
Salem County, New Jersey

**Dr. Abbey Dondanville, EdD, LAT**  
Associate Dean  
Department of Health Sciences  
Piedmont College  
Demorest, Georgia

**Robin Gardenhire, MEd**  
Clinical Instructor  
Department of Respiratory Therapy  
Georgia State University  
Atlanta, Georgia

**Dr. David Good, PhD**  
School of Allied Health  
Australian Catholic University  
Sydney, Australia

**Carolyn Hart, PhD, RN, CNE**  
Chair  
Department of Nursing  
Barry University  
Miami, Florida

**Chris Haynes, BS, MS**  
Department of Natural Sciences  
Shelton State College  
Tuscaloosa, Alabama

**Timothy Jones**  
University of Oklahoma  
Center for Distance Learning  
Norman, Oklahoma

**Karma Peters, PT, DPT, GCS**  
Clinical Assistant Professor of Physical Therapy  
Carroll University  
Waukesha, Wisconsin

**Melissa C. Poua, BSCLS, MT (ASCP)**  
Instructor  
Department of Medical Laboratory Sciences  
Andrews University  
Berrien Springs, Michigan

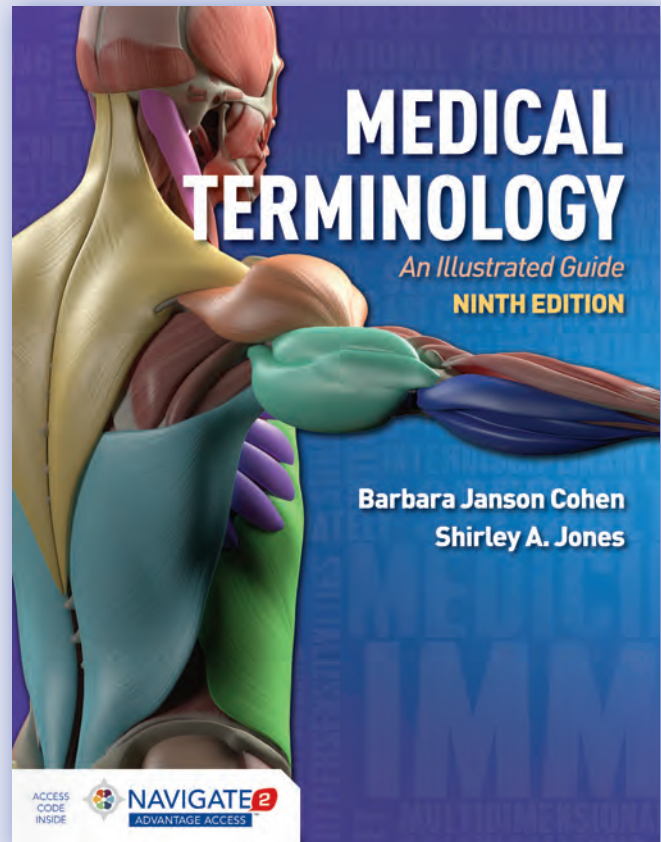
**Melissa Reed, PhD**  
Associate Professor  
Assistant Chair  
Exercise Science Division  
West Chester University  
West Chester, Pennsylvania

**Tasha Simpson**  
Assistant Professor  
Department of Medical Laboratory Sciences  
Andrews University  
Berrien Springs, Michigan

**Dr. Chanadra Young Whiting, EdD, MPH/HSA**  
Clinical Assistant Professor  
Health Services Administration  
Florida International University  
Miami, Florida

# User's Guide

**Medical Terminology: An Illustrated Guide, Ninth Edition** was created and developed to help you master the language of medicine. The tools and features in the text will help you work through the material presented. Please take a few moments to look through this User's Guide, which will introduce you to the features that will enhance your learning experience.



### Learning Objectives

After careful study of this chapter, you should be able to:

- 1 Compare the location and function of smooth, cardiac, and skeletal muscles. **P190**
- 2 Describe the typical structure of a skeletal muscle. **P190**
- 3 Briefly describe the mechanism of muscle contraction. **P190**
- 4 Explain how muscles work together to produce movement. **P191**
- 5 Describe the main types of movements produced by muscles. **P192**
- 6 List some of the criteria for naming muscles, and give examples of each. **P192**
- 7 Identify and use the roots pertaining to the muscular system. **P197**
- 8 Describe at least seven disorders that affect muscles. **P198**
- 9 Interpret abbreviations pertaining to muscles. **P204**
- 10 Analyze several case studies involving muscles. **PP189, 212**

### Case Study: Thomas's Brachial Plexus Injury



**Chief Complaint**  
Thomas, a 16 y/o high school student, had a severe lacrosse accident that resulted in a flail arm. He had sustained right brachial plexus injury and had no recovery. He has continued to take medication for neurologic pain. He was scheduled to see his orthopedic surgeon for a possible brachial plexus exploration.

**Clinical Course**  
Thomas and his parents had previous discussions with the surgeon and were aware of the prognosis and treatment plan. With middle trunk brachial plexus injury, damage to the subscapularis and teres major muscles. Damage to the long thoracic nerve prevents conduction to the serratus anterior muscles. Injury to the pectoral nerves affects the pectoralis major and minor muscles.

Thomas was scheduled for an EMG, nerve conduction studies, and somatosensory evoked potentials (SSEP). His diaphragm was examined under fluo oscopy to R/O phrenic nerve injury. The results of the diagnostic studies indicated that Thomas had most likely sustained a middle trunk brachial plexus injury. Thomas was scheduled for a brachial plexus exploration with possible bilateral sural (calf) nerve graft, nerve transfer, or gracilis muscle graft from his right thigh.

**Case Study Revisited:** Once you complete this chapter, please review the case follow-up on p. 205.

### Ancillaries At-A-Glance

Visit the web resource to access the following resources.

**Learning Resources**

- eBook
- A&P Module with Heart & Lung Sounds
- Image bank
- TestPrep
- Animations
- Audio Pronunciation Glossary

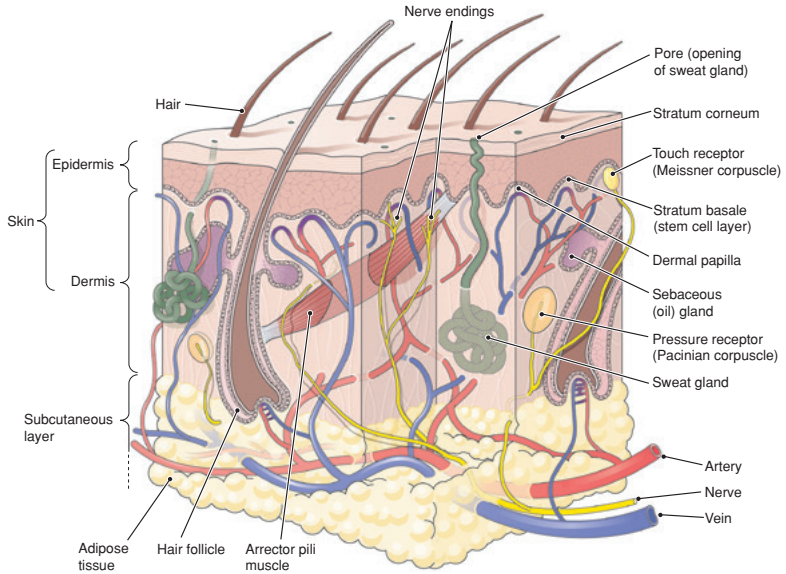

Chapter 6 ■ Muscular System 189

## Chapter Contents, Objectives, and Pretests

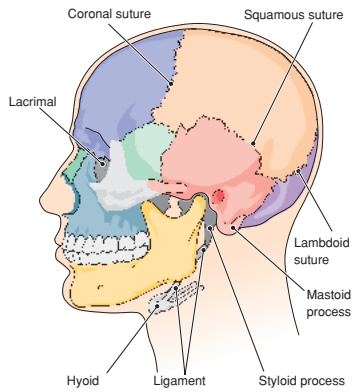
Chapter Opening Case Studies and Objectives help you identify learning goals and familiarize yourself with the materials covered in the chapter. Chapter Pretests quiz students on previous knowledge at the beginning of each chapter. Students should take each Chapter Pretest before starting the chapter and again after completing the chapter in order to measure progress.

### Detailed Illustrations

Detailed, full-color drawings and photographs illuminate the chapters. These include clinical photographs and tissue micrographs. The many figures amplify and clarify the text and are particularly helpful for visual learners.

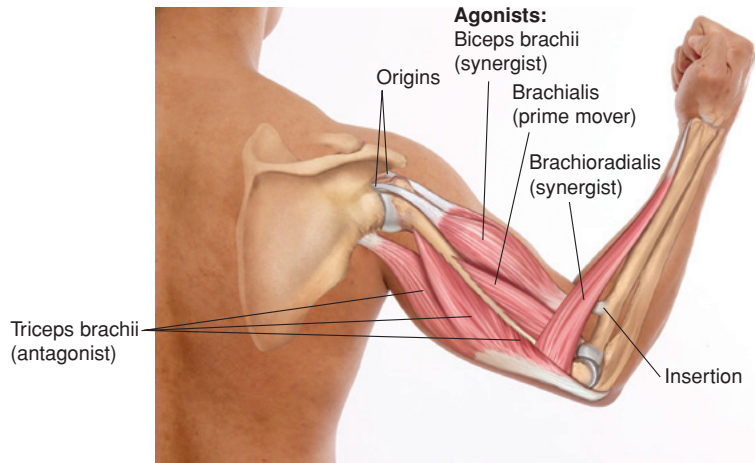


**FIGURE 4-1** Cross-section of the skin. The skin layers and associated structures are shown.



- Bones of the skull:**
- Frontal
  - Parietal
  - Sphenoid
  - Temporal
  - Nasal
  - Maxilla
  - Occipital
  - Zygomatic
  - Mandible

**FIGURE 5-2** The skull from the left. An additional cranial bone, the ethmoid (*ETH-moyd*), is visible mainly from the interior of the skull. The hyoid is considered part of the axial skeleton but is not attached to any other bones. The tongue and other muscles are attached to the hyoid.



**FIGURE 6-4** Muscles work together. When the brachialis, the agonistic prime mover, flexes the arm, the triceps brachii, the antagonist, must relax. Synergists, the biceps brachii and the brachioradialis, assist in this action. When the arm is extended, these muscle actions are reversed. This figure also shows three attachments of the biceps brachii, two origins and one insertion.

**Focus on Words boxes** provide historical or other interesting information on select terms within a chapter.



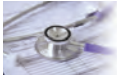### FOCUS ON WORDS Meaningful Suffixes

BOX 1-3

Suffixes sometimes take on a color of their own as they are added to different words. The suffix *-thon* is taken from the name of the Greek town Marathon, from which news of a battle victory was carried by a long-distance runner. It has been attached to various words to mean a contest of great endurance. We have bike-a-thons, dance-a-thons, telethons, and even major charity fundraisers called thon-a-thons.

The adjective ending *-ish* is used, as in *boyish* or *childish*, to suggest traces of certain characteristics. People tack it onto words to indicate that they are estimates, not right on target, as in *forty-ish* or *blue-ish*. A vague time for a lunch appointment could be *noon-ish*.

In science and medicine, the ending *-tech* is used to imply high technology, as in the company name Genetech, and *-pure* may be added to inspire confidence, as in the naming of the Multi-Pure water filter. The ending *-mate* suggests helping, as in *helpmate*, defined in the dictionary as a helpful companion, more specifically, a wife, or sometimes, a husband. The medical device HeartMate is a pump used to assist a damaged heart. In current terminology, the ending *-ome* refers to the objects in a comprehensive topic of study such as microbiome (total microbiologic population associated with an individual), genome (study of all the genes in an individual), and proteome (the entire protein makeup of an individual).



## CLINICAL PERSPECTIVES

BOX 4-1

### Medication Patches: No Bitter Pill to Swallow

For most people, pills are a convenient way to take medication, but for some, they have drawbacks. Pills must be taken at regular intervals to ensure consistent dosing, and they must be digested and absorbed into the bloodstream before they can begin to work. For those who have difficulty swallowing or digesting pills, transdermal (TD) patches offer an effective alternative to oral medications.

TD patches deliver a consistent dose of medication that diffuses at a constant rate through the skin into the bloodstream. There is no daily schedule to follow, nothing to swallow, and no stomach upset. TD patches can also deliver medication to unconscious patients, who would otherwise require intravenous drug delivery. TD patches are used in hormone replacement therapy, to treat heart disease, to manage pain, and to suppress motion sickness. Nicotine patches are also used as part of programs to quit smoking.

TD patches must be used carefully. Drug diffusion through the skin takes time, so it is important to know how long the patch must be in place before it is effective. It is also

important to know when the medication's effects disappear after the patch is removed. Because the body continues to absorb what has already diffused into the skin, removing the patch does not entirely remove the medicine. There is also a danger that patches may become unsafe when heated, as by exercise, high fever, or a hot environment, such as a hot tub, heating pad, or sauna. When heat dilates the capillaries in the skin, a dangerous increase in dosage may result as more medication enters the blood.

A recent advance in TD drug delivery is iontophoresis. Based on the principle that like charges repel each other, this method uses a mild electrical current to move ionic drugs through the skin. A small electrical device attached to the patch uses positive current to "push" positively charged drug molecules through the skin and a negative current to push negatively charged ones. Even though very low levels of electricity are used, people with pacemakers should not use iontophoretic patches. Another disadvantage of these patches is that they can move only ionic drugs through the skin.

Clinical Perspectives boxes focus on body processing, as well as techniques used in clinical settings.

Health Professions boxes focus on a variety of health careers, showing how the knowledge of medical terminology is applied in future careers.



## HEALTH PROFESSIONS

BOX 13-2

### Dental Hygienist

Dental hygienists focus primarily on dental health maintenance and preventive dental care. They examine patients' dentition and periodontium (supporting structures of the teeth); take radiographic images; and perform oral prophylaxis using hand and ultrasonic instruments to remove deposits, such as calculus, stains, and plaque. They may also apply fluorides to prevent caries. They work independently or along with a dentist to administer local anesthesia and nitrous oxide sedation and to do oral screenings, polish restorations, remove sutures, apply dental sealants, and perform periodontal procedures. Dental hygienists must be knowledgeable about safety concerning x-ray equipment, anesthesia, and infectious diseases. They wear safety glasses, surgical masks, and gloves to protect themselves and their patients. A major component of the dental hygienist's work is patient education for maintenance of good oral health. They may give instruction on nutrition and proper oral care, such as brushing, flossing, and the use of antimicrobial rinses.

Most dental hygiene programs award an associate degree; some offer bachelor's or master's degrees. The higher degrees are required for research, teaching, or practice in public or school health facilities. The professional program requires 1 year of college-level prerequisite courses. The curriculum includes courses in radiography, dental anatomy, pharmacology, head and neck anatomy, and other health- and dental-related sciences. Additional material on the legal and ethical aspects of dental hygiene practice and extensive clinical training are included in the program. After graduation, dental hygienists must be licensed in their states by passing clinical and written examinations administered by the American Dental Association's (ADA) Joint Commission on National Dental Examinations.

Almost all hygienists work in dental offices. One advantage of this field is scheduling flexibility and the opportunity for part-time work. Job prospects are good; dental hygiene is among the fastest growing occupations. Benefits vary with place of employment. For additional information, contact the American Dental Hygienists' Association at adha.org.



## FOR YOUR REFERENCE

BOX 1-2

### Silent Letters and Unusual Pronunciations

Letter(s)	Pronunciation	Example	Definition of Example
ch	k	chemical <i>KEM-ih-kal</i>	pertaining to the elements and their interactions (root <i>chem/o</i> means "chemical")
dys	dis	dysfunction <i>dis-FUNK-shun</i>	difficult or abnormal ( <i>dys-</i> ) function
eu	u	euphoria <i>u-FOR-e-ah</i>	exaggerated feeling of well-being ( <i>eu-</i> means "true" or "good")
gn	n	gnathic <i>NATH-ik</i>	pertaining to the jaw ( <i>gnath/o</i> )
ph	f	phantom <i>FAN-tom</i>	illusion or imaginary image
pn	n	pneumonia <i>nu-MO-ne-ah</i>	inflammation of the lungs ( <i>pneumon/o</i> )
ps	s	pseudonym <i>SU-do-nim</i>	false name ( <i>-nym</i> )
pt	t	ptosis <i>TO-sis</i>	dropping, downward displacement
rh	r	rhinoplasty <i>Ri-no-plas-te</i>	plastic repair of the nose ( <i>rhin/o</i> )
x	z	xiphoid <i>Zi-foyd</i>	pertaining to cartilage attached to the sternum (from Greek <i>xiphos</i> , meaning "sword")

For Your Reference boxes provide supplemental information for terms within a chapter.



**Table 2-1 Roots for Cells and Tissues**

Root	Meaning	Example	Definition of Example
morph/o	form	polymorphous <i>pol-e-MOR-fus</i>	having many forms
cyt/o, -cyte	cell	cytologist <i>si-TOL-o-jist</i>	one who studies cells
nucle/o	nucleus	nuclear <i>NU-kle-ar</i>	pertaining to a nucleus
kary/o	nucleus	karyotype <i>KAR-e-o-tipe</i>	picture of a cell's chromosomes organized according to size (FIG. 2-10)
hist/o, histi/o	tissue	histocompatibility <i>his-to-kom-pat-ib-BIL-ib-te</i>	tissue similarity that permits transplantation
fibr/o	fiber	fibrosis <i>fi-BRO-sis</i>	abnormal formation of fibrous tissue
reticul/o	network	reticulum <i>reb-TIK-u-lum</i>	a network
aden/o	gland	adenoma <i>ad-eb-NO-mab</i>	tumor (-oma) of a gland
papill/o	nipple	papilla <i>pab-PIL-ab</i>	projection that resembles a nipple
mys/o	mucus	myxadenitis <i>miks-ad-eb-NI-tis</i>	inflammation (-itis) of a mucus-secreting gland
muc/o	mucus, mucous membrane	mucorhea <i>mu-ko-RE-ab</i>	increased flow (-rhea) of mucus
somat/o, -some	body, small body	chromosome <i>KRO-mo-some</i>	small body that takes up color (dye) (chrom/o)

**Word Part Tables** present roots, prefixes, and suffixes covered in each chapter in an easy-to-reference format (with examples of their use in medical terminology). Word Part Knowledge aids in the learning and understanding of common terminology.

**Exercises** are designed to test your knowledge before you move to the next learning topic that follows each table.

**Exercise 13-3**

Complete the exercise. To check your answers go to Appendix 11.

Use the suffix *-ic* to write a word for the following definitions.

- pertaining to the liver \_\_\_\_\_
- pertaining to the gallbladder \_\_\_\_\_
- pertaining to the pancreas \_\_\_\_\_

Use the suffix *-graphy* to write a word for the following definitions.

- radiographic study of the liver \_\_\_\_\_
- radiographic study of the gallbladder \_\_\_\_\_
- radiographic study of the bile ducts \_\_\_\_\_
- radiographic study of the pancreas \_\_\_\_\_

Use the suffix *-lithiasis* to write a word for the following definitions.

- condition of having a stone in the common bile duct \_\_\_\_\_
- condition of having a stone in the pancreas \_\_\_\_\_

Fill in the blanks.

- Inflammation of the liver is called \_\_\_\_\_.
- The word biligenesis (*bil-ib-JEN-eb-sis*) means the formation of \_\_\_\_\_.
- A cholelith (*KO-le-lith*) is a(n) \_\_\_\_\_.
- Choledochotomy (*ko-led-o-KOT-o-me*) is incision of the \_\_\_\_\_.
- Cholecystectomy (*ko-le-sis-TEK-to-me*) is removal of the \_\_\_\_\_.
- Hepatomegaly (*hep-ab-to-MEG-ab-le*) is enlargement of the \_\_\_\_\_.
- Cholangitis (*ko-lan-JI-tis*) is inflammation of a(n) \_\_\_\_\_.
- Pancreatolysis (*pan-kre-ab-TOL-ib-sis*) is dissolving of the \_\_\_\_\_.

**Terminology Key Terms**

The terms listed below are emphasized in this chapter. Knowing them will help you organize and prioritize your learning. These boldface terms are also found, collectively, with all chapter key terms in the Glossary.

<b>Disease</b>	
<b>acute</b> <i>ab-KUTE</i>	Sudden, severe; having a short course
<b>benign</b> <i>be-NINE</i>	Not recurrent or malignant, favorable for recovery, describing a tumor that does not spread (metastasize) to other tissues
<b>carcinoma</b> <i>kar-sib-NO-mab</i>	A malignant neoplasm composed of epithelial cells (from Greek root <i>carcino</i> , meaning "crab") (adjective: carcinomatous)
<b>chronic</b> <i>KRON-ik</i>	Of long duration, progressing slowly
<b>cyst</b> <i>sist</i>	An abnormal filled sac or pouch; used as a root meaning a normal bladder or sac, such as the urinary bladder or gallbladder (root: <i>cyst/o</i> )
<b>edema</b> <i>eb-DE-mab</i>	Accumulation of fluid in the tissues, swelling; adjective: edematous (eb-DE-mab-tus) (see FIG. 3-2)
<b>etiology</b> <i>e-te-OL-o-je</i>	The cause of a disease
<b>Gram stain</b>	A laboratory staining procedure that divides bacteria into two groups: gram positive, which stains purple, and gram negative, which stains red
<b>hernia</b> <i>HER-ne-ab</i>	Protrusion of an organ through an abnormal opening; commonly called a rupture (FIG. 3-4)
<b>immunity</b> <i>ib-MU-nib-te</i>	All our defenses against infectious disease
<b>inflammation</b> <i>in-flab-MA-shun</i>	A localized response to tissue injury characterized by heat, pain, redness, and swelling
<b>lesion</b> <i>LE-shun</i>	A distinct area of damaged tissue, an injury or wound

**Terminology Tables-Key Terms** outline the key terms emphasized in the chapter and can be used as a learning and study tool.

Terminology	Enrichment Terms
The terms listed below expand on the key terms to increase your knowledge of this chapter topic.	
<b>amino acids</b> <i>ah-ME-no</i>	The nitrogen-containing compounds that make up proteins
<b>anabolism</b> <i>ah-NAB-o-lizm</i>	The type of metabolism in which body substances are made; the building phase of metabolism
<b>catabolism</b> <i>kah-TAB-o-lizm</i>	The type of metabolism in which substances are broken down for energy and simple compounds
<b>collagen</b> <i>KOL-ab-jen</i>	A fibrous protein found in connective tissue
<b>cortex</b> <i>KOR-tex</i>	The outer region of an organ
<b>glycogen</b> <i>GLI-ko-jen</i>	A complex sugar compound stored in liver and muscles and broken down into glucose when needed for energy
<b>interstitial</b> <i>in-ter-STISH-al</i>	Between parts, such as the spaces between cells in a tissue
<b>medulla</b> <i>meh-DUL-lah</i>	The inner region of an organ, marrow (root: medull/o)
<b>parenchyma</b> <i>par-EN-kib-mah</i>	The functional tissue of an organ
<b>parietal</b> <i>pah-RI-eb-tal</i>	Pertaining to a wall, describes a membrane that lines a body cavity
<b>soma</b> <i>SO-mah</i>	The body
<b>stem cell</b>	An immature cell that has the capacity to develop into any of a variety of different cell types, a precursor cell

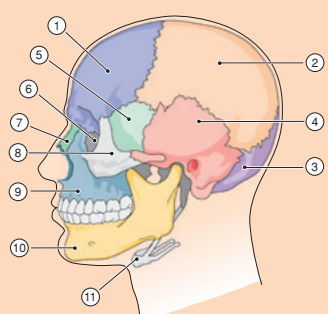
**Terminology Tables-Enrichment Terms** provide you with more challenging terms to expand your knowledge.

**Terminology Tables-Abbreviations** are listed for common terms.

Terminology	Abbreviations		
The abbreviations listed below are emphasized in this chapter. These are also found, collectively, with all chapter abbreviations in Appendix 2.			
<b>ACE</b>	Angiotensin-converting enzyme	<b>GFR</b>	Glomerular filtration rate
<b>ADH</b>	Antidiuretic hormone	<b>GU</b>	Genitourinary
<b>ARF</b>	Acute renal failure	<b>IVP</b>	Intravenous pyelography
<b>ATN</b>	Acute tubular necrosis	<b>IVU</b>	Intravenous urography
<b>BUN</b>	Blood urea nitrogen	<b>K</b>	Potassium
<b>CAPD</b>	Continuous ambulatory peritoneal dialysis	<b>KUB</b>	Kidney-ureter-bladder (radiography)
<b>CCPD</b>	Continuous cyclic peritoneal dialysis	<b>Na</b>	Sodium
<b>CMG</b>	Cystometrography; cystometrogram	<b>PEP</b>	Protein electrophoresis
<b>CRF</b>	Chronic renal failure	<b>SG</b>	Specific gravity
<b>EPO</b>	Erythropoietin	<b>Tm</b>	Maximal transport capacity
<b>ESRD</b>	End-stage renal disease	<b>UA</b>	Urinalysis
<b>ESWL</b>	Extracorporeal shock-wave lithotripsy	<b>UTI</b>	Urinary tract infection

**SKULL FROM THE LEFT**  
Write the name of each numbered part on the corresponding line.

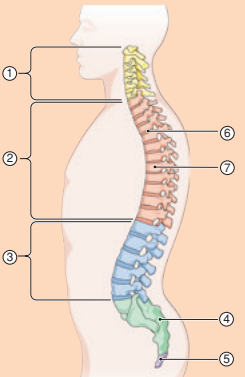
Frontal	Occipital
Hyoid	Parietal
Lacrimal	Sphenoid
Mandible	Temporal
Maxilla	Zygomatic
Nasal	



1. \_\_\_\_\_
2. \_\_\_\_\_
3. \_\_\_\_\_
4. \_\_\_\_\_
5. \_\_\_\_\_
6. \_\_\_\_\_
7. \_\_\_\_\_
8. \_\_\_\_\_
9. \_\_\_\_\_
10. \_\_\_\_\_
11. \_\_\_\_\_


**VERTEBRAL COLUMN**  
Write the name of each numbered part on the corresponding line.

Body of vertebra	Lumbar vertebrae
Cervical vertebrae	Sacrum
Coccyx	Thoracic vertebrae
Intervertebral disk	



1. \_\_\_\_\_
2. \_\_\_\_\_
3. \_\_\_\_\_
4. \_\_\_\_\_
5. \_\_\_\_\_
6. \_\_\_\_\_
7. \_\_\_\_\_

**Chapter Review Exercises** are designed to test your knowledge of the chapter material and appear at the end of each chapter.



### Case Study 9-2: Diabetes Treatment With an Insulin Pump

Maria, a 32 y/o marketing executive, was diagnosed with type 1 diabetes at the age of 3. She vividly remembers her mother taking her to the doctor because she had an illness that caused her to feel extremely tired and very thirsty and hungry. She also had begun to wet her bed and had a cut on her knee that would not heal. Her mother had had gestational diabetes during her pregnancy with Maria, and at birth, Maria was described as having "macrosomia" because she weighed 10 pounds.

Maria has managed her disease with meticulous attention to her diet, exercise, preventive health care, regular blood glucose monitoring, and twice-daily injections of regular and NPH insulin, which she rotates among her upper arms, thighs, and abdomen. She continues in a smoking cessation program supported by weekly acupuncture treatments. She maintains good control of her disease in spite of the inconvenience and time it consumes each day. She will be married next summer and would like to start a family. Maria's doctor suggested she try an insulin pump to give her more freedom and enhance her quality of life. After intensive training, she has received her pump. It is about the size of a deck of cards with a thin catheter that she introduces through a needle into her abdominal subcutaneous tissue. She can administer her insulin in a continuous subcutaneous insulin infusion (CSII) and in calculated meal bolus doses. She still has to test her blood for hyperglycemia and hypoglycemia and her urine for ketones when her blood glucose is too high. She hopes one day to have an islet transplantation.

#### Case Study 9-2 Questions

Follow the instructions for each question and check your answers in Appendix 11.

**Multiple Choice.** Select the best answer, and write the letter of your choice to the left of each number.

- Gestational diabetes occurs
  - in a pregnant woman
  - to any large fetus
  - during menopause
  - in a large baby with high blood glucose
- The term macrosomia describes
  - excessive weight gain during pregnancy
  - a large body
  - an excessive amount of sleep
  - inability to sleep during pregnancy
- Maria injected the insulin into the subcutaneous tissue, which is
  - present only in the abdomen, thighs, and upper arms
  - a topical application
  - below the skin
  - above the pubic bone
- An islet transplantation refers to
  - transfer of insulin-secreting cells into a pancreas
  - transfer of parathyroid cells to the liver
  - surgical insertion of an insulin pump into the abdomen
  - a total pancreas and kidney transplantation


Write the terms from the case study with the following meanings.

- high serum glucose \_\_\_\_\_
- a large dose of a therapeutic agent \_\_\_\_\_

Define the following abbreviations.

- NPH \_\_\_\_\_
- CSII \_\_\_\_\_

**Case Studies and Case Study Questions** at the end of every chapter present terminology in the context of a medical report. These are an excellent review tool because they test your cumulative knowledge of medical terminology and put terminology into a real-world context.



## Instructor, Student and Learning Resources

### For the Instructor

Qualified instructors will receive a full suite of instructor resources, including the following:

- Slides in PowerPoint format
- Testbank in LMS compatible format
- Lesson Plans

### For the Student

- eBook
- Anatomy & Physiology Review Module with Heart & Lung Sounds
- Animations
- TestPrep


### Learning Resources

- eBook
- A&P Module with Heart & Lung Sounds
- Image Bank
- TestPrep
- Animations
- Audio Pronunciation Glossary

# PART I

## Introduction to Medical Terminology

- Chapter 1 Concepts, Suffixes, and Prefixes of Medical Terminology
- Chapter 2 Body Structure
- Chapter 3 Disease and Treatment



# Concepts, Suffixes, and Prefixes of Medical Terminology

## Pretest

**Multiple Choice.** Select the best answer, and write the letter of your choice to the left of each number. To check your answers go to Appendix 11.

- \_\_\_\_\_ 1. The main part of a word is called the
  - a. origin
  - b. prefix
  - c. root
  - d. extension
- \_\_\_\_\_ 2. A word part at the end of a word is the
  - a. prefix
  - b. adjective
  - c. insertion
  - d. suffix
- \_\_\_\_\_ 3. The *ch* in the word *chemical* is pronounced like the letter
  - a. s
  - b. h
  - c. k
  - d. f
- \_\_\_\_\_ 4. The word below that has a hard *g* is
  - a. grip
  - b. page
  - c. gem
  - d. judge
- \_\_\_\_\_ 5. The suffixes *-ic*, *-ous*, *-al*, and *-oid* are found in
  - a. adjectives
  - b. nouns
  - c. verbs
  - d. roots
- \_\_\_\_\_ 6. The singular of *ova* (eggs) is
  - a. ovi
  - b. ovae
  - c. ovum
  - d. ovas
- \_\_\_\_\_ 7. The prefix in the word *microscopic* is
  - a. mic-
  - b. scop-
  - c. micro-
  - d. pic-
- \_\_\_\_\_ 8. The opposite of hypoglycemia (low blood sugar) is
  - a. hypogluccemia
  - b. hyperglycemia
  - c. hypocalcemia
  - d. hypoglycemic

## Learning Objectives

After careful study of this chapter, you should be able to:

- 1 Explain the purpose of medical terminology. **P4**
- 2 Name the languages from which most medical word parts are derived. **P4**
- 3 Define the terms *root*, *suffix*, and *prefix*. **P4**
- 4 Explain what combining forms are and why they are used. **P5**
- 5 List three features of medical dictionaries. **P8**
- 6 Recognize and apply some general noun, adjective, and plural suffixes used in medical terminology. **P9**
- 7 Recognize and define prefixes used in medical terminology. **P18**
- 8 Analyze the suffixes and prefixes used in chapter case studies. **PP3, 34**



## Case Study: David's Digestive Problems

### Chief Complaint

David, a 22 y/o college student, visited the university health clinic and stated he had a 4-month history of a burning pain in the middle of his chest (heartburn). He notices it more at night and has difficulty sleeping because of the pain. He said he is under stress due to the intensity of his college courses and has gained 20 pounds over the last 6 months. He also said that the pain seems to occur more frequently following late-night college gatherings where pizza, spicy chicken wings, and beer are served.

### Examination

A well-nourished 22 y/o male complaining of (c/o) epigastric (upper abdominal) pain no longer relieved by antacids; orthopnea—currently sleeping with three pillows to aid in breathing; occasional swallowing problems, or dysphagia; ETOH (alcohol) consumption is six to eight beers per week; nonsmoker; no neurologic, musculoskeletal, genitourinary, or respiratory deficits. David was referred to a gastroenterologist for ↑ acid production and possible gastroesophageal reflux disease (GERD).

### Clinical Course

The gastroenterologist saw David and ordered a special x-ray procedure, a barium swallow radiograph, to rule out any structural problems with the esophagus. The barium provides contrast to enable the radiologist to take x-rays of the esophagus. Since the results of this test proved to be inconclusive for GERD, David was scheduled for an esophageal gastroduodenoscopy (EGD). An EGD allows the gastroenterologist to visually examine the upper GI tract, showing the esophagus, stomach, and duodenum (the upper part of the small intestine). Results of the EGD showed no evidence of bleeding, ulcerations, or strictures. Since David still complained of mild heartburn he was sent home with a prescription of Prevacid and given educational material on GERD, including dietary, exercise, and stress reduction recommendations. He was told he needed to be reevaluated in 3 months.

**Case Study Revisited: Once you complete this chapter, please review the case follow-up on p. 27.**

## Ancillaries *At-A-Glance*

Visit the web resource to access the following resources.

### Learning Resources

- eBook
- A&P Module with Heart & Lung Sounds
- Image Bank
- TestPrep
- Animations
- Audio Pronunciation Glossary

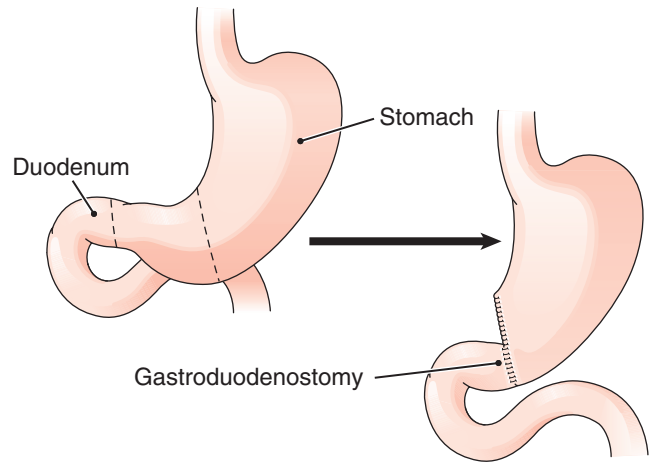
## Introduction

Medical terminology is a special vocabulary used by health-care professionals for effective and accurate communication. Every health-related field requires an understanding of medical terminology, and this book highlights selected healthcare occupations in special boxes (BOX 1-1). While studying this chapter, you will learn about the general concepts of medical terminology and explore the specific role of suffixes and prefixes in words.

## Concepts of Medical Terminology

Because it is based mainly on Greek and Latin words, medical terminology is consistent and uniform throughout the world. It is also efficient; although some of the terms are long, they often reduce an entire phrase to a single word. The one word *gastroduodenostomy*, for example, means “a communication between the stomach and the first part of the small intestine” (FIG. 1-1). The part *gastr* means stomach; *duoden* represents the duodenum, the first part of the small intestine; and *ostomy* means a communication.

The medical vocabulary is vast, and learning it may seem like learning the entire vocabulary of a foreign language. Moreover, like the jargon that arises in all changing fields, it is always expanding. Think of the terms that have been added to our vocabulary in relation to computers, such as *software*, *search engine*, *flash drive*, *app*, and *blog*. The task may seem overwhelming, but there are methods to aid in learning and remembering words and even to help make informed guesses about unfamiliar words. Most medical terms can be divided into component parts—roots, prefixes, and suffixes—that maintain the same meaning whenever



**FIGURE 1-1 Gastroduodenostomy.** A communication (-stomy) between the stomach (*gastr*) and the first part of the small intestine, or duodenum (*duoden*).

they appear. By learning these meanings, you can analyze and remember many words.

## Word Parts

Word components fall into three categories:

1. The **root** is the fundamental unit of each medical word. It establishes the basic meaning of the word and is the part to which modifying word parts are added.
2. A **suffix** is a short word part or series of parts added at the end of a root to modify its meaning. This book indicates suffixes by a dash before the suffix, such as *-itis* (inflammation).



## HEALTH PROFESSIONS

### Health Information Technicians

BOX 1-1

Patient medical records are used as the basis for all medical care delivered. Every time a patient receives medical treatment, information is added to the patient’s medical record, which includes the medical history, data about symptoms, test results, diagnoses, treatments, and follow-up care. Health information technicians (HITs) organize and manage these records and work closely with physicians, nurses, and other health professionals to ensure that they provide a complete and accurate basis for quality patient care.

Accurate medical records are essential for administrative purposes, third-party payers, and researchers. HITs assign a code to each diagnosis and procedure a patient receives, and this information is used for accurate patient billing. In addition, HITs analyze medical records to reveal trends in health and disease. This research can be used to improve patient care, manage costs, and help establish new medical treatments.

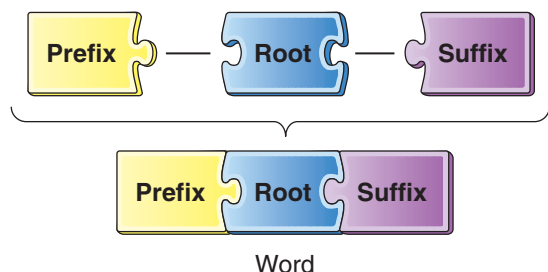
To read and interpret medical records, HITs need a thorough background in medical terminology. Students

planning to pursue this career may obtain a certificate in health information technology or complete an associate’s degree in health information technology at a community college. Those wanting to move into an administrative role may complete advanced studies and a bachelor’s degree in health informatics at a university. A certification examination is required to become certified as a registered health information technician (RHIT). Many institutions prefer to hire individuals who are professionally certified.

Most HITs work in hospitals and long-term care facilities. Others may work in medical clinics, government agencies, insurance companies, and consulting firms. Because of the growing need for medical care, health information technology is projected to be one of the fastest growing careers in the United States.

For more information about this profession, contact the American Health Information Management Association at [ahima.org](http://ahima.org).

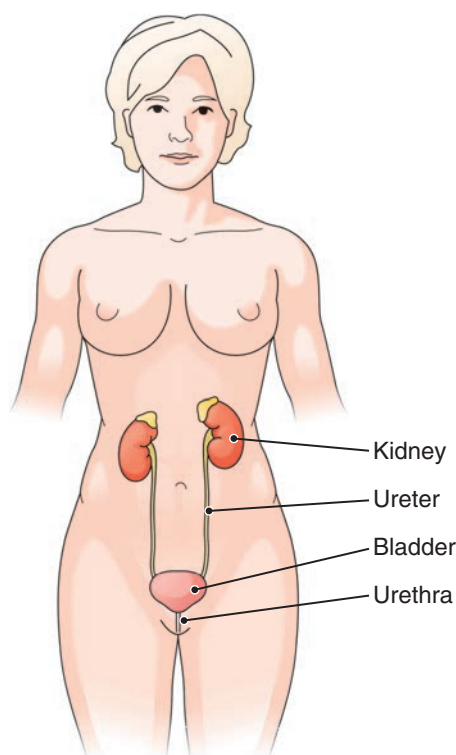
3. A **prefix** is a short word part added before a root to modify its meaning. This book indicates prefixes by a dash after the prefix, such as *pre-* (before).



Words are formed from roots, suffixes, and prefixes.

The simple word *learn* can be used as a root to illustrate. If we add the suffix *-er* to form *learner*, we have “one who learns.” If we add the prefix *re-* to form *relearn*, we have “to learn again.”

Not all roots are complete words. In fact, most medical roots are derived from other languages and are meant to be used in combinations. The Greek word *kardia*, for example, meaning “heart,” gives us the root *cardi*. The Latin word *pulmo*, meaning “lung,” gives us the root *pulm*. In a few instances, both the Greek and Latin roots are used for the same structure. We find both the Greek root *nephr* and the Latin root *ren* used in words pertaining to the kidney (FIG. 1-2).



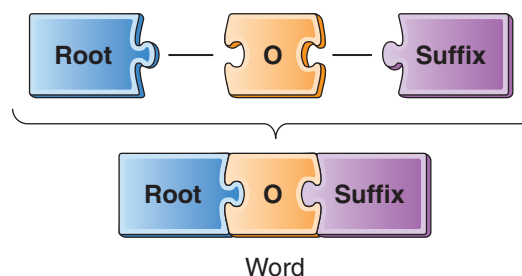
**FIGURE 1-2** Structures named with more than one word root. Medical terminology uses both the Greek root *nephr* and the Latin root *ren* for the kidney, an organ of the urinary system.

Note that the same root may have different meanings in different fields of study, just as the words *web*, *spam*, *cloud*, *cookie*, and *tweet* have different meanings in common vocabulary than they do in “computerese.” The root *myel* means “marrow” and may apply to either the bone marrow or the spinal cord. The root *scler* means “hard” but may also apply to the white of the eye. *Cyst* means “a filled sac or pouch” but also refers specifically to the urinary bladder. You will sometimes have to consider the context of a word before assigning its meaning.

A **compound word** contains more than one root. The words *eyeball*, *bedpan*, *frostbite*, and *wheelchair* are examples. Some examples of compound medical words are *cardiovascular* (pertaining to the heart and blood vessels), *urogenital* (pertaining to the urinary and reproductive systems), and *lymphocyte* (a white blood cell found in the lymphatic system).

## COMBINING FORMS

When a suffix or another root beginning with a consonant is added to a root, a vowel is inserted between the root and the next word part to aid in pronunciation. This combining vowel is usually an *o*, as seen in the previous example of gastroduodenostomy, but may occasionally be *a*, *e*, or *i*.

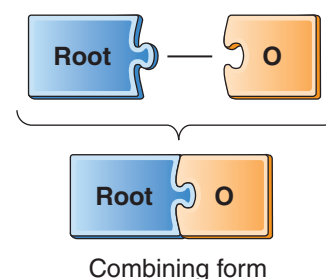


A combining vowel may be added between a root and a word part that follows.

Thus, when the suffix *-logy*, meaning “study of,” is added to the root *neur*, meaning “nerve or nervous system,” a combining vowel is added:

$neur + o + logy = \text{neurology}$  (study of the nervous system)

Roots shown with a combining vowel are called **combining forms**.



A root with a combining vowel is called a combining form.

This text gives roots with their most common combining vowels added after a slash and refers to them simply as roots, as in *neur/o*. A combining vowel is usually not used if



the ending begins with a vowel. For example, the root *neur* is combined with the suffix *-itis*, meaning “inflammation of,” in this way:

neur + itis = neuritis (inflammation of a nerve)

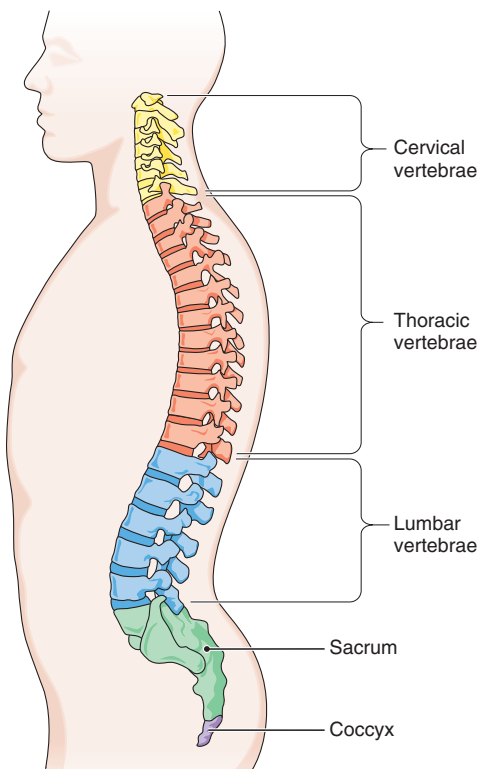
This rule has some exceptions, particularly when they affect pronunciation or meaning, and you will observe these as you work.

## Word Derivations

As mentioned, most medical word parts come from Greek (G.) and Latin (L.). The original words and their meanings are included in this text only occasionally. However, they are interesting and may aid in learning. For example, *muscle* comes from a Latin word that means “mouse” because the movement of a muscle under the skin was thought to resemble the scampering of a mouse. The coccyx, the tail end of the spine, is named for the cuckoo because it was thought to resemble the cuckoo’s bill (FIG. 1-3). For those interested in the derivations of medical words, a good medical dictionary will provide this information.

## WORDS ENDING IN *x*

When you add a suffix to a word ending in *x*, the *x* is changed to a *g* or a *c*. If there is a consonant before the *x*, such as *yx* or *nx*, the *x* is changed to a *g*. For example, *pharynx* (throat) becomes *pharyngeal* (*fah-RIN-je-al*), to mean



**FIGURE 1-3** Word derivations. The coccyx of the spine is named by its resemblance to a cuckoo’s bill.

“pertaining to the throat”; *coccyx* (terminal portion of the spine) becomes *coccygeal* (*kok-SIJ-e-al*), to mean “pertaining to the coccyx.”

If a vowel comes before the *x*, such as *ax* or *ix*, you change the *x* to a *c*. Thus, *thorax* (chest) becomes *thoracic* (*tho-RAS-ik*), to mean “pertaining to the chest”; and *cervix* (neck) becomes *cervical* (*SER-vih-kal*), to mean “pertaining to a neck.”

## SUFFIXES BEGINNING WITH *rh*

When you add a suffix beginning with *rh* to a root, the *r* is doubled. For example:

hem/o (blood) + rhage (bursting forth) = hemorrhage  
(a bursting forth of blood)

men/o (menses) + rhea (flow, discharge) = menorrhoea  
(menstrual flow)

## Pronunciation

This text provides phonetic pronunciations at every opportunity, even in the answer keys. The web resource has a large audio pronunciation dictionary. Take advantage of these aids. Repeat each word aloud as you learn to recognize it in print or hear it on the web resource.

The following definitions apply to pronunciation:

**Vowel:** There are five English vowels; a, e, i, o, u. Each has a specific sound when pronounced.

**Syllable:** A unit of pronunciation having one vowel sound, forming the whole or part of a word. The number of times you hear a vowel (a, e, i, o, u) in a word is equal to the number of syllables contained in the word.

No special marks are needed to follow the pronunciation if you keep a few simple rules in mind.

### Rule 1

Any vowel that appears alone or at the end of a syllable gets a long pronunciation. The alphabet sounds (when the vowel “says its name”) are called long vowels. They are called “long” because we hold them longer than the short sounds.

Vowel	Long Pronunciation
a	as in <i>say, ate, tape</i>
e	as in <i>tea, eat, seat</i>
i	as in <i>lie, mite, might</i>
o	as in <i>hose, oat, moat</i>
u	as in <i>sue, mute, cube</i>

### Rule 2

Any vowel that appears within a syllable gets a short pronunciation:

Vowel	Short Pronunciation
a	as in <i>hat, pan, mat</i>
e	as in <i>met, pen, bed</i>
i	as in <i>bin, pin, mitt</i>
o	as in <i>not, cot, rot</i>
u	as in <i>run, mutt, hug</i>

**Rule 3**

If a vowel is at the end of a syllable but needs a short pronunciation, an *h* is added, as in *vah-nil-ah* for vanilla.

**Rule 4**

If a vowel within a syllable needs a long pronunciation, an *e* is added, as in *re-pete* for repeat.

**Rule 5**

The accented syllable in each word is shown with capital letters, as in *AK-sent*.

Be aware that word parts may change in pronunciation when they are combined in different ways. Note also that accepted pronunciations may vary from place to place. Only one pronunciation for each word is given here, but be prepared for differences.

**SOFT AND HARD *c* AND *g***

- A soft *c*, as in *racer*, will be written in pronunciations as *s* (*RA-ser*).

- A hard *c*, as in *candy*, will be written as *k* (*KAN-de*).
- A soft *g*, as in *page*, will be written as *j* (*PAJE*).
- A hard *g*, as in *grow*, will be written as *g* (*GRO*).

**SILENT LETTERS AND UNUSUAL PRONUNCIATIONS**

A silent letter or an unusual pronunciation can be a problem, especially if it appears at the start of a word that you are trying to look up in the dictionary. See **BOX 1-2** for some examples.

The combinations in **BOX 1-2** may be pronounced differently when they appear within a word, as in *diagnosis* (*di-ag-NO-sis*), meaning determination of the cause of disease, in which the *g* is pronounced; *apnea* (*AP-ne-ah*), meaning cessation of breathing, in which the *p* is pronounced; *nephroptosis* (*nef-rop-TO-sis*), meaning dropping of the kidney, in which the *p* is pronounced.

1

**FOR YOUR REFERENCE**

BOX 1-2

**Silent Letters and Unusual Pronunciations**

Letter(s)	Pronunciation	Example	Definition of Example
ch	k	chemical <i>KEM-ih-kal</i>	pertaining to the elements and their interactions (root <i>chem/o</i> means “chemical”)
dys	dis	dysfunction <i>dis-FUNK-shun</i>	difficult or abnormal (dys-) function
eu	u	euphoria <i>u-FOR-e-ah</i>	exaggerated feeling of well-being ( <i>eu-</i> means “true” or “good”)
gn	n	gnathic <i>NATH-ik</i>	pertaining to the jaw (gnath/o)
ph	f	phantom <i>FAN-tom</i>	illusion or imaginary image
pn	n	pneumonia <i>nu-MO-ne-ah</i>	inflammation of the lungs (pneumon/o)
ps	s	pseudonym <i>SU-do-nim</i>	false name (-nym)
pt	t	ptosis <i>TO-sis</i>	dropping, downward displacement
rh	r	rhinoplasty <i>RI-no-plas-te</i>	plastic repair of the nose (rhin/o)
x	z	xiphoid <i>ZI-foyd</i>	pertaining to cartilage attached to the sternum (from Greek <i>xiphos</i> , meaning “sword”)

## Abbreviations

Shortened words or initials can save time in writing medical reports and case histories. We commonly use TV for television, Jr. for junior, F for Fahrenheit temperature readings, UV for ultraviolet, and Dr. for doctor. A few of the many medical abbreviations are mL for the metric measurement milliliter; dB for decibels, units of sound intensity; CA for cancer; hgb for hemoglobin; and ECG for electrocardiogram.

### PHRASE ABBREVIATIONS

An **acronym** is an abbreviation formed from the first letter of each word in a phrase. Some everyday acronyms are ASAP (as soon as possible), ATM (automated teller machine), and a computer's RAM (random access memory). Acronyms have become popular for saving time and space in naming objects, organizations, and procedures. They abound in the names of government agencies: FDA (Food and Drug Administration), USDA (United States Department of Agriculture), and NIH (National Institutes of Health). Some medical acronyms are BP for blood pressure, MRI for magnetic resonance imaging, AIDS for acquired immunodeficiency syndrome, CNS for the central nervous system, and RN for registered nurse. Acronyms and abbreviations that appear in a chapter are listed and defined at the end of that chapter. Appendix 2 is a more complete list of commonly used abbreviations and acronyms with their meanings. An abbreviation dictionary is also helpful.

## SYMBOLS

Symbols are commonly used as shorthand in case histories. Some examples are Ⓛ and Ⓜ for left and right and ↑ and ↓ for increase and decrease. A list of common symbols appears in Chapter 3 and in Appendix 1.

Symbols and abbreviations can save time, but they can also cause confusion if they are not universally understood. Usage varies in different institutions, and the same abbreviation may have different meanings in different fields. For example, the acronym CRF can mean chronic renal failure or case report form, and MS can represent mitral stenosis or multiple sclerosis. Again, as with roots having multiple meanings, if the acronym is not defined, its interpretation depends on its context.

Some abbreviations and symbols are subject to error and should never be used. These appear in “Do Not Use” lists published by organizations that promote patient safety, such as the Joint Commission on Accreditation of Health-care Organizations (JCAHO) and the Institute for Safe Medical Practices (ISMP). Most institutions have a policy manual that details the accepted abbreviations for that facility. Only the most commonly used symbols and abbreviations are given here.

## Medical Dictionaries

With few exceptions, you can do all the exercises in this book without the aid of a dictionary, but medical dictionaries are valuable references for everyone in health-related

## Terminology

### Key Terms

The terms listed below are emphasized in this chapter. Knowing them will help you organize and prioritize your learning. These boldface terms are also found, collectively, with all chapter key terms in the Glossary.

<b>acronym</b> <i>AK-ro-nim</i>	An abbreviation formed from the first letter of each word in a phrase
<b>combining forms</b> <i>kom-BI-ning</i>	A word root combined with a vowel that links the root with another word part, such as a suffix or another root; combining forms are shown with a slash between the root and the vowel, as in <i>neur/o</i>
<b>compound word</b> <i>KOM-pownd</i>	A word that contains more than one root
<b>prefix</b> <i>PRE-fix</i>	A word part added before a root to modify its meaning
<b>root</b> <i>rute</i>	The fundamental unit of a word
<b>suffix</b> <i>SUH-fix</i>	A word part added to the end of a root to modify its meaning

fields. These include not only complete, unabridged versions, but also easy-to-carry short versions and dictionaries of medical acronyms and abbreviations. Many of these dictionaries are also available on the internet, and as applications for smartphones and tablets. Dictionaries give information on meanings, synonyms, derivations, and related terms. Those dictionaries intended for nursing and allied health professions include more complete clinical information, with notes on patient care.

Dictionaries vary in organization; in some, almost all terms are entered as nouns, such as disease, syndrome, procedure, or test. Those with a more clinical approach enter some terms according to their first word, which may be an adjective or proper name, for example, biomedical engineering, Cushing disease, and wind chill factor. This format makes it easier to look up some terms. All dictionaries have directions on how to use the book and interpret the entries, as shown in Appendix 9, taken from *Stedman's Medical Dictionary*, 28th ed.

In addition to information on individual terms and phrases, medical dictionaries have useful appendices on measurements, clinical tests, drugs, diagnosis, body structure, information resources, and other topics.

## Suffixes

A suffix is a word ending that modifies a root. A suffix may indicate that the word is a noun or an adjective and often determines how the definition of the word will begin (BOX 1-3). For example, using the root *myello*, meaning “bone marrow,” the adjective ending *-oid* forms the word *myeloid*, which means “like or pertaining to bone marrow.” The ending *-oma* forms *myeloma*, which is a tumor

of the bone marrow. Adding another root, *gen*, which represents genesis or origin, and the adjective ending *-ous* forms the word *myelogenous*, meaning “originating in bone marrow.”

The suffixes given in this chapter are general ones that are used throughout medical terminology. They include endings that form:

- Nouns: a person, place, or thing
- Adjectives: words that modify nouns
- Plurals: endings that convert single nouns to multiples

Additional suffixes will be presented in later chapters as they pertain to disease states, medical treatments, or specific body systems.

## NOUN SUFFIXES

The following general suffixes convert roots into nouns. TABLE 1-1 lists suffixes that represent different conditions. Note that the ending *-sis* may appear with different combining vowels as *-osis*, *-iasis*, *-esis*, or *-asis*. The first two of these denote an abnormal condition.

TABLE 1-2 lists endings that convert roots into medical specialties or specialists. The suffix *-logy* applies to many fields other than medicine. It contains the root *log/o* taken from the Greek word *logos*, which means “word,” and generally means a field of study. Some examples are biology, archeology, terminology, and technology. Terms with this ending are also used to identify an institutional department or a specialty, as in cardiology, dermatology, radiology, and others. The two endings *-iatrics* and *-iatry* contain the root *-iatr/o*, based on a Greek word for healing and meaning “physician” or “medical treatment.”



### FOCUS ON WORDS

#### Meaningful Suffixes

BOX 1-3

Suffixes sometimes take on a color of their own as they are added to different words. The suffix *-thon* is taken from the name of the Greek town Marathon, from which news of a battle victory was carried by a long-distance runner. It has been attached to various words to mean a contest of great endurance. We have bike-a-thons, dance-a-thons, telethons, and even major charity fundraisers called thon-a-thons.

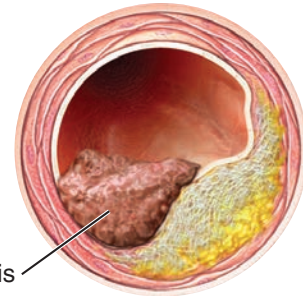
The adjective ending *-ish* is used, as in *boyish* or *childish*, to suggest traces of certain characteristics. People tack it onto words to indicate that they are estimates, not right on target, as in *forty-ish* or *blue-ish*. A vague time for a lunch appointment could be *noon-ish*.

In science and medicine, the ending *-tech* is used to imply high technology, as in the company name Genentech, and *-pure* may be added to inspire confidence, as in the naming of the Multi-Pure water filter. The ending *-mate* suggests helping, as in *helpmate*, defined in the dictionary as a helpful companion, more specifically, a wife, or sometimes, a husband. The medical device HeartMate is a pump used to assist a damaged heart. In current terminology, the ending *-ome* refers to the objects in a comprehensive topic of study such as microbiome (total microbiologic population associated with an individual), genome (study of all the genes in an individual), and proteome (the entire protein makeup of an individual).

Table 1-1

## Suffixes That Mean “Condition of”

Suffix	Example	Definition of Example
-ia	dementia <i>de-MEN-she-ah</i>	loss of (de-) intellectual function (from L. <i>mentis</i> : mind)
-ism	racism <i>RA-sizm</i>	discrimination based on race
-sis	thrombosis <i>throm-BO-sis</i>	having a blood clot (thrombus) in a vessel (FIG. 1-4)
-y	atony <i>AT-o-ne</i>	lack (a-) of muscle tone



**FIGURE 1-4 Thrombosis.** This term refers to having a blood clot (thrombus) in a vessel. The word *thrombosis* has the noun suffix *-sis*, meaning “condition of.”

## Exercise 1-1

Complete the exercise. To check your answers go to Appendix 11.

Write the suffix that means “condition of” in the following words. Remember to use the phonetics to pronounce each word as you work through the exercises.

1. phobia (unfounded fear; from G. *phobos*: fear)  
*FO-be-ah*

ia

2. psoriasis (skin disease)  
*so-RI-ah-sis*

3. egotism (exaggerated self-importance; from *ego*: self)  
*E-go-tizm*

4. dystrophy (changes due to lack of nourishment; root: troph/o)  
*DIS-tro-fe*

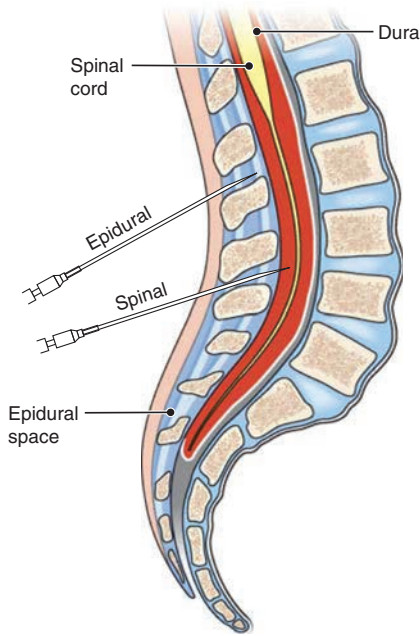
5. anesthesia (loss of sensation; root: esthesi/o) (FIG. 1-5)  
*an-es-THE-ze-ah*

6. parasitism (infection with parasites or behaving as a parasite)  
*PAR-ah-sit-izm*

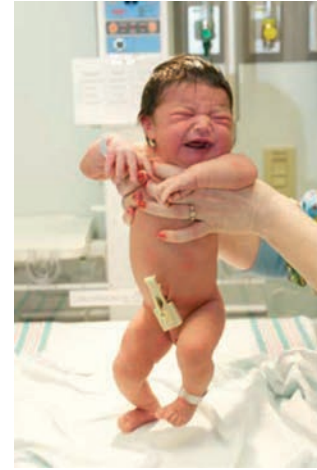7. stenosis (narrowing of a canal)  
*steh-NO-sis*

8. tetany (sustained muscle contraction)  
*TET-ah-ne*

9. diuresis (increased urination; root: ur/o)  
*di-u-RE-sis*



**FIGURE 1-5 Injection sites for anesthesia.** The word *anesthesia* uses the noun suffix *-ia*, meaning “condition of.” The dura is a layer of the meninges, the membranes that cover the brain and spinal cord. One who administers anesthesia is an anesthetist or anesthesiologist.



**FIGURE 1-6 Pediatrics is the care and treatment of children.** The ending *-ics* indicates a medical specialty. In this photo, a pediatrician, one who practices pediatrics, is testing an infant's reflexes. The root *ped/o* means “child.”

1

Table 1-2		Suffixes for Medical Specialties	
Suffix	Meaning	Example	Definition of Example
-ian	specialist in a field of study	physician <i>fib-ZISH-un</i>	practitioner of medicine (from root <i>physi/o</i> , meaning “nature”)
-iatrics	medical specialty	pediatrics <i>pe-de-AT-riks</i>	care and treatment of children ( <i>ped/o</i> ) (FIG. 1-6)
-iatry	medical specialty	psychiatry <i>si-KI-ah-tre</i>	study and treatment of mental ( <i>psych/o</i> ) disorders
-ics	medical specialty	orthopedics <i>or-tho-PE-diks</i>	study and treatment of the skeleton and joints (from root <i>ped/o</i> , meaning “child,” and prefix <i>ortho</i> , meaning “straight”)
-ist	specialist in a field of study	podiatrist <i>po-DI-ah-trist</i>	one who studies and treats the foot ( <i>pod/o</i> )
-logy	study of	physiology <i>fiz-e-OL-o-je</i>	study of function in a living organism (from root <i>physi/o</i> , meaning “nature”)

## Exercise 1-2

Complete the exercise. To check your answers go to Appendix 11.

Write the suffix in the following words that means “study of,” “medical specialty,” or “specialist in a field of study.”

- cardiologist (specialist in the study and treatment of the heart; root: *cardi/o*) \_\_\_\_\_ ist  
*kar-de-OL-o-jist*
- neurology (the study of the nervous system; root: *neur/o*) \_\_\_\_\_  
*nu-ROL-o-je*

(continued)

## Exercise 1-2 (Continued)

3. geriatrics (study and treatment of the aged; root: ger/e) (FIG. 1-7)  
*jer-e-AT-riks*
4. dermatology (study and treatment of the skin, or derma)  
*der-mah-TOL-o-je*
5. optician (one who makes and fits corrective lenses for the eyes; root: opt/o)  
*op-TISH-an*
6. anesthetist (one who administers anesthesia) (see FIG. 1-5)  
*ah-NES-theb-tist*

---



---



---



---

Write a word for a specialist in the following fields.

7. anatomy (study of body structure)  
*ah-NAT-o-me*
8. pediatrics (care and treatment of children; root: ped/o) (see FIG. 1-6)  
*pe-de-AT-riks*
9. radiology (use of radiation in diagnosis and treatment)  
*ra-de-OL-o-je*
10. psychology (study of the mind; root: psych/o)  
*si-KOL-o-je*
11. technology (practical application of science)  
*tek-NOL-o-je*
12. obstetrics (medical specialty concerning pregnancy and birth)  
*ob-STET-riks*

anatomist

---



---



---



---



---



---



**FIGURE 1-7** Geriatrics is the care and treatment of the aged. A specialist in this field, a geriatrician, is shown.

## ADJECTIVE SUFFIXES

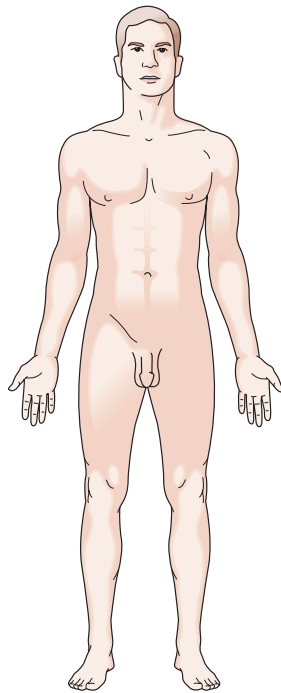
The suffixes below are all adjective endings that mean “pertaining to,” “like,” or “resembling” (TABLE 1-3). There are no rules for which ending to use for a given noun. Familiarity comes with practice. When necessary, tips on proper usage are given in the text.

Note that for words ending with the suffix *-sis*, the first *s* is changed to a *t* before adding *-ic* to form the adjective, as in genetic, pertaining to genesis (origin); psychotic, pertaining to psychosis (a mental disorder); or diuretic, pertaining to diuresis (increased urination).

Table 1-3

## Suffixes That Mean “Pertaining to,” “Like,” or “Resembling”

Suffix	Example	Definition of Example
-ac	cardiac <i>KAR-de-ak</i>	pertaining to the heart
-al	vocal <i>VO-kal</i>	pertaining to the voice
-ar	nuclear <i>NU-kle-ar</i>	pertaining to a nucleus
-ary	salivary <i>SAL-ih-var-e</i>	pertaining to saliva
-form	muciform <i>MU-sib-form</i>	like or resembling mucus
-ic	anatomic <i>an-ab-TOM-ik</i>	pertaining to anatomy (FIG. 1-8)
-ical (ic + al)	electrical <i>e-LEK-trib-kal</i>	pertaining to electricity
-ile	virile <i>VIR-il</i>	pertaining to the male, masculine
-oid	lymphoid <i>LIM-foyd</i>	pertaining to the lymphatic system
-ory	circulatory <i>SIR-ku-lah-tor-e</i>	pertaining to circulation
-ous	cutaneous <i>ku-TA-ne-us</i>	pertaining to the skin (from L. <i>cutis</i> : skin)



**FIGURE 1-8** The anatomical position. This posture is standard in the study of anatomy. A person in this position is facing forward with arms at the side and palms forward (anterior). The adjective suffix *-ic* means “pertaining to.”

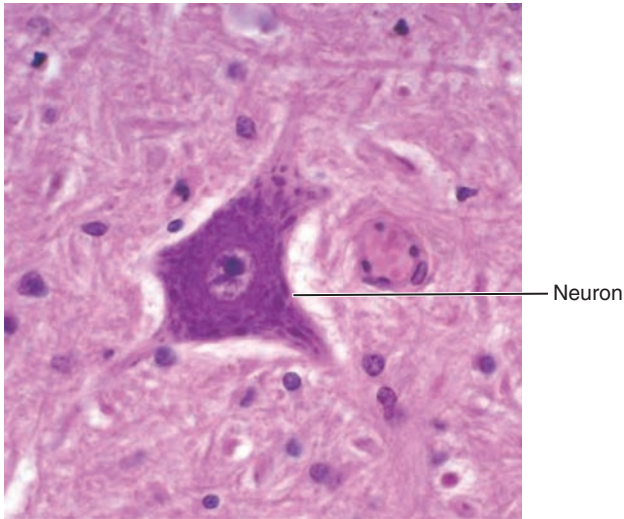


## Exercise 1-3

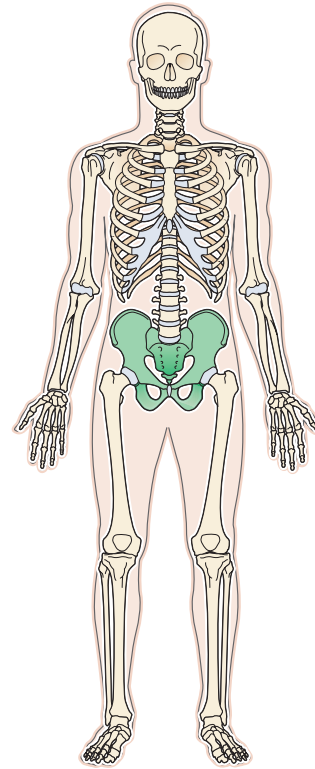
Complete the exercise. To check your answers go to Appendix 11.

Identify the suffix meaning “pertaining to,” “like,” or “resembling” in the following words. Remember to use the phonetics to pronounce each word as you work through the exercises.

- |  |           |
|--|-----------|
| 1. dietary (pertaining to the diet)<br><i>DI-eh-tar-e</i>  | _____ ary |
| 2. neuronal (pertaining to a nerve cell, or neuron) (FIG. 1-9)<br><i>NU-ro-nal</i>               | _____     |
| 3. metric (pertaining to a meter or measurement; root metr/o means “measure”)<br><i>MEH-trik</i> | _____     |
| 4. venous (pertaining to a vein; root: ven/o)<br><i>VE-nus</i>                                   | _____     |
| 5. epileptiform (like or resembling epilepsy)<br><i>ep-ih-LEP-tih-form</i>                       | _____     |
| 6. toxoid (like or resembling a toxin, or poison)<br><i>TOK-soyd</i>                             | _____     |
| 7. topical (pertaining to a surface)<br><i>TOP-ih-kal</i>  | _____     |
| 8. febrile (pertaining to fever)<br><i>FEB-rile</i>  | _____     |
| 9. neurotic (pertaining to neurosis, a mental disorder)<br><i>nu-ROT-ik</i>                      | _____     |
| 10. surgical (pertaining to surgery)<br><i>SUR-jih-kal</i>                                       | _____     |
| 11. muscular (pertaining to a muscle)<br><i>MUS-ku-lar</i>                                       | _____     |
| 12. urinary (pertaining to urine; root: ur/o)<br><i>U-rih-nar-e</i>                              | _____     |
| 13. respiratory (pertaining to respiration)<br><i>RES-pih-rah-tor-e</i>                          | _____     |
| 14. pelvic (pertaining to the pelvis) (FIG. 1-10)<br><i>PEL-vik</i>                              | _____     |
| 15. saccular (pouch-like, resembling a small sac)<br><i>SAK-u-lar</i>                            | _____     |



**FIGURE 1-9** A neuron is a nerve cell. The adjective form of *neuron* is *neuronal*.

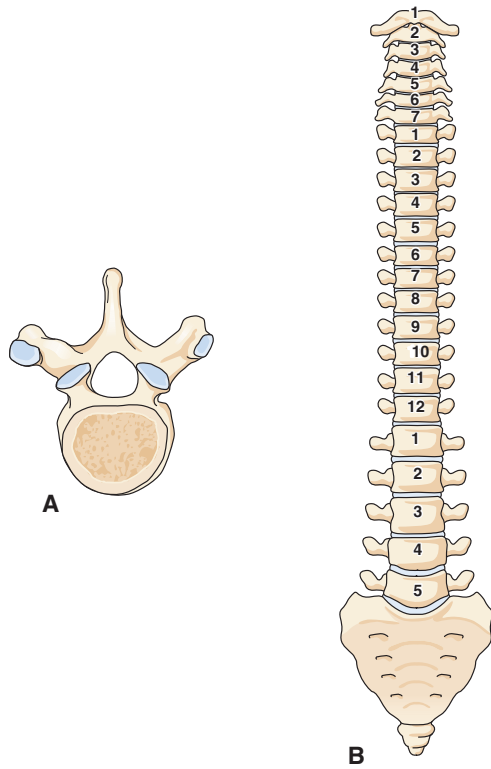


**FIGURE 1-10** The pelvis is the bony hip girdle. The adjective form of *pelvis* is *pelvic*.

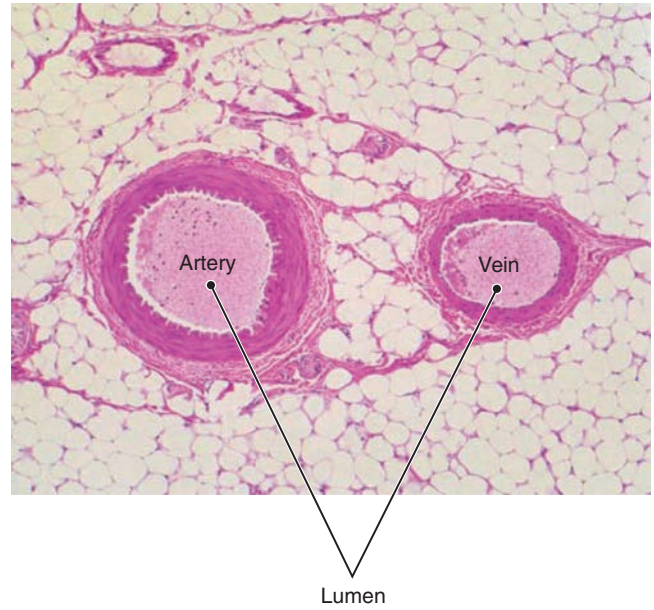
## Forming Plurals

Many medical words have special plural forms based on the ending of the word. **TABLE 1-4** gives some general rules for the formation of plurals along with examples. The plural endings listed in the second column are substituted for the word endings in the first column. Note that both singular endings *-on* and *-um* change to *-a* for the plural. You have to learn which singular ending to use for specific words when converting a plural word ending in *-a* to the singular.

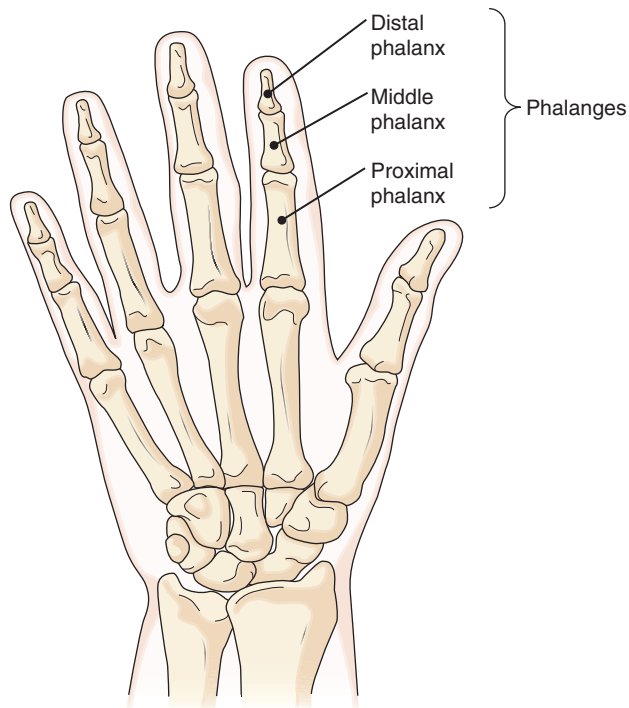
Table 1-4		Plural Endings	
Word Ending	Plural Ending	Singular Example	Plural Example
a	ae	vertebra (bone of the spine) <i>VER-teh-brah</i>	vertebrae ( <b>FIG. 1-11</b> ) <i>VER-teh-bre</i>
en	ina	lumen (central opening) <i>LU-men</i>	lumina ( <b>FIG. 1-12</b> ) <i>LU-min-ab</i>
ex, ix, yx	ices	matrix (background substance; mold) <i>MA-triks</i>	matrices <i>MA-trib-seze</i>
is	es	diagnosis (determination of a disease or defect) <i>di-ag-NO-sis</i>	diagnoses <i>di-ag-NO-seze</i>
ma	mata	stigma (mark or scar) <i>STIG-mah</i>	stigmata <i>stig-MAT-ab</i>
nx (anx, inx, ynx)	nges	phalanx (bone of finger or toe) <i>fab-LANKS</i>	phalanges ( <b>FIG. 1-13</b> ) <i>fab-LAN-jeze</i>
on	a	ganglion (mass of nervous tissue) <i>GANG-le-on</i>	ganglia <i>GANG-le-ab</i>
um	a	serum (thin fluid) <i>SE-rum</i>	sera <i>SE-rab</i>
us	i	thrombus (see <b>FIG. 1-4</b> ) <i>THROM-bus</i>	thrombi <i>THROM-bi</i>



**FIGURE 1-11** Bones of the spine. **A.** Each bone of the spine is a vertebra. **B.** The spinal column is made of 26 vertebrae.



**FIGURE 1-12** A lumen is the central opening of an organ or vessel. Two blood vessels are shown, an artery and a vein. The plural of lumen is *lumina*.



**FIGURE 1-13** Bones of the right hand (anterior view). Each bone of a finger or toe is a phalanx. Each hand has 15 phalanges.

## Exercise 1-4

Complete the exercise. To check your answers go to Appendix 11.

Write the plural form of the following words. The word ending is underlined in each. Remember to use the phonetics to pronounce each word as you work through the exercises.

- |  |                |
|--|----------------|
| 1. patella (kneecap)<br><i>pah-TEL-ah</i>  | _____ patellae |
| 2. phenomenon (occurrence or perception)<br><i>feh-NOM-eh-non</i>                | _____          |
| 3. omentum (abdominal membrane)<br><i>o-MEN-tum</i>                              | _____          |
| 4. prognosis (prediction of disease outcome)<br><i>prog-NO-sis</i>               | _____          |
| 5. apex (tip or peak)<br><i>A-peks</i>   | _____          |
| 6. ovum (female reproductive cell; egg)<br><i>O-vum</i>                          | _____          |
| 7. spermatozoon (male reproductive cell; sperm cell)<br><i>sper-mah-to-ZO-on</i> | _____          |
| 8. meninx (membrane around the brain and spinal cord)<br><i>MEH-ninks</i>        | _____          |
| 9. embolus (blockage in a vessel)<br><i>EM-bo-lus</i>                            | _____          |

Write the singular form of the following words. The word ending is underlined in each.

- |   |                 |
|---|-----------------|
| 10. protozoa (single-celled animals)<br><i>pro-to-ZO-ah</i> | _____ protozoon |
| 11. appendices (things added)<br><i>ah-PEN-dih-seze</i>     | _____           |
| 12. adenomata (tumors of glands)<br><i>ad-eh-NO-mah-tab</i> | _____           |
| 13. fungi (simple, nongreen plants)<br><i>FUN-ji</i>        | _____           |
| 14. pelves (cup-shaped cavities)<br><i>PEL-veze</i>         | _____           |
| 15. foramina (openings, passageways)<br><i>fo-RAM-ih-na</i> | _____           |
| 16. curricula (series of courses)<br><i>kur-RIK-u-lah</i>   | _____           |
| 17. indices (directories, lists)<br><i>IN-dih-seze</i>      | _____           |
| 18. alveoli (small sacs)<br><i>al-VE-o-li</i>               | _____           |

## SOME EXCEPTIONS TO THE RULES

There are exceptions to the rules given for forming plurals, some of which will appear in later chapters. For example, the plural of *sinus* (space) is *sinuses*, the plural of *virus* is *viruses*, and *serums* (thin fluids) is sometimes used instead of *sera*. An *-es* ending may be added to words ending in *-ex* or *-ix* to form a plural, as in *appendixes*, *apexes*, and *indexes*.

Some incorrect plural forms are in common usage, for example, *stigmas* instead of *stigmata*, *referendums* instead of *referenda*, *stadiums* instead of *stadia*. Often people use *phalange* instead of *phalanx* as the singular of *phalanges*. Words ending in *-oma*, meaning “tumor,” should be changed to *-omata*, but most people just add an *s* to form the plural. For example, the plural of *carcinoma* (a type of cancer) should be *carcinomata*, but *carcinomas* is commonly used.

## Prefixes

A prefix is a short word part added before a word or word root to modify its meaning. For example, the word *lateral*

means “side.” Adding the prefix *uni-*, meaning “one,” forms *unilateral*, which means “affecting or involving one side.” Adding the prefix *contra-*, meaning “against or opposite,” forms *contralateral*, which refers to an opposite side. The term *equilateral* means “having equal sides.” Prefixes in this book are followed by dashes to show that word parts are added to the prefix to form a word.

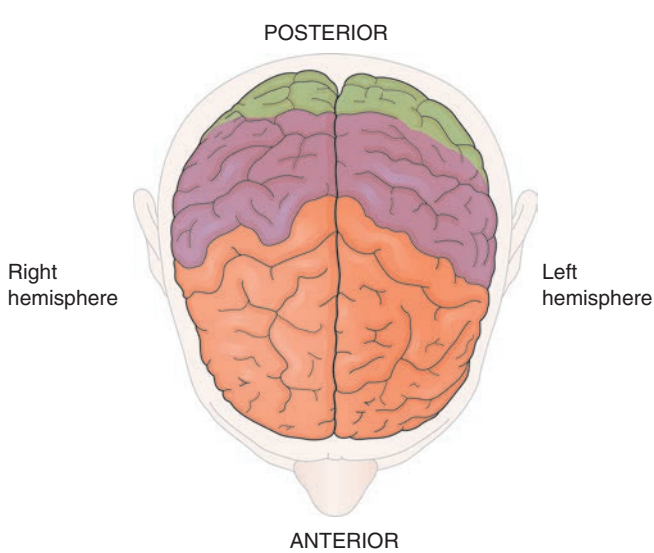
Most of the prefixes used in medical terminology are shown in **TABLES 1-5** to **1-12**. Although the list is long, almost all of the prefixes you will need to work through this book are presented here. Some additional prefixes, including those related to disease, are given in several later chapters. The meanings of many of the prefixes in this chapter are familiar to you from words that are already in your vocabulary. You may not know all the words in the exercises, but make your best guess. The words in the tables are given as examples of usage. Almost all of them reappear in other chapters. If you forget a prefix as you work, you may refer to this chapter or to the alphabetical lists of word parts and their meanings in Appendices 3 and 4. Appendix 7 lists prefixes only.

Table 1-5

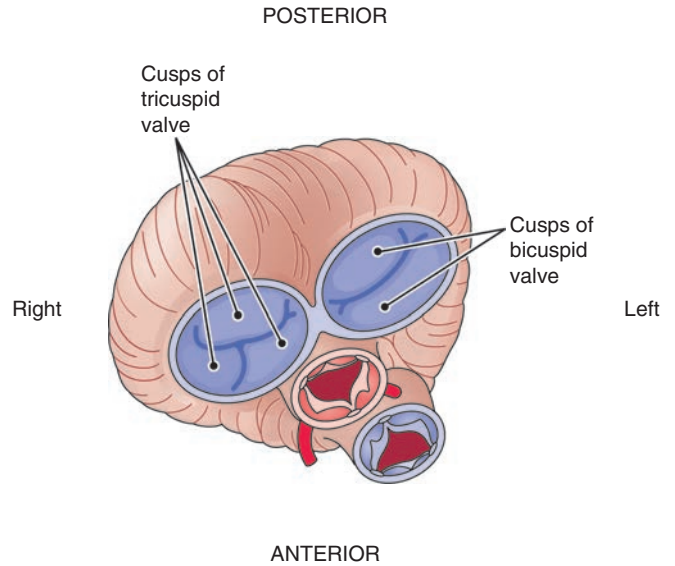
Prefixes for Numbers<sup>a</sup>

Prefix	Meaning	Example	Definition of Example
prim/i-	first	primary <i>PRI-mar-e</i>	first
mon/o-	one	monocular <i>mon-OK-u-lar</i>	having one eyepiece or affecting one eye
uni-	one	unite <i>u-NITE</i>	form into one part
hemi-	half, one side	hemisphere <i>HEM-ih-sfere</i>	one-half of a rounded structure ( <b>FIG. 1-14</b> )
semi-	half, partial	semipermeable <i>sem-e-PER-me-ah-bl</i>	partially permeable (capable of being penetrated)
bi-	two, twice	binary <i>BI-nar-e</i>	made up of two parts
di-	two, twice	diatomic <i>di-ab-TOM-ik</i>	having two atoms
dip/o-	double	diplococci <i>dip-lo-KOK-si</i>	round bacteria (cocci) that grow in groups of two
tri-	three	tricuspid <i>tri-KUS-pid</i>	having three points or cusps ( <b>FIG. 1-15</b> )
quadr/i-	four	quadruplet <i>kwah-DRUPE-let</i>	one of four babies born together
tetra-	four	tetralogy <i>tet-RAL-o-je</i>	a group of four
multi-	many	multicellular <i>mul-ti-SEL-u-lar</i>	consisting of many cells ( <b>FIG. 1-16</b> )
poly-	many, much	polymorphous <i>pol-e-MOR-fus</i>	having many forms (morph/o)

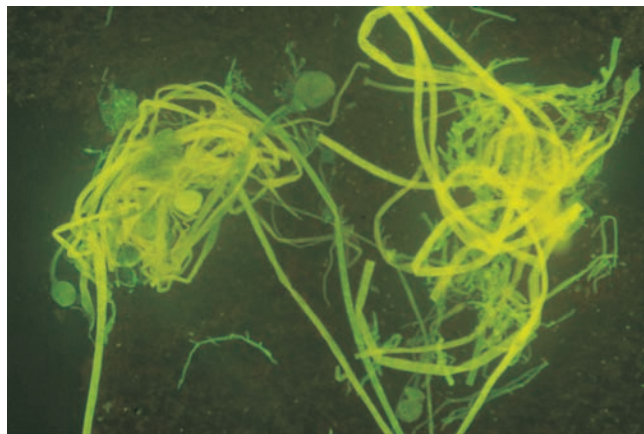
<sup>a</sup>Prefixes pertaining to the metric system are in Appendix 8-2.



**FIGURE 1-14 Brain hemispheres.** Each half of the brain is a hemisphere. The prefix *hemi-* means half or one side.



**FIGURE 1-15 Heart valves.** The valve on the heart's right side, the tricuspid, has three cusps (flaps); the valve on the heart's left side, the bicuspid, has two cusps. The prefixes *bi-* and *tri-* indicate number.



**FIGURE 1-16 A multicellular organism.** This fungus has more than one cell. It is a simple multicellular organism.

## Exercise 1-5

Complete the exercise. To check your answers go to Appendix 11.

Fill in the blanks. Use the phonetics to pronounce each word as you work through the exercises.

1. Place the following prefixes in order of increasing numbers: tri-, uni-, tetra-, bi- \_\_\_\_\_
2. A binocular (*bi-NOK-u-lar*) microscope has \_\_\_\_\_ eyepieces.
3. A quadruped (*KWAD-ru-ped*) animal walks on \_\_\_\_\_ feet (ped/o).
4. The term unilateral (*u-nih-LAT-eh-ral*) refers to \_\_\_\_\_ side (later/o).
5. The term semilunar (*sem-e-LU-nar*) means shaped like a \_\_\_\_\_ moon.
6. A diploid (*DIP-loyd*) organism has \_\_\_\_\_ sets of chromosomes (-ploid).

(continued)

## Exercise 1-5 (Continued)

7. A tetrad (*TET-rad*) has \_\_\_\_\_ components.
8. A tripod (*TRI-pod*) has \_\_\_\_\_ legs.
9. Monophonic (*mon-o-FON-ik*) sound has \_\_\_\_\_ channel.

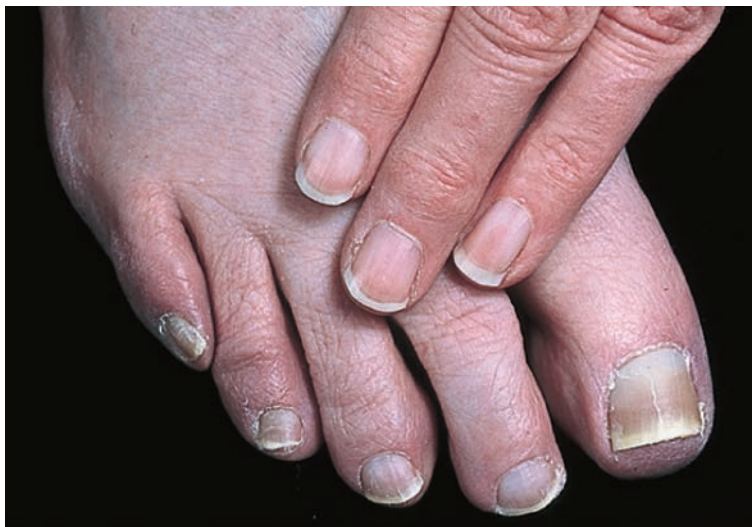Give a prefix that is similar in meaning to each of the following.

10. di- \_\_\_\_\_
11. poly- \_\_\_\_\_
12. hemi- \_\_\_\_\_
13. mon/o- \_\_\_\_\_

Table 1-6

### Prefixes for Colors

Prefix	Meaning	Example	Definition of Example
cyan/o-	blue	cyanosis <i>si-ab-NO-sis</i>	bluish discoloration of the skin due to lack of oxygen ( <b>FIG. 1-17</b> )
erythr/o-	red	erythrocyte <i>eh-RITH-ro-site</i>	red blood cell (-cyte)
leuk/o-	white, colorless	leukemia <i>lu-KE-me-ab</i>	cancer of white blood cells
melan/o-	black, dark	melanin <i>MEL-ab-nin</i>	the dark pigment that colors the hair and skin
xanth/o-	yellow	xanthoma <i>zan-THO-mah</i>	yellow growth (-oma) on the skin



**FIGURE 1-17 Cyanosis, a bluish discoloration.** This abnormal coloration is seen in the toenails and toes, as compared to the normal coloration of the fingertips. The prefix *cyan/o-* means “blue.”

**Exercise 1-6**

Complete the exercise. To check your answers go to Appendix 11.

Match the following terms, and write the appropriate letter to the left of each number.

- |   |                                       |
|---|---------------------------------------|
| ___ 1. melanocyte ( <i>MEL-ab-no-site</i> )   | a. pertaining to bluish discoloration |
| ___ 2. xanthoderma ( <i>zan-tho-DER-mah</i> ) | b. redness of the skin                |
| ___ 3. cyanotic ( <i>si-ab-NOT-ik</i> )       | c. yellow coloration of the skin      |
| ___ 4. erythema ( <i>eh-RIH-the-mah</i> )     | d. cell that produces dark pigment    |
| ___ 5. leukocyte ( <i>LU-ko-site</i> )        | e. white blood cell                   |

1

Table 1-7 Negative Prefixes

Prefix	Meaning	Example	Definition of Example
a-, an-	not, without, lack of, absence	anhydrous <i>an-HI-drus</i>	lacking water (hydr/o)
anti-	against	antiseptic <i>an-tih-SEP-tik</i>	agent used to prevent infection (sepsis)
contra-	against, opposite, opposed	contraindicated <i>kon-trah-IN-dih-ka-ted</i>	against recommendations, not advisable
de-	down, without, removal, loss	decalcify <i>de-KAL-sib-fi</i>	remove calcium (calc/i) from
dis-	absence, removal, separation	dissect <i>dih-SEKT</i>	to separate tissues for anatomic study
in- <sup>a</sup> , im- (used before b, m, p)	not	incontinent <i>in-KON-tih-nent</i>	not able to contain or control discharge of excretions
non-	not	noncontributory <i>non-kon-TRIB-u-tor-e</i>	not significant, not adding information to a medical diagnosis
un-	not	uncoordinated <i>un-ko-OR-dih-na-ted</i>	not working together, not coordinated

<sup>a</sup>May also mean “in” or “into” as in inject, inhale.

**Exercise 1-7**

Complete the exercise. To check your answers go to Appendix 11.

Identify and define the prefix in the following words.

	Prefix	Meaning of Prefix
1. aseptic	a	not, without, lack of, absence
2. antidote	_____	_____
3. amnesia	_____	_____
4. disintegrate	_____	_____
5. contraception	_____	_____
6. inadequate	_____	_____

(continued)



## Exercise 1-7 (Continued)

7. depilatory

8. nonconductor

Add a prefix to form the negative of the following words.

9. conscious

10. significant

11. infect

12. usual

13. specific

14. congestant

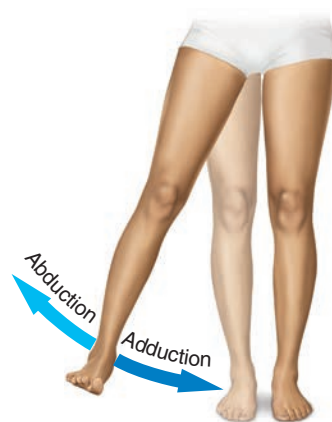15. compatible

unconscious

Table 1-8

### Prefixes for Direction

Prefix	Meaning	Example	Definition of Example
ab-	away from	abduct <i>ab-DUKT</i>	to move away from the midline ( <b>FIG. 1-18</b> )
ad-	toward, near	adduct <i>ad-DUKT</i>	to move toward the midline (see <b>FIG. 1-18</b> )
dia-	through	diarrhea <i>di-ab-RE-ab</i>	frequent discharge of fluid fecal matter
per-	through	percutaneous <i>per-ku-TA-ne-us</i>	through the skin
trans-	through	transected <i>tran-SEKT-ed</i>	cut (sectioned) through or across



**FIGURE 1-18 Abduction and adduction.** The prefix *ab-* means “away from”; the leg is moved away from the body in abduction. The prefix *ad-* means “toward”; the leg is moved toward the body in adduction.

## Exercise 1-8

Complete the exercise. To check your answers go to Appendix 11.

Identify and define the prefix in the following words.

	Prefix	Meaning of Prefix
1. dialysis	dia	through
2. percolate	_____	_____
3. adjacent	_____	_____
4. absent	_____	_____
5. diameter	_____	_____
6. transport	_____	_____

Table 1-9

### Prefixes for Degree

Prefix	Meaning	Example	Definition of Example
hyper-	over, excess, abnormally high, increased	hyperthermia <i>hi-per-THER-me-ah</i>	high body temperature
hypo- <sup>a</sup>	under, below, abnormally low, decreased	hyposecretion <i>hi-po-se-KRE-shun</i>	underproduction of a substance
olig/o-	few, scanty	oligospermia <i>ol-ih-go-SPER-me-ah</i>	abnormally low number of sperm cells in semen
pan-	all	pandemic <i>pan-DEM-ik</i>	disease affecting an entire population
super- <sup>a</sup>	above, excess	supernumerary <i>su-per-NU-mer-ar-e</i>	in excess number

<sup>a</sup>May also indicate position, as in hypodermic, superficial.

## Exercise 1-9

Complete the exercise. To check your answers go to Appendix 11.

Match the following terms, and write the appropriate letter to the left of each number.

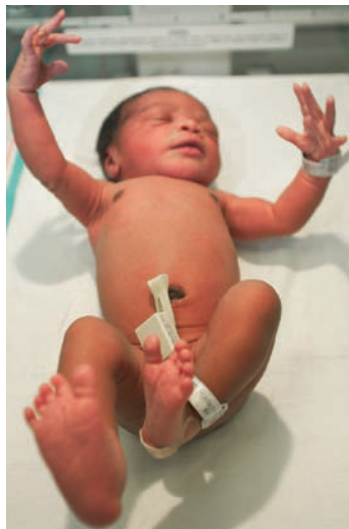- |   |   |
|---|---|
| ___ 1. hypotensive ( <i>hi-po-TEN-siv</i> )               | a. excess breathing                     |
| ___ 2. oligodontia ( <i>ol-ih-go-DON-she-ah</i> )         | b. something written above              |
| ___ 3. panplegia ( <i>pan-PLE-je-ah</i> )                 | c. having low blood pressure            |
| ___ 4. superscript ( <i>SU-per-skript</i> )               | d. total paralysis                      |
| ___ 5. hyperventilation ( <i>hi-per-ven-tih-LA-shun</i> ) | e. less than the normal number of teeth |

Table 1-10

## Prefixes for Size and Comparison

Prefix	Meaning	Example	Definition of Example
equi-	equal, same	equilibrium <i>e-kwib-LIB-re-um</i>	a state of balance, state in which conditions remain the same
eu-	true, good, easy, normal	euthanasia <i>u-thab-NA-ze-ab</i>	easy or painless death (thanat/o)
hetero-	other, different, unequal	heterogeneous <i>het-er-o-JE-ne-us</i>	composed of different materials, not uniform
homo-, homeo-	same, unchanging	homograft <i>HO-mo-graft</i>	tissue transplanted to another of the same species
iso-	equal, same	isocellular <i>i-so-SEL-u-lar</i>	composed of similar cells
macro-	large, abnormally large	macroscopic <i>mak-ro-SKOP-ik</i>	large enough to be seen without a microscope
mega- <sup>a</sup> , megal/o	large, abnormally large	megacolon <i>meg-ab-KO-lon</i>	enlargement of the colon
micro- <sup>a</sup>	small	microcyte <i>MI-kro-site</i>	very small cell (-cyte)
neo-	new	neonate <i>NE-o-nate</i>	a newborn infant ( <b>FIG. 1-19</b> )
normo-	normal	normovolemia <i>nor-mo-vol-E-me-ab</i>	normal blood volume
ortho-	straight, correct, upright	orthodontics <i>or-tho-DON-tiks</i>	branch of dentistry concerned with correction and straightening of the teeth (odont/o)
poikilo-	varied, irregular	poikilothermic <i>poy-kih-lo-THER-mik</i>	having variable body temperature (therm/o)
pseudo-	false	pseudoplegia <i>su-do-PLE-je-ab</i>	false paralysis (-plegia)
re-	again, back	reflux <i>RE-flux</i>	backward flow

<sup>a</sup>Mega- also means 1 million, as in megahertz. Micro- also means 1 millionth, as in microsecond.



**FIGURE 1-19** A neonate or newborn. The prefix *neo-* means “new.”

**Exercise 1-10**

Complete the exercise. To check your answers go to Appendix 11.

Match the following terms, and write the appropriate letter to the left of each number.

- |   |  |
|---|--|
| ___ 1. isograft ( <i>I-so-graft</i> )             | a. having a constant body temperature                |
| ___ 2. orthotic (or- <i>THOT-ik</i> )             | b. irregular, mottled condition of the skin          |
| ___ 3. pseudoreaction ( <i>su-do-re-AK-shun</i> ) | c. false response                                    |
| ___ 4. poikiloderma ( <i>poy-kil-o-DER-mah</i> )  | d. tissue transplanted between identical individuals |
| ___ 5. homothermic ( <i>ho-mo-THER-mik</i> )      | e. straightening or correcting deformity             |

Identify and define the prefix in the following words.

	Prefix	Meaning of Prefix
6. homeostasis	homeo	same, unchanging
7. equivalent	_____	_____
8. orthopedics	_____	_____
9. rehabilitation	_____	_____
10. euthyroidism	_____	_____
11. neocortex	_____	_____
12. megabladder	_____	_____
13. isometric	_____	_____
14. normothermic	_____	_____

Write the opposite of the following words.

- |  |       |
|--|-------|
| 15. homogeneous (of uniform composition)<br><i>ho-mo-JE-ne-us</i>                  | _____ |
| 16. macroscopic (large enough to see with the naked eye)<br><i>mah-kro-SKOP-ik</i> | _____ |

**Table 1-11 Prefixes for Time and/or Position**

Prefix	Meaning	Example	Definition of Example
ante-	before	antenatal <i>an-te-NA-tal</i>	before birth (nat/i)
pre-	before, in front of	premature <i>pre-mah-CHUR</i>	occurring before the proper time
pro-	before, in front of	prodrome <i>PRO-drome</i>	symptom that precedes a disease
post-	after, behind	postnasal <i>post-NA-sal</i>	behind the nose (nas/o)

## Exercise 1-11

Complete the exercise. To check your answers go to Appendix 11.

Match the following terms, and write the appropriate letter to the left of each number.

- |   |                                   |
|---|-----------------------------------|
| ___ 1. postmortem ( <i>post-MOR-tem</i> )   | a. to occur before another event  |
| ___ 2. antedate ( <i>AN-te-date</i> )       | b. ancestor, one who comes before |
| ___ 3. progenitor ( <i>pro-JEN-ih-tor</i> ) | c. before birth (parturition)     |
| ___ 4. prepartum ( <i>pre-PAR-tum</i> )     | d. throwing or extending forward  |
| ___ 5. projectile ( <i>pro-JEK-tile</i> )   | e. occurring after death          |

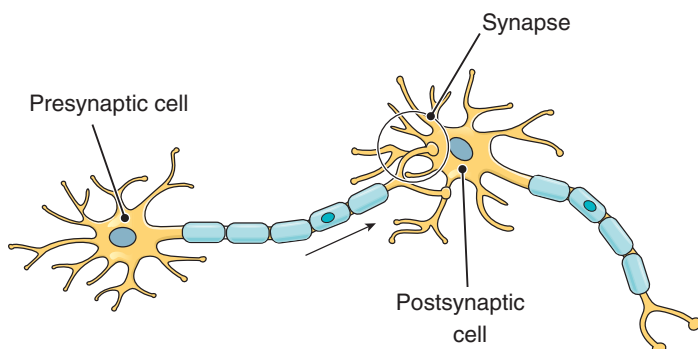
Identify and define the prefix in the following words.

	Prefix	Meaning of Prefix
6. prediction ( <i>pre-DIK-shun</i> )	pre	before, in front of
7. postmenopausal ( <i>post-men-o-PAW-zal</i> )	_____	_____
8. procedure ( <i>pro-SE-jur</i> )	_____	_____
9. predisposing ( <i>pre-dis-PO-zing</i> )	_____	_____
10. antepartum ( <i>an-te-PAR-tum</i> )	_____	_____

Table 1-12

Prefixes for Position

Prefix	Meaning	Example	Definition of Example
dextr/o-	right	dextrogastria <i>deks-tro-GAS-tre-ah</i>	displacement of the stomach (gastr/o) to the right
sinistr/o-	left	sinistromanual <i>sin-is-tro-MAN-u-al</i>	left-handed
ec-, ecto-	out, outside	ectopic <i>ek-TOP-ik</i>	out of normal position
ex/o-	away from, outside	excise <i>ek-SIZE</i>	to cut out
end/o-	in, within	endoderm <i>EN-do-derm</i>	inner layer of a developing embryo
mes/o-	middle	mesencephalon <i>mes-en-SEF-ab-lon</i>	middle portion of the brain (encephalon), midbrain
syn-, sym- (used before b, m, p)	together	synapse <i>SIN-aps</i>	a junction between two nerve cells (FIG. 1-20)
tel/e-, tel/o-	end, far, at a distance	teletherapy <i>tel-eh-THER-ab-pe</i>	radiation therapy delivered at a distance from the body



**FIGURE 1-20 A synapse.** Nerve cells come together at a synapse, as shown by the prefix *syn-*. The presynaptic cell is located before (prefix *pre-*) the synapse; the postsynaptic cell is located after (prefix *post-*) the synapse.

## Exercise 1-12

Complete the exercise. To check your answers go to Appendix 11.

Match the following terms, and write the appropriate letter to the left of each number.

- |  |   |
|--|---|
| ___ 1. mesoderm ( <i>MES-o-derm</i> )                | a. displacement of the heart to the left        |
| ___ 2. symbiosis ( <i>sim-bi-O-sis</i> )             | b. device for viewing the inside of a structure |
| ___ 3. sinistocardia ( <i>sin-is-tro-KAR-de-ab</i> ) | c. two organisms living together                |
| ___ 4. endoscope ( <i>EN-do-skope</i> )              | d. last stage of cell division (mitosis)        |
| ___ 5. telephase ( <i>TEL-eh-faze</i> )              | e. middle layer of a developing embryo          |

Identify and define the prefix in the following words.

	Prefix	Meaning of Prefix
6. sympathetic ( <i>sim-pah-THET-ik</i> )	sym	together
7. extract ( <i>EKS-tract</i> )	_____	_____
8. ectoparasite ( <i>ek-to-PAR-ab-site</i> )	_____	_____
9. syndrome ( <i>SIN-drome</i> )	_____	_____
10. endotoxin ( <i>en-do-TOX-in</i> )	_____	_____

Write the opposite of the following words.

11. exogenous (outside the organism) <i>eks-OJ-eh-nus</i>	_____	_____
12. dextromanual (right-handed) <i>deks-tro-MAN-u-al</i>	_____	_____
13. ectoderm (outermost layer of the embryo) <i>EK-to-derm</i>	_____	_____

## Case Study Revisited

### David's Follow-up

David took the recommendations and instructions from the gastroenterologist seriously. He was aware of the consequences of GERD since his father had undergone a surgical procedure for it 2 years ago. David's father had allowed his symptoms to go untreated which caused damage to his esophagus requiring surgery. Even after surgery, David's father continues to have ongoing issues due to his noncompliance with meds and obesity. David saw first-hand what he could be facing if he did not take care of his health.

David knew he had a lot to accomplish prior to his 3-month follow-up with his physician. He followed the dosage instructions on his Prevacid and made sure he stopped by the student health center to have his

monthly prescriptions filled. David also joined the local health club where he received a student discount. The club allowed free sessions with a personal trainer who helped David develop an exercise routine along with some diet tips. Soon David developed friendships with others at the club and began playing racquetball.

At his 3-month follow-up appointment, David reported no repeat episodes of epigastric pain. He completed his prescription of Prevacid, lost 10 pounds, changed his diet, and with the advice of his educational counselor cut back on some of his classes for the new semester. The gastroenterologist concluded that David's initial experience with epigastric pain was most likely due to gastroesophageal reflux (GER) and had been relieved by Prevacid and through David's lifestyle changes.



This review tests your understanding of the content introduced in this chapter. Follow the instructions for each exercise and check your answers in Appendix 11.

### MULTIPLE CHOICE

Select the best answer and write the letter of your choice to the left of each number.

- \_\_\_\_\_ 1. *Epi-* in the term *epigastric* is a
- word root
  - prefix
  - suffix
  - combining form
- \_\_\_\_\_ 2. The *-oid* in the term *xiphoid* is a
- root
  - prefix
  - derivation
  - suffix
- \_\_\_\_\_ 3. The term *musculoskeletal* is a(n)
- abbreviation
  - word root
  - combining form
  - compound word
- \_\_\_\_\_ 4. The adjective for *larynx* is
- larynxic
  - laryngeal
  - larynal
  - largeal
- \_\_\_\_\_ 5. The combining form for *thorax* (chest) is
- thorax/o
  - thor/o
  - thorac/o
  - thori/o
- \_\_\_\_\_ 6. In David's case study, the term GERD represents a(n)
- combining form
  - acronym
  - prefix
  - suffix
- \_\_\_\_\_ 7. In David's case study, the *ph* in *dysphagia* is pronounced as
- f
  - p
  - h
  - s

**FILL IN THE BLANKS**

Complete the sentence with the correct term(s).

8. A root with a vowel added to aid in pronunciation is called a(n) \_\_\_\_\_.
9. Combine the word parts *dia-*, meaning “through,” and *-rhea*, meaning “flow,” to form a word meaning “passage of fluid stool” \_\_\_\_\_.
10. The abbreviation ETOH means (refer to Appendix 2) \_\_\_\_\_.
11. Use Appendix 3 to find that the suffix in *gastroduodenoscopy*, seen in David’s opening case study, means \_\_\_\_\_.
12. Combine the root *cardi*, meaning “heart,” with the suffix *-logy*, meaning “study of,” to form a word meaning “study of the heart” \_\_\_\_\_.
13. The suffix *-al*, as in *esophageal*, seen in David’s case study follow-up means \_\_\_\_\_.
14. Appendix 1 shows that the symbol ↑ means \_\_\_\_\_.
15. A monocle has \_\_\_\_\_ lens(es).
16. A triplet is one of \_\_\_\_\_ babies born together.
17. Sinistrad means toward the \_\_\_\_\_.
18. A disaccharide is a sugar composed of \_\_\_\_\_ subunits.
19. A contralateral structure is located on the side \_\_\_\_\_ to a given point.
20. A tetralogy is composed of \_\_\_\_\_ part(s).

Identify the suffix that means “condition of” in the following words. Remember to use the phonetics in the following exercises to pronounce each word as you work.

21. alcoholism (*AL-ko-hol-izm*) (alcohol dependence) \_\_\_\_\_
22. insomnia (*in-SOM-ne-ah*) (inability to sleep; root: somn/o) \_\_\_\_\_
23. acidosis (*as-ih-DO-sis*) (acid body condition) \_\_\_\_\_
24. dysentery (*DIS-en-ter-e*) (intestinal disorder; root: enter/o) \_\_\_\_\_
25. psychosis (*si-KO-sis*) (disorder of the mind) \_\_\_\_\_
26. anemia (*ah-NE-me-ah*) (lack of blood or hemoglobin; root: hem/o) \_\_\_\_\_

Give the suffix in the following words that means “specialty” or “specialist.”

27. psychiatry (*si-KI-ah-tre*) \_\_\_\_\_
28. orthopedics (*or-tho-PE-diks*) \_\_\_\_\_
29. anesthesiologist (*an-es-the-ze-OL-o-jist*) \_\_\_\_\_
30. technician (*tek-NISH-un*) \_\_\_\_\_
31. obstetrician (*ob-steh-TRISH-un*) \_\_\_\_\_

Give the name of a specialist in the following fields.

32. dermatology (*der-mah-TOL-o-je*) \_\_\_\_\_
33. pediatrics (*pe-de-AH-triks*) \_\_\_\_\_
34. physiology (*fiz-e-OL-o-je*) \_\_\_\_\_
35. gynecology (*gi-neh-KOL-o-je*) \_\_\_\_\_



Identify the adjective suffix in the following words that means “pertaining to,” “like,” or “resembling.”

36. anxious (ANG-*shus*) \_\_\_\_\_
37. fibroid (FI-*broyd*) \_\_\_\_\_
38. arterial (ar-TE-*re-al*) \_\_\_\_\_
39. pelvic (PEL-*vik*) \_\_\_\_\_
40. binary (BI-*nar-e*) \_\_\_\_\_
41. skeletal (SKEL-*eh-tal*) \_\_\_\_\_
42. rheumatoid (RU-*mab-toyd*) \_\_\_\_\_
43. febrile (FEB-*rile*) \_\_\_\_\_
44. vascular (VAS-*ku-lar*) \_\_\_\_\_
45. exploratory (ek-SPLOR-*ah-tor-e*) \_\_\_\_\_

### PLURALS

Write the plural for the following words. Each word ending is underlined.

46. gingiva (JIN-*jih-vah*) (gum) \_\_\_\_\_
47. testis (TEST-*is*) (male reproductive organ) \_\_\_\_\_
48. criterion (kri-TIR-*e-on*) (standard) \_\_\_\_\_
49. lumenu (LU-*men*) (central opening) \_\_\_\_\_
50. locus (LO-*kus*) (place) \_\_\_\_\_
51. ganglion (GANG-*le-on*) (mass of nervous tissue) \_\_\_\_\_
52. larynx (LAR-*inks*) (voice box) \_\_\_\_\_
53. nucleus (NU-*kle-us*) (center; core) \_\_\_\_\_

### SINGULARS

Write the singular form for the following words. Each word ending is underlined.

54. thrombi (THROM-*bi*) (blood clots) \_\_\_\_\_
55. vertebraee (VER-*teh-bre*) (bones of the spine) \_\_\_\_\_
56. bacteriaa (bak-TE-*re-ah*) (type of microorganism) \_\_\_\_\_
57. alveolii (al-VE-*oli*) (air sacs) \_\_\_\_\_
58. apicese (A-*pih-seze*) (high points, tips) \_\_\_\_\_
59. foraminaa (fo-RAM-*ih-nah*) (openings) \_\_\_\_\_
60. diagnosese (di-ag-NO-*seze*) (identifications of disease) \_\_\_\_\_
61. carcinomataa (kar-sih-NO-*mah-tab*) (cancers) \_\_\_\_\_

### DEFINITIONS

Identify and define the prefix in the following words.

- |                   | Prefix | Meaning of Prefix |
|-------------------|--------|-------------------|
| 62. hyperactive   | _____  | _____             |
| 63. transfer      | _____  | _____             |
| 64. posttraumatic | _____  | _____             |
| 65. regurgitate   | _____  | _____             |
| 66. extend        | _____  | _____             |

- 67. adhere \_\_\_\_\_
- 68. unusual \_\_\_\_\_
- 69. detoxify \_\_\_\_\_
- 70. semisolid \_\_\_\_\_
- 71. premenstrual \_\_\_\_\_
- 72. perforate \_\_\_\_\_
- 73. dialysis (*di-AL-ib-sis*) \_\_\_\_\_
- 74. antibody \_\_\_\_\_
- 75. microsurgery \_\_\_\_\_
- 76. disease \_\_\_\_\_
- 77. endoparasite \_\_\_\_\_
- 78. symbiotic (*sim-bi-OT-ik*) \_\_\_\_\_
- 79. prognosis (*prog-NO-sis*) \_\_\_\_\_
- 80. insignificant \_\_\_\_\_

**OPPOSITES**

Write a word that means the opposite of each of the following.

- 81. humidify \_\_\_\_\_
- 82. permeable \_\_\_\_\_
- 83. heterogeneous \_\_\_\_\_
- 84. exotoxin \_\_\_\_\_
- 85. microscopic \_\_\_\_\_
- 86. hyperventilation \_\_\_\_\_
- 87. postsynaptic \_\_\_\_\_
- 88. septic \_\_\_\_\_

**SYNONYMS**

Write a synonym (a word having the same or nearly the same meaning as another word) in each of the following blanks.

- 89. supersensitivity \_\_\_\_\_
- 90. megalocyte (extremely large red blood cell) \_\_\_\_\_
- 91. antenatal \_\_\_\_\_
- 92. isolateral (having equal sides) \_\_\_\_\_

**TRUE-FALSE**

Examine the following statements. If the statement is true, write T in the first blank. If the statement is false, write F in the first blank, and correct the statement by replacing the underlined word in the second blank.

- |   | True or False | Correct Answer |
|---|---------------|----------------|
| 93. Immune cells are primed by their <u>first</u> exposure to a disease organism. | T             | _____          |
| 94. Unicellular organisms are composed of <u>10</u> cells.                        | F             | one cell       |
| 95. To bisect is to cut into <u>two</u> parts.                                    | _____         | _____          |
| 96. A tetrad has <u>five</u> parts  | _____         | _____          |

97. In Latin, the oculus dexter is the left eye. \_\_\_\_\_
98. A triceps muscle has six parts. \_\_\_\_\_
99. A polygraph measures many physiologic responses. \_\_\_\_\_

**PRONUNCIATION**

*Pronounce the following words.*

100. dyslexia  
 101. rheumatism  
 102. pneumatic  
 103. chemist  
 104. pharmacy

*Pronounce the following phonetic forms and write the words they represent.*

105. KAR-de-ak \_\_\_\_\_
106. HI-dro-jen \_\_\_\_\_
107. OK-u-lar \_\_\_\_\_
108. ru-MAT-ik \_\_\_\_\_

**MATCHING**

*Match the following terms, and write the appropriate letter to the left of each number.*

- |                         |                                      |
|-------------------------|--------------------------------------|
| _____ 109. primitive    | a. one-half or one side of the chest |
| _____ 110. biceps       | b. having two forms                  |
| _____ 111. unify        | c. combine into one part             |
| _____ 112. dimorphous   | d. a muscle with two parts           |
| _____ 113. hemithorax   | e. occurring first in time           |
| _____ 114. erythematous | a. cell with yellow color            |
| _____ 115. melanoma     | b. having a bluish discoloration     |
| _____ 116. xanthocyte   | c. darkly pigmented tumor            |
| _____ 117. cyanotic     | d. red in color                      |
| _____ 118. leukocyte    | e. white blood cell                  |

*Match each of the following prefixes with its meaning.*

- |                     |                      |
|---------------------|----------------------|
| _____ 119. poikilo- | a. good, true, easy  |
| _____ 120. eu-      | b. straight, correct |
| _____ 121. ortho-   | c. false             |
| _____ 122. pseudo-  | d. few, scanty       |
| _____ 123. oligo-   | e. varied, irregular |

**WORD BUILDING**

*Write words for the following definitions using the word parts provided. A combining vowel is included. Each word part can be used more than once.*

-itis	-logy	-ptosis	neph	-o	gastr	cardi	neur-
-------	-------	---------	------	----	-------	-------	-------

124. Inflammation of the stomach \_\_\_\_\_ gastritis
125. Study of the nervous system \_\_\_\_\_

126. Dropping of the kidney \_\_\_\_\_
127. Study of the kidney \_\_\_\_\_
128. Inflammation of a nerve \_\_\_\_\_
129. Downward displacement of the heart \_\_\_\_\_

Write words for the following definitions using the word parts provided. Each word part may be used more than once.

mon/o -al dextr/o end/o macro cardi cyt -ic ecto micro -ia

130. Pertaining to a very small cell \_\_\_\_\_
131. A condition in which the heart is outside its normal position \_\_\_\_\_
132. Pertaining to a cell with a single nucleus \_\_\_\_\_
133. Condition in which the heart is displaced to the right \_\_\_\_\_
134. Pertaining to the innermost layer of the heart \_\_\_\_\_
135. Pertaining to a very large cell \_\_\_\_\_
136. Condition in which the heart is extremely small \_\_\_\_\_

### WORD ANALYSIS

Define each of the following words, and give the meaning of the word parts in each. Use a dictionary if necessary. Remember to use the phonetics to pronounce each word as you work through the exercise.

137. renogastric (*re-no-GAS-trik*)
- a. ren/o \_\_\_\_\_
- b. gastr/o \_\_\_\_\_
- c. -ic \_\_\_\_\_
138. geriatrician (*jer-e-ah-TRIH-shun*)
- a. ger/e \_\_\_\_\_
- b. iatr/o \_\_\_\_\_
- c. -ic \_\_\_\_\_
- d. -ian \_\_\_\_\_
139. isometric (*i-so-MET-rik*)
- a. iso- \_\_\_\_\_
- b. metr/o \_\_\_\_\_
- c. -ic \_\_\_\_\_
140. symbiosis (*sim-be-O-sis*)
- a. sym- \_\_\_\_\_
- b. bio \_\_\_\_\_
- c. -sis \_\_\_\_\_

# Additional Case Studies

## Case Study 1-1: Greg's Arthritic Knees

### Chief Complaint

Greg, a 68 y/o male, presents to his family doctor c/o bilateral knee discomfort that worsens prior to a heavy rainstorm. He states that his "arthritis" is not getting any better. He has been taking NSAIDs but is not obtaining relief at this point. His family physician referred him to an orthopedic surgeon for further evaluation.

### Past Medical History

Greg was active in sports in high school and college. He tore his ACL while playing soccer during his junior year in college, at which time he retired from intercollegiate

athletics. His only other physical complaint involves stiffness in his right shoulder, which he attributes to pitching while playing baseball in high school.

### Current Medications

NSAIDs prn for arthritic pain; Lipitor 10 mg for mild hyperlipidemia.

### X-Rays

Bilateral knee x-rays revealed moderate degenerative changes with joint space narrowing in the left knee; severe degenerative changes and joint space narrowing in the right knee.

## Case Study 1-1 Questions

**Multiple Choice.** Select the best answer, and write the letter of your choice to the left of each number. To check your answers go to Appendix 11.

- \_\_\_\_\_ 1. The *bi-* in the word *bilateral* is a  
a. suffix  
b. root  
c. prefix  
d. combining form
- \_\_\_\_\_ 2. The *-itis* in the word *arthritis* is a  
a. root  
b. prefix  
c. derivation  
d. suffix

- \_\_\_\_\_ 3. *Arthr/o* is a(n)  
a. combining form  
b. acronym  
c. prefix  
d. suffix
- \_\_\_\_\_ 4. The *AI* in the abbreviation *NSAID* means (see Appendix 2)  
a. antacid  
b. anti-inflammatory  
c. anti-infectious  
d. after incident

Fill in the blank with the correct answer.

5. Use Appendix 2 to find what the abbreviation *ACL* means.  
\_\_\_\_\_
6. Use Appendix 2 to find what the abbreviation *c/o* means.  
\_\_\_\_\_
7. Use Appendix 7 to find what the prefix *hyper-* means.  
\_\_\_\_\_
8. Use Appendix 2 to find what the abbreviation *prn* means.  
\_\_\_\_\_
9. Use Appendices 5, 6, and 7 to find what the word parts in *hyperlipidemia* mean.  
a. hyper- \_\_\_\_\_  
b. lip/o \_\_\_\_\_  
c. -emia \_\_\_\_\_

10. Use Appendix 3 to find what the word parts in *orthopedic* mean.

a. orth/o \_\_\_\_\_

b. ped/o \_\_\_\_\_

11. Use Appendix 7 to find what the prefix *inter-* means.

\_\_\_\_\_

1

## Case Study 1-2: Sally's Job-Related Breathing Problems

### Chief Complaint

Sally, a 54 y/o woman, has been having difficulty breathing (dyspnea) that was originally attributed to a left upper lobe (LUL) pneumonia. She was treated with an antibiotic, and after no improvement was noted in her breathing, Sally had a follow-up chest x-ray that revealed a small LUL pneumothorax. She was referred to the respiratory clinic and saw Dr. Williams, a pulmonologist.

### Past Medical History

Sally has a history of smoking a pack of cigarettes a day for 30 years but stopped smoking 2 years ago. She noticed an improvement in her breathing and tired less easily after she quit. About 1 month ago, she complained of general malaise, dyspnea, and a productive cough; she was expectorating pus-containing (purulent) sputum and was febrile. The chest radiograph and sputum cultures indicate

that her symptoms had progressed into a bronchopneumonia with pulmonary edema complicated by a small pneumothorax in the LUL. A pea-size mass was identified in the left lobe. Also noted, Sally is a hairstylist as well as a manicurist and recently went back to work in a beauty salon. She has complained that the fumes from the hair chemicals and nail products affect her breathing.

### Clinical Course

Dr. Williams performed a bronchoscopic examination. During the examination, she took a biopsy of the mass, and the results were negative. Sputum cultures were also taken to determine the spectrum of action of an appropriate antibiotic. A respiratory therapist measured Sally's respiratory volumes and recorded any changes. Sally was told to drink plenty of liquids, get proper rest, and refrain from working for 1 week. She was told to wear a mask when she returned to work, avoid unventilated areas in the salon, and avoid the chemical fumes as much as possible. She was given an appointment to return to the clinic in 1 month for follow-up.

## Case Study 1-2 Questions

**Multiple Choice.** Select the best answer, and write the letter of your choice to the left of each number. To check your answers go to Appendix 11.

\_\_\_\_\_ 1. The *gh* in the terms cough and radiograph is pronounced as

- a. g
- b. h
- c. f
- d. s

\_\_\_\_\_ 2. The *pn* in the term bronchopneumonia is pronounced as

- a. p
- b. n
- c. f
- d. s

- \_\_\_\_\_ 3. Which of the following is a compound word?
- pulmonary
  - pneumothorax
  - respiratory
  - antibiotic
- \_\_\_\_\_ 4. The suffix that means “condition of” in *pneumonia* is
- nia
  - monia
  - ia
  - onia

- \_\_\_\_\_ 5. The plural of *spectrum* is
- spectra
  - spectria
  - spectrina
  - spectrums

Fill in the blank with the correct answer.

6. Find four words in the case study with a suffix that means “specialist in a field.”


- \_\_\_\_\_
- \_\_\_\_\_
- \_\_\_\_\_
- \_\_\_\_\_

7. Find five words in the case study with suffixes that mean “pertaining to, like, or resembling,” and write both the suffix and the word that contains it.

Suffix	Word
1. _____	_____
2. _____	_____
3. _____	_____
4. _____	_____
5. _____	_____

### Case Study 1-3: Displaced Fracture of the Femoral Neck

While walking home from the train station, Esther, a 72 y/o woman with pre-existing osteoporosis, tripped over a raised curb and fell. In the emergency department, she was assessed for severe pain, and swelling and bruising of her right thigh. A radiograph (x-ray) showed a fracture at the neck of the right femur (thigh bone) (FIG. 1-21). Esther was prepared for surgery and given a preoperative injection of an analgesic to relieve her pain. During surgery, she was given spinal anesthesia and positioned on an operating room table, with her right hip elevated on a small pillow. Intravenous antibiotics were given before the incision was made. Her right hip was repaired with a bipolar hemiarthroplasty (joint reconstruction). Postoperative care included maintaining the right hip in abduction, fluid replacement, physical therapy, and attention to signs of tissue degeneration and possible dislocation.



Anterior view

**FIGURE 1-21** The right femur (thigh bone). The femoral neck is the fracture site in Case Study 1-3.

### Case Study 1-3 Questions

Identify and define the prefixes in the following words. To check your answers go to Appendix 11.

	Prefix	Meaning of Prefix
1. pre-existing	_____	_____
2. analgesic, anesthesia	_____	_____
3. dislocation	_____	_____
4. replacement	_____	_____
5. bipolar	_____	_____
6. hemiarthroplasty	_____	_____
7. degeneration	_____	_____

Fill in the blanks.

8. The suffixes in the words osteoporosis and anesthesia mean \_\_\_\_\_.
9. The suffixes in the words intravenous, femoral, and analgesic mean \_\_\_\_\_.

Find a word in the case study that describes the following.

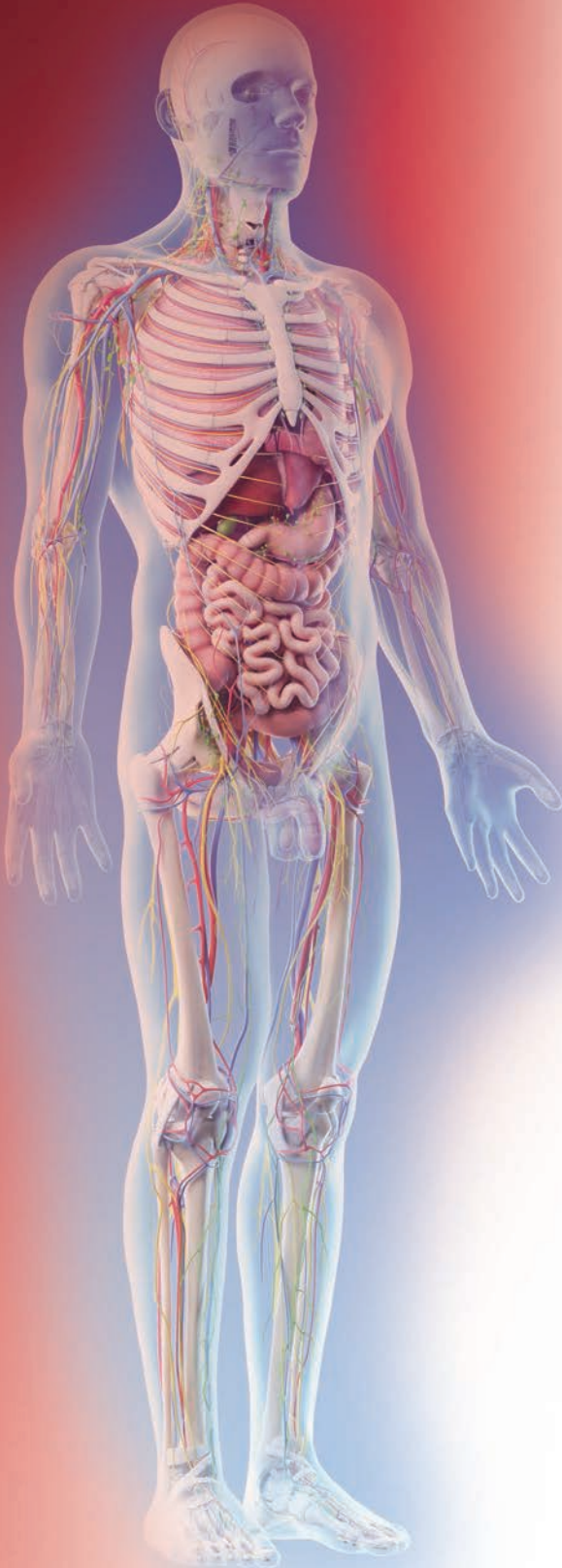10. The time period before surgery \_\_\_\_\_
11. The time period after surgery \_\_\_\_\_
12. A position away from the midline of the body \_\_\_\_\_



## Pretest

**Multiple Choice.** Select the best answer, and write the letter of your choice to the left of each number. To check your answers go to Appendix 11.

- \_\_\_\_\_ 1. The root that means “cell” is  
a. spher  
b. aden  
c. cyt  
d. gen
- \_\_\_\_\_ 2. The process of body cell division is called  
a. separation  
b. segregation  
c. mitosis  
d. gestation
- \_\_\_\_\_ 3. A compound that speeds up the rate of a metabolic reaction is a(n)  
a. vitamin  
b. enzyme  
c. salt  
d. lipid
- \_\_\_\_\_ 4. The substance that makes up the cell’s genetic material is  
a. DNA  
b. mineral  
c. base  
d. neurons
- \_\_\_\_\_ 5. Chemicals: cells: tissues: \_\_\_\_\_: systems: organism. What belongs in the blank?  
a. genes  
b. enzymes  
c. nuclei  
d. organs
- \_\_\_\_\_ 6. In humans, dorsal is another term for  
a. lateral  
b. central  
c. anterior  
d. posterior
- \_\_\_\_\_ 7. The root *brachi/o* refers to the  
a. head  
b. spinal cord  
c. leg  
d. arm
- \_\_\_\_\_ 8. The prefix *supra-* means  
a. above  
b. near  
c. behind  
d. below






## Learning Objectives

After careful study of this chapter, you should be able to:

- 1 List the simplest to the most complex levels of a living organism. **P40**
- 2 Describe and locate the main parts of a cell. **P40**
- 3 Name and give the functions of the four basic types of tissues in the body. **P43**
- 4 Define basic terms pertaining to the structure and function of body tissues. **P44**
- 5 Define the main directional terms used in anatomy. **P52**
- 6 Describe division of the body along three different planes. **P53**
- 7 Locate the dorsal and ventral body cavities. **P54**
- 8 Locate and name the nine divisions and four quadrants of the abdomen. **P54**
- 9 Describe the main body positions used in medical practice. **P55**
- 10 Define basic terms describing body structure. **P57**
- 11 Use word parts pertaining to body organization and structure. **P57**
- 12 Identify and analyze medical terms and abbreviations in chapter case studies. **PP39, 70**



## Case Study: Zachary's Self-Diagnosis

### Chief Complaint

Zachary is a second-year medical student who, until recently, has done well in school. Lately, he finds that he is always tired and unable to focus in class. He decides to self-diagnose and begins with

a review of systems (ROS). He notes that he is not having any cardiovascular, lymphatic, or respiratory system symptoms, such as tissue swelling, coughing, or shortness of breath. He also has not noticed any changes in urinary system functions. He realizes that he has gained some weight recently and has also been a little constipated but has no other problems with his digestive system. He rules out anything concerning his musculoskeletal system because he has no muscle cramps, joint pain, or weakness. He thinks his skin is drier than usual. He worries that this is an integumentary system sign of hypothyroidism and becomes concerned about his endocrine system function. Unable to perform any imaging studies or laboratory tests on his own, he makes an appointment to see a campus health services physician.

### Examination

Zachary tells the physician he feels he has a metabolic disorder. He thinks he might have an adenoma, a glandular tumor that is disrupting homeostasis, his normal metabolic state. The physician takes a complete history and orders various blood tests to assist with the diagnosis. He completes a physical examination that reveals no abnormalities.

### Clinical Course

The blood glucose levels, complete blood count (CBC), and thyroid function tests are all normal. Nothing in the tests indicates anything physically wrong with the Zachary. There is no indication that any further cytologic or histologic tests are necessary. The physician tells Zachary that he is sleep deprived from all his studying and that his weight gain can be explained by his poor food choices in the university cafeteria. In addition, the physician advises Zachary to schedule some exercise into his daily routine. Lastly, he reminds Zachary that although he is studying to be a physician, self-diagnosis at this point in his career could be inaccurate and cause undue anxiety.

**Case Study Revisited:** Once you complete this chapter, please review the case follow-up on p. 61.

## Ancillaries *At-A-Glance*

Visit the web resource to access the following resources.

## Learning Resources

- eBook
- A&P Module with Heart & Lung Sounds
- Image Bank

- TestPrep
- Animations
- Audio Pronunciation Glossary

## Introduction

All organisms are built from simple to more complex levels (FIG. 2-1). Chemicals form the materials that make up cells, which are the body's basic structural and functional units. Groups of cells working together make up **tissues**, which in turn make up the **organs**, which have specialized functions. Organs become components of the various systems, which together comprise the whole organism. This chapter discusses the terminology related to basic body structure, leading to the study of all the individual organ systems in Part II.

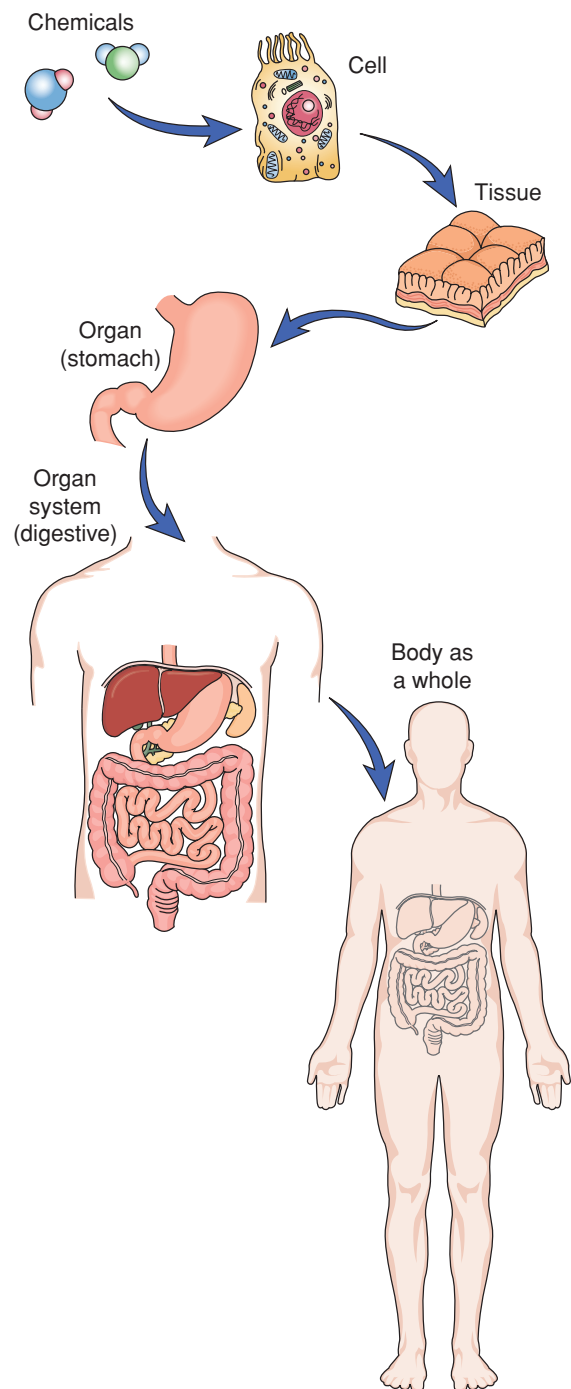
## The Cell

The **cell** is the basic unit of living organisms (FIG. 2-2). Cells accomplish all the activities and produce all the components of the body. They carry out **metabolism**, the sum of all the body's physical and chemical activities. They provide the energy for metabolic reactions in the form of the chemical **adenosine triphosphate (ATP)**, commonly described as the energy compound of the cell. The main categories of organic compounds contained in cells are:

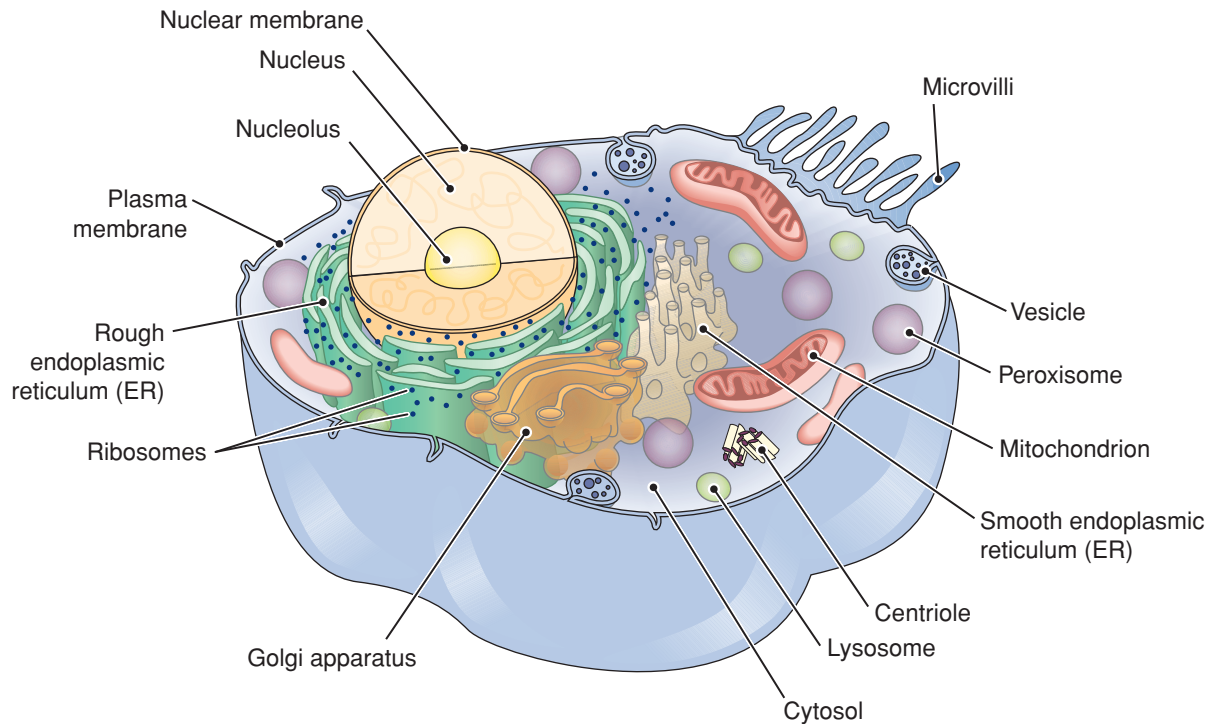
- **Proteins**, which include the **enzymes**, some hormones, and structural materials.
- **Carbohydrates**, which include sugars and starches. The main carbohydrate is the sugar **glucose**, which circulates in the blood to provide energy for the cells.
- **Lipids**, which include fats. Some hormones are derived from lipids, and adipose (fat) tissue is designed to store lipids.

Within the **cytoplasm** that fills the cell are subunits called **organelles**, each with a specific function (see FIG. 2-2). The main cell structures are named and described in **BOX 2-1**. Diseases may affect specific parts of cells. Cystic fibrosis and diabetes, for example, involve the plasma membrane. Other disorders originate with mitochondria, the endoplasmic reticulum (ER), lysosomes, or peroxisomes.

The **nucleus** is the control region of the cell. It contains the **chromosomes**, which carry genetic information (FIG. 2-3). Each human cell, aside from the reproductive (sex) cells, contains 46 chromosomes. These thread-like structures compose a complex organic substance, **deoxyribonucleic acid (DNA)**, which is organized into separate units called **genes**. Genes control the formation of proteins, most particularly enzymes, the catalysts needed to speed the rate of metabolic reactions. To help manufacture proteins, the cells use a compound called **ribonucleic acid (RNA)**, which is chemically related to DNA. Changes (mutations) in the



**FIGURE 2-1 Levels of organization.** The body is organized from the simple level of chemicals to the most complex level of the whole organism. The organ shown is the stomach, which is part of the digestive system.



**FIGURE 2-2** Generalized animal cell (sectional view). The main organelles are shown.



## FOR YOUR REFERENCE

### Cell Structures

BOX 2-1

Name	Description	Function
<b>plasma membrane</b> (PLAZ-mah)	outer layer of the cell, composed mainly of lipids and proteins	encloses the cell contents; regulates what enters and leaves the cell; participates in many activities, such as growth, reproduction, and interactions between cells
<b>microvilli</b> (mi-kro-VIL-i)	short extensions of the cell membrane	absorb materials into the cell
<b>nucleus</b> (NU-kle-us)	large, membrane-bound, dark-staining organelle near the center of the cell	contains the chromosomes, the hereditary units that direct all cellular activities
<b>nucleolus</b> (nu-KLE-o-lus)	small body in the nucleus	makes ribosomes
<b>cytoplasm</b> (SI-to-plazm)	colloidal suspension that fills the cell from the nuclear membrane to the plasma membrane	site of many cellular activities; consists of cytosol and organelles
<b>cytosol</b> (SI-to-sol)	fluid portion of the cytoplasm	surrounds the organelles
<b>endoplasmic reticulum (ER)</b> (en-do-PLAZ-mik re-TIK-u-lum)	network of membranes within the cytoplasm; rough ER has ribosomes attached to it; smooth ER does not	rough ER modifies, folds, and sorts proteins; smooth ER participates in lipid synthesis
<b>ribosomes</b> (RI-bo-somz)	small bodies free in the cytoplasm or attached to the ER, composed of RNA and protein	manufacture proteins

(continued)

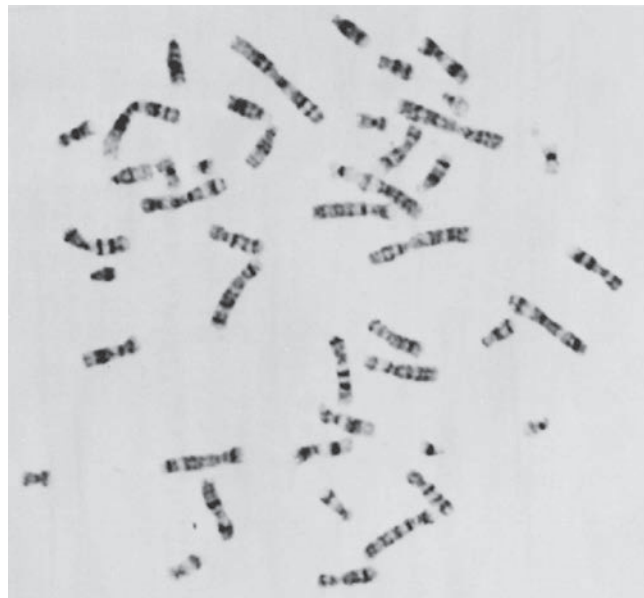

## FOR YOUR REFERENCE (Continued)

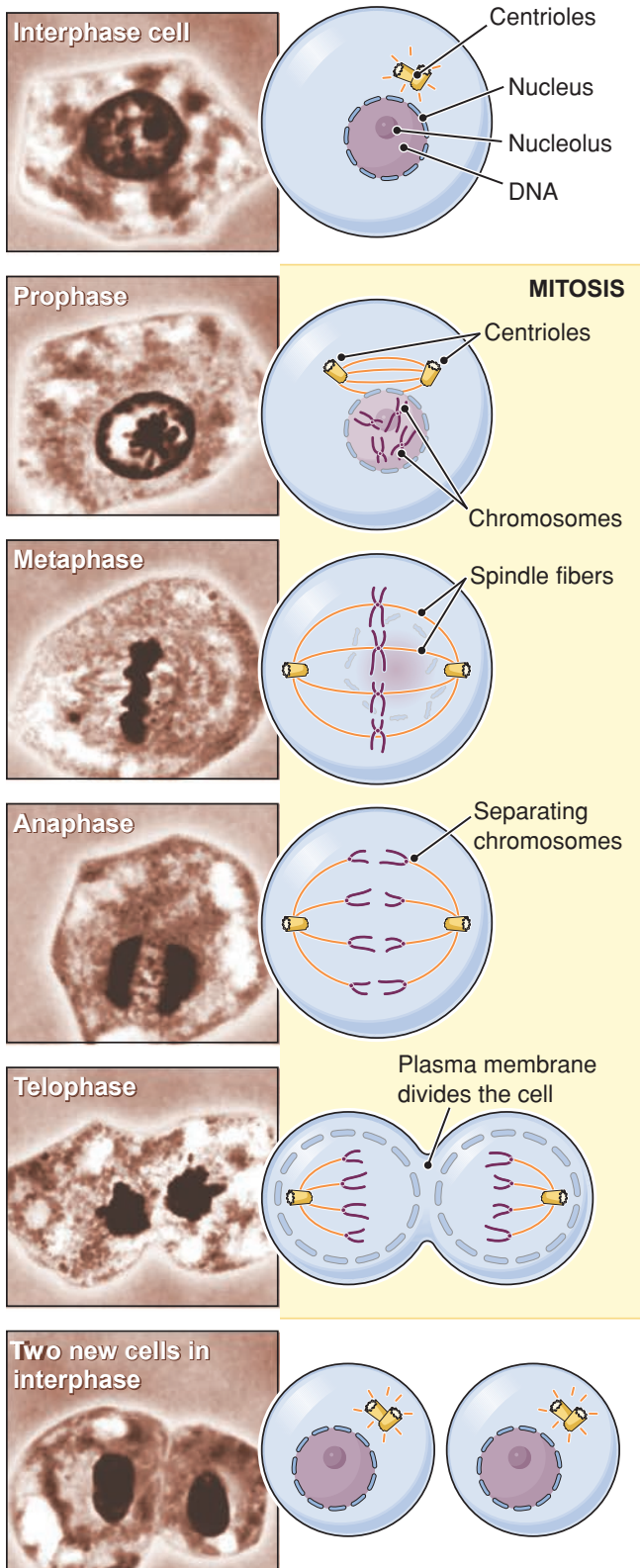
### Cell Structures

BOX 2-1

Name	Description	Function
<b>Golgi apparatus</b> ( <i>GOL-je</i> )	layers of membranes	modifies proteins; sorts and prepares proteins for transport to other parts of the cell or out of the cell
<b>mitochondria</b> ( <i>mi-to-KON-dre-ah</i> )	large organelles with internal folded membranes	convert energy from nutrients into ATP
<b>lysosomes</b> ( <i>LI-so-somz</i> )	small sacs of digestive enzymes	digest substances within the cell
<b>peroxisomes</b> ( <i>per-OKS-ih-somz</i> )	membrane-enclosed organelles containing enzymes	break down harmful substances
<b>vesicles</b> ( <i>VES-ih-klz</i> )	small membrane-bound sacs in the cytoplasm	store materials and move materials into or out of the cell in bulk
<b>centrioles</b> ( <i>SEN-tre-olz</i> )	rod-shaped bodies (usually two) near the nucleus	help separate the chromosomes during cell division
<b>surface projections</b>	structures that extend from the cell	move the cell or the fluids around the cell
<b>cilia</b> ( <i>SIL-e-ah</i> )	short, hair-like projections from the cell	move the fluids around the cell
<b>flagellum</b> ( <i>flah-JEL-um</i> )	long, whip-like extension from the cell	moves the cell



**FIGURE 2-3 Human chromosomes.** There are 46 chromosomes in each human cell, except the sex cells (egg and sperm).



**FIGURE 2-4** The stages in cell division (mitosis). When it is not undergoing mitosis, the cell is in interphase. The cell shown is for illustration only. It is not a human cell, which has 46 chromosomes.

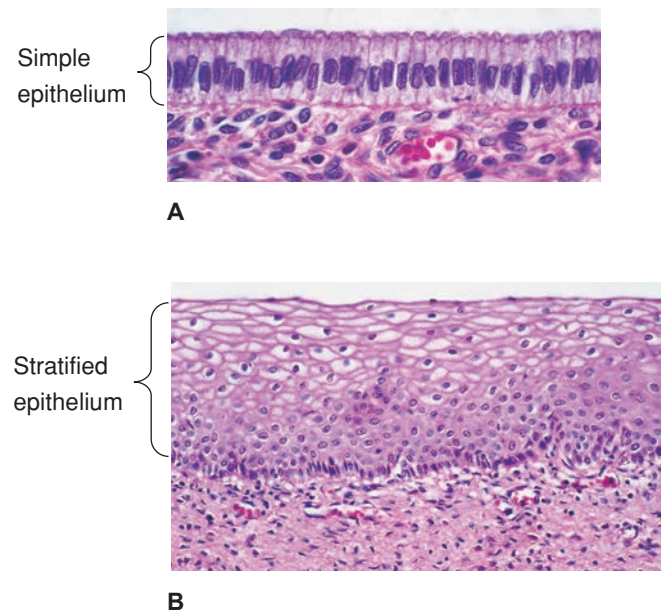
genes or chromosomes are the source of hereditary diseases, as described in Chapter 16.

When a body cell divides by the process of **mitosis**, the chromosomes are doubled and then equally distributed to the two daughter cells. The stages in mitosis are shown in **FIGURE 2-4**. When a cell is not dividing, it remains in a stage called *interphase*. In cancer, cells multiply without control causing cellular overgrowth and tumors. Reproductive cells (eggs and sperm) divide by a related process, meiosis, that halves the chromosomes in preparation for fertilization. The role of meiosis in reproduction is further explained in Chapter 15.

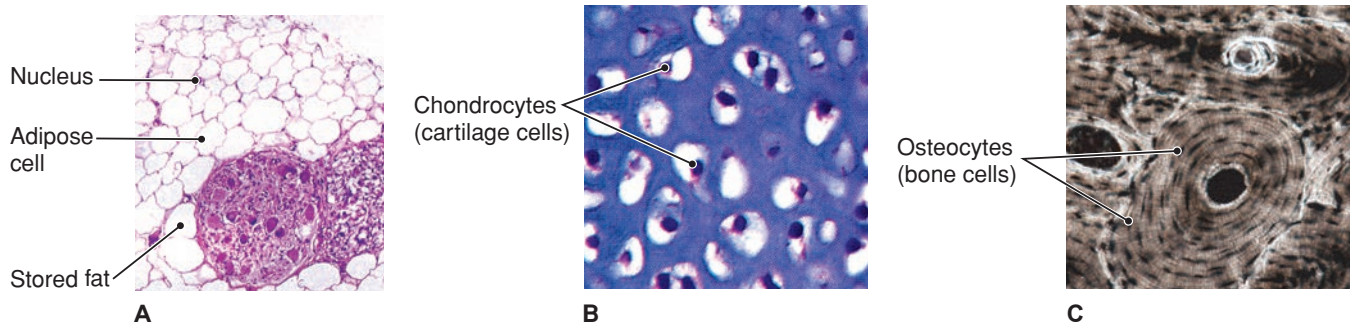
## Tissues

Cells are organized into four basic types of tissues that perform specific functions:

- Epithelial (*ep-ih-THE-le-al*) tissue, as shown in **FIGURE 2-5**, covers and protects body structures and lines organs, vessels, and cavities. Simple epithelium, composed of cells in a single layer, functions to absorb substances from one system to another, as in the respiratory and digestive tracts. Stratified epithelium, with cells in multiple layers, protects deeper tissues, as in the mouth and vagina. Most



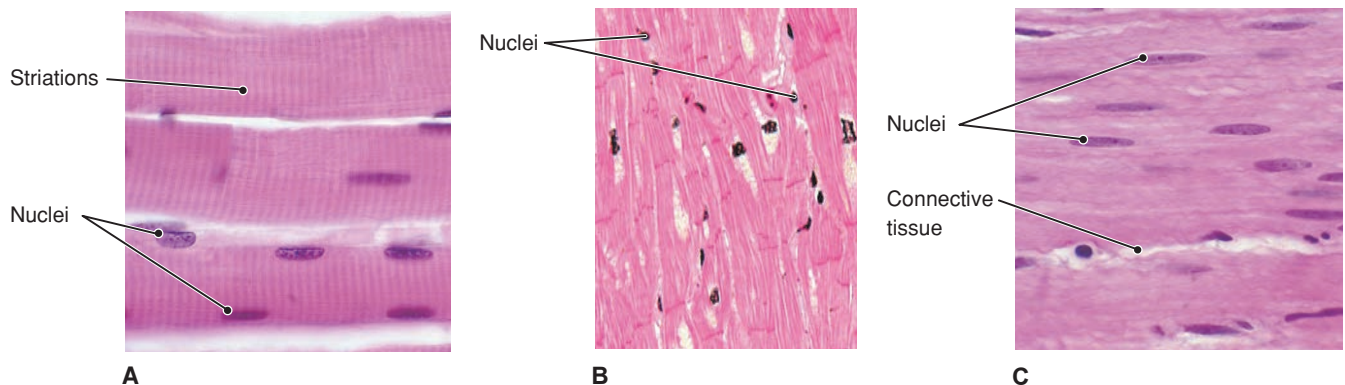
**FIGURE 2-5** Epithelial tissue. The cells in simple epithelium (**A**) are in a single layer and absorb materials from one system to another. The cells in stratified epithelium (**B**) are in multiple layers and protect deeper tissues.



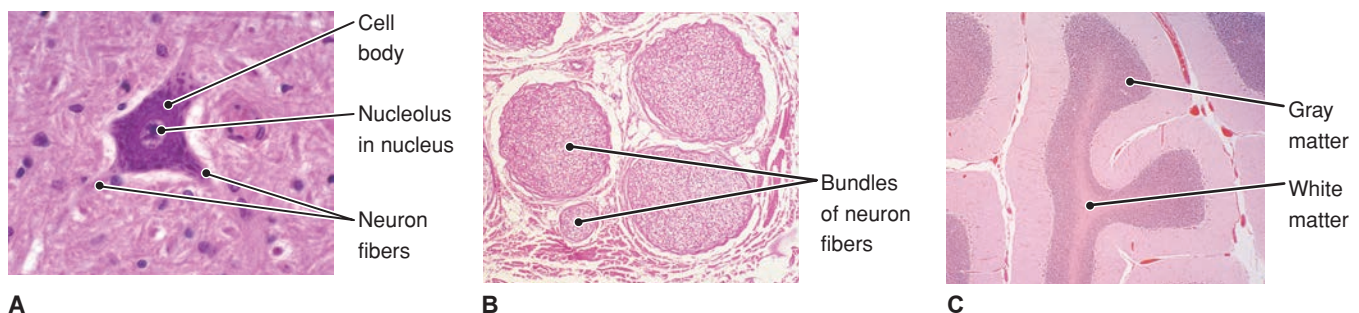**FIGURE 2-6** **Connective tissue.** Examples of connective tissue are adipose tissue (A), which stores fat; cartilage (B), which is used for protection and reinforcement; and bone (C), which makes up the skeleton.

of the active cells in glands are epithelial cells. Glands are described in more detail in Chapter 9.

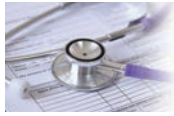- Connective tissue supports and binds body structures (FIG. 2-6). It contains fibers and other nonliving material between the cells. Included in this category are blood (Chapter 10), adipose (fat) tissue, cartilage, and bone (Chapter 5).
- Muscle tissue (root: my/o) contracts to produce movement (FIG. 2-7). There are three types of muscle tissues:
  - Skeletal muscle moves the skeleton. It has visible cross-bands, or striations, that are involved in contraction. Because it is under conscious control, it is also called voluntary muscle. Skeletal muscle is discussed in greater detail in Chapter 6.
  - Cardiac muscle forms the heart. It functions without conscious control and is described as involuntary. Chapter 10 describes the heart and its actions.
  - Smooth or visceral muscle forms the walls of the abdominal organs; it is also involuntary. Many organs described in later chapters on the systems have walls made of smooth muscle. The walls of ducts and blood vessels also are composed mainly of smooth muscle.
- Nervous tissue (root: neur/o) makes up the brain, spinal cord, and nerves (FIG. 2-8). It coordinates and controls



**FIGURE 2-7** **Muscle tissue.** Skeletal muscle (A) moves the skeleton. It has visible bands (striations) that produce contraction. Cardiac muscle (B) makes up the wall of the heart. Smooth muscle (C) makes up the walls of hollow organs, ducts, and vessels.



**FIGURE 2-8** **Nervous tissue.** The functional cell of the nervous system is the neuron (A). Neuron fibers join to form nerves (B). Nervous tissue also makes up the spinal cord and brain (C), where it is divided into gray matter and white matter.



## CLINICAL PERSPECTIVES

### Laboratory Study of Tissues

BOX 2-2

Biopsy is the removal and examination of living tissue to determine a diagnosis. The term is also applied to the specimen itself. *Biopsy* comes from the Greek word *bios*, meaning “life,” plus *opsis*, meaning “vision.” Together they mean the visualization of living tissue.

Some other terms that apply to cells and tissues come from Latin. *In vivo* means “in the living body,” as contrasted with *in vitro*, which literally means “in glass,” and refers to

procedures and experiments done in the laboratory, as compared to studies done in living organisms. *In situ* means “in its original place” and is used to refer to tumors that have not spread.

*In toto* means “whole” or “completely,” as in referring to a structure or organ removed totally from the body. *Postmortem* literally means “after death,” as in referring to an autopsy performed to determine the cause of death.

body responses by the transmission of electrical impulses. The basic cell in nervous tissue is the neuron, or nerve cell. The nervous system and senses are discussed in Chapters 7 and 8.

## MEMBRANES

A **membrane** (*MEM-brane*) is a simple, very thin, and pliable sheet of tissue. Membranes may cover an organ, line a cavity, or separate one structure from another. Some secrete special substances. Mucous membranes secrete **mucus**, a thick fluid that lubricates surfaces and protects the underlying tissue, as in the lining of the digestive tract and respiratory passages. Serous membranes, which secrete a thin, watery fluid, line body cavities and cover organs. These include the membranes around the heart and lungs. Fibrous membranes cover and support organs, as found around the bones, brain, and spinal cord.

The study of tissues is **histology** (*his-TOL-o-je*), based on the root *hist/o*, meaning “tissue.” **BOX 2-2** describes some terms used in histology.

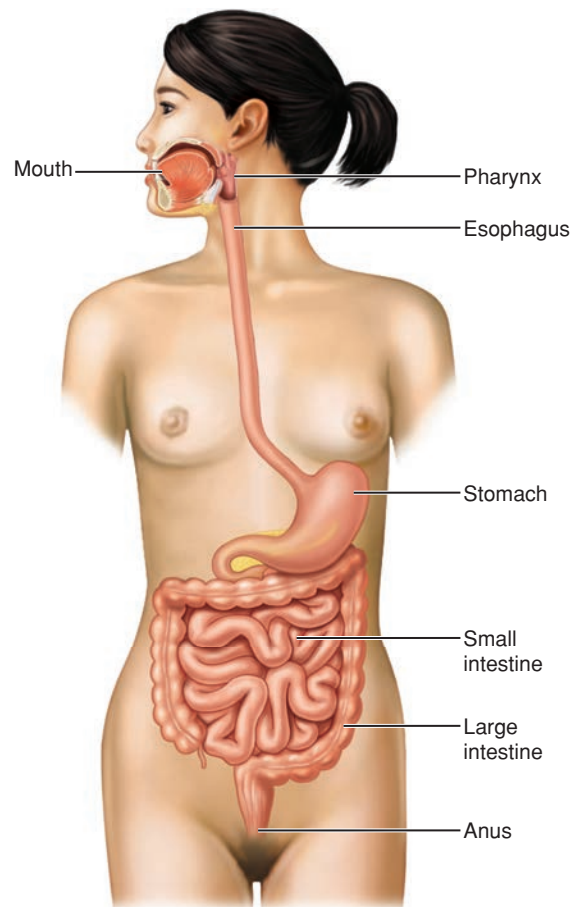
## Organs and Organ Systems

Tissues are arranged into organs, which serve specific functions, and organs, in turn, are grouped into individual systems. **FIGURE 2-9** shows the organs of the digestive system as an example. Although all body systems are interrelated, they are listed and described separately here as they appear in this text.

- Integumentary system, which includes the skin and its associated structures, such as hair, sweat glands, and oil glands. This system functions in protection and also helps to regulate body temperature.
- Skeletal system, which includes the bones and joints.
- Muscular system, which moves the skeleton and makes up the walls of internal organs. The muscular system and skeleton protect vital body parts.
- Nervous system, consisting of the brain, spinal cord, and nerves, and including the sensory system and

special senses, with emphasis on the ear and the eye. This system receives and processes stimuli and directs responses.

- Endocrine system, consisting of individual glands that produce hormones.
- Cardiovascular system, consisting of the blood, heart, and blood vessels.
- Lymphatic system, organs, and vessels that aid circulation and help protect the body from foreign materials.



**FIGURE 2-9** Organs of the digestive tract. Other organs and glands contribute to digestion, as described in Chapter 13.



- Respiratory system, which obtains the oxygen needed for metabolism and eliminates carbon dioxide, a byproduct of metabolism.
- Digestive system, which takes in, breaks down, and absorbs nutrients and eliminates undigested waste.
- Urinary system, which eliminates soluble waste and balances the volume and composition of body fluids
- The male and female reproductive systems concerned with production of offspring

Each of the body systems is discussed in Part II. However, bear in mind that the body functions as a whole; no system is independent of the others. They work together to maintain the body's state of internal stability, termed **homeostasis** (*ho-me-o-STA-sis*).

## Terminology

## Key Terms

The terms listed below are emphasized in this chapter. Knowing them will help you organize and prioritize your learning. These boldface terms are also found, collectively, with all chapter key terms in the Glossary.

### Cells to Organ Systems

<b>adenosine triphosphate (ATP)</b> <i>ab-DEN-o-sene tri-FOS-fate</i>	The energy compound of the cell that stores energy needed for cell activities
<b>carbohydrates</b> <i>kar-bo-HI-drates</i>	The category of organic compounds that includes sugars and starches
<b>cell</b> <i>sel</i>	The basic structural and functional unit of the living organism, a microscopic unit that combines with other cells to form tissues (root: <i>cyt/o</i> )
<b>chromosome</b> <i>KRO-mo-some</i>	A thread-like body in a cell's nucleus that contains genetic information
<b>cytology</b> <i>si-TOL-o-je</i>	Study of cells
<b>cytoplasm</b> <i>SI-to-plazm</i>	The fluid that fills a cell and holds the organelles
<b>deoxyribonucleic acid (DNA)</b> <i>de-ok-se-ri-bo-nu-KLE-ik</i>	The genetic compound of the cell, makes up the genes
<b>enzyme</b> <i>EN-zime</i>	An organic substance that speeds the rate of a metabolic reaction
<b>gene</b> <i>jene</i>	A hereditary unit composed of DNA and combined with other genes to form the chromosomes
<b>glucose</b> <i>GLU-kose</i>	A simple sugar that circulates in the blood, the main energy source for metabolism (roots: <i>gluc/o</i> , <i>glyc/o</i> )
<b>histology</b> <i>his-TOL-o-je</i>	Study of tissues
<b>homeostasis</b> <i>ho-me-o-STA-sis</i>	A steady state, a condition of internal stability and constancy
<b>lipid</b> <i>LIP-id</i>	A category of organic compounds that includes fats (root: <i>lip/o</i> )
<b>membrane</b> <i>MEM-brane</i>	A simple, very thin, and pliable sheet of tissue that might cover an organ, line a cavity, or separate structures
<b>metabolism</b> <i>meh-TAB-o-lizm</i>	The sum of all the physical and chemical reactions that occur within an organism
<b>mitosis</b> <i>mi-TO-sis</i>	Cell division
<b>mucus</b> <i>MU-kus</i>	A thick fluid secreted by cells in membranes and glands that lubricates and protects tissues (roots: <i>muc/o</i> , <i>myx/o</i> ); the adjective is <i>mucous</i>

## Terminology

## Key Terms (Continued)

<b>nucleus</b> <i>NU-kle-us</i>	The cell's control center; directs all cellular activities based on the information contained in its chromosomes (roots: nucle/o, kary/o)
<b>organ</b> <i>OR-gan</i>	A part of the body with a specific function, a component of a body system
<b>organelle</b> <i>OR-gah-nel</i>	A specialized structure in the cytoplasm of a cell
<b>protein</b> <i>PRO-tene</i>	A category of organic compounds that includes structural materials, enzymes, and some hormones
<b>ribonucleic acid (RNA)</b> <i>ri-bo-nu-KLE-ik</i>	An organic compound involved in the manufacture of proteins within cells
<b>tissue</b> <i>TISH-u</i>	A group of cells that acts together for a specific purpose (roots: hist/o, histi/o); types include epithelial tissue, connective tissue, muscle tissue, and nervous tissue

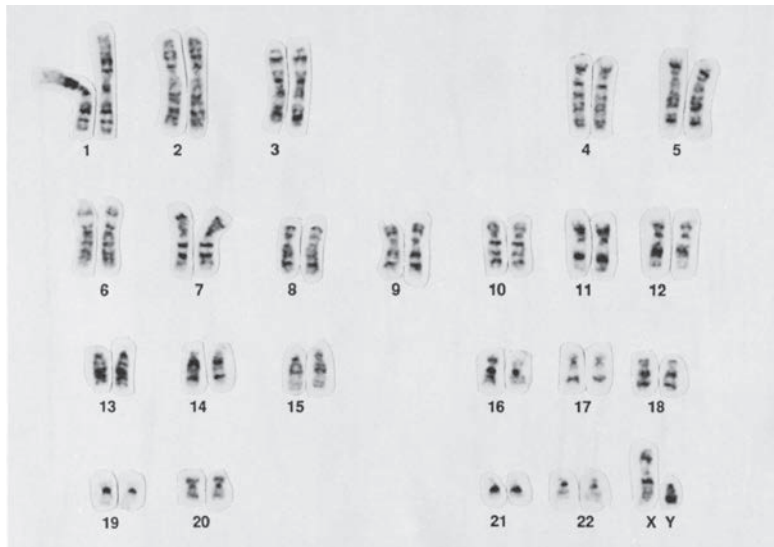## Word Parts Pertaining to Cells, Tissues, and Organs

See TABLES 2-1 to 2-3.

Table 2-1

## Roots for Cells and Tissues

Root	Meaning	Example	Definition of Example
morph/o	form	polymorphous <i>pol-e-MOR-fus</i>	having many forms
cyt/o, -cyte	cell	cytologist <i>si-TOL-o-jist</i>	one who studies cells
nucle/o	nucleus	nuclear <i>NU-kle-ar</i>	pertaining to a nucleus
kary/o	nucleus	karyotype <i>KAR-e-o-tipe</i>	picture of a cell's chromosomes organized according to size (FIG. 2-10)
hist/o, histi/o	tissue	histocompatibility <i>his-to-kom-pat-ih-BIL-ih-te</i>	tissue similarity that permits transplantation
fibr/o	fiber	fibrosis <i>fi-BRO-sis</i>	abnormal formation of fibrous tissue
reticul/o	network	reticulum <i>reh-TIK-u-lum</i>	a network
aden/o	gland	adenoma <i>ad-eh-NO-mah</i>	tumor (-oma) of a gland
papill/o	nipple	papilla <i>pah-PIL-ab</i>	projection that resembles a nipple
myx/o	mucus	myxadenitis <i>miks-ad-eh-NI-tis</i>	inflammation (-itis) of a mucus-secreting gland
muc/o	mucus, mucous membrane	mucorrhea <i>mu-ko-RE-ab</i>	increased flow (-rhea) of mucus
somat/o, -some	body, small body	chromosome <i>KRO-mo-some</i>	small body that takes up color (dye) (chrom/o)



**FIGURE 2-10 Human karyotype.** The 46 chromosomes are in 23 pairs arranged according to size. The XY sex chromosomes, the 23rd pair at the lower right, indicate that the cell is from a male; a female cell has XX sex chromosomes.

## Exercise 2-1

Complete the exercise. To check your answers go to Appendix 11.

Fill in the blanks. Use the phonetics to pronounce the words in the exercises.

1. Cytogenesis (*si-to-JEN-eh-sis*) is the formation (genesis) of \_\_\_\_\_ cells \_\_\_\_\_.
2. A fibril (*FI-bril*) is a small \_\_\_\_\_.
3. A histologist (*his-TOL-o-jist*) studies \_\_\_\_\_.
4. A dimorphic (*di-MOR-fik*) organism has two \_\_\_\_\_.
5. Karyomegaly (*kar-e-o-MEG-ah-le*) is enlargement (-megaly) of the \_\_\_\_\_.
6. Nucleoplasm (*NU-kle-o-plazm*) is the substance that fills the \_\_\_\_\_.
7. Adenitis (*ad-eh-NI-tis*) is inflammation (-itis) of a(n) \_\_\_\_\_.
8. A papillary (*PAP-ih-lar-e*) structure resembles a(n) \_\_\_\_\_.
9. A myxoma (*mik-SO-mah*) is a tumor of tissue that secretes \_\_\_\_\_.
10. A reticulocyte (*reh-TIK-u-lo-site*) is a cell that contains a(n) \_\_\_\_\_.
11. The term *mucosa* (*mu-KO-sah*) is used to describe a membrane that secretes \_\_\_\_\_.
12. Somatotropin (*so-mah-to-TRO-pin*), also called growth hormone, has a general stimulating effect on the \_\_\_\_\_.

Use the suffix -logy to build a word with each of the following meanings.

13. The study of form \_\_\_\_\_
14. The study of cells \_\_\_\_\_
15. The study of tissues \_\_\_\_\_

Table 2-2

## Roots for Cell Activity

Root	Meaning	Example	Definition of Example
blast/o, -blast	immature cell, productive cell, embryonic cell	histioblast <i>HIS-te-o-blast</i>	a tissue-forming cell
gen	origin, formation	karyogenesis <i>kar-e-o-JEN-eh-sis</i>	formation of a nucleus
phag/o	eat, ingest	autophagy <i>aw-TOF-ab-je</i>	self (auto)-destruction of a cell's organelles
phil	attract, absorb	basophilic <i>ba-so-FIL-ik</i>	attracting basic stain
plas	formation, molding, development	hyperplasia <i>hi-per-PLA-ze-ab</i>	overdevelopment of an organ or tissue
trop	act on, affect	chronotropic <i>kron-o-TROP-ik</i>	affecting rate or timing (chron/o)
troph/o	feeding, growth, nourishment	atrophy <i>AT-ro-fe</i>	tissue wasting

The roots in **TABLE 2-2** are often combined with a simple noun suffix (*-in*, *-y*, or *-ia*) or an adjective suffix (*-ic*) and used as word endings. Such combined forms that routinely

appear as word endings are simply described and used as suffixes in this book. Examples from the above list are: *-phagy*, *-philic*, *-plasia*, *-tropic*, and *-trophy*.

## Exercise 2-2

Complete the exercise. To check your answers go to Appendix 11.

Match the following terms in the following sets, and write the appropriate letter to the left of each number.

- |  |  |
|--|--|
| ___ 1. phagocyte ( <i>FAG-o-site</i> )           | a. overdevelopment of tissue             |
| ___ 2. histogenesis ( <i>his-to-JEN-eh-sis</i> ) | b. study of heredity                     |
| ___ 3. leukoblast ( <i>LU-ko-blast</i> )         | c. formation of tissue                   |
| ___ 4. genetics ( <i>jeb-NET-iks</i> )           | d. cell that ingests waste               |
| ___ 5. hypertrophy ( <i>hi-PER-tro-fe</i> )      | e. immature white blood cell             |
| ___ 6. neoplasia ( <i>ne-o-PLA-ze-ab</i> )       | a. attracting color                      |
| ___ 7. gonadotropin ( <i>gon-ab-do-TRO-pin</i> ) | b. pertaining to the body                |
| ___ 8. aplasia ( <i>ab-PLA-ze-ab</i> )           | c. substance that acts on the sex glands |
| ___ 9. somatic ( <i>so-MAT-ik</i> )              | d. new formation of tissue               |
| ___ 10. chromophilic ( <i>kro-mo-FIL-ik</i> )    | e. lack of development                   |

Identify and define the root in the following words.

	Root	Meaning of Root
11. genesis ( <i>JEN-eh-sis</i> )	gen	origin, formation
12. esophagus ( <i>eh-SOF-ab-gus</i> )	_____	_____
13. normoblast ( <i>NOR-mo-blast</i> )	_____	_____
14. aplastic ( <i>ab-PLAS-tik</i> )	_____	_____
15. dystrophy ( <i>DIS-tro-fe</i> )	_____	_____

Table 2-3

## Suffixes and Roots for Body Chemistry

Word Part	Meaning	Example	Definition of Example
<b>Suffixes</b>			
-ase	enzyme	lipase <i>LI-pase</i>	enzyme that digests fat (lipid)
-ose	sugar	lactose <i>LAK-tose</i>	milk sugar
<b>Roots</b>			
hydr/o	water, fluid	hydration <i>hi-DRA-shun</i>	addition of water, relative amount of water present
gluc/o	glucose	glucogenesis <i>glu-ko-JEN-eh-sis</i>	production of glucose
glyc/o	sugar, glucose	normoglycemia <i>nor-mo-gli-SE-me-ah</i>	normal blood sugar level
sacchar/o	sugar	polysaccharide <i>pol-e-SAK-ab-ride</i>	compound containing many simple sugars
amyl/o	starch	amyloid <i>AM-ih-loyd</i>	resembling starch
lip/o	lipid, fat	lipophilic <i>lip-o-FIL-ik</i>	attracting or absorbing lipids
adip/o	fat	adiposuria <i>ad-ih-po-SUR-e-ah</i>	presence of fat in the urine (ur/o)
steat/o	fatty	steatorrhea <i>ste-ah-to-RE-ah</i>	discharge (-rhea) of fatty stools
prote/o	protein	protease <i>PRO-te-ase</i>	enzyme that digests protein

## Exercise 2-3

Complete the exercise. To check your answers go to Appendix 11.

Fill in the blanks.

- A disaccharide (*di-SAK-ab-ride*) is a compound that contains two \_\_\_\_\_ sugars .
- The ending *-ose* indicates that fructose is a(n) \_\_\_\_\_ .
- Hydrophobia (*hi-dro-FO-be-ah*) is an aversion (-phobia) to \_\_\_\_\_ .
- Amylase (*AM-ih-lase*) is an enzyme that digests \_\_\_\_\_ .
- Liposuction (*LIP-o-suk-shun*) is the surgical removal of \_\_\_\_\_ .
- A glucocorticoid (*glu-ko-KOR-tih-koyd*) is a hormone that controls the metabolism of \_\_\_\_\_ .
- An adipocyte (*AD-ih-po-site*) is a cell that stores \_\_\_\_\_ .

Identify and define the root in the following words.

	Root	Meaning of Root
8. asteatosis ( <i>as-te-ah-TO-sis</i> )	_____	_____
9. lipoma ( <i>li-PO-mah</i> )	_____	_____
10. hyperglycemia ( <i>hi-per-gli-SE-me-ah</i> )	_____	_____
11. glycolytic ( <i>glu-ko-LIT-ik</i> )	_____	_____

**Terminology****Enrichment Terms**

The terms listed below expand on the key terms to increase your knowledge of this chapter topic.

<b>amino acids</b> <i>ah-ME-no</i>	The nitrogen-containing compounds that make up proteins
<b>anabolism</b> <i>ah-NAB-o-lizm</i>	The type of metabolism in which body substances are made; the building phase of metabolism
<b>catabolism</b> <i>kab-TAB-o-lizm</i>	The type of metabolism in which substances are broken down for energy and simple compounds
<b>collagen</b> <i>KOL-ab-jen</i>	A fibrous protein found in connective tissue
<b>cortex</b> <i>KOR-tex</i>	The outer region of an organ
<b>glycogen</b> <i>GLI-ko-jen</i>	A complex sugar compound stored in liver and muscles and broken down into glucose when needed for energy
<b>interstitial</b> <i>in-ter-STISH-al</i>	Between parts, such as the spaces between cells in a tissue
<b>medulla</b> <i>meh-DUL-lah</i>	The inner region of an organ, marrow (root: medull/o)
<b>parenchyma</b> <i>par-EN-kih-mah</i>	The functional tissue of an organ
<b>parietal</b> <i>pah-RI-eh-tal</i>	Pertaining to a wall, describes a membrane that lines a body cavity
<b>soma</b> <i>SO-mah</i>	The body
<b>stem cell</b>	An immature cell that has the capacity to develop into any of a variety of different cell types, a precursor cell
<b>visceral</b> <i>VIS-er-al</i>	Pertaining to the internal organs; describes a membrane on the surface of an organ

## The Body as a Whole

All healthcare professionals must be thoroughly familiar with the terms used to describe body locations and positions.

Radiologic technologists, for example, must be able to position a person and direct x-rays to obtain suitable images for diagnosis, as noted in **BOX 2-3**.



### HEALTH PROFESSIONS

#### Radiologic Technologist

**BOX 2-3**

Radiologic technologists help in the diagnosis of medical disorders by taking x-ray images (radiographs) of the body. They also use CT scans and other imaging technology to perform examinations on patients to aid in diagnosis. Following institutional safety patient mobilization procedures; they must prepare patients for radiologic examinations, place patients in appropriate positions; and then adjust equipment to the correct angles, heights, and settings for taking the x-ray or other diagnostic image. They must position the image receptors correctly and, after exposure, remove and process the images.

They are also required to keep patient records and maintain equipment. Radiologic technologists must minimize radiation hazards by using protective equipment for themselves and patients and by delivering the minimum possible amount of radiation. They wear badges to monitor radiation levels and keep records of their exposure.

Radiologic technologists may specialize in a specific imaging technique such as bone densitometry, cardiovascular-interventional radiography, computed tomography, mammography, magnetic resonance imaging, nuclear medicine,

(continued)



## HEALTH PROFESSIONS (Continued)

### Radiologic Technologist

BOX 2-3

and quality management. Some of these will be described in later chapters.

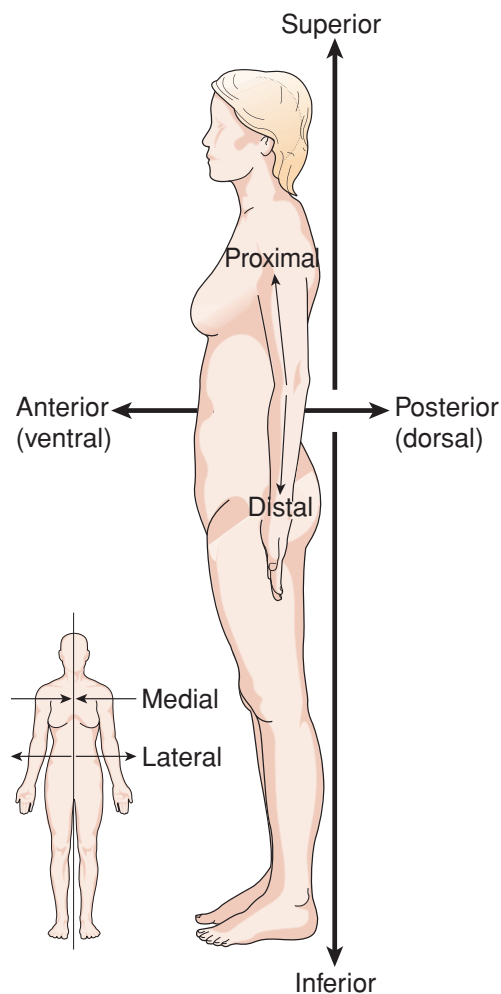
The majority of radiologic technologists work in hospitals, but they may also be employed in physicians' offices, diagnostic imaging centers (e.g., doing mammograms), and outpatient care centers. Radiologic technologists must possess a minimum of an associate's degree to qualify for professional certification. A higher degree is necessary for a supervisory or teaching position. The Joint Review Commit-

tee on Education in Radiologic Technology accredits most of the education programs. The American Registry of Radiologic Technologists (ARRT) offers a national certification examination in radiography as well as in other imaging technologies (CT, MRI, nuclear medicine, etc.). ARRT certification is required for employment as a radiologic technologist in most U.S. states. Job opportunities in this field are currently good. The American Society of Radiologic Technologists has information on this career at [asrt.org](http://asrt.org).

## DIRECTIONAL TERMS

In describing the location or direction of a given point in the body, it is always assumed that the subject is in the **anatomic position**, that is, upright, with face front, arms at the

sides with palms forward, and feet parallel. In this stance, the terms illustrated in **FIGURE 2-11** and listed in **BOX 2-4** are used to designate relative position.



**FIGURE 2-11** Directional terms.



## FOR YOUR REFERENCE

### Anatomic Directions

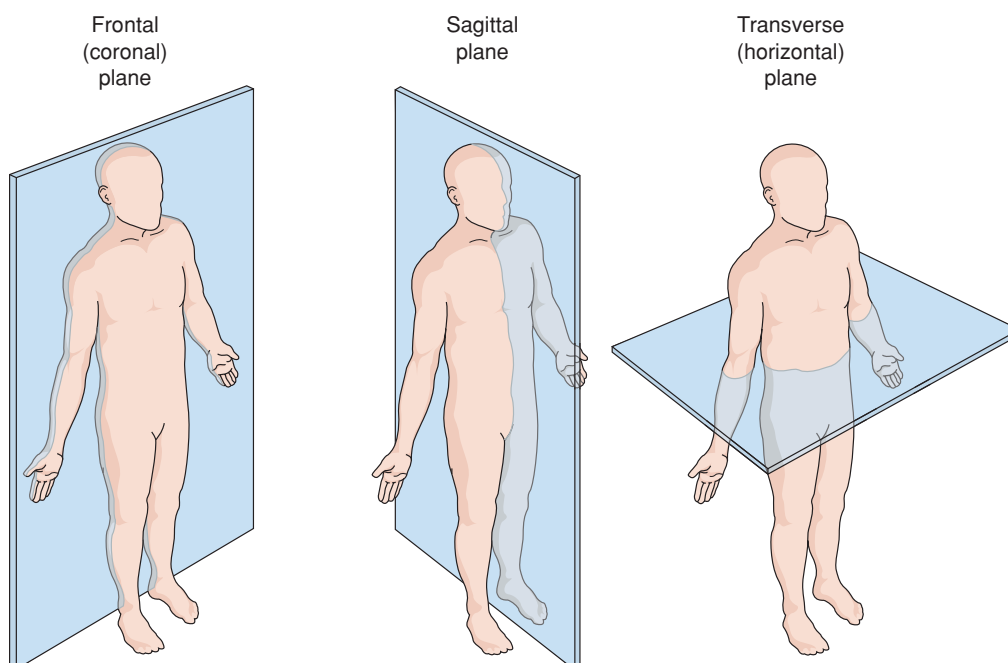
BOX 2-4

2

Term	Definition
<b>anterior (ventral)</b>	toward or at the front (belly) of the body
<b>posterior (dorsal)</b>	toward or at the back (dorsum) of the body
<b>medial</b>	toward the midline of the body
<b>lateral</b>	toward the side of the body
<b>proximal</b>	nearer to the point of attachment or to a given reference point
<b>distal</b>	farther from the point of attachment or from a given reference point
<b>superior</b>	above, in a higher position
<b>inferior</b>	below, in a lower position
<b>cranial (cephalad)</b>	toward the head
<b>caudal</b>	toward the lower end of the spine (Latin <i>cauda</i> means “tail”); in humans, in an inferior direction
<b>superficial (external)</b>	closer to the surface of the body
<b>deep (internal)</b>	closer to the center of the body

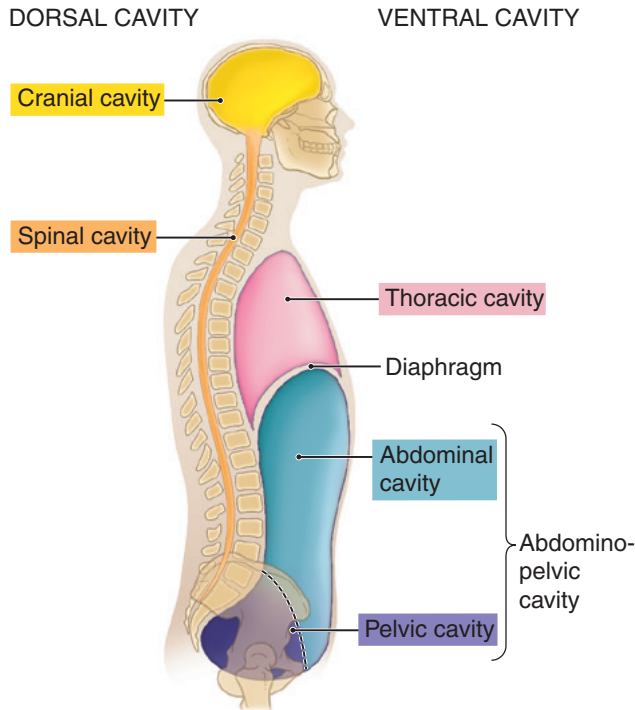
**FIGURE 2-12** illustrates planes of section, that is, directions in which the body can be cut. A **frontal plane**, also called a coronal plane, is made at right angles to the midline and divides the body into anterior and posterior parts. A **sagittal (SAJ-ih-tal) plane**

passes from front to back and divides the body into right and left portions. If the plane passes through the midline, it is a mid-sagittal or medial plane. A **transverse (horizontal) plane** passes horizontally, dividing the body into superior and inferior parts.



**FIGURE 2-12** Planes of division.





**FIGURE 2-13** Body cavities, lateral view. Shown are the dorsal and ventral cavities with their subdivisions.

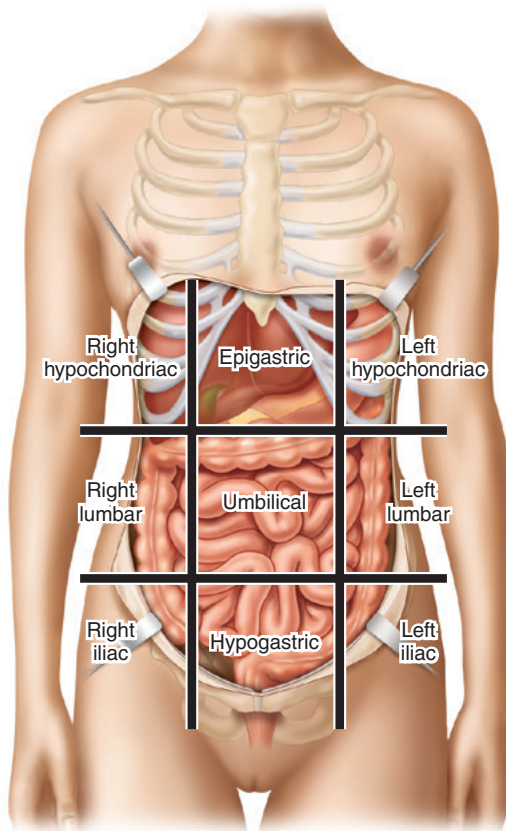
## BODY CAVITIES

Internal organs are located within dorsal and ventral cavities (**FIG. 2-13**). The dorsal cavity contains the brain in the **cranial cavity** and the spinal cord in the **spinal cavity (canal)**. The uppermost ventral space, the **thoracic cavity**, is separated from the **abdominal cavity** by the **diaphragm**, a muscle used in breathing. There is no anatomic separation between the abdominal cavity and the **pelvic cavity**, which together make up the **abdominopelvic cavity**. The large membrane that lines the abdominopelvic cavity and covers the organs within it is the **peritoneum** (*per-ih-to-NE-um*).

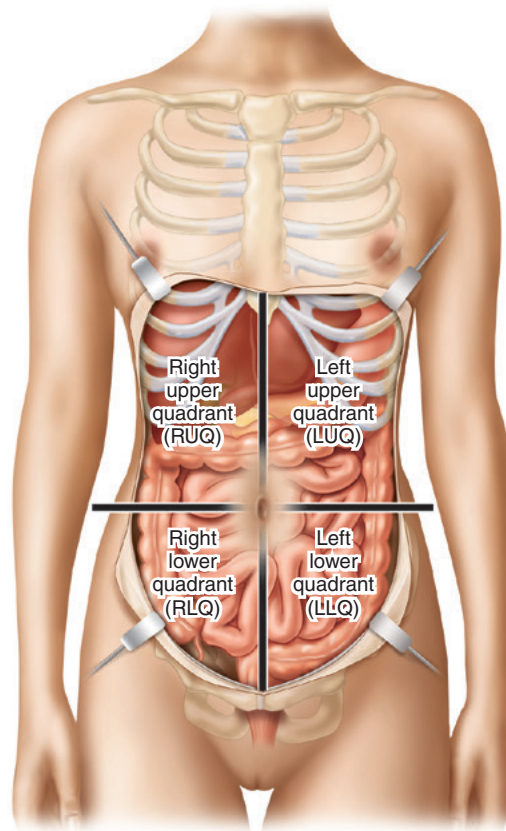
## ABDOMINAL REGIONS

For orientation, the abdomen can be divided by imaginary lines into nine regions—three medial regions and six lateral regions (**FIG. 2-14**). The sections down the midline are the:

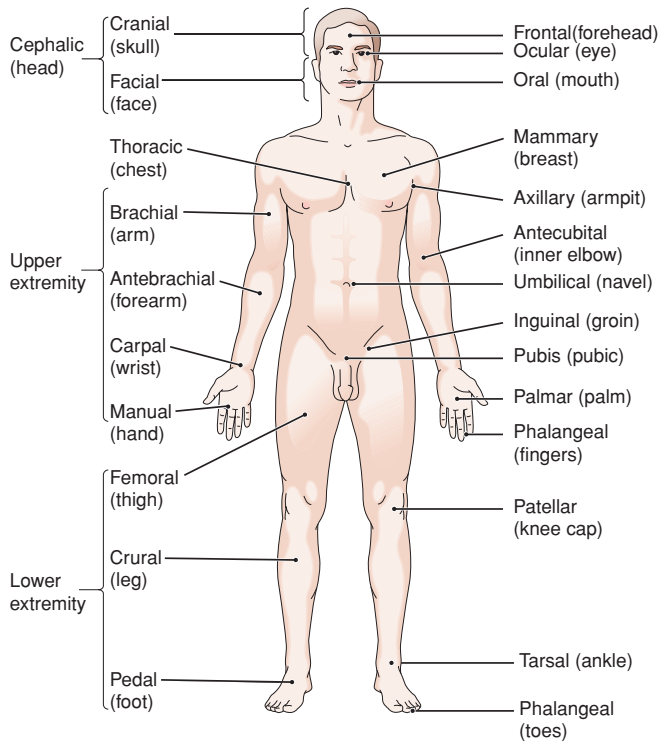
- epigastric (*ep-ih-GAS-trik*) region, located above the stomach
- umbilical (*um-BIL-ih-kal*) region, named for the umbilicus, or navel
- hypogastric (*hi-po-GAS-trik*) region, located below the stomach



**FIGURE 2-14** The nine regions of the abdomen.



**FIGURE 2-15** Quadrants of the abdomen. Some organs within the quadrants are indicated.

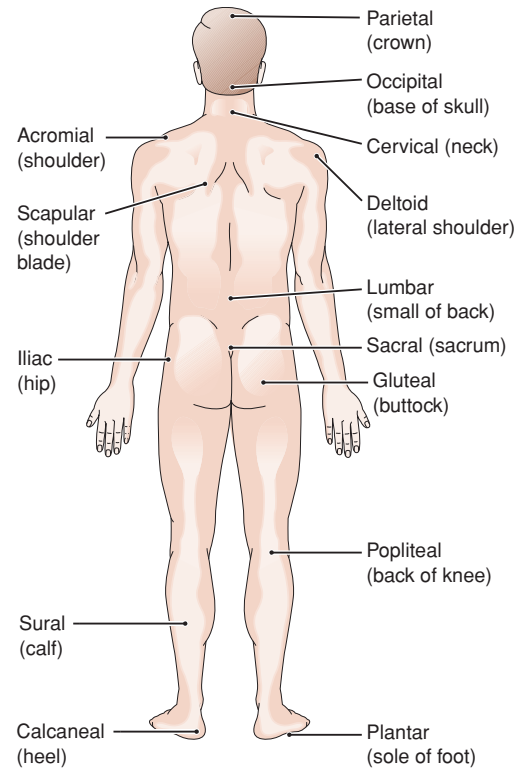


**FIGURE 2-16** Common terms for body regions, anterior view. Anatomic adjectives for regions are in parentheses.

The lateral regions have the same name on the left and right sides. They are the:

- hypochondriac (*hi-po-KON-dre-ak*) regions, right and left, named for their positions near the ribs, specifically near the cartilages (root: chondr/o) of the ribs
- lumbar (*LUM-bar*) regions, right and left, which are located near the small of the back (lumbar region of the spine)
- iliac (*IL-e-ak*) regions, right and left, named for the upper bone of the hip, the ilium; also called the inguinal (*ING-gwih-nal*) regions, with reference to the groin

More simply, but less precisely, the abdomen can be divided into four sections by a single vertical line and a



**FIGURE 2-17** Common terms for body regions, posterior view. Anatomic adjectives for regions are in parentheses.

single horizontal line that intersect at the umbilicus (navel) (**FIG. 2-15**). The sections are the right upper quadrant (RUQ), left upper quadrant (LUQ), right lower quadrant (RLQ), and left lower quadrant (LLQ).

Additional terms for body regions are shown in **FIGURES 2-16** and **2-17**. You may need to refer to these illustrations as you work through the book.

## POSITIONS

In addition to the anatomic position, there are other standard positions in which the body is placed for special purposes, such as examination, tests, surgery, or fluid drainage. The most common of these positions and some of their uses are described in **BOX 2-5**.

## FOR YOUR REFERENCE

### Body Positions

BOX 2-5

#### Position

#### Description

**anatomic position**  
*an-ah-TOM-ik*

standing erect, facing forward, arms at sides, palms forward, legs parallel, toes pointed forward; used for descriptions and studies of the body

**decubitus position**  
*de-KU-bih-tus*

lying down, specifically according to the part of the body resting on a flat surface, as in left or right lateral decubitus, or dorsal or ventral decubitus

**dorsal recumbent position**  
*re-KUM-bent*

on back, with legs bent and separated, feet flat; used for obstetrics and gynecology

(continued)



## FOR YOUR REFERENCE (Continued)

### Body Positions

BOX 2-5

Position	Description
<b>Fowler position</b>	on back, head of bed raised about 18 inches, knees elevated; used to ease breathing and for drainage
<b>jackknife position</b> <i>JAK-nife</i>	on back with shoulders elevated, legs flexed and thighs at right angles to the abdomen; used to introduce a tube into the urethra
<b>knee–chest position</b>	on knees, head and upper chest on table, arms crossed above head; used in gynecology and obstetrics and for flushing the intestine
<b>lateral recumbent position</b>	on the side with one leg flexed, arm position may vary
<b>lithotomy position</b> <i>lih-THOT-o-me</i>	on back, legs flexed on abdomen, thighs apart; used for gynecologic and urologic surgery
<b>prone</b>	lying face down
<b>prone jackknife position</b> <i>JAK-nife</i>	on abdomen with bed bent so that the body is in a V with the head and feet below the hips. Used for anorectal surgery
<b>Sims position</b>	on left side, right leg drawn up high and forward, left arm along back, chest forward resting on bed; used for kidney and uterine surgery, colon examination, and enemas
<b>supine<sup>a</sup></b> <i>SU-pine</i>	lying face up
<b>Trendelenburg position</b> <i>tren-DEL-en-berg</i>	on back with head lowered by tilting bed back at 45-degree angle; used for pelvic and abdominal surgery, treatment of shock

<sup>a</sup>To remember the difference between prone and supine, look for the word *up* in supine.

## Terminology

## Key Terms

The terms listed below are emphasized in this chapter. Knowing them will help you organize and prioritize your learning. These boldface terms are also found, collectively, with all chapter key terms in the Glossary.

### The Body as a Whole

<b>abdominal cavity</b> <i>ab-DOM-ih-nal</i>	The large ventral cavity below the diaphragm and above the pelvic cavity
<b>abdominopelvic cavity</b> <i>ab-dom-ih-no-PEL-vik</i>	The large ventral cavity between the diaphragm and pelvis that includes the abdominal and pelvic cavities
<b>anatomic position</b> <i>an-ab-TOM-ik</i>	Standard position for anatomic studies, in which the body is erect and facing forward, the arms are at the sides with palms forward, and the feet are parallel
<b>cranial cavity</b> <i>KRA-ne-al</i>	The dorsal cavity that contains the brain

Terminology	Key Terms (Continued)
<b>diaphragm</b> <i>DI-ab-fram</i>	The muscle that separates the thoracic from the abdominal cavity
<b>frontal (coronal) plane</b> <i>FRUHN-tal</i>	Plane of section that separates the body into anterior (front) and posterior (back) portions
<b>pelvic cavity</b> <i>PEL-vik</i>	The ventral cavity that is below the abdominal cavity
<b>peritoneum</b> <i>per-ib-to-NE-um</i>	The large serous membrane that lines the abdominopelvic cavity and covers the organs within it
<b>sagittal plane</b> <i>SAJ-ib-tal</i>	Plane that divides the body into right and left portions
<b>spinal cavity (canal)</b> <i>SPI-nal</i>	Dorsal cavity that contains the spinal cord
<b>thoracic cavity</b> <i>tho-RAS-ik</i>	The ventral cavity above the diaphragm, the chest cavity
<b>transverse (horizontal) plane</b> <i>trans-VERS</i>	Plane that divides the body into superior (upper) and inferior (lower) portions

## Word Parts Pertaining to Body Structure

TABLES 2-4 to 2-6 provide word roots and prefixes pertaining to body structure.

Table 2-4		Roots for Regions of the Head and Trunk	
Root	Meaning	Example	Definition of Example
cephal/o	head	megacephaly <i>meg-ab-SEF-a-le</i>	abnormal largeness of the head
cervic/o	neck	cervicofacial <i>ser-vih-ko-FA-shal</i>	pertaining to the neck and face
thorac/o	chest, thorax	thoracotomy <i>tho-rab-KOT-o-me</i>	incision (-tomy) into the chest
abdomin/o	abdomen	intra-abdominal <i>in-trab-ab-DOM-ib-nal</i>	within the abdomen
celi/o	abdomen	celiocentesis <i>se-le-o-sen-TE-sis</i>	surgical puncture (centesis) of the abdomen
lapar/o	abdominal wall	laparoscope <i>LAP-ab-ro-scope</i>	instrument (-scope) for viewing the peritoneal cavity through the abdominal wall
lumb/o	lumbar region, lower back	thoracolumbar <i>tho-rak-o-LUM-bar</i>	pertaining to the chest and lumbar region
periton, peritone/o	peritoneum	peritoneal <i>per-ib-to-NE-al</i>	pertaining to the peritoneum

## Exercise 2-4

Complete the exercise. To check your answers go to Appendix 11.

Write the adjective for each of the following definitions. The correct suffix is given in parentheses.

- Pertaining to (-ic) the chest \_\_\_\_\_ thoracic
- Pertaining to (-ic) the head \_\_\_\_\_
- Pertaining to (-al) the neck \_\_\_\_\_
- Pertaining to (-al) the abdomen \_\_\_\_\_
- Pertaining to (-ar) the lower back \_\_\_\_\_

Fill in the Blanks

- Peritonitis (*per-ih-to-NI-tis*) is inflammation (-itis) of the \_\_\_\_\_.
- The adjective celiac (*SE-le-ak*) pertains to the \_\_\_\_\_.
- A laparotomy (*lap-ab-ROT-o-me*) is an incision through the \_\_\_\_\_.

Table 2-5

Roots for the Extremities

Root	Meaning	Example	Definition of Example
acro	extremity, end	acrocyanosis <i>ak-ro-si-ab-NO-sis</i>	bluish discoloration of the extremities
brachi/o	arm	antebrachium <i>an-te-BRA-ke-um</i>	forearm
dactyl/o	finger, toe	polydactyly <i>pol-e-DAK-til-e</i>	having more than the normal number of fingers or toes
ped/o	foot	pedometer <i>pe-DOM-eh-ter</i>	instrument that measures footsteps
pod/o	foot	podiatric <i>po-de-AT-rik</i>	pertaining to study and treatment of the foot

## Exercise 2-5

Complete the exercise. To check your answers go to Appendix 11.

Fill in the blanks.

- Acrokinesia (*ak-ro-ki-NE-se-ah*) is excess motion (-kinesia) of the \_\_\_\_\_.
- Animals that brachiate (*BRA-ke-ate*), such as monkeys, swing from place to place using their \_\_\_\_\_.
- A dactylospasm (*DAK-til-o-spazm*) is a spasm (cramp) of a(n) \_\_\_\_\_.
- The term brachiocephalic (*bra-ke-o-seh-FAL-ik*) refers to the \_\_\_\_\_.
- Sinistropedal (*sih-nis-tro-PE-dal*) refers to the use of the left \_\_\_\_\_.

Table 2-6

## Prefixes for Position and Direction

Prefix	Meaning	Example	Definition of Example
circum-	around	circumoral <i>ser-kum-OR-al</i>	around the mouth
peri-	around	periorbital <i>per-e-OR-bit-al</i>	around the orbit (eye socket)
intra-	in, within	intravascular <i>in-trab-VAS-ku-lar</i>	within a vessel (vascul/o)
epi-	on, over	epithelial <i>ep-ib-THE-le-al</i>	referring to epithelium, tissue that covers surfaces
extra-	outside	extrathoracic <i>eks-trab-tho-RAS-ik</i>	outside the thorax
infra- <sup>a</sup>	below	infrascapular <i>in-frah-SKAP-u-lar</i>	below the scapula (shoulder blade)
sub- <sup>a</sup>	below, under	sublingual <i>sub-LING-gwal</i>	under the tongue (lingu/o)
inter-	between	intercostal <i>in-ter-KOS-tal</i>	between the ribs (cost/o)
juxta-	near, beside	juxtaposition <i>juks-tah-po-ZIH-shun</i>	a location near or beside another structure
para-	near, beside	parasagittal <i>par-ab-SAJ-ib-tal</i>	near or beside a sagittal plane
retro-	behind, backward	retrouterine <i>reh-tro-U-ter-in</i>	behind the uterus
supra-	above	suprapatellar <i>su-prah-pah-TEL-ar</i>	above the patella (kneecap)

<sup>a</sup>Also indicates degree.

## Exercise 2-6

Complete the exercise. To check your answers go to Appendix 11.

### Synonyms

Write a word that means the same as each of the following.

- |                  |                        |
|------------------|------------------------|
| 1. perioral      | _____ circumoral _____ |
| 2. infrascapular | _____                  |
| 3. perivascular  | _____                  |
| 4. subcostal     | _____                  |
| 5. circumorbital | _____                  |

### Opposites

Write a word that means the opposite of each of the following.

- |                  |                           |
|------------------|---------------------------|
| 6. suprapatellar | _____ infrapatellar _____ |
| 7. extracellular | _____                     |
| 8. subscapular   | _____                     |
| 9. intrathoracic | _____                     |

(continued)

## Exercise 2-6 (Continued)

Define the following words.

10. paranasal (*par-ab-NA-zal*) \_\_\_\_\_
11. retroperitoneal (*reh-tro-per-ih-to-NE-al*) \_\_\_\_\_
12. supraabdominal (*su-prah-ab-DOM-ib-nal*) \_\_\_\_\_
13. intrauterine (*in-trah-U-ter-in*) \_\_\_\_\_

Refer to **FIGURES 2-16** and **2-17** to define the following terms.

14. periumbilical (*per-e-um-BIL-ib-kal*) \_\_\_\_\_
15. intergluteal (*in-ter-GLU-te-al*) \_\_\_\_\_
16. epitarsal (*ep-ih-TAR-sal*) \_\_\_\_\_
17. intraocular (*in-trah-OK-u-lar*) \_\_\_\_\_
18. parasacral (*par-ab-SA-kral*) \_\_\_\_\_

## Terminology

### Enrichment Terms

The terms listed below expand on the key terms to increase your knowledge of this chapter topic.

#### The Body as a Whole

<b>digit</b> <i>DIJ-it</i>	A finger or toe (adjective: digital)
<b>epigastrium</b> <i>ep-ih-GAS-tre-um</i>	The epigastric region
<b>fundus</b> <i>FUN-dus</i>	The base or body of a hollow organ, the area of an organ farthest from its opening
<b>hypochondrium</b> <i>hi-po-KON-dre-um</i>	The hypochondriac region (left or right)
<b>lumen</b> <i>LU-men</i>	The central opening within a tube or hollow organ
<b>meatus</b> <i>me-A-tus</i>	A passage or opening
<b>orifice</b> <i>OR-ih-fis</i>	The opening of a cavity
<b>os</b>	Mouth, any body opening
<b>septum</b> <i>SEP-tum</i>	A wall dividing two cavities
<b>sinus</b> <i>SI-nus</i>	A cavity, as within a bone
<b>sphincter</b> <i>SFINK-ter</i>	A circular muscle that regulates an opening

**Terminology****Abbreviations**

The abbreviations listed below are emphasized in this chapter. These are also found, collectively, with all chapter abbreviations in Appendix 2.

**LLQ** Left lower quadrant

**RLQ** Right lower quadrant

**LUQ** Left upper quadrant

**RUQ** Right upper quadrant

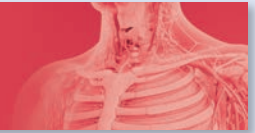2

**Case Study Revisited****Zachary's Return to Class Schedule**

Following his appointment, Zachary decided to accept his physician's advice. He started preparing at least two meals a day at home and often boxed a lunch to eat during the day on campus. The more nutritious meals provided him greater energy; he no longer felt sluggish. He visited the university gym to work out at least two to three times a week for 20 minutes and hoped to increase that time when his schedule permit-

ted. He realized how important exercise is to feeling energized, upbeat, and more confident in his everyday activities. By providing himself with healthy meals and routine exercise, Zachary was able to sleep better. He also made sure he had at least 8 hours of sleep each night. Finally, he recognized that a little knowledge is a dangerous thing and that it is not smart to try and diagnose oneself.





This review tests your understanding of the content introduced in this chapter. Follow the instructions for each exercise and check your answers in Appendix 11.

## LABELING EXERCISE

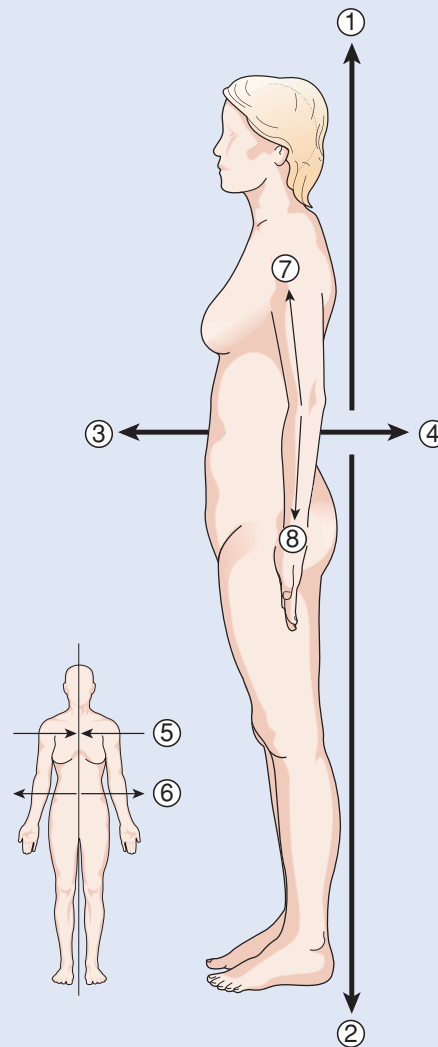
### DIRECTIONAL TERMS

Write the name of each numbered part on the corresponding line of the answer sheet.

Anterior (ventral)  
Distal  
Inferior (caudal)  
Lateral

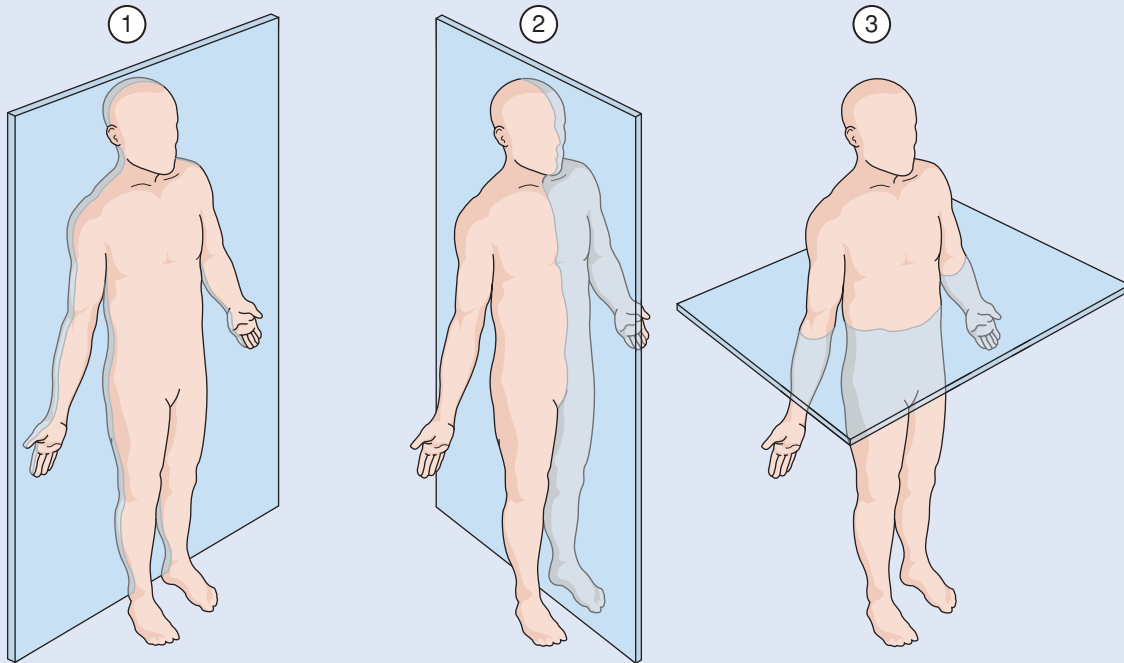
Medial  
Posterior (dorsal)  
Proximal  
Superior (cranial)

1. \_\_\_\_\_
2. \_\_\_\_\_
3. \_\_\_\_\_
4. \_\_\_\_\_
5. \_\_\_\_\_
6. \_\_\_\_\_
7. \_\_\_\_\_
8. \_\_\_\_\_



**PLANES OF DIVISION**

Write the name of each numbered part on the corresponding line of the answer sheet.



Frontal (coronal) plane  
Sagittal plane

Transverse (horizontal) plane

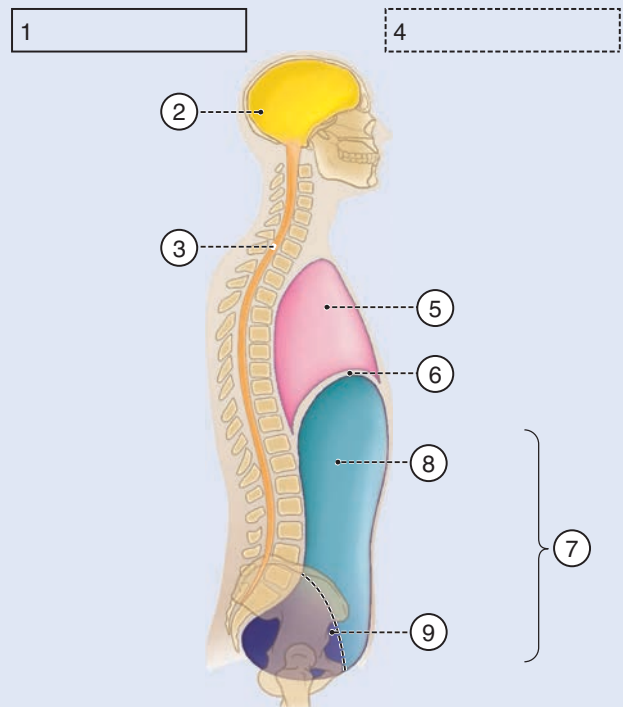
1. \_\_\_\_\_
2. \_\_\_\_\_
3. \_\_\_\_\_

**BODY CAVITIES, LATERAL VIEW**

Write the name of each numbered part on the corresponding line of the answer sheet.

- |                       |                       |
|-----------------------|-----------------------|
| Abdominal cavity      | Pelvic cavity         |
| Abdominopelvic cavity | Spinal cavity (canal) |
| Cranial cavity        | Thoracic cavity       |
| Diaphragm             | Ventral cavity        |
| Dorsal cavity         |                       |

1. \_\_\_\_\_
2. \_\_\_\_\_
3. \_\_\_\_\_
4. \_\_\_\_\_
5. \_\_\_\_\_
6. \_\_\_\_\_
7. \_\_\_\_\_
8. \_\_\_\_\_
9. \_\_\_\_\_

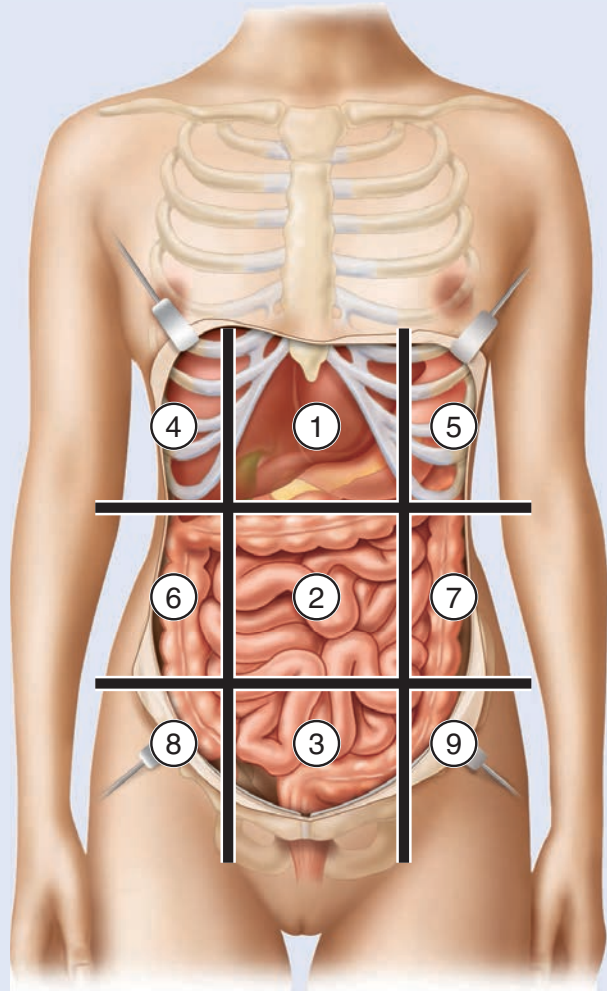


### THE NINE REGIONS OF THE ABDOMEN

Write the name of each numbered part on the corresponding line of the answer sheet.

Epigastric region	Right hypochondriac region
Hypogastric region	Right iliac (inguinal) region
Left hypochondriac region	Right lumbar region
Left iliac (inguinal) region	Umbilical region
Left lumbar region	

1. \_\_\_\_\_
2. \_\_\_\_\_
3. \_\_\_\_\_
4. \_\_\_\_\_
5. \_\_\_\_\_
6. \_\_\_\_\_
7. \_\_\_\_\_
8. \_\_\_\_\_
9. \_\_\_\_\_



## TERMINOLOGY

### MATCHING

Match the following terms, and write the appropriate letter to the left of each number.

- |                         |   |
|-------------------------|---|
| ___ 1. ATP              | a. control region of the cell                       |
| ___ 2. DNA              | b. material that holds the cellular organelles      |
| ___ 3. nucleoplasm      | c. energy compound of the cells                     |
| ___ 4. nucleus          | d. genetic material                                 |
| ___ 5. cytoplasm        | e. material that fills the nucleus                  |
| ___ 6. blastocyte       | a. immature cell                                    |
| ___ 7. ribosomes        | b. organelles that produce ATP                      |
| ___ 8. mitochondria     | c. organelles that contain RNA                      |
| ___ 9. mitosis          | d. small cellular body containing digestive enzymes |
| ___ 10. lysosome        | e. cell division                                    |
| ___ 11. reticular       | a. resembling a gland                               |
| ___ 12. adenoid         | b. fibrous tumor                                    |
| ___ 13. fibroma         | c. cell with a very large nucleus                   |
| ___ 14. megakaryocyte   | d. pertaining to a network                          |
| ___ 15. chromosome      | e. structure that contains genes                    |
| ___ 16. autotroph       | a. resembling a nipple                              |
| ___ 17. papilliform     | b. having no specific form                          |
| ___ 18. amorphous       | c. wasting of tissue                                |
| ___ 19. atrophy         | d. pertaining to the body                           |
| ___ 20. somatic         | e. organism that can manufacture its own food       |
| ___ 21. adiposuria      | a. presence of fat in the urine                     |
| ___ 22. proteolytic     | b. presence of glucose in the urine                 |
| ___ 23. glucosuria      | c. treatment using water                            |
| ___ 24. polysaccharide  | d. compound composed of many simple sugars          |
| ___ 25. hydrotherapy    | e. destroying or dissolving protein                 |
| ___ 26. macropodia      | a. circular cut                                     |
| ___ 27. subdermal       | b. excessive size of the feet                       |
| ___ 28. macrocephaly    | c. beneath the skin                                 |
| ___ 29. celiotomy       | d. abnormal largeness of the head                   |
| ___ 30. circumcision    | e. incision of the abdomen                          |
| <i>Enrichment Terms</i> |   |
| ___ 31. amino acid      | a. pertaining to the internal organs                |
| ___ 32. collagen        | b. breakdown phase of metabolism                    |
| ___ 33. visceral        | c. fibrous protein in connective tissue             |
| ___ 34. cortex          | d. outer region of an organ                         |
| ___ 35. catabolism      | e. building block of protein                        |

- |                   |  |
|-------------------|--|
| ___ 36. fundus    | a. passage or opening                        |
| ___ 37. meatus    | b. circular muscle that regulates an opening |
| ___ 38. lumen     | c. central opening of a tube                 |
| ___ 39. sphincter | d. base of a hollow organ                    |
| ___ 40. septum    | e. dividing wall                             |

**FILL IN THE BLANKS**

*Complete the sentence with the correct term(s).*

41. The study of tissues is called \_\_\_\_\_.
42. The four basic tissue types are \_\_\_\_\_.
43. All the activities of a cell make up its \_\_\_\_\_.
44. The systems involved in circulation are the cardiovascular system and the \_\_\_\_\_.
45. The simple sugar that is the main energy source for metabolism is \_\_\_\_\_.
46. A thick cellular secretion that lubricates and protects tissues is called \_\_\_\_\_.
47. An organic compound that speeds the rate of metabolic reactions is a(n) \_\_\_\_\_.
48. The term dehydration refers to a loss or deficiency of \_\_\_\_\_.
49. The study of form and structure is called \_\_\_\_\_.

**ADJECTIVES**

*Name the body part referred to in the following adjectives.*

50. celiac (*SE-le-ak*) \_\_\_\_\_
51. phalangeal (*fa-LAN-ge-al*) \_\_\_\_\_
52. occipital (*ok-SIP-ih-tal*) \_\_\_\_\_
53. carpal (*KAR-pal*) \_\_\_\_\_
54. cervical (*SER-vih-kal*) \_\_\_\_\_
55. brachial (*BRA-ke-al*) \_\_\_\_\_

**DEFINITIONS**

*Write words for the following definitions.*

56. laparoscope (*LAP-ab-ro-skope*) \_\_\_\_\_
57. suprapubic (*su-prah-PU-bic*) \_\_\_\_\_
58. infraumbilical (*in-fra-um-BIL-ih-kal*) \_\_\_\_\_
59. sublingual (*sub-LING-wal*) \_\_\_\_\_
60. retroperitoneal (*ret-ro-per-ih-to-NE-al*) \_\_\_\_\_
61. bipedal (*BIP-eh-dal*) \_\_\_\_\_

**SYNONYMS**

*Write a word that means the same as each of the following.*

62. posterior \_\_\_\_\_
63. circumocular \_\_\_\_\_
64. submammary \_\_\_\_\_
65. ventral \_\_\_\_\_

**OPPOSITES**

Write a word that means the opposite of each of the following.

66. microcephaly \_\_\_\_\_
67. deep \_\_\_\_\_
68. proximal \_\_\_\_\_
69. subscapular \_\_\_\_\_
70. extracellular \_\_\_\_\_
71. superior \_\_\_\_\_

**ELIMINATIONS**

In each of the sets below, underline the word that does not fit in with the rest and explain the reason for your choice.

72. umbilical region — hypochondriac region — epigastric region — cervical region — iliac region  
\_\_\_\_\_
73. jackknife — supine — transverse— decubitus — prone  
\_\_\_\_\_
74. thoracic cavity — spinal cavity — pelvic cavity — abdominal cavity — abdominopelvic cavity  
\_\_\_\_\_

**TRUE-FALSE**

Examine the following statements. If the statement is true, write T in the first blank. If the statement is false, write F in the first blank and correct the statement by replacing the underlined word in the second blank.

	True or False	Correct Answer
75. A megakaryocyte is a cell with a large <u>nucleus</u> .	T _____	_____
76. An adipocyte is a cell that stores <u>glucose</u> .	F _____	fat _____
77. A whip-like extension of a cell is a <u>flagellum</u> .	_____	_____
78. The cranial and spinal cavities are the <u>ventral</u> body cavities.	_____	_____
79. A <u>midsagittal plane</u> divides the body into equal right and left parts.	_____	_____
80. The wrist is <u>proximal</u> to the elbow.	_____	_____
81. A <u>transverse plane</u> divides the body into anterior and posterior parts.	_____	_____
82. The hypogastric region is <u>inferior</u> to the umbilical region.	_____	_____
83. The right hypochondriac region is in the <u>RUQ</u> .	_____	_____

**WORD BUILDING**

Write a word for each of the following definitions using the word parts provided. Each word part can be used more than once.

-oid	amyl/o	muc/o	aden/o	-ase	lip/o	leuk/o	histi/o	blast
------	--------	-------	--------	------	-------	--------	---------	-------

84. Like or resembling a gland \_\_\_\_\_ adenoid \_\_\_\_\_
85. Immature white blood cell \_\_\_\_\_
86. Enzyme that digests fat \_\_\_\_\_
87. Resembling mucus \_\_\_\_\_
88. Cell that gives rise to tissue \_\_\_\_\_
89. Enzyme that digests starch \_\_\_\_\_
90. Resembling starch \_\_\_\_\_

Write a word for each of the following definitions using the word parts provided. Each word part can be used more than once.

spasm	cephal	-o-	dactyl	extra-	-ic	infra-	syn-	thorac	a-	intra-	-y	poly-
-------	--------	-----	--------	--------	-----	--------	------	--------	----	--------	----	-------

91. cramp of a finger or toe \_\_\_\_\_
92. below the chest \_\_\_\_\_
93. inside the chest \_\_\_\_\_
94. condition of having extra fingers or toes \_\_\_\_\_
95. fusion of the fingers or toes \_\_\_\_\_
96. pertaining to the head and chest \_\_\_\_\_
97. absence of a finger or toe \_\_\_\_\_
98. within the head \_\_\_\_\_
99. absence of a head \_\_\_\_\_

**WORD ANALYSIS**

Define each of the following words, and give the meaning of the word parts in each. Use a dictionary if necessary.

100. homeostasis (*ho-me-o-STA-sis*)

- a. homeo \_\_\_\_\_
- b. stat (from Greek *states*) \_\_\_\_\_
- c. -sis \_\_\_\_\_

101. autophagy (*aw-TOF-ah-je*)

- a. auto \_\_\_\_\_
- b. phag/o \_\_\_\_\_
- c. -y \_\_\_\_\_

102. acrocyanosis (*ak-ro-si-ah-NO-sis*)

- a. acro \_\_\_\_\_
- b. cyan/o \_\_\_\_\_
- c. -sis \_\_\_\_\_

103. antebrachial (*an-te-BRA-ke-al*)

- a. ante- \_\_\_\_\_
- b. brachi/o \_\_\_\_\_
- c. -al \_\_\_\_\_



# Additional Case Studies

## Case Study 2-1: Needle Aspiration of Thyroid Tumor

### Chief Complaint

Mathew, a 65 y/o male, noticed a lump on the side of his neck and went to see his physician. He has a history of prostate cancer and had a prostatectomy 4 years ago. Bilateral lymph node dissection revealed no metastasis. His physician referred him to a surgeon for evaluation of a nodule on the thyroid gland.

### Examination

Dr. Thompson, a general surgeon, examined Mathew and recommended a needle aspiration of the thyroid gland.

The ultrasound-guided fine needle aspiration revealed atypical cells with abundant cytoplasm and prominent nuclei but no metastasis. However, the nuclei showed some morphologic changes. Histologic slides of the left thyroid showed clusters of epithelial cells associated with lymphocytes suggestive of lymphocytic thyroiditis.

### Clinical Course

Mathew underwent a total thyroidectomy and is healing well. A follow-up CT scan of the neck and chest showed no additional nodules or indications of metastatic disease.

### Case Study 2-1 Questions

Follow the instructions for each question and check your answers against Appendix 11.

**Multiple Choice.** Select the best answer and write the letter of your choice to the left of each number.

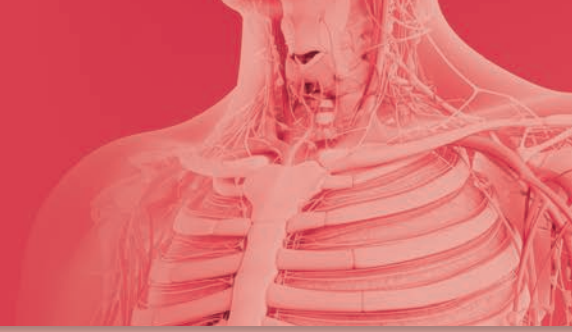- |  |  |
|--|--|
| _____ 1. The suffix in <i>prostatectomy</i> and <i>thyroidectomy</i> means | _____ 2. The singular form of <i>nuclei</i> is |
| a. removal or excision   | a. nucleolus                                   |
| b. incision into   | b. nucleoli                                    |
| c. inflammation  | c. nucleum                                     |
| d. resembling  | d. nucleus                                     |

Identify and give the meaning of the prefixes in the following words.

	Prefix	Meaning of Prefix
3. atypical	_____	_____
4. bilateral	_____	_____
5. metastasis (see Appendix 7)	_____	_____

Find words in the case study for the following.

- A word with a root that means form \_\_\_\_\_
- A word with a root that means tissue \_\_\_\_\_
- Three words that contain a root that means cell \_\_\_\_\_



## Case Study 2-2: Emergency Care

During a triathlon, paramedics responded to a scene with multiple patients involved in a serious bicycle accident. Patti, a 20 y/o woman, lost control of her bike while descending a hill at approximately 40 mph. As she fell, two other cyclists collided with her, sending all three crashing to the ground.

At the scene, Patti reported pain in her head, back, chest, and leg. She also had numbness and tingling in her legs and feet. Other injuries included a cut on her face and on her right arm and an obvious deformity to both her shoulder and knee. She had slight difficulty breathing.

The paramedic did a rapid cephalocaudal assessment and immobilized Patti's neck in a cervical collar. She was secured on a backboard and given oxygen. After her bleeding was controlled and her injured extremities were immobilized, she was transported to the nearest emergency department.

During transport, the paramedic in charge radioed ahead to provide a prehospital report to the charge nurse. Her report included the following information: occipital

and frontal head pain; laceration to right temple, superior and anterior to right ear; lumbar pain; bilateral thoracic pain on inspiration at midclavicular line on the right and midaxillary line on the left; dull aching pain of the posterior proximal right thigh; bilateral paresthesia (numbness and tingling) of distal lower legs circumferentially; varus (knock-knee) adduction deformity of left knee; and posterior displacement deformity of left shoulder.

At the hospital, the emergency department physician ordered radiographs for Patti. Before the procedure, the radiology technologist positioned a lead gonadal shield centered on the midsagittal line above Patti's symphysis pubis to protect her ovaries from unnecessary irradiation by the primary beam. The technologist knew that gonadal shielding is important for female patients undergoing imaging of the lumbar spine, sacroiliac joints, acetabula, pelvis, and kidneys. Shields should not be used for any examination in which an acute abdominal condition is suspected.

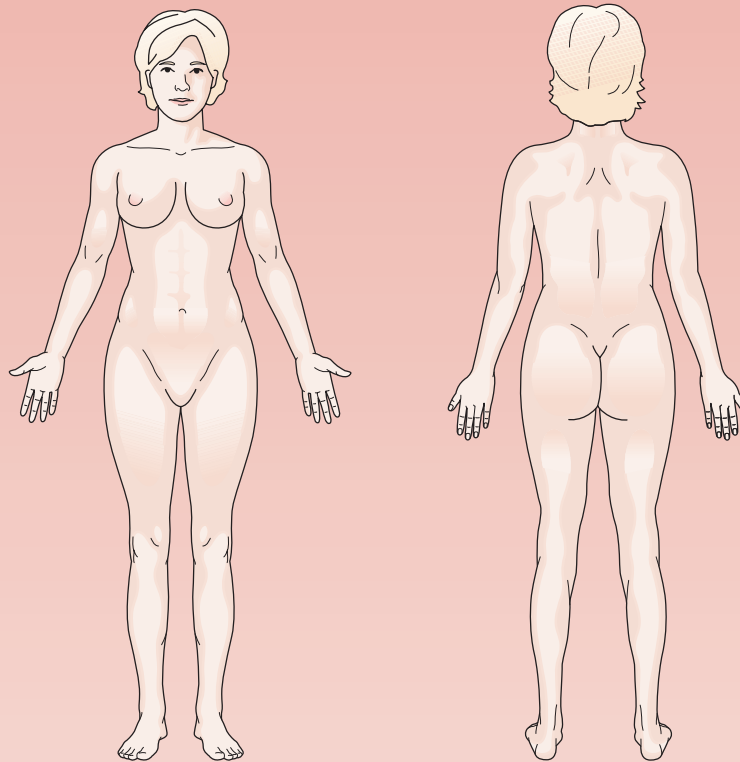
## Case Study 2-2 Questions

Follow the instructions for each question and check your answers against Appendix 11.

**Multiple Choice.** Select the best answer and write the letter of your choice to the left of each number.

- |  |   |
|--|---|
| <p>_____ 1. The term for the timespan between injury and admission to the emergency department is</p> <ul style="list-style-type: none"><li>a. preoperative</li><li>b. prehospital</li><li>c. pretrauma</li><li>d. intrainjury</li></ul> <p>_____ 2. A cephalocaudal assessment goes from</p> <ul style="list-style-type: none"><li>a. front to back</li><li>b. head to toe</li><li>c. side to side</li><li>d. skin to bone</li></ul> <p>_____ 3. The victim's injured extremities were immobilized before transport. Immobilized means</p> <ul style="list-style-type: none"><li>a. abducted as far as possible</li><li>b. internally rotated and flexed</li><li>c. adducted so that the limbs are crossed</li><li>d. held in place to prevent movement</li></ul> | <p>_____ 4. A cervical collar was placed on the victim to stabilize and immobilize the</p> <ul style="list-style-type: none"><li>a. uterus</li><li>b. shoulders</li><li>c. neck</li><li>d. pelvis</li></ul> <p>_____ 5. The singular form of acetabula is</p> <ul style="list-style-type: none"><li>a. acetabulum</li><li>b. acetabia</li><li>c. acetab</li><li>d. acetabulae</li></ul> |
|--|---|

Draw or shade the appropriate area(s) on one or both diagrams for each question pertaining to the case study.

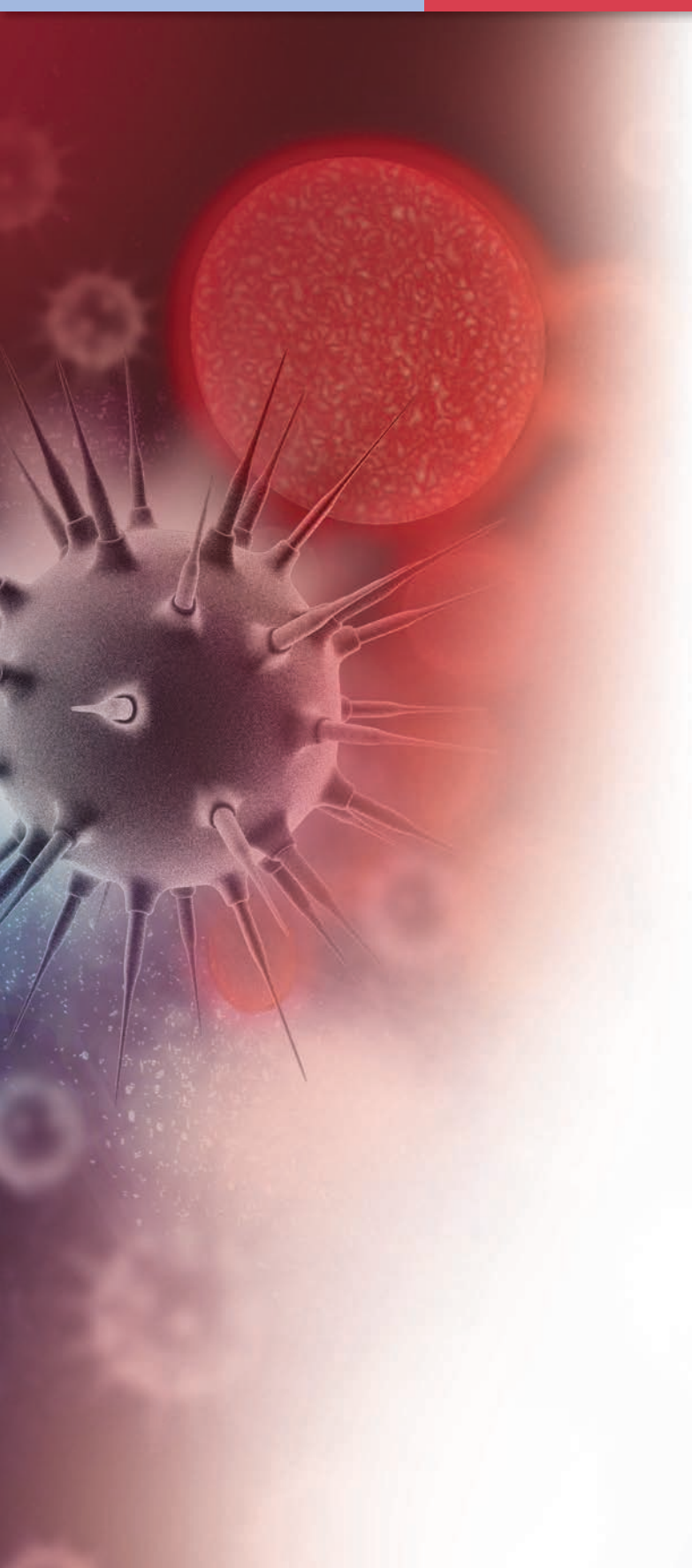


2

6. Draw dots over the areas of the victim's occipital and frontal head pain.
7. Draw a dash (—) over the area of the right temporal laceration—superior and anterior to the right ear.
8. Crosshatch the area of lumbar pain.
9. Place an X over the area of thoracic pain at the anterior left midaxillary line.
10. Draw a star at the area of the pain on the right proximal posterior thigh.
11. Shade the area of the bilateral paresthesia of the distal lower legs, circumferentially.
12. Draw an arrow to show the direction of the varus adduction of the left knee.
13. Draw an arrow to show the direction of the posterior displacement of the left shoulder.
14. Draw a fig leaf to show the gonadal shield on the midsagittal line above the symphysis pubis.
15. Draw a circle around the area of the sacroiliac joints.

### Pretest

**Multiple Choice.** Select the best answer, and write the letter of your choice to the left of each number. To check your answers go to Appendix 11.

- 
- \_\_\_\_\_ 1. A disease that has a sudden and severe onset is described as
- chronic
  - mild
  - acute
  - infectious
- \_\_\_\_\_ 2. Abnormal and uncontrolled growth of tissue is termed
- anemia
  - neoplasia
  - parasitism
  - toxicity
- \_\_\_\_\_ 3. White blood cells engulf foreign organisms by the process of
- phagocytosis
  - egestion
  - ejection
  - dysphagia
- \_\_\_\_\_ 4. The sum of all body defenses against infectious disease is termed
- pyosis
  - complementation
  - secretion
  - immunity
- \_\_\_\_\_ 5. Determination of a disease's nature and cause is called
- admission
  - diagnosis
  - titration
  - prognosis
- \_\_\_\_\_ 6. A simple device for listening to sounds within the body is a
- cystoscope
  - stethoscope
  - barometer
  - speculum
- \_\_\_\_\_ 7. A reason for not using a specific drug is a
- prescription
  - counter-purpose
  - contraindication
  - prognosis
- \_\_\_\_\_ 8. The solvent in an aqueous solution is
- acid
  - salt
  - base
  - water

## Learning Objectives

After careful study of this chapter, you should be able to:

- 1 List the major categories of diseases. **P76**
- 2 Compare the common types of infectious organisms and list some diseases caused by each. **P76**
- 3 Describe the common responses to disease. **P79**
- 4 Describe the main methods used in patient examination. **P91**
- 5 Name and describe nine imaging techniques. **P92**
- 6 Name possible forms of treatment. **P93**
- 7 Describe theories of alternative and complementary medicine and some healing practices used in these fields. **P95**
- 8 Explain the difference between over-the-counter and prescription drugs and the difference between generic and brand name drugs. **P106**
- 9 List three potential adverse side effects of drugs and two ways in which drugs can interact. **P106**
- 10 List three sources of drug information. **P106**
- 11 Describe five safety issues related to the use of herbal medicines. **P106**
- 12 List standard forms for drug preparation and administration. **P107**
- 13 Define basic terms related to disease and treatment. **P96**
- 14 Identify and use word parts pertaining to disease and treatment. **PP82, 98**
- 15 Identify and analyze medical terms and abbreviations in chapter case studies. **PP75, 120**

## Case Study: Mary's Rollerblading Injury



### Chief Complaint

Mary, an active 59 y/o woman, was rollerblading early one morning. When attempting to avoid some loose gravel, she fell, injuring her right wrist and knee. She immediately experienced pain in her wrist and knee and noticed that her knee was swelling. She was able to use her cell phone and call her husband who came and took her to a nearby emergency department.

### Examination

The physician assistant (PA) in the emergency department obtained the following history (Hx) of the incident:

Mary was rollerblading on a path early that morning and skated into some loose gravel, causing her to fall forward. She attempted to break the fall with her arms and ended up landing with her right hand and knee bearing the impact of the fall. She was able to take off the rollerblades and, favoring her right leg, make her way over to a nearby bench, where she used her cell phone to contact

her husband for help. Mary was not wearing a helmet or any protective pads on her knees, elbows, or wrists.

The PA inspected the wrist, which had no open wounds, was slightly deformed, and edematous. She palpated the wrist area and documented that Mary complained of pain with limited range of motion (ROM) of the wrist. The fingers were warm and dry with good sensation. Next, the PA examined the knee that had some superficial abrasions, was swollen and painful, limiting full weight bearing on the right leg. The PA explained the prognosis to Mary and her husband, then proceeded to order diagnostic tests. Mary's knee was cleansed with a mild antiseptic wash and covered with a dry dressing. Her right arm was placed in a sling that was evaluated above her heart with ice packs placed on the wrist and knee.

### Clinical Course

Mary was taken to the radiology department, where an x-ray of the right wrist revealed a distal radius or "Colles" fracture. An MRI was ordered for the knee and showed no fractures or ligament tears. The PA explained to Mary that she might

need to have an arthrocentesis, a tap to remove fluid in the knee joint, which would relieve some of the pain. She also explained that an endoscopic examination of the joint, an arthroscopy, might be required, but that the orthopedic surgeon who had already been consulted would determine whether or not this procedure was necessary.

**Case Study Revisited:** Once you complete this chapter, please review the case follow-up on p. 114.

## Ancillaries *At-A-Glance*

Visit the web resource to access the following resources.

### Learning Resources

- eBook
- A&P Module with Heart & Lung Sounds
- Image Bank
- TestPrep
- Animations
- Audio Pronunciation Glossary

## Introduction

Medical care begins with assessing a disorder using information gathered from the patient and a variety of testing and examination methods. Based on these results, a course of treatment is recommended that may include drugs and surgery.

## Types of Diseases

A disease is any disorder of normal body function. Diseases can be grouped into a number of different but often overlapping categories.

- Infectious diseases are caused by certain harmful **microorganisms** and other **parasites** that live at the expense of another organism. Any disease-causing agent is described as a **pathogen**.
- Degenerative diseases result from wear and tear, aging, or **trauma** (injury) that can lead to a **lesion** (wound) and perhaps **necrosis** (death of tissue). Common examples include arthritis, cardiovascular problems, and certain respiratory disorders such as emphysema. Structural malformations such as congenital malformations, **prolapse** (dropping), or **hernia** (rupture) may also result in degenerative changes.
- **Neoplasia** is the abnormal and uncontrolled growth of tissue.
- Immune disorders include failures of the immune system, allergies, and autoimmune diseases, in which the body makes antibodies to its own tissues. (Immune disorders receive more detailed discussion in Chapter 11.)

- Metabolic disorders result from lack of enzymes or other factors needed for cellular functions. Many hereditary disorders fall into this category. Malnutrition caused by inadequate intake of nutrients or inability of the body to absorb and use nutrients also upsets metabolism. (Metabolic disorders are discussed in more detail in Chapter 13, and hereditary disorders are discussed in Chapter 16.)
- Hormonal disorders are caused by underproduction or overproduction of hormones or by an inability of the hormones to function properly. One common example is diabetes mellitus. (Chapter 9 has more detail on hormonal disorders.)
- Mental and emotional disorders affect the mind and adaptation of an individual to his or her environment. (Chapter 7 has further discussion on behavioral disorders.)

Some methods for naming diseases are described in **BOX 3-1**.

The cause of a disease is its **etiology** (*e-te-OL-o-je*), although many diseases have multiple interacting causes. An **acute** disease is sudden, severe, and of short duration. A **chronic** disease is of long duration and progresses slowly. One health profession that deals with the immediate effects of acute disease is the emergency medical technician (EMT) (**BOX 3-2**).

## Infectious Diseases

Infectious diseases are caused by viruses, bacteria, fungi (yeasts and molds), protozoa (single-celled animals), and worms (helminths) (**BOX 3-3**). Infecting organisms can enter



## FOCUS ON WORDS

BOX 3-1

### Name That Disease

Diseases get their names in a variety of ways. Some are named for the places where they were first found, such as Lyme disease for Lyme, Connecticut; West Nile disease, Rift Valley fever, and Ebola for places in Africa; and hantavirus fever for a river in Korea. Others are named for the people who first described them, such as Cooley anemia; Crohn disease, an inflammatory bowel disease; and Hodgkin disease of the lymphatic system. Note, however, that the World Health Organization (WHO) is discouraging the use of people, places, and animals in naming diseases, because these names can be offensive or negative and are often inaccurate.

Many diseases are named on the basis of the symptoms they cause. Tuberculosis causes small lesions known as

tubercles in the lungs and other tissues. Skin anthrax produces lesions that turn black, and its name comes from the same root as anthracite coal. In sickle cell anemia, red blood cells become distorted into a crescent shape when they give up oxygen. Having lost their smooth, round form, the cells jumble together, blocking small blood vessels and depriving tissues of oxygen.

Bubonic plague causes painful and enlarged lymph nodes called buboes. Lupus erythematosus, a systemic autoimmune disorder, is named for the Latin term for wolf, because the red rash that may form on the faces of people with this disease gives them a wolf-like appearance. Yellow fever, scarlet fever, and rubella (German measles) are named for colors associated with the pathology of these diseases.

3



## HEALTH PROFESSIONS

### Emergency Medical Technicians

BOX 3-2

Emergency medical technicians (EMTs) are the first healthcare professionals to arrive at the scene of a motor vehicle accident, heart attack, or other emergency situation. EMTs must assess and respond rapidly to a medical crisis, taking a medical history, performing a physical examination, stabilizing the patient, and, if necessary, transporting the patient to the nearest medical facility.

To perform their lifesaving duties, EMTs need extensive training, including a thorough understanding of anatomy and physiology. EMTs must know how to use specialized equipment, such as backboards to immobilize injuries, and

automated external defibrillators (AEDs) to treat cardiac arrest. At medical facilities, EMTs work closely with physicians and nurses, reporting on histories, physical examinations, and measures taken to stabilize the patient. Most EMTs receive their training from college or technical schools and must be certified in the state where they are employed.

As the American population ages and becomes concentrated in urban centers, the rate of accidents and other emergencies is expected to rise. Thus, the need for EMTs remains high. For more information about this career, contact the National Association of Emergency Medical Technicians at [naemt.org](http://naemt.org).



## FOR YOUR REFERENCE

### Common Infectious Organisms

BOX 3-3

Type of Organism	Description	Examples of Diseases Caused
<b>bacteria</b> <i>bak-TE-re-ah</i>	simple microscopic organisms that are widespread throughout the world, some can produce disease; singular: bacterium ( <i>bak-TE-re-um</i> )	
<b>cocci</b> <i>KOK-si</i>	round bacteria; may be in clusters (staphylococci), chains (streptococci), and other formations; singular: coccus ( <i>KOK-us</i> )	pneumonia, rheumatic fever, food poisoning, septicemia, urinary tract infections, gonorrhea
<b>bacilli</b> <i>bah-SIL-i</i>	rod-shaped bacteria; singular: bacillus ( <i>ba-SIL-us</i> )	typhoid, dysentery, salmonellosis, tuberculosis, botulism, tetanus
<b>vibrios</b> <i>VIB-re-oze</i>	short curved rods	cholera, gastroenteritis
<b>spirochetes</b> <i>SPI-ro-ketze</i>	corkscrew-shaped bacteria that move with a twisting motion	Lyme disease, syphilis, Vincent disease

(continued)





## FOR YOUR REFERENCE (Continued)

### Common Infectious Organisms

BOX 3-3

Type of Organism	Description	Examples of Diseases Caused
<b>chlamydia</b> <i>klah-MID-e-ah</i>	extremely small bacteria with complex life cycles that grow in living cells but, unlike viruses, are susceptible to antibiotics	conjunctivitis, trachoma, pelvic inflammatory disease (PID), and other sexually transmitted infections (STIs)
<b>rickettsia</b> <i>rih-KET-se-ah</i>	extremely small bacteria that grow in living cells but are susceptible to antibiotics	typhus, Rocky Mountain spotted fever
<b>viruses</b> <i>VI-rus-es</i>	submicroscopic infectious agents that can live and reproduce only within living cells	colds, herpes, hepatitis, measles, varicella (chickenpox), influenza, AIDS
<b>fungi</b> <i>FUN-ji</i>	simple, nongreen plants, some of which are parasitic; includes yeasts and molds; singular: fungus ( <i>FUN-gus</i> )	candidiasis, skin infections (tinea, ringworm), valley fever
<b>protozoa</b> <i>pro-to-ZO-ah</i>	single-celled animals; singular: protozoan ( <i>pro-to-ZO-on</i> )	dysentery, <i>Trichomonas</i> infection, malaria
<b>helminths</b> <i>HEL-minths</i>	worms	trichinosis; infestations with roundworms, pinworms, hookworms

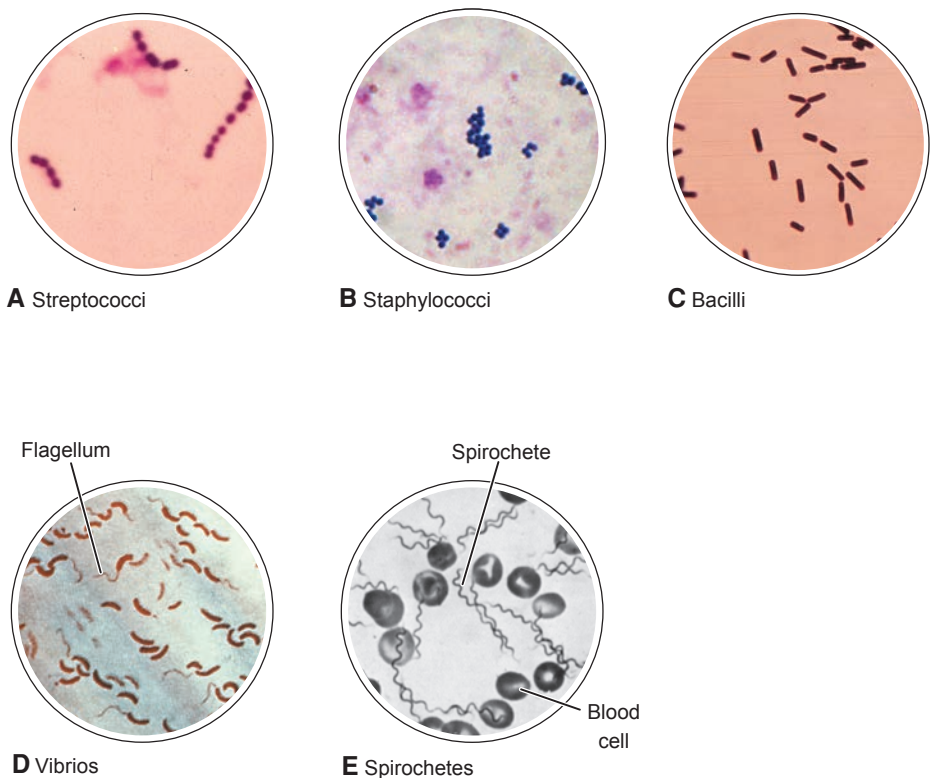
the body through several routes, or portals of entry, including damaged skin, respiratory tract, digestive system, and urinary and reproductive tracts. An infected person's bodily discharges may contain organisms that spread infection through the air, food, water, or direct contact. Microorganisms often produce disease by means of the **toxins** (poisons) they release. The presence of harmful microorganisms or their toxins in the body is termed **sepsis**.

## BACTERIA

Bacteria occur in the following shapes, as shown in **FIGURE 3-1**:

- Round, or cocci
- Rod-shaped, or bacilli
- Curved, including vibrios and spirochetes

Bacteria may be named according to their shape and also by the arrangements they form (see **FIG. 3-1**). They are also described according to the dyes they take up when stained in the laboratory. Chlamydia and rickettsia are two bacterial groups that are smaller than typical bacteria and can grow only within living host cells (see **BOX 3-3**).



**FIGURE 3-1 Bacteria.** **A.** Streptococci, round bacteria in chains. **B.** Staphylococci, round bacteria in clusters. **C.** Bacilli, rod-shaped bacteria. **D.** Vibrios, short curved rods. **E.** Spirochetes, spiral-shaped bacteria.

## Responses to Disease

### INFLAMMATION

A common response to infection and to other forms of disease is **inflammation**. When cells are injured, they release chemicals that allow blood cells and fluids to move into the tissues. This inflow of blood results in the four signs of inflammation:

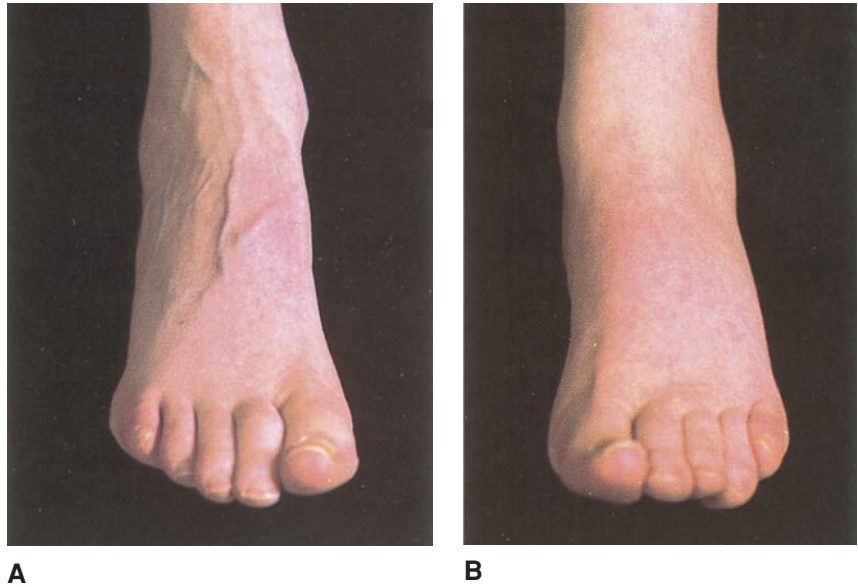- Heat
- Pain
- Redness
- Swelling

The suffix *-itis* indicates inflammation, as in appendicitis (inflammation of the appendix) and tonsillitis (inflammation of the tonsils).

Inflammation is one possible cause of **edema**, a swelling or accumulation of fluid in the tissues (FIG. 3-2). Other causes of edema include fluid blockage, heart failure, and imbalance in body fluid composition, as described in later chapters.

### PHAGOCYTOSIS

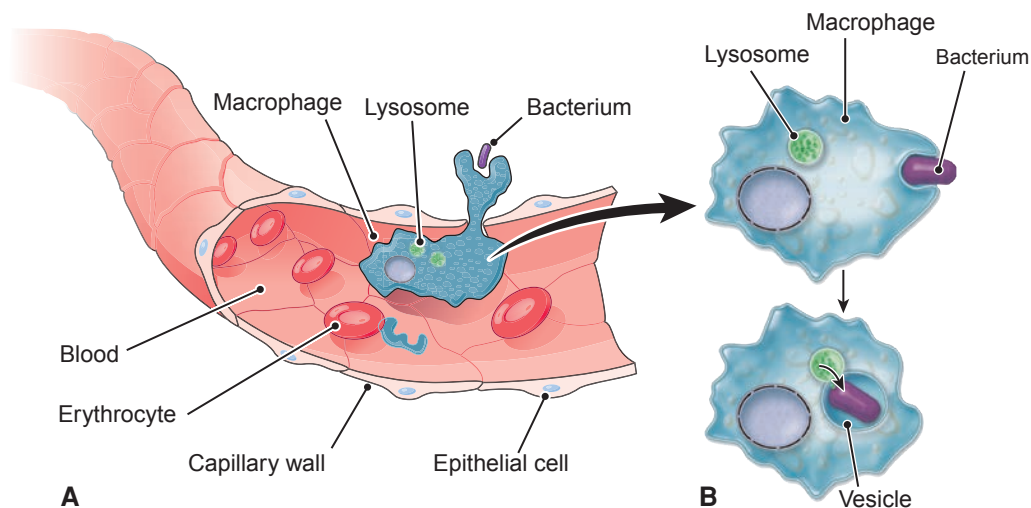
The body uses **phagocytosis** to get rid of invading microorganisms, damaged cells, and other types of harmful debris. Certain white blood cells are capable of engulfing these materials and destroying them internally (FIG. 3-3). Phagocytic cells are found circulating in the blood, in the tissues, and in the lymphatic system (see Chapters 10 and 11). The remains of phagocytosis consist of fluid and white blood cells, a mixture called **pus**.



**FIGURE 3-2 Edema.** **A.** A normal foot showing veins, tendons, and bones. **B.** Edema (swelling) obscures surface features.

### IMMUNITY

**Immunity** refers to all our defenses against infectious disease. Inflammation and phagocytosis are examples of inborn or innate protective mechanisms, which are based on a person's genetic makeup and do not require any previous exposure to a disease organism. Other defenses that fall into this category are mechanical barriers, such as intact skin and mucous membranes, as well as body secretions, such as stomach acid and enzymes in saliva and tears.



**FIGURE 3-3 Phagocytosis.** **A.** A phagocytic white blood cell squeezes through a capillary wall to engulf a bacterium. **B.** The bacterium is enclosed in a vesicle and destroyed by lysosomal enzymes.

Immunity that we develop during life from exposure to disease organisms is termed *adaptive immunity*, or acquired immunity. This type of immunity is specific for particular diseases encountered by natural exposure or by the administration of vaccines (see Chapter 11). The system responsible for adaptive immunity consists of cells in the blood, lymphatic system, and other tissues. These cells recognize different foreign invaders and get rid of them by direct attack and by producing circulating antibodies that immobilize and help destroy them. The immune system also monitors the body continuously for abnormal and malfunctioning cells, such as cancer cells. The immune system may overreact to produce allergies and may react to one's own tissues to cause autoimmune diseases.

## Neoplasia

As noted earlier, a **neoplasm** is an abnormal and uncontrolled growth of tissue—a tumor or growth. A **benign**

neoplasm does not spread, that is, undergo **metastasis** to other tissues, although it may cause damage at the site where it grows. An invasive neoplasm that can metastasize to other tissues is termed **malignant** and is commonly called *cancer*. A malignant tumor that involves epithelial tissue is a **carcinoma**. If the tumor arises in glandular epithelium, it is an adenocarcinoma (the root *aden/o* means “gland”); a cancer of pigmented epithelial cells (melanocytes) is a melanoma. A neoplasm that involves connective tissue or muscle is a **sarcoma**. Cancers of the blood, lymphatic system, and nervous system are classified according to the cell types involved and other clinical features. Further descriptions of these cancers appear in Chapters 11 and 7.

Often mistaken for a malignancy is a **cyst**, a sac or pouch filled with fluid or semisolid material that is abnormal but not cancerous. Common sites for cyst formation are the breasts, the skin's sebaceous glands, and the ovaries. Causes of cyst formation include infection or blockage of a duct.

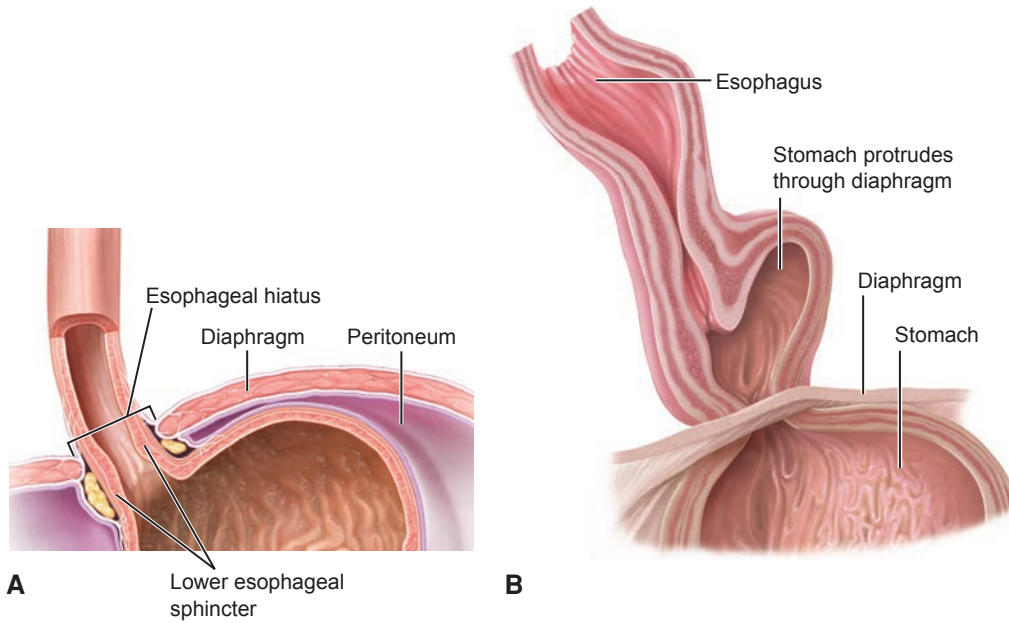
## Terminology

## Key Terms

The terms listed below are emphasized in this chapter. Knowing them will help you organize and prioritize your learning. These boldface terms are also found, collectively, with all chapter key terms in the Glossary.

### Disease

<b>acute</b> <i>ab-KUTE</i>	Sudden, severe; having a short course
<b>benign</b> <i>be-NINE</i>	Not recurrent or malignant, favorable for recovery, describing a tumor that does not spread (metastasize) to other tissues
<b>carcinoma</b> <i>kar-sib-NO-mah</i>	A malignant neoplasm composed of epithelial cells (from Greek root <i>carcino</i> , meaning “crab”) (adjective: carcinomatous)
<b>chronic</b> <i>KRON-ik</i>	Of long duration, progressing slowly
<b>cyst</b> <i>sist</i>	An abnormal filled sac or pouch; used as a root meaning a normal bladder or sac, such as the urinary bladder or gallbladder (root: <i>cyst/o</i> )
<b>edema</b> <i>eh-DE-mah</i>	Accumulation of fluid in the tissues, swelling; adjective: edematous (eh-DE-mah-tus) (see <b>FIG. 3-2</b> )
<b>etiology</b> <i>e-te-OL-o-je</i>	The cause of a disease
<b>Gram stain</b>	A laboratory staining procedure that divides bacteria into two groups: gram positive, which stains purple, and gram negative, which stains red
<b>hernia</b> <i>HER-ne-ab</i>	Protrusion of an organ through an abnormal opening; commonly called a rupture ( <b>FIG. 3-4</b> )
<b>immunity</b> <i>ih-MU-nih-te</i>	All our defenses against infectious disease
<b>inflammation</b> <i>in-flah-MA-shun</i>	A localized response to tissue injury characterized by heat, pain, redness, and swelling
<b>lesion</b> <i>LE-zhun</i>	A distinct area of damaged tissue, an injury or wound



**FIGURE 3-4 Hernia. A.** Normal stomach. **B.** Hiatal hernia. The stomach protrudes through the diaphragm into the thoracic cavity, raising the level of the junction between the esophagus and the stomach.

## Terminology

## Key Terms (Continued)

<b>malignant</b> <i>mah-LIG-nant</i>	Growing worse, harmful, tending to cause death, describing an invasive tumor that can spread (metastasize) to other tissues
<b>metastasis</b> <i>meh-TAS-tab-sis</i>	Spread from one part of the body to another, characteristic of cancer; verb is metastasize ( <i>meh-TAS-tab-size</i> ), adjective: metastatic ( <i>met-ab-STAT-ik</i> ); from Greek met/a (beyond, change) + stasis (stand)
<b>microorganism</b> <i>mi-kro-OR-gan-izm</i>	An organism too small to be seen without the aid of a microscope
<b>necrosis</b> <i>neh-KRO-sis</i>	Death of tissue (root necr/o means “death”); adjective: necrotic ( <i>neh-KROT-ik</i> )
<b>neoplasia</b> <i>ne-o-PLA-ze-ah</i>	An abnormal and uncontrolled growth of tissue; from prefix neo- meaning “new” and root plasm meaning “formation”
<b>neoplasm</b> <i>NE-o-plazm</i>	A tumor, or abnormal growth, which may be benign or malignant (root onc/o and suffix -oma refer to neoplasms)
<b>parasite</b> <i>PAR-ab-site</i>	An organism that grows on or in another organism (the host), causing damage to it
<b>pathogen</b> <i>PATH-o-jen</i>	An organism capable of causing disease (root path/o means “disease”)
<b>phagocytosis</b> <i>fag-o-si-TO-sis</i>	The ingestion of organisms, such as invading bacteria or small particles of waste material by a cell (root phag/o means “to eat”); the phagocytic cell, or phagocyte, then destroys the ingested material (see <b>FIG. 3-3</b> )
<b>prolapse</b> <i>PRO-laps</i>	A dropping or downward displacement of an organ or part, ptosis
<b>pus</b>	A product of inflammation consisting of fluid and white blood cells (root: py/o)
<b>sarcoma</b> <i>sar-KO-mah</i>	A malignant neoplasm arising from connective tissue (from Greek root sarco, meaning “flesh”); adjective: sarcomatous

(continued)

## Terminology

## Key Terms (Continued)

**sepsis**  
SEP-sis

The presence of harmful microorganisms or their toxins in the blood or other tissues; adjective: septic

**toxin**  
TOKS-in

A poison; adjective: toxic (roots: tox/o, toxic/o)

**trauma**  
TRAW-mah

A physical or psychological wound or injury

See also **BOX 3-3** on infectious organisms.

## Word Parts Pertaining to Disease

See **TABLES 3-1** to **3-5**.

Table 3-1

## Roots for Disease

Root	Meaning	Example	Definition of Example
alg/o, algi/o, algesi/o	pain	algisia <i>al-JE-ze-ab</i>	condition of having pain
carcin/o	cancer, carcinoma	carcinoid <i>KAR-sih-noyd</i>	resembling a carcinoma
cyst/o	filled sac or pouch, cyst, bladder	cystic <i>SIS-tik</i>	pertaining to or having cysts
lith	calculus, stone	lithiasis <i>lith-I-ab-sis</i>	stone formation
onc/o	tumor	oncogenic <i>on-ko-JEN-ik</i>	causing a tumor
path/o	disease	pathogen <i>PATH-o-jen</i>	organism that produces disease
py/o	pus	pyocyst <i>PI-o-sist</i>	cyst filled with pus
pyr/o, pyret/o	fever, fire	pyrexia <i>pi-REK-se-ab</i>	fever
scler/o	hard	sclerosis <i>skle-RO-sis</i>	hardening of tissue
tox/o, toxic/o	poison	endotoxin <i>en-do-TOK-sin</i>	toxin within bacterial cells

## Exercise 3-1

Complete the exercise. To check your answers go to Appendix 11.

Identify and define the root in each of the following words.

	Root	Meaning of Root
1. toxicology ( <i>tok-sih-KOL-o-je</i> )	toxic/o	poison
2. pyorrhea ( <i>pi-o-RE-ab</i> )	_____	_____
3. lithotomy ( <i>lih-THOT-o-me</i> )	_____	_____
4. pathologist ( <i>pah-THOL-o-jist</i> )	_____	_____

## Exercise 3-1 (Continued)

### Fill in the blanks

5. Arteriosclerosis (*ar-te-re-o-skleh-RO-sis*) is a(n) \_\_\_\_\_ of the arteries.
6. A urolith (*U-ro-lith*) is a(n) \_\_\_\_\_ in the urinary tract (ur/o).
7. A cystotome (*SIS-to-tome*) is an instrument for incising the \_\_\_\_\_.
8. The term pathogenic (*path-o-JEN-ik*) means producing \_\_\_\_\_.
9. A carcinogen (*kar-SIN-o-jen*) is a substance that causes \_\_\_\_\_.
10. An exotoxin (*ek-so-TOK-sin*) is a(n) \_\_\_\_\_ secreted by bacterial cells.
11. Pyoderma (*pi-o-DER-mah*) is a skin disease associated with \_\_\_\_\_.
12. An algometer (*al-jeh-SIM-eh-ter*) is used to measure sensitivity to \_\_\_\_\_.
13. An oncogene (*ON-ko-jene*) is a gene that causes a(n) \_\_\_\_\_.
14. A pyrogenic (*pi-ro-JEN-ik*) agent induces \_\_\_\_\_.

Table 3-2

Prefixes for Disease

Prefix	Meaning	Example	Definition of Example
brady-	slow	bradypnea <i>brad-ip-NE-ab</i>	slow breathing (-pnea) rate
dys-	abnormal, painful, difficult	dysplasia <i>dis-PLA-je-ab</i>	abnormal development (plas) of tissue
mal-	bad, poor	malabsorption <i>mal-ab-SORP-shun</i>	poor absorption of nutrients
pachy-	thick	pachycephaly <i>pak-ih-SEF-ab-le</i>	abnormal thickness of the skull
tachy-	rapid	tachycardia <i>tak-ih-KAR-de-ab</i>	rapid heart (cardi/o) rate
xero-	dry	xeroderma <i>ze-ro-DER-mah</i>	dryness of the skin

## Exercise 3-2

Complete the exercise. To check your answers go to Appendix 11.

Match the following terms, and write the appropriate letter to the left of each number.

- |  |                                      |
|--|--------------------------------------|
| ___ 1. tachycardia ( <i>tak-ih-KAR-de-ab</i> ) | a. abnormal thickness of the fingers |
| ___ 2. pachydactyly ( <i>pak-e-DAK-til-e</i> ) | b. abnormal nourishment of tissue    |
| ___ 3. bradypnea ( <i>brad-IP-ne-ab</i> )      | c. difficulty in swallowing          |
| ___ 4. dystrophy ( <i>DIS-tro-fee</i> )        | d. slow breathing                    |
| ___ 5. dysphagia ( <i>dis-FA-je-ab</i> )       | e. rapid heart rate                  |

Identify and define the prefix in each of the following words.

	Prefix	Meaning of Prefix
6. xerosis ( <i>ze-RO-sis</i> )	_____	_____
7. dysentery ( <i>DIS-en-ter-e</i> )	_____	_____
8. maladjustment ( <i>mal-ad-JUST-ment</i> )	_____	_____

Table 3-3

## Suffixes for Disease

Suffix	Meaning	Example	Definition of Example
-algia, -algnesia	pain	neuralgia <i>nu-RAL-je-ab</i>	pain in a nerve (neur/o)
-cele	hernia, localized dilation	gastrocele <i>GAS-tro-sele</i>	hernia of the stomach (gastr/o)
-clasis, -clasia	breaking	karyoclasia <i>kar-e-OK-lah-sis</i>	breaking of a nucleus (kary/o)
-itis	inflammation	cystitis <i>sis-TI-tis</i>	inflammation of the urinary bladder (cyst/o)
-megaly	enlargement	hepatomegaly <i>hep-ab-to-MEG-ab-le</i>	enlargement of the liver (hepat/o)
-odynia	pain	urodynia <i>u-ro-DIN-e-ab</i>	pain on urination (ur/o)
-oma <sup>a</sup>	tumor	lipoma <i>li-PO-mah</i>	tumor of fat cells
-pathy	any disease of	nephropathy <i>nep-ROP-ab-the</i>	any disease of the kidney (nephro)
-rhage <sup>b</sup> , -rhagia <sup>b</sup>	bursting forth, profuse flow, hemorrhage	hemorrhage <i>HEM-or-ij</i>	profuse flow of blood
-rhea <sup>b</sup>	flow, discharge	pyorrhea <i>pi-o-RE-ab</i>	discharge of pus
-rhexis <sup>b</sup>	rupture	amniorrhaxis <i>am-ne-o-REK-sis</i>	rupture of the amniotic sac (bag of waters)
-schisis	fissure, splitting	retinoschisis <i>ret-ih-NOS-kih-sis</i>	splitting of the retina of the eye

<sup>a</sup>Plurals: -omas, -omata.

<sup>b</sup>Remember to double the r when adding this suffix to a root.

## Exercise 3-3

Complete the exercise. To check your answers go to Appendix 11.

Match the following terms, and write the appropriate letter to the left of each number.

- |  |                                      |
|--|--------------------------------------|
| ___ 1. adipocela ( <i>AD-ih-po-sele</i> )            | a. hernia containing fat             |
| ___ 2. blastoma ( <i>blas-TO-mah</i> )               | b. fissure of the chest              |
| ___ 3. thoracoschisis ( <i>tho-rah-KOS-kih-sis</i> ) | c. breaking of a bone                |
| ___ 4. melanoma ( <i>mel-ab-NO-mah</i> )             | d. tumor of immature cells           |
| ___ 5. osteoclasia ( <i>os-te-OK-lah-sis</i> )       | e. tumor of pigmented cells          |
| ___ 6. gastrodynia ( <i>gas-tro-DIN-e-ab</i> )       | a. local dilatation containing fluid |
| ___ 7. menorrhagia ( <i>men-o-RA-je-ab</i> )         | b. pain in the stomach               |
| ___ 8. hydrocele ( <i>HI-dro-sele</i> )              | c. pain in the head                  |
| ___ 9. cephalgia ( <i>seh-FAL-je-ab</i> )            | d. profuse menstrual flow            |
| ___ 10. hepatorrhaxis ( <i>hep-ab-to-REK-sis</i> )   | e. rupture of the liver              |

## Exercise 3-3 (Continued)

The root *my/o* means “muscle.” Define the following terms.

11. myalgia (*mi-AL-je-ab*) \_\_\_\_\_
12. myopathy (*mi-OP-ab-the*) \_\_\_\_\_
13. myorrhexis (*mi-o-REK-sis*) \_\_\_\_\_
14. myodynia (*mi-o-DIN-e-ab*) \_\_\_\_\_
15. myoma (*mi-O-mah*) \_\_\_\_\_

Some words pertaining to disease are used as suffixes in compound words (TABLE 3-4). As previously noted, the term *suffix* is used in this book to mean any word part that

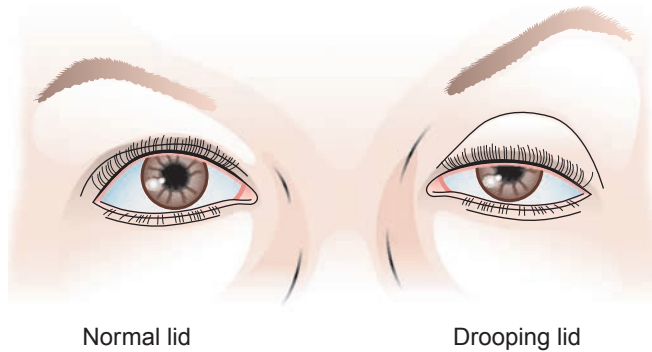
consistently appears at the end of words. This may be a simple suffix (such as *-y*, *-ia*, *-ic*), a word, or a root–suffix combination, such as *-megaly*, *-rhagia*, *-pathy*.

Table 3-4 Words for Disease Used as Suffixes

Word	Meaning	Example	Definition of Example
dilation <sup>a</sup> , dilatation <sup>a</sup>	expansion, widening	vasodilation <i>vas-o-di-LA-shun</i>	widening of blood vessels ( <i>vas/o</i> )
ectasia, ectasis	dilation, dilatation, distension	gastroectasia <i>gas-trek-TA-se-ab</i>	dilatation of the stomach ( <i>gastr/o</i> )
edema	accumulation of fluid, swelling	cephaledema <i>sef-al-eh-DE-mah</i>	swelling of the head
lysis <sup>a</sup>	separation, loosening, dissolving, destruction	dialysis <i>di-AL-ih-sis</i>	separation of substances by passage through ( <i>dia-</i> ) a membrane
malacia	softening	craniomalacia <i>kra-ne-o-mah-LA-she-ab</i>	softening of the skull ( <i>crani/o</i> )
necrosis	death of tissue	osteonecrosis <i>os-te-o-neh-KRO-sis</i>	death of bone ( <i>oste/o</i> ) tissue
ptosis	dropping, downward displacement, prolapse	blepharoptosis <i>blef-eh-rop-TO-sis</i>	dropping or drooping of the eyelid ( <i>blephar/o</i> ; FIG. 3-5)
sclerosis	hardening	phlebosclerosis <i>fleb-o-skleh-RO-sis</i>	hardening of veins ( <i>phleb/o</i> )
spasm	sudden contraction, cramp	arteriospasm <i>ar-TERE-e-o-spazm</i>	spasm of an artery
stasis <sup>a</sup>	suppression, stoppage	menostasis <i>men-OS-tab-sis</i>	suppression of menstrual ( <i>men/o</i> ) flow
stenosis	narrowing, constriction	bronchostenosis <i>brong-ko-steh-NO-sis</i>	narrowing of a bronchus (air passageway)
toxin	poison	nephrotoxin <i>nef-ro-TOK-sin</i>	substance poisonous or harmful for the kidneys

<sup>a</sup>May also refer to treatment.





**FIGURE 3-5** Blepharoptosis (dropping or drooping of the eyelid). Ptosis means a downward displacement.

## Exercise 3-4

Complete the exercise. To check your answers go to Appendix 11.

Match the following terms, and write the appropriate letter to the left of each number.

- |   |                               |
|---|-------------------------------|
| ___ 1. myolysis ( <i>mi-OL-ib-sis</i> )                 | a. destruction of blood cells |
| ___ 2. osteomalacia ( <i>os-te-o-mah-LA-she-ah</i> )    | b. death of heart tissue      |
| ___ 3. cardioneclerosis ( <i>kar-de-o-neb-KRO-sis</i> ) | c. stoppage of blood flow     |
| ___ 4. hemolysis ( <i>he-MOL-ib-sis</i> )               | d. softening of a bone        |
| ___ 5. hemostasis ( <i>he-mo-STA-sis</i> )              | e. dissolving of muscle       |

The root splen/o means “spleen.” Define the following words.

6. splenomalacia (*sple-no-mah-LA-she-ah*) \_\_\_\_\_
7. splenoptosis (*sple-nop-TO-sis*) \_\_\_\_\_
8. splenotoxin (*sple-no-TOK-sin*) \_\_\_\_\_

Table 3-5

### Prefixes and Roots for Infectious Diseases

Word Part	Meaning	Example	Definition of Example
<b>Prefixes</b>			
staphylo-	grape-like cluster	staphylococcus <i>staf-ib-lo-KOK-us</i>	a round bacterium that forms clusters (see FIG. 3-1B)
strepto-	chain	streptobacillus <i>strep-to-bah-SIL-us</i>	a rod-shaped bacterium that forms chains (see FIG. 3-1A)
<b>Roots</b>			
bacill/i, bacill/o	bacillus	bacilluria <i>bas-ih-LU-re-ah</i>	bacilli in the urine (-uria)
bacteri/o	bacterium	bacteriostatic <i>bak-tere-e-o-STAT-ik</i>	stopping (stasis) the growth of bacteria
myc/o	fungus, mold	mycotic <i>mi-KOT-ik</i>	pertaining to a fungus
vir/o	virus	viremia <i>vi-RE-me-ah</i>	presence of viruses in the blood (-emia)

## Exercise 3-5

Complete the exercise. To check your answers go to Appendix 11.

Fill in the blanks.

1. A bactericidal (*bak-tere-ih-SI-dal*) agent kills \_\_\_\_\_.
2. A mycosis (*mi-KO-sis*) is any disease caused by a(n) \_\_\_\_\_.
3. The term bacillary (*BAS-il-ab-re*) means pertaining to \_\_\_\_\_.
4. The prefix strepto- means \_\_\_\_\_.
5. The prefix staphylo- means \_\_\_\_\_.

Use the suffix -logy to write a word that means the same as each of the following.

6. Study of fungi \_\_\_\_\_
7. Study of viruses \_\_\_\_\_
8. Study of bacteria \_\_\_\_\_

## Terminology Enrichment Terms

The terms listed below expand on the key terms to increase your knowledge of this chapter topic.

### Disease

<b>acid-fast stain</b>	A laboratory staining procedure used mainly to identify the tuberculosis (TB) organism
<b>communicable</b> <i>ko-MUN-ih-kab-bl</i>	Capable of passing from one person to another, such as an infectious disease
<b>endemic</b> <i>en-DEM-ik</i>	Occurring at a low level but continuously in a given region, such as the common cold (from en-, meaning “in” and Greek demos, meaning “people”)
<b>epidemic</b> <i>ep-ih-DEM-ik</i>	Affecting many people in a given region at the same time, a disease that breaks out in a large proportion of a population at a given time
<b>exacerbation</b> <i>eks-zas-er-BA-shun</i>	Worsening of disease, increase in severity of a disease or its symptoms
<b>iatrogenic</b> <i>i-at-ro-JEN-ik</i>	Caused by the effects of treatment (from Greek root iatro-, meaning “physician”)
<b>idiopathic</b> <i>id-e-o-PATH-ik</i>	Having no known cause (root idio means “self-originating”)
<b>in situ</b> <i>in SI-tu</i>	Localized, noninvasive (literally “in position”); said of tumors that do not spread, such as carcinoma in situ (CIS)
<b>normal flora</b> <i>FLO-rah</i>	The microorganisms that normally live on or in the body and are generally harmless and often beneficial but can cause disease under special circumstances, such as injury or failure of the immune system
<b>nosocomial</b> <i>nos-o-KO-me-al</i>	Describing an infection acquired in a hospital (root nos/o means “disease,” and comial refers to a hospital), which can be a serious problem, especially if it is resistant to antibiotics, such as strains of methicillin-resistant <i>Staphylococcus aureus</i> (MRSA) and vancomycin-resistant <i>S. aureus</i> (VRSA)
<b>opportunistic</b> <i>op-por-tu-NIS-tik</i>	Describing an infection that occurs because of a host’s poor or altered condition
<b>pandemic</b> <i>pan-DEM-ik</i>	Describing a disease that is prevalent throughout an entire region or the world; for example, AIDS is pandemic in certain regions of the world

(continued)

## Terminology

## Enrichment Terms (Continued)

<b>remission</b> <i>re-MISH-un</i>	A lessening of disease symptoms, the period during which such lessening occurs
<b>septicemia</b> <i>sep-tih-SE-me-ah</i>	Presence of pathogenic bacteria in the blood, blood poisoning
<b>systemic</b> <i>sis-TEM-ik</i>	Pertaining to the whole body
<b>Manifestations of Disease</b>	
<b>abscess</b> <i>AB-ses</i>	A localized collection of pus
<b>adhesion</b> <i>ad-HE-zhun</i>	A uniting of two surfaces or parts that may normally be separated
<b>anaplasia</b> <i>ah-nah-PLA-ze-ah</i>	Lack of normal differentiation, as shown by cancer cells
<b>ascites</b> <i>a-SI-teze</i>	Accumulation of fluid in the peritoneal cavity
<b>cellulitis</b> <i>sel-u-LI-tis</i>	A spreading inflammation of tissue
<b>effusion</b> <i>eh-FU-zhun</i>	Escape of fluid into a cavity or other body part
<b>exudate</b> <i>EKS-u-date</i>	Material that escapes from blood vessels as a result of tissue injury
<b>fissure</b> <i>FISH-ur</i>	A groove or split
<b>fistula</b> <i>FIS-tu-lah</i>	An abnormal passage between two organs or from an organ to the surface of the body
<b>gangrene</b> <i>GANG-grene</i>	Death of tissue, usually caused by lack of blood supply; may be associated with bacterial infection and decomposition
<b>hyperplasia</b> <i>hi-per-PLA-ze-ah</i>	Excessive growth of normal cells in normal arrangement
<b>hypertrophy</b> <i>hi-PER-tro-fe</i>	An increase in the size of an organ without increase in the number of cells; may result from an increase in activity, as in muscles
<b>induration</b> <i>in-du-RA-shun</i>	Hardening, an abnormally hard spot or place
<b>metaplasia</b> <i>met-ah-PLA-ze-ah</i>	Conversion of cells to a form that is not normal for that tissue (prefix meta- means “change”)
<b>polyp</b> <i>POL-ip</i>	A tumor attached by a thin stalk
<b>purulent</b> <i>PUR-u-lent</i>	Forming or containing pus
<b>suppuration</b> <i>sup-u-RA-shun</i>	Pus formation

## Terminology

## Abbreviations Pertaining to Disease

The abbreviations listed below are emphasized in this chapter. These are also found, collectively, with all chapter abbreviations in Appendix 2.

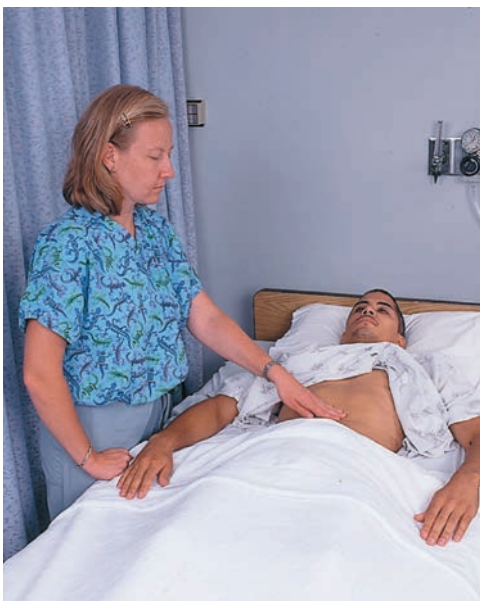<b>AF</b>	Acid fast	<b>MDR</b>	Multidrug resistant
<b>CA, Ca</b>	Cancer	<b>MRSA</b>	Methicillin-resistant <i>S. aureus</i>
<b>CIS</b>	Carcinoma in situ	<b>Staph</b>	<i>Staphylococcus</i>
<b>FUO</b>	Fever of unknown origin	<b>Strep</b>	<i>Streptococcus</i>
<b>Gm+</b>	Gram positive	<b>VRSA</b>	Vancomycin-resistant <i>S. aureus</i>
<b>Gm<sup>-</sup></b>	Gram negative		

## Diagnosis

Medical **diagnosis**, the determination of the nature and cause of an illness, begins with a patient history. This includes a history of the present illness with a description of **symptoms** (evidence of disease), a past medical history, and a family and a social history.

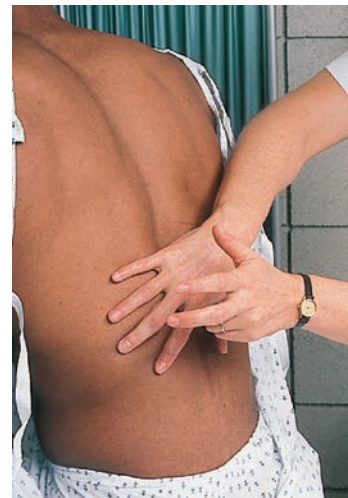A physical examination, which includes a review of all systems and observation of any **signs** of illness, follows the history taking. Practitioners use the following techniques in performing physicals:

- **Inspection:** visual examination
- **Palpation:** touching the surface of the body with the hands or fingers (**FIG. 3-6**)
- **Percussion:** tapping the body to evaluate tissue according to the sounds produced (**FIG. 3-7**)

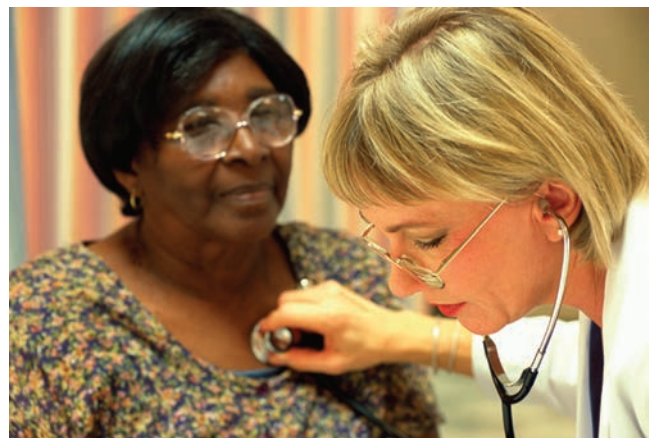

**FIGURE 3-6 Palpation.** The practitioner touches the body surface with the hands or fingers.

- **Auscultation:** listening to body sounds with a stethoscope (**FIG. 3-8**)



**FIGURE 3-7 Percussion.** The practitioner taps the body to evaluate tissues.



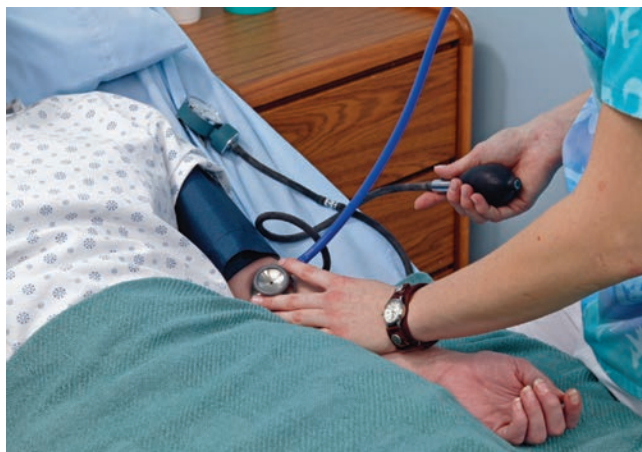**FIGURE 3-8 Auscultation.** The practitioner uses a stethoscope to listen to body sounds.




**FIGURE 3-9 Pulse rate.** The practitioner palpates an artery to measure pulse rate in beats per minute.

Vital signs (VS) are also recorded for comparison with normal ranges. VS are measurements that reflect basic functions necessary to maintain life and include:

- Temperature (T).
- Pulse rate, measured in beats per minute (bpm) (FIG. 3-9). Pulse rate normally corresponds to the heart rate (HR), the number of times the heart beats per minute.
- Respiration rate (R), measured in breaths per minute.
- Blood pressure (BP), measured in millimeters of mercury (mm Hg) and recorded when the heart is contracting (systolic pressure) and relaxing (diastolic pressure) (FIG. 3-10). An examiner typically uses a **stethoscope** and a blood pressure cuff, or **sphygmomanometer** (*sfig-mo-mah-NOM-eh-ter*), to measure blood pressure. Newer devices that read blood pressure directly and give digital readings are also in use. Chapter 10 has more information on blood pressure.



**FIGURE 3-10 Blood pressure.** The practitioner uses a blood pressure cuff (sphygmomanometer) and a stethoscope to measure systolic and diastolic pressures.



A



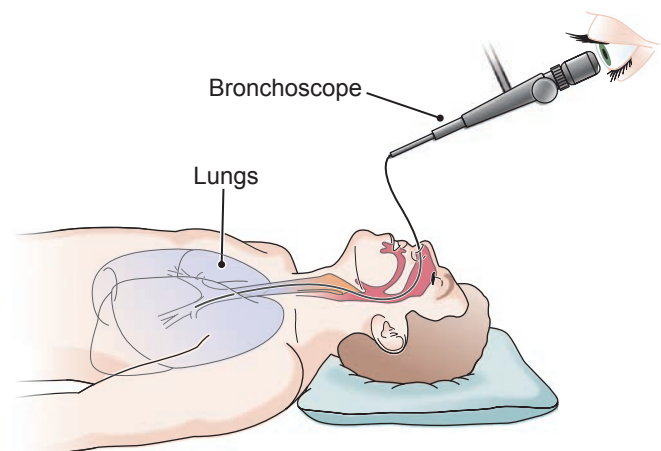
B

**FIGURE 3-11 Examination tools.** A. Ophthalmoscope for eye examination. B. Otoscope for ear examination.

Additional tools used in physical examinations include the **ophthalmoscope** (FIG. 3-11A), for examination of the eyes; the **otoscope** (FIG. 3-11B), for examination of the ears; and hammers for testing reflexes.

The skin, hair, and nails provide easily observable indications of a person's state of health. Skin features such as color, texture, thickness, and presence of lesions (local injuries) are noted throughout the course of the physical examination. Chapter 4 contains a discussion of the skin and skin diseases.

Diagnosis is further aided by laboratory test results. These may include tests on blood, urine, and other body fluids and the identification of infectious organisms. Additional tests may include study of the electrical activity of tissues such as the brain and heart, examination of body cavities by means of an **endoscope** (FIG. 3-12), and imaging



**FIGURE 3-12 Endoscope.** A bronchoscope is a type of endoscope used to examine the respiratory bronchi.

techniques. **Biopsy** is the removal of tissue for microscopic examination. Biopsy specimens can be obtained by:

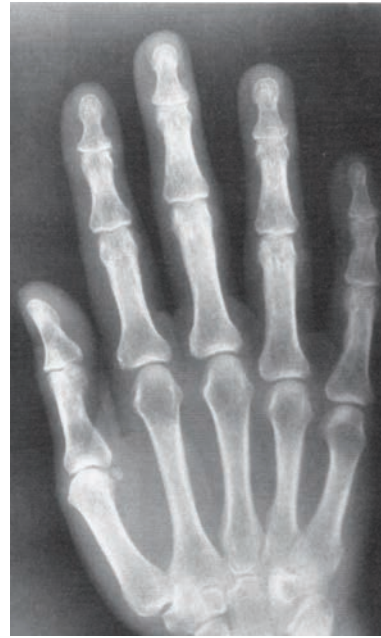- Needle withdrawal (aspiration) of fluid, as from the chest or from a cyst
- A small punch, as of the skin
- Endoscopy, as from the respiratory or digestive tract
- Surgical removal, as of a tumor or node

In some cases, cancer can be diagnosed and its treatment monitored by a *liquid biopsy*, which relies on analysis of cancerous cells or tumor DNA in circulating blood. These samples are easier to obtain, may give a more complete picture of tumor spread than isolated tissue biopsies, and may someday be used as screening tests for hard-to-diagnose types of cancer.

When new tests appear, as in all other areas of health sciences, new terminology is added to the medical vocabulary.

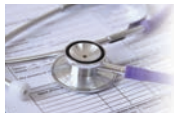## IMAGING TECHNIQUES

Imaging techniques employ various types of energy to produce visual images of the body. The most fundamental imaging method is **radiography** (FIG. 3-13), which uses x-rays to produce an image (radiograph) on film or to produce a digital image that can be viewed on a monitor. Radiography is the preferred method for imaging dense tissues, such as bone. Some soft-tissue structures can be demonstrated as well, but a contrast medium, such as a barium mixture, may be needed to enhance visualization. Other forms of energy



**FIGURE 3-13 Radiography.** The action of x-rays on sensitized film produced this image (radiograph) of a normal right hand.

used to produce diagnostic images include sound waves, radioactive isotopes, radio waves, and magnetic fields. See **BOX 3-4** for a description of the most commonly used imaging methods and **BOX 3-5** for a summary of these and other imaging techniques in use.



## CLINICAL PERSPECTIVES

### Medical Imaging

BOX 3-4

Three imaging techniques that have revolutionized medicine are radiography, computed tomography (CT), and magnetic resonance imaging (MRI). With them, physicians today can “see” inside the body without making a single cut.

The oldest technique is radiography (*ra-de-OG-rah-fe*), in which a machine beams x-rays (a form of radiation) through the body onto a piece of film. The resulting image is called a radiograph. Dark areas indicate where the beam passed through the body and exposed the film, whereas light areas show where the beam did not pass through. Dense tissues (bone, teeth) absorb most of the x-rays, preventing them from exposing the film. For this reason, radiography is commonly used to visualize bone fractures and tooth decay as well as abnormally dense tissues like tumors. Radiography does not provide clear images of soft tissues because most of the beam passes through and exposes the film, but contrast media can help make structures like blood vessels and hollow organs more visible. For example, barium sulfate (which absorbs x-rays) coats the digestive tract when ingested.

During a CT scan, a machine revolves around the patient, beaming x-rays through the body onto a detector. The detector takes numerous images of the beam and a computer assembles them into transverse sections, or “slices.” Unlike conventional radiography, CT produces clear images of soft structures such as the brain, liver, and lungs. It is commonly used to visualize brain injuries and tumors and even blood vessels when used with contrast media.

MRI uses a strong magnetic field and radio waves. The patient undergoing MRI lies inside a chamber within a very powerful magnet. The molecules in the patient’s soft tissues align with the magnetic field inside the chamber. When radio waves hit the soft tissue, the aligned molecules emit energy that the MRI machine detects, and a computer converts these signals into an image. MRI produces even clearer images of soft tissue than does CT and can create detailed views of blood vessels without contrast media. MRI can visualize brain injuries and tumors that might be missed using CT.

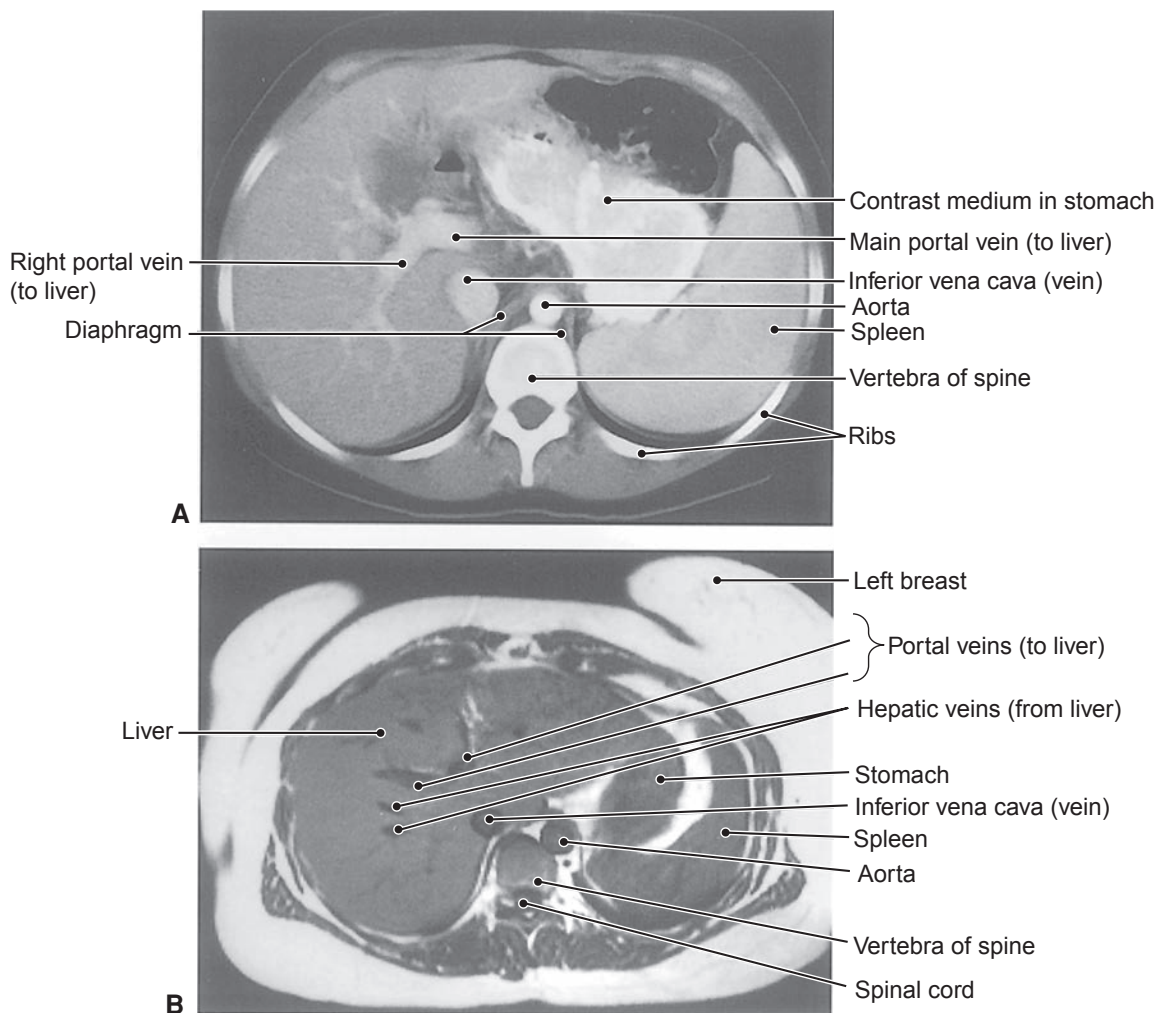


## FOR YOUR REFERENCE

### Imaging Techniques

BOX 3-5

Method	Description
<b>cineradiography</b> <i>sin-eh-ra-de-OG-rah-fe</i>	making of a motion picture of successive images appearing on a fluoroscopic screen
<b>computed tomography (CT, CT scan)</b> <i>to-MOG-rah-fe</i>	use of a computer to generate an image from a large number of x-rays passed at different angles through the body; a three-dimensional image of a cross-section of the body is obtained; reveals more about soft tissues than does simple radiography (FIG. 3-14A)
<b>fluoroscopy</b> <i>flor-OS-ko-pe</i>	use of x-rays to examine deep structures; the shadows cast by x-rays passed through the body are observed on a fluorescent screen; the device used is called a fluoroscope
<b>magnetic resonance imaging (MRI)</b>	production of images through the use of a magnetic field and radio waves; the characteristics of soft tissue are revealed by differences in molecular properties; eliminates the need for x-rays and contrast media (see FIG. 3-14B)



**FIGURE 3-14** Imaging techniques. Shown are cross-sections through the liver and spleen. **A.** Computed tomography (CT). **B.** Magnetic resonance imaging (MRI).



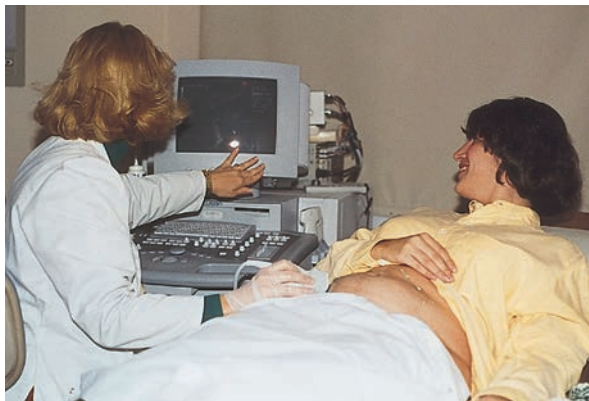
## FOR YOUR REFERENCE (Continued)

### Imaging Techniques

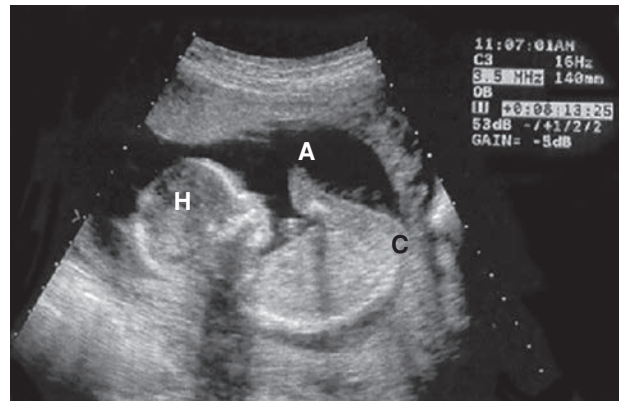
BOX 3-5

3

Method	Description
<b>positron emission tomography (PET)</b>	production of sectional body images by administration of a natural substance, such as glucose, labeled with a positron-emitting isotope; the rays subsequently emitted are interpreted by a computer to show the internal distribution of the substance administered; PET has been used to follow blood flow through an organ and to measure metabolic activity within an organ, such as the brain, under different conditions
<b>radiography</b> <i>ra-de-OG-rah-fe</i>	use of x-rays passed through the body to make a visual record (radiograph) of internal structures either on specially sensitized film or digitally; also called roentgenography ( <i>rent-geh-NOG-rah-fe</i> ) after the developer of the technique
<b>scintigraphy</b> <i>sin-TIG-rah-fe</i>	imaging the radioactivity distribution in tissues after internal administration of a radioactive substance (radionuclide); the images are obtained with a scintillation camera; the record produced is a scintiscan ( <i>SIN-tih-skan</i> ) and usually specifies the part examined or the isotope used for the test, as in bone scan, gallium scan
<b>single-photon emission computed tomography (SPECT)</b>	scintigraphic technique that permits visualization of a radioisotope's cross-sectional distribution
<b>ultrasonography</b> <i>ul-trah-son-OG-rah-fe</i>	generation of a visual image from the echoes of high-frequency sound waves traveling back from different tissues; also called sonography ( <i>so-NOG-rah-fe</i> ) and echography ( <i>ek-OG-rah-fe</i> ) (FIG. 3-15)



A



B

**FIGURE 3-15 Ultrasonography.** **A.** The practitioner is using ultrasound to monitor pregnancy. **B.** Sonogram of a pregnant uterus at 10 to 11 weeks showing the amniotic cavity (A) filled with amniotic fluid. The fetus is seen in longitudinal section showing the head (H) and coccyx (C).

## Treatment

If diagnosis so indicates, treatment, also termed **therapy**, is begun. This may consist of counseling, drugs, surgery, radiation, physical therapy, occupational therapy, psychiatric treatment, or some combination of these. Drugs and their actions are discussed in Appendix 10. **Palliative therapy** is treatment that provides relief but is not intended as a cure. Terminally ill patients, for example, may receive treatment that eases pain and provides comfort but is not expected to change the outcome of the disease. During diagnosis and throughout the course of treatment, a patient is evaluated to

establish a **prognosis**—that is, a prediction of the disease's outcome.

## SURGERY

Surgery is a method for treating disease or injury by manual operations. Surgery may be done through an existing body opening, but usually it involves cutting or puncturing tissue with a sharp instrument in the process of **incision**. **BOX 3-6** for descriptions of surgical instruments and **FIGURE 3-16** for pictures of surgical instruments. Surgery usually requires some form of **anesthesia** to dull or eliminate





## FOR YOUR REFERENCE

### Surgical Instruments

BOX 3-6

Instrument	Description
<b>bougie</b> <i>BOO-zhe</i>	slender, flexible instrument for exploring and dilating tubes
<b>cannula</b> <i>KAN-u-lah</i>	tube enclosing a trocar (see below) that allows escape of fluid or air after removal of the trocar
<b>clamp</b>	instrument used to compress tissue
<b>curet (curette)</b> <i>KU-ret</i>	spoon-shaped instrument for removing material from the wall of a cavity or other surface (see FIG. 3-16)
<b>elevator</b> <i>EL-eh-va-tor</i>	instrument for lifting tissue or bone
<b>forceps</b> <i>FOR-seps</i>	instrument for holding or extracting (see FIG. 3-16)
<b>Gigli saw</b> <i>JE-yile</i>	flexible wire saw
<b>hemostat</b> <i>HE-mo-stat</i>	small clamp for stopping blood flow from a vessel (see FIG. 3-16)
<b>rasp</b>	surgical file
<b>retractor</b> <i>re-TRAK-tor</i>	instrument used to maintain exposure by separating a wound and holding back organs or tissues (see FIG. 3-16)
<b>rongeur</b> <i>ron-ZHUR</i>	gouge forceps
<b>scalpel</b> <i>SKAL-pel</i>	surgical knife with a sharp blade (see FIG. 3-16)
<b>scissors</b> <i>SIZ-ors</i>	a cutting instrument with two opposing blades
<b>sound</b> <i>sownd</i>	instrument for exploring a cavity or canal (see FIG. 3-16)
<b>trocar</b> <i>TRO-kar</i>	sharp pointed instrument contained in a cannula used to puncture a cavity

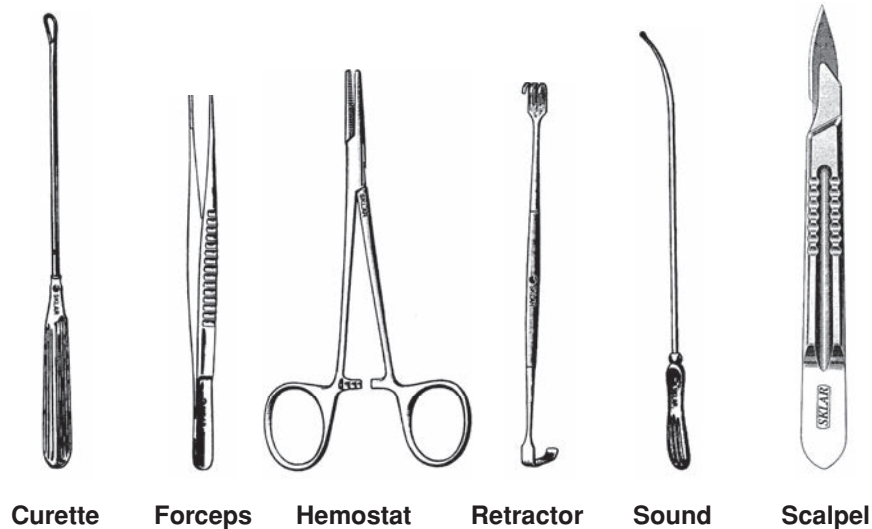
pain. After surgery, incisions must be closed for proper healing. Traditionally, surgeons have used stitches or **sutures** to close wounds, but today they also use adhesive strips, staples, and skin glue.

Many types of operations are now performed with a **laser**, an intense beam of light. Some procedures require destruction of tissue by a harmful agent, such as by heat or a chemical, in the process of **cautery** or cauterization. Surgeons are now increasingly using computer-assisted robotic surgery for certain procedures. In this type of operation, the surgeon uses robotic instruments manipulated remotely or by a computer. These operations can be less invasive than standard surgeries and result in less bleeding. The method

has been used mainly for urogenital procedures, some joint replacement, correction of certain heart abnormalities, and gallbladder removal.

Some of the purposes of surgery include:

- **Treatment:** For **excision** (cutting out) of diseased or abnormal tissue, such as a tumor or an inflamed appendix. Surgical methods are also used to repair wounds or injuries, as in skin grafting for burns or for realigning broken bones. Surgical methods are used to correct circulatory problems and to return structures to their normal positions, as in raising a prolapsed organ, such as the urinary bladder, in a surgical **fixation** procedure.



**FIGURE 3-16** Surgical instruments.

- **Diagnosis:** To remove tissue for laboratory study in a biopsy, as previously described. Exploratory surgery to investigate the cause of symptoms is performed less frequently now because of advances in noninvasive diagnostic and imaging techniques.
- **Restoration:** Surgery may compensate for lost function, as when a section of the intestine is redirected in a colostomy, a tube is inserted to allow breathing in a tracheostomy, a feeding tube is inserted, or an organ is transplanted. Surgeons may perform plastic or reconstructive surgery to accommodate a prosthesis (substitute part), to restore proper appearance, or for cosmetic reasons.
- **Relief:** Palliative surgery relieves pain or discomfort, as by cutting the nerve supply to an organ or reducing the size of a tumor to relieve pressure.

Surgery may be done in an emergency or urgent situation under conditions of acute danger, as in traumatic injury or severe blockage. Other procedures, such as cataract removal from the eye, may be planned when convenient. Elective or optional surgery would not cause serious consequences if delayed or not done.

Over time, surgery has extended beyond the classic operating room of a hospital to other hospital areas and to private surgical facilities where people can be treated within 1 day as outpatients. Preoperative care is given before surgery and includes examination, obtaining the patient's informed consent for the procedure, and preadmission testing. Postoperative care includes recovery from anesthesia, follow-up evaluations, and instructions for home care.

## Alternative and Complementary Medicine

During the past century, the leading causes of death in industrialized countries have gradually shifted from infectious diseases to chronic diseases of the cardiovascular and respiratory

systems and cancer. In addition to advancing age, life habits and the environment greatly influence these conditions. As a result, many people have begun to consider healing practices from other philosophies and cultures as alternatives and complements to conventional Western medicine. Some of these philosophies include **osteopathy**, **naturopathy**, **homeopathy**, and **chiropractic**. Techniques of **acupuncture**, **biofeedback**, **massage**, and **meditation** may also be used, as well as herbal remedies (see Chapter 8) and nutritional counseling on diet, vitamins, and minerals. Complementary and alternative therapies emphasize maintaining health rather than treating disease and allowing the body opportunity to heal itself. These ideas fit into the concept of **holistic health care**, which promotes treating an individual as a whole with emotional, social, and spiritual needs in addition to physical needs and encouraging people to be involved in their own health maintenance.

The U.S. government has established the National Center for Complementary and Alternative Medicine (NCCAM) within the National Institutes of Health (NIH) to study these therapies.

## Cancer

Methods used in the diagnosis of cancer include physical examination, biopsy, imaging techniques, and laboratory tests for abnormalities, or “markers,” associated with specific types of malignancies. Some cancer markers are byproducts, such as enzymes, hormones, and cellular proteins that are abnormal or are produced in abnormal amounts. Researchers have also linked specific genetic mutations to certain forms of cancer.

Oncologists (cancer specialists) use two methods, **grading** and **staging**, to classify cancers, select and evaluate therapy, and estimate disease outcome. Grading is based on histologic (tissue) changes observed in tumor cells when they are examined microscopically. Grades increase from I to IV with increasing cellular abnormality.

Staging is a procedure for establishing the clinical extent of tumor spread, both at the original site and in

other parts of the body (metastases). The TNM system is commonly used. These letters stand for primary tumor (T), regional lymph nodes (N), and distant metastases (M). Evaluation in these categories varies for each type of tumor. Based on TNM results, a stage ranging in severity from I to IV is assigned. Cancers of the blood, lymphatic system, and nervous system are evaluated by different standards.

The most widely used methods for treatment of cancer are surgery, radiation therapy, and **chemotherapy** (treatment with chemicals). Newer methods of **immunotherapy** use substances that stimulate the immune system as a whole or vaccines prepared specifically against a tumor. Hormone therapy may also be effective against certain types of tumors. When no active signs of the disease remain, the cancer is said to be in **remission**.

## Terminology

## Key Terms

The terms listed below are emphasized in this chapter. Knowing them will help you organize and prioritize your learning. These boldface terms are also found, collectively, with all chapter key terms in the Glossary.

### Diagnosis and Treatment

<b>anesthesia</b> <i>an-es-THE-ze-ab</i>	Loss of the ability to feel pain, as by administration of a drug
<b>auscultation</b> <i>aws-kul-TA-shun</i>	Listening for sounds within the body, usually within the chest or abdomen (see <b>FIG. 3-8</b> )
<b>biopsy</b> <i>BI-op-se</i>	Removal of a small amount of tissue for microscopic examination
<b>cautery</b> <i>KAW-ter-e</i>	Destruction of tissue by a damaging agent, such as a harmful chemical, heat, or electric current (electrocautery); cauterization
<b>chemotherapy</b> <i>ke-mo-THER-ab-pe</i>	Use of chemicals to treat disease; the term is often applied specifically to the treatment of cancer with chemicals
<b>diagnosis</b> <i>di-ag-NO-sis</i>	The process of determining the cause and nature of an illness
<b>endoscope</b> <i>EN-do-skope</i>	An instrument for examining the inside of an organ or cavity through a body opening or small incision; most endoscopes use fiber optics for viewing (see <b>FIG. 3-12</b> )
<b>excision</b> <i>ek-SIZH-un</i>	Removal by cutting (suffix: -ectomy)
<b>fixation</b> <i>fik-SA-shun</i>	Holding or fastening a structure in a firm position (suffix: -pexy)
<b>grading</b> <i>GRA-ding</i>	A method for evaluating a tumor based on microscopic examination of the cells
<b>immunotherapy</b> <i>im-u-no-THER-ab-pe</i>	Treatment that involves stimulation or suppression of the immune system, either specifically or nonspecifically
<b>incision</b> <i>in-SIZH-un</i>	A cut, as for surgery; also the act of cutting (suffix: -tomy)
<b>inspection</b> <i>in-SPEK-shun</i>	Visual examination of the body
<b>laser</b> <i>LA-zer</i>	A device that transforms light into a beam of intense heat and power; used for surgery and diagnosis
<b>ophthalmoscope</b> <i>of-THAL-mo-skope</i>	An instrument for examining the interior of the eye (see <b>FIG. 3-11A</b> )
<b>otoscope</b> <i>O-to-skope</i>	Instrument used to examine the ears (see <b>FIG. 3-11B</b> )
<b>palliative therapy</b> <i>PAL-e-ab-tiv</i>	Providing relief but not cure; a treatment that provides such relief

## Terminology

## Key Terms (Continued)

<b>palpation</b> <i>pal-PA-shun</i>	Examining by placing the hands or fingers on the surface of the body to determine characteristics such as texture, temperature, movement, and consistency (see FIG. 3-6)
<b>percussion</b> <i>per-KUSH-un</i>	Tapping the body lightly but sharply to assess the condition of the underlying tissue by the sounds obtained (see FIG. 3-7)
<b>prognosis</b> <i>prog-NO-sis</i>	Prediction of a disease's course and outcome
<b>radiography</b> <i>ra-de-OG-rab-fe</i>	Use of x-rays passed through the body to make a visual record (radiograph) of internal structures either on specially sensitized film or digitally; roentgenography ( <i>rent-geh-NOG-rab-fe</i> )
<b>remission</b> <i>re-MISH-un</i>	Lessening of disease symptoms; the period during which this decrease occurs or the period when no sign of a disease exists
<b>sign</b> <i>sine</i>	Objective evidence of disease that can be observed or tested; examples are fever, rash, high blood pressure, and blood or urine abnormalities; an objective symptom
<b>sphygmomanometer</b> <i>sfig-mo-mah-NOM-eh-ter</i>	Blood pressure apparatus or blood pressure cuff; pressure is read in millimeters of mercury (mm Hg) when the heart is contracting (systolic pressure) and when the heart is relaxing (diastolic pressure) and is reported as systolic/diastolic (see FIG. 3-10)
<b>staging</b> <i>STA-jing</i>	The process of classifying malignant tumors for diagnosis, treatment, and prognosis
<b>stethoscope</b> <i>STETH-o-skope</i>	An instrument used for listening to sounds produced within the body (from the Greek root <i>steth/o</i> , meaning “chest”) (see FIG. 3-8)
<b>surgery</b> <i>SUR-jer-e</i>	A method for treating disease or injury by manual operations
<b>suture</b> <i>SU-chur</i>	To unite parts by stitching them together; also the thread or other material used in that process or the seam formed by surgical stitching (suffix: -rhaphy)
<b>symptom</b> <i>SIMP-tum</i>	Any evidence of disease; sometimes limited to subjective evidence of disease as experienced by the individual, such as pain, dizziness, and weakness
<b>therapy</b> <i>THER-ab-pe</i>	Treatment, intervention
<b>vital signs</b> <i>VI-tal</i>	Measurements that reflect basic functions necessary to maintain life
<b>Alternative and Complementary Medicine</b>	
<b>acupuncture</b> <i>AK-u-punk-chur</i>	An ancient Chinese method of inserting thin needles into the body at specific points to relieve pain, induce anesthesia, or promote healing; similar effects can be obtained by using firm finger pressure at the surface of the body in the technique of <i>acupressure</i>
<b>biofeedback</b> <i>bi-o-FEDE-bak</i>	A method for learning control of involuntary physiologic responses by using electronic devices to monitor bodily changes and feeding this information back to a person
<b>chiropractic</b> <i>ki-ro-PRAK-tik</i>	A science that stresses the condition of the nervous system in diagnosis and treatment of disease; often, the spine is manipulated to correct misalignment; most patients consult for musculoskeletal pain and headaches (from Greek <i>cheir</i> , meaning “hand”)
<b>holistic health care</b> <i>ho-LIS-tik</i>	Practice of treating a person as a whole entity with physical, emotional, social, and spiritual needs; it stresses comprehensive care, involvement in one's own care, and the maintenance of good health rather than the treatment of disease
<b>homeopathy</b> <i>ho-me-OP-ab-the</i>	A philosophy of treating disease by administering drugs in highly diluted form along with promoting healthy life habits and a healthy environment (from <i>home/o</i> , meaning “same,” and <i>path/o</i> , meaning “disease”)

(continued)

## Terminology

## Key Terms (Continued)

<b>massage</b> <i>ma-SAHJ</i>	Manipulation of the body or portion of the body to calm, relieve tension, increase circulation, and stimulate muscles
<b>meditation</b> <i>med-ih-TA-shun</i>	Process of clearing the mind by concentrating on the inner self while controlling breathing and perhaps repeating a word or phrase (mantra)
<b>naturopathy</b> <i>na-chur-OP-ab-the</i>	A therapeutic philosophy of helping people heal themselves by developing healthy lifestyles; naturopaths may use some of the methods of conventional medicine (from <i>nature</i> and <i>path/o</i> , meaning “disease”)
<b>osteopathy</b> <i>os-te-OP-ab-the</i>	A system of therapy based on the theory that the body can overcome disease when it has normal structure, a favorable environment, and proper nutrition; osteopaths use standard medical practices for diagnosis and treatment but stress the identification and correction of faulty body structure (from <i>oste/o</i> , meaning “bone,” and <i>path/o</i> , meaning “disease”)

## Word Parts Pertaining to Diagnosis and Treatment

See TABLES 3-6 to 3-8.

Table 3-6

## Roots for Physical Forces

Root	Meaning	Example	Definition of Example
aer/o	air, gas	aerobic <i>air-O-bik</i>	pertaining to or requiring air (oxygen)
bar/o	pressure	barometer <i>bah-ROM-eh-ter</i>	instrument used to measure pressure
chrom/o, chromat/o	color, stain	chromatic <i>kro-MAT-ik</i>	having color
chron/o	time	chronologic <i>kron-o-LOJ-ik</i>	arranged according to the time of occurrence
cry/o	cold	cryoprobe <i>KRI-o-probe</i>	instrument used to apply extreme cold
electr/o	electricity	electrolysis <i>e-lek-TROL-ih-sis</i>	decomposition of a substance by means of electric current
erg/o	work	synergistic <i>sin-er-JIS-tik</i>	working together with increased effect, such as certain drugs in combination
phon/o	sound, voice	phonograph <i>FO-no-graf</i>	instrument used to reproduce sound
phot/o	light	photoreaction <i>fo-to-re-AK-shun</i>	response to light
radi/o	radiation, x-ray	radiology <i>ra-de-OL-o-je</i>	study and use of radiation
son/o	sound	sonogram <i>SON-o-gram</i>	record obtained by use of ultrasound
therm/o	heat, temperature	hypothermia <i>hi-po-THER-me-ab</i>	abnormally low body temperature

## Exercise 3-6

Complete the exercise. To check your answers go to Appendix 11.

Match the following terms, and write the appropriate letter to the left of each number.

- |  |                                     |
|--|-------------------------------------|
| ___ 1. hyperthermia ( <i>hi-per-THER-me-ah</i> ) | a. abnormally high body temperature |
| ___ 2. hyperbaric ( <i>hi-per-BAR-ik</i> )       | b. any pigmented cell               |
| ___ 3. synchrony ( <i>SIN-kro-ne</i> )           | c. pertaining to increased pressure |
| ___ 4. radioactive ( <i>ra-de-o-AK-tiv</i> )     | d. occurrence at the same time      |
| ___ 5. chromocyte ( <i>kro-mo-site</i> )         | e. giving off radiation             |

Identify and define the root in each of the following words.

	Root	Meaning of Root
6. sonographer ( <i>so-NOG-rah-fer</i> )	_____	_____
7. chronic ( <i>KRON-ik</i> )	_____	_____
8. homeothermic ( <i>ho-me-o-THER-mik</i> )	_____	_____
9. exergonic ( <i>eks-er-GON-ik</i> )	_____	_____
10. anaerobic ( <i>an-er-O-bik</i> )	_____	_____
11. achromatic ( <i>ak-ro-MAT-ik</i> )	_____	_____

Fill in the blanks

12. The term electroconvulsive (*e-lek-tro-con-VUL-siv*) means causing convulsions by means of \_\_\_\_\_.
13. A photograph (*FO-to-graf*) is an image produced by means of \_\_\_\_\_.
14. Cryotherapy (*kri-o-THER-ab-pe*) is treatment using \_\_\_\_\_.
15. Barotrauma (*bah-ro-TRAW-mah*) is injury caused by \_\_\_\_\_.
16. Phonetics (*fo-NET-iks*) is the study of \_\_\_\_\_.

Table 3-7

### Suffixes for Diagnosis

Suffix	Meaning	Example	Definition of Example
-graph	instrument for recording data	<b>polygraph</b> <i>POL-e-graf</i>	instrument used to record many physiologic responses simultaneously; lie detector
-graphy	act of recording data <sup>a</sup>	<b>echography</b> <i>ek-OG-rah-fe</i>	recording data obtained by ultrasound
-gram <sup>b</sup>	a record of data	<b>electrocardiogram</b> <i>eh-lek-tro-KAR-de-o-gram</i>	record of the heart's electrical activity
-meter	instrument for measuring	<b>calorimeter</b> <i>kal-o-RIM-eh-ter</i>	instrument for measuring the caloric energy of food
-metry	measurement of	<b>audiometry</b> <i>au-de-OM-eh-tre</i>	measurement of hearing ( <i>audi/o</i> ); root <i>metr/o</i> means "measure"
-scope	instrument for viewing or examining	<b>bronchoscope</b> <i>BRONG-ko-skope</i>	instrument for examining the bronchi (breathing passages) (see <b>FIG. 3-12</b> )
-scopy	examination of	<b>celioscopy</b> <i>se-le-OS-ko-pe</i>	examination of the abdominal cavity ( <i>celi/o</i> )

<sup>a</sup>This ending is often used to mean not only the recording of data but also the evaluation and interpretation of the data.

<sup>b</sup>An image prepared simply using x-rays is called a radiograph. When special techniques are used to image an organ or region with x-rays, the ending *-gram* is used with the root for that area, as in urogram (urinary tract), angiogram (blood vessels), and mammogram (breast).

## Exercise 3-7

Complete the exercise. To check your answers go to Appendix 11.

Match the following terms, and write the appropriate letter to the left of each number.

- |   |  |
|---|--|
| ___ 1. microscope ( <i>MI-kro-skope</i> )                           | a. examination of the abdomen                                |
| ___ 2. ergometry ( <i>er-GOM-eh-tre</i> )                           | b. a record of sound   |
| ___ 3. thermometer ( <i>ther-MOM-eh-ter</i> )                       | c. measurement of work done                                  |
| ___ 4. laparoscopy ( <i>lap-ab-ROS-ko-pe</i> )                      | d. instrument for measuring temperature                      |
| ___ 5. sonogram ( <i>SON-o-gram</i> )                               | e. instrument for examining very small objects               |
| ___ 6. endoscope ( <i>EN-do-skope</i> )                             | a. a record of sound   |
| ___ 7. electroencephalograph ( <i>e-lek-tro-en-SEF-ab-lo-graf</i> ) | b. instrument for measuring time                             |
| ___ 8. audiometer ( <i>aw-de-OM-eh-ter</i> )                        | c. instrument for viewing the inside of a cavity or organ    |
| ___ 9. phonogram ( <i>FO-no-gram</i> )                              | d. instrument used to measure hearing                        |
| ___ 10. chronometer ( <i>kron-OM-eh-ter</i> )                       | e. instrument used to record the brain's electrical activity |

Table 3-8

Suffixes for Surgery

Suffix	Meaning	Example	Definition of Example
-centesis	puncture, tap	thoracentesis <i>thor-ab-sen-TE-sis</i>	puncture of the chest (thorac/o)
-desis	binding, fusion	pleurodesis <i>plu-ROD-eh-sis</i>	binding of the pleura (membranes around the lungs)
-ectomy	excision, surgical removal	hepatectomy <i>hep-ab-TEK-to-me</i>	excision of liver tissue (hepat/o)
-pexy	surgical fixation	hysteropexy <i>HIS-ter-o-pek-se</i>	surgical fixation of the uterus (hyster/o)
-plasty	plastic repair, plastic surgery, reconstruction	rhinoplasty <i>RI-no-plas-te</i>	plastic surgery of the nose (rhin/o)
-rhaphy	surgical repair, suture	herniorrhaphy <i>her-ne-OR-ab-fe</i>	surgical repair of a hernia (herni/o)
-stomy	surgical creation of an opening	tracheostomy <i>tra-ke-OS-to-me</i>	creation of an opening into the trachea (trache/o)
-tome	instrument for incising (cutting)	microtome <i>MI-kro-tome</i>	instrument for cutting thin sections of tissue for microscopic study
-tomy	incision, cutting	laparotomy <i>lap-ab-ROT-o-me</i>	surgical incision of the abdomen (lapar/o)
-tripsy	crushing	neurotripsy <i>nu-ro-TRIP-se</i>	crushing of a nerve (neur/o)

## Exercise 3-8

Complete the exercise. To check your answers go to Appendix 11.

Match the following terms, and write the appropriate letter to the left of each number.

- |  |                                    |
|--|------------------------------------|
| ___ 1. nephropexy ( <i>nef-ro-PEK-se</i> )         | a. crushing of a stone             |
| ___ 2. rhinoplasty ( <i>RI-no-plas-te</i> )        | b. surgical fixation of the kidney |
| ___ 3. lithotripsy ( <i>LITH-o-trip-se</i> )       | c. puncture of the abdomen         |
| ___ 4. adenectomy ( <i>ad-eh-NEK-to-me</i> )       | d. excision of a gland             |
| ___ 5. celiocentesis ( <i>se-le-o-sen-TE-sis</i> ) | e. plastic surgery of the nose     |

The root *cyst/o* means “urinary bladder.” Use this root to write a word that means each of the following.

6. Incision into the bladder \_\_\_\_\_
7. Surgical fixation of the bladder \_\_\_\_\_
8. Plastic repair of the bladder \_\_\_\_\_
9. Surgical repair of the bladder \_\_\_\_\_
10. Creation of an opening into the bladder \_\_\_\_\_

The root *arthr/o* means “joint.” Use this root to write a word that means each of the following.

11. Plastic repair of a joint \_\_\_\_\_
12. Instrument for incising a joint \_\_\_\_\_
13. Incision of a joint \_\_\_\_\_
14. Puncture of a joint \_\_\_\_\_
15. Fusion of a joint \_\_\_\_\_

Write a word for each of the following definitions using the roots given.

16. Incision into the trachea (*trache/o*) \_\_\_\_\_
17. Surgical repair of the stomach (*gastr/o*) \_\_\_\_\_
18. Creation of an opening into the colon (*col/o*) \_\_\_\_\_

## Terminology Enrichment Terms

The terms listed below expand on the key terms to increase your knowledge of this chapter topic.

### Diagnosis and Treatment

#### Symptoms

<b>clubbing</b> <i>KLUB-ing</i>	Enlargement of the ends of the fingers and toes because of soft-tissue growth of the nails; seen in a variety of diseases, especially lung and heart diseases ( <b>FIG. 3-17</b> )
<b>colic</b> <i>KOL-ik</i>	Acute abdominal pain associated with smooth muscle spasms
<b>cyanosis</b> <i>si-ah-NO-sis</i>	Bluish discoloration of the skin due to lack of oxygen
<b>diaphoresis</b> <i>di-ah-fo-RE-sis</i>	Profuse sweating

(continued)



## Terminology

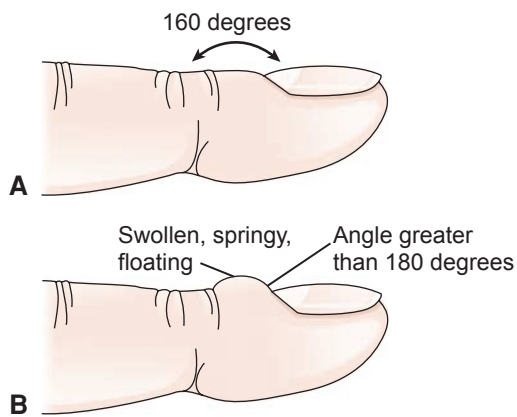
## Enrichment Terms (Continued)

<b>malaise</b> <i>mah-LAZE</i>	A feeling of discomfort or uneasiness, often indicative of infection or other disease (from French, meaning “discomfort,” using the prefix mal-, meaning “bad”)
<b>nocturnal</b> <i>nok-TUR-nal</i>	Pertaining to or occurring at night (roots noct/i and nyct/o mean “night”)
<b>pallor</b> <i>PAL-or</i>	Paleness, lack of color
<b>prodrome</b> <i>PRO-drome</i>	A symptom indicating an approaching disease
<b>sequela</b> <i>seh-KWEL-ab</i>	A lasting effect of a disease (plural: sequelae)
<b>syncope</b> <i>SIN-ko-pe</i>	A temporary loss of consciousness because of inadequate blood flow to the brain, fainting
<b>Diagnosis</b>	
<b>alpha-fetoprotein (AFP)</b> <i>AL-fah-fe-to-PRO-tene</i>	A fetal protein that appears in the blood of adults with certain types of cancer
<b>bruit</b> <i>brwe</i>	A sound, usually abnormal, heard in auscultation
<b>facies</b> <i>FA-she-eze</i>	The expression or appearance of the face
<b>febrile</b> <i>FEB-riI</i>	Pertaining to fever
<b>nuclear medicine</b>	The branch of medicine concerned with the use of radioactive substances (radionuclides) for diagnosis, therapy, and research
<b>radiology</b> <i>ra-de-OL-o-je</i>	The branch of medicine that uses radiation, such as x-rays, in the diagnosis and treatment of disease; a specialist in this field is a radiologist
<b>radionuclide</b> <i>ra-de-o-NU-klide</i>	A substance that gives off radiation; used for diagnosis and treatment; also called radioisotope or radiopharmaceutical
<b>speculum</b> <i>SPEK-u-lum</i>	An instrument for examining a canal ( <b>FIG. 3-18</b> )
<b>syndrome</b> <i>SIN-drome</i>	A group of signs and symptoms that together characterize a disease condition
<b>Treatment</b>	
<b>catheter</b> <i>KATH-eh-ter</i>	A thin tube that can be passed into the body; used to remove fluids from or introduce fluids into a body cavity ( <b>FIG. 3-19</b> )
<b>clysis</b> <i>KLI-sis</i>	The introduction of fluid into the body, other than orally, as into the rectum or abdominal cavity; also refers to the solution thus used
<b>irrigation</b> <i>ir-ib-GA-shun</i>	Flushing of a tube, cavity, or area with a fluid (see <b>FIG. 3-19</b> )
<b>lavage</b> <i>lah-VAJ</i>	The washing out of a cavity, irrigation
<b>normal saline (NS)</b> <i>SA-lene</i>	A salt (NaCl) solution compatible with living cells, also called physiologic saline solution (PSS)
<b>paracentesis</b> <i>par-ab-sen-TE-sis</i>	Puncture of a cavity for removal of fluid

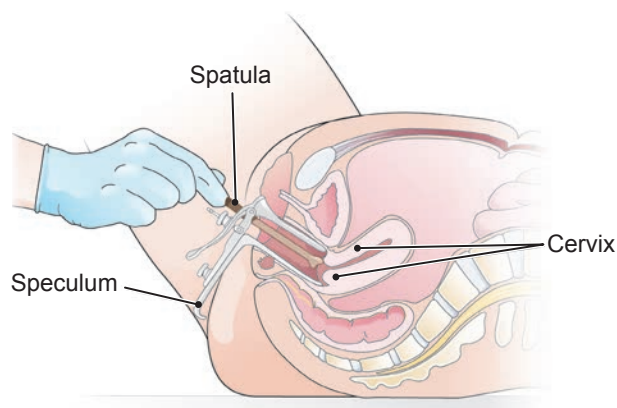
## Terminology

## Enrichment Terms (Continued)

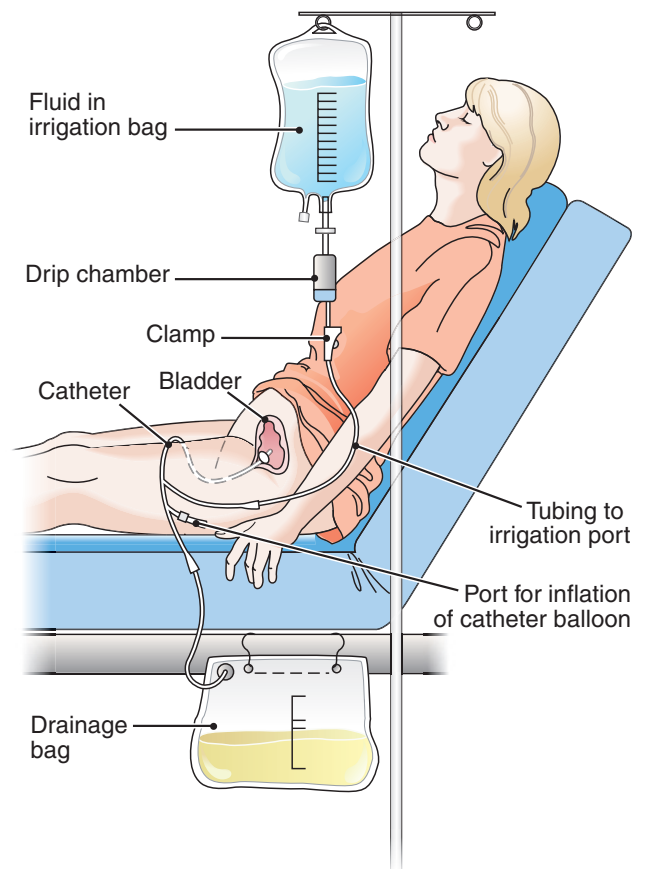
<b>prophylaxis</b> <i>pro-fib-LAK-sis</i>	Prevention of disease
<b>Surgery</b>	
<b>drain</b>	Device for allowing matter to escape from a wound or cavity; common types include Penrose (cigarette), T-tube, Jackson–Pratt (J-P), and Hemovac
<b>ligature</b> <i>LIG-ab-chur</i>	A tie or bandage, the process of binding or tying (also called ligation)
<b>resection</b> <i>re-SEK-shun</i>	Partial excision of a structure
<b>stapling</b> <i>STA-pling</i>	In surgery, the joining of tissue by using wire staples that are pushed through the tissue and then bent
<b>surgeon</b> <i>SUR-jun</i>	A physician who specializes in surgery



**FIGURE 3-17 Clubbing.** A. Normal. B. Clubbing; the end of the finger is enlarged because of soft-tissue growth around the nail.



**FIGURE 3-18 A vaginal speculum.** This instrument is used to examine the vagina and cervix and to obtain a cervical sample for testing.



**FIGURE 3-19 Continuous bladder irrigation using a catheter.**

Terminology		Symbols	
1°	primary	°	degree
2°	secondary (to)	^	above
Δ	change	∨	below
Ⓛ	left	=	equal to
Ⓡ	right	≠	not equal to
↑	increase(d)	±	doubtful, slight
↓	decrease(d)	~	approximately
♂	male	×	times
♀	female	#	number, pound

## Terminology *Abbreviations*

The abbreviations listed below are emphasized in this chapter. These are also found, collectively, with all chapter abbreviations in Appendix 2.

### History and Physical Examination

<b>ADL</b>	Activities of daily living	<b>IVDA</b>	Intravenous drug abuse
<b>BP</b>	Blood pressure	<b>NAD</b>	No apparent distress
<b>bpm</b>	Beats per minute	<b>NKDA</b>	No known drug allergies
<b>C</b>	Celsius (centigrade)	<b>P</b>	Pulse
<b>CC</b>	Chief complaint	<b>PE</b>	Physical examination
<b>c/o, co</b>	Complains (complaining) of	<b>PE(R)RLA</b>	Pupils equal (regular) react to light and accommodation
<b>EOMI</b>	Extraocular muscles intact	<b>PMH</b>	Past medical history
<b>ETOH</b>	Alcohol (ethyl alcohol)	<b>pt</b>	Patient
<b>F</b>	Fahrenheit	<b>R</b>	Respiration
<b>HEENT</b>	Head, eyes, ears, nose, and throat	<b>R/O</b>	Rule out
<b>HIPAA</b>	Health Insurance Portability and Accountability Act	<b>ROS</b>	Review of systems
<b>h/o</b>	History of	<b>T</b>	Temperature
<b>H&amp;P</b>	History and physical	<b>TPR</b>	Temperature, pulse, respiration
<b>HPI</b>	History of present illness	<b>VS</b>	Vital signs
<b>HR</b>	Heart rate	<b>WD</b>	Well developed
<b>Hx</b>	History	<b>WNL</b>	Within normal limits
<b>I&amp;O</b>	Intake and output	<b>w/o</b>	Without
<b>IPPA</b>	Inspection, palpation, percussion, auscultation	<b>y/o, YO</b>	Years old, year-old

## Terminology

## Abbreviations (Continued)

## Diagnosis and Treatment

<b>ABC</b>	Aspiration biopsy cytology
<b>AFP</b>	Alpha-fetoprotein
<b>BS</b>	Bowel sounds, breath sounds
<b>bx</b>	Biopsy
<b>CAM</b>	Complementary and alternative medicine
<b>Ci</b>	Curie (unit of radioactivity)
<b>C&amp;S</b>	Culture and (drug) sensitivity (of bacteria)
<b>CT</b>	Computed tomography
<b>D/C, dc</b>	Discontinue
<b>Dx</b>	Diagnosis
<b>EBL</b>	Estimated blood loss
<b>ED</b>	Emergency department
<b>ICU</b>	Intensive care unit
<b>I&amp;D</b>	Incision and drainage
<b>MET</b>	Metastasis
<b>MRI</b>	Magnetic resonance imaging
<b>NCCAM</b>	National Center for Complementary and Alternative Medicine
<b>NS, N/S</b>	Normal saline
<b>OR</b>	Operating room
<b>PACU</b>	Postanesthesia care unit
<b>PCA</b>	Patient-controlled analgesia
<b>PET</b>	Positron emission tomography
<b>PICC</b>	Peripherally inserted central catheter
<b>postop</b>	Postoperative
<b>preop</b>	Preoperative

<b>PSS</b>	Physiologic saline solution
<b>RATx</b>	Radiation therapy
<b>Rx</b>	Drug, prescription, therapy
<b>SPECT</b>	Single-photon emission computed tomography
<b>TNM</b>	(Primary) tumor, (regional lymph) nodes, (distant) metastases

## UV

Ultraviolet

## Views for Radiography

<b>AP</b>	Anteroposterior
<b>LL</b>	Left lateral
<b>PA</b>	Posteroanterior
<b>RL</b>	Right lateral

## Orders

<b>AMA</b>	Against medical advice
<b>AMB</b>	Ambulatory
<b>BRP</b>	Bathroom privileges
<b>CBR</b>	Complete bed rest
<b>DNR</b>	Do not resuscitate
<b>KVO</b>	Keep vein open
<b>NPO</b>	Nothing by mouth (Latin, <i>non per os</i> )
<b>OOB</b>	Out of bed
<b>QNS</b>	Quantity not sufficient
<b>QS</b>	Quantity sufficient
<b>STAT</b>	Immediately
<b>TKO</b>	To keep open

## Drugs

A **drug** is a substance that alters body function. Traditionally, drugs have been derived from natural plant, animal, and mineral sources. Today, most are manufactured synthetically by pharmaceutical companies. A few, such as certain hormones and enzymes, have been produced by genetic engineering.

Many drugs, described as over-the-counter (OTC) drugs, are available without a signed order, or **prescription (Rx)**. Others require a healthcare provider's prescription for use.

Responsibility for the safety and **efficacy** (effectiveness) of all drugs sold in the United States lies with the Federal Food and Drug Administration (FDA), which must approve all drugs before they are sold.

### ADVERSE DRUG EFFECTS

An unintended or off-target effect of a drug or any other form of treatment is a **side effect**. Most drugs have potential adverse side effects that must be evaluated before they are prescribed. In addition, there may be **contraindications**, or reasons not to use a particular drug for a specific individual based on the person's medical conditions, current medications, sensitivity, or family history. While a patient is under treatment, it is important to be alert for signs of adverse effects such as digestive upset, changes in the blood, or signs of allergy, such as hives or skin rashes. **Anaphylaxis** is an immediate and severe allergic reaction that may be caused by a drug. It can lead to life-threatening respiratory distress and circulatory collapse.

Because drugs given in combination may interact, the prescriber must know of any drugs the patient is taking before prescribing another. In some cases, a combination may result in **synergy** or **potentiation**, meaning that the drugs together have a greater effect than either of the drugs acting alone. In other cases, one drug may act as an **antagonist** of another, interfering with its action. Drugs may also react adversely with certain foods or substances used socially, such as alcohol and tobacco.

Drugs that act on the central nervous system may lead to psychological or physical **substance dependence**, in which a person has a chronic or compulsive need for a drug regardless of its bad effects. With repeated use, a drug **tolerance** may develop, whereby a constant dose has less effect, and the dose must be increased to produce the original response. Cessation of the drug then leads to symptoms of substance **withdrawal**, a state that results from a drug's removal or dose reduction. Certain symptoms are associated with withdrawal from specific drugs.

### DRUG NAMES

Drugs may be cited by either their generic or **brand names**. The **generic name** is usually a simple version of the chemical name for the drug and is not capitalized. The brand name

(trade name, proprietary name) is a registered trademark of the manufacturer and is written with an initial capital letter. For example, Tylenol is the brand name for the analgesic compound acetaminophen; the antidepressant Prozac is fluoxetine. A brand name is protected by a patent; only the company that holds the patent can produce and sell that drug under its brand name until the patent expires. Appendix 10 has many more examples of generic and brand names. Note that the same drug may be marketed by different companies under different brand names. Both Motrin and Advil, for example, are the generic anti-inflammatory agent ibuprofen.

### DRUG INFORMATION

In the United States, the standard for drug information is the *United States Pharmacopeia* (USP). This reference is published by a national committee of pharmacologists and other scientists. It contains formulas for drugs sold in the United States; standards for testing the strength, quality, and purity of drugs; and standards for the preparation and dispensing of drugs. The American Society of Health System Pharmacists (ASHP) publishes extensive drug information, and the *Physicians' Desk Reference* (PDR), published yearly by Thomson Healthcare, contains information supplied by drug manufacturers. An enormous amount of drug information is available online through the websites for these publications and others. Another excellent source of up-to-date information on drugs is a community or hospital pharmacist.

## Herbal Medicines

For hundreds of years, people have used plants to treat diseases, a practice described as herbal medicine or **phyto-medicine**. Many people in industrialized countries are now turning to herbal products as alternatives or complements to conventional medicines. Although plants are the source of many conventional drugs, pharmaceutical companies usually purify, measure, and often modify or synthesize the active ingredients in these plants rather than presenting them in their natural states.

Some issues have arisen with the increased use of herbal medicines and nutritional supplements, including questions about their purity, safety, concentration, and efficacy. Another issue is drug interactions. Healthcare providers should ask about the use of herbal remedies when taking a patient's drug history, and patients should report any herbal medicines they take when under treatment. The FDA does not test or verify herbal medicines, and there are no requirements to report adverse effects. There are, however, restrictions on the health claims that can be made by the manufacturers of herbal medicines. The U.S. government has established the Office of Dietary Supplements (ODS) to support and coordinate research in this field.

## Terminology *Key Terms*

The terms listed below are emphasized in this chapter. Knowing them will help you organize and prioritize your learning. These boldface terms are also found, collectively, with all chapter key terms in the Glossary.

### Drugs

<b>anaphylaxis</b> <i>an-ab-fib-LAK-sis</i>	An extreme allergic reaction that can lead to respiratory distress, circulatory collapse, and death
<b>antagonist</b> <i>an-TAG-o-nist</i>	A substance that interferes with or opposes the action of a drug
<b>brand name</b>	The trade or proprietary name of a drug, a registered trademark of the manufacturer; written with an initial capital letter
<b>contraindication</b> <i>kon-trab-in-dih-KA-shun</i>	A factor that makes the use of a drug undesirable or dangerous
<b>drug</b>	A substance that alters body function
<b>efficacy</b> <i>EF-ih-kah-se</i>	The power to produce a specific result; effectiveness
<b>generic name</b> <i>jeb-NER-ik</i>	The nonproprietary name of a drug; that is, a name that is not privately owned or trademarked; usually a simplified version of the chemical name; not capitalized
<b>phytomedicine</b> <i>fi-to-MED-ib-sin</i>	Another name for herbal medicine (root <i>phyt/o</i> meaning “plant”)
<b>potentiation</b> <i>po-ten-she-A-shun</i>	Increased potency created by two drugs acting together
<b>prescription (Rx)</b> <i>pre-SKRIP-shun</i>	Written and signed order for a drug with directions for its administration
<b>side effect</b>	A result of drug therapy or other therapy that is unrelated to or an extension of its intended effect; usually applies to an undesirable effect of treatment
<b>substance dependence</b>	A condition that may result from chronic use of a drug, in which a person has a chronic or compulsive need for a drug regardless of its adverse effects; dependence may be psychological or physical
<b>synergy</b> <i>SIN-er-je</i>	Combined action of two or more drugs working together to produce an effect greater than any of the drugs could produce when acting alone; also called synergism ( <i>SIN-er-jizm</i> ); adjective: synergistic ( <i>sin-er-JIS-tik</i> )
<b>tolerance</b>	A condition in which chronic use of a drug results in loss of effectiveness and the dose must be increased to produce the original response
<b>withdrawal</b>	A condition that results from abrupt cessation or reduction of a drug that has been used regularly

Appendix 10 has a reference chart (A10-1) on common drugs and their actions, with select examples in each category according to generic and brand names. A second chart (A10-2) lists some common herbal medicines and their therapeutic uses. Drug information also appears within chapters on individual systems, but Appendix 10 is available as a general reference as you study.

## Drug Administration

The next section provides reference information and illustrations on drug preparations and routes of administration. **BOX 3-7** has information on routes of administration, **BOX 3-8** describes drug preparations, and **BOX 3-9** lists terms pertaining to injectable drugs.

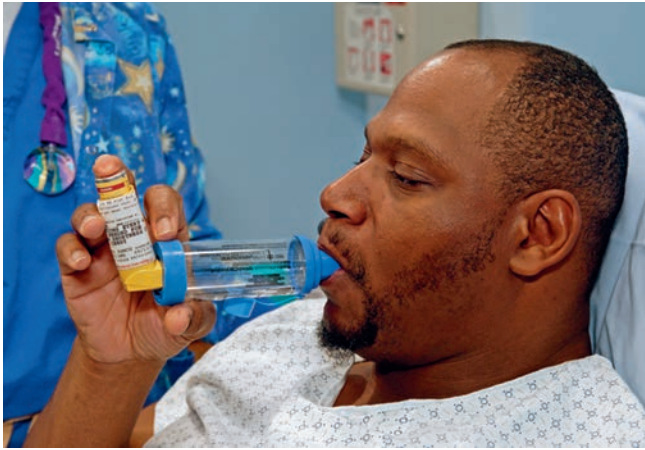

## FOR YOUR REFERENCE

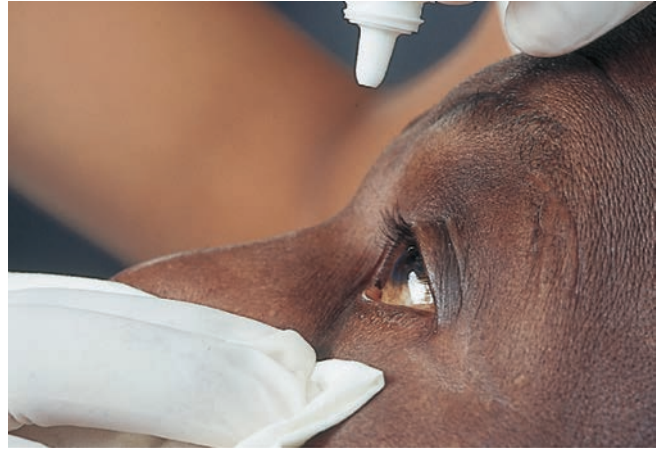### Routes of Drug Administration

BOX 3-7

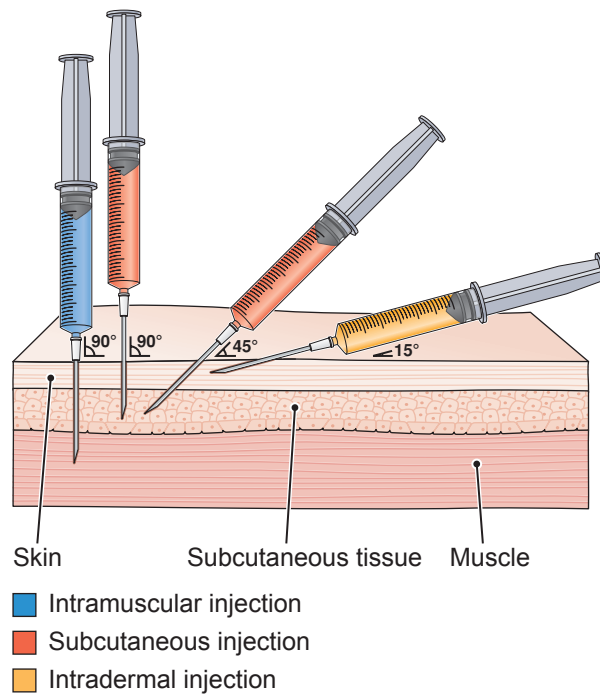
Route	Description
<b>BY ABSORPTION</b>	
<b>absorption</b> <i>ab-SORP-shun</i>	drug taken into the circulation through the digestive tract or by transfer across another membrane
<b>inhalation</b> <i>in-hah-LA-shun</i>	administration through the respiratory system, as by breathing in an aerosol or nebulizer spray ( <b>FIG. 3-20</b> )
<b>instillation</b> <i>in-stil-LA-shun</i>	liquid is dropped or poured slowly into a body cavity or on the surface of the body, such as into the ear or onto the conjunctiva of the eye ( <b>FIG. 3-21</b> )
<b>oral</b> <i>OR-al</i>	given by mouth; per os (po)
<b>rectal</b> <i>REK-tal</i>	administered by rectal suppository or enema
<b>sublingual (SL)</b> <i>sub-LING-gwal</i>	administered under the tongue
<b>topical</b> <i>TOP-ih-kal</i>	applied to the surface of the skin
<b>transdermal</b> <i>trans-DER-mal</i>	absorbed through the skin, as from a patch placed on the surface of the skin
<b>BY INJECTION</b>	
<b>injection</b> <i>in-JEK-shun</i>	administered by a needle and syringe ( <b>FIG. 3-22</b> ); described as parenteral ( <i>pah-REN-ter-al</i> ) routes of administration
<b>epidural</b> <i>ep-ih-DUR-al</i>	injected into the space between the meninges (membranes around the spinal cord) and the spine
<b>hypodermoclysis</b> <i>hi-po-der-MOK-lih-sis</i>	administration of a solution by subcutaneous infusion; useful for fluid delivery as an alternative for intravenous infusion
<b>intra dermal (ID)</b> <i>in-trah-DER-mal</i>	injected into the skin
<b>intramuscular (IM)</b> <i>in-trah-MUS-ku-lar</i>	injected into a muscle
<b>intravenous (IV)</b> <i>in-trah-VE-nus</i>	injected into a vein
<b>spinal (intrathecal)</b> <i>in-trah-THE-kal</i>	injected through the meninges into the spinal fluid
<b>subcutaneous (SC)</b> <i>sub-ku-TA-ne-us</i>	injected beneath the skin; hypodermic



**FIGURE 3-20 Inhalation of a drug.** The patient is using a metered-dose inhaler for drug administration.



**FIGURE 3-21 Instillation of a drug.** A practitioner pulls down the lower lid to administer eye drops into the lower conjunctival sac.



**FIGURE 3-22 Injection.** Comparison of the angles of insertion for intramuscular, subcutaneous, and intradermal injections.





## FOR YOUR REFERENCE

### Drug Preparations

BOX 3-8

Form	Description
<b>LIQUID</b>	
<b>aerosol</b> <i>AIR-o-sol</i>	solution dispersed as a mist to be inhaled
<b>aqueous solution</b> <i>AKE-we-us</i>	substance dissolved in water
<b>elixir (elix)</b> <i>e-LIK-sar</i>	a clear, pleasantly flavored and sweetened hydroalcoholic liquid intended for oral use
<b>emulsion</b> <i>e-MUL-shun</i>	a mixture in which one liquid is dispersed but not dissolved in another liquid
<b>lotion</b> <i>LO-shun</i>	solution prepared for topical use
<b>suspension (susp)</b> <i>sus-PEN-shun</i>	fine particles dispersed in a liquid, must be shaken before use
<b>tincture (tinct)</b> <i>TINK-chur</i>	substance dissolved in an alcoholic solution
<b>SEMISOLID</b>	
<b>cream</b> <i>kreme</i>	a semisolid emulsion used topically
<b>ointment (ung)</b> <i>OYNT-ment</i>	drug in a base that keeps it in contact with the skin
<b>SOLID</b>	
<b>capsule (cap)</b> <i>KAP-sule</i>	material in a gelatin container that dissolves easily in the stomach
<b>lozenge</b> <i>LOZ-enj</i>	a pleasant-tasting medicated tablet or disk to be dissolved in the mouth, such as a cough drop
<b>suppository (supp)</b> <i>su-POZ-ih-tor-e</i>	substance mixed and molded with a base that melts easily when inserted into a body opening
<b>tablet (tab)</b> <i>TAB-let</i>	a solid dosage form containing a drug in a pure state or mixed with a nonactive ingredient and prepared by compression or molding, also called a pill



## FOR YOUR REFERENCE

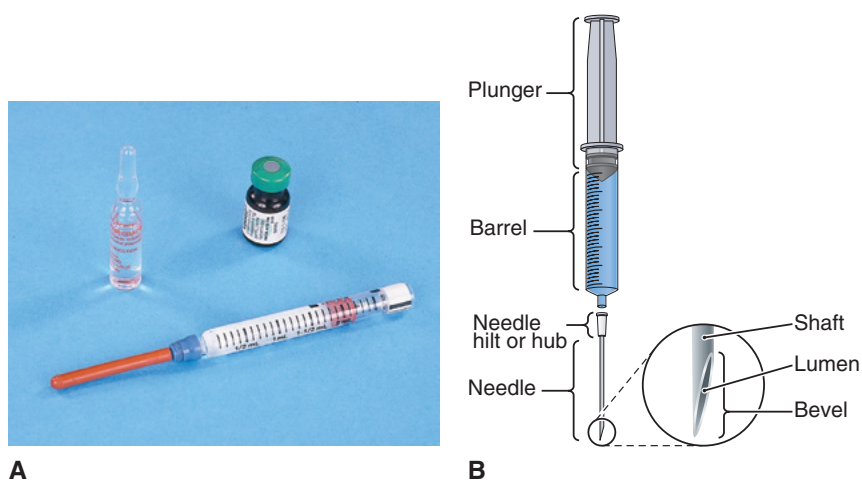
### Terms Pertaining to Injectable Drugs

BOX 3-9

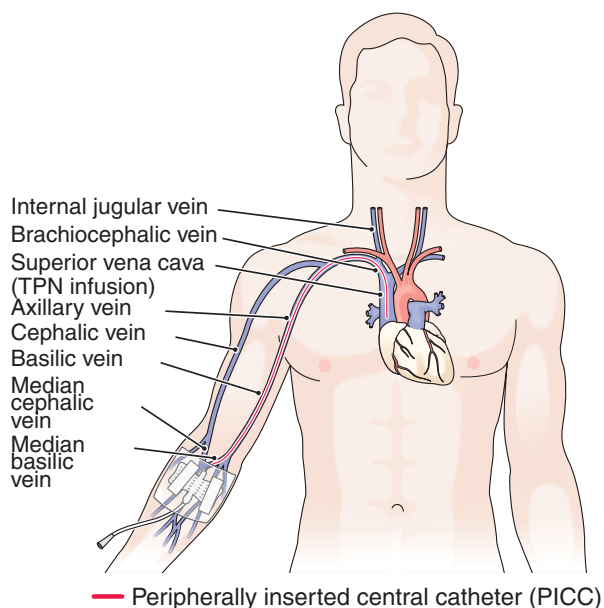
Term	Meaning
<b>ampule</b> <i>AM-pule</i>	a small sealed glass or plastic container used for sterile intravenous solutions (FIG. 3-23)
<b>bolus</b> <i>BO-lus</i>	a concentrated amount of a diagnostic or therapeutic substance given rapidly intravenously
<b>catheter</b> <i>KATH-eh-ter</i>	a thin tube that can be passed into a body cavity, organ, or vessel (FIG. 3-24)
<b>syringe</b> <i>sir-INJ</i>	an instrument for injecting fluid (see FIG. 3-23)
<b>vial</b> <i>VI-al</i>	a small glass or plastic container (see FIG. 3-23A)

**FIGURE 3-23** Injectable drug materials.

**A.** Injectable drug containers. An ampule (top left), a vial (top right), and a syringe (bottom) are shown. **B.** Parts of a needle and syringe.



**FIGURE 3-24** Catheter. Shown is placement of a peripherally inserted central catheter (PICC).



## Word Parts Pertaining to Drugs

TABLE 3-9 lists word parts pertaining to drugs.

Table 3-9		Word Parts Pertaining to Drugs	
	Meaning	Example	Definition of Example
<b>Suffixes</b>			
-lytic (adjective of lysis)	dissolving, reducing, loosening	thrombolytic <i>throm-bo-LIT-ik</i>	agent that dissolves a blood clot (thrombus)
-mimetic	mimicking, simulating	sympathomimetic <i>sim-pab-tho-mih-MET-ik</i>	mimicking the effects of the sympathetic nervous system
-tropic	acting on	psychotropic <i>si-ko-TROP-ik</i>	acting on the mind (psych/o)
<b>Prefixes</b>			
anti-	against	antiemetic <i>an-te-eh-MET-ik</i>	drug that prevents vomiting (emesis)
contra-	against, opposite, opposed	contraceptive <i>kon-trab-SEP-tiv</i>	preventing conception
counter-	against, opposed	countertransport <i>kown-ter-TRANS-port</i>	movement in an opposite direction
<b>Roots</b>			
alg/o, algi/o, algesi/o	pain	algisia <i>al-JE-ze-ab</i>	sense of pain
chem/o	chemical	chemotherapy <i>ke-mo-THER-ab-pe</i>	treatment with drugs
hypn/o	sleep	hypnosis <i>hip-NO-sis</i>	induced state of sleep
narc/o	stupor	narcotic <i>nar-KOT-ik</i>	agent that induces a state of stupor with decreased sensation
pharm, pharmac/o	drug, medicine	pharmacy <i>FAR-mab-se</i>	the science of preparing and dispensing drugs, or the place where these activities occur
pyr/o, pyret/o	fever	antipyretic <i>an-te-pi-RET-ik</i>	counteracting fever
tox/o, toxic/o	poison, toxin	toxicity <i>tok-SIS-ih-te</i>	state of being poisonous
vas/o	vessel	vasodilation <i>vas-o-di-LA-shun</i>	widening of a vessel

### Exercise 3-9

Complete the exercise. To check your answers go to Appendix 11.

Identify and define the suffix in each of the following words.

	Suffix	Meaning of Suffix
1. hemolytic ( <i>he-mo-LIT-ik</i> )	_____	_____
2. hydrotropic ( <i>hi-dro-TROP-ik</i> )	_____	_____
3. parasympathomimetic ( <i>par-ab-sim-pab-tho-mih-MET-ik</i> )	_____	_____

**Exercise 3-9 (Continued)**

Using the prefixes listed in **TABLE 3-9**, write the opposite of each of the following words.

4. bacterial \_\_\_\_\_
5. lateral \_\_\_\_\_
6. septic \_\_\_\_\_
7. act \_\_\_\_\_
8. emetic \_\_\_\_\_
9. pyretic \_\_\_\_\_

Identify and define the root in each of the following words.

	Root	Meaning of Root
10. narcosis ( <i>nar-KO-sis</i> )	_____	_____
11. chemistry ( <i>KEM-is-tre</i> )	_____	_____
12. analgesia ( <i>an-al-JE-ze-ah</i> )	_____	_____
13. toxicology ( <i>tok-sib-KOL-o-je</i> )	_____	_____
14. hypnotic ( <i>hip-NOT-ik</i> )	_____	_____

Define each of the following words.

15. vasodilation (*va-so-di-LA-shun*) \_\_\_\_\_
16. pharmacology (*far-mah-KOL-o-je*) \_\_\_\_\_
17. mucolytic (*mu-ko-LIT-ik*) \_\_\_\_\_
18. gonadotropic (*go-nad-o-TROP-ik*) \_\_\_\_\_

**Terminology Abbreviations**

The abbreviations listed below are emphasized in this chapter. These are also found, collectively, with all chapter abbreviations in Appendix 2.

**Drugs and Drug Formulations**

<b>APAP</b>	Acetaminophen
<b>ASA</b>	Acetylsalicylic acid (aspirin)
<b>ASHP</b>	American Society of Health System Pharmacists
<b>cap</b>	Capsule
<b>elix</b>	Elixir
<b>FDA</b>	Food and Drug Administration
<b>INH</b>	Isoniazid (antituberculosis drug)
<b>MED(s)</b>	Medicine(s), medication(s)
<b>NSAID(s)</b>	Nonsteroidal anti-inflammatory drug(s)
<b>ODS</b>	Office of Dietary Supplements

**OTC** Over-the-counter

**PDR** *Physicians' Desk Reference*

**Rx** Prescription

**supp** Suppository

**susp** Suspension

**tab** Tablet

**tinct** Tincture

**ung** Ointment

**USP** *United States Pharmacopeia*

**Dosages and Directions**

**ā** Before (Latin, *ante*)

(continued)

## Terminology

## Abbreviations (Continued)

<b>āā</b>	Of each (Greek, <i>ana</i> )	<b>pc</b>	After meals (Latin, <i>post cibum</i> )
<b>ac</b>	Before meals (Latin, <i>ante cibum</i> )	<b>po, PO</b>	By mouth (Latin, <i>per os</i> )
<b>ad lib</b>	As desired (Latin, <i>ad libitum</i> )	<b>pp</b>	Postprandial (after a meal)
<b>aq</b>	Water (Latin, <i>aqua</i> )	<b>prn</b>	As needed (Latin, <i>pro re nata</i> )
<b>bid, b.i.d.</b>	Twice a day (Latin, <i>bis in die</i> )	<b>qam</b>	Every morning (Latin, <i>quaque ante meridiem</i> )
<b>ċ</b>	With (Latin, <i>cum</i> )	<b>qh</b>	Every hour (Latin, <i>quaque hora</i> )
<b>DAW</b>	Dispense as written	<b>q__h</b>	Every _____ hours
<b>D/C, dc</b>	Discontinue	<b>qid, q.i.d.</b>	Four times a day (Latin, <i>quater in die</i> )
<b>DS</b>	Double strength	<b>ś</b>	Without (Latin, <i>sine</i> )
<b>hs</b>	At bedtime (Latin, <i>hora somni</i> )	<b>SA</b>	Sustained action
<b>ID</b>	Intradermal(ly)	<b>SC, SQ, subcut</b>	Subcutaneous(ly)
<b>IM</b>	Intramuscular(ly)	<b>SL</b>	Sublingual(ly)
<b>IU</b>	International unit	<b>SR</b>	Sustained release
<b>IV</b>	Intravenous(ly)	<b>śś</b>	Half (Latin, <i>semis</i> )
<b>LA</b>	Long-acting	<b>tid, t.i.d.</b>	Three times per day (Latin, <i>ter in die</i> )
<b>mcg</b>	Microgram	<b>U</b>	Unit(s)
<b>mg</b>	Milligram	<b>x</b>	Times
<b>mL</b>	Milliliter		
<b>p</b>	After, post		

## Case Study Revisited

**Mary's Injury Follow-Up**

Mary was seen by the orthopedic surgeon who scheduled an OR and performed a surgical procedure by making an incision to directly access the broken bones to improve alignment (open reduction). A plate and screws were inserted to hold the bones in the proper place. Generally, the plate stays in permanently, causes no problems, and usually does not set off airport alarms. Mary was then scheduled for an arthrocentesis to remove fluid from the right knee. After an overnight stay in the hospital Mary was discharged to home. The physical therapist (PT) gave Mary educational material on how to safely be mobile at home and guided her through some exercises.

Since Mary's gait was a bit unsteady the PT sent her home with a platform walker, which is designed for

those who are unable to grip the walker. A large top bracket allows the platform attachment to be placed over the right or left hand grip of the walker. In Mary's case placement was over the right-hand grip with an adjustable strap to secure the arm in place. The surgeon directed Mary to take an anti-inflammatory medication (NSAID) for the inflammation and pain. She said that postoperative fractures hurt moderately for a few days to a couple of weeks. She also instructed that using ice, elevation (holding her right arm up above her heart) in addition to the NSAID should be all that would be needed to relieve pain. The surgeon also scheduled several clinic visits with Mary to closely monitor the healing by taking regular x-rays and checking the incision site.

These questions test your understanding of the content introduced in this chapter. Follow the instructions for each exercise and check your answers in Appendix 11.

*Match the following terms, and write the appropriate letter to the left of each number.*

- |                        |   |
|------------------------|---|
| ___ 1. cardiomegaly    | a. pertaining to profuse flow of blood              |
| ___ 2. neuroma         | b. fear of cancer                                   |
| ___ 3. carcinophobia   | c. tumor of a nerve                                 |
| ___ 4. encephalitis    | d. enlargement of the heart                         |
| ___ 5. hemorrhagic     | e. inflammation of the brain                        |
| ___ 6. sclerotic       | a. stone formation                                  |
| ___ 7. oncolysis       | b. dry  |
| ___ 8. analgesia       | c. destruction of a tumor                           |
| ___ 9. xerotic         | d. absence of pain                                  |
| ___ 10. lithiasis      | e. hardened   |
| ___ 11. blepharoptosis | a. local wound or injury                            |
| ___ 12. hemostasis     | b. stoppage of blood flow                           |
| ___ 13. toxoid         | c. dropping of the eyelid                           |
| ___ 14. lesion         | d. like a poison                                    |
| ___ 15. ectasia        | e. dilatation                                       |
| ___ 16. electrolyte    | a. substance that conducts electric current         |
| ___ 17. staging        | b. evidence of disease                              |
| ___ 18. symptom        | c. classification of malignant tumors               |
| ___ 19. syndrome       | d. a group of symptoms that characterizes a disease |
| ___ 20. suture         | e. to unite parts by stitching them together        |
| ___ 21. cautery        | a. a removal of tissue for microscopic study        |
| ___ 22. scintiscan     | b. pain caused by cold                              |
| ___ 23. cryalgnesia    | c. destruction of tissue with a damaging agent      |
| ___ 24. vasotripsy     | d. image obtained with a radionuclide               |
| ___ 25. biopsy         | e. crushing of a vessel                             |
| ___ 26. hyperpyrexia   | a. extreme allergic reaction                        |
| ___ 27. potentiation   | b. effectiveness                                    |
| ___ 28. chronotropic   | c. affecting timing                                 |
| ___ 29. anaphylaxis    | d. combined drug action to greater effect           |
| ___ 30. efficacy       | e. abnormally high body temperature                 |

*Enrichment Terms*

- |                     |  |
|---------------------|--|
| ___ 31. nosocomial  | a. abnormal passageway                             |
| ___ 32. iatrogenic  | b. escape of fluid into a cavity                   |
| ___ 33. fistula     | c. tumor attached by a thin stalk                  |
| ___ 34. polyp       | d. acquired in a hospital                          |
| ___ 35. effusion    | e. caused by effects of treatments                 |
|                     |  |
| ___ 36. sequelae    | a. partial excision                                |
| ___ 37. prophylaxis | b. prevention of disease                           |
| ___ 38. clubbing    | c. symptom indicating an approaching disease       |
| ___ 39. prodrome    | d. lasting effects of disease                      |
| ___ 40. resection   | e. enlargement of the ends of the fingers and toes |
|                     |  |
| ___ 41. catheter    | a. thin tube                                       |
| ___ 42. colic       | b. feeling of discomfort                           |
| ___ 43. diaphoresis | c. acute abdominal pain                            |
| ___ 44. malaise     | d. washing out of a cavity                         |
| ___ 45. lavage      | e. profuse sweating                                |

**FILL IN THE BLANKS**

*Complete the sentence with the correct term(s).*

46. Heat, pain, redness, and swelling are the four major signs of \_\_\_\_\_.
47. Any abnormal and uncontrolled growth of tissue, whether benign or malignant, is called a(n) \_\_\_\_\_.
48. The spreading of cancer to other parts of the body is the process of \_\_\_\_\_.
49. Protrusion of an organ through an abnormal opening is a(n) \_\_\_\_\_.
50. Death of tissue is called \_\_\_\_\_.
51. An oncoprotein is a protein associated with a(n) \_\_\_\_\_.
52. The common name for a helminth is a(n) \_\_\_\_\_.
53. The PA in Mary's case evaluated her wrist by touching it. The term for this examination technique is \_\_\_\_\_.
54. Following her examination, the PA predicted the outcome of Mary's injuries; that is, she gave a(n) \_\_\_\_\_.
55. In the same case study, the adjective form of edema is \_\_\_\_\_.
56. Another word for *treatment* is \_\_\_\_\_.
57. Photochromic eyeglass lenses change color in response to \_\_\_\_\_.
58. Plastic repair of the stomach is called \_\_\_\_\_.
59. Fusion of a joint is \_\_\_\_\_.
60. Surgical creation of an opening in the colon is a(n) \_\_\_\_\_.
61. A transdermal route of administration is through the \_\_\_\_\_.
62. When a drug has lost its effect at a constant dose, the patient has developed \_\_\_\_\_.
63. An intravenous injection is given into a(n) \_\_\_\_\_.
64. With reference to drug interactions, another term for synergy is \_\_\_\_\_.

Use Appendix 10 to answer the following six questions.

65. Any drug that promotes excretion by the kidney is a(n) \_\_\_\_\_.
66. Any drug that relieves nausea and prevents vomiting is (a)n \_\_\_\_\_.
67. Analgesics are used to eliminate \_\_\_\_\_.
68. Any drug that affects the mind is described as a(n) \_\_\_\_\_.
69. Flax is an herbal substance that supplies \_\_\_\_\_.
70. The part of the aloe plant that is used for treatment is the \_\_\_\_\_.

Use the root *-hepat/o*, meaning “liver,” to write a word for each of the following.

71. Incision of the liver \_\_\_\_\_
72. Excision of liver tissue \_\_\_\_\_
73. Surgical fixation of the liver \_\_\_\_\_
74. Surgical repair of the liver \_\_\_\_\_

Use the suffix *-genesis* to write words with the following meanings.

75. Formation of cancer \_\_\_\_\_
76. Origin of any disease \_\_\_\_\_
77. Formation of pus \_\_\_\_\_
78. Formation of a tumor \_\_\_\_\_

The root *bronch/o* pertains to a bronchus, an air passageway in the lungs. Add a suffix to this root to form words with the following meanings.

79. Excessive flow or discharge from a bronchus \_\_\_\_\_
80. Inflammation of a bronchus \_\_\_\_\_
81. Narrowing of a bronchus \_\_\_\_\_
82. Sudden contraction of a bronchus \_\_\_\_\_

Use the root *oste/o*, meaning “bone,” to form words with the following meanings.

83. Pain in a bone \_\_\_\_\_
84. Death of bone tissue \_\_\_\_\_
85. Tumor of a bone \_\_\_\_\_
86. Breaking of a bone \_\_\_\_\_
87. Softening of a bone \_\_\_\_\_



**TRUE-FALSE**

Examine the following statements. If the statement is true, write T in the first blank. If the statement is false, write F in the first blank, and correct the statement by replacing the underlined word in the second blank.

	True or False	Correct Answer
88. A mycosis is an infection with a <u>protozoan</u> .	_____	_____
89. Round bacteria in chains are <u>streptococci</u> .	_____	_____
90. A sudden disease of short duration is <u>chronic</u> .	_____	_____
91. A tumor that does not metastasize is termed <u>benign</u> .	_____	_____
92. A slower than normal heart rate is <u>tachycardia</u> .	_____	_____
93. An otoscope is used to examine the <u>eye</u> .	_____	_____
94. An image produced by x-rays is a <u>radiogram</u> .	_____	_____
95. Arthroscopy is endoscopic examination of a <u>joint</u> .	_____	_____

**ELIMINATIONS**

In each of the sets below, underline the word that does not fit in with the rest, and explain the reason for your choice.

96. cocci — helminths — chlamydia — bacilli — vibrios  
\_\_\_\_\_
97. septicemic — endemic — metastatic — opportunistic — epidemic  
\_\_\_\_\_
98. percussion — inspection — palpation — remission — auscultation  
\_\_\_\_\_
99. ophthalmoscope — sphygmomanometer — stethoscope — syncope — endoscope  
\_\_\_\_\_
100. solution — elixir — tincture — emulsion — tablet  
\_\_\_\_\_

**WORD BUILDING**

Use the word parts given to build words for the following definitions. Each word part can be used more than once.

tox	pyr	gen	o	py	-oma	-y	path	nephr	-logy	-ic
-----	-----	-----	---	----	------	----	------	-------	-------	-----

101. poisonous for the kidney \_\_\_\_\_
102. producing pus \_\_\_\_\_
103. tumor of the kidney \_\_\_\_\_
104. study of disease \_\_\_\_\_
105. producing fever \_\_\_\_\_
106. study of the kidney \_\_\_\_\_
107. producing disease \_\_\_\_\_
108. any disease of the kidney \_\_\_\_\_
109. producing kidney tissue \_\_\_\_\_

**WORD BUILDING**

Use the word parts given to build words for the following definitions. Each word part can be used more than once.

lith/o    -rhaphy    neur/o    -tripsy    -tome    r    -pexy    -scopy    cyst/o

110. Crushing of a nerve \_\_\_\_\_
111. Surgical repair of the bladder \_\_\_\_\_
112. Surgical fixation of the bladder \_\_\_\_\_
113. Surgical repair of a nerve \_\_\_\_\_
114. Crushing of a stone \_\_\_\_\_
115. Bladder stone \_\_\_\_\_
116. Endoscopic examination of the bladder \_\_\_\_\_
117. Instrument used to incise a nerve \_\_\_\_\_
118. Instrument used to incise the bladder \_\_\_\_\_

**WORD ANALYSIS**

Define the following words, and give the meanings of the word parts in each. Use a dictionary if necessary.

119. phagocytosis (*fag-o-si-TO-sis*)
- a. phag/o \_\_\_\_\_
- b. cyt/o \_\_\_\_\_
- c. -sis \_\_\_\_\_
120. antipyretic (*an-te-pi-RET-ik*)
- a. anti- \_\_\_\_\_
- b. pyret/o \_\_\_\_\_
- c. -ic \_\_\_\_\_
121. arteriosclerosis (*ar-te-re-o-skleh-RO-sis*)
- a. arterio/o \_\_\_\_\_
- b. scler/o \_\_\_\_\_
- c. -sis \_\_\_\_\_
122. asymmetric (*a-sim-ET-rik*)
- a. a- \_\_\_\_\_
- b. sym- \_\_\_\_\_
- c. metr/o \_\_\_\_\_
- d. -ic \_\_\_\_\_

# Additional Case Studies

## Case Study 3-1: Endocarditis

Robert, a 37 y/o man, sought treatment after experiencing several days of high fever and generalized weakness on return from his vacation. Robert's family doctor suspected cardiac involvement because of Robert's history of rheumatic fever. The doctor was concerned because Robert's brother had died of acute malignant hyperpyrexia during surgery at the age of 12. Robert was referred to a cardiologist,

who scheduled an electrocardiogram (ECG) and a transesophageal echocardiogram (TEE).

Robert was admitted to the hospital with subacute bacterial endocarditis (SBE) and placed on high-dose IV antibiotics and bed rest. He had also developed a heart murmur, which was diagnosed as idiopathic hypertrophic subaortic stenosis (IHSS).

### Case Study 3-1 Questions

Follow the instructions for each question and check your answers in Appendix 11.

**Multiple Choice.** Select the best answer, and write the letter of your choice to the left of each number.

- |  |   |
|--|---|
| <p>_____ 1. The endocardium is the tissue lining the heart's chambers. Endocarditis refers to a(n) _____ of this lining.</p> <ul style="list-style-type: none"><li>a. narrowing</li><li>b. inflammation</li><li>c. overgrowth</li><li>d. thinning</li></ul> <p>_____ 2. Robert's heart murmur was caused by a stenosis, or _____ of the heart's aortic valve.</p> <ul style="list-style-type: none"><li>a. narrowing</li><li>b. inflammation</li><li>c. overgrowth</li><li>d. cancer</li></ul> | <p>_____ 3. The term for a condition or disease of unknown etiology is</p> <ul style="list-style-type: none"><li>a. iatrogenic</li><li>b. chronic</li><li>c. acute</li><li>d. idiopathic</li></ul> <p>_____ 4. A term that describes increase in the size of an organ without increase in the number of cells is</p> <ul style="list-style-type: none"><li>a. hyperplastic</li><li>b. fistular</li><li>c. hypertrophic</li><li>d. metaplastic</li></ul> |
|--|---|

Give the meaning of the following abbreviations.

- 5. ECG \_\_\_\_\_
- 6. TEE \_\_\_\_\_
- 7. SBE \_\_\_\_\_
- 8. IHSS \_\_\_\_\_

## Case Study 3-2: Asthma

Chelsea, a 20 y/o woman with asthma, visited the preadmission testing unit 1 week before her cosmetic surgery to meet with the nurse and anesthesiologist. Her current meds included several bronchodilators, which she takes by mouth and by inhalation, and a tranquilizer that she takes when needed for nervousness. She sometimes receives inhalation treatments with Mucomyst, a mucolytic agent. On Chelsea's preoperative note, the nurse wrote:

Theo-Dur 1 cap 200 mg t.i.d.  
 Flovent inhaler 1 spray (50 mcg each nostril b.i.d.)  
 Ativan (lorazepam) 1 mg po b.i.d.  
 Albuterol metered-dose inhaler 2 puffs (180 mcg) p.r.n.  
 q4–6h for bronchospasm and before exercise

Chelsea stated that she has difficulty with her asthma when she is anxious and when she exercises. She also admitted to occasional use of marijuana and ecstasy, a hallucinogen and mood-altering illegal recreational drug. The anesthesiologist wrote an order for lorazepam 4 mg IV 1 hour preop. The plastic surgeon recommended several supplements to complement her surgery and her recovery. He ordered a high-potency vitamin, 1 tab with breakfast and dinner, to support tissue health and healing. He also prescribed bromelain, an enzyme from pineapple, to decrease inflammation, one 500 mg cap po q.i.d. 3 days before surgery and postoperatively for 2 weeks. Arnica montana was prescribed to decrease discomfort, swelling, and bruising; three tabs sublingual t.i.d. the evening after surgery and for the following 10 days.

### Case Study 3-2 Questions

Follow the instructions for each question and check your answers in Appendix 11.

**Multiple Choice.** Select the best answer, and write the letter of your choice to the left of each number.

- |   |   |
|---|---|
| <p>_____ 1. Chelsea's Flovent inhaler is indicated as 1 spray of 50 mcg in each nostril b.i.d. How many micrograms (mcg) does she get in 1 day?</p> <p>a. 100 mcg<br/>           b. 200 mcg<br/>           c. 250 mcg<br/>           d. 500 mcg</p> <p>_____ 2. As noted in Appendix 10, the Ativan that E.N. takes for nervousness is a(n) _____ drug.</p> <p>a. anxiolytic<br/>           b. antiemetic<br/>           c. analgesic<br/>           d. bronchodilator</p> <p>_____ 3. The anesthesiologist ordered lorazepam (Ativan) to be given IV preop to decrease anxiety and to smooth Chelsea's anesthesia induction. The complementary way that lorazepam and anesthesia work together is called</p> <p>a. antagonistic<br/>           b. complementary medicine<br/>           c. synergy<br/>           d. tolerance</p> | <p>_____ 4. Bromelain and Arnica montana are supplements that can be described as all of the following except</p> <p>a. phytopharmaceutical<br/>           b. alternative<br/>           c. chronotropic<br/>           d. complementary</p> <p>_____ 5. Arnica montana was prescribed three tabs SL t.i.d. How many tablets would Chelsea take in 1 day?</p> <p>a. 6<br/>           b. 33<br/>           c. 12<br/>           d. 9</p> <p>_____ 6. Flovent is administered as an inhalant. The form in which the drug is prepared is called a(n)</p> <p>a. aerosol<br/>           b. elixir<br/>           c. unguent<br/>           d. emulsion</p> |
|---|---|

*Define each of the following abbreviations.*

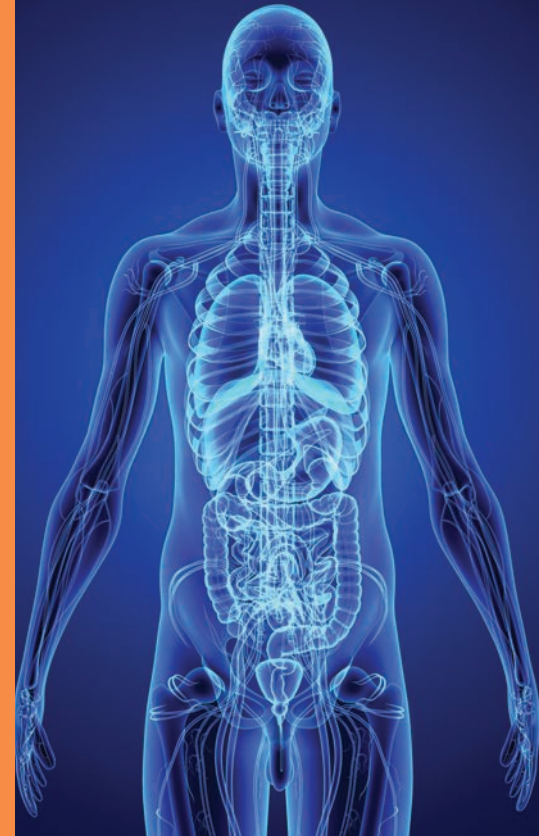7. po \_\_\_\_\_
8. mg \_\_\_\_\_
9. mcg \_\_\_\_\_
10. IV \_\_\_\_\_

# PART III

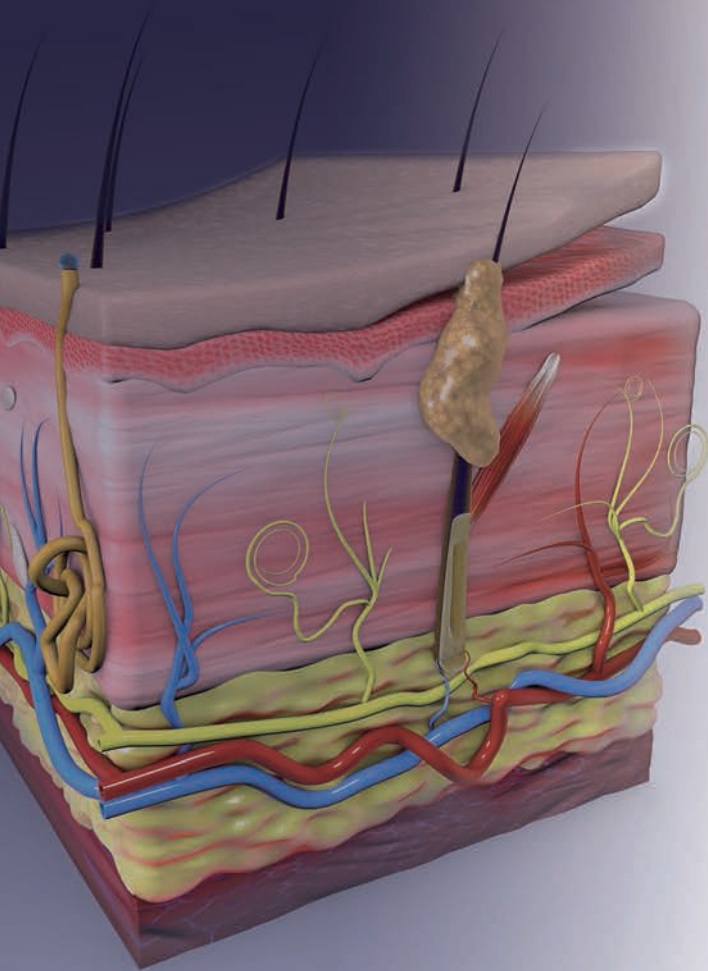


## Body Systems

- Chapter 4 Integumentary System**
- Chapter 5 Skeletal System**
- Chapter 6 Muscular System**
- Chapter 7 Nervous System and Mental Health**
- Chapter 8 Special Senses: Ear and Eye**
- Chapter 9 Endocrine System**
- Chapter 10 Cardiovascular and Lymphatic Systems**
- Chapter 11 Blood and Immunity**
- Chapter 12 Respiratory System**
- Chapter 13 Digestive System**
- Chapter 14 Urinary System**
- Chapter 15 Male Reproductive System**
- Chapter 16 Female Reproductive System; Pregnancy and Birth**



# Integumentary System



## Pretest

**Multiple Choice.** Select the best answer, and write the letter of your choice to the left of each number. To check your answers go to Appendix 11.

- \_\_\_\_\_ 1. The uppermost portion of the skin is called the
  - a. fossa
  - b. cuticle
  - c. epidermis
  - d. epiphysis
- \_\_\_\_\_ 2. The glands that secrete an oily substance that lubricates the skin are the
  - a. mammary glands
  - b. sebaceous glands
  - c. sweat glands
  - d. ceruminous glands
- \_\_\_\_\_ 3. The rule of nines is a system used to evaluate
  - a. burns
  - b. fever
  - c. immunity
  - d. inflammation
- \_\_\_\_\_ 4. A pigmented skin tumor is a(n)
  - a. chondrosarcoma
  - b. melanoma
  - c. lymphoma
  - d. adenoma
- \_\_\_\_\_ 5. The root *hidr/o* pertains to
  - a. saliva
  - b. tears
  - c. mucus
  - d. sweat
- \_\_\_\_\_ 6. Onychomycosis is a fungal infection of a(n)
  - a. eyelid
  - b. hair
  - c. nail
  - d. bone

## Learning Objectives

After careful study of this chapter, you should be able to:

- 1 Define and list the functions of the integumentary system. **P126**
- 2 Compare the locations and structures of the epidermis, dermis, and subcutaneous tissues. **P126**
- 3 Describe the roles of keratin and melanin in the skin. **P126**
- 4 Name and describe the glands in the skin. **P126**
- 5 Describe the structure of hair and nails. **P127**
- 6 Identify and use roots pertaining to the integumentary system. **P129**
- 7 Describe the main disorders that affect the skin. **P130**
- 8 Interpret abbreviations used in the study and treatment of the skin. **P141**
- 9 Identify and analyze medical terms and abbreviations in chapter case studies. **PP125, 148**

## Case Study: Kathleen's Pressure Ulcer



### Chief Complaint

Kathleen, an elderly woman in failing health, had recently moved in with her daughter after her hospitalization for a stroke. The daughter reported to the home care nurse that her mother had minimal appetite and was confused and disoriented and that a blister had developed on her lower back since she had been confined to bed.

### Examination

During the biweekly visit, the home care nurse spoke with the daughter and then went in to see the mother. On her initial assessment, the nurse noted that Kathleen had lost weight since her last visit and that her skin was dry, with poor skin turgor pressure. She also observed that the mother was wearing an "adult diaper," which was wet. The nurse took the mother's BP, HR, and R, which were normal. She assessed the mother's mental status and then proceeded to a skin assessment paying special attention to the bony prominences. After examining Kathleen's sacrum, the nurse noted a nickel-sized open area, 2 cm in diameter and 1 cm in depth (stage II pressure ulcer), with a 0.5-cm reddened surrounding area with no drainage.

Kathleen moaned when the nurse palpated the lesion. The nurse also noted reddened areas on Kathleen's elbows and heels. The remainder of the examination saw no change from the previous visit.

### Clinical Course

The nurse provided Kathleen's daughter with instructions for proper skin care, incontinence management, enhanced nutrition, and frequent repositioning to prevent pressure ischemia to the prominent body areas. However, 6 months later, Kathleen's pressure ulcer had deteriorated to class III. She was hospitalized under the care of a plastic surgeon and wound care nurse. Surgery was scheduled for debridement of the sacral wound and closure with a full-thickness skin graft (FTSG) taken from her thigh. Kathleen was discharged 8 days later to a long-term care facility with orders for an alternating pressure mattress, position change every 2 hours, supplemental nutrition, and meticulous wound care.

**Case Study Revisited:** Once you complete this chapter, please review the case follow-up on p. 142.

## Ancillaries *At-A-Glance*

Visit the web resource to access the following resources.



## Learning Resources

- eBook
- A&P Module with Heart & Lung Sounds
- Image Bank

- TestPrep
- Animations
- Audio Pronunciation Glossary

## Introduction

The skin and its associated structures make up the **integumentary system**. This body-covering system protects against infection, dehydration, ultraviolet radiation, and injury. Extensive damage to the skin, such as by burns, can result in a host of dangerous complications.

The skin helps to regulate temperature by evaporation of sweat and by changes in the diameter of surface blood vessels, which control how much heat is lost to the environment. The skin also contains receptors for the sensory perceptions of touch, temperature, pressure, and pain. Medication can be delivered through the skin from patches, as explained in **BOX 4-1**.

The word **derma** (from Greek) means “skin” and is used as an ending in words pertaining to the skin, such as xeroderma (dryness of the skin) and scleroderma (hardening of the skin). The adjective **cutaneous** refers to the skin and is from the Latin word *cutis* for skin. Like the eyes, the skin is a readily visible reflection of one’s health. Its color, texture, and resilience reveal much, as does the condition of the hair and nails.

## Anatomy of the Skin

The skin’s outermost portion is the **epidermis**, consisting of four to five layers (strata) of epithelial cells (**FIG. 4-1**). The

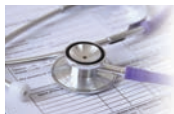deepest epidermal layer, the stratum basale, or basal layer, produces new cells. As these cells gradually rise toward the surface, they die and become filled with **keratin**, a protein that thickens and toughens the skin. The outermost epidermal layer, the stratum corneum or horny layer, is composed of flat, dead, protective cells that are constantly being shed and replaced. Some of the cells in the epidermis produce **melanin**, a pigment that gives the skin color and protects against sunlight. Irregular spots of melanin form freckles.

The **dermis** is beneath the epidermis. It contains connective tissue, nerves, blood vessels, lymphatics, and sensory receptors. This layer supplies nourishment and support for the skin. The **subcutaneous layer** beneath the dermis is composed mainly of connective tissue and fat.

## Associated Skin Structures

Specialized structures within the skin are part of the integumentary system:

- The **sweat** (sudoriferous) **glands** act mainly in temperature regulation by releasing a watery fluid that evaporates to cool the body.
- The **sebaceous glands** release an oily fluid, **sebum**, that lubricates the hair and skin and prevents drying.



### CLINICAL PERSPECTIVES

#### Medication Patches: No Bitter Pill to Swallow

BOX 4-1

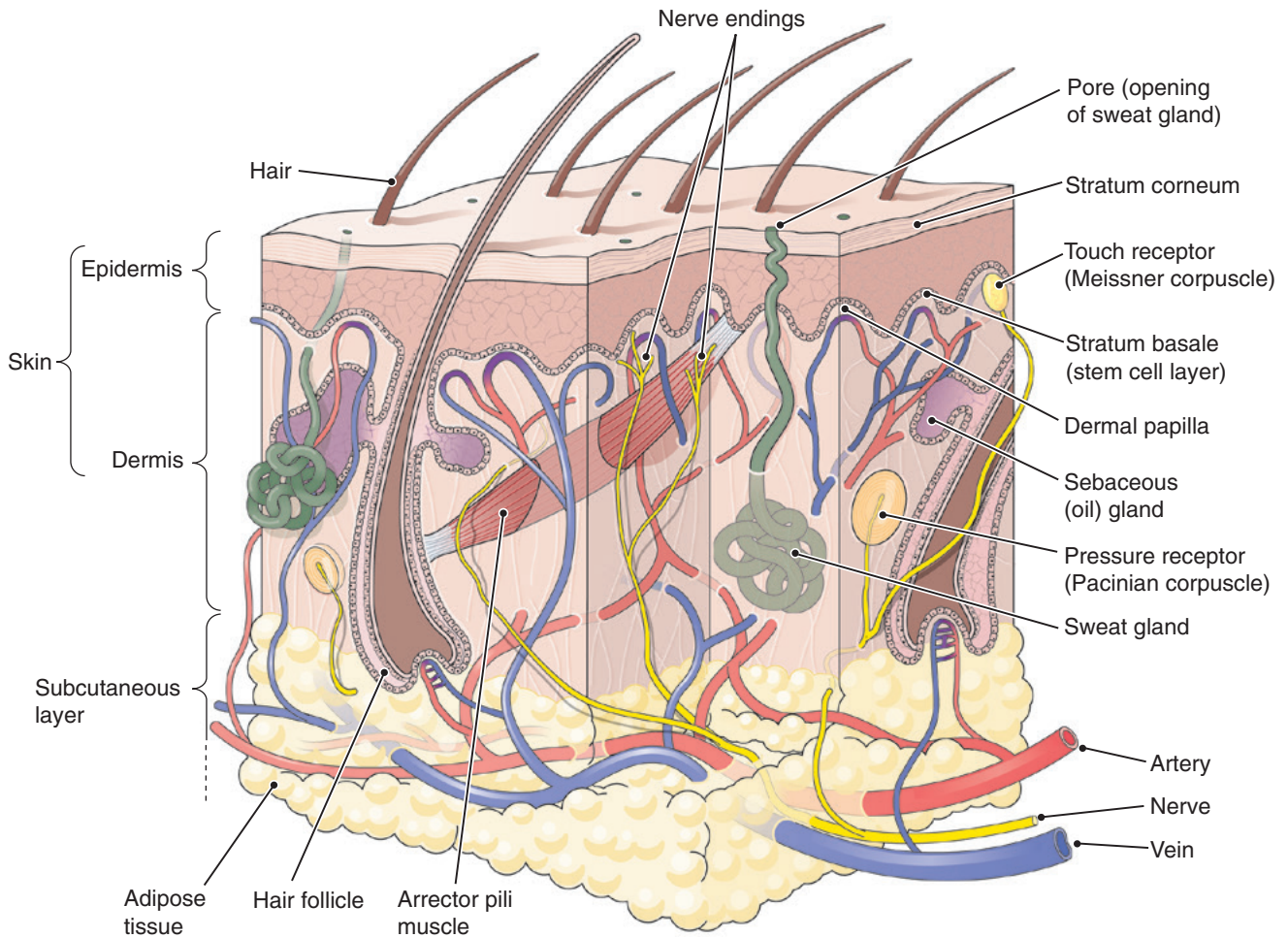
For most people, pills are a convenient way to take medication, but for some, they have drawbacks. Pills must be taken at regular intervals to ensure consistent dosing, and they must be digested and absorbed into the bloodstream before they can begin to work. For those who have difficulty swallowing or digesting pills, transdermal (TD) patches offer an effective alternative to oral medications.

TD patches deliver a consistent dose of medication that diffuses at a constant rate through the skin into the bloodstream. There is no daily schedule to follow, nothing to swallow, and no stomach upset. TD patches can also deliver medication to unconscious patients, who would otherwise require intravenous drug delivery. TD patches are used in hormone replacement therapy, to treat heart disease, to manage pain, and to suppress motion sickness. Nicotine patches are also used as part of programs to quit smoking.

TD patches must be used carefully. Drug diffusion through the skin takes time, so it is important to know how long the patch must be in place before it is effective. It is also

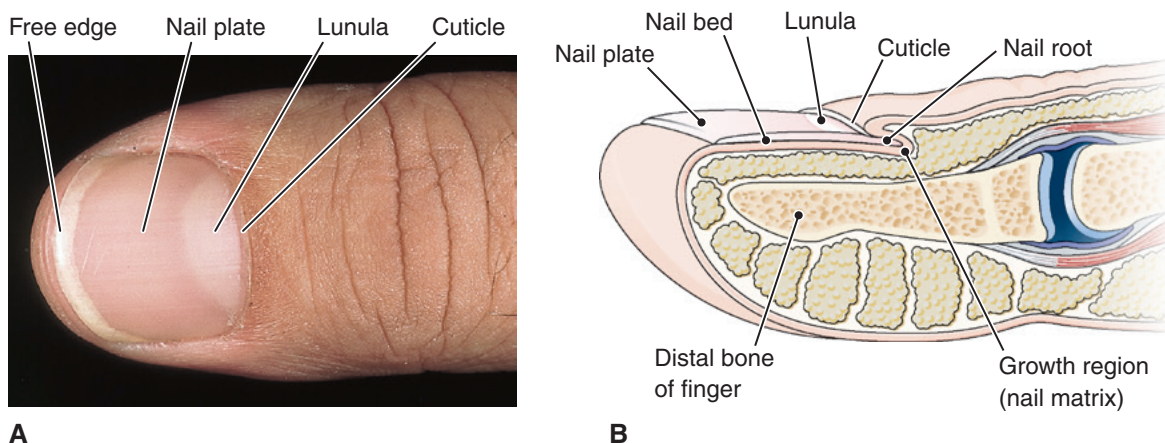
important to know when the medication’s effects disappear after the patch is removed. Because the body continues to absorb what has already diffused into the skin, removing the patch does not entirely remove the medicine. There is also a danger that patches may become unsafe when heated, as by exercise, high fever, or a hot environment, such as a hot tub, heating pad, or sauna. When heat dilates the capillaries in the skin, a dangerous increase in dosage may result as more medication enters the blood.

A recent advance in TD drug delivery is iontophoresis. Based on the principle that like charges repel each other, this method uses a mild electrical current to move ionic drugs through the skin. A small electrical device attached to the patch uses positive current to “push” positively charged drug molecules through the skin and a negative current to push negatively charged ones. Even though very low levels of electricity are used, people with pacemakers should not use iontophoretic patches. Another disadvantage of these patches is that they can move only ionic drugs through the skin.



**FIGURE 4-1** Cross-section of the skin. The skin layers and associated structures are shown.

- **Hair** is widely distributed over the body. Each hair develops within a sheath or **hair follicle** and grows from its base within the skin's deep layers. A small muscle (arrector pili) attached to the follicle raises the hair to produce "goosebumps" when one is frightened or cold (see **FIG. 4-1**). In animals this is a warning sign and a means of insulation.
- **Nails** develop from a growing region at the proximal end (**FIG. 4-2**). The cuticle, technically named the eponychium (*ep-o-NIK-e-um*), is an extension of the epidermis onto the surface of the nail plate. A lighter region distal to the cuticle is called the lunula because it looks like a half moon. Here the underlying skin is thicker, and blood does not show as much through the nail.



**FIGURE 4-2** Nail structure. **A.** Photograph of a nail, superior view. **B.** Midsagittal section of a fingertip showing the growth region and tissue surrounding the nail plate.

Hair and nails are composed of nonliving material consisting mainly of keratin. Both function in protection.

## Terminology

## Key Terms

The terms listed below are emphasized in this chapter. Knowing them will help you organize and prioritize your learning. These boldface terms are also found, collectively, with all chapter key terms in the Glossary.

### Normal Structure and Function

<b>cutaneous</b> <i>ku-TA-ne-us</i>	Pertaining to the skin (from Latin <i>cutis</i> , meaning “skin”)
<b>derma</b> <i>DER-mab</i>	Skin (from Greek)
<b>dermis</b> <i>DER-mis</i>	The layer of the skin between the epidermis and the subcutaneous tissue; the true skin or corium
<b>epidermis</b> <i>ep-ih-DER-mis</i>	The outermost layer of the skin (from <i>epi-</i> , meaning “upon or over” and <i>derm</i> , meaning “skin”)
<b>hair</b> <i>har</i>	A thread-like keratinized outgrowth from the skin (root: <i>trich/o</i> )
<b>hair follicle</b> <i>FOL-ih-kl</i>	The sheath in which a hair develops
<b>integumentary system</b> <i>in-teg-u-MEN-tab-re</i>	The skin and its associated glands, hair, and nails
<b>keratin</b> <i>KER-ab-tin</i>	A protein that thickens and toughens the skin and makes up hair and nails (root: <i>kerat/o</i> )
<b>melanin</b> <i>MEL-ab-nin</i>	A dark pigment that gives color to the hair and skin and protects the skin against the sun’s radiation (root: <i>melan/o</i> )
<b>nail</b> <i>nale</i>	A plate-like keratinized outgrowth of the skin that covers the dorsal surface of the terminal phalanges (root: <i>onych/o</i> )
<b>sebaceous gland</b> <i>se-BA-shus</i>	A skin gland that produces sebum; usually associated with a hair follicle (root: <i>seb/o</i> )
<b>sebum</b> <i>SE-bum</i>	A fatty secretion of the sebaceous glands that lubricates the hair and skin (root: <i>seb/o</i> )
<b>skin</b>	The tissue that covers the body; the integument (roots: <i>derm/o</i> , <i>dermat/o</i> )
<b>subcutaneous layer</b> <i>sub-ku-TA-ne-us</i>	The layer of tissue beneath the skin; also called the hypodermis
<b>sweat gland</b> <i>swet</i>	A gland that releases a watery fluid (perspiration) to the skin surface in order to cool the body. Certain sweat glands, located mainly in the armpits and groin area, release secretions with some cellular material in response to stress. A sudoriferous ( <i>su-dor-IF-er-us</i> ) gland. (root: <i>hidr/o</i> )

## Roots Pertaining to the Integumentary System

See TABLE 4-1.

Table 4-1		Roots Pertaining to the Skin and Associated Structures	
Root	Meaning	Example	Definition of Example
derm/o, dermat/o	skin	dermabrasion <i>derm-ab-BRA-zhun</i>	surgical procedure used to resurface the skin and remove imperfections
kerat/o	keratin, horny layer of the skin	keratinous <i>keb-RAT-ib-nus</i>	containing keratin; horny
melan/o	dark, black, melanin	melanosome <i>MEL-ab-no-some</i>	a small cellular body that produces melanin
hidr/o	sweat, perspiration	anhidrosis <i>an-bi-DRO-sis</i>	absence of sweating
seb/o	sebum, sebaceous gland	seborrhea <i>seb-or-E-ab</i>	excess flow of sebum (adjective: seborrheic)
trich/o	hair	trichomycosis <i>trik-o-mi-KO-sis</i>	fungal infection of the hair
onych/o	nail	onychia <i>o-NIK-e-ab</i>	inflammation of the nail and nail bed (Note: not an <i>-itis</i> ending)

### Exercise 4-1

Complete the exercise. To check your answers go to Appendix 11.

Identify and define the roots in the following words.

	Root	Meaning of Root
1. hypodermis ( <i>hi-po-DER-mis</i> )	_____	_____
2. seborrheic ( <i>seb-o-RE-ik</i> )	_____	_____
3. hypermelanosis ( <i>hi-per-mel-ab-NO-sis</i> )	_____	_____
4. dyskeratosis ( <i>dis-ker-ab-TO-sis</i> )	_____	_____
5. hypohidrosis ( <i>hi-po-bi-DRO-sis</i> )	_____	_____
6. hypertrichosis ( <i>hi-per-trih-KO-sis</i> )	_____	_____
7. eponychium ( <i>ep-o-NIK-e-um</i> )	_____	_____

Fill in the blanks.

- Dermatopathology (*der-mah-to-pah-THOL-o-je*) is study of diseases of the \_\_\_\_\_.
- Keratolysis (*ker-ab-TOL-ib-sis*) is loosening of the skin's \_\_\_\_\_.
- A melanocyte (*MEL-ab-no-site*) is a cell that produces \_\_\_\_\_.
- Trichoid (*TRIK-oyd*) means resembling a(n) \_\_\_\_\_.
- Onychomycosis (*on-ib-ko-mi-KO-sis*) is a fungal infection of a(n) \_\_\_\_\_.
- Hidradenitis (*hi-drad-eh-NI-tis*) is inflammation of a gland that produces \_\_\_\_\_.
- A hypodermic (*hi-po-DER-mik*) injection is given under the \_\_\_\_\_.

(continued)

## Exercise 4-1 (Continued)

Write words for the following definitions.

15. loosening or separation of the skin \_\_\_\_\_
16. study of the skin and skin diseases \_\_\_\_\_
17. softening of a nail \_\_\_\_\_
18. excess production of sweat \_\_\_\_\_
19. study of the hair \_\_\_\_\_
20. instrument for cutting the skin \_\_\_\_\_
21. formation (-genesis) of keratin \_\_\_\_\_
22. a tumor containing melanin \_\_\_\_\_

Use *-derma* as a suffix meaning “skin” to write words for the following. Use the word part appendices if needed.

23. hardening of the skin \_\_\_\_\_
24. presence of pus in the skin \_\_\_\_\_

## Clinical Aspects of the Skin

Many diseases are manifested by changes in the quality of the skin or by specific lesions. Some types of skin lesions are described and illustrated in **BOX 4-2** and appear later in

photographs of specific skin disorders. The study of the skin and skin diseases is **dermatology**, but careful observation of the skin, hair, and nails should be part of every physical examination. The skin should be examined for color, unusual pigmentation, and lesions. It should be palpated to



### FOR YOUR REFERENCE Types of Skin Lesions

BOX 4-2

Lesion	Description
<b>bull</b> <i>BUL-ah</i>	raised, fluid-filled lesion larger than a vesicle (plural: bullae) (see <b>FIGS. 4-5B</b> and <b>4-7</b> )
<b>fissure</b> <i>FISH-ure</i>	crack or break in the skin
<b>macule</b> <i>MAK-ule</i>	flat, colored spot less than 1 cm in size. A larger spot is called a patch
<b>nodule</b> <i>NOD-ule</i>	solid, raised lesion larger than a papule; often indicative of systemic disease (see <b>FIG. 4-9</b> )
<b>papule</b> <i>PAP-ule</i>	firm, circular, raised surface lesion less than 1 cm in size, such as a pimple (see <b>FIG. 4-8</b> )
<b>plaque</b> <i>plak</i>	superficial, flat, or slightly raised differentiated patch more than 1 cm in diameter (see <b>FIG. 4-6</b> )
<b>pustule</b> <i>PUS-tule</i>	raised pus-filled lesion; often in a hair follicle or sweat pore (see <b>FIG. 4-13</b> )
<b>ulcer</b> <i>UL-ser</i>	lesion resulting from destruction of the skin and perhaps subcutaneous tissue (see <b>FIG. 4-18</b> )
<b>vesicle</b> <i>VES-ih-kl</i>	fluid-filled, raised lesion less than 5 mm in size; a blister or bleb
<b>wheel</b> <i>wele</i>	smooth, rounded, slightly raised area often associated with itching; seen in urticaria (hives), such as that resulting from allergy (see <b>FIG. 4-17</b> )



## HEALTH PROFESSIONS

### Nurse Practitioners

BOX 4-3

A nurse practitioner (NP) is a nurse with a professional degree beyond registered nurse (RN) who provides healthcare services similar to those of a physician. All NPs have a master's degree in nursing and postmaster's, or doctoral education. They can specialize in areas such as acute care, family health, neonatology, or gerontology and medical specialties such as oncology or psychiatry. Their advanced education allows them to independently diagnose and treat patients, order testing, perform minor surgeries, and often prescribe medications. Many NPs practice autonomously, with so-called "full practice authority,"

but most work in collaboration with physicians. They focus not only on treatment of disease but also on disease prevention, patient education, and counseling. Such early intervention and education can lower overall healthcare costs.

NPs are licensed to practice in all U.S. states and must follow the rules and regulations of the state in which they are licensed. In most states, they are able to prescribe medications without a physician's cosignature, and they may bill insurance agencies for services. Their professional organization is the American Academy of Nurse Practitioners at [aanp.org](http://aanp.org).

evaluate its texture, temperature, moisture, firmness, and any tenderness. **BOX 4-3** on nurse practitioners, who, like other healthcare professionals, observe the skin when performing physical examinations.

## WOUNDS

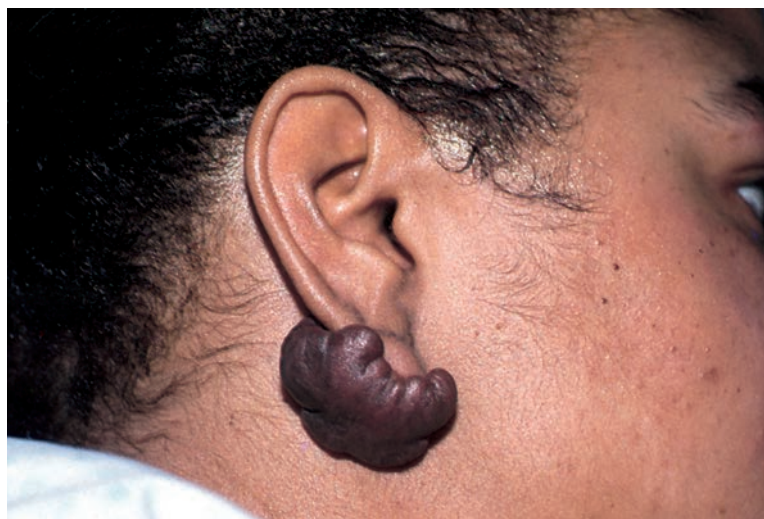Wounds are caused by trauma, as in cases of accidents or attacks, or by surgery and other therapeutic or diagnostic procedures. Wounds may affect not only the injured area but also other body systems. Infection and hemorrhage may complicate wounds, as do **dehiscence**, disruption of the wound layers, and **evisceration**, protrusion of internal organs through the lesion.

As a wound heals, fluid and cells drain from the damaged tissue. This drainage, called **exudate**, may be clear, bloody (sanguinous), or pus-containing (purulent). Tubes may be used to remove exudate from the site of a wound.

Proper wound healing depends on cleanliness and care of the lesion and also on proper circulation, good general

health, and good nutrition. The edges of a deep wound should be joined by sutures, either stitches or, for simple cuts in areas that can be kept dry and immobilized, with a tissue adhesive (glue). Healing is accompanied by scar formation or **cicatrization** (an alternative name for a scar is a **cicatrix**). Permanent scarring is lessened by appropriate wound care, but some people, especially those of African or Asian descent, may tend to form **keloids** because of excess collagen formation during healing (**FIG. 4-3**). Plastic surgery can often improve keloids and other unsightly scars.

Various types of dressings are used to protect wounded areas and promote healing. Vacuum-assisted closure (VAC) uses negative pressure to close the tissues and begin the healing process. Healing may be promoted by **debridement**, the removal of dead or damaged tissue from a wound. **BOX 4-4** mentions the origin of the word debridement and gives the meaning of other medical terms taken from French. Debridement may be accomplished by cutting or scrubbing away the dead tissue or by means of enzymes. A thick, dark crust or scab (**eschar**) may be removed in an **escharotomy**.



**FIGURE 4-3 Keloid.** Marked overgrowth of scar tissue following earlobe piercing.



## FOCUS ON WORDS

### The French Connection

BOX 4-4

Many scientific and medical terms are adapted from foreign languages. Most roots come from Latin and Greek; others are derived from German or French. Sometimes a foreign word is used “as is.” Debridement, removal of dead or damaged tissue from a wound, comes from French, meaning removal of a restraint, such as the bridle of a harness. Also from French, a *contrecoup* injury occurs when the head is thrown forward and back, as in a car accident, and the brain is injured by hitting

the skull on the side opposite the blow. *Contrecoup* in French means “counterblow.” *Tic douloureux*, a disorder causing pain along the path of the trigeminal nerve in the face, translates literally as “painful spasm.” A sound heard while listening to the body with a stethoscope is a *bruit*, a word in French that literally means “noise.” *Lavage*, which refers to irrigation of a cavity, is a French word meaning “washing.”

Deep wounds may require skin grafting for proper healing. Grafts may be a full-thickness skin graft (FTSG), which consists of the epidermis and dermis, or a split-thickness skin graft (STSG), consisting of the epidermis only. Skin is cut for grafting with a **dermatome**.

### Burns

Most burns are caused by hot objects, explosions, or scalding with hot liquids. They may also be caused by electricity, contact with harmful chemicals, or abrasion. Sunlight can also cause severe burns that may result in serious illness. Burns are assessed in terms of the depth of damage and the percentage of body surface area (BSA) involved. Depth of tissue destruction is categorized as follows:

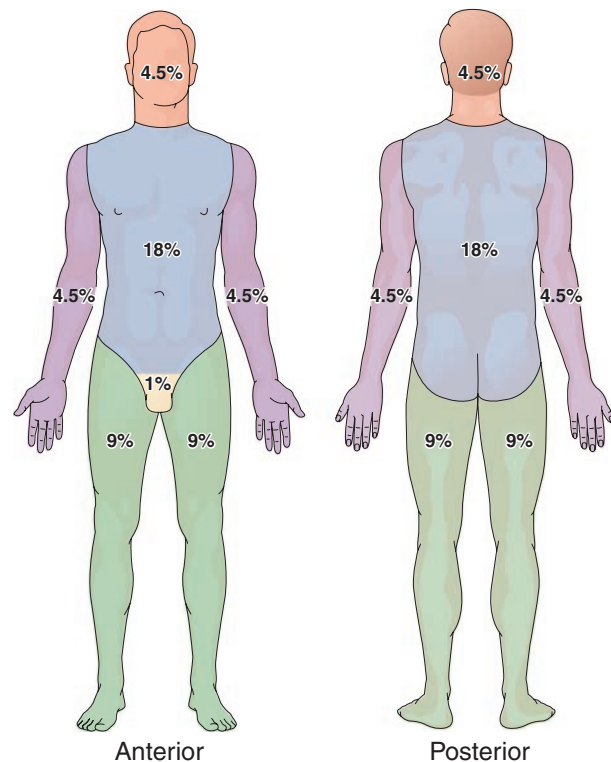
1. *Superficial*—involves the epidermis only. The skin is red and dry; there is minimal pain. Typical causes are mild sunburn and very short heat exposure. This type of burn is also called a first-degree burn. The skin will whiten (blanch) when pressed and then turn bright red again when released.
2. *Superficial partial thickness*—involves the epidermis and a superficial portion of the dermis. The tissue reddens and blisters and is painful, as in cases of severe sunburn or scalding.
3. *Deep partial thickness*—involves the epidermis and both superficial and deeper regions of the dermis. The tissue may be blistered with a weeping surface or dry because of sweat gland damage. These burns may be less painful than superficial burns because of nerve damage. The blisters may fill with blood due to dermal capillary damage. Causes include scalding and exposure to flame or hot grease. Superficial and deep partial thickness burns are also classified as second-degree burns.
4. *Full thickness*—involves the full skin and sometimes subcutaneous tissue and underlying tissues as well. The tissue is broken, dry and pale, or charred. These injuries may require skin grafting and may result in loss of digits or limbs. Full-thickness burns are also classified as third-degree or fourth-degree burns.

The amount of BSA involved in a burn may be estimated by using the **rule of nines**, in which areas of body surface are

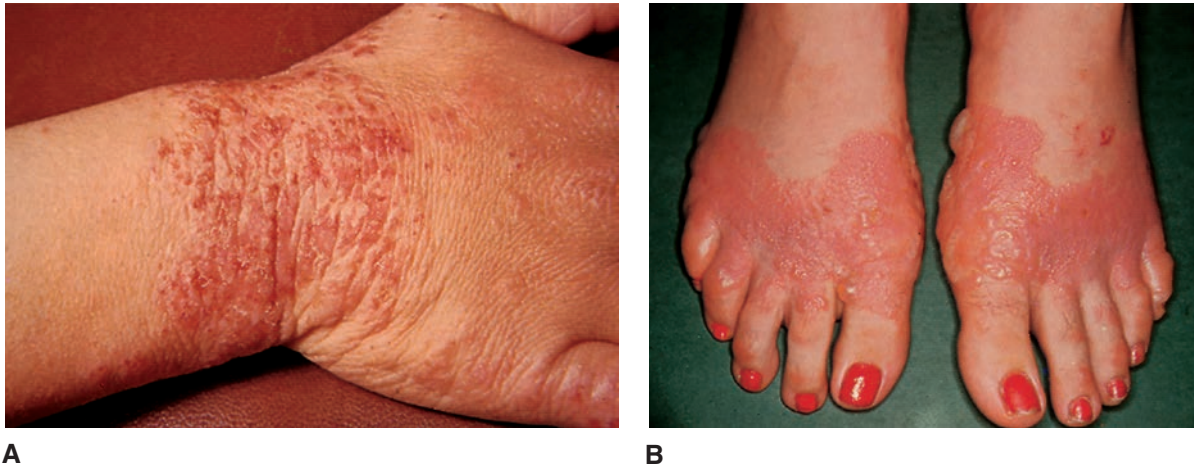
assigned percentages in multiples of nine (**FIG. 4-4**). The more accurate Lund and Browder method divides the body into small areas and estimates the proportion of BSA contributed by each.

Infection is a common complication of burns because a person’s major defense against bacterial invasion is damaged. Respiratory complications and shock may also occur.

Treatment of burns includes respiratory care, administration of fluids, wound care, and pain control. Monitoring for cardiovascular complications, infections, and signs of posttraumatic stress is also important.



**FIGURE 4-4** The rule of nines. Percentage of body surface area (BSA) in the adult is estimated by sectioning the body surface into areas with numerical values related to nine. This method is used to evaluate the extent of skin burns.



**FIGURE 4-5 Dermatitis.** **A.** Atopic dermatitis (eczema) on an infant's wrist. **B.** Contact dermatitis from shoe material. Note several fluid-filled bullae (see **BOX 4-2**).

### Pressure Ulcers

**Pressure ulcers** are necrotic skin lesions that appear where the body rests on skin that covers bony projections, such as the sacrum, heel, elbow, ischial bone of the pelvis, or greater trochanter of the femur (see *ulcer*, **BOX 4-2**, and Kathleen's opening case study). The pressure interrupts circulation, leading to thrombosis, ulceration, and tissue death (necrosis). Poor general health, malnutrition, age, obesity, and infection contribute to the development of pressure ulcers.

Pressure ulcer lesions first appear as redness of the skin. If ignored, they may penetrate the skin and underlying muscle, extending even to bone, and may require months to heal.

Pads or mattresses to relieve pressure, regular cleansing and drying of the skin, frequent change in position, and good nutrition help to prevent pressure ulcers. Other terms for pressure ulcers are *decubitus ulcer* and *bedsore*. Both of these terms refer to lying down in bed, although pressure ulcers may appear in anyone with limited movement, not only those who are confined to bed.

## DERMATITIS

**Dermatitis** is a general term for inflammation of the skin, which may be acute or chronic. Mild forms show **erythema** (redness) and edema and sometimes **pruritus** (itching), but the condition may worsen to include deeper lesions and secondary bacterial infections. A chronic allergic form of this disorder that appears early in childhood is called **atopic dermatitis** or **eczema** (**FIG. 4-5**). Although its exact cause is unknown, atopic dermatitis is made worse by allergies, infection, temperature extremes, and skin irritants. Patients have tried a variety of treatments for this disorder over the years. Clinicians are currently studying biologic drugs targeting specific immune system components that are overproduced in cases of eczema and other allergic disorders.

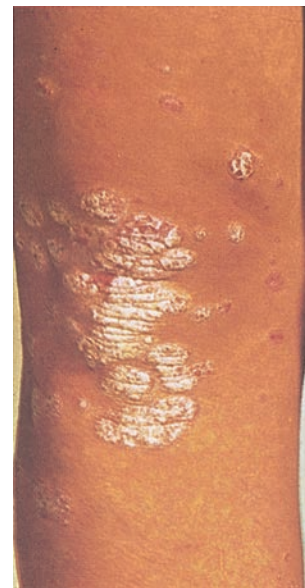Other forms of dermatitis include contact dermatitis, caused by allergens or chemical irritants (see **FIG. 4-5B**); seborrheic dermatitis, which involves areas with many sebaceous glands, such as the scalp and face; and stasis dermatitis, caused by poor circulation.

## PSORIASIS

Psoriasis is a chronic overgrowth (hyperplasia) of the epidermis, producing large, erythematous (red) plaques with silvery scales (**FIG. 4-6**; see also *plaques*, **BOX 4-2**). The cause is unknown, but there is sometimes a hereditary pattern, and autoimmunity may be involved.

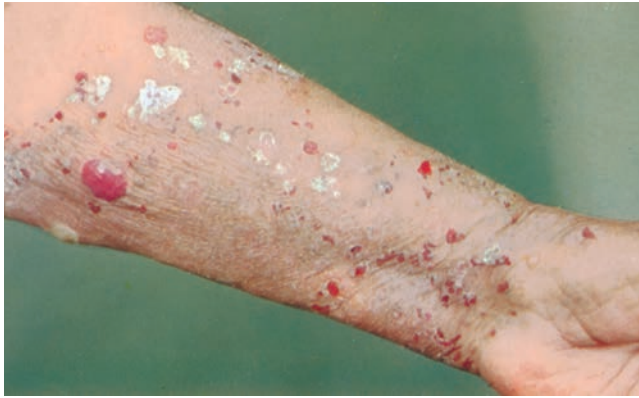Dermatologists treat psoriasis in the following ways depending on severity:

1. Topical agents, including corticosteroids, immunosuppressants, vitamins A and D
2. Phototherapy—exposure to ultraviolet B (UVB) light; administration of the drug psoralen (P) to increase skin sensitivity to light followed by exposure to ultraviolet A (UVA) light; laser treatment
3. Systemic suppression of the immune system



**FIGURE 4-6 Psoriasis.** Plaques with scales seen at the front of the knee (see *plaque*, **BOX 4-2**).





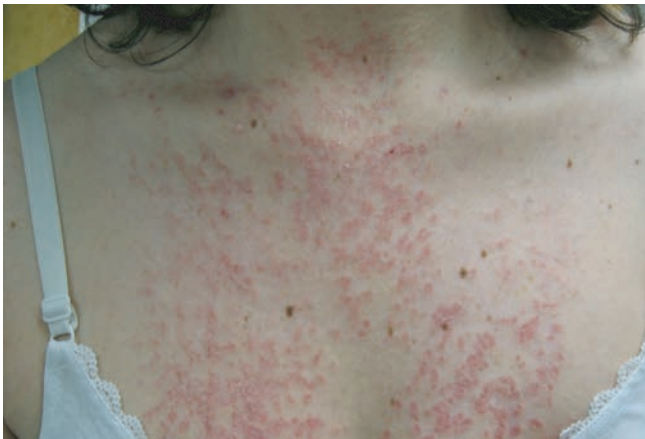**FIGURE 4-7 Pempfigus.** Blisters (bullae) are seen on the forearm (see *bullae*, **BOX 4-2**).

## AUTOIMMUNE DISORDERS

The diseases discussed below are caused, at least in part, by autoimmune reactions. They are diagnosed by biopsy of lesions and by antibody studies.

**Pempfigus** is characterized by the formation of bullae (blisters) in the skin and mucous membranes caused by a separation of epidermal cells from underlying layers (**FIG. 4-7**; see also *bullae*, **BOX 4-2**). Rupture of these lesions leaves deeper skin areas unprotected from infection and fluid loss, much as in cases of burns. The cause is an autoimmune reaction to epithelial cells. Pempfigus is fatal unless treated by suppressing the immune system.

**Lupus erythematosus (LE)** is a chronic inflammatory autoimmune disease of connective tissue. The more widespread form of the disease, systemic lupus erythematosus (SLE), involves the skin and other organs. SLE is more prevalent in women than in men and has a higher incidence among Asians and blacks than among other populations.



**FIGURE 4-8 Discoid (cutaneous) lupus erythematosus.** Erythematous papules and plaques in a typical sun-exposed distribution on the chest (see *plaque*, **BOX 4-2**).

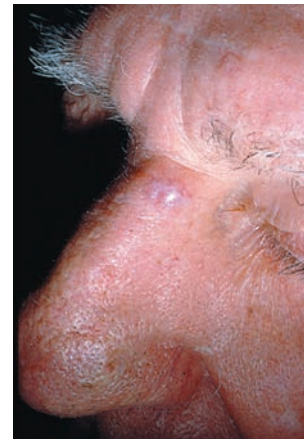The discoid form (DLE) involves only the skin. It is seen as rough, raised, erythematous papules that are worsened by exposure to the ultraviolet radiation in sunlight (**FIG. 4-8**). Lupus skin lesions are confined to the face and scalp and may form a typical butterfly-shaped rash across the nose and cheeks.

**Scleroderma** is a disease of unknown cause that involves thickening and tightening of the skin. There is gradual fibrosis of the dermis because of collagen overproduction. Sweat glands and hair follicles are also involved. A very early sign of scleroderma is Raynaud disease, in which blood vessels in the fingers and toes constrict in the cold, causing numbness, pain, coldness, and tingling. Skin symptoms first appear on the forearms and around the mouth. Internal organs become involved in a diffuse form of scleroderma called progressive systemic sclerosis (PSS).

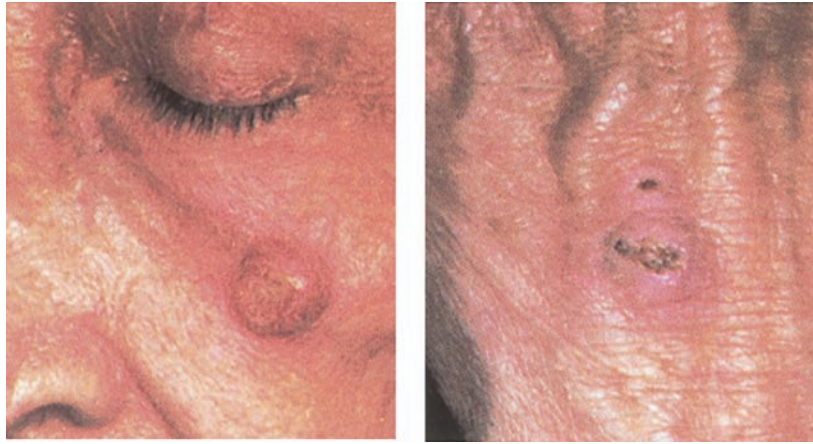## SKIN CANCER

Skin cancer is the most common type of human cancer. Its incidence has been increasing in recent years, mainly because of the mutation-causing effects of sunlight's ultraviolet rays. **Squamous cell carcinoma** and **basal cell carcinoma** are both cancers of epithelial cells. Both appear in areas exposed to sunlight, such as the face and hands. Basal cell carcinoma constitutes more than 75% of all skin cancers. It usually appears as a smooth, pearly papule (**FIG. 4-9**; see also *papules*, **BOX 4-2**). Because these cancers are easily seen and do not metastasize, the cure rate after excision is greater than 95%.

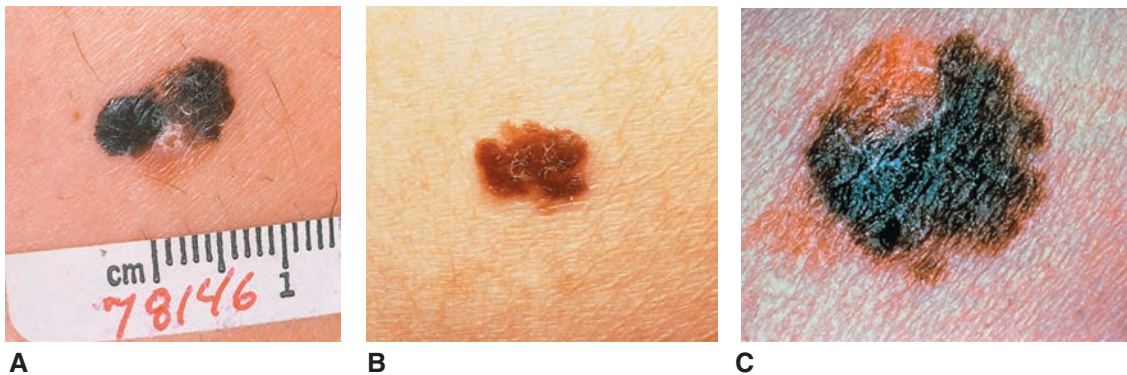
Squamous cell carcinoma appears as a painless, firm, red nodule or plaque that may develop surface scales, ulceration, or crusting (**FIG. 4-10**; see also **BOX 4-2**). This cancer may invade underlying tissue but tends not to metastasize. It is treated by surgical removal and sometimes with x-irradiation or chemotherapy.



**FIGURE 4-9 Basal cell carcinoma.** An initial translucent nodule has spread, leaving a depressed center and a firm, elevated border (see *nodule*, **BOX 4-2**).



**FIGURE 4-10 Squamous cell carcinoma.** Lesions are shown on the face and the back of the hand, sun-exposed areas that are commonly affected.



**FIGURE 4-11 Melanoma.** Several characteristics are shown. **A.** Asymmetry. **B.** Irregular borders. **C.** Variation in color, a diameter greater than 6 mm, and elevation.

Melanoma results from a malignant overgrowth of melanocytes, the pigment-producing cells in the epidermis. It can arise anywhere in the body where melanocytes are found and is the most dangerous form of skin cancer because of its tendency to metastasize. This cancer appears as a lesion that is variable in color with an irregular border (FIG. 4-11). A melanoma shows the so-called ABCDE factors: asymmetry, uneven borders, different colors, diameter of more than 6 millimeters, and evolution (change). The tumor may spread superficially for up to 1 or 2 years before it

begins to invade the deeper skin tissues and to metastasize through blood and lymph. Predisposing factors for melanoma include severe sunburn and frequent tanning. The prognosis for cure is good if the lesion is recognized and removed surgically before it enters this invasive stage.

**Kaposi sarcoma**, once considered rare, is now seen frequently in association with AIDS. It usually appears as distinct brownish areas on the legs. These plaques become raised and firm as the tumor progresses. In those with weakened immune systems, such as patients with AIDS, the cancer can metastasize.

## Terminology

## Key Terms

The terms listed below are emphasized in this chapter. Knowing them will help you organize and prioritize your learning. These boldface terms are also found, collectively, with all chapter key terms in the Glossary.

### Clinical Aspects

**atopic dermatitis**  
*ab-TOP-ik der-mah-TI-tis*

Hereditary, allergic, chronic skin inflammation with pruritus (itching); eczema

**basal cell carcinoma**  
*BA-sal*

An epithelial tumor that rarely metastasizes and has a high cure rate with surgical removal

**cicatritization**  
*sik-ab-trih-ZA-shun*

The process of scar formation; a scar is a cicatrix (*SIK-ab-triks*)

(continued)

## Terminology

## Key Terms (Continued)

<b>debridement</b> <i>da-brede-MON</i>	Removal of dead or damaged tissue, as from a wound
<b>dehiscence</b> <i>de-HIS-ens</i>	Splitting or bursting, as when the layers of a wound separate
<b>dermatitis</b> <i>der-mab-TI-tis</i>	Inflammation of the skin, often associated with redness and itching; may be caused by allergy, irritants (contact dermatitis), or a variety of diseases
<b>dermatology</b> <i>der-mab-TOL-o-je</i>	Study of the skin and diseases of the skin
<b>dermatome</b> <i>DER-mab-tome</i>	Instrument for cutting thin skin sections for grafting
<b>eczema</b> <i>EK-ze-mah</i>	A general term for skin inflammation with redness, lesions, and itching; atopic dermatitis
<b>erythema</b> <i>er-ib-THE-mah</i>	Diffuse redness of the skin
<b>escharotomy</b> <i>es-kar-OT-o-me</i>	Removal of scab tissue resulting from burns or other skin injuries; a scab or crust is an eschar ( <i>ES-kar</i> )
<b>evisceration</b> <i>e-vis-er-A-shun</i>	Protrusion of internal organs (viscera) through an opening, as through a wound
<b>exudate</b> <i>EKS-u-date</i>	Material, which may include fluid, cells, pus, or blood, that escapes from damaged tissue
<b>Kaposi sarcoma</b> <i>KAP-o-se</i>	Cancerous lesion of the skin and other tissues seen most often in patients with AIDS
<b>keloid</b> <i>KE-loyd</i>	A raised, thickened scar caused by tissue overgrowth during scar formation
<b>lupus erythematosus (LE)</b> <i>LU-pus er-ib-the-mab-TO-sis</i>	A chronic, inflammatory, autoimmune disease of connective tissue that often involves the skin; types include the more widespread systemic lupus erythematosus (SLE) and a discoid form (DLE) that involves only the skin
<b>melanoma</b> <i>mel-ab-NO-mah</i>	A metastasizing pigmented skin tumor that arises from melanocytes; malignant melanoma
<b>pemphigus</b> <i>PEM-fih-gus</i>	An autoimmune disease of the skin characterized by sudden, intermittent formation of bullae (blisters); may be fatal if untreated
<b>pressure ulcer</b>	An ulcer caused by pressure to an area of the body, as from a bed or chair; decubitus ( <i>de-KU-bih-tus</i> ) ulcer, bedsore, pressure sore
<b>pruritus</b> <i>pru-RI-tus</i>	Severe itching
<b>psoriasis</b> <i>so-RI-ab-sis</i>	A chronic hereditary dermatitis with red lesions covered by silvery scales
<b>rule of nines</b>	A method for estimating the extent of body surface area involved in a burn by assigning percentages in multiples of nine to various body regions
<b>scleroderma</b> <i>sklere-o-DER-mah</i>	A chronic disease that is characterized by thickening and tightening of the skin and that often involves internal organs in a form called progressive systemic sclerosis (PSS)
<b>squamous cell carcinoma</b> <i>SKWA-mus</i>	An epidermal cancer that may invade deeper tissues but tends not to metastasize

## Terminology

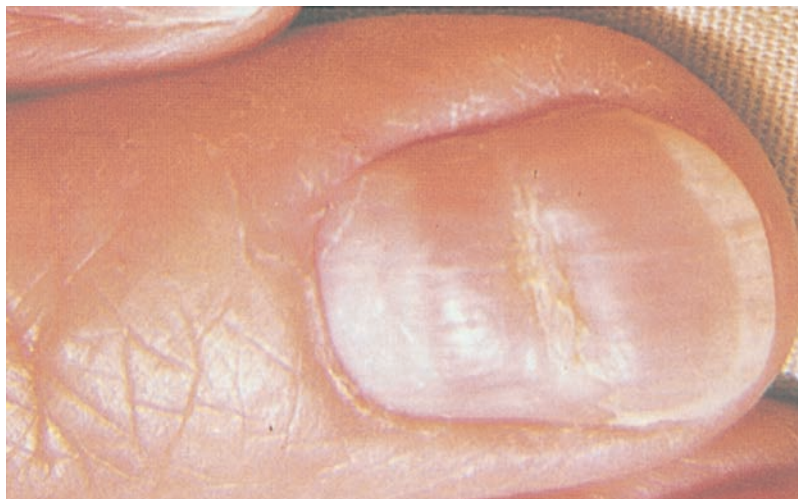## Enrichment Terms

The terms listed below expand on the key terms to increase your knowledge of this chapter topic.

## Symptoms and Conditions

<b>acne</b> <i>AK-ne</i>	An inflammatory disease of the sebaceous glands and hair follicles usually associated with excess sebum secretion; acne vulgaris
<b>actinic</b> <i>ak-TIN-ik</i>	Pertaining to the effects of radiant energy, such as sunlight, ultraviolet light, and x-rays
<b>albinism</b> <i>AL-bin-izm</i>	A hereditary lack of pigment in the skin, hair, and eyes
<b>alopecia</b> <i>al-o-PE-she-ab</i>	Absence or loss of hair; baldness
<b>Beau lines</b> <i>bo</i>	White lines across the fingernails; usually a sign of systemic disease or injury ( <b>FIG. 4-12</b> )
<b>bromhidrosis</b> <i>brom-hi-DRO-sis</i>	Sweat that has a foul odor because of bacterial decomposition; also spelled bromidrosis ( <i>bro-mih-DRO-sis</i> )
<b>carbuncle</b> <i>CAR-bung-kl</i>	A localized infection of the skin and subcutaneous tissue, usually caused by staphylococcus, and associated with pain and discharge of pus
<b>comedo</b> <i>KOM-eh-do</i>	A plug of sebum, often containing bacteria, in a hair follicle; a blackhead (plural: comedones)
<b>dermatophytosis</b> <i>der-mah-to-fi-TO-sis</i>	Fungal infection of the skin, especially between the toes; athlete's foot (root <i>phyt/o</i> means "plant")
<b>diaphoresis</b> <i>di-ab-fo-RE-sis</i>	Profuse sweating
<b>dyskeratosis</b> <i>dis-ker-ab-TO-sis</i>	Any abnormality in keratin formation in epithelial cells
<b>ecchymosis</b> <i>ek-ib-MO-sis</i>	A collection of blood under the skin caused by leakage from small vessels
<b>erysipelas</b> <i>er-ib-SIP-eh-las</i>	An acute infectious skin disease with localized redness and swelling and systemic symptoms

(continued)

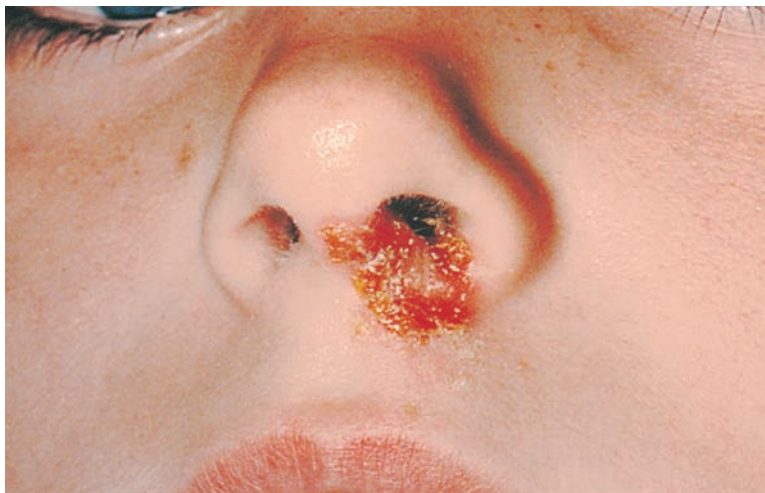

**FIGURE 4-12 Beau lines.** These transverse depressions in the nails are associated with acute severe illness.

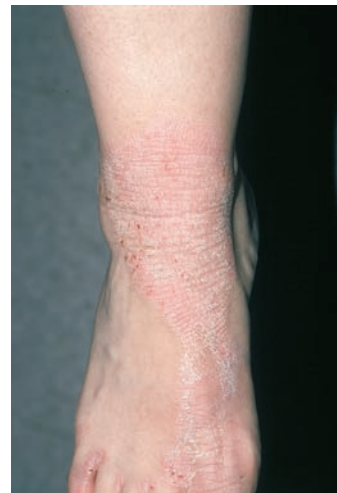## Terminology

## Enrichment Terms (Continued)

<b>erythema nodosum</b> <i>no-DO-sum</i>	Inflammation of subcutaneous tissues resulting in tender, erythematous nodules; may be an abnormal immune response to a systemic disease, an infection, or a drug
<b>exanthema</b> <i>ek-zan-THE-mah</i>	Any cutaneous eruption that accompanies a disease, such as measles; a rash
<b>excoriation</b> <i>eks-ko-re-A-shun</i>	Lesion caused by scratching or abrasion
<b>folliculitis</b> <i>fo-lik-u-LI-tis</i>	Inflammation of a hair follicle
<b>furuncle</b> <i>FU-rung-kl</i>	A painful skin nodule caused by staphylococci that enter through a hair follicle; a boil
<b>hemangioma</b> <i>he-man-je-O-mah</i>	A benign tumor of blood vessels; in the skin, called birthmarks or port wine stains
<b>herpes simplex</b> <i>HER-peze SIM-pleks</i>	A group of acute infections caused by herpes simplex virus; type I herpes simplex virus produces fluid-filled vesicles, usually on the lips, after fever, sun exposure, injury, or stress, also called cold sore or fever blister; type II infections usually involve the genital organs
<b>hirsutism</b> <i>HIR-su-tizm</i>	Excessive growth of hair
<b>ichthyosis</b> <i>ik-the-O-sis</i>	A dry, scaly condition of the skin (from the root <i>ichthyo</i> , meaning “fish”)
<b>impetigo</b> <i>im-peh-TI-go</i>	A bacterial skin infection with pustules that rupture and form crusts; most commonly seen in children, usually on the face ( <b>FIG. 4-13</b> ; see also <i>pustules</i> , <b>BOX 4-2</b> )
<b>keratosis</b> <i>ker-ab-TO-sis</i>	Any skin condition marked by thickened or horny growth; seborrheic keratosis is a benign tumor, yellow or light brown in color, that appears in the elderly; actinic keratosis is caused by exposure to sunlight and may lead to squamous cell carcinoma
<b>lichenification</b> <i>li-ken-ih-fib-KA-shun</i>	Thickened marks caused by chronic rubbing, as seen in atopic dermatitis (a lichen is a flat, branching type of plant that grows on rocks and bark) ( <b>FIG. 4-14</b> )

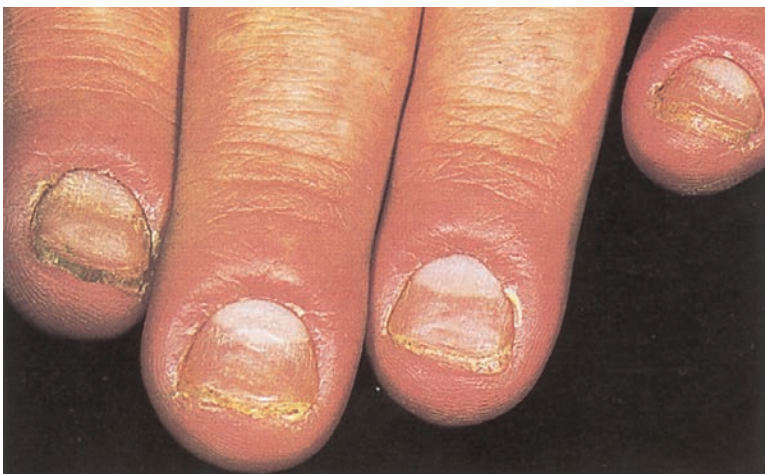

**FIGURE 4-13 Impetigo.** This bacterial skin infection, seen here on the nostril, causes pustules that rupture and form crusts (see *pustule*, **BOX 4-2**).

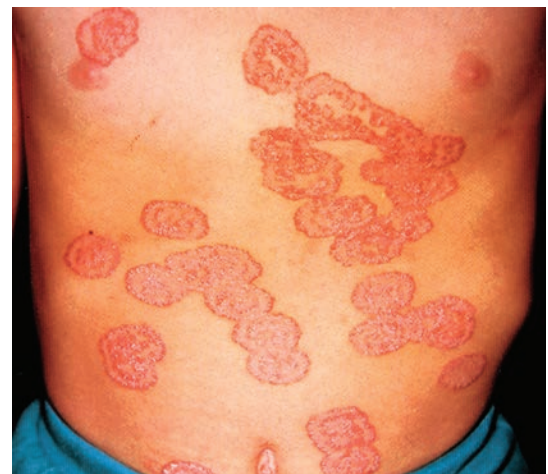

**FIGURE 4-14 Lichenification.** Skin shows thickened areas from chronic rubbing, as seen in atopic dermatitis.

Terminology	Enrichment Terms (Continued)
<b>mycosis fungoides</b> <i>mi-KO-sis fun-GOY-deze</i>	A rare malignant disease that originates in the skin and involves the internal organs and lymph nodes; there are large, painful, ulcerating tumors
<b>nevus</b> <i>NE-vus</i>	A defined discoloration of the skin; a congenital vascular skin tumor; a mole, birthmark
<b>paronychia</b> <i>par-o-NIK-e-ab</i>	Infection around a nail ( <b>FIG. 4-15</b> ) caused by bacteria or fungi; may affect multiple nails
<b>pediculosis</b> <i>peh-dik-u-LO-sis</i>	Infestation with lice
<b>petechiae</b> <i>pe-TE-ke-e</i>	Flat, pinpoint, purplish-red spots caused by bleeding within the skin or mucous membrane (singular: petechia)
<b>photosensitization</b> <i>fo-to-sen-sib-tih-ZA-shun</i>	Sensitization of the skin to light, usually from the action of drugs, plant products, or other substances
<b>purpura</b> <i>PUR-pu-rah</i>	A condition characterized by hemorrhages into the skin and other tissues
<b>rosacea</b> <i>ro-ZA-she-ab</i>	A condition of unknown cause involving redness of the skin, pustules, and overactivity of sebaceous glands, mainly on the face
<b>scabies</b> <i>SKA-beze</i>	A highly contagious skin disease caused by a mite
<b>senile lentigines</b> <i>len-TIJ-ih-neze</i>	Brown macules that appear on sun-exposed skin in adults; liver spots
<b>shingles</b>	An acute eruption of vesicles along the path of a nerve; herpes zoster ( <i>HER-peze ZOS-ter</i> ); caused by the same virus that causes chickenpox
<b>tinea</b> <i>TIN-e-ab</i>	A fungal skin infection; ringworm ( <b>FIG. 4-16</b> )
<b>tinea versicolor</b> <i>VER-sib-kol-or</i>	Superficial chronic fungal infection that causes varied skin pigmentation

*(continued)*

**FIGURE 4-15 Paronychia.** Infection and inflammation of the proximal and lateral nail folds is shown.

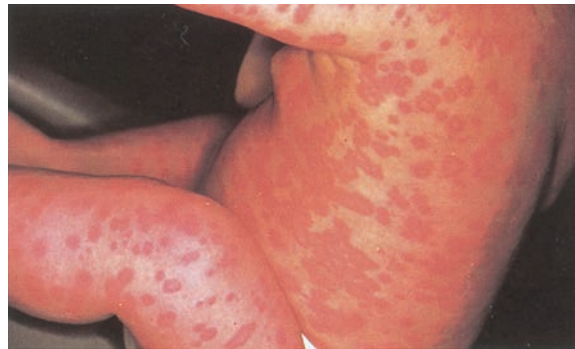

**FIGURE 4-16 Tinea corporis.** Ringworm infection seen on the body.

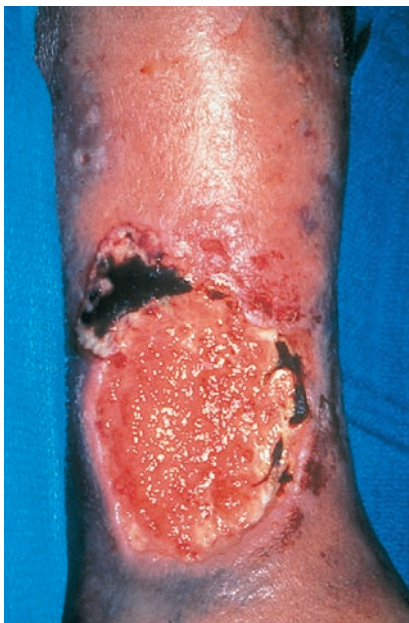## Terminology

## Enrichment Terms (Continued)

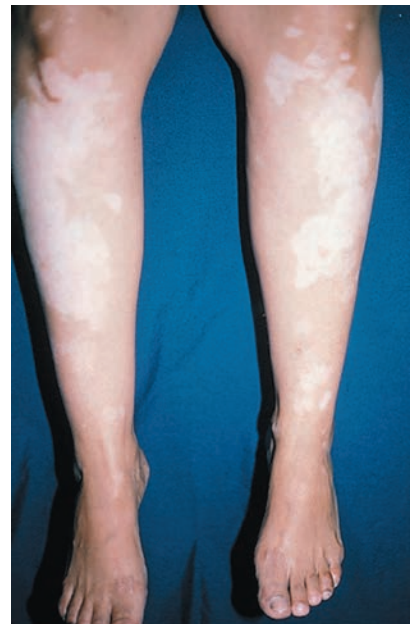
<b>urticaria</b> <i>ur-tih-KAR-e-ab</i>	A skin reaction marked by temporary, smooth, raised areas (wheals) associated with itching; hives ( <b>FIG. 4-17</b> ; see also <i>wheals</i> , <b>BOX 4-2</b> )
<b>venous stasis ulcer</b>	Ulcer caused by venous insufficiency and stasis of venous blood; usually forms near the ankle ( <b>FIG. 4-18</b> ; see also <i>ulcer</i> , <b>BOX 4-2</b> )
<b>verruca</b> <i>ver-RU-kab</i>	A small, usually benign epidermal tumor caused by human papilloma virus (HPV); a wart
<b>vitiligo</b> <i>vit-ib-LI-go</i>	Patchy disappearance of pigment in the skin; leukoderma ( <b>FIG. 4-19</b> )
<b>xeroderma pigmentosum</b> <i>ze-ro-DER-mah pig-men-TO-sum</i>	A fatal hereditary disease that begins in childhood with skin discolorations and ulcers and muscle atrophy; there is increased sensitivity to the sun and increased susceptibility to cancer



**FIGURE 4-17 Urticaria (hives).** Wheals associated with drug allergy are shown in an infant (see *wheel*, **BOX 4-2**).



**FIGURE 4-18 Venous stasis ulcer.** Lesion on the ankle caused by venous insufficiency and blood stasis (see *ulcer*, **BOX 4-2**).



**FIGURE 4-19 Vitiligo.** Depigmented macules appear on the skin and may merge into large areas that lack melanin. The brown pigment seen in the illustration is the person's normal skin color; the pale areas are caused by vitiligo.

## Terminology

## Enrichment Terms (Continued)

## Diagnosis and Treatment

<b>aloe</b> <i>AH-lo</i>	A gel from leaves of the plant <i>Aloe vera</i> that is used in treatment of burns and minor skin irritations
<b>antipruritic</b> <i>an-te-pru-RIT-ik</i>	Agent that prevents or relieves itching
<b>cautery</b> <i>KAW-ter-e</i>	Destruction of tissue by physical or chemical means; cauterization; also the instrument or chemical used for this purpose
<b>dermabrasion</b> <i>DERM-ab-bra-zhun</i>	A plastic surgical procedure for removing scars or birthmarks by chemical or mechanical destruction of epidermal tissue
<b>dermatoplasty</b> <i>DER-mab-to-plas-te</i>	Transplantation of human skin; skin grafting
<b>diascopy</b> <i>di-AS-ko-pe</i>	Examination of skin lesions by pressing a glass plate against the skin
<b>fulguration</b> <i>ful-gu-RA-shun</i>	Destruction of tissue by high-frequency electric sparks
<b>skin turgor</b> <i>TUR-gor</i>	Resistance of the skin to deformation; evidenced by the ability of the skin to return to position when pinched; skin turgor is a measure of the skin's elasticity and state of hydration; typically declines with age and when decreased may also be a sign of poor nutrition
<b>Wood lamp</b>	An ultraviolet light used to diagnose fungal infections

## Terminology

## Abbreviations

The abbreviations listed below are emphasized in this chapter. These are also found, collectively, with all chapter abbreviations in Appendix 2.

<b>ABCDE</b>	Asymmetry, uneven borders, different colors, diameter of more than 6 millimeters, and evolution (change).	<b>SCLE</b>	Subacute cutaneous lupus erythematosus
<b>BSA</b>	Body surface area	<b>SLE</b>	Systemic lupus erythematosus
<b>DLE</b>	Discoid lupus erythematosus	<b>SPF</b>	Sun protection factor
<b>FTSG</b>	Full-thickness skin graft	<b>STSG</b>	Split-thickness skin graft
<b>LE</b>	Lupus erythematosus	<b>UV</b>	Ultraviolet
<b>PSS</b>	Progressive systemic sclerosis	<b>UVA</b>	Ultraviolet A
<b>PUVA</b>	Psoralen ultraviolet A	<b>UVB</b>	Ultraviolet B
		<b>VAC</b>	Vacuum-assisted closure



## Case Study Revisited

### Kathleen's Follow-Up

Kathleen made progress while in the long-term care facility. She also worked with a physical therapist (PT) and occupational therapist (OT) and began performing simple activities of daily living (ADL). The therapists performed range of motion (ROM) activities on a regular schedule to both the stroke-affected and unaffected sides. With the increase in activity and improved nutrition, Kathleen's circulation and skin condition

improved. She also showed less confusion. Kathleen's daughter visited her frequently. She was thus able to observe and assist with her mother's activities and receive instruction for her care firsthand. Goals were set to evaluate Kathleen's progress. Discharge plans were made to have her return home at an appropriate time. In expectation of her mother's return, her daughter had made arrangements for a home healthcare worker to assist in her care.

These questions test your understanding of the content introduced in this chapter. Follow the instructions for each exercise and check your answers in Appendix 11.

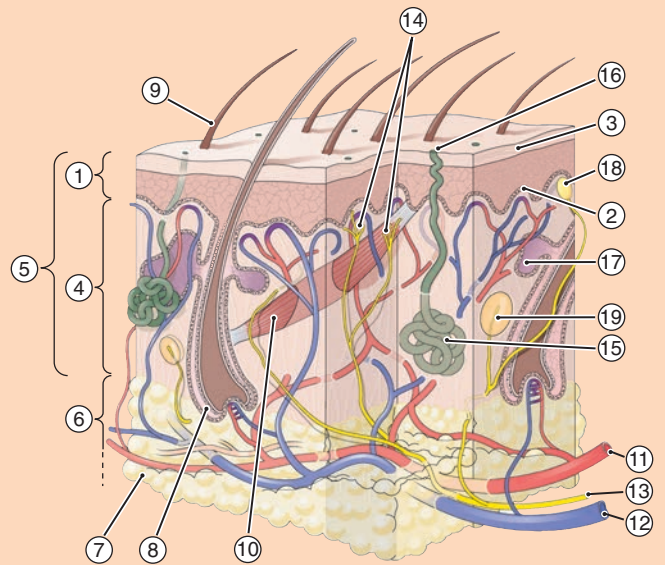
**LABELING EXERCISE**

**CROSS-SECTION OF THE SKIN**

*Write the name of each numbered part on the corresponding line of the answer sheet.*

- |                               |                                |
|-------------------------------|--------------------------------|
| Adipose tissue                | Pressure receptor              |
| Arrector pili muscle          | Sebaceous (oil) gland          |
| Artery                        | Skin                           |
| Dermis                        | Stratum basale (growing layer) |
| Epidermis                     | Stratum corneum                |
| Hair                          | Subcutaneous layer             |
| Hair follicle                 | Sweat gland                    |
| Nerve                         | Touch receptor                 |
| Nerve endings                 | Vein                           |
| Pore (opening of sweat gland) |                                |

1. \_\_\_\_\_
2. \_\_\_\_\_
3. \_\_\_\_\_
4. \_\_\_\_\_
5. \_\_\_\_\_
6. \_\_\_\_\_
7. \_\_\_\_\_
8. \_\_\_\_\_
9. \_\_\_\_\_
10. \_\_\_\_\_
11. \_\_\_\_\_
12. \_\_\_\_\_
13. \_\_\_\_\_



14. \_\_\_\_\_
15. \_\_\_\_\_
16. \_\_\_\_\_
17. \_\_\_\_\_
18. \_\_\_\_\_
19. \_\_\_\_\_

## TERMINOLOGY

### MATCHING

- |                          |  |
|--------------------------|--|
| _____ 1. cicatrization   | a. redness of the skin                       |
| _____ 2. erythema        | b. severe itching                            |
| _____ 3. eczema          | c. material that escapes from damaged tissue |
| _____ 4. pruritus        | d. atopic dermatitis                         |
| _____ 5. exudate         | e. scar formation                            |
| _____ 6. stratum basale  | a. oily skin secretion                       |
| _____ 7. hypodermis      | b. sheath that contains a hair               |
| _____ 8. sebum           | c. subcutaneous layer                        |
| _____ 9. stratum corneum | d. growing layer of the epidermis            |
| _____ 10. follicle       | e. thickened layer of the epidermis          |

### Enrichment Terms

- |                        |   |
|------------------------|---|
| _____ 11. alopecia     | a. profuse sweating   |
| _____ 12. excoriation  | b. lesion caused by scratching or abrasion                    |
| _____ 13. nevus        | c. mole or birthmark  |
| _____ 14. diaphoresis  | d. blackhead  |
| _____ 15. comedo       | e. baldness   |
| _____ 16. rosacea      | a. condition causing redness and pustules, mainly on the face |
| _____ 17. tinea        | b. fungal skin infection                                      |
| _____ 18. bromhidrosis | c. infection around a nail                                    |
| _____ 19. albinism     | d. lack of skin pigmentation                                  |
| _____ 20. paronychia   | e. sweat with a foul odor                                     |

### FILL IN THE BLANKS

Complete the sentence with the correct term(s).

21. The main pigment in skin is \_\_\_\_\_.
22. The oil-producing glands of the skin are the \_\_\_\_\_.
23. A sudoriferous gland produces \_\_\_\_\_.
24. The adjective *cutaneous* refers to the \_\_\_\_\_.
25. Dermabrasion (*der-mah-BRA-zhun*) is surface scraping of the \_\_\_\_\_.
26. The protein that thickens the skin and makes up hair and nails is \_\_\_\_\_.
27. Schizonychia (*skiz-o-NIK-e-ah*) is splitting of a(n) \_\_\_\_\_.

Refer to Kathleen's opening case study.

28. Two other terms for a pressure ulcer are \_\_\_\_\_.
29. When the nurse palpated Kathleen's lesion, she used her sense of \_\_\_\_\_.
30. Part of Kathleen's treatment was removal of dead skin from her lesion. This process is called \_\_\_\_\_.
31. The abbreviation FTSG refers to a(n) \_\_\_\_\_.
32. A term for lack of blood (root: hem/o) to tissue is \_\_\_\_\_.
33. The medical specialist who treated Kathleen's deteriorating pressure ulcer was a(n) \_\_\_\_\_.

**DEFINITIONS**

*Define the following words.*

34. xeroderma (*ze-ro-DER-mah*) \_\_\_\_\_
35. dyskeratosis (*dis-ker-ah-TO-sis*) \_\_\_\_\_
36. seborrhea (*seb-or-E-ah*) \_\_\_\_\_
37. pachyderma (*pak-e-DER-mah*) \_\_\_\_\_
38. onychia (*o-NIK-e-ah*) \_\_\_\_\_
39. hypermelanosis (*hi-per-mel-ah-NO-sis*) \_\_\_\_\_
40. percutaneous (*per-ku-TA-ne-us*) \_\_\_\_\_
41. keratogenic (*ker-ah-to-JEN-ik*) \_\_\_\_\_

*Write words for the following definitions.*

42. pertaining to discharge of sebum \_\_\_\_\_
43. excess production of keratin \_\_\_\_\_
44. instrument for cutting the skin \_\_\_\_\_
45. tumor containing melanin \_\_\_\_\_
46. cell that produces melanin \_\_\_\_\_
47. hardening of the skin \_\_\_\_\_

*Use the word hidrosis (sweating) as an ending for words with the following meanings.*

48. absence of sweating \_\_\_\_\_
49. excess sweating \_\_\_\_\_
50. excretion of colored (chrom/o) sweat \_\_\_\_\_

**PLURALS**

*Give the plural form for the following key and enrichment terms.*

51. bulla \_\_\_\_\_
52. ecchymosis \_\_\_\_\_
53. fungus \_\_\_\_\_
54. comedo \_\_\_\_\_
55. staphylococcus \_\_\_\_\_

**TRUE-FALSE**

Examine the following statements. If the statement is true, write T in the first blank. If the statement is false, write F in the first blank, and correct the statement by replacing the underlined word in the second blank.

	True or False	Correct Answer
56. The skin and its associated structures make up the <u>integumentary system</u> .	_____	_____
57. The root trich/o refers to <u>hair</u> .	_____	_____
58. The <u>dermis</u> is between the epidermis and the subcutaneous layer.	_____	_____
59. A <u>cicatrix</u> is a scar.	_____	_____
60. Hirsutism is excess growth of <u>nails</u> .	_____	_____

**WORD BUILDING**

Write a word for the following definitions using the word parts provided. Each word part can be used more than once.

-lysis   onych/o   -sis   myc/o   path/o   dermat/o   -y   log/o   -oid   trich/o

61. loosening or separation of the skin \_\_\_\_\_
62. fungal infection of a nail \_\_\_\_\_
63. resembling a hair \_\_\_\_\_
64. study of hair \_\_\_\_\_
65. loosening of a nail \_\_\_\_\_
66. like or resembling skin \_\_\_\_\_
67. any disease of a nail \_\_\_\_\_
68. fungal infection of the hair \_\_\_\_\_
69. any disease of the skin \_\_\_\_\_
70. study and treatment of the skin \_\_\_\_\_

**ELIMINATIONS**

In each of the sets below, underline the word that does not fit in with the rest, and explain the reason for your choice.

71. nodule — vesicle — keloid — macule — papule
- \_\_\_\_\_

72. impetigo — escharotomy — psoriasis — dermatitis — pemphigus
- \_\_\_\_\_

73. SLE — PSS — SCLE — BSA — DLE
- \_\_\_\_\_

**WORD ANALYSIS**

Define the following words, and give the meaning of the word parts in each. Use a dictionary if necessary.

74. dermatophytosis (*der-mah-to-fi-TO-sis*)

- a. dermat/o \_\_\_\_\_
- b. phyt/o \_\_\_\_\_
- c. -sis \_\_\_\_\_

75. hidradenoma (*hi-drad-eh-NO-mah*)

- a. hidr/o \_\_\_\_\_
- b. aden/o \_\_\_\_\_
- c. -oma \_\_\_\_\_

76. onychocryptosis (*on-ih-ko-krip-TO-sis*)

- a. onych/o \_\_\_\_\_
- b. crypt/o \_\_\_\_\_
- c. -sis \_\_\_\_\_

77. achromotrichia (*ah-kro-mo-TRIK-e-ah*)

- a. a- \_\_\_\_\_
- b. chrom/o \_\_\_\_\_
- c. trich/o \_\_\_\_\_
- d. -ia \_\_\_\_\_

# Additional Case Studies

## Case Study 4-1: Basal Cell Carcinoma

Joanne, a 32 y/o fitness instructor, had noticed a “tiny hard lump” at the base of her left nostril while cleansing her face. The lesion had been present for about 2 months when she consulted a dermatologist. She had recently moved north from Florida, where she had worked as a lifeguard. She thought the lump might have been triggered by the regular tanning salon sessions she had used to retain her tan because it did not resemble the acne pustules, blackheads, or resulting scars of her adolescent years. Although dermabrasion had removed the obvious acne scars and left several areas of dense skin, this lump was brown-pigmented and different. Joanne was afraid

it might be a malignant melanoma. On examination, the dermatologist noted a small pearly-white nodule at the lower portion of the left ala (outer flared portion of the nostril). There were no other lesions on her face or neck.

A plastic surgeon excised the lesion and was able to reapproximate the wound edges without a full-thickness skin graft (FTSG). The pathology report identified the lesion as a basal cell carcinoma with clean margins of normal skin and subcutaneous tissue and stated that the entire lesion had been excised. Joanne was advised to wear SPF 30 sun protection on her face at all times and to avoid excessive sun exposure and tanning salons.

### Case Study 4-1 Questions

Follow the instructions for each question and check your answers in Appendix 11.

**Multiple Choice.** Select the best answer, and write the letter of your choice to the left of each number.

- |  |  |
|--|--|
| <p>_____ 1. Joanne’s basal cell carcinoma may have been caused by chronic exposure to the sun and use of an ultraviolet tanning bed. The scientific explanation for this is the</p> <ul style="list-style-type: none"><li>a. autoimmune response</li><li>b. actinic effect</li><li>c. allergic reaction</li><li>d. sunblock tanning lotion theory</li></ul> <p>_____ 2. The characteristic pimples of adolescent acne are whiteheads and blackheads. The medical terms for these lesions are</p> <ul style="list-style-type: none"><li>a. vesicles and macules</li><li>b. pustules and blisters</li><li>c. pustules and comedones</li><li>d. furuncles and sebaceous cysts</li></ul> | <p>_____ 3. Which skin cancer is an overgrowth of pigment-producing epidermal cells?</p> <ul style="list-style-type: none"><li>a. basal cell carcinoma</li><li>b. Kaposi sarcoma</li><li>c. cutaneous lymphoma</li><li>d. melanoma</li></ul> <p>_____ 4. Basal cell carcinoma involves</p> <ul style="list-style-type: none"><li>a. subcutaneous tissue</li><li>b. hair follicles</li><li>c. connective tissue</li><li>d. epithelial cells</li></ul> |
|--|--|

Write terms from the case study with the following meanings.

- 5. skin sanding procedure \_\_\_\_\_
- 6. a solid raised lesion larger than a papule \_\_\_\_\_
- 7. physician who cares for patients with skin diseases \_\_\_\_\_
- 8. layer of connective tissue and fat beneath the dermis \_\_\_\_\_

Define the following abbreviations. See Appendix 2 if needed.

- 9. FTSG \_\_\_\_\_
- 10. SPF \_\_\_\_\_

## Case Study 4-2: Cutaneous Lymphoma

Laurie, a 52 y/o female research chemist, has had a history of T-cell lymphoma for 8 years. She was initially treated with systemic chemotherapy with methotrexate, until she developed mouth ulcers. Continued therapy with topical chemotherapeutic agents brought measurable improvement. She also had a history of hidradenitis.

A recent physical examination showed diffuse erythroderma with scaling and hyperkeratosis, plus alopecia. She had painful leukoplakia and ulcerations

of the mouth and tongue. Laurie was hospitalized and given two courses of topical chemotherapy. She was referred to dental medicine for treatment of the oral lesions and was discharged in stable condition with an appointment for follow-up in 4 weeks. Her discharge medications included the application of 2% hydrocortisone ointment to the affected lesions hs, Keralyt gel bid for the hyperkeratosis, and Dyclone and Benadryl for her stomatitis prn.

### Case Study 4-2 Questions

Follow the instructions for each question and check your answers in Appendix 11.

**Multiple Choice.** Select the best answer, and write the letter of your choice to the left of each number.

- |  |   |
|--|---|
| <p>_____ 1. Hidradenitis is inflammation of a</p> <ul style="list-style-type: none"> <li>a. sweat gland</li> <li>b. salivary gland</li> <li>c. sebaceous gland</li> <li>d. meibomian gland</li> </ul> <p>_____ 2. Leukoplakia is</p> <ul style="list-style-type: none"> <li>a. baldness</li> <li>b. ulceration</li> <li>c. formation of white patches in the mouth</li> <li>d. formation of yellow patches on the skin</li> </ul> <p>_____ 3. Hydrocortisone is a(n)</p> <ul style="list-style-type: none"> <li>a. vitamin</li> <li>b. steroid</li> <li>c. analgesic</li> <li>d. diuretic</li> </ul> | <p>_____ 4. An example of a topical drug is a</p> <ul style="list-style-type: none"> <li>a. systemic chemotherapeutic agent</li> <li>b. drug derived from rainforest plants</li> <li>c. skin ointment</li> <li>d. Benadryl capsule, 25 mg</li> </ul> <p>_____ 5. Stomatitis, a common side effect of systemic chemotherapy, is an inflammatory condition of the</p> <ul style="list-style-type: none"> <li>a. mouth</li> <li>b. stomach</li> <li>c. teeth and hair</li> <li>d. debridement</li> </ul> |
|--|---|

Write terms from the case study with the following meanings.

6. diffuse redness of the skin \_\_\_\_\_
7. increased production of keratin in the skin \_\_\_\_\_

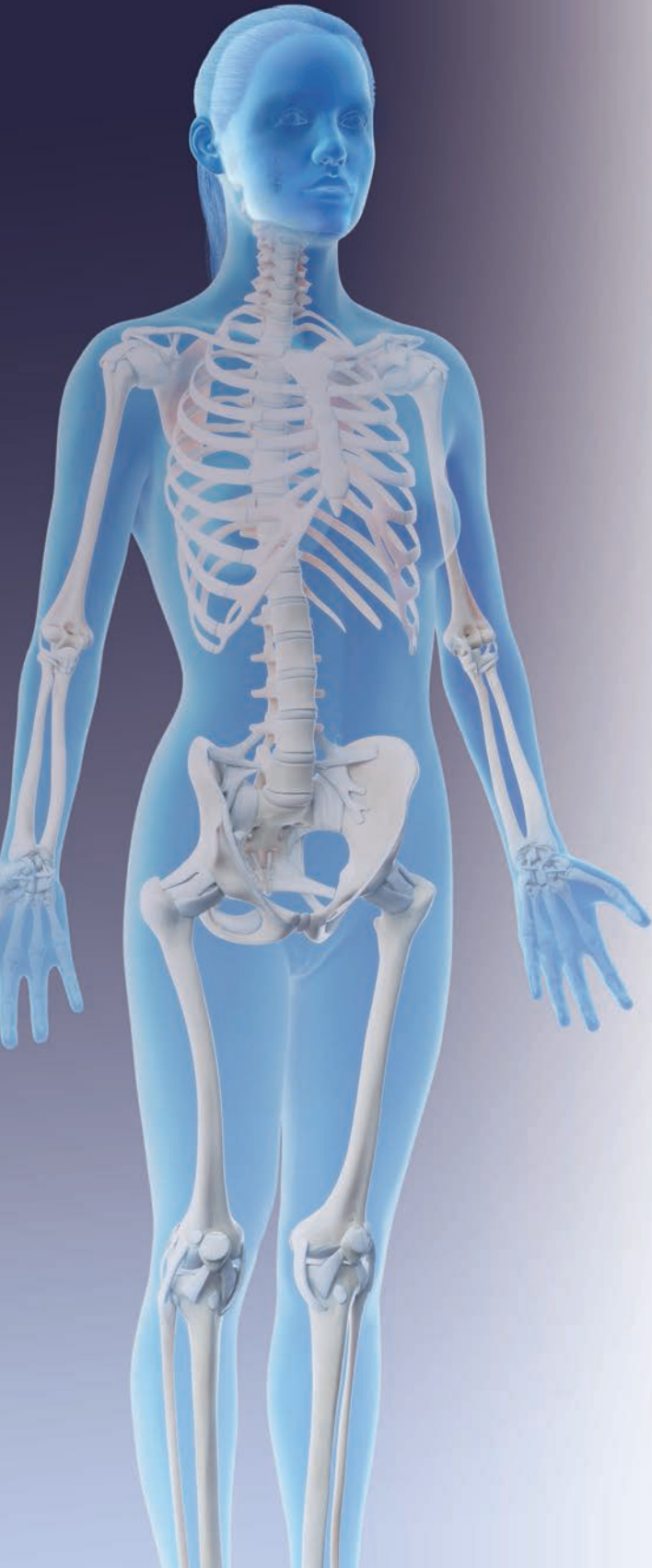Define the following abbreviations. See Appendix 2 if needed.

8. hs \_\_\_\_\_
9. bid \_\_\_\_\_
10. prn \_\_\_\_\_



# CHAPTER 5

## Skeletal System



### Pretest

**Multiple Choice.** Select the best answer, and write the letter of your choice to the left of each number. To check your answers go to Appendix 11.

- \_\_\_\_\_ 1. The root *oste/o* means
  - a. cartilage
  - b. fat
  - c. heart
  - d. bone
- \_\_\_\_\_ 2. The root *myel/o* used in reference to bones means
  - a. bone marrow
  - b. joint
  - c. bone shaft
  - d. membrane
- \_\_\_\_\_ 3. A bone of the spinal column is a
  - a. ventricle
  - b. cortex
  - c. labyrinth
  - d. vertebra
- \_\_\_\_\_ 4. The large, flared superior bone of the pelvis is the
  - a. phalange
  - b. ilium
  - c. thorax
  - d. duodenum
- \_\_\_\_\_ 5. The bones of the wrist are the
  - a. digits
  - b. cervices
  - c. carpals
  - d. ribs
- \_\_\_\_\_ 6. The bone of the thigh is the
  - a. patella
  - b. cranium
  - c. umbilicus
  - d. femur
- \_\_\_\_\_ 7. A general term for inflammation of a joint is
  - a. arthritis
  - b. conjunctivitis
  - c. epididymitis
  - d. myocarditis
- \_\_\_\_\_ 8. Chondrosarcoma is a tumor that originates in
  - a. adipose tissue
  - b. bone
  - c. cartilage
  - d. muscle

## Learning Objectives

After careful study of this chapter, you should be able to:

- 1 Compare the axial skeleton and the appendicular skeleton. **P152**
- 2 Briefly describe the formation of bone tissue. **P155**
- 3 Describe the structure of a long bone. **P155**
- 4 Compare a suture, a symphysis, and a synovial joint. **P156**
- 5 Describe the structure of a synovial joint. **P156**
- 6 Identify and use roots pertaining to the skeleton. **P158**
- 7 Describe six disorders that affect the skeleton and joints. **P160**
- 8 Interpret abbreviations used in relation to the skeleton. **P174**
- 9 Identify and analyze medical terms and abbreviations in chapter case studies. **PP151, 184**



## Case Study: Rachel's Idiopathic Adolescent Scoliosis

### Chief Complaint

Four years ago, Rachel, a 15 y/o female, had a posterior spinal fusion (PSF) for correction of idiopathic adolescent scoliosis in a pediatric orthopedic hospital in another state. Rachel is a gifted musician, and her favorite pastime is playing the piano, guitar, and other musical instruments. Lately she has experienced considerable back pain that she attributed to long hours at the piano or playing the guitar. It was time for her routine follow-up orthopedic visit, and now she presents with a significant prominence of the right scapula and back pain in the mid- and lower back.

### Examination

A history was taken and medical records were reviewed followed by a physical examination. The medical records indicated that the patient's spinal curvature had been surgically corrected with the insertion of bilateral laminar and pedicle hooks and two 3/16-in rods. A bone autograft was taken from Rachel's right posterior superior ilium and applied along the lateral processes of T4 to L2 to complete the fusion. The physical examination was normal except for surgical scarring along the spine, a projecting right scapula, and asymmetry of the rib cage. During the history, Rachel denied numbness or tingling of the lower extremities, bowel or bladder problems, chest pain, or shortness

of breath. The physician ordered a CT scan to determine if there had been continued growth on the anterior portion of the spine following the posterior fusion.

### Clinical Course

The results of the CT scan of the upper thoracic spine showed a prominent rotatory scoliosis deformity of the right posterior thorax with acute angulation of the ribs. Rachel's deformity is a common consequence of overcorrection of prior spinal fusion surgery, called crankshaft phenomenon.

Rachel was referred to the chief spinal surgeon of a local pediatric orthopedic hospital for removal of the spinal instrumentation, posterior spinal osteotomies from T4 to L2, insertion of replacement hooks and rods, bilateral rib resections, autograft bone from the resected ribs, partial scapulectomy and possible bone allograft, and bilateral chest tube placement. The surgical plan was explained to her and her mother, and consent was obtained and signed. The surgical procedure and the potential benefits versus risks were discussed. Rachel and her parents stated that they fully understood and provided consent to proceed with the plan for surgery.

**Case Study Revisited: Once you complete this chapter, please review the case follow-up on p. 175.**

## Ancillaries *At-A-Glance*

Visit the web resource to access the following resources.

### Learning Resources

- eBook
- A&P Module with Heart & Lung Sounds
- Image Bank

- TestPrep
- Animations
- Audio Pronunciation Glossary

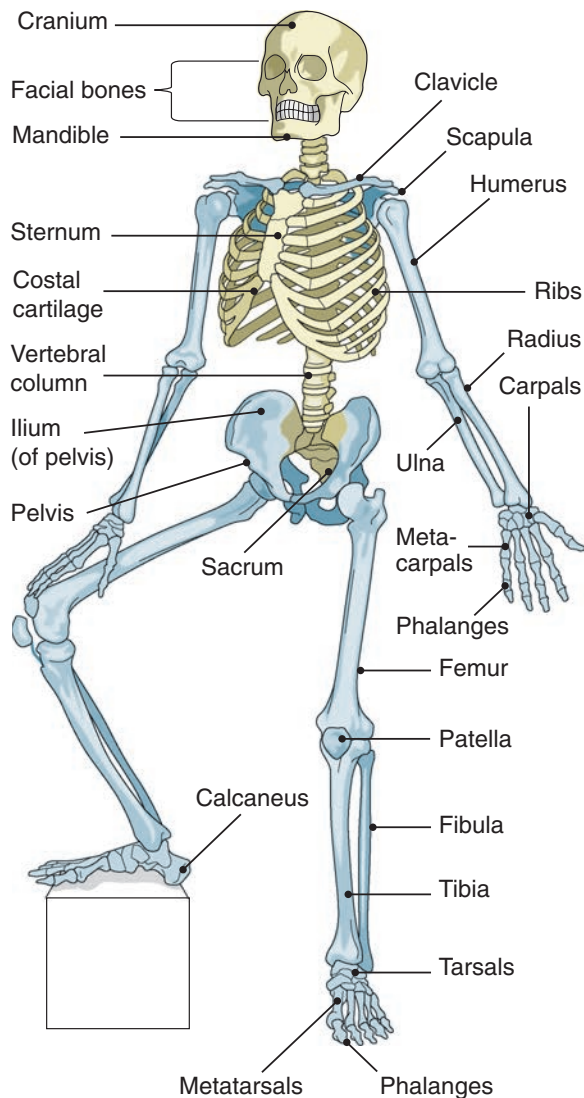
## Introduction

The **skeleton** forms the framework of the body, protects vital organs, and works with the muscular system to produce movement at the **joints**. The human adult skeleton is composed of 206 **bones**, which are organized for study into two divisions.

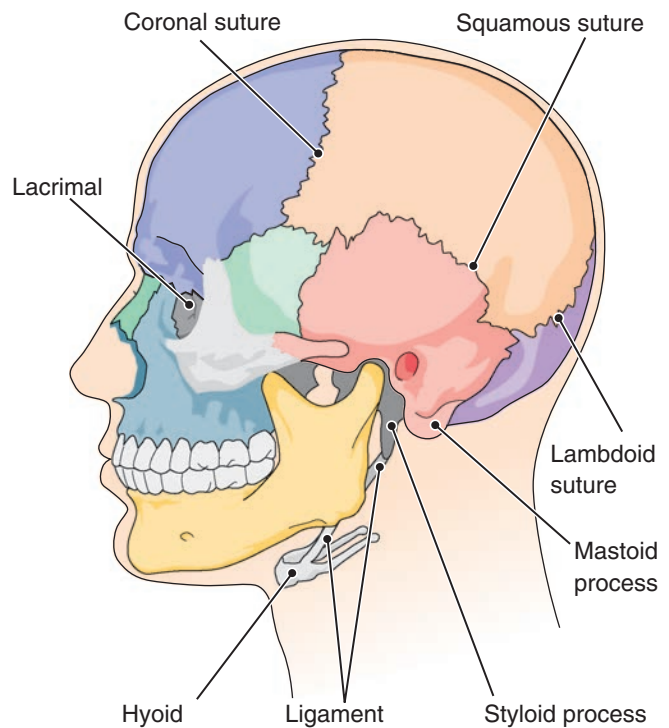
## Divisions of the Skeleton

The axial skeleton forms the central core or “axis” of the body’s bony framework (FIG. 5-1). It consists of:

- The skull, made up of 8 cranial bones and 14 bones of the face (FIG. 5-2). The skull bones are joined by immovable joints (sutures), except for the joint between the lower jaw (mandible) and the temporal bone of the cranium, the temporomandibular joint (TMJ).
- The spinal column (FIG. 5-3) consisting of 26 vertebrae. Between the vertebrae are disks of cartilage that add strength and flexibility to the spine. The five groups of vertebrae, listed from superior to inferior with the number of bones in each group are:



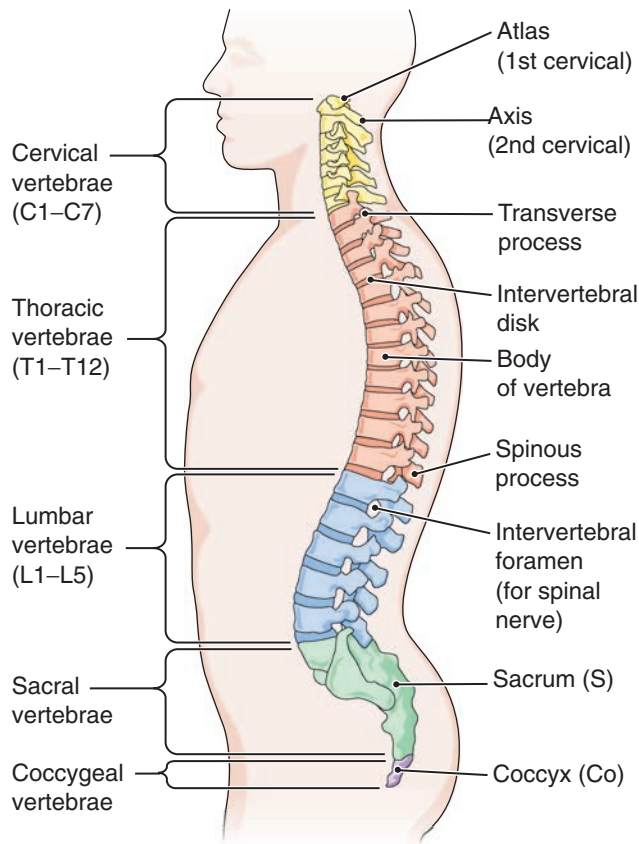
**FIGURE 5-1 The skeleton.** The skeleton is divided into two portions. The axial skeleton is shown here in yellow; the appendicular in blue.



### Bones of the skull:

- |            |             |
|------------|-------------|
| ■ Frontal  | ■ Maxilla   |
| ■ Parietal | ■ Occipital |
| ■ Sphenoid | ■ Zygomatic |
| ■ Temporal | ■ Mandible  |
| ■ Nasal    |             |

**FIGURE 5-2 The skull from the left.** An additional cranial bone, the ethmoid (*ETH-moyd*), is visible mainly from the interior of the skull. The hyoid is considered part of the axial skeleton but is not attached to any other bones. The tongue and other muscles are attached to the hyoid.



**FIGURE 5-3** Vertebral column, left lateral view. The number of vertebrae in each group and the abbreviations for each are shown. The sacrum and coccyx are formed from fused bones.

1. Cervical (7), designated C1 to C7. The first and second cervical vertebrae also have specific names, the **atlas** and the **axis**, respectively (see **FIG. 5-3**).

2. Thoracic (12), designated T1 to T12
3. Lumbar (5), designated L1 to L5
4. The sacrum (S), composed of five fused bones
5. The coccyx (Co), composed of four to five fused bones

- The **thorax**, consisting of 12 pairs of ribs joined by cartilage to the sternum (breastbone). The rib cage encloses and protects the thoracic organs.

The appendicular skeleton is attached or “appended” to the axial skeleton (see **FIG. 5-1**). The upper division includes:

- The bones of the shoulder girdle, the clavicle (collar bone), and scapula (shoulder blade)
- The bones of the upper extremities (arms), the humerus, radius, ulna, carpals (wrist bones), metacarpals (bones of the palm), and phalanges (finger bones)

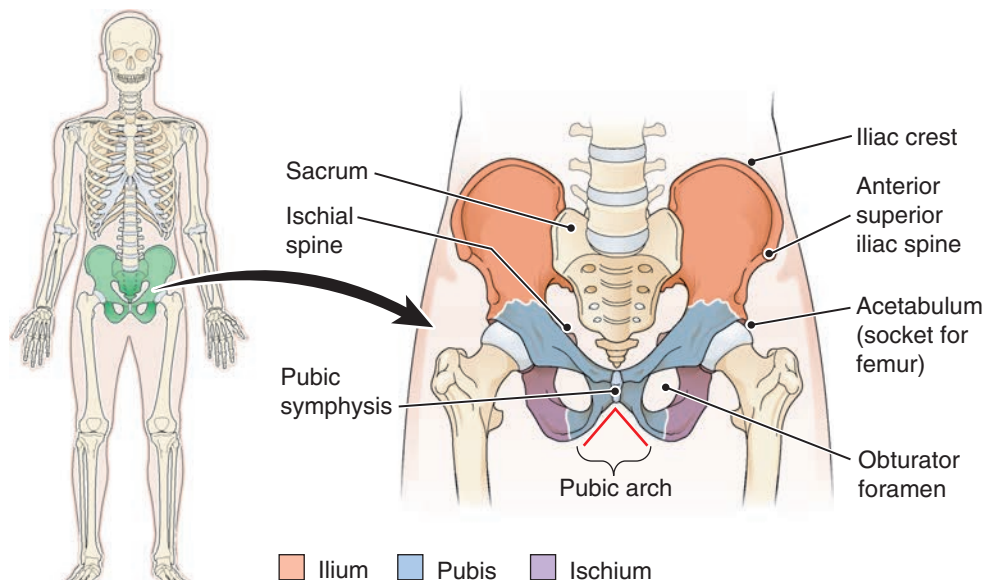
The lower division includes:

- The pelvic bones, two large bones that join the sacrum and coccyx to form the bony **pelvis**. Each pelvic or hip bone (os coxae) is formed by three fused bones: the large, flared **ilium**; the ischium; and the pubis (**FIG. 5-4**). The deep socket in the hip bone that holds the head of the femur is the **acetabulum**. The female pelvis is wider than the male pelvis and has other differences to accommodate childbirth.
- The bones of the lower extremities (legs), the femur, patella (kneecap), tibia, fibula, tarsals (ankle bones), metatarsals (bones of the instep), and phalanges (toe bones). The large tarsal bone that forms the heel is the **calcaneus** (*kal-KA-ne-us*), shown in **FIGURE 5-1**.

All of these bone groups, and also the hyoid under the jaw and the ear ossicles, are listed with phonetic pronunciations and described in **BOX 5-1**.

**FIGURE 5-4** The pelvic bones.

Each pelvic or hip bone is formed from three fused bones, the ilium, ischium, and pubis. Together with the sacrum and coccyx, they form the bony pelvis. The acetabulum is the socket for the femur.





## FOR YOUR REFERENCE

### Bones of the Skeleton

BOX 5-1

Region	Bones	Description
<b>AXIAL SKELETON</b> (AK-se-al)		
<b>SKULL</b>		
<b>cranium</b> (KRA-ne-um)	cranial bones (8)	form the chamber enclosing the brain; house the ear and form part of the eye socket
<b>facial portion</b> (FA-shal)	facial bones (14)	form the face and chambers for sensory organs
<b>hyoid</b> (HI-oyd)		U-shaped bone under mandible (lower jaw); used for muscle attachments
<b>ossicles</b> (OS-ih-klz)	ear bones (3)	transmit sound waves through middle ear
<b>TRUNK</b>		
<b>vertebral column</b> (VER-teh-bral)	vertebrae (26) (VER-teh-bre)	enclose the spinal cord
<b>thorax</b> (THO-raks)	sternum (STER-num) ribs (12 pairs)	anterior bone of the thorax enclose the organs of the thorax
<b>APPENDICULAR SKELETON</b> (ap-en-DIK-u-lar)		
<b>UPPER DIVISION</b>		
<b>shoulder girdle</b>	clavicle (KLAV-ih-kl) scapula (SKAP-u-lah)	anterior, between sternum and scapula posterior, anchors muscles that move arm
<b>upper extremity</b>	humerus (HU-mer-us) ulna (UL-nah) radius (RA-de-us) carpals (8) (KAR-palz) metacarpals (5) (met-ah-KAR-palz) phalanges (14) (fah-LAN-jeze)	proximal arm bone medial bone of forearm lateral bone of forearm wrist bones bones of palm bones of fingers
<b>LOWER DIVISION</b>		
<b>pelvic bones</b> (PEL-vic)	os coxae (2) (os KOK-se)	join sacrum and coccyx of vertebral column to form the bony pelvis
<b>lower extremity</b>	femur (FE-mur) patella (pah-TEL-ah) tibia (TIB-e-ah) fibula (FIB-u-lah) tarsal bones (7) (TAR-sal) metatarsals (5) (met-ah-TAR-salz) phalanges (14) (fah-LAN-jeze)	thigh bone kneecap medial bone of leg lateral bone of leg ankle bones; the large heel bone is the calcaneus (kal-KA-ne-us) bones of instep bones of toes

## Bone Formation

Most bone tissue is formed by the gradual addition of calcium and phosphorus salts to **cartilage**, a type of dense connective tissue. (In a few places, such as the flat bones of the skull, bone forms from fibrous connective tissue.) The bone-forming process of **ossification** begins before birth and continues to adulthood. The fibrous protein, collagen, gives bone tissue its strength and resiliency. Although bone appears to be inert, it is actually living tissue that is constantly being replaced and remodeled throughout life. Three types of cells are involved in these changes:

- **Osteoblasts**, the cells that produce bone
- **Osteocytes**, mature bone cells that help to maintain bone tissue
- **Osteoclasts**, involved in the breakdown of bone tissue to release needed minerals or to allow for reshaping and repair

The process of destroying bone so that its components can be taken into the circulation is called **resorption**. This activity occurs continuously and is normally in balance with bone formation. In disease states, resorption may occur more rapidly or more slowly than bone production.

## Structure of a Long Bone

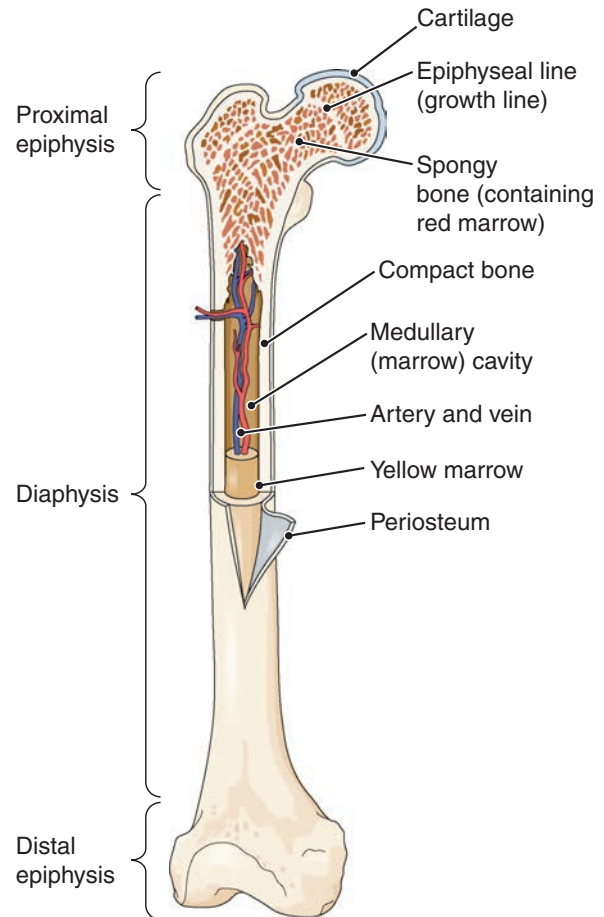
A typical long bone (**FIG. 5-5**) has a shaft or **diaphysis** composed of compact bone tissue. Within the shaft is a medullary (marrow) cavity containing the yellow form of **bone marrow**, which is high in fat. The irregular **epiphysis** at either end is made of a less dense, spongy (cancellous) bone tissue (**FIG. 5-6**). This type of bone tissue encloses red bone marrow, where blood cells are formed.

The spaces in spongy bone contain the blood-forming red bone marrow. A layer of cartilage covers the epiphysis to protect the bone surface at a joint. The thin layer of fibrous tissue, or **periosteum**, that covers the bone's outer surface nourishes and protects the bone and also generates new bone cells for growth and repair.

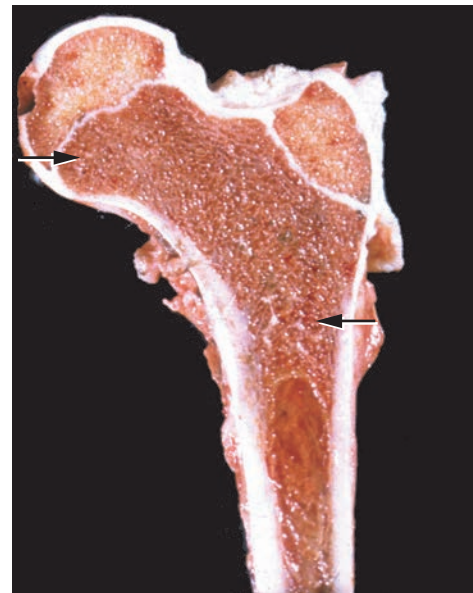Between the diaphysis and the epiphysis at each end, in a region called the **metaphysis**, is the growth region or **epiphyseal plate**. Long bones continue to grow in length at these regions throughout childhood and into early adulthood. When the bone stops elongating, this area becomes fully calcified but remains visible as the epiphyseal line (see **FIG. 5-5**).

Long bones are found in the arms, legs, hands, and feet. Other bones are described as:

- Flat (e.g., cranial bones, ribs, scapulae)
- Short (e.g., wrist and ankle bones)
- Irregular (e.g., facial bones, vertebrae)



**FIGURE 5-5** Structure of a long bone.



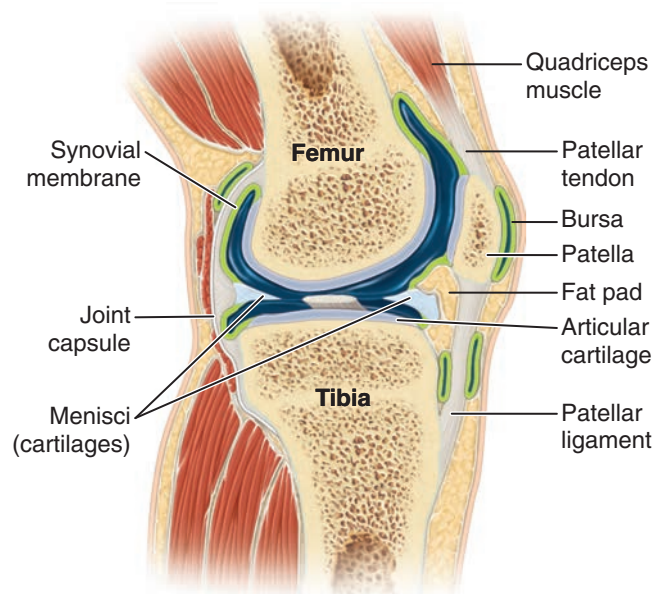
**FIGURE 5-6** Bone tissue, longitudinal section. The epiphysis (end) of this long bone has an outer layer of compact bone. The remainder of the tissue is spongy (cancellous) bone, shown by the arrows. Transverse growth lines are also visible.

## Joints

The joints, or **articulations**, are classified according to the degree of movement they allow:

- A **suture** is an immovable joint held together by fibrous connective tissue, as is found between the bones of the skull (see **FIG. 5-2**).
- A **symphysis** is a slightly movable joint connected by fibrous cartilage. Examples are the joints between the bodies of the vertebrae (see **FIG. 5-3**) and the joint between the pubic bones (see **FIG. 5-4**).
- A **synovial joint**, or **diarthrosis**, is a freely movable joint. Such joints allow for a wide range of movements, as described in Chapter 6. **Tendons** attach muscles to bones to produce movement at the joints.

Freely movable joints are subject to wear and tear, and they therefore have some protective features (**FIG. 5-7**). The cavity of a diarthrotic joint contains **synovial fluid**, which cushions and lubricates the joint. This fluid is produced by the synovial membrane that lines the joint cavity. The ends of the articulating bones are cushioned and protected by cartilage. A fibrous capsule, continuous with the periosteum, encloses the joint. Synovial joints are stabilized and strengthened by **ligaments**, which connect the articulating bones. A **bursa** is a small sac of synovial fluid that cushions the area around a joint. Bursae are found at stress points between tendons, ligaments, and bones (see **FIG. 5-7**).



**FIGURE 5-7** The knee joint, sagittal section. The knee joint is an example of a freely movable, synovial joint, also called a diarthrosis. Synovial fluid fills the joint cavity. Other protective structures such as cartilage, the joint capsule, ligaments, and bursae are also shown.

## Terminology

## Key Terms

The terms listed below are emphasized in this chapter. Knowing them will help you organize and prioritize your learning. These boldface terms are also found, collectively, with all chapter key terms in the Glossary.

### Normal Structure and Function

<b>acetabulum</b> <i>as-eb-TAB-u-lum</i>	The bony socket in the hip bone that holds the head of the femur (from the Latin word for vinegar because it resembles the base of a vinegar cruet) (see <b>FIG 5-4</b> )
<b>articulation</b> <i>ar-tik-u-LA-shun</i>	A joint (adjective: articular)
<b>atlas</b> <i>AT-las</i>	The first cervical vertebra (see <b>FIG. 5-3</b> ) (root: atlant/o)
<b>axis</b> <i>AK-sis</i>	The second cervical vertebra (see <b>FIG. 5-3</b> )
<b>bone</b>	A calcified form of dense connective tissue; osseous tissue; also an individual unit of the skeleton made of such tissue (root: oste/o)
<b>bone marrow</b>	The soft material that fills bone cavities; yellow marrow fills the central cavity of the long bones; blood cells are formed in red bone marrow, which is located in spongy bone tissue (root: myel/o)
<b>bursa</b> <i>BUR-sah</i>	A fluid-filled sac that reduces friction near a joint (root: burs/o)
<b>cartilage</b> <i>KAR-tib-lij</i>	A type of dense connective tissue that is found in the skeleton, larynx, trachea, and bronchi; it is the precursor to most bone tissue (root: chondr/o)
<b>diarthrosis</b> <i>di-ar-THRO-sis</i>	A freely movable joint; also called a synovial joint (adjective: diarthrotic)

## Terminology

## Key Terms (Continued)

<b>diaphysis</b> <i>di-AF-ih-sis</i>	The shaft of a long bone
<b>epiphyseal plate</b> <i>ep-ih-FIZ-e-al</i>	The growth region of a long bone; located in the metaphysis, between the diaphysis and epiphysis; when bone growth ceases, this area appears as the epiphyseal line; also spelled epiphysial
<b>epiphysis</b> <i>eh-PIF-ih-sis</i>	The irregularly shaped end of a long bone
<b>ilium</b> <i>IL-e-um</i>	The large, flared, superior portion of the pelvic bone (root: ili/o) (adjective: iliac)
<b>joint</b>	The junction between two bones; articulation (root: arthr/o)
<b>ligament</b> <i>LIG-ah-ment</i>	A strong band of connective tissue that joins one bone to another
<b>metaphysis</b> <i>meh-TAF-ih-sis</i>	The region of a long bone between the diaphysis (shaft) and epiphysis (end); during development, the growing region of a long bone
<b>ossification</b> <i>os-ih-fib-KA-shun</i>	The formation of bone tissue (from Latin <i>os</i> , meaning “bone”)
<b>osteoblast</b> <i>OS-te-o-blast</i>	A cell that produces bone tissue
<b>osteoclast</b> <i>OS-te-o-clast</i>	A cell that destroys bone tissue
<b>osteocyte</b> <i>OS-te-o-site</i>	A mature bone cell that nourishes and maintains bone tissue
<b>pelvis</b> <i>(PEL-vis)</i>	The large ring of bone at the inferior trunk formed of the two hip bones ( <i>ossa coxae</i> ) joined to the sacrum and coccyx; each <i>os coxae</i> is formed of three bones: the superior, flared ilium ( <i>IL-e-um</i> ); ischium ( <i>IS-ke-um</i> ); and pubis ( <i>PU-bis</i> ) (plural: <i>pelves</i> [ <i>PEL-veze</i> ])
<b>periosteum</b> <i>per-e-OS-te-um</i>	The fibrous membrane that covers a bone’s surface
<b>resorption</b> <i>re-SORP-shun</i>	Removal of bone by breakdown and absorption into the circulation
<b>skeleton</b> <i>SKEL-eh-ton</i>	The body’s bony framework, consisting of 206 bones; the axial portion (80 bones) is composed of the skull, spinal column, ribs, and sternum; the appendicular skeleton (126 bones) contains the bones of the arms and legs, shoulder girdle, and pelvis (root: <i>skelet/o</i> )
<b>suture</b> <i>SU-chur</i>	An immovable joint, such as the joints between the skull bones
<b>symphysis</b> <i>SIM-fih-sis</i>	A slightly movable joint
<b>synovial fluid</b> <i>sih-NO-ve-al</i>	The fluid contained in a freely movable (diarthrotic) joint; synovia (root: <i>synov/i</i> )
<b>synovial joint</b>	A freely movable joint; has a joint cavity containing synovial fluid; a diarthrosis
<b>tendon</b> <i>TEN-don</i>	A fibrous band of connective tissue that attaches a muscle to a bone
<b>thorax</b> <i>THO-raks</i>	The upper part of the trunk between the neck and the abdomen; formed by the 12 pairs of ribs and sternum



## Roots Pertaining to the Skeletal System

See TABLES 5-1 and 5-2.

Table 5-1		Roots for Bones and Joints	
Root	Meaning	Example	Definition of Example
oste/o	bone	osteopenia <i>os-te-o-PE-ne-ab</i>	deficiency of bone tissue
myel/o	bone marrow; also, spinal cord	myeloid <i>MI-eh-loyd</i>	pertaining to or resembling bone marrow
chondr/o	cartilage	chondroblast <i>KON-dro-blast</i>	a cartilage-forming cell
arthr/o	joint	arthrosis <i>ar-THRO-sis</i>	joint; condition affecting a joint
synov/i	synovial fluid, joint, or membrane	asynovia <i>ah-sin-O-ve-ab</i>	lack of synovial fluid
burs/o	bursa	peribursal <i>per-ih-BER-sal</i>	around a bursa

### Exercise 5-1

Complete the exercise. To check your answers go to Appendix 11.

Fill in the blanks.

1. Arthrodesis (*ar-THROD-eh-sis*) is fusion of a(n) \_\_\_\_\_ .
2. Myelogenous (*mi-eh-LOJ-eh-nus*) means originating in \_\_\_\_\_ .
3. Osteolysis (*os-te-OL-ih-sis*) is destruction of \_\_\_\_\_ .
4. A chondrocyte (*KON-dro-site*) is a cell found in \_\_\_\_\_ .
5. A bursolith (*BUR-so-lith*) is a stone in a(n) \_\_\_\_\_ .

Define the following words.

6. arthrocentesis (*ar-thro-sen-TE-sis*) \_\_\_\_\_
7. myelopoiesis (*mi-eh-lo-poy-E-sis*) \_\_\_\_\_
8. chondrodynia (*kon-dro-dih-ne-ab*) \_\_\_\_\_
9. osteoid (*OS-te-oyd*) \_\_\_\_\_
10. bursitis (*bur-SI-tis*) \_\_\_\_\_
11. synovial (*sih-NO-ve-al*) \_\_\_\_\_

**Exercise 5-1 (Continued)**

Write words for the following definitions.

12. inflammation of bone and bone marrow \_\_\_\_\_

13. a bone-forming cell \_\_\_\_\_

14. pertaining to or resembling cartilage \_\_\_\_\_

15. any disease of a joint \_\_\_\_\_

16. inflammation of a synovial membrane \_\_\_\_\_

17. radiography of the spinal cord \_\_\_\_\_

18. incision of a bursa \_\_\_\_\_

19. tumor of bone marrow \_\_\_\_\_

20. instrument for examining the interior of a joint \_\_\_\_\_

The word *ostosis* means “bone growth.” Use this as a suffix for the following two words.

21. excess growth of bone \_\_\_\_\_

22. abnormal growth of bone \_\_\_\_\_

Table 5-2

**Roots for the Skeleton**

Root	Meaning	Example	Definition of Example
crani/o	skull, cranium	craniometry <i>kra-ne-OM-eh-tre</i>	measurement of the cranium
spondyl/o	vertebra	spondylolysis <i>spon-dih-LOL-ih-sis</i>	destruction and separation of a vertebra
vertebr/o	vertebra, spinal column	paravertebral <i>pah-rah-VER-te-bral</i>	near the vertebrae or spinal column
rachi/o	spine	rachischisis <i>ra-KIS-kih-sis</i>	fissure (-schisis) of the spine; spina bifida
cost/o	rib	costochondral <i>kos-to-KON-dral</i>	pertaining to a rib and its cartilage
sacr/o	sacrum	presacral <i>pre-SA-kral</i>	in front of the sacrum
coccy, coccyg/o	coccyx	coccygeal <sup>a</sup> <i>kok-SIJ-e-al</i>	pertaining to the coccyx
pelvi/o	pelvis	pelviscope <i>PEL-vih-skope</i>	endoscope for examining the pelvis
ili/o	ilium	iliopelvic <i>il-e-o-PEL-vik</i>	pertaining to the ilium and pelvis

<sup>a</sup>Note spelling.

## Exercise 5-2

Complete the exercise. To check your answers go to Appendix 11.

Write adjectives for the following definitions. The adjective endings are provided in parentheses.

1. pertaining to (-al) the skull \_\_\_\_\_
2. pertaining to (-al) a rib \_\_\_\_\_
3. pertaining to (-ic) the pelvis \_\_\_\_\_
4. pertaining to (-ac) the ilium \_\_\_\_\_
5. pertaining to (-al) the spinal column \_\_\_\_\_
6. pertaining to (-al) the sacrum \_\_\_\_\_

Define the following terms.

7. craniotomy (*kra-ne-OT-o-me*) \_\_\_\_\_
8. prevertebral (*pre-VER-teh-bral*) \_\_\_\_\_
9. spondylodynia (*spon-dih-lo-DIN-e-ab*) \_\_\_\_\_
10. pelvimetry (*pel-VIM-eh-tre*) \_\_\_\_\_

Write words for the following definitions.

11. fissure of the skull \_\_\_\_\_
12. above the pelvis \_\_\_\_\_
13. pertaining to the cranium and sacrum \_\_\_\_\_
14. pertaining to the sacrum and ilium \_\_\_\_\_
15. surgical puncture of the spine; spinal tap \_\_\_\_\_
16. surgical excision of a rib \_\_\_\_\_
17. plastic repair of a vertebra (use *vertebr/o*) \_\_\_\_\_
18. inflammation of the vertebrae (use *spondyl/o*) \_\_\_\_\_
19. around the sacrum \_\_\_\_\_
20. below the ribs \_\_\_\_\_
21. pertaining to the ilium and coccyx \_\_\_\_\_
22. excision of the coccyx \_\_\_\_\_

## Clinical Aspects of the Skeleton

Disorders of the skeleton often involve surrounding tissues—ligaments, tendons, and muscles—and may be studied together as diseases of the musculoskeletal system. (The muscular system is described in Chapter 6.) The medical specialty that concentrates on diseases of the skeletal and muscular systems is **orthopedics**. Physical therapists and occupational therapists must also understand these systems

(**BOX 5-2**). (Some colorful terms used to describe musculoskeletal abnormalities are given in **BOX 5-3**.)

Most abnormalities of the bones and joints appear on simple radiographs (**FIG. 5-8** shows a radiograph of a normal joint). Radioactive bone scans, computed tomography (CT), and magnetic resonance imaging (MRI) scans are used as well. Also indicative of disorders are changes in blood levels of calcium and **alkaline phosphatase**, an enzyme needed for bone calcification.



## HEALTH PROFESSIONS

### Careers in Physical Therapy

BOX 5-2

Physical therapy restores mobility and relieves pain in cases of arthritis or musculoskeletal injuries. Individuals who are recovering from neuromuscular, cardiovascular, pulmonary, and integumentary events are also candidates for physical therapy. Some examples include traumatic brain injury (TBI), myocardial infarction (MI), chronic obstructive pulmonary disease (COPD), and burns, respectively.

Physical therapists (PTs) work closely with physicians, nurses, occupational therapists, and other allied healthcare professionals. Some treat a wide range of ailments, whereas others focus on a particular age group, medical field, or sports medicine. Regardless of specialty, PTs are responsible for examining their patients and developing individualized treatment programs. The examination includes a medical history and tests measuring strength, mobility, balance, coordination, and endurance. The treatment plan may include stretching and exercise to improve mobility; hot packs, cold compresses,

and massage to reduce pain; and the use of crutches, prostheses, and wheelchairs. Physical therapy assistants (PTAs) work directly under the supervision of a physical therapist. PTAs are responsible for implementing a pre-established treatment plan, teaching patients exercises and equipment use, and reporting results back to the physical therapist.

Whereas many practicing physical therapists in the United States have bachelor's or master's degrees, most accredited physical therapy schools now offer doctoral programs requiring 3 years of postgraduate education. PTAs in the United States usually graduate with an associate degree from a community college and must pass a licensing exam. PTs and PTAs practice in hospitals and clinics and may also visit homes and schools. As the U.S. population continues to age and the need for rehabilitative therapy increases, job prospects are good. For more information about careers in physical therapy, contact the American Physical Therapy Association at [apta.org](http://apta.org).

5



## FOCUS ON WORDS

### Names That Are Like Pictures

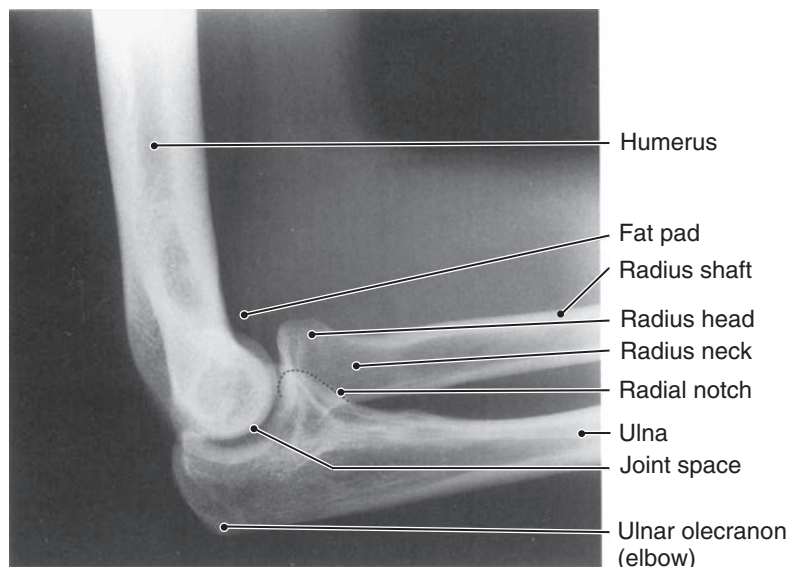
BOX 5-3

Some conditions are named by terms that are very descriptive. In orthopedics, several names for types of bursitis are based on the repetitive stress that leads to the irritation. For example, “tailor’s bottom” involves the ischial (“sit”) bones of the pelvis, as might be irritated by sitting tailor-fashion to sew. “Housemaid’s knee” comes from the days of scrubbing floors on hands and knees, and “tennis elbow” is named for the sport that is its most common cause. “Student’s elbow” results from leaning to pore over books while studying, although today a student is more likely to have neck and wrist problems from working at a computer.

The term *knock-knee* describes genu valgum, in which the knees are abnormally close and the space between the ankles

is wide. The opposite is genu varum, in which the knees are far apart and the bottom of the legs are close together, giving rise to the term *bowleg*. A dowager’s hump appears dorsally between the shoulders as a result of osteoporosis and is most commonly seen in elderly women.

Injury to the roots of nerves that supply the arm may cause the arm to abduct slightly and rotate medially with the wrist flexed and the fingers pointing backward, a condition colorfully named “waiter’s tip position.” “Popeye’s shoulder” is a sign of a separation or tear at the head of the biceps tendon. The affected arm, when abducted with the elbow flexed, reveals a bulge on the upper arm—just like Popeye’s!



**FIGURE 5-8 Radiograph of a normal left elbow joint, lateral view.** The olecranon (*o-LEK-rah-non*) is the proximal ulnar enlargement that forms the prominent bone of the elbow.

## INFECTION

**Osteomyelitis** is an inflammation of bone caused by pus-forming bacteria that enter through a wound or are carried by the blood. Often the blood-rich ends of the long bones are invaded, and the infection then spreads to other regions, such as the bone marrow and even the joints. The use of antibiotics has greatly reduced the threat of osteomyelitis.

Tuberculosis may spread to bone, especially the long bones of the arms and legs and the bones of the wrist and ankle. Tuberculosis of the spine is **Pott disease**. Infected vertebrae are weakened and may collapse, causing pain, deformity, and pressure on the spinal cord. Antibiotics can control tuberculosis as long as the strains are not resistant to these drugs and the host is not weakened by other diseases.

## FRACTURES

A **fracture** is a break in a bone, usually caused by trauma. The effects of a fracture depend on the break's location and severity; the amount of associated injury; possible complications, such as infections; and success of healing, which may take months. Healing may be promoted by injecting a synthetic bone cement or applying an external magnetic field. In a closed or simple fracture, the skin is not broken. If the fracture is accompanied by a wound in the skin, it is described as an open fracture. Various types of fractures are listed in **BOX 5-4** and illustrated in **FIGURE 5-9**.

**Reduction of a fracture** refers to realignment of the broken bone. If no surgery is required, the reduction is

described as closed; an open reduction is one that requires surgery to place the bone in proper position. Rods, plates, or screws might be needed to ensure proper healing. A splint or cast is often needed during the healing phase to immobilize the bone. **Traction** refers to using pulleys and weights to maintain alignment of a fractured bone during healing. A traction device may be attached to the skin or attached to the bone itself by means of a pin or wire.

## METABOLIC BONE DISEASES

**Osteoporosis** is a loss of bone mass that results in bone weakening (**FIG. 5-10**). A decrease in estrogens after menopause makes women over age 50 most susceptible to the effects of this disorder. Efforts to prevent osteoporosis include a healthful diet, adequate intake of calcium and vitamin D, and engaging in regular weight-bearing exercises, such as walking, running, aerobics, and weight training. These exercises stimulate bone growth and also contribute to the balance and muscle strength needed to prevent falls. Postmenopausal hormone replacement therapy (HRT) prevents bone loss, but medical researchers continue to evaluate the safety of this treatment. Long-term HRT has been implicated in breast and uterine cancers as well as increased risk of heart attack or stroke. The therapy is now recommended for short-term treatment of perimenopausal symptoms. Some drugs are available for reducing bone resorption and increasing bone density. These include the **bisphosphonates** and **selective estrogen receptor modulators (SERMs)** described in Chapter 16. Bisphosphonates are used with caution, as they have been

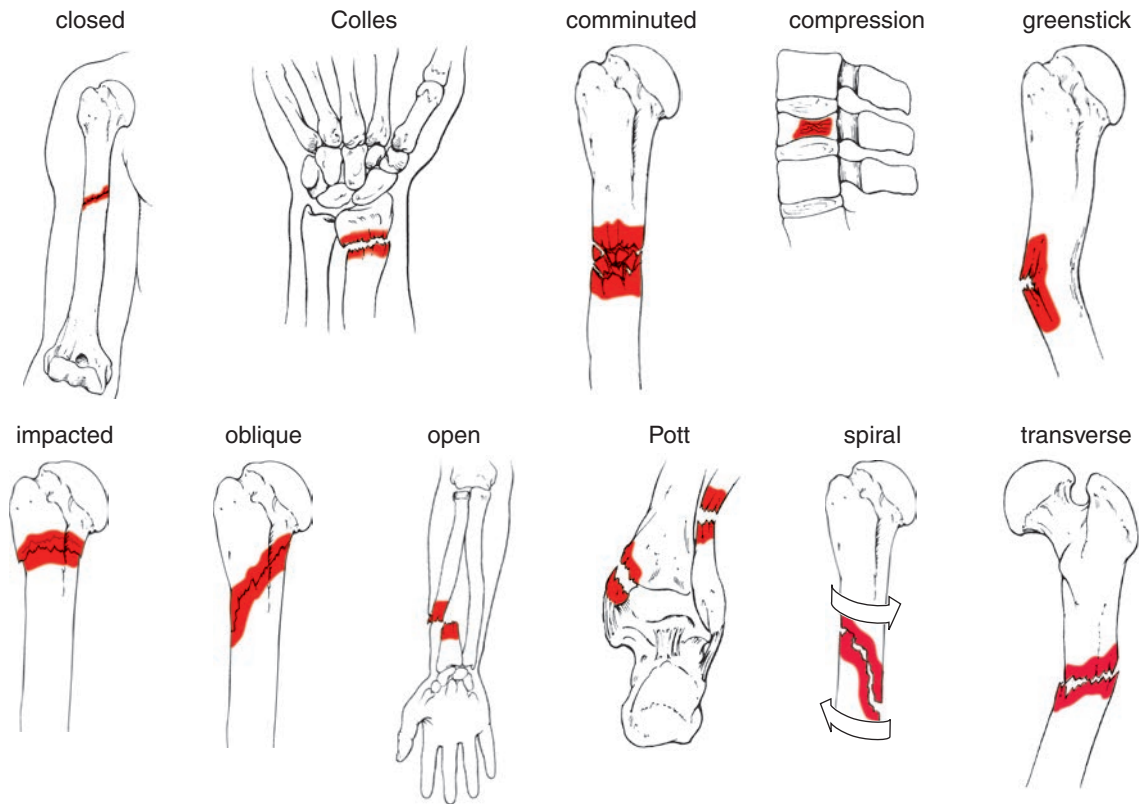


## FOR YOUR REFERENCE

### Types of Fractures

**BOX 5-4**

Fracture	Description
<b>closed</b>	a simple fracture with no open wound
<b>Colles</b> <i>KOL-eze</i>	fracture of the distal end of the radius with backward displacement of the hand
<b>comminuted</b> <i>COM-ih-nu-ted</i>	fracture in which the bone is splintered or crushed
<b>compression</b>	fracture caused by force from both ends, as to a vertebra
<b>greenstick</b>	one side of the bone is broken and the other side is bent
<b>impacted</b>	one fragment is driven into the other
<b>oblique</b>	break occurs at an angle across the bone; usually one fragment slips by the other
<b>open</b>	fracture is associated with an open wound, or broken bone protrudes through the skin
<b>Pott</b>	fracture of the distal end of the fibula with injury to the tibial joint
<b>spiral</b>	fracture is in a spiral or S shape; usually caused by twisting injuries
<b>transverse</b>	a break at right angles to the long axis of a bone



**FIGURE 5-9** Types of fractures.

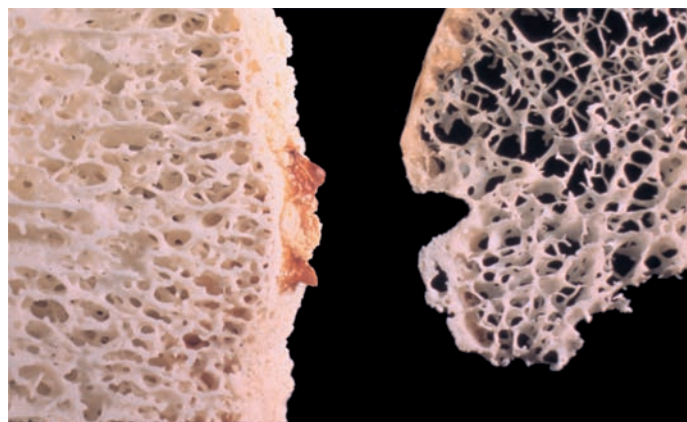
associated with unexplained bone fractures, necrosis of the jaw, and damage to the digestive tract.

Osteoporosis is diagnosed and monitored using a DEXA (dual-energy x-ray absorptiometry) scan, an imaging technique that measures bone mineral density (BMD). The diagnostic term **osteopenia** refers to a lower-than-average bone density, which is not considered to be abnormal. Osteopenia may progress to osteoporosis, but does not necessarily need treatment.

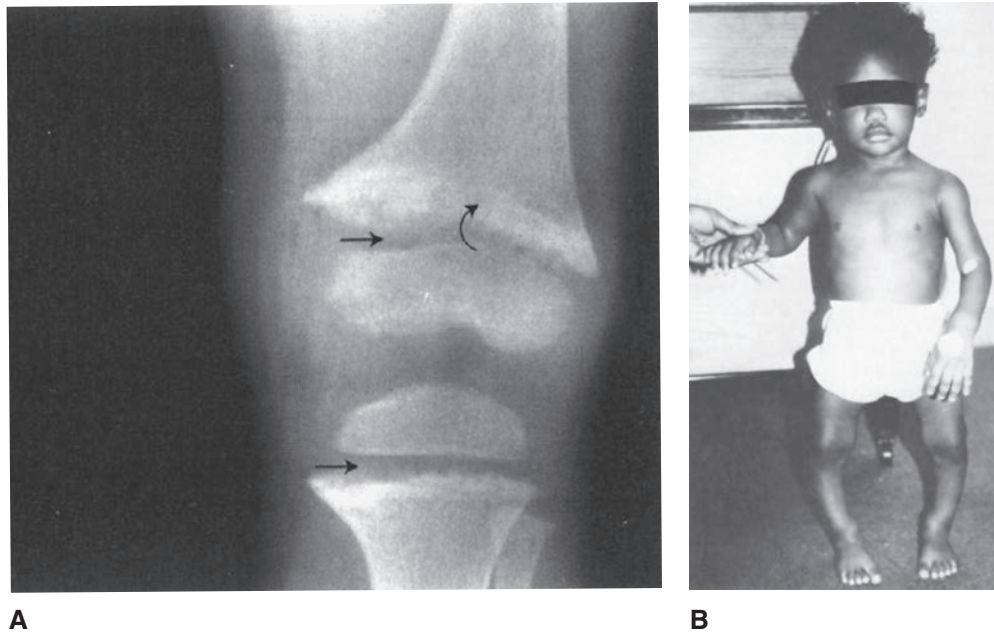
Other conditions that can lead to bone loss include nutritional deficiencies; disuse, as in paralysis or immobilization

in a cast; and excess adrenocortical steroids. Overactivity of the parathyroid glands also leads to osteoporosis because parathyroid hormone causes calcium release from bones to raise blood calcium levels. Certain drugs, smoking, lack of exercise, and high intake of alcohol, caffeine, and proteins may also contribute to the development of osteoporosis.

In **osteomalacia** there is a softening of bone tissue because of diminished calcium salt formation. Possible causes include deficiency of vitamin D, needed to absorb calcium and phosphorus from the intestine; renal disorders; liver disease; and certain intestinal disorders. When



**FIGURE 5-10** Osteoporosis. Femoral head showing osteoporosis (*right*) compared with a normal control (*left*).

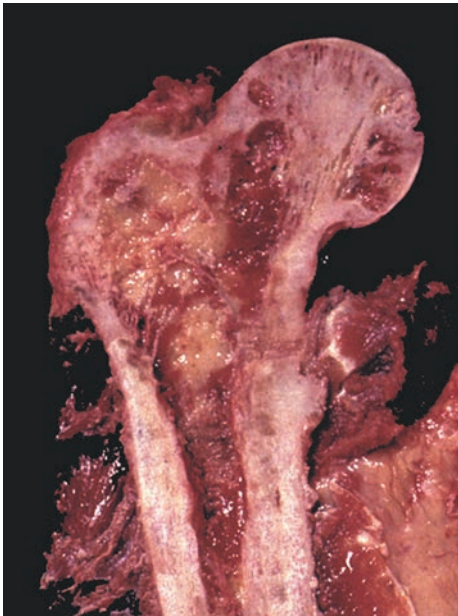


**FIGURE 5-11 Rickets.** A. Radiograph of the left knee joint showing widening of the growth regions of the bones (arrows). B. Young child showing rickets.

osteomalacia occurs in children, the disease is called **rickets** (FIG. 5-11). Rickets is usually caused by a vitamin D deficiency.

**Paget disease** (osteitis deformans) is a disorder of aging in which bones become overgrown and thicker but deformed (FIG. 5-12). The disease results in bowing of the

long bones and distortion of the flat bones, such as the skull bones. Paget disease usually involves the bones of the axial skeleton, causing pain, fractures, and hearing loss. With time, there may be neurologic signs, heart failure, and predisposition to bone cancer.



**FIGURE 5-12 Paget disease.** A section of the femur shows bone overgrowth in the diaphysis.

## NEOPLASMS

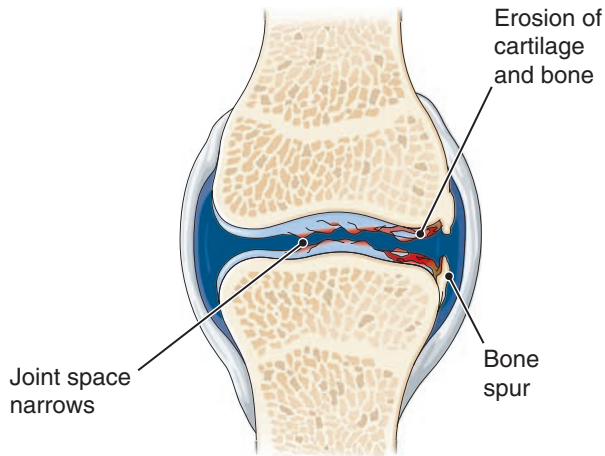
**Osteogenic sarcoma** (osteosarcoma) most commonly occurs in a bone's growing region, especially around the knee. This is a highly malignant tumor that often requires amputation. It most commonly metastasizes to the lungs.

**Chondrosarcoma** usually appears in midlife. As the name implies, this tumor arises in cartilage. It may require amputation and most frequently metastasizes to the lungs.

In cases of malignant bone tumors, early surgical removal is important for prevention of metastasis. Signs of bone tumors are pain, easy fracture, and increases in serum calcium and alkaline phosphatase levels. Aside from primary tumors, neoplasms at other sites often metastasize to bone, most commonly to the spine.

## JOINT DISORDERS

Some sources of joint problems include congenital malformations; infectious disease of the joint or adjacent bones; injury leading to degeneration; and necrosis resulting from loss of blood supply. **Arthritis** is a term broadly used to mean any inflammation of a joint. Based on the cause, several types are recognized.



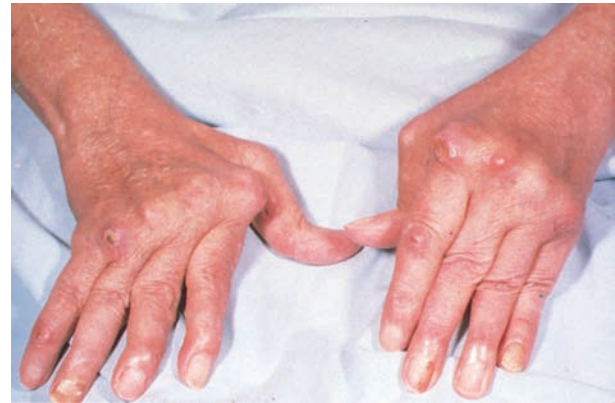**FIGURE 5-13 Joint changes in osteoarthritis (OA).** The left side of the joint shows early changes with breakdown of cartilage and narrowing of the joint space. The right side shows progression of the disease with loss of cartilage and a bone overgrowth (spur).

### Arthritis

The most common form of arthritis is **osteoarthritis (OA)** or **degenerative joint disease (DJD)** (FIG. 5-13). This involves a gradual degeneration of articular (joint) cartilage as a result of wear and tear. Predisposing factors for OA are age, heredity, injury, congenital skeletal abnormalities, and endocrine disorders. OA usually appears at midlife and beyond and involves the weight-bearing joints, such as the knees, hips, and finger joints. Radiographs show a narrowing of the joint cavity and bone thickening. Cartilage may crack and break loose, causing inflammation in the joint and exposing the underlying bone.

OA is treated with analgesics to relieve pain; **anti-inflammatory agents**, such as corticosteroids; **nonsteroidal anti-inflammatory drugs (NSAIDs)**; and physical therapy. Steroids can be injected directly into an arthritic joint, but because they may ultimately cause cartilage damage, only a few injections can be given within a year at intervals of several months. Treatment may include drainage of excess fluid from the joint in an **arthrocentesis**. Application of ice, elevation, and acupuncture may also help to relieve pain in cases of joint inflammation.

**Rheumatoid arthritis (RA)** is a systemic inflammatory joint disease that commonly appears in young adult women. Its exact causes are unknown, but it may involve immunologic reactions. A group of antibodies called **rheumatoid factor** often appears in the blood, but it is not always specific for RA as it may occur in other systemic diseases as well. There is an overgrowth of the synovial membrane that lines the joint cavity. As this membrane covers and destroys the joint cartilage, synovial fluid accumulates, causing joint swelling (FIG. 5-14). There is degeneration of the underlying bones, eventually causing fusion, or **ankylosis**. Treatment includes rest, physical therapy, analgesics, and anti-inflammatory drugs.

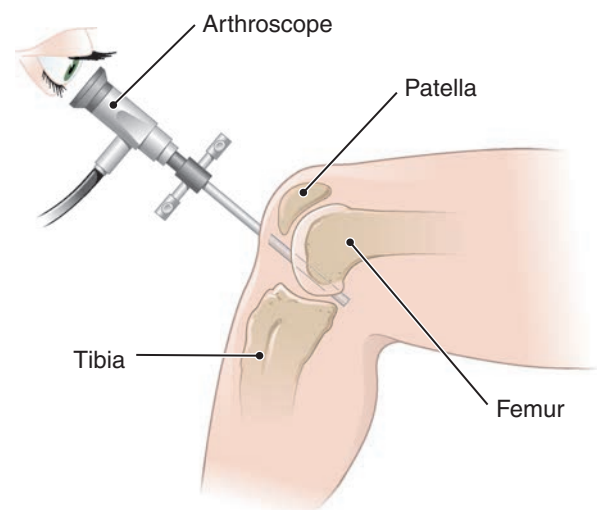


**FIGURE 5-14 Advanced rheumatoid arthritis.** The hands show swelling of the joints and deviation of the fingers.

**Gout** is caused by an increased level of uric acid in the blood, salts of which are deposited in the joints. It mostly occurs in middle-aged men and almost always involves pain at the base of the great toe. Gout may result from a primary metabolic disturbance or may be a secondary effect of another disease, as of the kidneys. It is treated with drugs to suppress formation of uric acid or to increase its elimination (uricosuric agent).

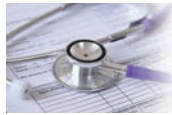### Joint Repair

In **arthroscopy**, orthopedic surgeons use a type of endoscope called an arthroscope to examine a joint's interior and perform surgical repairs if needed (FIG. 5-15). With an arthroscope, it is possible to remove or reshape articular cartilage and repair or replace ligaments.



**FIGURE 5-15 Arthroscopic examination of the knee.** An arthroscope (a type of endoscope) is inserted between projections at the end of the femur to view the posterior of the knee.





## CLINICAL PERSPECTIVES

### Arthroplasty: Bionic Parts for a Better Life

**BOX 5-5**

Since the first total hip replacement in the early 1960s, millions of joint replacements, called arthroplasties, have been performed successfully. Most are done to decrease joint pain in older people with osteoarthritis and other chronic degenerative bone diseases after other treatments such as weight loss, physical therapy, and medication have been tried. Hips and knees are most commonly restored, with over 300,000 hip arthroplasties and more than 700,000 knee replacements performed each year in the United States. Orthopedic surgeons can also replace shoulder, elbow, wrist, hand, ankle, and foot joints.

Artificial, or *prosthetic*, joints are engineered to be strong, nontoxic, corrosion-resistant, and firmly bondable to the patient. Computer-controlled machines now produce individualized joints in less time and at less cost than in the past. Ball-and-socket joint prostheses, like those used in total hip replacement, consist of a cup, ball, and stem. The cup replaces

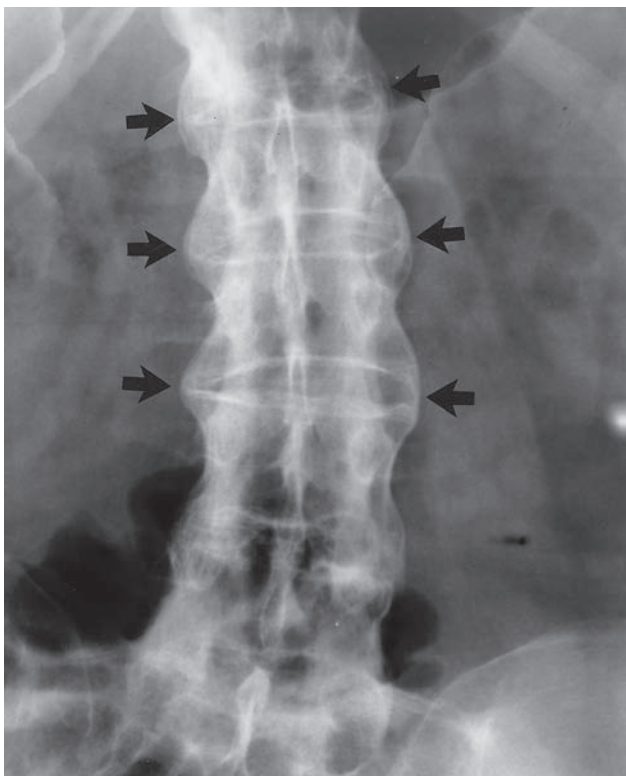
the hip socket (acetabulum) and is bonded to the pelvis using screws or specialized cements. The cup is usually plastic but may also be made of longer-lasting ceramic or metal. The ball, made of metal or ceramic, replaces the femoral head and is attached to the stem, which is implanted into the femoral shaft. Stems are made of various metal alloys such as cobalt and titanium and are often glued into place. Stems designed to promote bone growth into them are commonly used in younger, more active patients because it is believed that they will remain firmly attached for a longer time.

Until recently, arthroplasty was rarely performed on young people because prostheses had life spans of only about 10 years. Today's materials and surgical techniques could increase this time to 20 years or more, and young people who undergo arthroplasty will require fewer replacements later on. This improvement is important because the incidence of sports-related joint injuries in young adults is increasing.

If more conservative treatments do not bring relief, orthopedists may recommend an arthroplasty. This term generally means any joint reconstruction but usually applies to a total or partial joint replacement. Hips, knees, shoulders, and other joints can be replaced with

prostheses to eliminate pain and restore mobility, as explained in **BOX 5-5**.

A final alternative to relieve pain and provide stability at a joint is fusion, or **arthrodesis**, which results in total loss of joint mobility. Surgeons use pins or bone grafts to stabilize the joint and allow bone surfaces to adhere.



**FIGURE 5-16 Ankylosing spondylitis.** A frontal lumbar radiograph showing bone formation bridging the intervertebral disk spaces (arrows) and fusing the vertebrae.

## DISORDERS OF THE SPINE

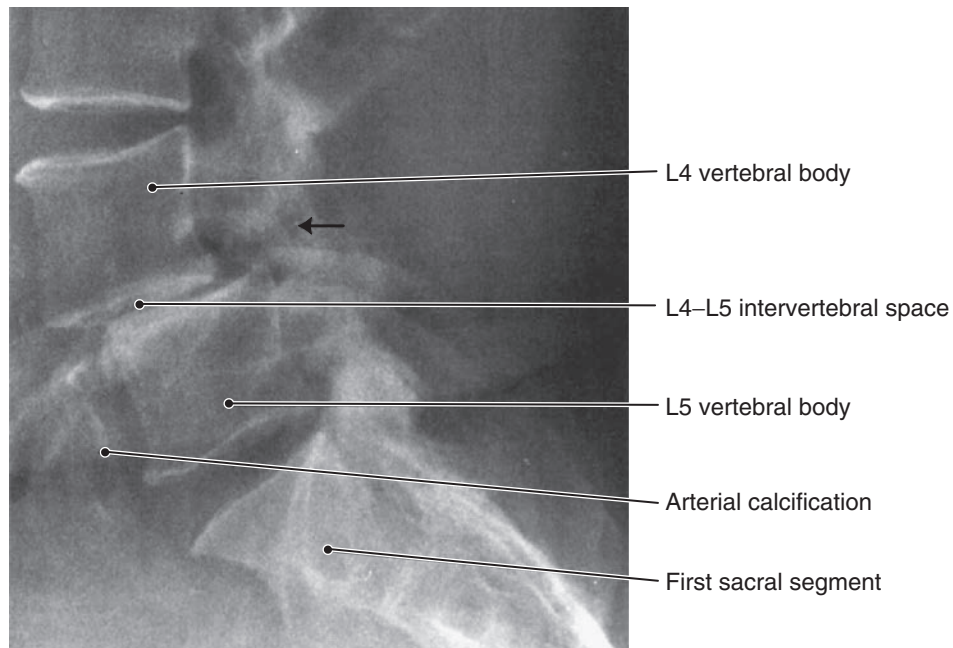
**Ankylosing spondylitis** is a disease of the spine that appears mainly in males. Joint cartilage is destroyed; eventually, the disks between the vertebrae calcify and there is ankylosis (fusion) of the bones (**FIG. 5-16**). Changes begin low in the spine and progress upward, limiting mobility.

**Spondylolisthesis** is a forward sliding of a vertebra over the vertebra below (-listhesis means “a slipping”) (**FIG. 5-17**). The condition follows **spondylolysis**, degeneration of the joint structures that normally stabilize the vertebrae. Spondylolisthesis is most common in the spine’s weight-bearing lumbar region, where it causes low back pain and sometimes leg pain resulting from irritation of spinal nerve roots.

### Herniated Disk

In cases of a **herniated disk** (**FIG. 5-18**), the central mass (nucleus pulposus) of an intervertebral disk protrudes through the disk’s weakened outer ring (annulus fibrosus) into the spinal canal. This commonly occurs in the spine’s lumbosacral or cervical regions as a result of injury or heavy lifting. The herniated or “slipped” disk puts pressure on the spinal cord or spinal nerves, often causing **sciatica**, which is pain along the sciatic nerve in the thigh. There may be spasms of the back muscles, leading to disability.

A herniated disk is diagnosed by myelography, CT scan, MRI, and neuromuscular tests. Treatment is bed rest and



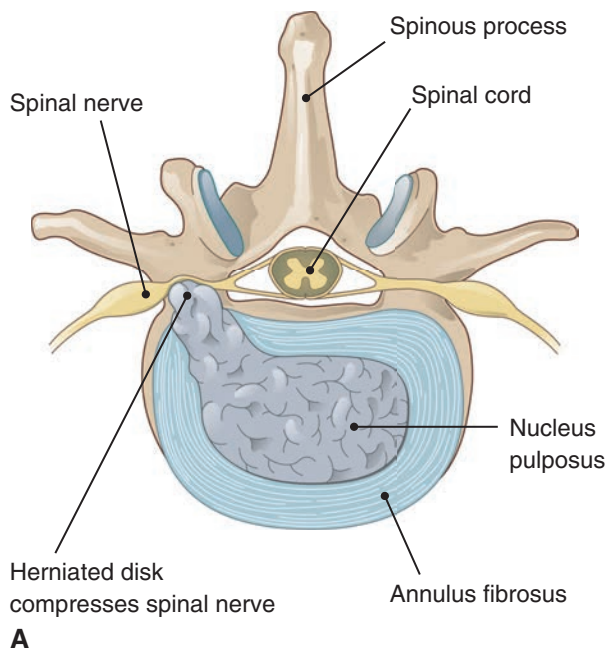
**FIGURE 5-17 Spondylolisthesis.** The L4 vertebral body has slid forward over L5, and there is marked narrowing of the L4–L5 intervertebral disk space.

drugs to reduce pain, muscle spasms, and inflammation followed by an exercise program to strengthen core and associated muscles. In severe cases, it may be necessary to remove the disk surgically in a **discectomy**, sometimes followed by vertebral fusion with a bone graft to stabilize the spine. Using techniques of microsurgery (surgery done under magnification through a small incision), it is now possible to

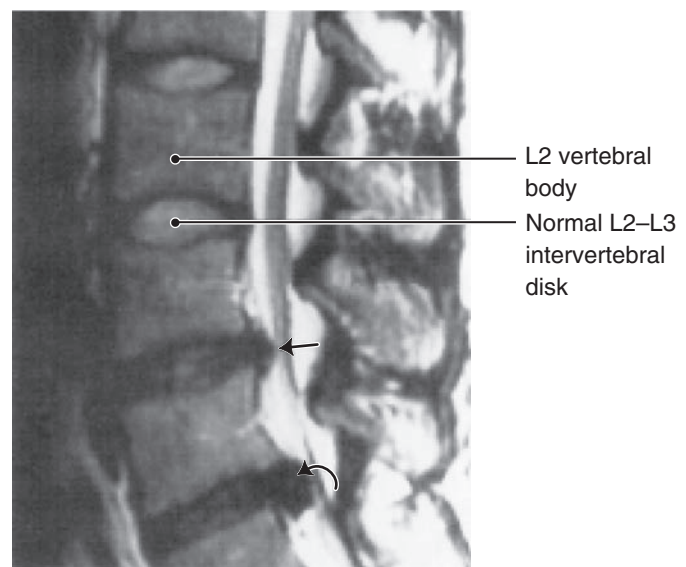
remove an exact amount of extruded disk tissue instead of the entire disk.

### Curvatures of the Spine

The spine has four normal curves—two directed toward the anterior in the cervical and lumbar regions and two directed toward the posterior in the thoracic and sacral regions



**A**



**B**

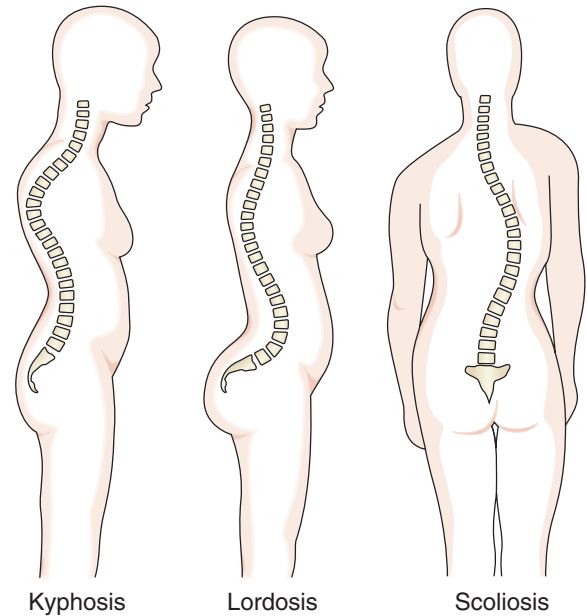
**FIGURE 5-18 Herniated disk.** **A.** The central mass of the disk protrudes into the spinal canal, putting pressure on the spinal nerve. **B.** Magnetic resonance image (MRI) of the lumbar spine, sagittal section, showing herniated disks at multiple levels. There is a bulging L3–L4 disk (*straight arrow*) and an extruded L4–L5 lumbar disk (*curved arrow*).

(see FIG. 5-3). Any exaggeration or deviation of these curves is described as **curvature of the spine**. Three common types of spinal curvatures are shown in FIGURE 5-19 and described as follows:

- **Kyphosis** is an exaggerated curve in the thoracic region, popularly known as “hunchback.”
- **Lordosis** is an exaggerated curve in the lumbar region, popularly known as “swayback.”
- **Scoliosis** is a sideways curvature of the spine in any region. (A case of scoliosis is described in Rachel’s opening case study.)

Spinal curvatures may be congenital or may result from muscle weakness or paralysis, poor posture, joint problems, disk degeneration, extreme obesity, or disease, such as spinal tuberculosis, rickets, or osteoporosis. Extreme cases may cause pain, breathing problems, or degenerative changes.

Bracing the spine during childhood may help to correct a curvature. If surgery is needed, vertebrae are fused and bone grafts and implants are used to stabilize the spine. It is now sometimes possible for surgeons to make these corrections endoscopically.



**FIGURE 5-19** Curvatures of the spine. Kyphosis is an exaggerated thoracic curve; lordosis is an exaggerated lumbar curve; scoliosis is a sideways curve in any region.

## Terminology

## Key Terms

The terms listed below are emphasized in this chapter. Knowing them will help you organize and prioritize your learning. These boldface terms are also found, collectively, with all chapter key terms in the Glossary.

### Disorders

<b>ankylosing spondylitis</b> <i>ang-kih-LO-sing spon-dih-LI-tis</i>	A chronic, progressive inflammatory disease involving the spinal joints and surrounding soft tissue, most common in young males; also called rheumatoid spondylitis
<b>ankylosis</b> <i>ang-kih-LO-sis</i>	Immobility and fixation of a joint
<b>arthritis</b> <i>ar-THRI-tis</i>	Inflammation of a joint
<b>chondrosarcoma</b> <i>kon-dro-sar-KO-mah</i>	A malignant tumor of cartilage
<b>curvature of the spine</b> <i>KER-vah-chure</i>	An exaggerated spinal curve, such as scoliosis, lordosis, or kyphosis (see FIG. 5-19)
<b>degenerative joint disease</b> <i>(DJD)</i>	Osteoarthritis (see below)
<b>fracture</b> <i>FRAK-chure</i>	A break in a bone; in a closed or simple fracture, the broken bone does not penetrate the skin; in an open fracture, there is an accompanying wound in the skin (see FIG. 5-9)
<b>gout</b> <i>gowt</i>	A form of acute arthritis, usually beginning in the knee or foot, caused by deposit of uric acid salts in the joints
<b>herniated disk</b> <i>HER-ne-a-ted</i>	Protrusion of the center (nucleus pulposus) of an intervertebral disk into the spinal canal; ruptured or “slipped” disk
<b>kyphosis</b> <i>ki-FO-sis</i>	An exaggerated curve of the spine in the thoracic region; hunchback, humpback (see FIG. 5-19)

## Terminology

## Key Terms (Continued)

<b>lordosis</b> <i>lor-DO-sis</i>	An exaggerated curve of the spine in the lumbar region; swayback (see <b>FIG. 5-19</b> )
<b>osteoarthritis (OA)</b> <i>os-te-o-ar-THRI-tis</i>	Progressive deterioration of joint cartilage with growth of new bone and soft tissue in and around the joint; the most common form of arthritis; results from wear and tear, injury, or disease; also called degenerative joint disease (DJD)
<b>osteogenic sarcoma</b> <i>os-te-o-JEN-ik</i>	A malignant bone tumor; osteosarcoma
<b>osteomalacia</b> <i>os-te-o-mah-LA-she-ab</i>	A softening and weakening of the bones due to vitamin D deficiency or other disease
<b>osteomyelitis</b> <i>os-te-o-mi-eh-LI-tis</i>	Inflammation of bone and bone marrow caused by infection, usually bacterial
<b>osteopenia</b> <i>os-te-o-PE-ne-ab</i>	A lower-than-average bone density, which may foreshadow osteoporosis
<b>osteoporosis</b> <i>os-te-o-po-RO-sis</i>	A condition characterized by reduction in bone density, most common in white women past menopause; predisposing factors include poor diet, inactivity, and low estrogen levels
<b>Paget disease</b> <i>PAJ-et</i>	Skeletal disease of the elderly characterized by bone thickening and distortion with bowing of long bones; osteitis deformans
<b>Pott disease</b>	Inflammation of the vertebrae, usually caused by tuberculosis
<b>rheumatoid arthritis (RA)</b> <i>RU-mah-toyd</i>	A chronic autoimmune disease of unknown origin resulting in inflammation of peripheral joints and related structures; more common in women than in men
<b>rheumatoid factor</b>	A group of antibodies found in the blood in cases of rheumatoid arthritis and other systemic diseases
<b>rickets</b> <i>RIK-ets</i>	Faulty bone formation in children, usually caused by a deficiency of vitamin D
<b>sciatica</b> <i>si-AT-ib-kah</i>	Severe pain in the leg along the course of the sciatic nerve, usually related to spinal nerve root irritation
<b>scoliosis</b> <i>sko-le-O-sis</i>	A sideways curvature of the spine in any region (see <b>FIG. 5-19</b> )
<b>spondylolisthesis</b> <i>spon-dih-lo-lis-THE-sis</i>	A forward displacement of one vertebra over another (-listhesis means “a slipping”); also pronounced <i>spon-dih-lo-LIS-theb-sis</i>
<b>spondylolysis</b> <i>spon-dih-LOL-ib-sis</i>	Degeneration of the articulating portions of a vertebra allowing for spinal distortion, specifically in the lumbar region
<b>Treatment</b>	
<b>alkaline phosphatase</b> <i>AL-kah-lin FOS-fah-tase</i>	An enzyme needed in the formation of bone; serum activity of this enzyme is useful in diagnosis
<b>arthrocentesis</b> <i>ar-thro-sen-TE-sis</i>	Aspiration of fluid from a joint by needle puncture
<b>arthrodesis</b> <i>ar-THROD-eh-sis</i>	Surgical immobilization (fusion) of a joint; artificial ankylosis
<b>arthroplasty</b> <i>AR-thro-plas-te</i>	Partial or total replacement of a joint with a prosthesis
<b>arthroscopy</b> <i>ar-THROS-ko-pe</i>	Use of an endoscope to examine the interior of a joint or to perform surgery on the joint (see <b>FIG. 5-14</b> ); the instrument used is an arthroscope

(continued)

## Terminology

## Key Terms (Continued)

<b>diskectomy</b> <i>dis-KEK-to-me</i>	Surgical removal of a herniated intervertebral disk; also spelled discectomy
<b>orthopedics</b>	The study and treatment of disorders of the skeleton, muscles, and associated structures; literally “straight” (ortho) “child” (ped); also spelled orthopaedics
<b>reduction of a fracture</b>	Return of a fractured bone to a normal position; may be closed (not requiring surgery) or open (requiring surgery)
<b>traction</b> <i>TRAK-shun</i>	The process of drawing or pulling, such as traction of the head in the treatment of injuries to the cervical vertebrae
<b>Drugs</b>	
<b>anti-inflammatory agent</b>	Drug that reduces inflammation; includes steroids, such as hydrocortisone, and nonsteroidal anti-inflammatory drugs (NSAIDs)
<b>bisphosphonate</b> <i>bis-FOS-fo-nate</i>	Agent used to prevent and treat osteoporosis; increases bone mass by decreasing bone turnover; examples are alendronate (Fosamax), risedronate (Actonel), and ibandronate (Boniva)
<b>nonsteroidal anti-inflammatory drug (NSAID)</b>	Drug that reduces inflammation but is not a steroid; examples include aspirin and ibuprofen and other inhibitors of prostaglandins, naturally produced substances that promote inflammation
<b>selective estrogen receptor modulator (SERM)</b>	Drug that acts on estrogen receptors; raloxifene (Evista) is used to prevent bone loss after menopause; other SERMs are used to prevent and treat estrogen-sensitive breast cancer

## Terminology

## Enrichment Terms

The terms listed below expand on the key terms to increase your knowledge of this chapter topic.

Normal Structure and Function<sup>a</sup>

<b>annulus fibrosus</b> <i>AN-u-lus fi-BRO-sus</i>	Outer ring-like portion of an intervertebral disk (see <b>FIG. 5-17</b> )
<b>calvaria</b> <i>kal-VAR-e-ah</i>	The dome-like upper portion of the skull
<b>coxa</b> <i>KOK-sa</i>	Hip
<b>cruciate ligaments</b> <i>KRU-she-ate</i>	Ligaments that cross in the knee joint to connect the tibia and fibula; they are the anterior cruciate ligament (ACL) and the posterior cruciate ligament (PCL); <i>cruciate</i> means “shaped like a cross”
<b>genu</b> <i>JE-nu</i>	The knee
<b>glenoid cavity</b> <i>GLEN-oyd</i>	The bony socket in the scapula that articulates with the head of the humerus
<b>hallux</b> <i>HAL-uks</i>	The great toe
<b>malleolus</b> <i>mah-LE-o-lus</i>	The projection of the tibia or fibula on either side of the ankle
<b>meniscus</b> <i>meh-NIS-kus</i>	Crescent-shaped disk of cartilage found in certain joints, such as the knee joint; in the knee, the medial meniscus and the lateral meniscus separate the tibia and femur; <i>meniscus</i> means “crescent”; (plural: menisci [ <i>meh-NIS-si</i> ])

## Terminology

## Enrichment Terms (Continued)

<b>nucleus pulposus</b> <i>NU-kle-us pul-PO-sus</i>	The central mass of an intervertebral disk (see FIG. 5-17)
<b>olecranon</b> <i>o-LEK-rah-non</i>	The process of the ulna that forms the elbow
<b>os</b>	Bone (plural: ossa)
<b>osseous</b> <i>OS-e-us</i>	Pertaining to bone
<b>symphysis pubis</b> <i>SIM-fih-sis</i>	The anterior pelvic joint, formed by the union of the two pubic bones (see FIG. 5-4); also called pubic symphysis
<b>Symptoms and Conditions</b>	
<b>achondroplasia</b> <i>ah-kon-dro-PLA-ze-ah</i>	Decreased growth of cartilage in the growth plate of long bones resulting in dwarfism; a genetic disorder
<b>Baker cyst</b>	Mass formed at the knee joint by distention of a bursa with excess synovial fluid resulting from chronic irritation
<b>bunion</b> <i>BUN-yun</i>	Inflammation and enlargement of the metatarsal joint of the great toe, usually with displacement of the great toe toward the other toes
<b>bursitis</b> <i>bur-SI-tis</i>	Inflammation of a bursa, a small fluid-filled sac near a joint; causes include injury, irritation, and joint disease; the shoulder, hip, elbow, and knee are common sites
<b>carpal tunnel syndrome</b>	Numbness and weakness of the hand caused by pressure on the median nerve as it passes through a channel formed by carpal bones
<b>chondroma</b> <i>kon-DRO-mah</i>	A benign tumor of cartilage
<b>Ewing tumor</b> <i>YU-ing</i>	A bone tumor that usually appears in children 5 to 15 years of age; it begins in the shaft of a bone and spreads readily to other bones; it may respond to radiation therapy but then returns; also called Ewing sarcoma
<b>exostosis</b> <i>eks-os-TO-sis</i>	A bony outgrowth from the surface of a bone
<b>giant cell tumor</b>	A bone tumor that usually appears in children and young adults; the ends of the bones are destroyed, commonly at the knee, by a large mass that does not metastasize
<b>hammertoe</b>	Change in position of the toe joints so that the toe takes on a claw-like appearance and the first joint protrudes upward, causing irritation and pain on walking
<b>hallux valgus</b>	Painful condition involving lateral displacement of the great toe at the metatarsal joint; there is also enlargement of the metatarsal head and bunion formation
<b>Heberden nodes</b> <i>HE-ber-den</i>	Small, hard nodules formed in the cartilage of the distal finger joints in osteoarthritis
<b>hemarthrosis</b> <i>heme-ar-THRO-sis</i>	Bleeding into a joint cavity
<b>Legg–Calvé–Perthes disease</b> <i>leg kahl-VA PER-tez</i>	Degeneration (osteochondrosis) of the femur's proximal growth center; the bone is eventually restored, but there may be deformity and weakness; most common in young boys; also called coxa plana
<b>multiple myeloma</b> <i>mi-eh-LO-mah</i>	A cancer of blood-forming cells in bone marrow (see Chapter 11)
<b>neurogenic arthropathy</b> <i>nu-ro-JEN-ikar-THROP-ab-the</i>	Degenerative joint disease caused by impaired nervous stimulation; most common cause is diabetes mellitus; Charcot ( <i>shar-KO</i> ) arthropathy

(continued)

## Terminology

## Enrichment Terms (Continued)

<b>Osgood–Schlatter disease</b> <i>OZ-good SHLAHT-er</i>	Degeneration (osteochondrosis) of the tibia’s proximal growth center causing pain and tendinitis at the knee
<b>osteochondroma</b> <i>os-te-o-kon-DRO-mah</i>	A benign tumor consisting of cartilage and bone
<b>osteochondrosis</b> <i>os-te-o-kon-DRO-sis</i>	Disease of a bone’s growth center in children; tissue degeneration is followed by recalcification
<b>osteodystrophy</b> <i>os-te-o-DIS-tro-fe</i>	Abnormal bone development
<b>osteogenesis imperfecta (OI)</b> <i>os-te-o-JEN-eh-sis im-per-FEK-tab</i>	A hereditary disease resulting in the formation of brittle bones that fracture easily; there is faulty synthesis of collagen, the main structural protein in connective tissue
<b>osteoma</b> <i>os-te-O-mah</i>	A benign bone tumor that usually remains small and localized
<b>Reiter syndrome</b> <i>RI-ter</i>	Chronic polyarthritis that usually affects young men; occurs after a bacterial infection and is common in those infected with HIV; may also involve the eyes and genitourinary tract
<b>spondylosis</b> <i>spon-dih-LO-sis</i>	Degeneration and ankylosis of the vertebrae resulting in pressure on the spinal cord and spinal nerve roots; often applied to any degenerative lesion of the spine
<b>subluxation</b> <i>sub-luk-SA-shun</i>	A partial dislocation
<b>talipes</b> <i>TAL-ih-peze</i>	A deformity of the foot, especially one occurring congenitally; clubfoot
<b>valgus</b> <i>VAL-gus</i>	Bent outward
<b>varus</b> <i>VAR-us</i>	Bent inward
<b>von Recklinghausen disease</b> <i>fon REK-ling-how-zen</i>	Loss of bone tissue caused by increased parathyroid hormone; bones become decalcified and deformed and fracture easily
<b>Diagnosis and Treatment</b>	
<b>allograft</b> <i>AL-o-graft</i>	Graft of tissue between individuals of the same species but different genetic makeup; homograft, allogeneic graft (see autograft)
<b>arthroclasia</b> <i>ar-thro-KLA-ze-ab</i>	Surgical breaking of an ankylosed joint to provide movement
<b>aspiration</b> <i>as-pih-RA-shun</i>	Removal by suction, as removal of fluid from a body cavity; also inhalation, such as accidental inhalation of material into the respiratory tract
<b>autograft</b> <i>AW-to-graft</i>	Graft of tissue taken from a site on or in the body of the person receiving the graft; autologous graft (see allograft)
<b>chondroitin</b> <i>kon-DRO-ih-tin</i>	A complex polysaccharide found in connective tissue; used as a dietary supplement, usually with glucosamine, for treatment of joint pain
<b>glucosamine</b> <i>glu-KOS-ab-mene</i>	A dietary supplement used in the treatment of joint pain
<b>goniometer</b> <i>go-ne-OM-eh-ter</i>	A device used to measure joint angles and movements (root goni/o means “angle”)
<b>iontophoresis</b> <i>i-on-to-for-E-sis</i>	Introduction into the tissue by means of electric current, using the ions of a given drug; used in the treatment of musculoskeletal disorders

## Terminology

## Enrichment Terms (Continued)

<b>laminectomy</b> <i>lam-ih-NEK-to-me</i>	Excision of the posterior arch (lamina) of a vertebra
<b>meniscectomy</b> <i>men-ih-SEK-to-me</i>	Removal of the crescent-shaped cartilage (meniscus) of the knee joint
<b>myelogram</b> <i>MI-eh-lo-gram</i>	Radiograph of the spinal canal after injection of a radiopaque dye; used to evaluate a herniated disk
<b>osteoplasty</b> <i>OS-te-o-plas-te</i>	Scraping and removal of damaged bone from a joint
<b>prosthesis</b> <i>PROS-the-sis</i>	An artificial organ or part, such as an artificial limb

<sup>a</sup>See **BOX 5-6** for a list of bone markings.



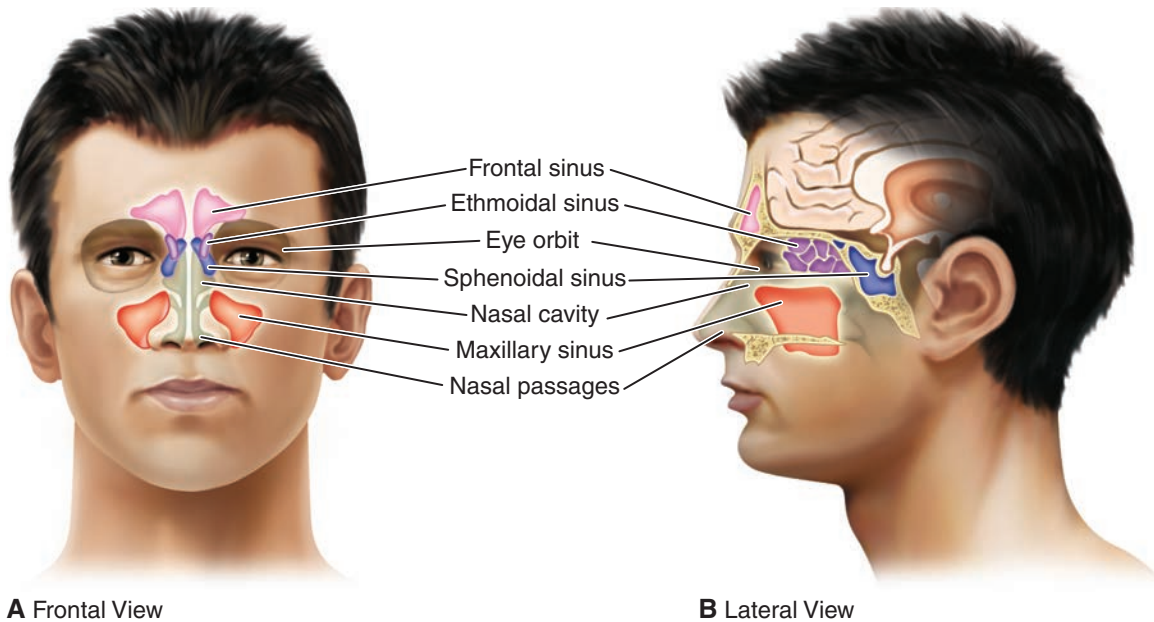
## FOR YOUR REFERENCE

### Bone Markings

BOX 5-6

Marking	Description
<b>condyle</b> <i>KON-dile</i>	smooth, rounded protuberance at a joint
<b>crest</b>	raised, narrow ridge (see iliac crest in <b>FIG. 5-4</b> )
<b>epicondyle</b> <i>ep-ih-KON-dile</i>	projection above a condyle
<b>facet</b> <i>FAS-et</i>	small, flattened surface
<b>foramen</b> <i>for-A-men</i>	rounded opening (see foramen for spinal nerve in <b>FIG. 5-3</b> )
<b>fossa</b> <i>FOS-ah</i>	hollow cavity
<b>meatus</b> <i>me-A-tus</i>	passage or channel, such as a long channel within a bone; also the external opening of a canal, such as the urinary meatus
<b>process</b>	projection (see mastoid process and styloid process in <b>FIG. 5-2</b> )
<b>sinus</b> <i>SI-nus</i>	a space or channel, such as the air-filled spaces in certain skull bones ( <b>FIG. 5-20</b> )
<b>spine</b>	sharp projection (see ischial spine in <b>FIG. 5-4</b> )
<b>trochanter</b> <i>tro-KAN-ter</i>	large, blunt projection as at the top of the femur
<b>tubercle</b> <i>TU-ber-kl</i>	small, rounded projection
<b>tuberosity</b> <i>tu-ber-OS-ih-te</i>	large, rounded projection





A Frontal View

B Lateral View

**FIGURE 5-20 Sinuses.** A sinus is a cavity or hollow space, such as the air-filled chambers in certain skull bones that lighten the skull's weight. **A.** Frontal view of the head showing sinuses. **B.** Lateral view.

## Terminology

## Abbreviations

The abbreviations listed below are emphasized in this chapter. These are also found, collectively, with all chapter abbreviations in Appendix 2.

**ACL** Anterior cruciate ligament

**AE** Above the elbow

**AK** Above the knee

**ASF** Anterior spinal fusion

**BE** Below the elbow, also barium enema

**BK** Below the knee

**BMD** Bone mineral density

**C** Cervical vertebra; numbered C1 to C7

**Co** Coccyx; coccygeal

**DEXA** Dual-energy x-ray absorptiometry (scan)

**DIP** Distal interphalangeal (joint)

**DJD** Degenerative joint disease

**Fx** Fracture

**HNP** Herniated nucleus pulposus

**IM** Intramedullary, also intramuscular

**L** Lumbar vertebra; numbered L1 to L5

**MCP** Metacarpophalangeal (joint)

**MTP** Metatarsophalangeal (joint)

**NSAID(s)** Nonsteroidal anti-inflammatory drug(s)

**OA** Osteoarthritis

**OI** Osteogenesis imperfecta

**ORIF** Open reduction internal fixation

**ortho, ORTH** Orthopedics

**PCL** Posterior cruciate ligament

**PIP** Proximal interphalangeal (joint)

**PSF** Posterior spinal fusion

**RA** Rheumatoid arthritis

**S** Sacrum; sacral

**SERM** Selective estrogen receptor modulator

**T** Thoracic vertebra; numbered T1 to T12

**THA** Total hip arthroplasty

**THP** Total hip precautions

**THR** Total hip replacement

**TKA** Total knee arthroplasty

**TMJ** Temporomandibular joint

**Tx** Traction

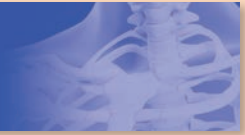## Case Study Revisited

### Rachel's Follow-Up

Rachel underwent a successful surgical procedure and was transferred to the pediatric ICU. While in the ICU she was monitored and cared for by experienced pediatric RNs. She had round the clock assessments on her musculoskeletal and nervous systems, including checking for movement and sensation in her legs. Her vital signs, including pain scale, were monitored. The surgical sites were checked for any appearance of infection. And, proper nutrition was maintained to ensure her body stayed strong. Rachel did need some interventions such as oxygen, an adjustment of her pain meds, and comfort measures during the first days of recovery. She was also seen by the physical therapist (PT) who helped her learn how to ease herself into a seated position in the hospital bed. With further help

from the PT Rachel was able to stand, pivot, and take two steps to the bedside chair. After 30 minutes sitting in the chair, Rachel was helped back to bed. On the PT's next visit Rachel was able to take a short walk in the hallway with assistance. Soon Rachel was feeling stronger. She was able to stand and walk with supervision and a walker. Her pain medicine was changed from IV to pill form.

Rachel felt well enough after four nights in the hospital to be discharged to home and was excited to get back to her own room. Her postoperative course progressed well. Her parents took her to her scheduled outpatient physical therapy and follow-up visits to see the surgeon. Rachel had excellent compliance with all postoperative instructions and was able to resume her musical activities sooner than expected.



This review tests your understanding of the content introduced in this chapter. Follow the instructions for each exercise and check your answers in Appendix 11.

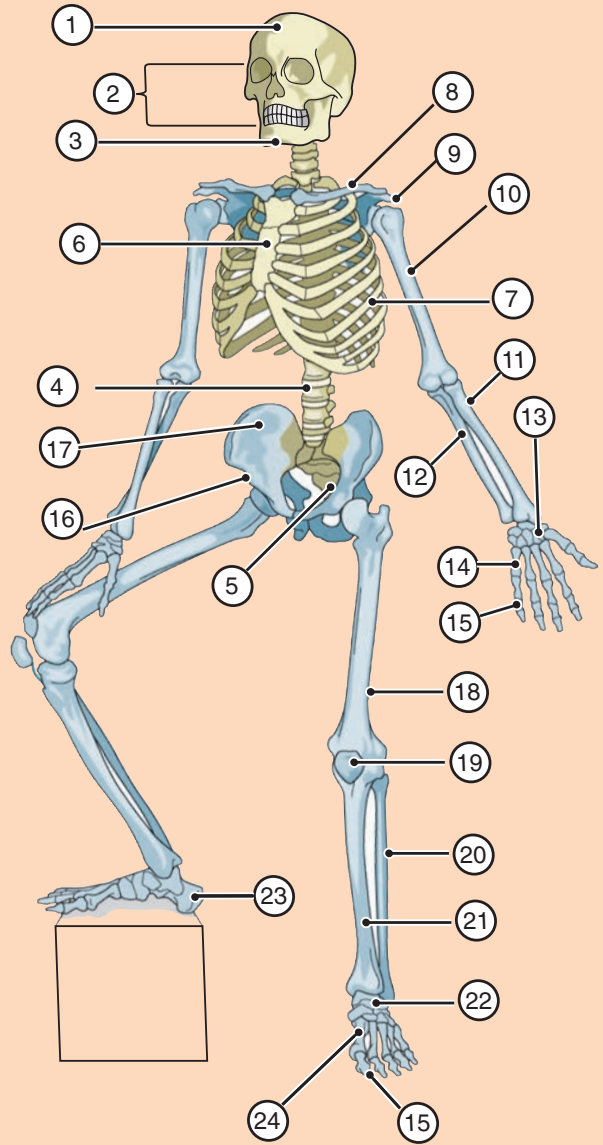
### LABELING EXERCISE

#### THE SKELETON

Write the name of each numbered part on the corresponding line.

- |              |                  |
|--------------|------------------|
| Calcaneus    | Patella          |
| Carpals      | Pelvis           |
| Clavicle     | Phalanges        |
| Cranium      | Radius           |
| Facial bones | Ribs             |
| Femur        | Sacrum           |
| Fibula       | Scapula          |
| Humerus      | Sternum          |
| Ilium        | Tarsals          |
| Mandible     | Tibia            |
| Metacarpals  | Ulna             |
| Metatarsals  | Vertebral column |

1. \_\_\_\_\_
2. \_\_\_\_\_
3. \_\_\_\_\_
4. \_\_\_\_\_
5. \_\_\_\_\_
6. \_\_\_\_\_
7. \_\_\_\_\_
8. \_\_\_\_\_
9. \_\_\_\_\_
10. \_\_\_\_\_
11. \_\_\_\_\_
12. \_\_\_\_\_
13. \_\_\_\_\_
14. \_\_\_\_\_
15. \_\_\_\_\_
16. \_\_\_\_\_
17. \_\_\_\_\_
18. \_\_\_\_\_
19. \_\_\_\_\_
20. \_\_\_\_\_
21. \_\_\_\_\_



22. \_\_\_\_\_
23. \_\_\_\_\_
24. \_\_\_\_\_

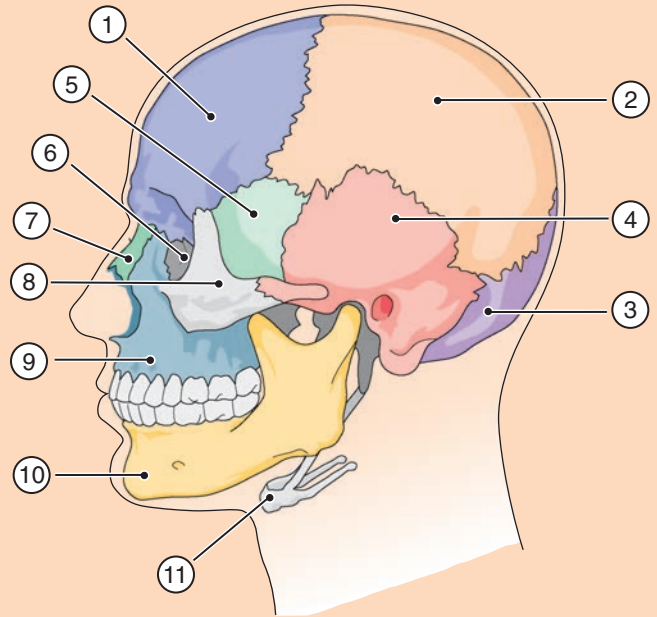
**SKULL FROM THE LEFT**

Write the name of each numbered part on the corresponding line.

Frontal  
Hyoid  
Lacrimal  
Mandible  
Maxilla  
Nasal

Occipital  
Parietal  
Sphenoid  
Temporal  
Zygomatic

- 1. \_\_\_\_\_
- 2. \_\_\_\_\_
- 3. \_\_\_\_\_
- 4. \_\_\_\_\_
- 5. \_\_\_\_\_
- 6. \_\_\_\_\_
- 7. \_\_\_\_\_
- 8. \_\_\_\_\_
- 9. \_\_\_\_\_
- 10. \_\_\_\_\_
- 11. \_\_\_\_\_



5

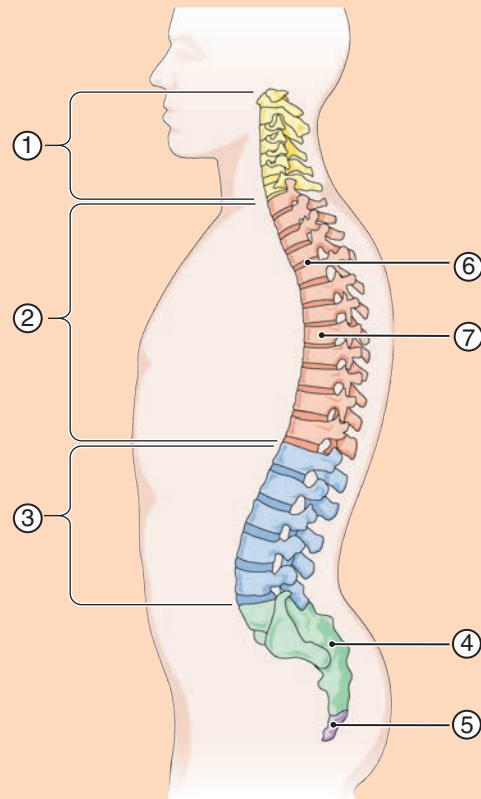
**VERTEBRAL COLUMN**

Write the name of each numbered part on the corresponding line.

Body of vertebra  
Cervical vertebrae  
Coccyx  
Intervertebral disk

Lumbar vertebrae  
Sacrum  
Thoracic vertebrae

- 1. \_\_\_\_\_
- 2. \_\_\_\_\_
- 3. \_\_\_\_\_
- 4. \_\_\_\_\_
- 5. \_\_\_\_\_
- 6. \_\_\_\_\_
- 7. \_\_\_\_\_

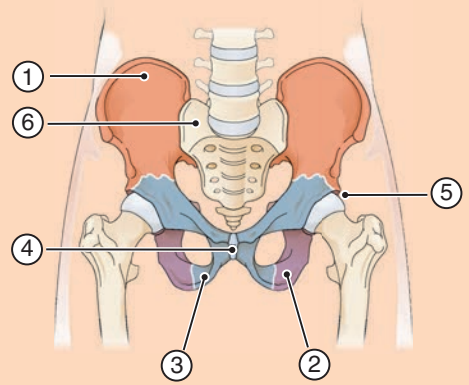


**THE PELVIC BONES**

Write the name of each numbered part on the corresponding line.

- |         |                 |
|---------|-----------------|
| Ilium   | Pubic symphysis |
| Ischium | Acetabulum      |
| Pubis   | Sacrum          |

1. \_\_\_\_\_
2. \_\_\_\_\_
3. \_\_\_\_\_
4. \_\_\_\_\_
5. \_\_\_\_\_
6. \_\_\_\_\_

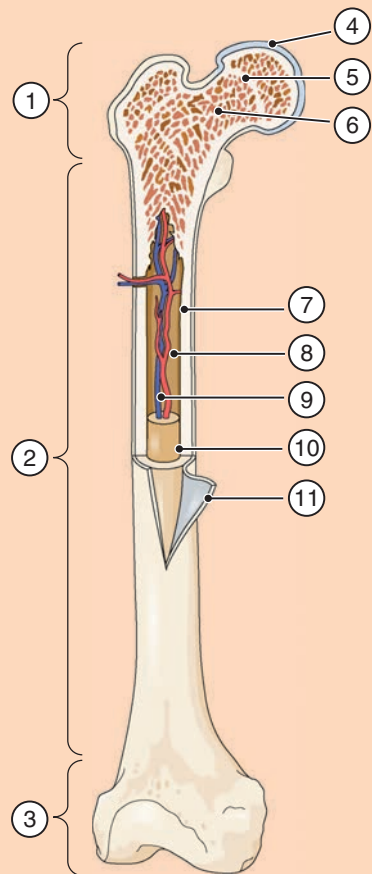


**STRUCTURE OF A LONG BONE**

Write the name of each numbered part on the corresponding line.

- |                               |                                     |
|-------------------------------|-------------------------------------|
| Artery and vein               | Medullary cavity                    |
| Cartilage                     | Periosteum                          |
| Compact bone                  | Proximal epiphysis                  |
| Diaphysis                     | Spongy bone (containing red marrow) |
| Distal epiphysis              | Yellow marrow                       |
| Epiphyseal line (growth line) |                                     |

1. \_\_\_\_\_
2. \_\_\_\_\_
3. \_\_\_\_\_
4. \_\_\_\_\_
5. \_\_\_\_\_
6. \_\_\_\_\_
7. \_\_\_\_\_
8. \_\_\_\_\_
9. \_\_\_\_\_
10. \_\_\_\_\_
11. \_\_\_\_\_



## TERMINOLOGY

### MATCHING

Match the following terms, and write the appropriate letter to the left of each number.

- |                            |  |
|----------------------------|--|
| _____ 1. periosteum        | a. an immovable joint                      |
| _____ 2. epiphysis         | b. breakdown and removal of tissue         |
| _____ 3. suture            | c. cell that breaks down bone              |
| _____ 4. osteoclast        | d. membrane that covers a bone             |
| _____ 5. resorption        | e. end of a long bone                      |
| _____ 6. osteopenia        | a. immobility of a joint                   |
| _____ 7. ankylosis         | b. spinal tap                              |
| _____ 8. kyphosis          | c. displacement of a vertebra              |
| _____ 9. spondylolisthesis | d. exaggerated curve of the thoracic spine |
| _____ 10. rachiocentesis   | e. deficiency of bone tissue               |

### Enrichment Terms

- |                        |   |
|------------------------|---|
| _____ 11. laminectomy  | a. great toe                                      |
| _____ 12. chondroitin  | b. dietary supplement for treatment of joint pain |
| _____ 13. subluxation  | c. excision of part of a vertebra                 |
| _____ 14. hallux       | d. part of the ulna that forms the elbow          |
| _____ 15. olecranon    | e. partial dislocation                            |
| _____ 16. meniscus     | a. breaking of a joint                            |
| _____ 17. goniometer   | b. device used to measure joint angles            |
| _____ 18. arthroclasia | c. knee   |
| _____ 19. genu         | d. crescent-shaped cartilage                      |
| _____ 20. prosthesis   | e. artificial part                                |

### FILL IN THE BLANKS

Complete the sentence with the correct term(s).

21. A fibrous band of connective tissue that connects a muscle to a bone is a(n) \_\_\_\_\_.
22. The type of tissue that covers the ends of the bones at the joints is \_\_\_\_\_.
23. The study and treatment of disorders of the skeleton, muscles, and associated structures is \_\_\_\_\_.
24. The part of the vertebral column that articulates with the ilium is the \_\_\_\_\_.
25. Chondrosarcoma (*kon-dro-sar-KO-mah*) is a malignant tumor of \_\_\_\_\_.
26. The fluid that fills a freely movable joint is \_\_\_\_\_.
27. A fluid-filled sac near a joint is a(n) \_\_\_\_\_.
28. Myelogenesis (*mi-eh-lo-JEN-eh-sis*) is the formation of \_\_\_\_\_.
29. Hemarthrosis (*heme-ar-THRO-sis*) is bleeding into a(n) \_\_\_\_\_.
30. Spondylarthritis (*spon-dil-ar-THRI-tis*) is arthritis of the \_\_\_\_\_.
31. Rachischisis (*ra-KIS-kib-sis*) is fissure of the \_\_\_\_\_.

**DEFINITIONS**

*Define the following words. Remember to use the phonetics in the following exercises to pronounce each word as you work.*

32. myelitis (*mi-eh-LI-tis*) \_\_\_\_\_
33. ossification (*os-sih-fih-KA-shun*) \_\_\_\_\_
34. arthrodesis (*ar-THROD-eh-sis*) \_\_\_\_\_
35. synovectomy (*sin-o-VEK-to-me*) \_\_\_\_\_
36. chondrocyte (*KON-dro-site*) \_\_\_\_\_
37. subcostal (*sub-KOS-tal*) \_\_\_\_\_
38. coccydynia (*kok-se-DIN-e-ah*) \_\_\_\_\_
39. spondylitis (*spon-dih-LI-tis*) \_\_\_\_\_
40. polyarticular (*pol-e-ar-TIK-u-lar*) \_\_\_\_\_
41. intraosteal (*in-trah-OS-te-al*) \_\_\_\_\_
42. peribursal (*per-ih-BER-sal*) \_\_\_\_\_

*Write words for the following definitions.*

43. formation of cartilage \_\_\_\_\_
44. surgical immobilization of a joint \_\_\_\_\_
45. measurement of the pelvis \_\_\_\_\_
46. tumor of bone and cartilage \_\_\_\_\_
47. narrowing of a joint \_\_\_\_\_
48. death (necrosis) of bone tissue \_\_\_\_\_
49. stone in a bursa \_\_\_\_\_
50. incision into the cranium \_\_\_\_\_
51. near the sacrum \_\_\_\_\_
52. pertaining to the sacrum and ilium \_\_\_\_\_
53. surgical excision of the coccyx \_\_\_\_\_
54. endoscopic examination of a joint \_\_\_\_\_

*Find a word in Rachel's opening case study for each of the following.*

55. describing a disease with no known cause \_\_\_\_\_
56. a bone of the shoulder girdle \_\_\_\_\_
57. a bone of the pelvis \_\_\_\_\_
58. the area where T4 is located \_\_\_\_\_
59. incisions into bones \_\_\_\_\_
60. sideways curvature of the spine \_\_\_\_\_

**ADJECTIVES**

Write the adjective form of the following words.

61. sacrum \_\_\_\_\_
62. vertebra \_\_\_\_\_
63. coccyx \_\_\_\_\_
64. pelvis \_\_\_\_\_
65. ilium \_\_\_\_\_

**TRUE-FALSE**

Examine each of the following statements. If the statement is true, write T in the first blank. If the statement is false, write F in the first blank, and correct the statement by replacing the underlined word in the second blank.

	True or False	Correct Answer
66. The growth region of a long bone is in the <u>diaphysis</u> .	_____	_____
67. The tarsal bones are found in the <u>ankle</u> .	_____	_____
68. A slightly moveable joint is a <u>symphysis</u> .	_____	_____
69. The femur is part of the <u>axial</u> skeleton.	_____	_____
70. The <u>cervical</u> vertebrae are located in the neck.	_____	_____
71. The cells that produce cartilage are <u>chondroblasts</u> .	_____	_____
72. Blood cells are formed in <u>yellow</u> bone marrow.	_____	_____
73. An exaggerated lumbar curve of the spine is <u>scoliosis</u> .	_____	_____
74. The term <i>varus</i> means bent <u>inward</u> .	_____	_____

**ELIMINATIONS**

In each of the sets below, underline the word that does not fit in with the rest, and explain the reason for your choice.

75. trochanter — process — hyoid — meatus — condyle  
\_\_\_\_\_
76. lambdoid — occipital — parietal — frontal — sphenoid  
\_\_\_\_\_
77. sacr/o — rachi/o — spondyl/o — vertebr/o — cost/o  
\_\_\_\_\_
78. Pott — sciatic — impacted — comminuted — greenstick  
\_\_\_\_\_
79. T — C — L — Co — OA  
\_\_\_\_\_



**WORD BUILDING**

Write words for the following definitions using the word parts provided. Each word part can be used more than once.

spondyl/o	-plasty	arthr/o	-lysis	-odynia	oste/o	-tome
-----------	---------	---------	--------	---------	--------	-------

80. pain in a joint \_\_\_\_\_
81. destruction of a vertebra \_\_\_\_\_
82. pain in a vertebra \_\_\_\_\_
83. loosening or separation of a joint \_\_\_\_\_
84. instrument for cutting bone tissue \_\_\_\_\_
85. plastic repair of a joint \_\_\_\_\_
86. pain in a bone \_\_\_\_\_
87. instrument for incising a joint \_\_\_\_\_
88. destruction of bone tissue \_\_\_\_\_
89. plastic repair of a bone \_\_\_\_\_

**WORD ANALYSIS**

Define the following words, and give the meaning of the word parts in each. Use a dictionary if necessary.

90. osteochondrosis (*os-te-o-kon-DRO-sis*)
  - a. oste/o \_\_\_\_\_
  - b. chondr/o \_\_\_\_\_
  - c. -sis \_\_\_\_\_
91. spondylosynthesis (*spon-dih-lo-SIN-deh-sis*)
  - a. spondyl/o \_\_\_\_\_
  - b. syn- \_\_\_\_\_
  - c. -desis \_\_\_\_\_
92. exostosis (*eks-os-TO-sis*)
  - a. ex/o \_\_\_\_\_
  - b. ost(e)/o \_\_\_\_\_
  - c. -sis \_\_\_\_\_

93. achondroplasia (*ah-kon-dro-PLA-ze-ah*)

a. a- \_\_\_\_\_

b. chondr/o \_\_\_\_\_

c. plas \_\_\_\_\_

d. -ia \_\_\_\_\_

94. osteoporosis (*os-te-o-po-RO-sis*)

a. osteo- \_\_\_\_\_

b. poro- \_\_\_\_\_

c. -sis \_\_\_\_\_

## Additional Case Studies

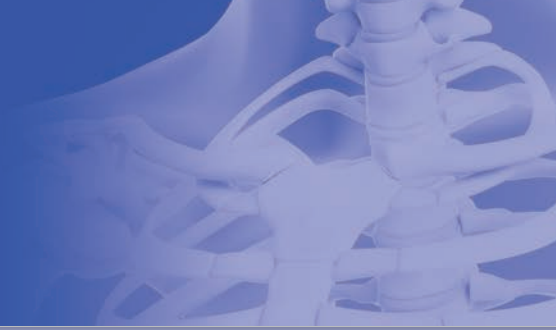### Case Study 5-1: Arthroplasty of the Right TMJ

Susan, a 38 y/o teacher, was admitted for surgery for degenerative joint disease (DJD) of her right temporomandibular joint (TMJ). She has experienced chronic pain in her right jaw, neck, and ear since her automobile accident the previous year. Susan's diagnosis was confirmed by CT scan and was followed up with conservative therapy, which included a bite plate, NSAIDs, and steroid injections. She had also tried hypnosis in an attempt to manage her pain but was not able to gain relief. Her doctor referred her to an oral surgeon who specializes in TMJ disorders. Susan was scheduled for an arthroplasty of the right TMJ to remove diseased bone on the articular surface of the right mandibular condyle.

On the following day, she was transported to the OR for surgery. She was given general endotracheal anesthesia, and a vertical incision was made from the superior aspect of the right ear down to the base of the attachment of the right earlobe. After appropriate dissection and retraction, the posterior–superior aspect of the right zygomatic arch was bluntly dissected anteroposteriorly. With a nerve stimulator, the zygomatic branch of the facial

nerve was identified and retracted from the surgical field with a vessel loop. The periosteum was then incised along the superior aspect of the arch. An inferior dissection was then made along the capsular ligament and retracted posteriorly. With a Freer elevator, the meniscus was freed, and a horizontal incision was made to the condyle. With a Hall drill and saline coolant, a high condylectomy of approximately 3 mm of bone was removed while conserving function of the external pterygoid muscle. The stump of the condyle was filed smooth and irrigated copiously with NS. The lateral capsule, periosteum, subcutaneous tissue, and skin were then closed with sutures. The facial nerve was tested before closing and confirmed to be intact. A pressure pack and Barton bandage were applied. The sponge, needle, and instrument counts were correct. Estimated blood loss (EBL) was approximately 50 mL.

Susan was discharged on the second postoperative day with instructions for a soft diet, daily mouth-opening exercises, an antibiotic (Keflex 500 mg po q6h), Tylenol no. 3 po q4h p.r.n. for pain, and four weekly postoperative appointments.



## Case Study 5-1 Questions

Follow the instructions for each question and check your answers in Appendix 11.

**Multiple Choice.** Select the best answer, and write the letter of your choice to the left of each number.

- |  |   |
|--|---|
| <p>_____ 1. A condylectomy is</p> <ul style="list-style-type: none"><li>a. removal of a joint capsule</li><li>b. removal of a rounded bone protuberance</li><li>c. enlargement of a cavity</li><li>d. removal of a tumor</li></ul> <p>_____ 2. The articular surface of a bone is located</p> <ul style="list-style-type: none"><li>a. under the epiphysis</li><li>b. at a joint</li><li>c. at a muscle attachment</li><li>d. at a tendon attachment</li></ul> | <p>_____ 3. The dissection directed anteroposteriorly was done</p> <ul style="list-style-type: none"><li>a. posterior–superior</li><li>b. circumferentially</li><li>c. front to back</li><li>d. top to bottom</li></ul> |
|--|---|

5

Write terms from the case study that means the following.

- 4. pertaining to the cheek bone \_\_\_\_\_
- 5. the membrane around a bone \_\_\_\_\_
- 6. a crescent-shaped cartilage in a joint \_\_\_\_\_
- 7. plastic repair of a joint \_\_\_\_\_

Define the following abbreviations. Refer to Appendix 2, if needed.

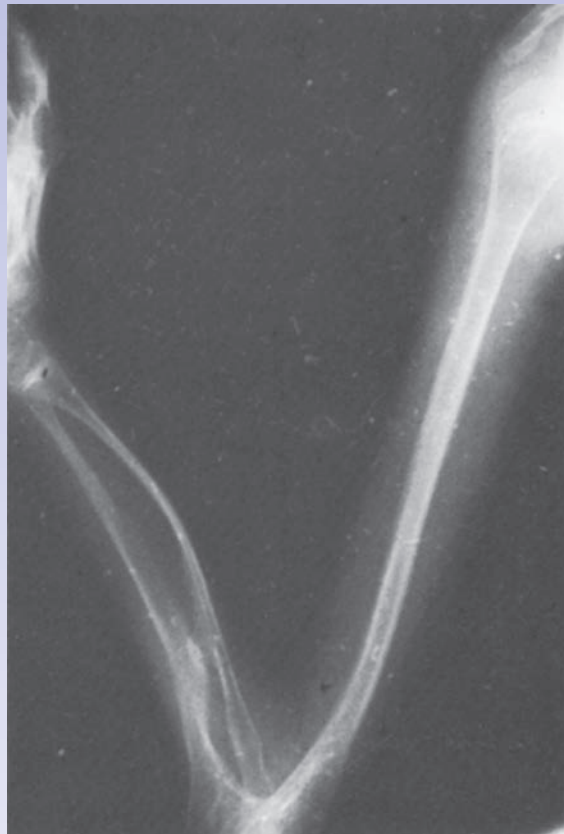
- 8. DJD \_\_\_\_\_
- 9. NS \_\_\_\_\_
- 10. TMJ \_\_\_\_\_
- 11. EBL \_\_\_\_\_

## Case Study 5-2: Osteogenesis Imperfecta

Cooper, a 3 y/o boy with osteogenesis imperfecta (OI) type III, was admitted to the pediatric orthopedic hospital for treatment of yet another fracture. Since birth he has had 15 arm and leg fractures as a result of his congenital disease. This latest fracture occurred when he twisted at the hip while standing in his wheeled walker. He has been in a research study and receives a bisphosphonate infusion every 2 months. He is short in stature with short limbs for his age and has bowing of both legs.

Cooper was transferred to the OR and carefully lifted to the OR table by the staff. After he was anesthetized, he was positioned with gentle manipulation, and

his left hip was elevated on a small gel pillow. After skin preparation and sterile draping, a stainless-steel rod was inserted into the medullary canal of his left femur to reduce and stabilize the femoral fracture. The muscle, fascia, subcutaneous tissue, and skin were sutured closed. Three nurses gently held Cooper in position on a pediatric spica box while the surgeon applied a hip spica (body cast) to stabilize the fixation, protect the leg, and maintain abduction. Cooper was transferred to the postanesthesia care unit (PACU) for recovery. The surgeon dictated the procedure as an open reduction internal fixation (ORIF) of the left femur with intramedullary (IM) rodding and application of spica cast.



**Osteogenesis imperfecta.** X-ray of the upper extremity shows the thin bones and fractures that result from defective collagen production.

## Case Study 5-2 Questions

Follow the instructions for each question and check your answers in Appendix 11.

**Multiple Choice.** Select the best answer, and write the letter of your choice to the left of each number.

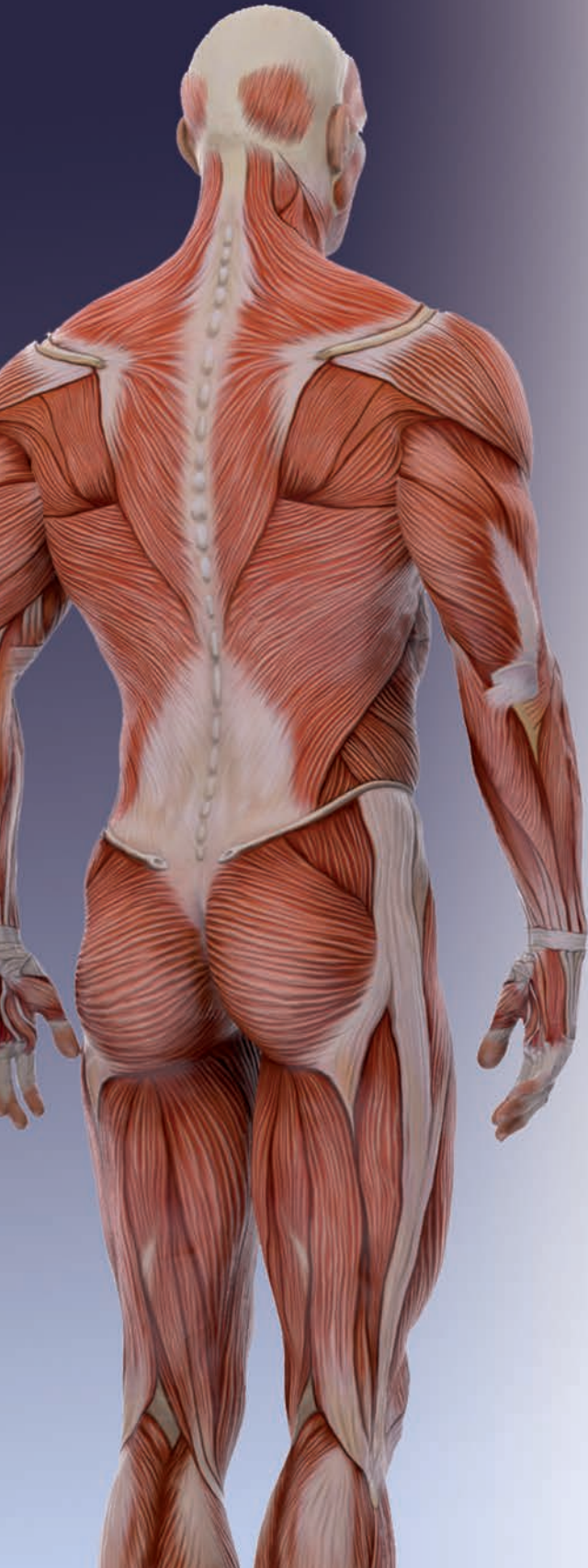- |   |  |
|---|--|
| _____ 1. Another term for bow-legged is | _____ 2. An IM rod is placed               |
| a. knock-kneed                          | a. inferior to the femoral condyle         |
| b. adduction                            | b. into the acetabulum                     |
| c. varus                                | c. within the medullary canal              |
| d. valgus                               | d. lateral to the epiphysial growth plates |

Write terms from the case study that means the following.

3. formation of bone tissue \_\_\_\_\_
4. a break in a bone \_\_\_\_\_
5. present at birth \_\_\_\_\_
6. the thigh bone \_\_\_\_\_

Define the following abbreviations.

7. OI \_\_\_\_\_
8. ORIF \_\_\_\_\_
9. OR \_\_\_\_\_
10. IM \_\_\_\_\_
11. PACU \_\_\_\_\_



## Pretest

**Multiple Choice.** Select the best answer, and write the letter of your choice to the left of each number. To check your answers go to Appendix 11.

- \_\_\_\_\_ 1. The neuromuscular junction is between a muscle and a
  - a. gland
  - b. neuron
  - c. bone
  - d. gonad
- \_\_\_\_\_ 2. In the muscular system, the opposite of the origin is the
  - a. counterorigin
  - b. agonist
  - c. insertion
  - d. diaphragm
- \_\_\_\_\_ 3. The quadriceps femoris muscle forms the anterior part of the
  - a. neck
  - b. back
  - c. abdomen
  - d. thigh
- \_\_\_\_\_ 4. The opposite of flexion is
  - a. rotation
  - b. antiflexion
  - c. relaxation
  - d. extension
- \_\_\_\_\_ 5. The opposite of abduction is
  - a. adduction
  - b. circumduction
  - c. periduction
  - d. pronation
- \_\_\_\_\_ 6. The band of connective tissue that attaches a muscle to a bone is a
  - a. cartilage
  - b. tendon
  - c. bursa
  - d. diaphysis
- \_\_\_\_\_ 7. Polymyositis is inflammation of many
  - a. sense organs
  - b. glands
  - c. muscles
  - d. bones
- \_\_\_\_\_ 8. The word *kinesis* means
  - a. movement
  - b. bending
  - c. stretching
  - d. pain



## Learning Objectives

After careful study of this chapter, you should be able to:

- 1 Compare the location and function of smooth, cardiac, and skeletal muscles. **P190**
- 2 Describe the typical structure of a skeletal muscle. **P190**
- 3 Briefly describe the mechanism of muscle contraction. **P190**
- 4 Explain how muscles work together to produce movement. **P191**
- 5 Describe the main types of movements produced by muscles. **P192**
- 6 List some of the criteria for naming muscles, and give examples of each. **P192**
- 7 Identify and use the roots pertaining to the muscular system. **P197**
- 8 Describe at least seven disorders that affect muscles. **P198**
- 9 Interpret abbreviations pertaining to muscles. **P204**
- 10 Analyze several case studies involving muscles. **PP189, 212**

## Case Study: Thomas's Brachial Plexus Injury



### Chief Complaint

Thomas, a 16 y/o high school student, had a severe lacrosse accident that resulted in a flail arm. He had sustained right brachial plexus injury and had no recovery. He has continued to take medication for neurologic pain. He was scheduled to see his orthopedic surgeon for a possible brachial plexus exploration.

### Examination

The orthopedic surgeon examined Thomas and noted that there had not been any change in his condition since the previous visit. Thomas still had no feeling or motion in his right shoulder or arm. He had atrophy over the supraspinatus and infraspinatus muscles and also subluxation of his shoulder and deltoid atrophy. He had no active motion of the right upper extremity and no sensation. The rest of his orthopedic exam showed full ROM of his hips, knees, and ankles with intact sensation and palpable distal pulses as well as normal motor function. He was diagnosed with a possible middle trunk brachial plexus injury from C7.

### Clinical Course

Thomas and his parents had previous discussions with the surgeon and were aware of the prognosis and treatment plan. With middle trunk brachial plexus injury, damage to the subscapular nerve will interrupt conduction to the subscapularis and teres major muscles. Damage to the long thoracic nerve prevents conduction to the serratus anterior muscles. Injury to the pectoral nerves affects the pectoralis major and minor muscles.

Thomas was scheduled for an EMG, nerve conduction studies, and somatosensory evoked potentials (SSEPs). His diaphragm was examined under fluoroscopy to R/O phrenic nerve injury. The results of the diagnostic studies indicated that Thomas had most likely sustained a middle trunk brachial plexus injury. Thomas was scheduled for a brachial plexus exploration with possible bilateral sural (calf) nerve graft, nerve transfer, or gracilis muscle graft from his right thigh.

**Case Study Revisited: Once you complete this chapter, please review the case follow-up on p. 205.**

## Ancillaries *At-A-Glance*

Visit the web resource to access the following resources.

### Learning Resources

- eBook
- A&P Module with Heart & Lung Sounds
- Image Bank
- TestPrep
- Animations
- Audio Pronunciation Glossary



## Introduction

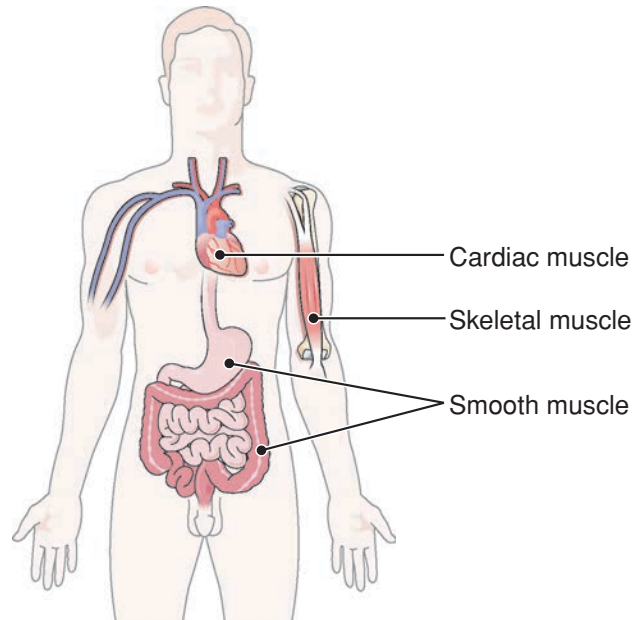
The main characteristic of **muscle** tissue is its ability to contract. When stimulated, muscles shorten to produce movement of the skeleton, vessel walls, or internal organs. Muscles may also remain partially contracted to maintain posture. In addition, the heat generated by muscle contraction is the main source of body heat.

## Types of Muscles

There are three types of muscle tissue in the body (FIG. 6-1):

- **Smooth** (visceral) **muscle** makes up the walls of the hollow organs, such as the stomach, intestines, and uterus, and the walls of ducts, such as the blood vessels and bronchioles. Smooth muscle operates involuntarily and is responsible for peristalsis, the wave-like movements that propel materials through the systems.
- **Cardiac muscle** makes up the myocardium of the heart wall. It functions involuntarily and is responsible for the heart's pumping action.
- **Skeletal muscle** is attached to bones and is responsible for voluntary movement. It also maintains posture and generates a large proportion of body heat. All of these voluntary muscles together make up the muscular system.

branch of a neuron meets a muscle cell, the neurotransmitter **acetylcholine (ACh)** is released from small vesicles (sacs) in an axon branch. ACh interacts with the muscle cell membrane to prompt cellular contraction. Two special protein filaments in muscle cells, **actin** and **myosin**, interact to produce the contraction. ATP (the cell's energy compound) and calcium are needed for this response. **BOX 6-1** discusses the use of steroids to increase muscle development and strength.



**FIGURE 6-1 Muscle types.** Smooth muscle makes up the walls of ducts and hollow organs, such as the stomach and intestine; cardiac muscle makes up the heart wall; skeletal muscle is attached to bones.

## Skeletal Muscle

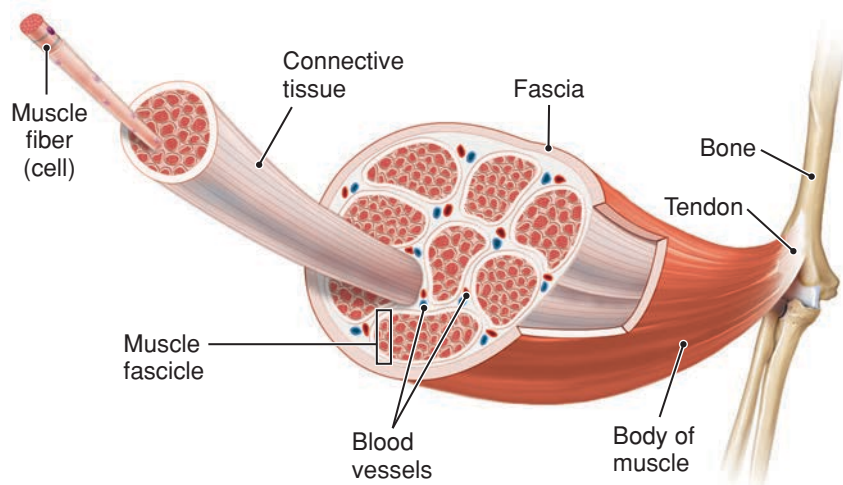
The discussion that follows describes the characteristics of skeletal muscle, which has been the most extensively studied of the three muscle types.

### MUSCLE STRUCTURE

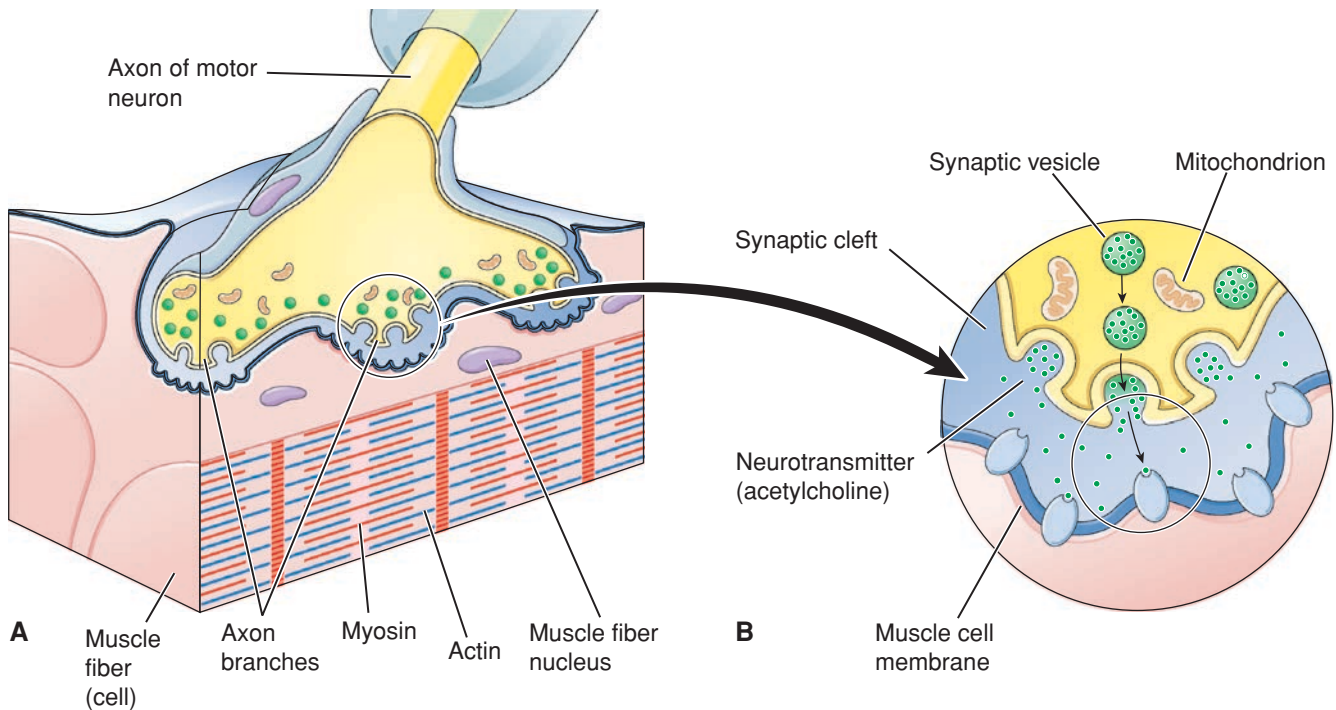
Muscles are composed of individual cells, often referred to as fibers because they are so long and thread-like. These cells are held together in **fascicles** (bundles) by connective tissue (FIG. 6-2). Covering each muscle is a sheath of connective tissue or **fascia**. These supporting tissues merge to form the **tendons** that attach the muscle to bones.

### MUSCLE ACTION

Skeletal muscles are stimulated to contract by motor neurons of the nervous system (FIG. 6-3). At the **neuromuscular junction (NMJ)**, the synapse (junction) where a



**FIGURE 6-2 Structure of a skeletal muscle.** Connective tissue coverings are shown as is the tendon that attaches the muscle to a bone.

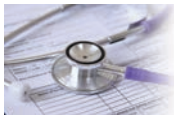

**FIGURE 6-3 Neuromuscular junction (NMJ).** **A.** The branched end of a motor neuron makes contact with the membrane of a muscle fiber (cell). **B.** Enlarged view of the NMJ showing release of neurotransmitter (acetylcholine) from a neuron and its attachment to a muscle cell membrane. Mitochondria generate ATP, the cells' energy compound.

Most skeletal muscles contract rapidly to produce movement and then relax rapidly unless stimulation continues. Sometimes muscles are kept in a steady partially contracted state, to maintain posture, for example. This state of firmness is called **tonus**, or *muscle tone*.

Muscles work in pairs to produce movement at the joints. Any muscle that produces a given movement is described as an **agonist**. If a group of muscles

is involved in the action, the main one is called the **prime mover**. When an agonist contracts, an opposing muscle, the **antagonist**, must relax. For example, when the brachialis muscle on the anterior surface of the upper arm contracts as the prime mover to flex the arm, the triceps brachii on the posterior surface must relax (**FIG. 6-4**). When the arm is extended, these actions are reversed; the triceps brachii contracts, and



## CLINICAL PERSPECTIVES

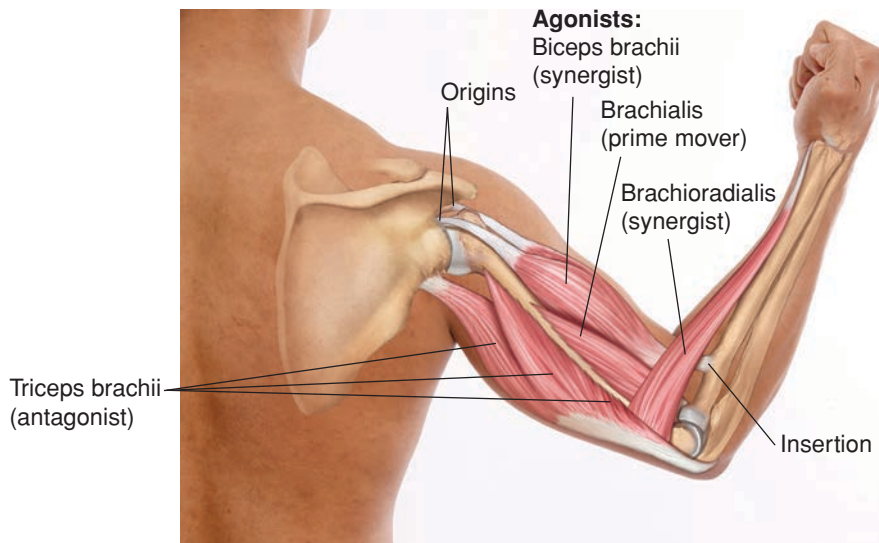
### Anabolic Steroids: Winning at All Costs?

BOX 6-1

Anabolic steroids mimic the effects of the male sex hormone testosterone by promoting metabolism and stimulating growth. These drugs are legally prescribed to promote muscle regeneration and prevent atrophy from disuse after surgery. However, athletes also purchase them illegally, using them to increase muscle size and strength and improve endurance.

When steroids are used illegally to enhance athletic performance, the doses needed are large enough to cause serious side effects. They increase blood cholesterol levels, which may lead to atherosclerosis, heart disease, kidney failure, and

stroke. Steroids damage the liver, making it more susceptible to disease and cancer, and they suppress the immune system, increasing the risk of infection and cancer. In men, steroids cause impotence, testicular atrophy, low sperm count, infertility, and the development of female sex characteristics such as breasts (gynecomastia). In women, steroids disrupt ovulation and menstruation and produce male sex characteristics such as breast atrophy, clitoral enlargement, increased body hair, and deepening of the voice. In both sexes, steroids increase the risk for baldness, and especially in men, they cause mood swings, depression, and violence.



**FIGURE 6-4 Muscles work together.** When the brachialis, the agonistic prime mover, flexes the arm, the triceps brachii, the antagonist, must relax. Synergists, the biceps brachii and the brachioradialis, assist in this action. When the arm is extended, these muscle actions are reversed. This figure also shows three attachments of the biceps brachii, two origins and one insertion.

the brachialis must relax. Any muscle that assists the prime mover to produce an action is called a **synergist**. For example, the biceps brachii (most visible on the anterior surface when the arm is flexed) and the brachioradialis assist the brachialis to flex the arm.

In a given movement, the point where the muscle is attached to a stable part of the skeleton is the **origin**; the point where a muscle is attached to a moving part of the skeleton is the **insertion** (see **FIG. 6-4**).

**BOX 6-2** describes various types of movements at the joints; these are illustrated in **FIGURE 6-5**. See also **BOX 6-3** for a description of careers in physical fitness.

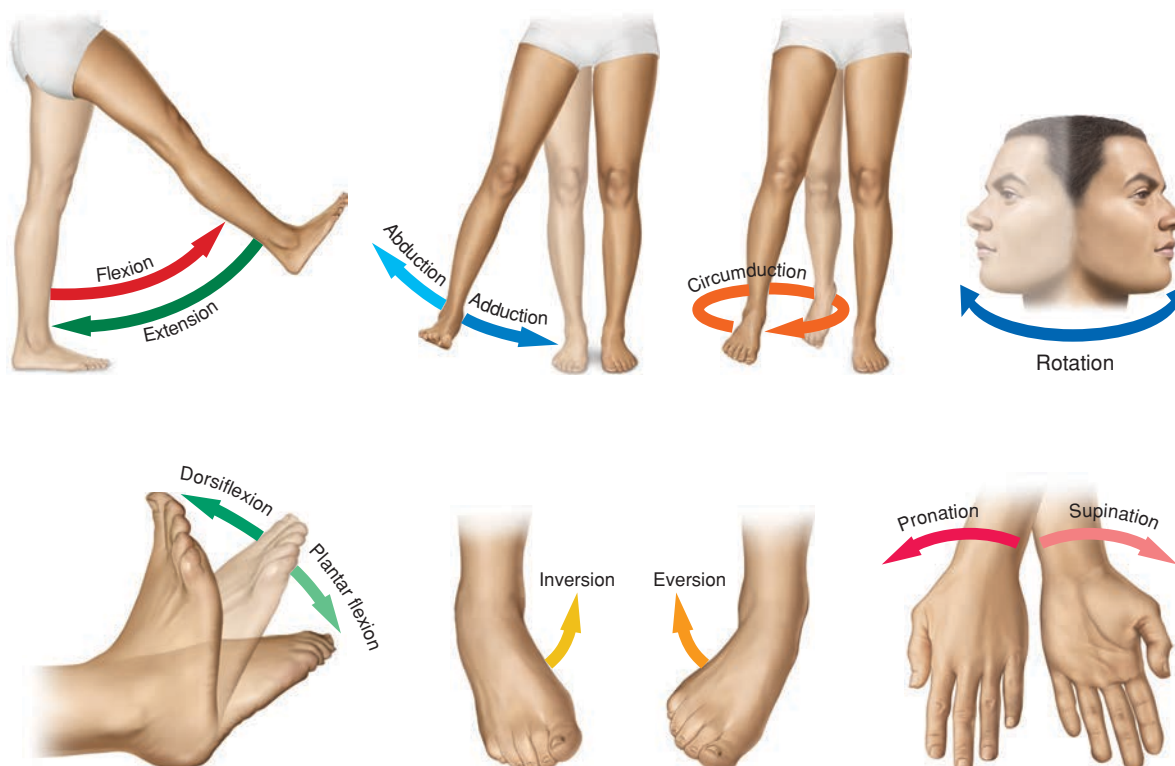


## FOR YOUR REFERENCE

### Types of Movement

BOX 6-2

Movement	Definition	Example
<b>flexion</b> <i>FLEK-shun</i>	closing the angle at a joint	bending at the knee or elbow
<b>extension</b> <i>eks-TEN-shun</i>	opening the angle at a joint	straightening at the knee or elbow
<b>abduction</b> <i>ab-DUK-shun</i>	movement away from the midline of the body	outward movement of the arm at the shoulder
<b>adduction</b> <i>ah-DUK-shun</i>	movement toward the midline of the body	return of lifted arm to the body
<b>rotation</b> <i>ro-TA-shun</i>	turning of a body part on its own axis	turning of the forearm from the elbow
<b>circumduction</b> <i>ser-kum-DUK-shun</i>	circular movement from a central point	tracing a circle with an outstretched arm
<b>pronation</b> <i>pro-NA-shun</i>	turning downward	turning the palm of the hand downward
<b>supination</b> <i>su-pin-A-shun</i>	turning upward	turning the palm of the hand upward
<b>eversion</b> <i>e-VER-zhun</i>	turning outward	turning the sole of the foot outward
<b>inversion</b> <i>in-VER-zhun</i>	turning inward	turning the sole of the foot inward
<b>dorsiflexion</b> <i>dor-shi-FLEK-shun</i>	bending backward	moving the foot so that the toes point upward, away from the sole of the foot
<b>plantar flexion</b>	bending the sole of the foot	pointing the toes downward



**FIGURE 6-5 Types of movement.** Muscle contraction produces movement at the joints. All movements are shown in reference to the anatomic position. Some muscles are named for the type of movement they produce, such as flexor, extensor, and adductor.



## HEALTH PROFESSIONS

### Careers in Exercise and Fitness

BOX 6-3

Several related careers are concerned with the management of exercise programs for therapy, health maintenance, and recreation. The American College of Sports Medicine (ACSM) at [acsm.org](http://acsm.org) has information on these fields and some certification programs.

- Exercise physiologists study the mechanisms involved in physical exercise and the body's physiologic responses to exercise. They design programs for general health, athletics, and rehabilitation for disability or disease, such as cardiovascular and respiratory diseases. They may work in clinical settings in cooperation with physicians, in private industry, in health clubs, or in teaching. Most exercise physiologists (EPs) have master's degrees, but some jobs may require only a bachelor's degree. A PhD is needed for teaching or research. EPs may be certified through ACSM or the Center for Exercise Physiology (CEP). The American Society of Exercise Physiologists at [asep.org](http://asep.org) has information about this profession.
- Athletic trainers specialize in the prevention and treatment of musculoskeletal injuries. They advise clients on the proper use of exercise equipment and devices, such as braces, that help prevent injuries. They work in cooperation with physicians in private establishments, in health care facilities, and with athletes and sports teams. An athletic trainer's job may have a set schedule, but if the job is for a sports team, it may require long and irregular hours. A majority of athletic trainers have master's degrees or higher.

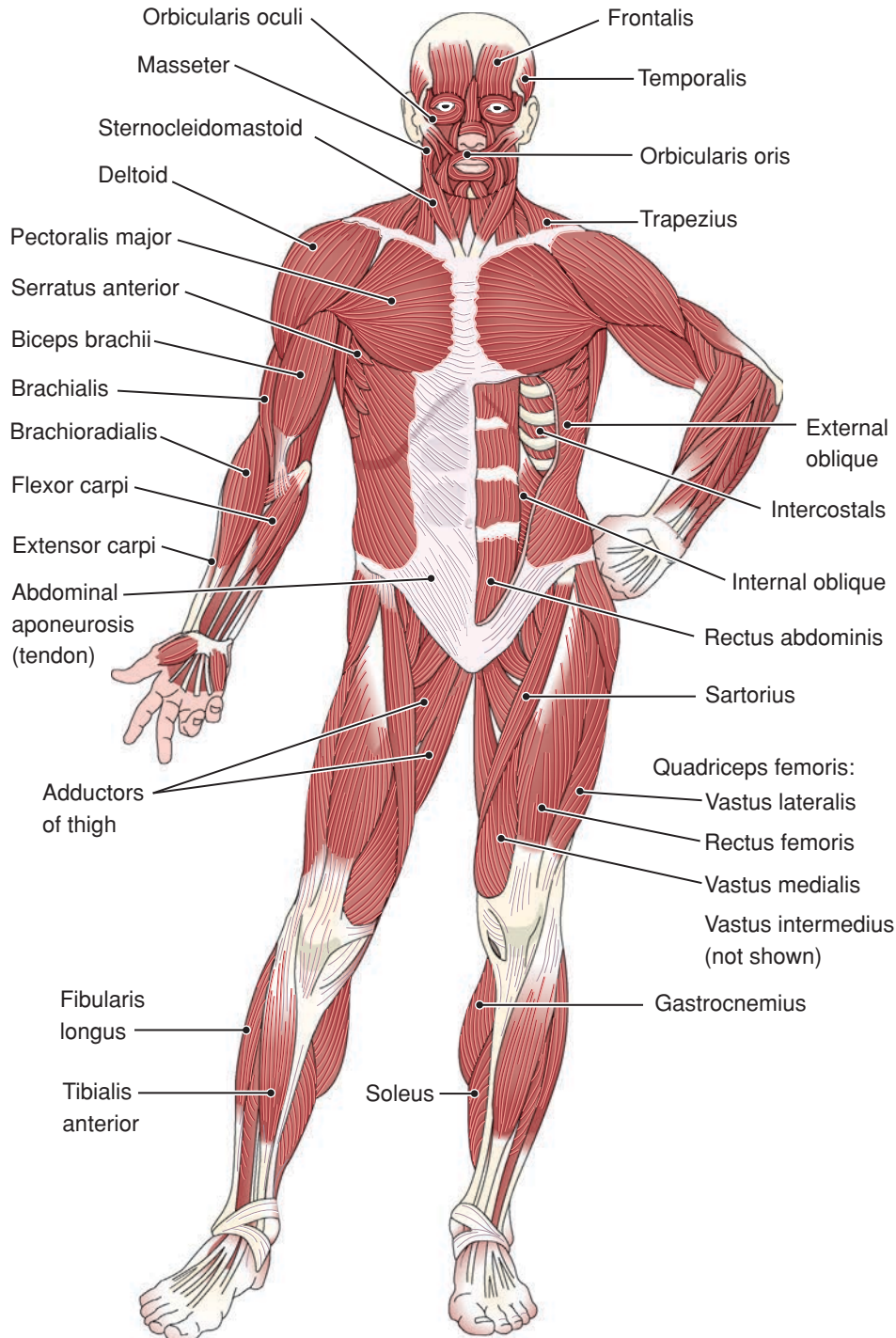
Employment opportunities in health care and teaching are expected to be good, although jobs with sports teams are limited. The National Athletic Trainers' Association at [nata.org](http://nata.org) has more information on this career.

- Fitness workers make up a category that includes a variety of career activities, such as personal trainers and group fitness, yoga, and Pilates instructors. These professionals lead, instruct, and motivate individuals or groups in all types of exercise activities. Traditionally, they have worked in studios, health clubs, or private homes, but they are increasingly found in the workplace, where they organize and direct fitness programs for employees. Their jobs may involve administrative duties as well. Personal trainers must be certified, and certification is encouraged for other fitness professionals. Candidates must have a high school diploma and certification in CPR, and must pass a written exam and sometimes a practical exam as well. Increasingly, a bachelor's degree is required, and those who wish to progress to management jobs may need a higher degree. Instructors who specialize in a particular exercise method, such as Pilates or yoga, must pass their own training standards. Job opportunities in these fields are expected to increase with an aging population and increasing concern for good health and physical fitness. The National Commission for Certifying Agencies at [credentialingexcellence.org](http://credentialingexcellence.org) can help locate accredited fitness certification programs.

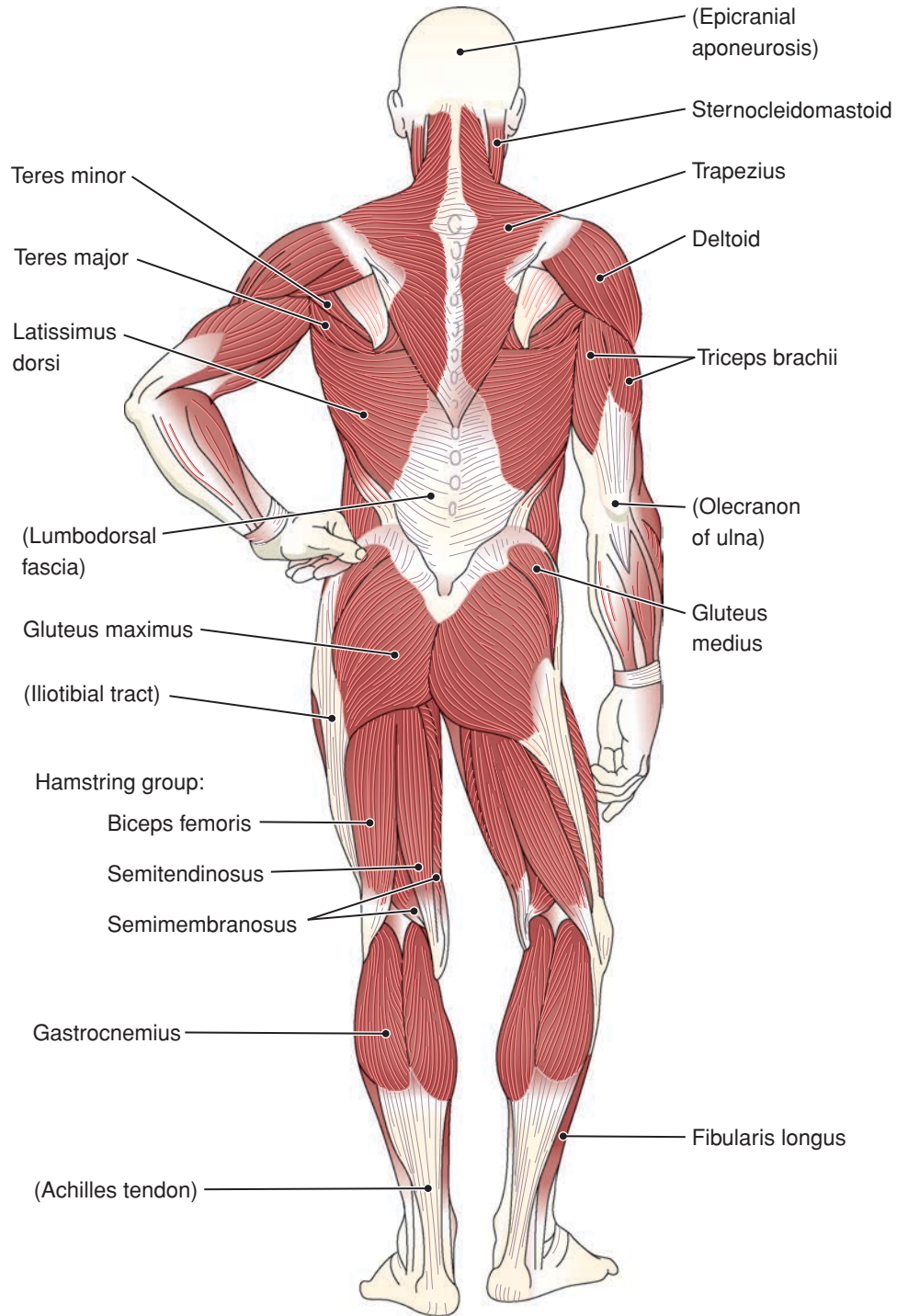
## NAMING OF MUSCLES

A muscle can be named by its location (e.g., near a bone), by the direction of its fibers, or by its size, shape, or number of attachment points (heads), as indicated by the suffix *-ceps* (see FIG. 6-4). It may also be named for its action, adding the

suffix *-or* to the root for the action. For example, a muscle that produces flexion at a joint is a flexor. Examine the muscle diagrams in FIGURES 6-6 and 6-7. See how many of these criteria you can find in the muscle names. Note that sometimes more than one criterion is used in the name.



**FIGURE 6-6** Superficial muscles, anterior view.



**FIGURE 6-7** Superficial muscles, posterior view. Associated structures are labeled in parentheses.

## Terminology

## Key Terms

The terms listed below are emphasized in this chapter. Knowing them will help you organize and prioritize your learning. These boldface terms are also found, collectively, with all chapter key terms in the Glossary.

## Normal Structure and Function

<b>acetylcholine (ACh)</b> <i>as-eb-til-KO-lene</i>	A neurotransmitter that stimulates contraction of skeletal muscles
<b>actin</b> <i>AK-tin</i>	One of the two contractile proteins in muscle cells; the other is myosin
<b>agonist</b> <i>AG-on-ist</i>	A muscle that carries out a given movement (from Greek <i>agon</i> meaning “contest,” “struggle”)
<b>antagonist</b> <i>an-TAG-o-nist</i>	The muscle that opposes an agonist; it must relax when the agonist contracts
<b>cardiac muscle</b> <i>KAR-de-ak</i>	Involuntary muscle that makes up the heart wall
<b>fascia</b> <i>FASH-e-ah</i>	The fibrous sheath of connective tissue that covers a muscle; called deep fascia to differentiate it from the superficial fascia that underlies the skin (root: <i>fasci/o</i> ) (plural: <i>fasciae</i> )
<b>fascicle</b> <i>FAS-ih-kl</i>	A small bundle, as of muscle or nerve fibers
<b>insertion</b> <i>in-SER-shun</i>	In a given movement, the point where a muscle is attached to a moving part of the skeleton
<b>muscle</b> <i>MUS-el</i>	An organ that produces movement by contracting; also the tissue that composes such organs (roots: <i>my/o</i> , <i>muscul/o</i> )
<b>myosin</b> <i>MI-o-sin</i>	One of the two contractile proteins in muscle cells; the other is actin
<b>neuromuscular junction (NMJ)</b> <i>nu-ro-MUS-ku-lar JUNK-shun</i>	The point of contact, or synapse, between a branch of a motor neuron and a muscle cell
<b>origin</b> <i>OR-ih-jin</i>	In a given movement, the point where a muscle is attached to a stable part of the skeleton
<b>prime mover</b>	The main muscle involved in a given movement
<b>skeletal muscle</b> <i>SKEL-eh-tal</i>	Voluntary muscle that moves the skeleton and maintains posture
<b>smooth muscle</b>	Involuntary muscle that makes up the wall of hollow organs, vessels, and ducts; visceral muscle
<b>synergist</b> <i>SIN-er-jist</i>	A muscle that assists a prime mover to produce a given movement
<b>tendon</b> <i>TEN-dun</i>	A fibrous band of connective tissue that attaches a muscle to a bone (roots: <i>ten/o</i> , <i>tendin/o</i> )
<b>tonus</b> <i>TO-nus</i>	A state of steady, partial muscle contraction that maintains firmness; muscle tone (root: <i>ton/o</i> )

## Roots Pertaining to Muscles

See TABLE 6-1.

Table 6-1		Roots Pertaining to Muscles	
Root	Meaning	Example	Definition of Example
my/o	muscle	myositis <sup>a</sup> <i>mi-o-SI-tis</i>	inflammation of muscle
muscul/o	muscle	musculature <i>MUS-kyu-lab-chur</i>	muscle arrangement in a part or the whole body
in/o	fiber	inotropic <i>in-o-TROP-ik</i>	acting on (muscle) fibers
fasci/o	fascia	fasciodesis <i>fash-e-OD-eh-sis</i>	binding (suture) of a fascia to a tendon or other fascia
ten/o, tendin/o	tendon	tenostosis <i>ten-os-TO-sis</i>	ossification of a tendon
ton/o	tone	cardiotonic <i>kar-de-o-TON-ik</i>	having a strengthening action on the heart muscle
erg/o	work	ergonomics <i>er-go-NOM-iks</i>	study of the efficient use of energy during work
kin/o-, kine, kinesi/o, kinet/o	movement	kinesis <i>ki-NE-sis</i>	movement (adjective: kinetic)

<sup>a</sup>Note addition of s to this root before the suffix *-itis*.

### Exercise 6-1

Complete the exercise. To check your answers go to Appendix 11.

Define the following adjectives.

1. muscular \_\_\_\_\_
2. fascial \_\_\_\_\_
3. kinetic \_\_\_\_\_
4. tendinous \_\_\_\_\_
5. tonic \_\_\_\_\_

Write words for the following definitions.

6. incision into a muscle \_\_\_\_\_
7. inflammation of a muscle with its tendon \_\_\_\_\_
8. study of movement \_\_\_\_\_
9. excision of fascia \_\_\_\_\_
10. pain in a tendon \_\_\_\_\_

Fill in the blanks.

11. Myoglobin (*mi-o-GLO-bin*) is a type of protein (globin) found in \_\_\_\_\_.
12. Inosclerosis (*in-o-skle-RO-sis*) is hardening of tissue from an increase in \_\_\_\_\_.
13. Fasciitis (*fash-e-I-tis*) is inflammation of \_\_\_\_\_.
14. Dystonia (*dis-TO-ne-ah*) is abnormal muscle \_\_\_\_\_.

(continued)



## Exercise 6-1 (Continued)

15. An ergograph (*ER-go-graf*) is an instrument for recording muscle \_\_\_\_\_ .
16. Kinesia (*ki-NE-se-ab*) is a term for sickness caused by \_\_\_\_\_ .
17. Myofibrils (*mi-o-FI-brils*) are small fibers found in \_\_\_\_\_ .
18. The muscularis layer in the wall of a hollow organ or duct is composed of \_\_\_\_\_ .

### Define the following terms.

19. hypermyotonia (*hi-per-mi-o-TO-ne-ab*) \_\_\_\_\_
20. fasciorrhaphy (*fash-e-OR-ab-fe*) \_\_\_\_\_
21. tendinitis (*ten-dih-NI-tis*), also tendonitis (*ten-don-I-tis*) \_\_\_\_\_
22. musculotendinous (*mus-ku-lo-TEN-dih-nus*) \_\_\_\_\_
23. tenodesis (*ten-OD-eh-sis*) \_\_\_\_\_
24. myalgia (*mi-AL-je-ab*) \_\_\_\_\_
25. kinesitherapy (*ki-ne-sib-THER-ab-pe*) \_\_\_\_\_
26. dyskinesia (*dis-ki-NE-se-ab*) \_\_\_\_\_
27. atony (*AT-o-ne*) \_\_\_\_\_
28. ergogenic (*er-go-JEN-ik*) \_\_\_\_\_
29. myofascial (*mi-o-FASH-e-al*) \_\_\_\_\_
30. myotenositis (*mi-o-ten-o-SI-tis*) \_\_\_\_\_

## Clinical Aspects of the Muscular System

Muscle function may be affected by disorders elsewhere, particularly in the nervous system and connective tissue. The conditions described below affect the muscular system directly or involve the muscles but have not been described in other chapters. Any disorder of muscles is described as a myopathy.

Techniques for diagnosing muscle disorders include electrical studies of muscle in action, **electromyography (EMG)**, and serum assay of enzymes released in increased amounts from damaged muscles, mainly **creatine kinase (CK)**.

### MUSCULAR DYSTROPHY

**Muscular dystrophy** refers to a group of hereditary diseases involving progressive, noninflammatory muscular degeneration. There is weakness and wasting of muscle tissue with its gradual replacement by connective tissue and fat. There may also be cardiomyopathy (cardiac muscle disease) and mental impairment.

Duchenne muscular dystrophy, is an inherited form of the disease found most frequently in male children. It

results from a defect in a protein that stabilizes the links between myofibrils within the muscle cell and the cell membrane. When this protein (dystrophin) is abnormal, every muscle contraction damages the cells, eventually leading to the replacement of muscle tissue with scar tissue. The result is progressive weakness, and eventual paralysis. Even heart muscle is affected, so that death usually comes from weakness of the cardiac muscle (heart failure) or paralysis of the respiratory muscles.

Life expectancy is about 25 years for the most common type of muscular dystrophy and about 40 years for the other types. Progress toward definitive treatment for inherited forms of the disease may be possible now that scientists have identified the genetic defects that cause them.

### MULTIPLE-SYSTEM DISORDERS INVOLVING MUSCLES

#### Polymyositis

**Polymyositis** is inflammation of skeletal muscle leading to weakness, frequently associated with dysphagia (difficulty in swallowing) or cardiac problems. The cause is unknown and may be related to viral infection or autoimmunity. Often the disorder is associated with some other

systemic disease such as rheumatoid arthritis or lupus erythematosus.

When the skin is involved, the condition is termed **dermatomyositis**. In this case, there is erythema (redness of the skin), dermatitis (inflammation of the skin), and a typical lilac-colored rash, predominantly on the face. In addition to enzyme studies and EMG, clinicians use muscle biopsy in diagnosis.

### Fibromyalgia Syndrome

**Fibromyalgia syndrome (FMS)** is a difficult-to-diagnose condition involving the muscles. It is associated with widespread muscle aches, tenderness, and stiffness, along with fatigue and sleep disorders in the absence of neurologic abnormalities or any other known cause. The disorder may coexist with other chronic diseases, may follow a viral infection, and may involve immune system dysfunction. A current theory is that FMS results from hormonal or neurotransmitter imbalances that increase sensitivity to pain. Treatments for FMS include a carefully planned exercise program and medication with pain relievers, muscle relaxants, or antidepressants.

### Chronic Fatigue Syndrome

**Chronic fatigue syndrome (CFS)** involves persistent fatigue of no known cause that may be associated with impaired memory, sore throat, painful lymph nodes, muscle and joint pain, headaches, sleep problems, and immune disorders. The condition often occurs after a viral infection. Epstein–Barr virus (the cause of mononucleosis), herpesvirus, and other viruses have been suggested as possible causes of CFS. No traditional or alternative therapies have been consistently successful in treating CFS.

### Myasthenia Gravis

**Myasthenia gravis (MG)** is an acquired autoimmune disease caused by the loss of acetylcholine receptors in the muscle cell membrane when a person's immune system mistakenly recognizes these receptors as foreign and attacks them with antibodies. Without these receptors, the neurons cannot trigger muscle contraction. There is a progressive loss of muscle power characterized by chronic muscular fatigue brought on by the slightest exertion. It affects adults and begins with the muscles of the head. Drooping of the eyelids (ptosis) is a common early sign.

### Amyotrophic Lateral Sclerosis

Also named *Lou Gehrig disease* after a famous baseball player who died of the disorder, **amyotrophic lateral sclerosis (ALS)** is a progressive degeneration of motor neurons that leads to muscle atrophy (amyotrophy). Early signs are weakness, cramping, and muscle twitching. The facial or respiratory muscles may be affected early depending on the site of degeneration. Mental function, sensory perception, and bowel and bladder function usually remain intact. The disease progresses and eventually leads to death from respiratory muscle paralysis in 3 to 5 years.

### STRESS INJURIES

Not as grave as the above diseases perhaps, but much more common, are musculoskeletal disorders caused by physical stress. These include accidental injuries and work- or sports-related damage caused by overexertion or repetitive motion, so-called **repetitive strain injury (RSI)**. Damages to soft tissues include **sprain**, injury to a ligament caused by abnormal or excessive force at a joint but without bone dislocation or fracture; muscle **strain**, inflammation or tearing of ligaments and tendons; and bursitis. **Tenosynovitis**, commonly called **tendinitis**, is inflammation of a tendon, tendon sheath, and the synovial membrane at a joint. The signs of these injuries are pain, fatigue, weakness, stiffness, numbness, and reduced range of motion (ROM). (The origins of some colorful terms for such conditions are given in **BOX 6-4**.)

Stress injuries may involve any muscles or joints, but some common upper extremity conditions are:

- **Rotator cuff (RTC) injury**—The RTC, which strengthens the shoulder joint, is formed by four muscles, the supraspinatus, infraspinatus, teres minor, and subscapularis, the “SITS” muscles (**FIG. 6-8**). Inflammation or tearing of the RTC can occur in people who repeatedly perform overhead activities, such as swimming, painting, or pitching.
- **Epicondylitis**—The medial and lateral epicondyles (projections) of the distal humerus are attachment points for muscles that flex and extend the wrist and fingers. Inflammation of these tendons of origin causes pain at



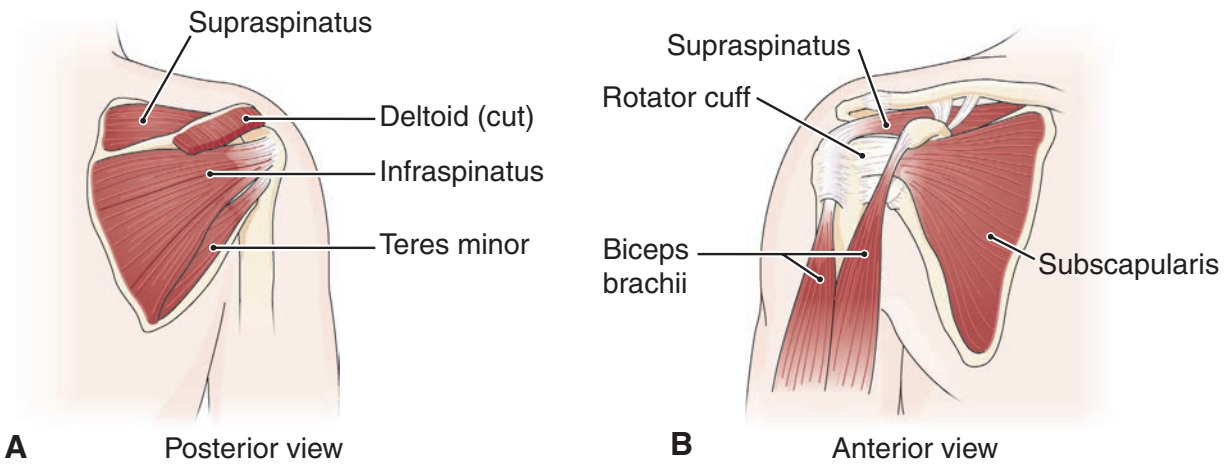
## FOCUS ON WORDS

### Some Colorful Musculoskeletal Terms

BOX 6-4

Some common terms for musculoskeletal disorders have interesting origins. A charley horse describes muscular strain and soreness, especially in the legs. The term comes from common use of the name Charley for old lame horses that were kept around for family use when they could no longer be used for hard work. Wryneck, technically torticollis, uses the word *wry*, meaning twisted or turned, as in the word *awry* (*ah-ri*), meaning amiss or out of position.

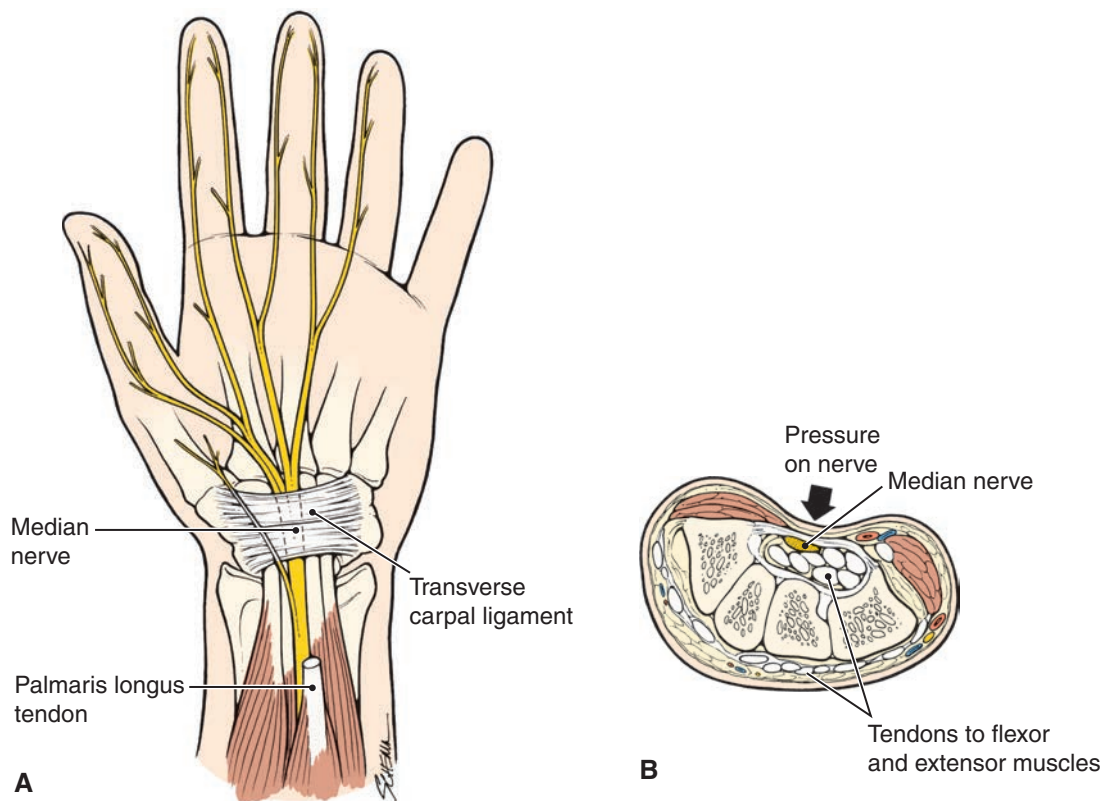
A bunion, technically called hallux valgus, is an enlargement of the first joint of the great toe with bursitis at the joint. It probably comes from the word *bony*, changed to *bunny*, and used to mean a bump on the head and then a swelling on a joint. A *clavus* is commonly called a *corn* because it is a hardened or horny thickening of the skin in an area of friction or pressure.



**FIGURE 6-8 Anatomy of the rotator cuff.** Four muscles contribute to the rotator cuff that strengthens the shoulder. They are the supraspinatus, infraspinatus, teres minor, and subscapularis. Two adjacent muscles are also shown, the deltoid and biceps brachii. **A.** Posterior. **B.** Anterior.

the elbow and forearm on lifting, carrying, squeezing, or typing. These stress injuries are often sports-related, leading to the terms “golfer’s elbow” and “tennis elbow” for medial and lateral epicondylitis, respectively. A brace worn below the elbow to distribute stress on the joint may be helpful.

- Carpal tunnel syndrome (CTS)—CTS involves the tendons of the finger flexor muscles and the nerves that supply the hand and fingers (FIG. 6-9). Hand numbness and weakness are caused by pressure on the median nerve as it passes through a channel formed by the carpal (wrist) bones. CTS commonly appears in people who use their



**FIGURE 6-9 Carpal tunnel syndrome.** **A.** Pressure on the median nerve as it passes through the carpal (wrist) bones causes numbness and weakness in the areas of the hand supplied by the nerve. **B.** Cross-section of the wrist showing compression of the median nerve.

hands and fingers strenuously, such as musicians and keyboarders.

- **Trigger finger**—This is a painful snapping, triggering, or locking of a finger as it is moved. It is caused by inflammation and swelling of the flexor tendon sheath at the metacarpophalangeal joint that prevents the tendon from sliding back and forth.

Some stress injuries that involve the lower extremities are:

- **Hamstring strain**—The hamstring is a large muscle group in the posterior thigh that extends from the hip to the knee and flexes the knee (see FIG. 6-7). A “pulled hamstring” is common in athletes who stop and start running suddenly. It is treated with stretching and strengthening activities.
- **Shin-splint**—This is pain in the leg’s anterior tibial region from running on hard surfaces or overuse of the foot flexors, as in athletes and dancers. Help comes from

good shoes with adequate support and avoidance of hard surfaces for exercise.

- **Achilles tendinitis**—The Achilles (*a-KIL-eze*) tendon is a large tendon that attaches the calf muscles to the heel and is used to plantar flex the foot at the ankle (see FIGS. 6-5 and 6-7). Damage to the Achilles tendon hampers or prevents walking and running.

### Treatment

Orthopedists diagnose musculoskeletal disorders by MRI and other imaging techniques, ROM measurements, and strength testing. Treatment of stress injuries usually begins conservatively with rest, elevation, ice packs, bracing, and medications, such as analgesics, anti-inflammatory agents, and muscle relaxants. (The acronym RICE represents this simple approach—rest, ice, compression, elevation.) Treatment may progress to steroid injections, ultrasound therapy for deep heat, strengthening exercises, or even surgery.

## Terminology

## Key Terms

The terms listed below are emphasized in this chapter. Knowing them will help you organize and prioritize your learning. These boldface terms are also found, collectively, with all chapter key terms in the Glossary.

### Disorders

<b>amyotrophic lateral sclerosis (ALS)</b> <i>ah-mi-o-TROF-ik</i>	A disease caused by motor neuron degeneration resulting in muscular weakness and atrophy; Lou Gehrig disease
<b>chronic fatigue syndrome (CFS)</b> <i>KRON-ik fab-TEGE SIN-drome</i>	A disease of unknown cause that involves persistent fatigue along with muscle and joint pain and other symptoms; may be virally induced
<b>dermatomyositis</b> <i>der-mah-to-mi-o-SI-tis</i>	A disease of unknown origin involving muscular inflammation as well as dermatitis and skin rashes
<b>fibromyalgia syndrome (FMS)</b> <i>fi-bro-mi-AL-je-ab</i>	A disorder associated with widespread muscular aches and stiffness and having no known cause
<b>muscular dystrophy</b> <i>DIS-tro-fe</i>	A group of hereditary muscular disorders marked by progressive weakness and muscular atrophy
<b>myasthenia gravis (MG)</b> <i>mi-as-THE-ne-ab GRAH-vis</i>	A disease characterized by progressive muscular weakness; an autoimmune disease affecting the neuromuscular junction
<b>polymyositis</b> <i>pol-e-mi-o-SI-tis</i>	A disease of unknown cause involving muscular inflammation and weakness
<b>repetitive strain injury (RSI)</b>	Tissue damage caused by repeated motion, usually overuse of the arm or hand in occupational activities such as writing, typing, painting, or using hand tools; also called repetitive motion injury, cumulative trauma injury, overuse syndrome
<b>sprain</b> <i>sprane</i>	Injury to a ligament caused by abnormal or excessive force at a joint, but without bone dislocation or fracture
<b>strain</b> <i>strane</i>	Trauma to a muscle because of overuse or excessive stretch; if severe, may involve muscular tearing, bleeding, separation of a muscle from its tendon, or tendon separation from a bone
<b>tendinitis</b> <i>ten-dih-NI-tis</i>	Inflammation of a tendon, usually caused by injury or overuse; the shoulder, elbow, and hip are common sites; also spelled tendonitis

(continued)

## Terminology

## Key Terms (Continued)

<b>tenosynovitis</b> <i>ten-o-sin-o-VI-tis</i>	Inflammation of a tendon and its sheath
<b>Diagnosis</b>	
<b>creatin kinase (CK)</b> <i>KRE-ah-tin KI-nase</i>	An enzyme found in muscle tissue; the serum CK level increases in cases of muscle damage; creatine phosphokinase (CPK)
<b>electromyography (EMG)</b> <i>e-lek-tro-mi-OG-rah-fe</i>	Study of the electrical activity of muscles during contraction

## Terminology

## Enrichment Terms

The terms listed below expand on the key terms to increase your knowledge of this chapter topic.

## Normal Structure and Function

<b>aponeurosis</b> <i>ap-o-nu-RO-sis</i>	A flat, white, sheet-like tendon that connects a muscle with the part that it moves (see abdominal aponeurosis, <b>FIG. 6-6</b> )
<b>creatine</b> <i>KRE-ah-tin</i>	A substance in muscle cells that stores energy for contraction
<b>glycogen</b> <i>GLI-ko-jen</i>	A complex sugar that is stored for energy in muscles and in the liver
<b>isometric</b> <i>i-so-MET-rik</i>	Pertaining to a muscle action in which the muscle tenses but does not shorten (literally: same measurement)
<b>isotonic</b> <i>i-so-TON-ik</i>	Pertaining to a muscle action in which the muscle shortens to accomplish movement (literally: same tone)
<b>kinesthesia</b> <i>kin-es-THE-ze-ah</i>	Awareness of movement; perception of the weight, direction, and degree of movement (-esthesia means “sensation”)
<b>lactate</b> <i>LAK-tate</i>	An organic compound that accumulates in muscle cells functioning without enough oxygen (anaerobically), as in times of great physical exertion
<b>motor unit</b>	A single motor neuron and all of the muscle cells that its branches stimulate
<b>myoglobin</b> <i>mi-o-GLO-bin</i>	A protein similar to hemoglobin that stores oxygen in muscle cells

## Symptoms and Conditions

<b>asterixis</b> <i>as-ter-IK-sis</i>	Rapid, jerky movements, especially in the hands, caused by intermittent loss of muscle tone
<b>asthenia</b> <i>as-THE-ne-ah</i>	Weakness (prefix a- meaning “without” with root sthen/o meaning “strength”)
<b>ataxia</b> <i>ah-TAK-se-ah</i>	Lack of muscle coordination (from root <i>tax/o</i> meaning “order, arrangement”) (adjective: ataxic)
<b>athetosis</b> <i>ath-eh-TO-sis</i>	A condition marked by slow, irregular, twisting movements, especially in the hands and fingers (adjective: athetotic)

## Terminology

## Enrichment Terms (Continued)

<b>atrophy</b> <i>AT-ro-fe</i>	A wasting away; a decrease in the size of a tissue or organ, such as muscular wasting from disuse
<b>avulsion</b> <i>ah-VUL-shun</i>	Forcible tearing away of a part
<b>clonus</b> <i>KLO-nus</i>	Alternating spasmodic contraction and relaxation in a muscle (adjective: clonic)
<b>contracture</b> <i>kon-TRAK-chur</i>	Permanent contraction of a muscle
<b>fasciculation</b> <i>fah-sik-u-LA-shun</i>	Involuntary small contractions or twitching of muscle fiber groups (fasciculi)
<b>fibromyositis</b> <i>fi-bro-mi-o-SI-tis</i>	A nonspecific term for pain, tenderness, and stiffness in muscles and joints
<b>fibrositis</b> <i>fi-bro-SI-tis</i>	Inflammation of fibrous connective tissue, especially the muscle fasciae; marked by pain and stiffness
<b>restless legs syndrome (RLS)</b>	Uneasiness, twitching, or restlessness in the legs that occurs after going to bed and often leading to insomnia; may be caused by poor circulation or drug side effects
<b>rhabdomyolysis</b> <i>rab-do-mi-OL-ih-sis</i>	An acute disease involving diffuse destruction of skeletal muscle cells (root <i>rhabd/o</i> means “rod,” referring to the long, rod-like muscle cells)
<b>rhabdomyoma</b> <i>rab-do-mi-O-mah</i>	A benign tumor of skeletal muscle
<b>rhabdomyosarcoma</b> <i>rab-do-mi-o-sar-KO-mah</i>	A highly malignant tumor of skeletal muscle
<b>rheumatism</b> <i>RU-mah-tizm</i>	A general term for inflammation, soreness, and stiffness of muscles associated with joint pain (adjectives: rheumatic, rheumatoid)
<b>spasm</b> <i>spazm</i>	A sudden, involuntary muscle contraction; may be clonic (contraction alternating with relaxation) or tonic (sustained); a strong and painful spasm may be called a cramp (adjectives: spastic, spasmodic)
<b>spasticity</b> <i>spas-TIS-ih-te</i>	Increased tone or contractions of muscles causing stiff and awkward movements
<b>tetanus</b> <i>TET-ah-nus</i>	An acute infectious disease caused by the anaerobic bacillus <i>Clostridium tetani</i> ; marked by persistent painful spasms of voluntary muscles; lockjaw
<b>tetany</b> <i>TET-ah-ne</i>	A condition marked by spasms, cramps, and muscle twitching caused by a metabolic imbalance, such as low blood calcium resulting from underactivity of the parathyroid glands
<b>torticollis</b> <i>tor-tib-KOL-is</i>	Spasmodic contraction of the neck muscles causing stiffness and twisting of the neck; wryneck
<b>Diagnosis and Treatment</b>	
<b>Chvostek sign</b> <i>VOS-tek</i>	Spasm of facial muscles after a tap over the facial nerve; evidence of tetany
<b>dynamometer</b> <i>di-nah-MOM-eh-ter</i>	Instrument for measuring degree of muscle power; from root <i>dynam/o</i> meaning “force, energy”; also called ergometer
<b>occupational therapy (OT)</b>	Health profession concerned with increasing function and preventing disability through work and play activities; the goal of occupational therapy is to increase the patient’s independence and quality of daily life (see <b>BOX 7-2</b> )

(continued)

## Terminology

## Enrichment Terms (Continued)

<b>physical therapy (PT)</b>	Health profession concerned with physical rehabilitation and prevention of disability; exercise, massage, and other therapeutic methods are used to restore proper movement (see <b>BOX 5-2</b> )
<b>rheumatology</b> <i>ru-mab-TOL-o-je</i>	The study and treatment of rheumatic diseases
<b>Trousseau sign</b> <i>tru-SO</i>	Spasmodic contractions caused by pressing the nerve supplying a muscle; seen in tetany
<b>Drugs</b>	
<b>anti-inflammatory agent</b>	Drug that reduces inflammation; includes steroids, such as cortisol, and nonsteroidal anti-inflammatory drugs
<b>COX-2 inhibitor</b>	Nonsteroidal anti-inflammatory drug that does not cause the stomach problems associated with other NSAIDs; inhibits the cyclooxygenase (COX)-2 enzyme without affecting the COX-1 enzyme, a lack of which can cause stomach ulcers; example is celecoxib (Celebrex); some of these drugs have been withdrawn from the market because of cardiac risk
<b>muscle relaxant</b> <i>re-LAX-ant</i>	A drug that reduces muscle tension; different forms may be used to relax muscles during surgery, to control spasticity, or to relieve musculoskeletal pain
<b>nonsteroidal anti-inflammatory drug (NSAID)</b>	Drug that reduces inflammation but is not a steroid; examples include aspirin, ibuprofen, naproxen, and other inhibitors of prostaglandins, naturally produced substances that promote inflammation

## Terminology

## Abbreviations

The abbreviations listed below are emphasized in this chapter. These are also found, collectively, with all chapter abbreviations in Appendix 2.

<b>ACh</b>	Acetylcholine	<b>OT</b>	Occupational therapy/therapist
<b>ALS</b>	Amyotrophic lateral sclerosis	<b>PACU</b>	Postanesthesia care unit
<b>CFS</b>	Chronic fatigue syndrome	<b>PT</b>	Physical therapy/therapist
<b>C(P)K</b>	Creatine (phospho) kinase	<b>RICE</b>	Rest, ice, compression, elevation
<b>CTS</b>	Carpal tunnel syndrome	<b>RLE</b>	Right lower extremity
<b>EMG</b>	Electromyography, electromyogram	<b>RLS</b>	Restless legs syndrome
<b>FMS</b>	Fibromyalgia syndrome	<b>ROM</b>	Range of motion
<b>LLE</b>	Left lower extremity	<b>RSI</b>	Repetitive strain injury
<b>LUE</b>	Left upper extremity	<b>RTC</b>	Rotator cuff
<b>MG</b>	Myasthenia gravis	<b>RUE</b>	Right upper extremity
<b>MMT</b>	Manual muscle test(ing)	<b>SITS</b>	Supraspinatus, infraspinatus, teres minor, subscapularis (muscles)
<b>NMJ</b>	Neuromuscular junction		

## Case Study Revisited

### Thomas's Follow-Up

The exploratory surgery confirmed the brachial plexus injury with a gap between several torn nerve ends where it was not possible to have a tension-free repair and nerve grafting was required. Thomas underwent a bilateral sural (calf) nerve graft. The sural nerve is an easily harvested nerve graft that allows the surgeon to implant healthy nerves to replace the damaged nerves in the brachial plexus. Following the four-hour procedure, Thomas was admitted to the pediatric ICU. After 6 days, he was discharged home with his right arm in a shoulder immobilizer. The incisions from the nerve graft donor sites on his right and left calf were healing nicely.

He was given antibiotic ointment to apply for the next week to prevent infection. He was also told to elevate his legs, for several days, when he was sitting or in bed.

Thomas received instructions on activities that he could or could not perform and was told to see the orthopedic surgeon in 1 week and again 3 weeks later. Physical therapy was ordered to prevent further atrophy and to begin rebuilding the arm muscles. At his 1-week follow-up, Thomas stated his frustration with the slow progress. The orthopedic surgeon had said that in time, he should regain full use of his right arm and normal activities of daily living should be restored.





This review tests your understanding of the content introduced in this chapter. Follow the instructions for each exercise and check your answers in Appendix 11.

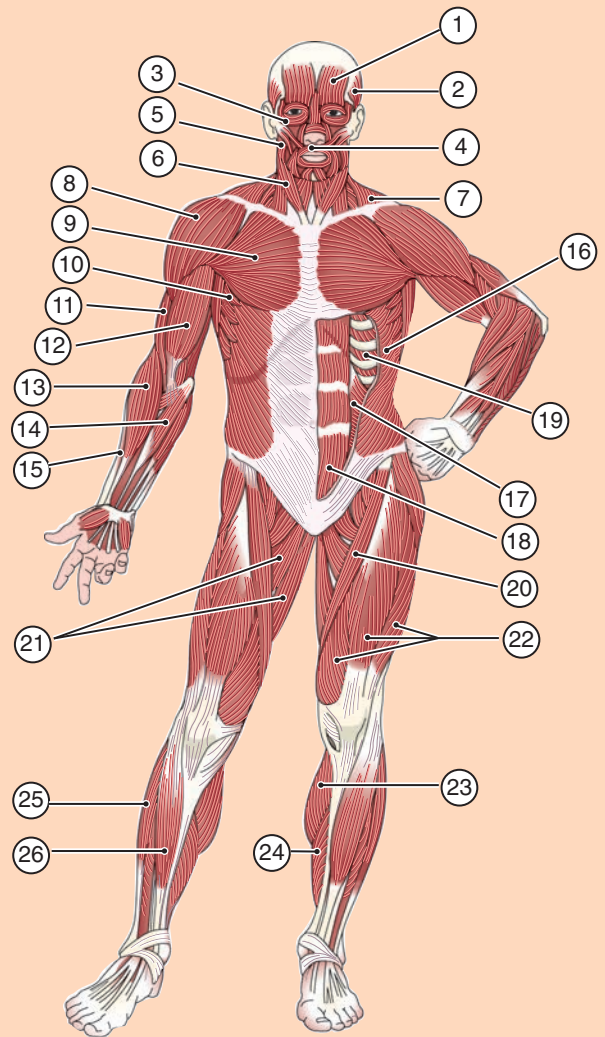
### LABELING EXERCISE

#### SUPERFICIAL MUSCLES, ANTERIOR VIEW

Write the name of each numbered part on the corresponding line.

- |                    |                    |                     |
|--------------------|--------------------|---------------------|
| Adductors of thigh | Frontalis          | Rectus abdominis    |
| Biceps brachii     | Gastrocnemius      | Sartorius           |
| Brachialis         | Intercostals       | Serratus anterior   |
| Brachioradialis    | Internal oblique   | Soleus              |
| Deltoid            | Masseter           | Sternocleidomastoid |
| Extensor carpi     | Orbicularis oculi  | Temporalis          |
| External oblique   | Orbicularis oris   | Tibialis anterior   |
| Fibularis longus   | Pectoralis major   | Trapezius           |
| Flexor carpi       | Quadriceps femoris |                     |

1. \_\_\_\_\_
2. \_\_\_\_\_
3. \_\_\_\_\_
4. \_\_\_\_\_
5. \_\_\_\_\_
6. \_\_\_\_\_
7. \_\_\_\_\_
8. \_\_\_\_\_
9. \_\_\_\_\_
10. \_\_\_\_\_
11. \_\_\_\_\_
12. \_\_\_\_\_
13. \_\_\_\_\_
14. \_\_\_\_\_
15. \_\_\_\_\_
16. \_\_\_\_\_
17. \_\_\_\_\_
18. \_\_\_\_\_
19. \_\_\_\_\_
20. \_\_\_\_\_
21. \_\_\_\_\_
22. \_\_\_\_\_



Anterior view

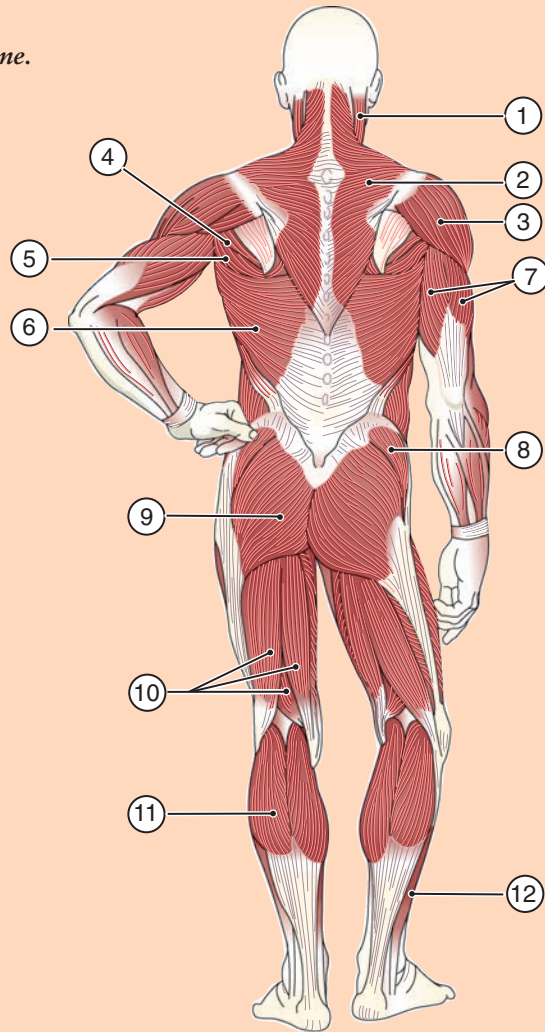
23. \_\_\_\_\_
24. \_\_\_\_\_
25. \_\_\_\_\_
26. \_\_\_\_\_

**SUPERFICIAL MUSCLES, POSTERIOR VIEW**

Write the name of each numbered part on the corresponding line.

- |                  |                     |
|------------------|---------------------|
| Deltoid          | Latissimus dorsi    |
| Fibularis longus | Sternocleidomastoid |
| Gastrocnemius    | Teres major         |
| Gluteus maximus  | Teres minor         |
| Gluteus medius   | Trapezius           |
| Hamstring group  | Triceps brachii     |

1. \_\_\_\_\_
2. \_\_\_\_\_
3. \_\_\_\_\_
4. \_\_\_\_\_
5. \_\_\_\_\_
6. \_\_\_\_\_
7. \_\_\_\_\_
8. \_\_\_\_\_
9. \_\_\_\_\_
10. \_\_\_\_\_
11. \_\_\_\_\_
12. \_\_\_\_\_



Posterior view



**TERMINOLOGY**

**MATCHING**

Match the following terms, and write the appropriate letter to the left of each number.

- |                             |   |
|-----------------------------|---|
| _____ 1. masseter           | a. muscle used in chewing; jaw muscle   |
| _____ 2. quadriceps femoris | b. large muscle of the upper chest      |
| _____ 3. pectoralis major   | c. a group of four muscles in the thigh |
| _____ 4. gastrocnemius      | d. main muscle of the calf              |
| _____ 5. trapezius          | e. muscle of the upper back and neck    |
| _____ 6. akinesia           | a. instrument for measuring muscle work |
| _____ 7. fascicle           | b. absence of movement                  |
| _____ 8. inotropic          | c. a small bundle of fibers             |
| _____ 9. dystonia           | d. acting on muscle fibers              |
| _____ 10. ergometer         | e. abnormal muscle tone                 |

*Enrichment Terms*

- |                     |  |
|---------------------|--|
| ___ 11. lactate     | a. protein that stores oxygen in muscle cells      |
| ___ 12. aponeurosis | b. flat, white, sheet-like tendon                  |
| ___ 13. tetany      | c. muscular spasms and cramps                      |
| ___ 14. myoglobin   | d. complex sugar stored in muscles                 |
| ___ 15. glycogen    | e. byproduct of anaerobic muscle contractions      |
| ___ 16. asterixis   | a. awareness of movement                           |
| ___ 17. ataxia      | b. weakness  |
| ___ 18. torticollis | c. rapid, jerky movements, especially of the hands |
| ___ 19. asthenia    | d. wryneck   |
| ___ 20. kinesthesia | e. lack of muscle coordination                     |
| ___ 21. athetosis   | a. forcible tearing away of a part                 |
| ___ 22. clonus      | b. acute infectious disease that affects muscles   |
| ___ 23. spasm       | c. intermittent muscle contractions                |
| ___ 24. avulsion    | d. sudden involuntary muscle contraction           |
| ___ 25. tetanus     | e. condition marked by slow, twisting movements    |

*Refer to Thomas's case study.*

- |                     |                                |
|---------------------|--------------------------------|
| ___ 26. deltoid     | a. partial dislocation         |
| ___ 27. atrophy     | b. shoulder muscle             |
| ___ 28. subluxation | c. network                     |
| ___ 29. plexus      | d. pertaining to the diaphragm |
| ___ 30. phrenic     | e. tissue wasting              |

**FILL IN THE BLANKS***Complete the sentence with the correct term(s).*

31. A band of connective tissue that attaches a muscle to a bone is a(n) \_\_\_\_\_.
32. A musculotropic substance acts on \_\_\_\_\_.
33. The number of origins (heads) in the triceps brachii muscle is \_\_\_\_\_.
34. A muscle that produces extension at a joint is called a(n) \_\_\_\_\_.
35. The neurotransmitter released at the neuromuscular junction is \_\_\_\_\_.
36. The strong, cord-like tendon that attaches the calf muscle to the heel is the \_\_\_\_\_.
37. Movement toward the midline of the body is termed \_\_\_\_\_.
38. The sheath of connective tissue that covers a muscle is called \_\_\_\_\_.

*Refer to Thomas's case study.*

39. The nerves of the brachial plexus supply the \_\_\_\_\_.
40. The muscle above the spine of the scapula is the \_\_\_\_\_.
41. The vertebra C7 is in the region of the \_\_\_\_\_.

**DEFINITIONS***Define the following words.*

42. myofascial (*mi-o-FASH-e-al*) \_\_\_\_\_
43. tendinoplasty (*TEN-din-o-plas-te*) \_\_\_\_\_
44. hypotonia (*hi-po-TO-ne-ah*) \_\_\_\_\_

45. hyperkinesia (*hi-per-ki-NE-se-ah*) \_\_\_\_\_
46. inotropic (*in-o-TROP-ik*) \_\_\_\_\_
47. myositis (*mi-o-SI-tis*) \_\_\_\_\_

*Write words for the following definitions.*

48. suture of fascia \_\_\_\_\_
49. death of muscle tissue \_\_\_\_\_
50. study of movement \_\_\_\_\_
51. absence of muscle tone \_\_\_\_\_
52. surgical incision of a tendon (use ten/o-) \_\_\_\_\_
53. study of muscles \_\_\_\_\_
54. excision of fascia \_\_\_\_\_
55. pertaining to a tendon \_\_\_\_\_

### OPPOSITES

*Write a word that means the opposite of the following terms as they pertain to muscles.*

56. agonist \_\_\_\_\_
57. origin \_\_\_\_\_
58. abduction \_\_\_\_\_
59. pronation \_\_\_\_\_
60. extension \_\_\_\_\_

### ADJECTIVES

*From the enrichment terms, write the adjective form of the following words.*

61. ataxia \_\_\_\_\_
62. athetosis \_\_\_\_\_
63. spasm \_\_\_\_\_
64. clonus \_\_\_\_\_

### TRUE-FALSE

*Examine the following statements. If the statement is true, write T in the first blank. If the statement is false, write F in the first blank, and correct the statement by replacing the underlined word in the second blank.*

	True or False	Correct Answer
65. The part of a neuron that contacts a muscle cell is the <u>dendrite</u> .	_____	_____
66. Skeletal muscle is <u>involuntary</u> .	_____	_____
67. The quadriceps muscle has <u>three</u> components.	_____	_____
68. <u>Pronation</u> means turning downward.	_____	_____
69. The hamstring group is in the <u>anterior</u> thigh.	_____	_____
70. Smooth muscle is also called <u>visceral</u> muscle.	_____	_____
71. The <u>origin</u> of a muscle is attached to a moving part.	_____	_____
72. In an <u>isotonic</u> contraction, a muscle shortens.	_____	_____

**ELIMINATIONS**

*In each of the sets below, underline the word that does not fit in with the rest, and explain the reason for your choice.*

73. fascicle — fiber — tendon — osteoblast — fascia

---

74. soleus — flexor carpi — biceps brachii — brachioradialis — extensor carpi

---

75. vastus intermedius — intercostals — vastus lateralis — vastus medialis — rectus femoris

---

76. circumduction — inversion — actin — dorsiflexion — rotation

---

77. EMG — ALS — FMS — CFS — MG

---

**ABBREVIATIONS**

*Write the meaning of each of the following.*

78. RICE \_\_\_\_\_

79. RTC \_\_\_\_\_

80. CTS \_\_\_\_\_

81. NMJ \_\_\_\_\_

82. EMG \_\_\_\_\_

**WORD BUILDING**

*Write a word for the following definitions using the word parts provided. Each word part can be used more than once.*

-ia	ten/o	-al	alg/o	-itis	-desis	-blast	-lysis	fasci/o	my/o
-----	-------	-----	-------	-------	--------	--------	--------	---------	------

83. inflammation of fascia \_\_\_\_\_

84. binding of a tendon \_\_\_\_\_

85. pain in a tendon \_\_\_\_\_

86. destruction of muscle tissue \_\_\_\_\_

87. binding of a fascia \_\_\_\_\_

88. an immature muscle cell \_\_\_\_\_

89. separation of a tendon \_\_\_\_\_

90. pertaining to fascia \_\_\_\_\_

91. pain in a muscle \_\_\_\_\_

**WORD ANALYSIS**

Define each of the following words, and give the meaning of the word parts in each. Use a dictionary if necessary.

92. fibromyositis (*fi-bro-mi-o-SI-tis*)

- a. fibr/o \_\_\_\_\_
- b. my/o(s) \_\_\_\_\_
- c. -itis \_\_\_\_\_

93. myasthenia (*mi-as-THE-ne-ah*)

- a. my/o \_\_\_\_\_
- b. a- \_\_\_\_\_
- c. sthen/o \_\_\_\_\_
- d. -ia \_\_\_\_\_

94. dyssynergia (*dis-in-ER-je-ah*)

- a. dys- \_\_\_\_\_
- b. syn- \_\_\_\_\_
- c. erg/o \_\_\_\_\_
- d. -ia \_\_\_\_\_

95. amyotrophic (*ab-mi-o-TRO-fik*)

- a. a- \_\_\_\_\_
- b. my/o \_\_\_\_\_
- c. troph/o \_\_\_\_\_
- d. -ic \_\_\_\_\_


## Additional Case Studies

### Case Study 6-1: Rotator Cuff Tear

Michael, a 56 y/o business executive and former college football player, was referred to an orthopedic surgeon for recurrent shoulder pain. Michael was unable to abduct his right arm without pain even after 6 months of physical therapy and NSAIDs. In addition, he had taken supplements of glucosamine, chondroitin, and S-adenosylmethionine for several months in an effort to protect the flexibility of his shoulder joint. Michael recalled a shoulder dislocation resulting from a football injury 35 years earlier. An MRI scan confirmed a complete rotator cuff tear. The surgeon recommended the Bankart procedure for Michael's injury to restore his joint stability, alleviate his pain, and permit him to return to his former normal activities, including golf.

After anesthesia induction and positioning in a semisitting (beach chair) position, the surgeon made an anterosuperior deltoid incision (the standard deltopectoral

approach) and divided the coracoacromial ligament at the acromial attachment. The rotator cuff was identified after the deltoid was retracted and the clavipectoral fascia was incised. The subscapularis tendon was incised proximal to its insertion. After capsular incision, inspection showed a large pouch inferiorly in the capsule, consistent with laxity (looseness). The capsule's torn edges were anchored to the rim of the glenoid fossa with heavy nonabsorbable sutures. A flap from the subscapularis tendon was transposed and sutured to the supraspinatus and infraspinatus muscles to bridge the gap. An intraoperative ROM examination showed that the external rotation could be performed past neutral and that the shoulder did not dislocate. The wound was closed, and a shoulder immobilizer sling was applied. Michael was referred to PT to begin therapy in 3 weeks and was assured he would be able to play golf in 6 months.



## Case Study 6-1 Questions

Follow the instructions for each question and check your answers in Appendix 11.

**Multiple Choice.** Select the best answer, and write the letter of your choice to the left of each number.

- \_\_\_\_\_ 1. The insertion of the muscle is
- the thick middle portion
  - the point of attachment to a moving bone
  - the point of attachment to a stable bone
  - the fibrous sheath
- \_\_\_\_\_ 2. Michael was unable to abduct his affected arm. This motion is
- toward the midline
  - circumferential
  - away from the midline
  - a position with the palm facing upward
- \_\_\_\_\_ 3. An anterosuperior deltoid incision would be made
- perpendicular to the muscle fibers
  - below the fascial sheath
  - behind the glenoid fossa
  - at the top and to the front of the deltoid muscle
- \_\_\_\_\_ 4. The subscapularis tendon arises from the subscapularis
- fascia
  - nerve
  - bone
  - flexor
- \_\_\_\_\_ 5. The intraoperative ROM examination was performed
- in the OR corridor
  - during surgery
  - before surgery
  - after surgery
- \_\_\_\_\_ 6. Michael's arm and shoulder were placed in a sling after surgery to
- encourage movement beyond the point of pain
  - minimize rapid ROM
  - maintain adduction and external rotation
  - prevent movement

6

Write terms from the case study with the following meanings.

7. pertaining to treatment of skeletal and muscular disorders \_\_\_\_\_
8. a term that means looseness \_\_\_\_\_

Define the following abbreviations.

9. PT \_\_\_\_\_
10. ROM \_\_\_\_\_



## Case Study 6-2: “Wake-Up” Test During Spinal Fusion Surgery

Lynn’s somatosensory evoked potentials (SSEPs) were monitored throughout her spinal fusion surgery to provide continuous information on the functional state of her sensory pathways from the median and posterior tibial nerves through the dorsal column to the primary somatosensory cortex. Before surgery, needle electrodes were inserted into Lynn’s right and left quadriceps muscles to determine nerve conduction through L2 to L4, into the anterior tibialis muscles to measure passage through L5, and into the gastrocnemius muscles to measure S1 to S2. Electrodes were placed in her rectus abdominis to monitor S1 to S2. All electrodes were taped in place, and the wires were plugged into a transformer box with feedback to a computer. A neuromonitoring technologist placed the electrodes and attended the computer monitor throughout the case. During the procedure, selected muscle groups were stimulated with 15 to 40 milliamperes (mA) of current to test the nerves and muscles. Data fed back into the computer confirmed the neuromuscular integrity and status of the spinal fixation, the instrumentation, and implants.

After the pedicle screws, hooks, and wires were in place and the spinal rods were cinched down to straighten the spine, Lynn was permitted to emerge temporarily from anesthesia and muscle paralysis medication to a lightly sedated but pain-free state. She was given commands to move her feet, straighten her legs, and wiggle her toes to test all neuromuscular groups that could be affected by misplaced or compressed spinal fixation devices. Her feet were watched, and movement was announced to the team. Dorsiflexion cleared the tibialis anterior muscles; plantar flexion cleared the gastrocnemius muscles. Knee flexion cleared the hamstring muscle group, and knee extension determined function of the quadriceps group. Lynn had a successful “wake-up” test. She was put back into deep anesthesia, and her incision was closed. A postoperative “wake-up” test was repeated after she was moved to her bed. The surgical instruments and tables were kept sterile until after all of the monitored muscle groups were tested and showed voluntary movement. The electrodes were removed, and she was taken to the postanesthesia care unit (PACU) for recovery.

### Case Study 6-2 Questions

Follow the instructions for each question and check your answers in Appendix 11.

**Multiple Choice.** Select the best answer, and write the letter of your choice to the left of each number.

- |  |  |
|--|--|
| <p>_____ 1. The quadriceps muscle group is made up of</p> <ol style="list-style-type: none"> <li>smooth and cardiac muscle fibers</li> <li>four muscles in the thigh</li> <li>three muscles in the leg and one in the foot</li> <li>fascia and tendon sheaths</li> </ol>                                 | <p>_____ 4. The movement of elevating the toes toward the anterior ankle is</p> <ol style="list-style-type: none"> <li>supination</li> <li>pronation</li> <li>dorsiflexion</li> <li>plantar flexion</li> </ol>   |
| <p>_____ 2. The anterior tibialis muscle is in the</p> <ol style="list-style-type: none"> <li>thigh</li> <li>spine</li> <li>foot</li> <li>leg</li> </ol>   | <p>_____ 5. Knee extension results in</p> <ol style="list-style-type: none"> <li>a bent knee</li> <li>a ballet position with the toes turned out</li> <li>bilateral abduction</li> <li>a straight leg</li> </ol> |
| <p>_____ 3. The nerve supply for the rectus abdominis muscle runs through S1 to S2. This anatomic region is</p> <ol style="list-style-type: none"> <li>the first and second sural sheath</li> <li>subluxation and suppuration</li> <li>sacral disk space 1 and 2</li> <li>sacral disk space 3</li> </ol> |  |

Write terms from the case study with the following meanings.

6. bending at a joint \_\_\_\_\_

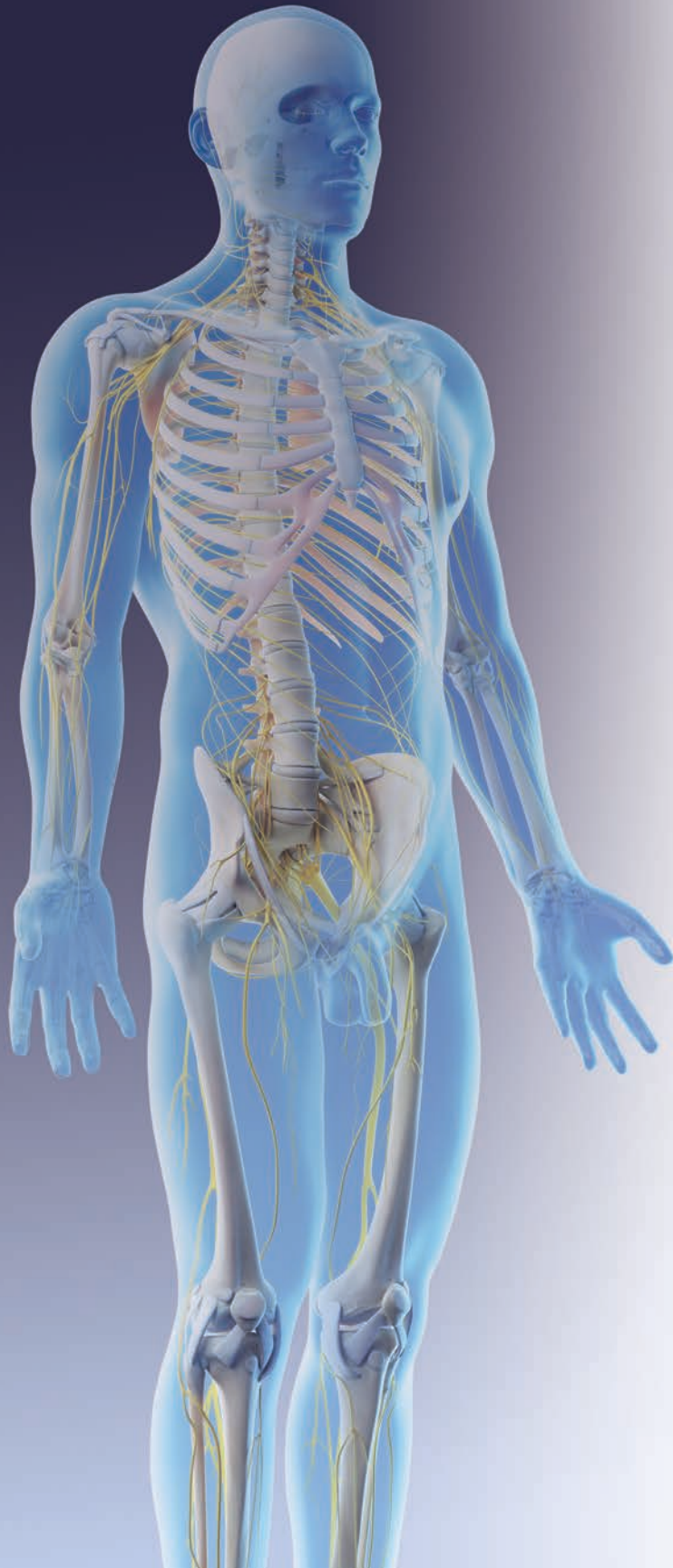7. to point the toes downward \_\_\_\_\_

Define the following abbreviations.

8. SSEP \_\_\_\_\_

9. PACU \_\_\_\_\_

# Nervous System and Mental Health



## Pretest

**Multiple Choice.** Select the best answer, and write the letter of your choice to the left of each number. To check your answers go to Appendix 11.

- \_\_\_\_\_ 1. The basic cell of the nervous system is a(n)
  - a. myofiber
  - b. neuron
  - c. osteoblast
  - d. chondrocyte
- \_\_\_\_\_ 2. The largest part of the brain is the
  - a. cerebrum
  - b. adrenal
  - c. cortex
  - d. pituitary
- \_\_\_\_\_ 3. The midbrain, pons, and medulla oblongata make up the
  - a. ventricle
  - b. spinal cord
  - c. cerebellum
  - d. brainstem
- \_\_\_\_\_ 4. Involuntary responses are controlled by the
  - a. somatic nervous system
  - b. voluntary nervous system
  - c. autonomic nervous system
  - d. diaphragm
- \_\_\_\_\_ 5. A simple response that requires few cells is a
  - a. reflex
  - b. mutation
  - c. sensation
  - d. stimulus
- \_\_\_\_\_ 6. A disorder, often of unknown cause, characterized by seizures is called
  - a. cystic fibrosis
  - b. spina bifida
  - c. epilepsy
  - d. thyrotoxicosis
- \_\_\_\_\_ 7. An instrument used to study the electric activity of the brain is the
  - a. electrocardiograph
  - b. electroencephalograph
  - c. CT scanner
  - d. sonograph
- \_\_\_\_\_ 8. An extreme, persistent fear is a(n)
  - a. palliative
  - b. prognosis
  - c. analgesic
  - d. phobia

## Learning Objectives

After careful study of this chapter, you should be able to:

- 1 Describe the components of the nervous system. **P218**
- 2 Describe the structure of a neuron. **P218**
- 3 Briefly describe the regions of the brain and their functions. **P219**
- 4 Describe how the central nervous system is protected. **P220**
- 5 Describe the structure of the spinal cord. **P222**
- 6 Name the components of a simple reflex. **P222**
- 7 Compare the sympathetic and parasympathetic systems. **P224**
- 8 Identify and use word parts pertaining to the nervous system. **P227**
- 9 Describe eight major types of disorders affecting the nervous system. **P231**
- 10 Describe five major categories of behavioral disorders. **P235**
- 11 Define abbreviations used in neurology. **P245**
- 12 Analyze medical terms in several case studies involving the nervous system. **PP217, 256**

## Case Study: William's Diving Accident and Spinal Cord Injury



### Chief Complaint

William, a 12 y/o male, was transported to the emergency department after diving into a shallow backyard cement pool. He c/o severe head and neck pain and has minimal movement of his arms.

He is not able to move his legs.

### Examination

A well-nourished 12 y/o male is awake and oriented, initially hypotensive and bradycardic, but vital signs are stabilizing. He reports being at a backyard pool party for his friend's birthday and remembers diving into the pool head first. The next thing he recalls is waking up on the deck of the pool with his friends standing all around him. He has a large erythematous and bruised area centered on the upper part of his forehead. William has full head and neck movement with fair muscle strength. He has weak shoulder movement and is able to slightly flex his elbows and extend his wrists. His legs are flexic and flaccid. He has no finger movement. Past medical history is noncontributory.

### Clinical Course

William is diagnosed with a burst or comminuted fracture of the C6 vertebra that may potentially result in quadriplegia. After surgical stabilization of the cervical fracture, William was transferred to the spinal cord unit where his vital signs could be monitored closely along with frequent assessments for orthostatic hypotension and possible complications following spinal surgery. He will be moved to a rehabilitation center in about 2 weeks for physical and occupational therapy (OT). His medical team consists of his primary physician (pediatrician), a neurosurgeon, a neurologist, and a physical medicine and rehabilitation (PM&R) specialist. Because a spinal cord injury can result in psychological as well as permanent physical damage, William's condition will require a full complement of healthcare team members, including nurses, psychologists, physical and occupational therapists, pharmacists, and social workers.

**Case Study Revisited:** Once you complete this chapter, please review the case follow-up on p. 246.

## Ancillaries *At-A-Glance*

Visit the web resource to access the following resources.

### Learning Resources

- eBook
- A&P Module with Heart & Lung Sounds
- Image Bank

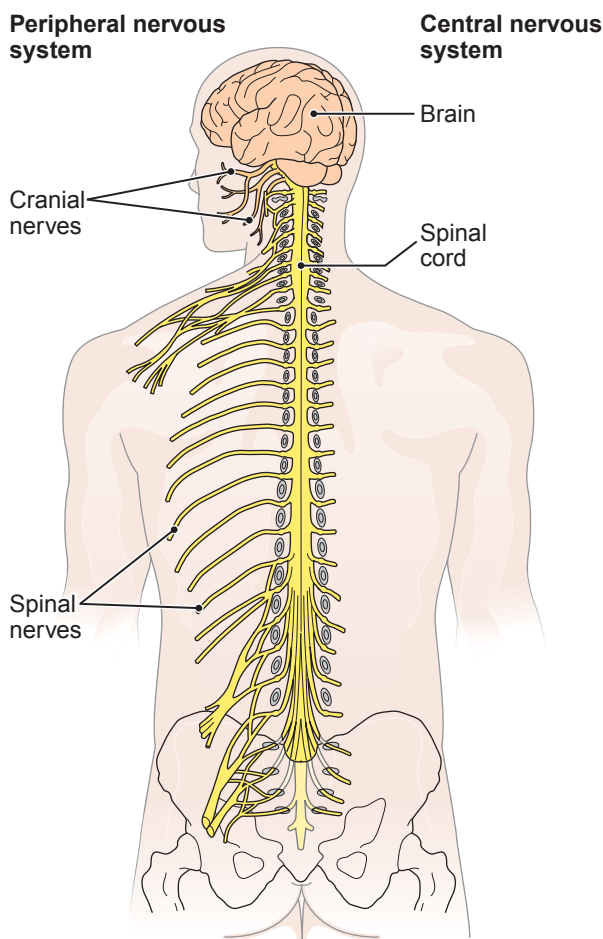
- TestPrep
- Animations
- Audio Pronunciation Glossary

## Introduction

The nervous system and the endocrine system coordinate and control the body. Together they regulate our responses to the environment and maintain homeostasis. Whereas the endocrine system functions by means of circulating hormones, the nervous system functions by means of electric impulses and locally released chemicals called neurotransmitters.

## Organization of the Nervous System

For study purposes, the nervous system may be divided structurally into two parts:



**FIGURE 7-1** Anatomic divisions of the nervous system.

- The **central nervous system (CNS)**, consisting of the **brain** and **spinal cord** (FIG. 7-1)
- The **peripheral nervous system (PNS)**, consisting of all nervous tissue outside the brain and spinal cord (see FIG. 7-1)

Functionally, the nervous system can be divided into the:

- **Somatic nervous system**, which controls skeletal muscles
- **Autonomic nervous system (ANS)**, or **visceral nervous system**, which controls smooth muscle, cardiac muscle, and glands; regulates responses to stress; and helps to maintain homeostasis

Two types of cells are found in the nervous system. **Neurons**, or nerve cells, make up the conducting tissue of the nervous system. **Neuroglia** are the cells that support and protect nervous tissue.

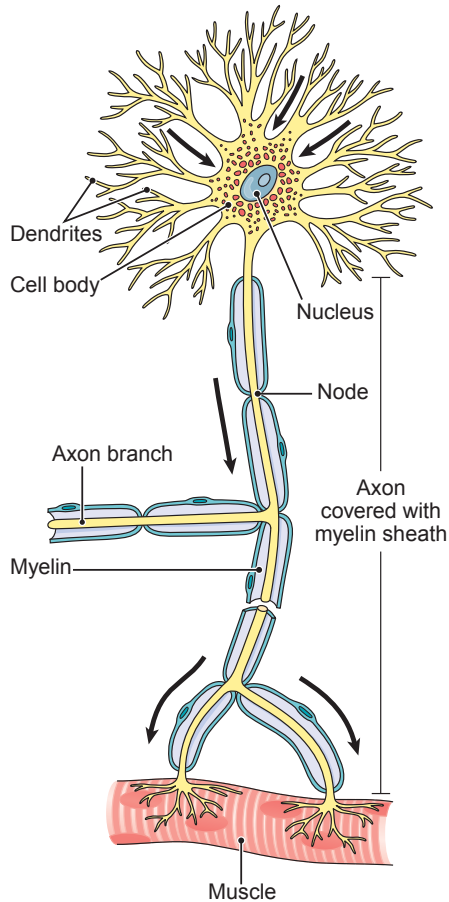
## THE NEURON

The neuron is the nervous system's basic functional unit (FIG. 7-2). Each neuron has two types of fibers extending from the cell body:

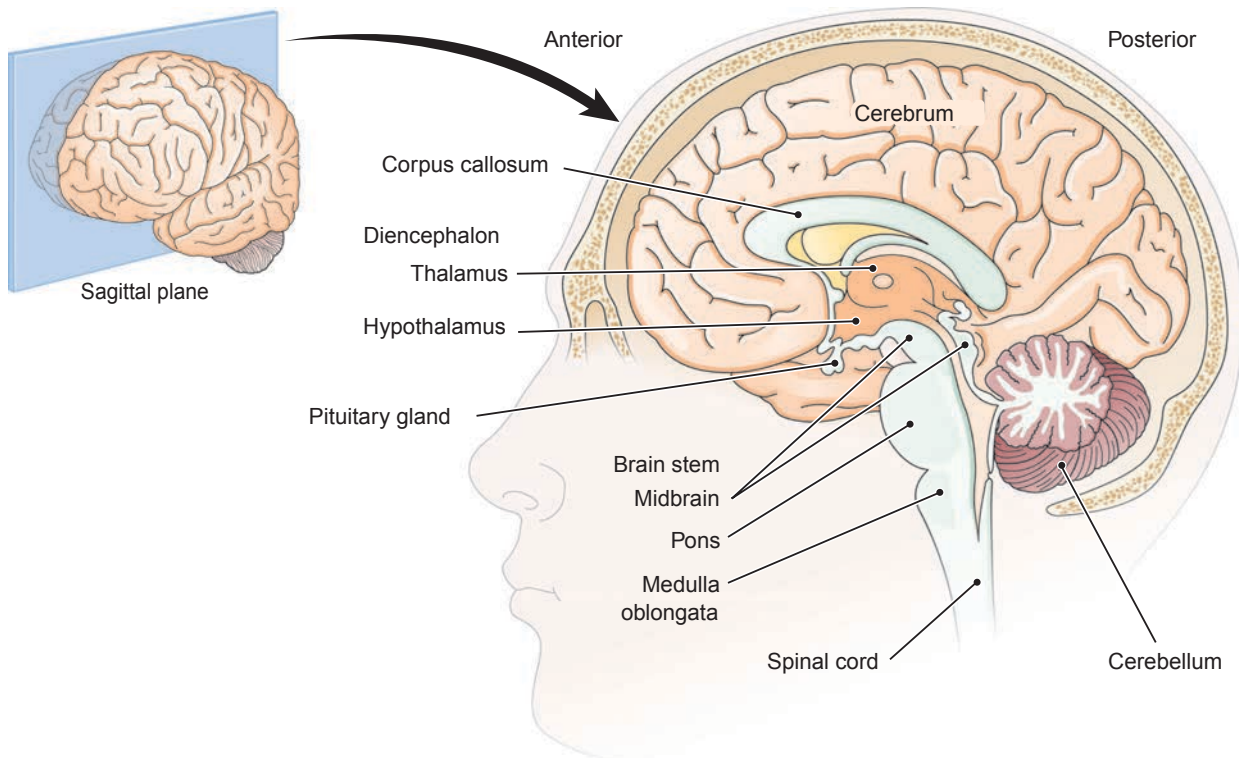
- A **dendrite** carries impulses toward the cell body.
- An **axon** carries impulses away from the cell body.

Some axons are covered with **myelin**, a whitish, fatty material that insulates and protects the axon and speeds electric conduction. Axons so covered are described as *myelinated*, and they make up the **white matter** of the nervous system. Unmyelinated tissue makes up the nervous system's **gray matter**. The myelin sheath consists of individual cells that wrap around the axon. The spaces between these cells are called *nodes*. Myelinated axons conduct nerve impulses more rapidly than unmyelinated axons because the electric impulse can skip from node to node.

Each neuron is part of a pathway that carries information through the nervous system. A neuron that transmits impulses toward the CNS is a **sensory**, or **afferent**, neuron; a neuron that transmits impulses away from the CNS is a **motor**, or **efferent**, neuron. There are also connecting cells within the CNS called **interneurons**.



**FIGURE 7-2 A motor neuron.** The break in the axon denotes length. The *arrows* show the direction of the nerve impulse.



**FIGURE 7-3 Brain, sagittal section.** The main divisions are shown.

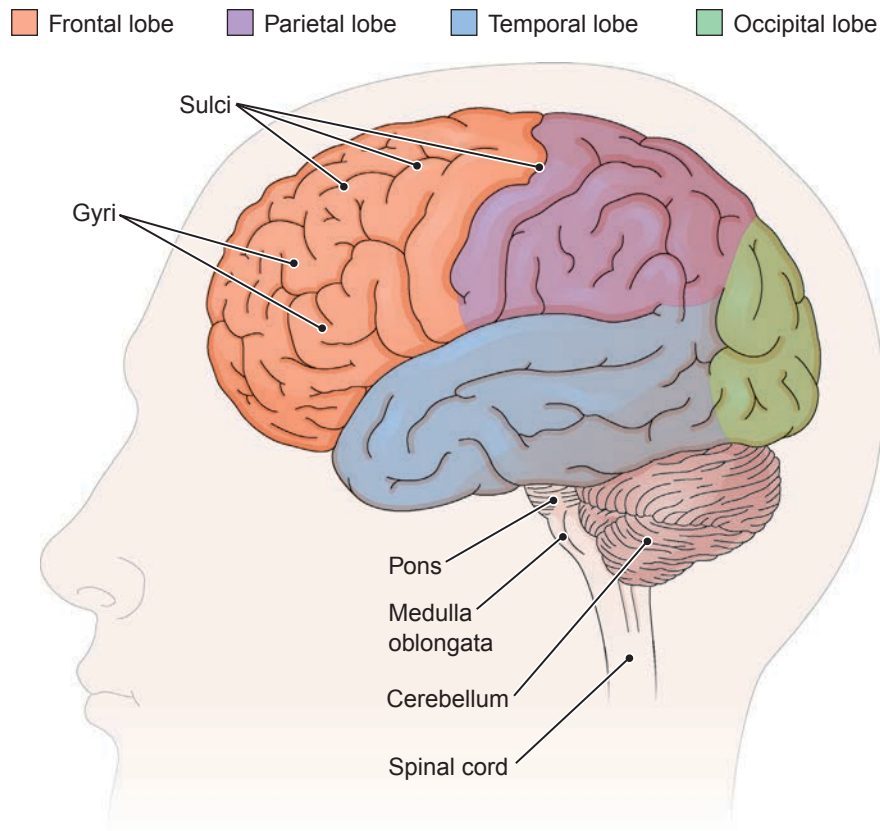
A **synapse** is the point of contact between two neurons. At the synapse, energy is passed from one cell to another, usually by means of a **neurotransmitter** and sometimes by direct transfer of electric current.

## NERVES

Individual neuron fibers are held together in bundles like wires in a cable. If this bundle is part of the PNS, it is called a **nerve**. A collection of cell bodies along the pathway of a nerve is a **ganglion**. A few nerves (sensory nerves) contain only sensory neurons, and a few (motor nerves) contain only motor neurons, but most contain both types of fibers and are described as *mixed nerves*.

## The Brain

The brain is nervous tissue contained within the cranium. It consists of the **cerebrum**, **diencephalon**, **brainstem**, and **cerebellum**. The cerebrum is the largest part of the brain (**FIG. 7-3**); it is composed largely of white matter with a thin outer layer of gray matter, the **cerebral cortex**. It is within the cortex that the higher brain functions of memory, reasoning, and abstract thought occur. The cerebrum's distinct surface is formed by grooves, or **sulci** (singular: sulcus), and raised areas, or **gyri** (singular: gyrus), that provide additional



**FIGURE 7-4 External surface of the brain, lateral view.** The lobes and surface features of the cerebrum are shown as well as other divisions of the brain and the spinal cord.

surface area (FIG. 7-4). The cerebrum is divided into two hemispheres by a deep groove, the longitudinal fissure. Each hemisphere is further divided into lobes with specialized functions (see FIG. 7-4). The lobes are named for the skull bones under which they lie.

The remaining parts of the brain, shown in FIGURE 7-3, are as follows:

- The diencephalon contains the **thalamus**, the **hypothalamus**, and the pituitary gland. The thalamus receives sensory information and directs it to the proper portion of the cortex. The hypothalamus controls the pituitary and forms a link between the endocrine and nervous systems.
- The brainstem consists of the:
  - **Midbrain**, which contains reflex centers for improved vision and hearing.
  - **Pons**, which forms a bulge on the anterior surface of the brainstem. It contains fibers that connect the brain's different regions.
  - **Medulla oblongata**, which connects the brain with the spinal cord. All impulses passing to and from the brain travel through this region. The medulla also has vital centers for control of heart rate, respiration, and blood pressure.
- The cerebellum is under the cerebrum and dorsal to the pons and medulla. Like the cerebrum, it is divided into

two hemispheres. The cerebellum helps to control voluntary muscle movements and to maintain posture, coordination, and balance.

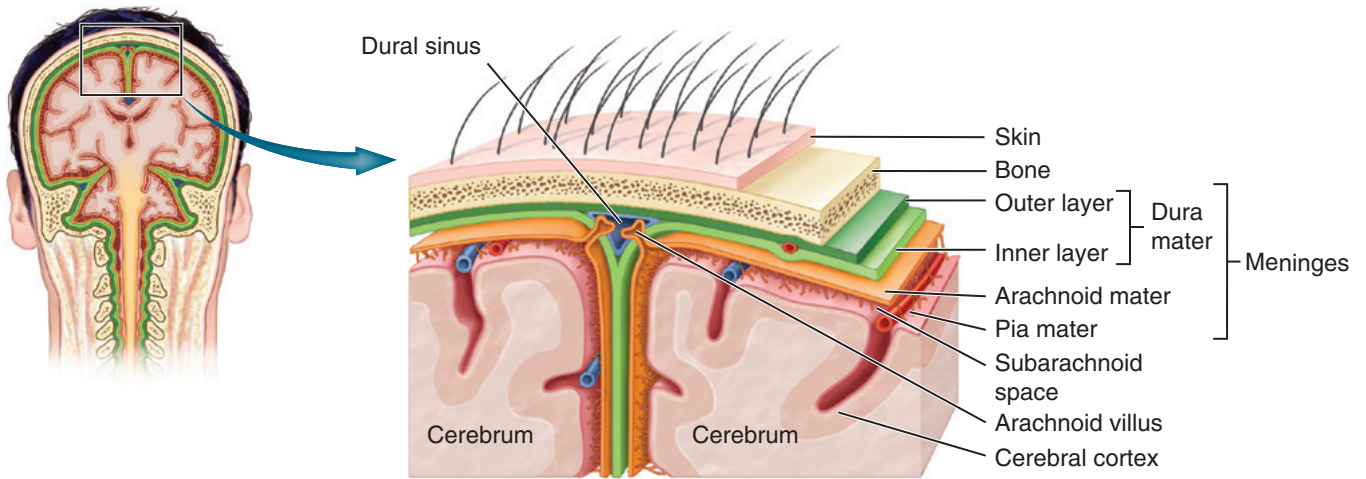
## PROTECTING THE BRAIN

Within the brain are four **ventricles** (cavities) in which **cerebrospinal fluid (CSF)** is formed. This fluid circulates around the brain and spinal cord, acting as a protective cushion for these tissues.

Covering the brain and the spinal cord are three protective layers, together called the **meninges** (FIG. 7-5). All are named with the Latin word *mater*, meaning “mother,” to indicate their protective function. They are the:

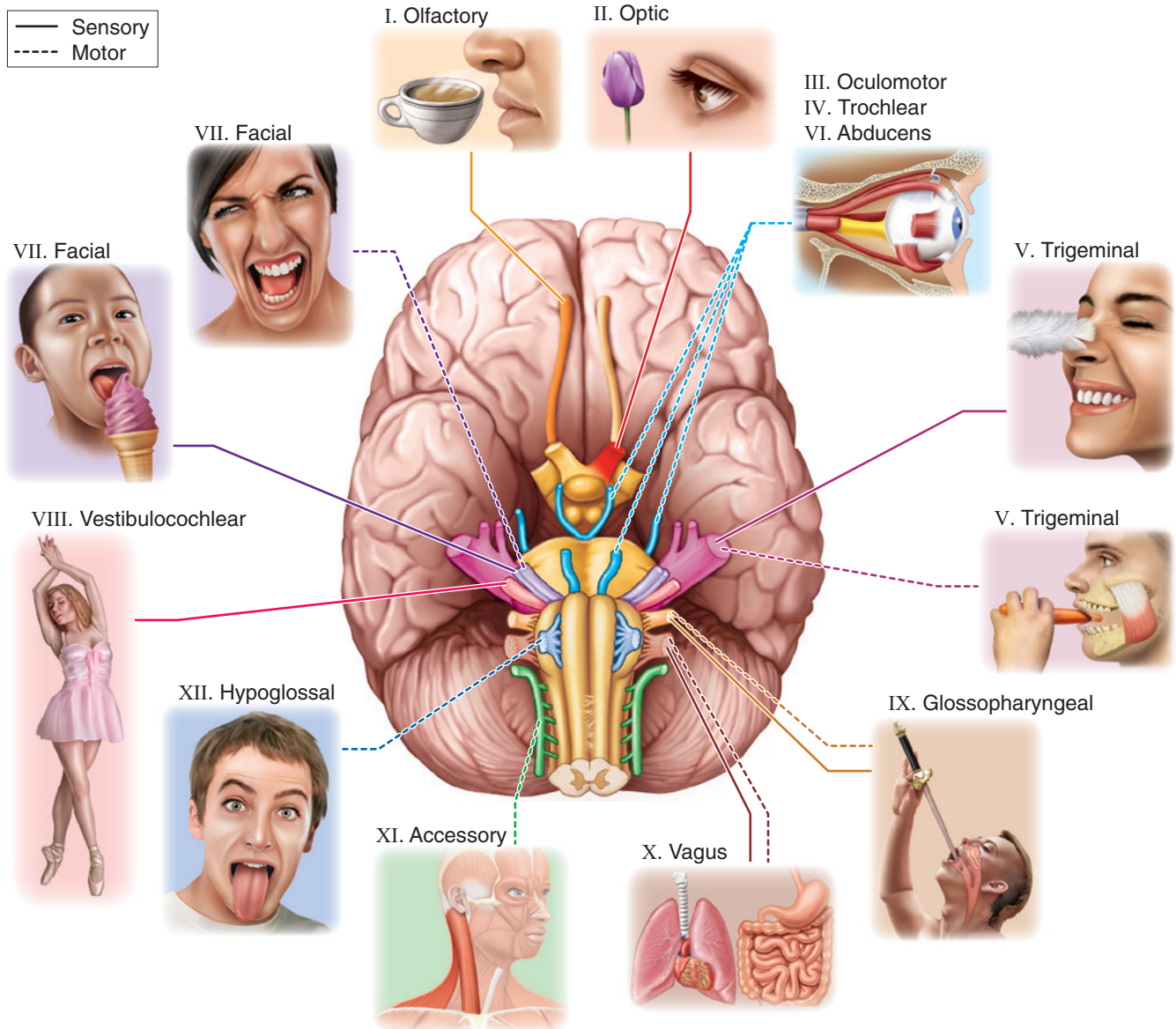
- **Dura mater**, the outermost and toughest of the three. *Dura* means “hard.”
- **Arachnoid mater**, the thin, web-like middle layer. It is named for the Latin word for spider, because it resembles a spider web.
- **Pia mater**, the thin, vascular inner layer, attached directly to the tissue of the brain and spinal cord. *Pia* means “tender.”

Twelve pairs of **cranial nerves** connect with the brain (FIG. 7-6). These nerves are identified by Roman numerals and also by name. **BOX 7-1** is a summary chart of the cranial nerves.



**FIGURE 7-5 The meninges.** The three protective layers and adjacent tissue are shown in a frontal section of the head.

7



**FIGURE 7-6 Cranial nerves.** The 12 nerves are shown from the base of the brain.





## FOR YOUR REFERENCE

### The Cranial Nerves

BOX 7-1

Number	Name	Function
I	<b>olfactory</b> <i>ol-FAK-to-re</i>	carries impulses for the sense of smell toward the brain
II	<b>optic</b> <i>OP-tik</i>	carries visual impulses from the eye to the brain
III	<b>oculomotor</b> <i>ok-u-lo-MO-tor</i>	controls movement of eye muscles; carries the parasympathetic fibers that constrict the pupil
IV	<b>trochlear</b> <i>TROK-le-ar</i>	controls a muscle of the eyeball
V	<b>trigeminal</b> <i>tri-JEM-ih-nal</i>	carries sensory impulses from the eye, upper jaw, and lower jaw toward the brain; controls chewing muscles
VI	<b>abducens</b> <i>ab-DU-sens</i>	controls a muscle of the eyeball
VII	<b>facial</b> <i>FA-shal</i>	controls muscles of facial expression, carries sensation for taste, stimulates small salivary glands and lacrimal (tear) glands
VIII	<b>vestibulocochlear</b> <i>ves-tib-u-lo-KOK-le-ar</i>	carries impulses for hearing and equilibrium from the inner ear toward the brain; also called auditory or acoustic nerve
IX	<b>glossopharyngeal</b> <i>glos-o-fah-RIN-je-al</i>	carries sensory impulses from the tongue and pharynx (throat), controls swallowing muscles, and stimulates the parotid salivary gland
X	<b>vagus</b> <i>VA-gus</i>	supplies most of the organs in the thoracic and abdominal cavities; carries motor impulses to the larynx (voice box) and pharynx
XI	<b>spinal accessory</b> <i>ak-SES-o-re</i>	controls muscles in the neck and larynx
XII	<b>hypoglossal</b> <i>hi-po-GLOS-al</i>	controls muscles of the tongue

## The Spinal Cord

The spinal cord begins at the medulla oblongata and tapers to an end between the first and second lumbar vertebrae (FIG. 7-7). It has enlargements in the cervical and lumbar regions, where nerves for the arms and legs join the cord. Seen in cross-section (FIG. 7-8), the spinal cord has a central area of gray matter surrounded by white matter. The gray matter projects toward the posterior and the anterior as the dorsal and ventral horns. The white matter contains the ascending and descending tracts (fiber bundles) that carry impulses to and from the brain. A central canal contains CSF.

### THE SPINAL NERVES

Thirty-one pairs of spinal nerves connect with the spinal cord (see FIG. 7-7). These nerves are grouped in the segments of the cord as follows:

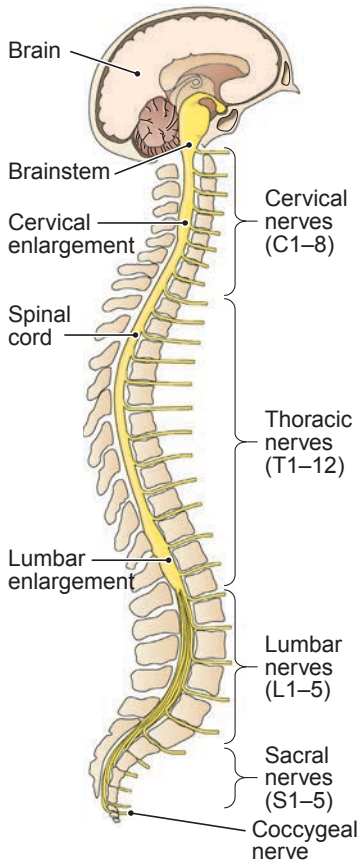
- Cervical: 8
- Thoracic: 12

- Lumbar: 5
- Sacral: 5
- Coccygeal: 1

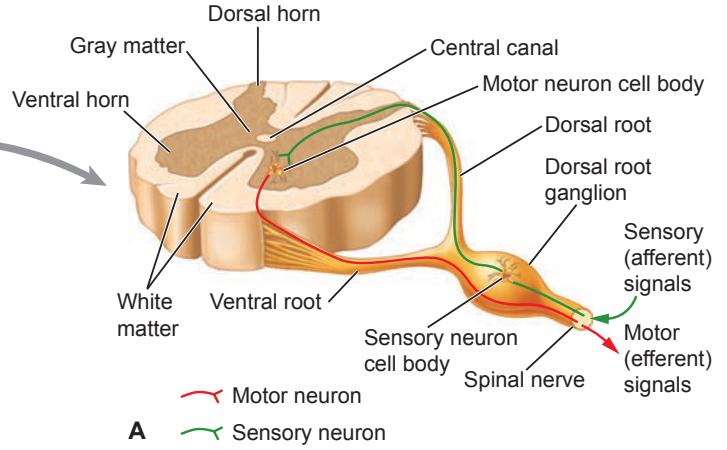
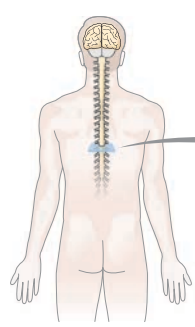
Each nerve joins the cord by two roots (see FIG. 7-8). The dorsal, or posterior, root carries sensory impulses into the cord; the ventral, or anterior, root carries motor impulses away from the cord and out toward a muscle or gland. An enlargement on the dorsal root, the dorsal root ganglion, has the cell bodies of sensory neurons carrying impulses toward the CNS.

### REFLEXES

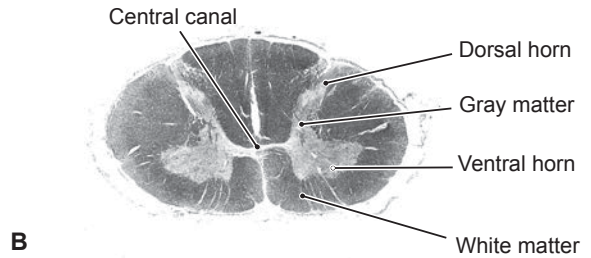
A simple response that requires few neurons is a reflex (FIG. 7-9). In a spinal reflex, impulses travel through the spinal cord only and do not reach the brain. An example of this type of response is the knee-jerk reflex used in physical examinations. However, most neurologic responses involve complex interactions among multiple neurons in the CNS.



**FIGURE 7-7 Spinal cord, lateral view.** The divisions of the spinal nerves are shown.

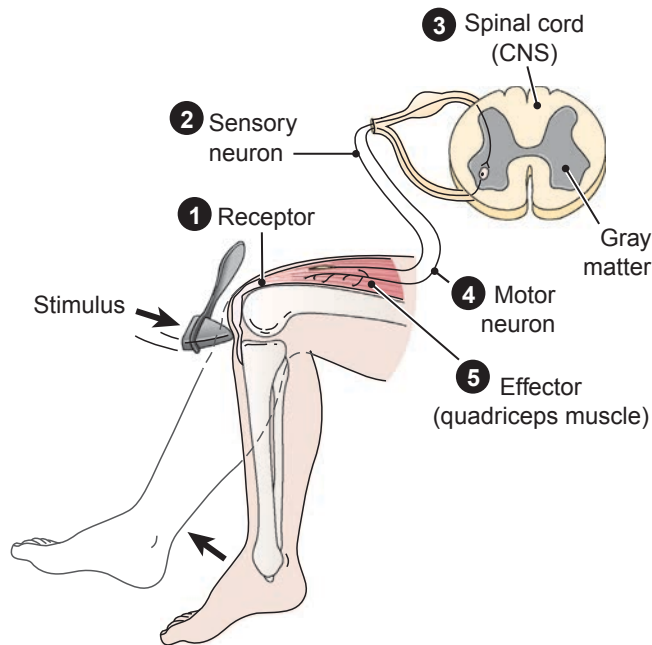


**A** Motor neuron  
Sensory neuron



**B**

**FIGURE 7-8 Spinal cord, cross-section. A.** Diagram shows the organization of gray and white matter in the cord. The roots of the spinal nerves and the pathway of nerve impulses through the spinal cord are also shown. **B.** Microscopic view of the spinal cord in cross-section (magnification 5x).



**FIGURE 7-9 A reflex pathway (arc).** The patellar (knee-jerk) reflex is shown, with numbers indicating the sequence of impulses.

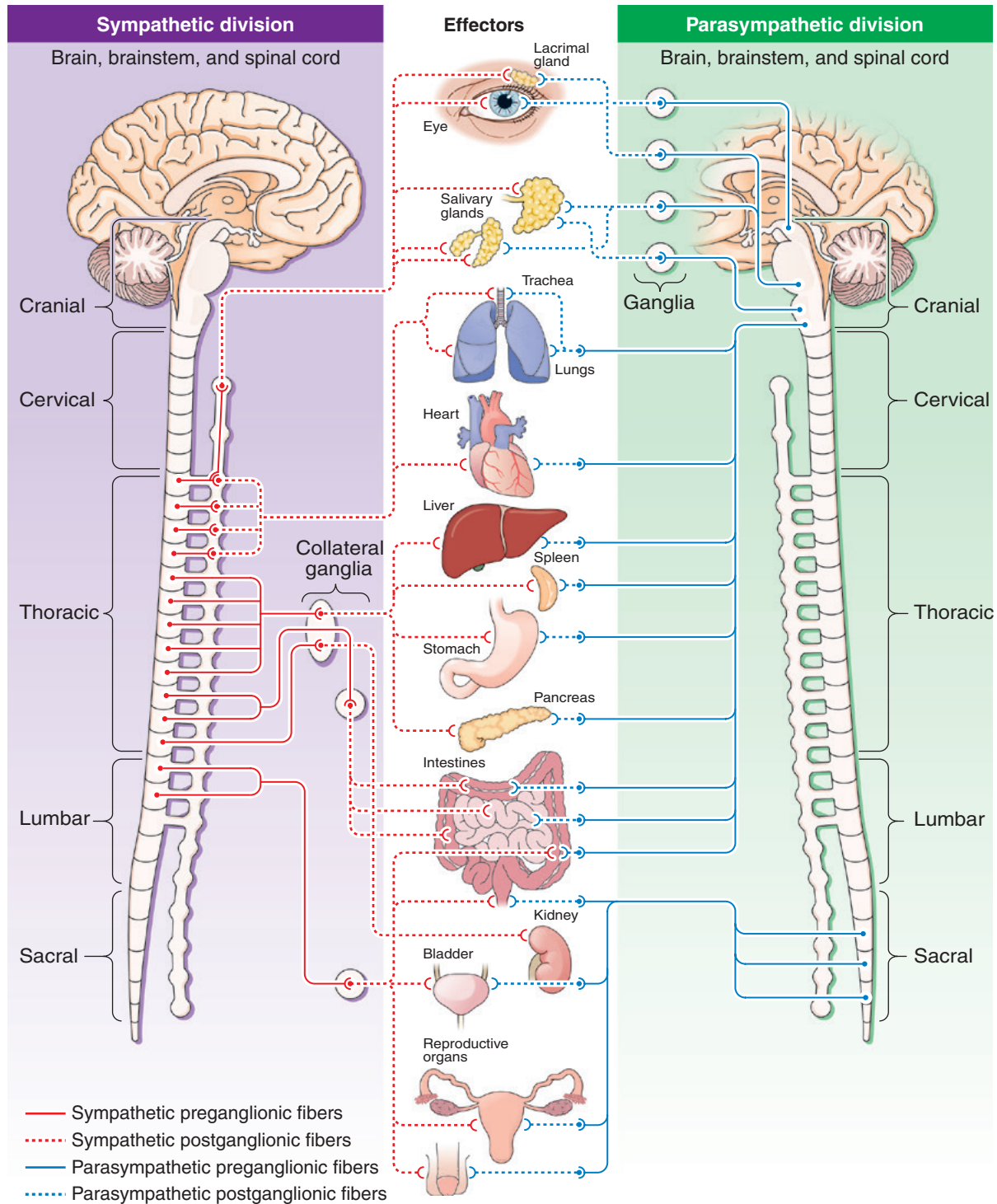
## The Autonomic Nervous System

The ANS is the division of the nervous system that controls the involuntary actions of muscles and glands (FIG. 7-10). The ANS itself has two divisions:

- The **sympathetic nervous system** motivates our response to stress, the so-called fight-or-flight response. It increases

heart rate and respiration rate, stimulates the adrenal gland, and delivers more blood to skeletal muscles.

- The **parasympathetic nervous system** returns the body to a steady state and stimulates maintenance activities, such as digestion of food. Most organs are controlled by both systems, and in general, the two systems have opposite effects on a given organ.



**FIGURE 7-10 Autonomic nervous system.** Each ANS pathway has two neurons, as shown by the *solid* and *dashed* lines. The diagram shows only one side of the body for each division (sympathetic and parasympathetic).

## Terminology *Key Terms*

The terms listed below are emphasized in this chapter. Knowing them will help you organize and prioritize your learning. These boldface terms are also found, collectively, with all chapter key terms in the Glossary.

### Normal Structure and Function

<b>afferent</b> <i>AF-er-ent</i>	Carrying toward a given point, such as the sensory neurons and nerves that carry impulses toward the CNS (root <i>fer</i> means “to carry”)
<b>arachnoid mater</b> <i>ah-RAK-noyd</i>	The middle layer of the meninges (from the Greek word for spider, because this tissue resembles a spider web)
<b>autonomic nervous system (ANS)</b> <i>aw-to-NOM-ik</i>	The division of the nervous system that regulates involuntary activities, controlling smooth muscles, cardiac muscle, and glands; the visceral nervous system
<b>axon</b> <i>AK-son</i>	The fiber of a neuron that conducts impulses away from the cell body
<b>brain</b> <i>brane</i>	The nervous tissue contained within the cranium; consists of the cerebrum, diencephalon, brainstem, and cerebellum (root: <i>encephal/o</i> )
<b>brainstem</b>	The part of the brain that consists of the midbrain, pons, and medulla oblongata
<b>central nervous system (CNS)</b>	The brain and spinal cord
<b>cerebellum</b> <i>ser-eh-BEL-um</i>	The posterior portion of the brain dorsal to the pons and medulla; helps to coordinate movement and to maintain balance and posture (cerebellum means “little brain”) (root: <i>cerebell/o</i> )
<b>cerebral cortex</b> <i>SER-eh-bral</i>	The cerebrum’s thin surface layer of gray matter (the cortex is the outer region of an organ) (root: <i>cortic/o</i> )
<b>cerebrum</b> <i>SER-eh-brum</i>	The large upper portion of the brain; it is divided into two hemispheres by the longitudinal fissure (root: <i>cerebr/o</i> )
<b>cerebrospinal fluid (CSF)</b> <i>ser-eh-bro-SPI-nal</i>	The watery fluid that circulates in and around the brain and spinal cord for protection
<b>cranial nerves</b>	The 12 pairs of nerves that are connected to the brain
<b>dendrite</b> <i>DEN-drite</i>	A fiber of a neuron that conducts impulses toward the cell body
<b>diencephalon</b> <i>di-en-SEF-ah-lon</i>	The part of the brain that contains the thalamus, hypothalamus, and pituitary gland; located between the cerebrum and the brainstem
<b>dura mater</b> <i>DU-rah MA-ter</i>	The strong, fibrous outermost layer of the meninges
<b>efferent</b> <i>EF-er-ent</i>	Carrying away from a given point, such as the motor neurons and nerves that carry impulses away from the CNS (root <i>fer</i> means “to carry”)
<b>ganglion</b> <i>GANG-gle-on</i>	A collection of neuron cell bodies outside the CNS (plural: ganglia) (roots: <i>gangli/o</i> , <i>ganglion/o</i> )
<b>gray matter</b>	Unmyelinated tissue of the nervous system
<b>gyrus</b> <i>JI-rus</i>	A raised convolution of the surface of the cerebrum (see <b>FIG. 7-4</b> ) (plural: gyri)
<b>hypothalamus</b> <i>hi-po-THAL-ah-mus</i>	The part of the brain that controls the pituitary gland and maintains homeostasis
<b>interneuron</b> <i>in-ter-NU-ron</i>	Any neuron located between a sensory and a motor neuron in a neural pathway, such as the neurons that transmit impulses within the CNS

(continued)

## Terminology

## Key Terms (Continued)

<b>medulla oblongata</b> <i>meh-DUL-lahob-long-GAH-tah</i>	The portion of the brain that connects with the spinal cord; it has vital centers for control of respiration, heart rate, and blood pressure (root: medull/o); often called simply medulla
<b>meninges</b> <i>men-IN-jeze</i>	The three membranes that cover the brain and spinal cord (see FIG. 7-5) (singular: meninx) (roots: mening/o, meninge/o)
<b>midbrain</b>	The part of the brainstem between the diencephalon and the pons; contains centers for coordination of reflexes for vision and hearing
<b>motor</b>	Producing movement; describes efferent neurons and nerves that carry impulses away from the CNS
<b>myelin</b> <i>MI-eh-lin</i>	A whitish, fatty substance that surrounds certain axons of the nervous system
<b>neuroglia</b> <i>nu-ROG-le-ah</i>	The support cells of the nervous system; also called glial cells (from glia meaning “glue”) (root: gli/o)
<b>neuron</b> <i>NU-ron</i>	The basic unit of the nervous system; a nerve cell
<b>neurotransmitter</b> <i>nu-ro-TRANS-mit-er</i>	A chemical that transmits energy across a synapse; examples are norepinephrine ( <i>nor-ep-ih-NEF-rin</i> ), acetylcholine ( <i>ab-se-til-KO-lene</i> ), serotonin ( <i>ser-o-TO-nin</i> ), and dopamine ( <i>DO-pab-mene</i> )
<b>nerve</b>	A bundle of neuron fibers outside the CNS (root: neur/o)
<b>parasympathetic nervous system</b> <i>par-ab-sim-pab-THET-ik</i>	The part of the autonomic nervous system that reverses the response to stress and restores homeostasis; it slows heart rate and respiration rate and stimulates digestive, urinary, and reproductive activities
<b>peripheral nervous system (PNS)</b> <i>per-IF-er-al</i>	The portion of the nervous system outside the CNS
<b>pia mater</b> <i>PE-ab MA-ter</i>	The innermost layer of the meninges
<b>pons</b> <i>ponz</i>	A rounded area on the ventral surface of the brainstem; contains fibers that connect brain regions (adjective: pontine [ <i>PON-tene</i> ])
<b>reflex</b> <i>RE-fleks</i>	A simple, rapid, and automatic response to a stimulus
<b>root</b> <i>rute</i>	The fundamental unit of a word. A branch of a spinal nerve that connects with the spinal cord; the dorsal (posterior) root joins the spinal cord’s dorsal gray horn; the ventral (anterior) root joins the spinal cord’s ventral gray horn (root: radicul/o)
<b>sensory</b> <i>SEN-so-re</i>	Pertaining to the senses or sensation; describing afferent neurons and nerves that carry impulses toward the CNS
<b>somatic nervous system</b> <i>so-MAT-ik</i>	The division of the nervous system that controls skeletal (voluntary) muscles
<b>spinal cord</b>	The nervous tissue contained within the spinal column; extends from the medulla oblongata to the second lumbar vertebra (root: myel/o)
<b>spinal nerves</b>	The 31 pairs of nerves that connect with the spinal cord
<b>sulcus</b> <i>SUL-kus</i>	A shallow furrow or groove, as on the surface of the cerebrum (see FIG. 7-4) (plural: sulci)
<b>sympathetic nervous system</b> <i>sim-pab-THET-ik</i>	The part of the autonomic nervous system that mobilizes a response to stress, increases heart rate and respiration rate, and delivers more blood to skeletal muscles
<b>synapse</b> <i>SIN-aps</i>	The junction between two neurons; also the junction between a motor neuron and a muscle or gland

## Terminology

## Key Terms (Continued)

<b>thalamus</b> <i>THAL-ab-mus</i>	The part of the brain that receives all sensory impulses, except those for the sense of smell, and directs them to the proper portion of the cerebral cortex (root: thalam/o)
<b>tract</b> <i>trakt</i>	A bundle of neuron fibers within the CNS
<b>ventricle</b> <i>VEN-trik-l</i>	A small cavity, such as one of the cavities in the brain in which CSF is formed. One of the two lower pumping chambers of the heart (root: ventricul/o)
<b>visceral nervous system</b> <i>VIS-er-al</i>	The autonomic nervous system
<b>white matter</b>	Myelinated tissue of the nervous system

7

## Word Parts Pertaining to the Nervous System

See TABLES 7-1 to 7-3.

Table 7-1

## Roots for the Nervous System and the Spinal Cord

Root	Meaning	Example	Definition of Example
neur/o, neur/i	nervous system, nervous tissue, nerve	neurotrophin <i>nu-ro-TRO-fin</i>	factor that promotes nerve growth (troph/o means “nourish”)
gli/o	neuroglia	glial <i>GLI-al</i>	pertaining to neuroglia
gangli/o, ganglion/o	ganglion	ganglioma <i>gang-gle-O-mah</i>	tumor of a ganglion
mening/o, meninge/o	meninges	meningocele <i>meh-NING-go-sele</i>	hernia of the meninges
myel/o	spinal cord (also bone marrow)	hematomyelia <i>he-mah-to-mi-E-le-ab</i>	hemorrhage into the spinal cord
radicul/o	spinal nerve root	radiculopathy <i>rah-dik-u-LOP-ab-the</i>	any disease of a spinal nerve root

## Exercise 7-1

Complete the exercise. To check your answers go to Appendix 11.

Define the following adjectives.

1. neural (*NU-ral*) pertaining to a nerve or the nervous system \_\_\_\_\_
2. neuroglial (*nu-ROG-le-al*) \_\_\_\_\_
3. radicular (*rah-DIK-u-lar*) \_\_\_\_\_
4. meningeal (*meh-NIN-je-al*) \_\_\_\_\_
5. ganglionic (*gang-gle-ON-ik*) \_\_\_\_\_

(continued)

## Exercise 7-1 (Continued)

Fill in the blanks.

6. A meningioma (*meh-nin-je-O-mah*) is a tumor affecting the \_\_\_\_\_.
7. A neurotropic (*nu-ro-TROP-ik*) dye has an affinity for the \_\_\_\_\_.
8. Meningococci (*meh-ning-go-KOK-si*) are bacteria (cocci) that infect the \_\_\_\_\_.
9. Myelodysplasia (*mi-eh-lo-dis-PLA-se-ah*) is abnormal development of the \_\_\_\_\_.

Define the following terms.

10. ganglionectomy (*gang-gle-o-NEK-to-me*) \_\_\_\_\_
11. polyradiculitis (*pol-e-rah-dik-u-LI-tis*) \_\_\_\_\_
12. neurolysis (*nu-ROL-ih-sis*) \_\_\_\_\_
13. radiculalgia (*rah-dik-u-LAL-je-ah*) \_\_\_\_\_
14. myelography (*mi-eh-LOG-rah-fe*) \_\_\_\_\_

Write words for the following definitions.

15. tumor of glial cells \_\_\_\_\_
16. x-ray image of the spinal cord \_\_\_\_\_
17. pain in a nerve \_\_\_\_\_
18. inflammation of the spinal cord \_\_\_\_\_
19. any disease of the nervous system \_\_\_\_\_

Table 7-2

### Roots for the Brain

Root	Meaning	Example	Definition of Example
encephal/o	brain	anencephaly <i>an-en-SEF-ah-le</i>	absence of a brain
cerebr/o	cerebrum (loosely, brain)	infracerebral <i>in-frah-SER-eh-bral</i>	below the cerebrum
cortic/o	cerebral cortex, outer portion	corticospinal <i>kor-tih-ko-SPI-nal</i>	pertaining to the cerebral cortex and spinal cord
cerebell/o	cerebellum	supracerebellar <i>su-prah-ser-eh-BEL-ar</i>	above the cerebellum
thalam/o	thalamus	thalamotomy <i>thal-ab-MOT-o-me</i>	incision of the thalamus
ventricul/o	cavity, ventricle	intraventricular <i>in-trah-ven-TRIK-u-lar</i>	within a ventricle
medull/o	medulla oblongata (also spinal cord)	medullary <i>MED-u-lar-e</i>	pertaining to the medulla
psych/o	mind	psychogenic <i>si-ko-JEN-ik</i>	originating in the mind
narc/o	stupor, unconsciousness	narcosis <i>nar-KO-sis</i>	state of stupor induced by drugs
somn/o, somn/i	sleep	somnolence <i>SOM-no-lens</i>	sleepiness

## Exercise 7-2

Complete the exercise. To check your answers go to Appendix 11.

Fill in the blanks.

1. Somnambulism (*som-NAM-bu-lizm*) means walking during \_\_\_\_\_ .
2. The term decerebrate (*de-SER-eh-brate*) refers to functional loss in the \_\_\_\_\_ .
3. The hypothalamus (*hi-po-THAL-ah-mus*) is below the \_\_\_\_\_ .
4. A psychoactive (*si-ko-AK-tiv*) drug has an effect on the \_\_\_\_\_ .
5. A narcotic (*nar-KOT-ik*) is a drug that causes \_\_\_\_\_ .
6. An electroencephalogram (*e-lek-tro-en-SEF-ab-lo-gram*) (EEG) is a record of the electric activity of the \_\_\_\_\_ .
7. The term cerebrovascular (*ser-e-bro-VAS-ku-lar*) refers to blood vessels in the \_\_\_\_\_ .

Write an adjective for the following definitions. Note the endings.

8. pertaining to (-ic) the mind \_\_\_\_\_
9. pertaining to (-al) the cerebral cortex \_\_\_\_\_
10. pertaining to (-ic) the thalamus \_\_\_\_\_
11. pertaining to (-al) the cerebrum \_\_\_\_\_
12. pertaining to (-ar) a ventricle \_\_\_\_\_

Define the following words.

13. encephalopathy (*en-sef-ab-LOP-ab-the*) \_\_\_\_\_
14. insomnia (*in-SOM-ne-ab*) \_\_\_\_\_
15. psychology (*si-KOL-oje*) \_\_\_\_\_
16. cerebrospinal (*ser-eh-bro-SPI-nal*) \_\_\_\_\_
17. extramedullary (*eks-trab-MED-u-lar-e*) \_\_\_\_\_
18. ventriculotomy (*ven-trik-u-LOT-o-me*) \_\_\_\_\_

Write words for the following definitions.

19. radiograph of a ventricle \_\_\_\_\_
20. pertaining to the cerebral cortex and the thalamus \_\_\_\_\_
21. within the cerebellum \_\_\_\_\_
22. inflammation of the brain \_\_\_\_\_
23. above the cerebrum \_\_\_\_\_



Table 7-3

## Suffixes for the Nervous System

Suffix	Meaning	Example	Definition of Example
-phasia	speech	heterophasia <i>het-er-o-FA-ze-ab</i>	uttering words that are different from those intended
-lalia	speech, babble	coprolalia <i>kop-ro-LA-le-ab</i>	compulsive use of obscene words (copro- means “feces”)
-lexia	reading	bradylexia <i>brad-e-LEK-se-ab</i>	slowness in reading
-plegia	paralysis	tetraplegia <i>tet-rah-PLE-je-ab</i>	paralysis of all four limbs
-paresis <sup>a</sup>	partial paralysis, weakness	hemiparesis <i>hem-e-pah-RE-sis</i>	partial paralysis of one side of the body
-lepsy	seizure	narcolepsy <i>NAR-ko-lep-se</i>	condition marked by sudden episodes of sleep
-phobia <sup>a</sup>	persistent, irrational fear	agoraphobia <i>ag-o-rah-FO-be-ab</i>	fear of being in a public place (from Greek <i>agora</i> , meaning “marketplace”)
-mania <sup>a</sup>	excited state, obsession	megalomania <i>meg-ab-lo-MA-ne-ab</i>	exaggerated self-importance; “delusions of grandeur”

<sup>a</sup>May be used alone as a word.

## Exercise 7-3

Complete the exercise. To check your answers go to Appendix 11.

Fill in the blanks.

1. Epilepsy (*EP-ih-lep-se*) is a disease characterized by \_\_\_\_\_.
2. A person with alexia (*ah-LEK-se-ab*) lacks the ability to \_\_\_\_\_.
3. Echolalia (*ek-o-LA-le-ab*) refers to repetitive \_\_\_\_\_.
4. Another term for quadriplegia (*kwah-drih-PLE-je-ab*) is \_\_\_\_\_.
5. In myoparesis (*mi-o-pah-RE-sis*), a muscle shows \_\_\_\_\_.

Define the following words.

6. cardioplegia (*kar-de-o-PLE-je-ab*) \_\_\_\_\_
7. aphasia (*ah-FA-ze-ab*) \_\_\_\_\_
8. alexia (*ah-LEK-se-ab*) \_\_\_\_\_
9. pyromania (*pi-ro-MA-ne-ab*) \_\_\_\_\_
10. gynephobia (*gi-neh-FO-be-ab*) \_\_\_\_\_
11. quadriplegia (*kwah-drih-ple-je-ab*) \_\_\_\_\_

Write words for the following definitions.

12. fear of (or abnormal sensitivity to) light \_\_\_\_\_
13. fear of night and darkness \_\_\_\_\_
14. paralysis of one side (hemi-) of the body \_\_\_\_\_
15. slowness in speech (-lalia) \_\_\_\_\_

## Clinical Aspects of the Nervous System

### VASCULAR DISORDERS

The term **cerebrovascular accident (CVA)**, or **stroke**, applies to any occurrence that deprives brain tissue of oxygen. These events include blockage in a vessel that supplies the brain, a ruptured blood vessel, or some other damage that leads to hemorrhage within the brain. Stroke is the fourth leading cause of death in developed countries and is a leading cause of **paralysis** and other neurologic disabilities. Risk factors for a stroke include hypertension, atherosclerosis, heart disease, diabetes mellitus, and cigarette smoking. Heredity is also a factor.

#### Thrombosis

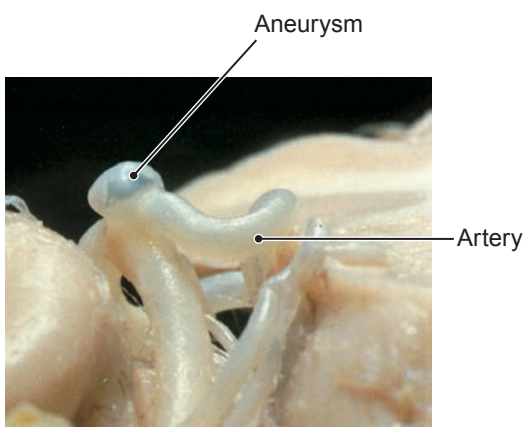
**Thrombosis** is the formation of a blood clot in a vessel. Often, in cases of CVA, thrombosis occurs in the carotid artery, the large vessel in the neck that supplies the brain. Sudden blockage by an obstruction traveling from another part of the body is described as an **embolism**. In cases of stroke, the embolus usually originates in the heart.

These obstructions can be diagnosed by **cerebral angiography** with radiopaque dye, computed tomographic (CT) scans, and other radiographic techniques. In cases of thrombosis, surgeons can remove the blocked section of a vessel and insert a graft. If the carotid artery leading to the brain is involved, a **carotid endarterectomy** may be performed to open the vessel. Thrombolytic drugs for dissolving (“busting”) such clots are also available.

#### Aneurysm

An **aneurysm** (FIG. 7-11) is a localized dilation of a vessel that may rupture and cause hemorrhage. An aneurysm may be congenital or may arise from other causes, especially atherosclerosis, which weakens the vessel wall. Hypertension then contributes to its rupture.

The effects of cerebral hemorrhage vary from massive functional loss to mild sensory or motor impairment



**FIGURE 7-11 Aneurysm.** A thin-walled aneurysm protrudes from an artery.

depending on the degree of damage. **Aphasia**, loss or impairment of speech communication, is a common after-effect. **Hemiplegia** (paralysis of one side of the body) on the side opposite the damage is also seen. It has been found in cases of hemorrhage, as in other forms of brain injury, that immediate retraining therapy may help to restore lost function.

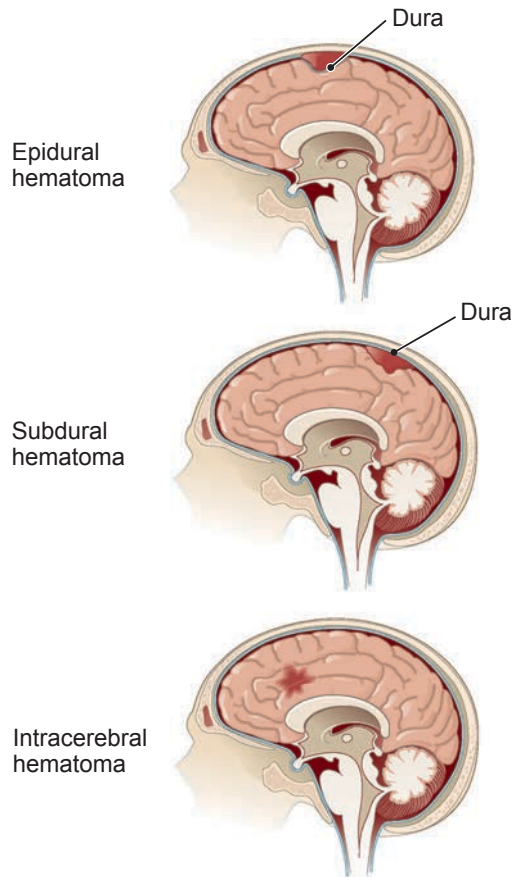
### HEAD INJURY

A **cerebral contusion** is a bruise to the brain’s surface, usually caused by a blow to the head. Blood escapes from local vessels, but the injury is not deep. Cerebral **concussion**, also known as a **mild traumatic brain injury (MTBI)**, refers to a transient alteration in brain function resulting from head trauma or from acceleration–deceleration events where a head in motion suddenly comes to a stop. The effects include amnesia, headache, dizziness, vomiting, disorientation, and sometimes loss of consciousness. Damage that occurs on the side of the brain opposite a blow as the brain is thrown against the skull is described as a **contrecoup** (*kon-treh-KU*) **injury** (from French, meaning “counterblow”).

*Postconcussion syndrome* describes symptoms that persist or develop a month or more after the injury, such as headache, fatigue, mood changes, and cognitive deficits. Individuals who have suffered one concussion are more susceptible to future concussions, and subsequent concussions can cause more severe and long-lasting symptoms. So, athletes diagnosed with concussion should not return to play until a medical professional certifies the absence of any symptoms. New research has shown that psychological factors play a large role in the severity of the symptoms and the speed of recovery. Concussions are treated with physical and cognitive rest, including restrictions on sports, computer use, reading, and even texting.

A more serious result of head trauma is bleeding into or around the meninges. Damage to an artery from a skull fracture, usually on the side of the head, may result in bleeding between the dura mater and the skull, an **epidural hematoma** (FIG. 7-12). The rapidly accumulating blood puts pressure on blood vessels and interrupts blood flow to the brain. Symptoms include headache, vomiting, confusion, aphasia (loss of speech), **hemiparesis** (partial paralysis) on the side opposite the blow, dilated pupils, seizures, and coma. Diagnosis is made by CT scan or magnetic resonance imaging (MRI). If pressure is not relieved within 1 or 2 days, death results. An epidural hematoma requires an immediate neurosurgery consultation, because early surgical intervention often provides the best hope of recovery.

A tear in the wall of a dural sinus causes a **subdural hematoma** (see FIG. 7-12). This often results from a blow to the front or back of the head that separates the dura from the arachnoid, as occurs when the moving head hits a stationary object. Blood gradually accumulates in the subdural space, putting pressure on the brain and causing headache, weakness, and confusion. Death results from continued untreated bleeding. Note that blood can accumulate over time in older people with less brain tissue and more



**FIGURE 7-12 Cranial hematomas.** Location of epidural, subdural, and intracerebral hematomas are shown.

intracranial space. Healthcare providers should consider the possibility of subdural hematoma in an older person who shows increasing confusion and has a history of recent head trauma. **FIGURE 7-12** also shows a site of bleeding into the brain tissue itself, forming an intracerebral hematoma.

Other injuries may damage the brain directly. Injury to the base of the brain may involve vital centers in the medulla and interfere with respiration and cardiac functions.

## CONFUSION AND COMA

**Confusion** is a state of reduced comprehension, coherence, and reasoning ability resulting in inappropriate responses to environmental stimuli. Confusion may worsen to include loss of language ability, memory loss, reduced alertness, and emotional changes. This condition may accompany a head injury, drug toxicity, extensive surgery, organ failure, infection, or degenerative disease.

**Coma** is a state of unconsciousness from which one cannot be aroused. Causes of coma include brain injury, epilepsy, toxins, metabolic imbalance (such as the ketoacidosis or glucose imbalances associated with diabetes mellitus), and respiratory, hepatic, or renal failure.

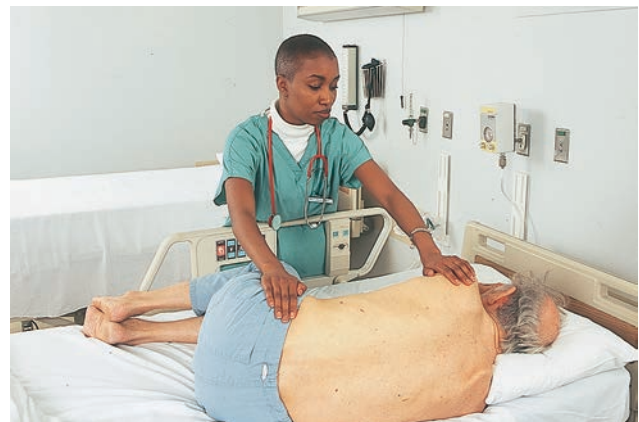Healthcare professionals use various responses to evaluate coma, for example, reflex behavior and responses to touch, pressure, and mild pain, as from a light pin prick.

Laboratory tests, **electroencephalography (EEG)**, and sometimes CT and MRI scans help to identify the causes of coma.

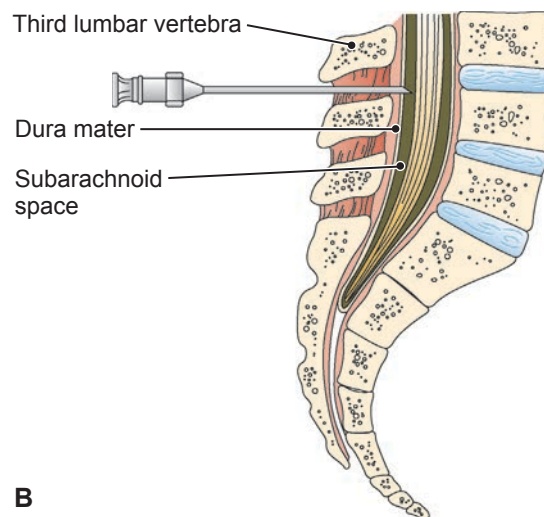
## INFECTION

Inflammation of the meninges, or **meningitis**, is usually caused by bacteria that enter through the ear, nose, or throat or are carried by the blood. One of these organisms, the meningococcus (*Neisseria meningitidis*), is responsible for meningitis epidemics among individuals living in close quarters. Other bacteria implicated in cases of meningitis include *Haemophilus influenzae*, *Streptococcus pneumoniae*, and *Escherichia coli*. A stiff neck is a common symptom. The presence of pus or lymphocytes in spinal fluid is also characteristic.

Physicians can withdraw fluid for diagnosis by a **lumbar puncture (FIG. 7-13)**, using a needle to remove CSF from the meninges in the lumbar region of the spine. A laboratory can examine this fluid for white blood cells and bacteria in the case of meningitis; for red blood cells in the case of brain injury; or for tumor cells. The fluid can also be analyzed



**A**



**B**

**FIGURE 7-13 Lumbar puncture.** **A.** Position of the patient for a lumbar puncture. **B.** CSF is withdrawn from the subarachnoid space between the third and fourth or fourth and fifth lumbar vertebrae.

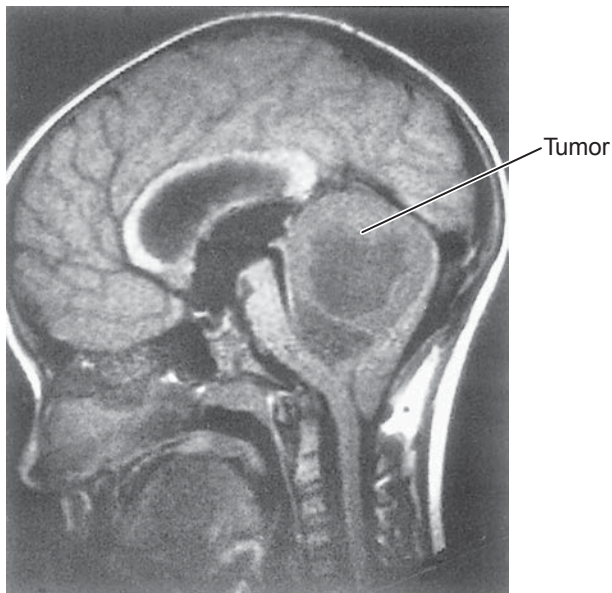
chemically. Normally, spinal fluid is clear, with glucose and chlorides present but no protein and very few cells.

Other conditions that can cause meningitis and **encephalitis** (inflammation of the brain) include viral infections, tuberculosis, and syphilis. Viruses that can involve the CNS include the poliovirus; rabies virus; herpes virus; HIV (human immunodeficiency virus); tick- and mosquito-borne viruses, such as West Nile virus; and rarely, viruses that ordinarily cause relatively mild diseases, such as measles and chickenpox. Aseptic meningitis is a benign, nonbacterial form of the disease caused by a virus.

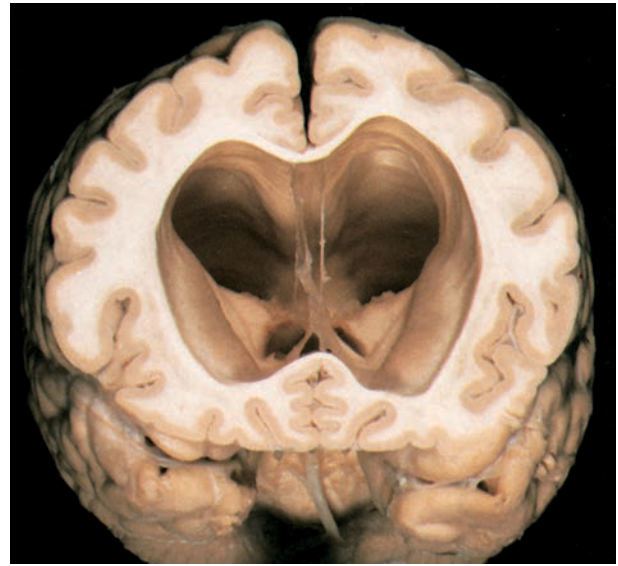
Varicella-zoster virus, which causes chickenpox, is also responsible for **shingles**, a nerve infection. If someone had chickenpox as a child, the latent virus can become reactivated later in life and spread along peripheral nerves, causing an itching, blistering rash. The name *shingles* comes from the Latin word for belt, as the shingles rash is often near or around the waist. A vaccine is now available for people over 60.

## NEOPLASMS

Almost all tumors that originate in the nervous system are tumors of nonconducting support cells, the neuroglia. These growths are termed **gliomas** and may be named for the specific cell type involved, such as **astrocytoma**, a tumor of astrocytes, or **neurilemmoma** (schwannoma), a tumor of the cells that make the myelin sheath. Because they tend not to metastasize, these tumors may be described as benign. However, they do harm by compressing brain tissue (FIG. 7-14). The symptoms they cause depend on their size and location. There may be **seizures**, headache, vomiting, muscle weakness, or interference with a special sense, such as vision or hearing. If present, edema and **hydrocephalus**, accumulation of excess CSF in the ventricles, add to the tumor's effects (FIG. 7-15).



**FIGURE 7-14 Brain tumor.** MRI shows a large tumor that arises from the cerebellum and pushes the brainstem forward.



**FIGURE 7-15 Hydrocephalus.** Coronal section of the brain showing marked enlargement of the ventricles caused by a tumor that obstructed the flow of CSF.

A **meningioma** is a tumor of the meninges. Because a meningioma does not spread and is localized at the surface, a surgeon can usually remove it completely.

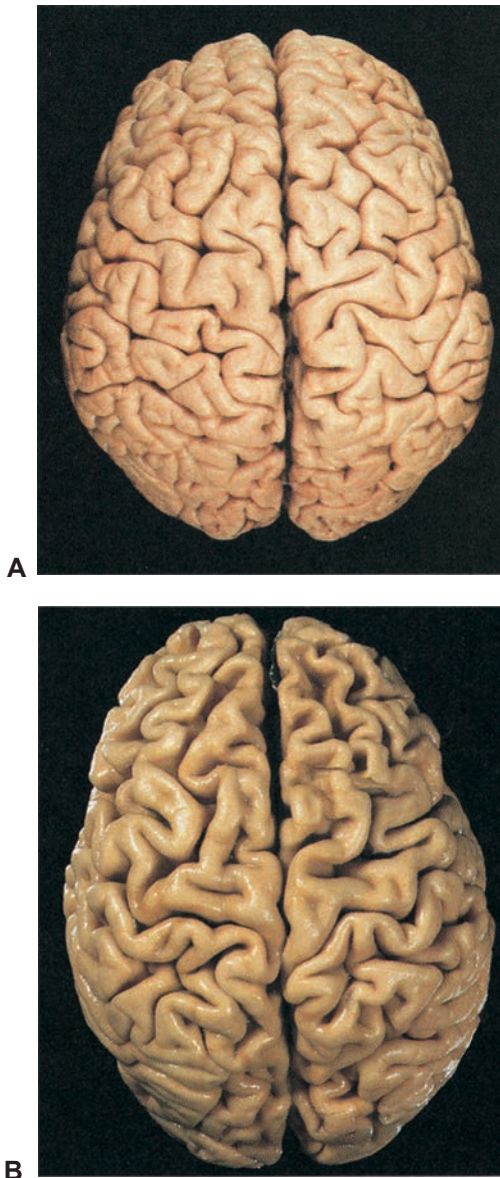
Tumors of nervous tissue generally occur in childhood and may even originate before birth, when this tissue is actively multiplying. Also, cancer may metastasize to the brain from elsewhere in the body. For unknown reasons, certain forms of cancer, especially melanoma, breast cancer, and lung cancer, tend to spread to the brain.

## DEGENERATIVE DISEASES

**Multiple sclerosis (MS)** is an autoimmune disease resulting in the demyelination (loss of the myelin sheath) of CNS axons and eventually neuronal death. In this disease, the immune system mistakenly attacks oligodendrocytes, destroying myelin and often the cells as well. Demyelination slows the speed of nerve impulse conduction and disrupts nervous system communication. Both the spinal cord and the brain can be affected. The symptoms include vision problems, tingling or numbness in the arms and legs, urinary incontinence, **tremor** (shaking), and stiff gait. The advancement of newer drugs helps prevent antibodies from accessing the CNS and causing additional lesions.

**Parkinsonism** occurs when, for unknown reasons, certain neurons in the midbrain fail to secrete the neurotransmitter dopamine. This leads to tremors, muscle rigidity, flexion at the joints, akinesia (loss of movement), and emotional problems. Parkinsonism is treated with daily administration of the drug **L-dopa** (levodopa), a form of dopamine that the circulation can carry into the brain.

**Alzheimer disease (AD)** results from unexplained degeneration of neurons and atrophy of the cerebral cortex (FIG. 7-16). These changes cause progressive loss of recent memory, confusion, and mood changes. Dangers associated with AD are injury, infection, malnutrition, and aspiration



**FIGURE 7-16** Effects of Alzheimer disease. **A.** Normal brain. **B.** Brain of a patient with Alzheimer disease, showing atrophy of the cortex with narrow gyri and enlarged sulci.

of food or fluids into the lungs. Originally called *presenile dementia* and used only to describe cases in patients about 50 years of age, the term is now applied to these same changes when they occur in elderly patients.

AD is diagnosed by CT or MRI scans and confirmed at autopsy. Histologic (tissue) studies show deposits of a substance called **amyloid** in the tissues. The disease may be hereditary. AD commonly develops in people with Down syndrome after age 40, indicating that AD is associated with abnormality on chromosome 21, the same chromosome that is involved in Down syndrome.

**Multi-infarct dementia (MID)** resembles AD in that it is a progressive cognitive impairment associated with loss of memory, loss of judgment, aphasia, altered motor and sensory function, repetitive behavior, and loss of social skills.

The disorder is caused by multiple small strokes that interrupt blood flow to brain tissue and deprive areas of oxygen.

## EPILEPSY

A prime characteristic of epilepsy is recurrent seizures brought on by abnormal electric activity of the brain. These attacks may vary from brief and mild episodes known as absence (*petit mal*) seizures to major tonic-clonic (*grand mal*) seizures with loss of consciousness, **convulsion** (intervals of violent involuntary muscle contractions), and sensory disturbances. In other cases (psychomotor seizures), there is a 1- to 2-minute period of disorientation. Epilepsy may be the result of a tumor, injury, or neurologic disease, but in most cases, the cause is unknown.

EEG reveals abnormalities in brain activity and can be used in the diagnosis and treatment of epilepsy. The disorder is treated with antiepileptic and anticonvulsive drugs to control seizures, and sometimes surgery is of help. If seizures cannot be controlled, the individual with epilepsy may have to avoid certain activities that can lead to harm.

## SLEEP DISTURBANCES

The general term *dysomnia* includes a variety of possible disorders that result in excessive sleepiness or difficulty in beginning or maintaining sleep. Simple causes for such disorders include schedule changes or travel to different time zones (jet lag). **Insomnia** refers to insufficient or nonrestorative sleep despite ample opportunity to sleep. There may be physical causes for insomnia, but often it is related to emotional upset caused by stressful events. **Narcolepsy** is characterized by brief, uncontrollable attacks of sleep during the day. The disorder is treated with stimulants, regulation of sleep habits, and short daytime naps.

**Sleep apnea** refers to failure to breathe for brief periods during sleep. It usually results from upper airway obstruction, often associated with obesity, alcohol consumption, or weakened throat muscles, and is usually accompanied by loud snoring with brief periods of silence. Dental appliances that move the tongue and jaw forward may help to prevent sleep apnea. Other options are surgery to correct an obstruction or positive air pressure delivered through a mask.

Sleep disorders are diagnosed by physical examination, a sleep history, and a log of sleep habits, including details of the sleep environment and note of any substances consumed that may interfere with sleep. Study in a sleep laboratory with a variety of electric and other studies, constituting **polysomnography**, may also be needed.

Sleep studies identify two components of normal sleep, each showing a specific EEG pattern. Nonrapid eye movement (NREM) sleep has four stages, which take a person progressively into the deepest level of sleep. If sleepwalking (*somnambulism*) occurs, it occurs during this stage. NREM sleep is interrupted about every 1.5 hours by episodes of rapid eye movement (REM) sleep, during which the eyes move rapidly, although they are closed. Dreaming occurs during REM sleep and muscles lose tone, while heart rate, blood pressure, and brain activity increase.



## HEALTH PROFESSIONS

### Careers in Occupational Therapy

BOX 7-2

Occupational therapy (OT) helps people with physical or mental disability achieve independence at home and at work by teaching them “skills for living.” Many people can benefit, including those:

- Recovering from traumas such as fractures, amputations, burns, spinal cord injury, stroke, and heart attack
- With chronic conditions such as arthritis, multiple sclerosis, Alzheimer disease, and schizophrenia
- With developmental disabilities such as Down syndrome, cerebral palsy, spina bifida, muscular dystrophy, and autism

OTs work as part of multidisciplinary teams, which include but are not limited to physicians, nurses, physical therapists, speech pathologists, and social workers. OTs also work closely with families to educate and instruct them on how to assist in the client’s progress. They assess their clients’ capabilities and develop individualized treatment programs that help them recover from injury or compensate for permanent disability. Treatment may include teaching activities ranging from work

tasks to dressing, cooking, and eating, and using adaptive equipment such as wheelchairs and computers.

OT assistants implement treatment plans developed by an occupational therapist and regularly consult with the occupational therapist on progress and possible reassessment of goals. To perform their duties, OTs and assistants need a thorough scientific education and clinical background. A current practicing OT in the United States has either a bachelor’s or master’s degree. As of 2007, OTs must earn a master’s degree in OT in order to practice. After graduation, they must pass a national certification examination and, where necessary, be licensed by the state to practice. Assistants typically train in 2-year programs and also take a certification examination.

OTs and their assistants work in hospitals, clinics, and nursing care facilities, and also visit homes and schools. As the population continues to age and the need for rehabilitative therapy increases, job prospects remain good. The American Occupational Therapy Association at [aota.org](http://aota.org) has more information on OT careers.

## OTHERS

Many hereditary diseases affect the nervous system. Some of these are described in Chapter 16. Hormonal imbalances that involve the nervous system are described in Chapter 9. Finally, drugs, alcohol, toxins, and nutritional deficiencies may act on the nervous system in a variety of ways.

**BOX 7-2** has information on occupational therapists, who are often involved in treating people with neurologic disturbances.

## Behavioral Disorders

This section is an introduction to some of the behavioral disorders that involve the nervous system. Criteria for clinical diagnosis of these and other behavioral and mental disorders are set forth in the *Diagnostic and Statistical Manual of Mental Disorders* (DSM) published by the American Psychiatric Association.

## ANXIETY DISORDERS

**Anxiety** is a feeling of fear, worry, uneasiness, or dread. It may be associated with physical problems or drugs and is often prompted by feelings of helplessness or loss of self-esteem. Generalized anxiety disorder (GAD) is characterized by chronic excessive and uncontrollable worry about various life circumstances, often with no basis. It may be accompanied by muscle tensing, restlessness, dyspnea, palpitations, insomnia, irritability, or fatigue.

**Panic disorder** is a form of anxiety disorder marked by episodes of intense fear. A person with panic disorder may isolate himself or herself or avoid social situations for fear of having a panic attack or in response to attacks.

A **phobia** is an extreme, persistent fear of a specific object or situation (**BOX 7-3**). It may center on social situations, particular objects, such as animals or blood, or activities, such as flying or driving through tunnels.



## FOCUS ON WORDS

### Phobias and Manias

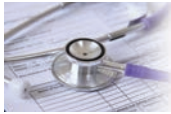BOX 7-3

Some of the terms for phobias and manias are just as strange and interesting as the behaviors themselves.

Agoraphobia is fear of being in a public place. The agora in ancient Greece was the marketplace. Xenophobia is an irrational fear of strangers, taken from the Greek root *xen/o*, which means strange or foreign. Acrophobia, a fear of heights, is taken from the root *acro-*, meaning terminal, highest, or topmost. In most medical terms, this root is used to mean extremity, as in *acrocytosis*. Hydrophobia is a fear of or aversion to

water (*hydr/o*). The term was used as an alternative name for rabies, because people infected with this paralytic disease had difficulty swallowing water and other liquids.

Trichotillomania is the odd practice of compulsively pulling out one’s hair in response to stress. The word comes from the root for hair (*trich/o*) plus a Greek word that means “to pull.” Kleptomania, also spelled cleptomania, is from the Greek word for thief and describes an irresistible urge to steal in the absence of need.



## CLINICAL PERSPECTIVES

BOX 7-4

### Psychoactive Drugs: Adjusting Neurotransmitters to Alter Mood

Many psychoactive drugs used today operate by affecting levels and activities of neurotransmitters, such as serotonin, norepinephrine, and dopamine, in the brain. Examples are fluoxetine (Prozac) and related compounds, which are prescribed to alter mood.

Prozac increases serotonin's activity by blocking its reuptake—that is, it blocks transporters that carry serotonin back into the secreting cell at the synapse. Like other selective serotonin reuptake inhibitors (SSRIs), Prozac prolongs the neurotransmitter's activity at the synapse, producing a mood-elevating effect. Prozac is used to treat depression, anxiety, and symptoms of obsessive–compulsive disorder.

Other psychoactive drugs are less selective than Prozac. Venlafaxine (Effexor) blocks reuptake of serotonin and norepinephrine and is used to treat depression and GAD. Bupropion

(Zyban) inhibits reuptake of norepinephrine and dopamine and is prescribed for depression and smoking cessation. Another class of antidepressants, the monoamine oxidase inhibitors (MAOIs), prevents an enzyme from breaking down serotonin in the synapse. Like SSRIs, MAOIs increase the amount of serotonin available in the synapse. Examples are phenelzine (Nardil) and tranylcypromine (Parnate).

Some herbal remedies are also used to treat depression. St. John's wort contains the active ingredient hypericin, which appears to both nonselectively inhibit serotonin reuptake and block norepinephrine and dopamine reuptake. As with any drug, care must be taken when using St. John's wort, especially if it is combined with other antidepressant medications, and healthcare providers should always be informed of any drugs, including herbal preparations, that a person is taking.

**Obsessive–compulsive disorder (OCD)** is a condition marked by disturbing thoughts or images that are persistent and intrusive. To relieve anxiety about these thoughts or images, the person with OCD engages in repetitive behavior that interferes with normal daily activities, although he or she knows that such behavior is unreasonable. These patterns include repeated washing; performing rituals; arranging, touching, or counting objects; and repeating words or phrases. OCD is associated with perfectionism and rigidity in behavior. Some specialists believe that OCD is related to low levels of the neurotransmitter serotonin in the brain. Treatment is with behavioral therapy and antidepressant drugs that increase the brain's serotonin levels (**BOX 7-4**).

When a highly stressful, catastrophic event results in persistent emotional difficulties, the condition is described as **posttraumatic stress disorder (PTSD)**. People who are abused, have their lives threatened, witness a crime, experience a natural disaster, and combat veterans are subject to PTSD. Responses include anger, fear, sleep disturbances, and physical symptoms, including changes in brain chemistry and hormone imbalances. PTSD is often associated with other emotional problems such as depression, withdrawal, substance abuse, and impaired social and family relationships. Patients need early treatment with emotional support, protection, psychotherapy, and drugs to treat depression and anxiety.

## MOOD DISORDERS

**Depression** is a mental state characterized by profound feelings of sadness, emptiness, hopelessness, inability to concentrate, and lack of interest or pleasure in activities. Depression is often accompanied by insomnia, loss of appetite, and suicidal tendencies, and it frequently coexists with other physical or emotional conditions.

**Dysthymia** is a chronic mood disorder that lasts for several months to years and is often triggered by a serious

event. Depression is a common symptom, as well as eating disorders, sleep disturbances, fatigue, lack of concentration, indecision, and feelings of hopelessness.

In **bipolar disorder** (formerly called manic–depressive illness), normal moods alternate with episodes of depression and **mania**, a state of elation that may include agitation, hyperexcitability, or hyperactivity. Treatment for bipolar disorder may differ from therapy for depression alone and includes mood-stabilizing drugs and professional mental health therapy.

Most of the drugs used to treat mood disorders affect the level of neurotransmitters in the brain, such as the SSRIs, which prolong the action of serotonin.

## PSYCHOSIS

**Psychosis** is a mental state in which there is gross misperception of reality. This loss of touch with reality may be evidenced by **delusions** (false beliefs), including **paranoia**, delusions of persecution or threat, or **hallucinations**, imagined sensory experiences. Although the patient's condition makes it impossible for him or her to cope with the ordinary demands of life, there is lack of awareness that this behavior is inappropriate.

**Schizophrenia** is a form of chronic psychosis that may include bizarre behavior, paranoia, anxiety, delusions, withdrawal, and suicidal tendencies. The diagnosis of schizophrenia encompasses a broad category of disorders with many subtypes. The causes of schizophrenia are unknown, but there is evidence of hereditary factors and imbalance in brain chemistry.

## ATTENTION DEFICIT HYPERACTIVITY DISORDER

**Attention deficit hyperactivity disorder (ADHD)** is difficult to diagnose because many of its symptoms overlap or coexist

with other behavioral disorders. Although inattention and hyperactivity usually appear together in these cases, one component may predominate. ADHD commonly begins in childhood and is characterized by attention problems, easy boredom, impatience, and impulsive behavior. Associated hyperactivity may be manifested by fidgeting, squirming, rapid motion, or excessive talking. In adults, the signs of ADHD may be confused with other disorders, such as mood disturbances, substance abuse, and endocrine problems.

ADHD has been correlated with alterations in brain structure and metabolism. Treatment is with psychotherapy or behavioral therapy and certain drugs. A stimulant, methylphenidate (Ritalin) has traditionally been prescribed for children with ADHD, but more recently, the antidepressant atomoxetine (Strattera) has given positive results.

## AUTISM SPECTRUM DISORDER

The term autism spectrum disorder (ASD) applies to a range of impairments that appear early in life and affect social interactions and communication skills. Despite their limitations, a person with ASD may be of normal or above average intelligence, and even brilliant. Each individual with ASD is unique and has his or her own specific needs. All of these conditions fall into a continuum that ranges from classic **autism**, at its most severe, to milder conditions known as high functioning autism, previously called Asperger syndrome, or other forms of developmental disorders.

Autism is a complex disorder of unknown cause that usually appears between the ages of 2 and 6 years as a child fails to reach appropriate developmental signposts. It is marked by self-absorption and lack of response to social contact and affection. Autistic children may have low

intelligence and poor language skills. They often appear to be disconnected and out of place. They may overrespond to stimuli and may show self-destructive behavior. There may also be stereotyped (repetitive) behavior, preoccupations, mood swings, and resistance to change. Autism may be accompanied by neurologic problems and problems with sleeping and eating. Those with autism may need the help of mental health specialists; social workers; and occupational, physical, and speech therapists. Levels of autism are determined by the extent of disability and need for support services.

People with less extreme forms of autism are often highly intelligent and verbal, but have trouble with social interactions and understanding others' behaviors. Thus, as children, they are often isolated and bullied. Repetitive behaviors may develop. These children also may develop a strong interest in specific topics. They need help in learning to interpret social cues but often can apply their talents in satisfying occupations.

## DRUGS USED IN TREATMENT

A psychotropic or psychoactive drug is one that acts on the mental state. This category of drugs includes antianxiety drugs or anxiolytics, mood stabilizers, antidepressants, and antipsychotics, also called *neuroleptics*. Many of these drugs work by increasing the brain's levels of neurotransmitters. Note that psychoactive drugs do not work in the same way for everyone. It is often necessary to try different therapies until the right drug is found. Also, it may take several weeks for a drug to become effective. For more information, see descriptions and examples of specific types of psychoactive drugs in the supplementary terms.

## Terminology

## Key Terms

The terms listed below are emphasized in this chapter. Knowing them will help you organize and prioritize your learning. These boldface terms are also found, collectively, with all chapter key terms in the Glossary.

### Neurologic Disorders

<b>Alzheimer disease (AD)</b> <i>ALTS-hi-mer</i>	A form of dementia caused by atrophy of the cerebral cortex; presenile dementia (see <b>FIG. 7-16</b> )
<b>amyloid</b> <i>AM-ih-loyd</i>	A starch-like substance of unknown composition that accumulates in the brain in Alzheimer and other diseases
<b>aneurysm</b> <i>AN-u-rizm</i>	A localized abnormal dilation of a blood vessel that results from weakness of the vessel wall (see <b>FIG. 7-11</b> ), usually of an artery; may eventually burst
<b>aphasia</b> <i>ah-FA-ze-ah</i>	Specifically, loss or defect in speech communication (from Greek <i>phasis</i> , meaning “speech”); in practice, the term is applied more broadly to a range of language disorders, both spoken and written, that may affect the ability to understand speech (receptive aphasia) or the ability to produce speech (expressive aphasia); both forms are combined in global aphasia
<b>astrocytoma</b> <i>as-tro-si-TO-mah</i>	A neuroglial tumor composed of astrocytes
<b>cerebral contusion</b> <i>kon-TU-zhun</i>	A bruise to the surface of the brain following a blow to the head

(continued)



## Terminology

## Key Terms (Continued)

<b>cerebrovascular accident (CVA)</b> <i>ser-eh-bro-VAS-ku-lar</i>	Sudden damage to the brain resulting from reduction of cerebral blood flow; possible causes are atherosclerosis, thrombosis, or a ruptured aneurysm; commonly called stroke
<b>coma</b> <i>KO-mah</i>	State of deep unconsciousness from which one cannot be roused
<b>concussion</b> <i>kon-KUSH-un</i>	Injury resulting from a violent blow or shock; a brain concussion usually results in loss of consciousness
<b>confusion</b> <i>kon-FU-zhun</i>	A state of reduced comprehension, coherence, and reasoning ability resulting in inappropriate responses to environmental stimuli
<b>contrecoup injury</b> <i>kon-treb-KU</i>	Damage to the brain on the side opposite the point of a blow as a result of the brain hitting the skull (from French, meaning “counterblow”)
<b>convulsion</b> <i>kon-VUL-shun</i>	A series of violent, involuntary muscle contractions; a tonic convulsion involves prolonged muscle contraction; in a clonic convulsion, there is alternation of contraction and relaxation; both forms appear in grand mal epilepsy
<b>dementia</b> <i>de-MEN-she-ab</i>	A gradual and usually irreversible loss of intellectual function
<b>embolism</b> <i>EM-bo-lizm</i>	Obstruction of a blood vessel by a blood clot or other material carried in the circulation
<b>encephalitis</b> <i>en-sef-ab-LI-tis</i>	Inflammation of the brain
<b>epidural hematoma</b> <i>he-mah-TO-mah</i>	Accumulation of blood in the epidural space (between the dura mater and the skull) (see <b>FIG. 7-12</b> )
<b>epilepsy</b> <i>EP-ih-lep-se</i>	A chronic disease involving periodic sudden bursts of electric activity from the brain, resulting in seizures
<b>glioma</b> <i>gli-O-mah</i>	A tumor of neuroglial cells
<b>hemiparesis</b> <i>hem-ih-pah-RE-sis</i>	Partial paralysis or weakness of one side of the body
<b>hemiplegia</b> <i>hem-ih-PLE-je-ab</i>	Paralysis of one side of the body
<b>hydrocephalus</b> <i>hi-dro-SEF-ab-lus</i>	Increased accumulation of CSF in or around the brain as a result of obstructed flow; may be caused by tumor, inflammation, hemorrhage, or congenital abnormality (see <b>FIG. 7-15</b> )
<b>insomnia</b> <i>in-SOM-nee-ab</i>	Insufficient or nonrestorative sleep despite ample opportunity to sleep
<b>meningioma</b> <i>men-nin-je-O-mah</i>	Tumor of the meninges
<b>meningitis</b> <i>men-in-JI-tis</i>	Inflammation of the meninges
<b>multi-infarct dementia (MID)</b>	Dementia caused by chronic cerebral ischemia (lack of blood supply) as a result of multiple small strokes; there is progressive loss of cognitive function, memory, and judgment as well as altered motor and sensory function
<b>multiple sclerosis (MS)</b>	A chronic, progressive disease involving loss of myelin in the CNS
<b>narcolepsy</b> <i>NAR-ko-lep-se</i>	Brief, uncontrollable episodes of sleep during the day
<b>neurilemmoma</b> <i>nu-rih-lem-O-mah</i>	A tumor of a peripheral nerve sheath (neurilemma); schwannoma

## Terminology

## Key Terms (Continued)

<b>paralysis</b> <i>pah-RAL-ih-sis</i>	Temporary or permanent loss of function; flaccid paralysis involves loss of muscle tone and reflexes and muscular degeneration; spastic paralysis involves excess muscle tone and reflexes but no degeneration
<b>parkinsonism</b> <i>PAR-kin-son-izm</i>	A disorder originating in the brain's basal ganglia (nuclei) and characterized by slow movements, tremor, rigidity, and mask-like face; also called Parkinson disease
<b>seizure</b> <i>SE-zhur</i>	A sudden attack, as seen in epilepsy; the most common forms of seizure are tonic-clonic, or grand mal ( <i>gran mal</i> ) (from French, meaning "great illness"); absence seizure, or petit mal ( <i>pet-E mal</i> ), meaning "small illness"; and psychomotor seizure
<b>shingles</b>	An acute viral infection that follows nerve pathways causing small lesions on the skin; caused by reactivation of the virus that also causes chickenpox (varicella-zoster virus); also called herpes zoster ( <i>HER-peze ZOS-ter</i> )
<b>sleep apnea</b> <i>ap-NE-ab</i>	Brief periods of breathing cessation during sleep
<b>stroke</b>	Sudden interference with blood flow in one or more cerebral vessels leading to oxygen deprivation and necrosis of brain tissue; caused by a blood clot in a vessel (ischemic stroke) or rupture of a vessel (hemorrhagic stroke); cerebrovascular accident (CVA)
<b>subdural hematoma</b> <i>sub-DU-ral he-mah-TO-mah</i>	Accumulation of blood beneath the dura mater (see <b>FIG. 7-12</b> )
<b>thrombosis</b> <i>throm-BO-sis</i>	Development of a blood clot within a vessel
<b>tremor</b> <i>TREM-or</i>	A shaking or involuntary movement
<b>Diagnosis and Treatment</b>	
<b>carotid endarterectomy</b> <i>end-ar-ter-EK-to-me</i>	Surgical removal of the lining of the carotid artery, the large artery in the neck that supplies blood to the brain
<b>cerebral angiography</b> <i>SER-eh-bral an-je-OG-rah-fe</i>	Radiographic study of the brain's blood vessels after injection of a contrast medium
<b>electroencephalography (EEG)</b> <i>e-lek-tro-en-sef-ah-LOG-rah-fe</i>	Amplification, recording, and interpretation of the brain's electric activity
<b>L-dopa</b> <i>DO-pah</i>	A drug used in the treatment of parkinsonism; levodopa
<b>lumbar puncture</b>	Puncture of the subarachnoid space in the lumbar region of the spinal cord to remove spinal fluid for diagnosis or to inject anesthesia (see <b>FIG. 7-13</b> ); spinal tap
<b>polysomnography</b> <i>pol-e-som-NOG-rah-fe</i>	Simultaneous monitoring of a variety of physiologic functions during sleep to diagnose sleep disorders
<b>Behavioral Disorders</b>	
<b>anxiety</b> <i>ang-ZI-eh-te</i>	A feeling of fear, worry, uneasiness, or dread
<b>attention deficit hyperactivity disorder (ADHD)</b>	A condition that begins in childhood and is characterized by attention problems, easy boredom, impulsive behavior, and hyperactivity
<b>autism</b> <i>AW-tizm</i>	A disorder of unknown cause consisting of self-absorption, lack of response to social contact and affection, preoccupations, stereotyped behavior, and resistance to change (from auto-, "self," and -ism, "condition of")
<b>autism spectrum disorder (ASD)</b>	A disability that falls within a range of neurodevelopmental impairments that appears early in life and affects social interactions and communications skills

(continued)

## Terminology

## Key Terms (Continued)

<b>bipolar disorder</b> <i>bi-PO-lar</i>	A form of depression with episodes of mania (a state of elation); manic depressive illness
<b>delusion</b> <i>de-LU-zhun</i>	A false belief inconsistent with knowledge and experience
<b>depression</b> <i>de-PRESH-un</i>	A mental state characterized by profound feelings of sadness, emptiness, hopelessness, and lack of interest or pleasure in activities
<b>dysthymia</b> <i>dis-THI-me-ab</i>	A mild form of depression that usually develops in response to a serious life event (from <i>dys-</i> and Greek <i>thymos</i> , meaning “mind, emotion”)
<b>hallucination</b> <i>hab-lu-sib-NA-shun</i>	A false perception unrelated to reality or external stimuli
<b>mania</b> <i>MA-ne-ab</i>	A state of elation, which may include agitation, hyperexcitability, or hyperactivity (adjective: manic)
<b>obsessive–compulsive disorder (OCD)</b> <i>ob-SES-iv kom-PUL-siv</i>	A condition associated with recurrent and intrusive thoughts, images, and repetitive behaviors performed to relieve anxiety
<b>panic disorder</b>	A form of anxiety disorder marked by episodes of intense fear
<b>paranoia</b> <i>par-ab-NOY-ab</i>	A mental state characterized by jealousy, delusions of persecution, or perceptions of threat or harm
<b>phobia</b> <i>FO-be-ab</i>	An extreme, persistent fear of a specific object or situation
<b>posttraumatic stress disorder (PTSD)</b>	Persistent emotional disturbances that follow exposure to life-threatening, catastrophic events, such as trauma, abuse, natural disasters, and warfare
<b>psychosis</b> <i>si-KO-sis</i>	A mental disorder extreme enough to cause gross misperception of reality with delusions and hallucinations
<b>schizophrenia</b> <i>skiz-o-FRE-ne-ab</i>	A poorly understood group of severe mental disorders with features of psychosis, delusions, hallucinations, and withdrawn or bizarre behavior (schizo means “split,” and phren/o means “mind”)

## Terminology

## Enrichment Terms

The terms listed below expand on the key terms to increase your knowledge of this chapter topic.

## Normal Structure and Function

<b>acetylcholine (ACh)</b> <i>as-e-til-KO-lene</i>	A neurotransmitter; activity involving acetylcholine is described as cholinergic
<b>basal ganglia</b>	Four masses of gray matter in the cerebrum and upper brainstem that are involved in movement and coordination; basal nuclei
<b>blood–brain barrier</b>	A special membrane between circulating blood and the brain that prevents certain damaging substances from reaching brain tissue
<b>Broca area</b> <i>BRO-kah</i>	An area in the left frontal lobe of the cerebrum that controls speech production
<b>cerebral arterial circle</b>	An interconnection (anastomosis) of several arteries supplying the brain; located at the base of the cerebrum; circle of Willis
<b>contralateral</b> <i>kon-trah-LAT-er-al</i>	Affecting the opposite side of the body

## Terminology

## Enrichment Terms (Continued)

<b>corpus callosum</b> <i>KOR-pus kab-LO-sum</i>	A large band of connecting fibers between the cerebral hemispheres
<b>dermatome</b> <i>DER-mah-tome</i>	The area of the skin supplied by a spinal nerve; term also refers to an instrument used to cut skin for grafting (see Chapter 4)
<b>ipsilateral</b> <i>ip-sih-LAT-er-al</i>	On the same side; unilateral
<b>leptomeninges</b> <i>lep-to-men-IN-jeze</i>	The pia mater and arachnoid together
<b>norepinephrine</b> <i>nor-ep-ih-NEF-rin</i>	A neurotransmitter very similar in chemical composition and function to the hormone epinephrine; also called noradrenaline
<b>nucleus</b> <i>NU-kle-us</i>	A collection of nerve cells within the central nervous system
<b>plexus</b> <i>PLEKS-us</i>	A network, as of nerves or blood vessels
<b>pyramidal tracts</b> <i>pih-RAM-ih-dal</i>	A group of motor tracts involved in fine coordination; most of the fibers in these tracts cross in the medulla to the opposite side of the spinal cord and affect the opposite side of the body; fibers not included in the pyramidal tracts are described as extrapyramidal
<b>reticular activating system (RAS)</b> <i>reh-TIK-u-lar</i>	A widespread system in the brain that maintains wakefulness
<b>Schwann cells</b> <i>shvon</i>	Cells that produce the myelin sheath around peripheral axons
<b>Wernicke area</b> <i>VER-nih-ke</i>	An area in the temporal lobe concerned with speech comprehension
<b>Symptoms and Conditions</b>	
<b>amyotrophic lateral sclerosis (ALS)</b> <i>ah-mi-o-TROF-ik</i>	A disorder marked by muscular weakness, spasticity, and exaggerated reflexes caused by degeneration of motor neurons; Lou Gehrig disease
<b>amnesia</b> <i>am-NE-ze-ab</i>	Loss of memory (from Greek word <i>mneme</i> meaning “memory” and the negative prefix <i>a-</i> )
<b>apraxia</b> <i>ah-PRAK-se-ab</i>	Inability to move with purpose or to use objects properly
<b>ataxia</b> <i>ah-TAK-se-ab</i>	Lack of muscle coordination; dyssynergia
<b>athetosis</b> <i>ath-eh-TO-sis</i>	Involuntary, slow, twisting movements in the arms, especially the hands and fingers
<b>Bell palsy</b> <i>PAWL-ze</i>	Paralysis of the facial nerve
<b>berry aneurysm</b> <i>AN-u-rizm</i>	A small sac-like aneurysm of a cerebral artery
<b>catatonia</b> <i>kat-ab-TO-ne-ab</i>	A phase of schizophrenia in which the patient is unresponsive; there is a tendency to remain in a fixed position without moving or talking
<b>cerebral palsy</b> <i>SER-eh-bral PAWL-ze</i>	A nonprogressive neuromuscular disorder usually caused by damage to the CNS near the time of birth; may include spasticity, involuntary movements, or ataxia
<b>chorea</b> <i>KOR-e-ab</i>	A nervous condition marked by involuntary twitching of the limbs or facial muscles

(continued)

## Terminology

## Enrichment Terms (Continued)

<b>claustrophobia</b> <i>claws-tro-FO-be-ah</i>	Fear of being shut in or enclosed (from Latin <i>claudere</i> , “to shut”)
<b>compulsion</b> <i>kom-PUL-shun</i>	A repetitive, stereotyped act performed to relieve tension
<b>Creutzfeldt–Jakob disease (CJD)</b> <i>KROITS-felt YAH-kob</i>	A slow-growing degenerative brain disease caused by a prion ( <i>PRI-on</i> ), an infectious protein; related to bovine spongiform encephalopathy (BSE, “mad cow disease”) in cattle
<b>delirium</b> <i>de-LIR-e-um</i>	A sudden and temporary state of confusion marked by excitement, physical restlessness, and incoherence
<b>dysarthria</b> <i>dis-AR-thre-ah</i>	Defect in speech articulation caused by lack of control over the required muscles
<b>dysmetria</b> <i>dis-ME-tre-ah</i>	Disturbance in the path or placement of a limb during active movement; in hypometria, the limb falls short; in hypermetria, the limb extends beyond the target
<b>euphoria</b> <i>u-FOR-e-ah</i>	An exaggerated feeling of well-being; elation
<b>glioblastoma</b> <i>gli-o-blas-TO-mah</i>	A malignant astrocytoma
<b>Guillain–Barré syndrome</b> <i>ge-YAN bar-RA</i>	An acute polyneuritis with progressive muscular weakness that usually occurs after a viral infection; in most cases recovery is complete, but it may take several months to years
<b>hematomyelia</b> <i>he-mah-to-mi-E-le-ah</i>	Hemorrhage of blood into the spinal cord, as from an injury
<b>hemiballism</b> <i>hem-e-BAL-izm</i>	Jerking, twitching movements of one side of the body
<b>Huntington disease</b>	A hereditary disease of the CNS that usually appears between ages 30 and 50; the patient shows progressive dementia and chorea, and death occurs within 10 to 15 years
<b>hypochondriasis</b> <i>hi-po-kon-DRI-ah-sis</i>	Abnormal anxiety about one’s health
<b>ictus</b> <i>IK-tus</i>	A blow or sudden attack, such as an epileptic seizure
<b>lethargy</b> <i>LETH-ar-je</i>	A state of sluggishness or stupor
<b>migraine</b> <i>MI-grane</i>	Chronic intense, throbbing headache that may result from vascular changes in cerebral arteries; possible causes include genetic factors, stress, trauma, and hormonal fluctuations; headache might be signaled by visual disturbances, nausea, photophobia, and tingling sensations
<b>neurofibromatosis</b> <i>nu-ro-fi-bro-mah-TO-sis</i>	A condition involving multiple tumors of peripheral nerves
<b>neurosis</b> <i>nu-RO-sis</i>	An emotional disorder caused by unresolved conflicts, with anxiety as a main characteristic
<b>paraplegia</b> <i>par-ab-PLE-je-ah</i>	Paralysis of the legs and lower part of the body
<b>parasomnia</b> <i>par-ab-SOM-ne-ah</i>	Condition of having undesirable phenomena, such as nightmares, occur during sleep or become worse during sleep
<b>quadriplegia</b> <i>kwah-drib-PLE-je-ah</i>	Paralysis of all four limbs; tetraplegia

## Terminology

## Enrichment Terms (Continued)

<b>Reye syndrome</b> <i>ri</i>	A rare acute encephalopathy occurring in children after viral infections; the liver, kidney, and heart may be involved; linked to administration of aspirin during a viral illness
<b>sciatica</b> <i>si-AT-ib-kah</i>	Neuritis characterized by severe pain along the sciatic nerve and its branches
<b>somatoform disorders</b> <i>so-MAH-to-form</i>	Conditions associated with symptoms of physical disease, such as pain, hypertension, or chronic fatigue, with no physical basis
<b>somnambulism</b> <i>som-NAM-bu-lizm</i>	Walking or performing other motor functions while asleep and out of bed; sleepwalking
<b>stupor</b> <i>STU-por</i>	A state of unconsciousness or lethargy with loss of responsiveness
<b>syringomyelia</b> <i>sir-in-go-mi-E-le-ab</i>	A progressive disease marked by formation of fluid-filled cavities in the spinal cord
<b>tic</b> <i>tik</i>	Involuntary, spasmodic, recurrent, and purposeless motor movements or vocalizations
<b>tic douloureux</b> <i>tik du-lu-RU</i>	Episodes of extreme pain in the area supplied by the trigeminal nerve; also called trigeminal neuralgia
<b>tabes dorsalis</b> <i>TA-bezedor-SAL-is</i>	Destruction of the dorsal (posterior) portion of the spinal cord with loss of sensation and awareness of body position, as seen in advanced cases of syphilis
<b>Tourette syndrome</b> <i>tu-RET</i>	A tic disorder with intermittent motor and vocal manifestations that begins in childhood; there also may be obsessive and compulsive behavior, hyperactivity, and distractibility
<b>transient ischemic attack (TIA)</b> <i>is-KE-mik</i>	A sudden, brief, and temporary cerebral dysfunction usually caused by interruption of blood flow to the brain
<b>Wallerian degeneration</b> <i>wahl-LE-re-an</i>	Degeneration of a nerve distal to an injury
<b>whiplash</b>	Cervical injury caused by rapid acceleration and deceleration, resulting in damage to muscles, ligaments, disks, and nerves
<i>Additional terms related to neurologic symptoms can be found in Chapters 6 (on the muscular system) and 8 (on the sensory system)</i>	
<b>Diagnosis and Treatment</b>	
<b>Babinski reflex</b> <i>bah-BIN-ske</i>	A spreading of the outer toes and extension of the big toe over the others when the sole of the foot is stroked; this response is normal in infants but indicates a lesion of specific motor tracts in adults ( <b>FIG. 7-17</b> )
<b>evoked potentials</b>	Record of the brain's electric activity after sensory stimulation; included are visual evoked potentials (VEPs), brainstem auditory evoked potentials (BAEPs), and somatosensory evoked potentials (SSEPs), obtained by stimulating the hand or leg; these tests are used to evaluate CNS function
<b>Glasgow Coma Scale</b>	A system for assessing level of consciousness (LOC) by assigning a score to each of three responses: eye opening, motor responses, and verbal responses
<b>positron emission tomography (PET)</b>	Use of radioactive glucose or other metabolically active substance to produce images of biochemical activity in tissues; used for study of the living brain, both healthy and diseased, and also in cardiology; <b>FIGURE 7-18</b> compares brain CT, MRI, and PET scans
<b>Romberg sign</b>	Inability to maintain balance when the eyes are shut and the feet are close together
<b>sympathectomy</b> <i>sim-pah-THEK-to-me</i>	Interruption of sympathetic nerve transmission either surgically or chemically
<b>trepination</b> <i>tref-ib-NA-shun</i>	Cutting a piece of bone out of the skull; the instrument used is a trepan ( <i>tre-PAN</i> ) or trephine ( <i>tre-FIN</i> )

(continued)

## Terminology

## Enrichment Terms (Continued)

## Psychoactive Drugs

**antianxiety agent***an-te-ang-ZI-eh-te*

Relieves anxiety by means of a calming, sedative effect on the CNS; examples are chlordiazepoxide (Librium), diazepam (Valium), alprazolam (Xanax); anxiolytic

**antidepressant** (other than those listed in separate categories below)

Blocks the reuptake of neurotransmitters such as serotonin, norepinephrine, and dopamine, alone or in combination; examples are bupropion (Wellbutrin, Zyban), mirtazapine (Remeron), nefazodone (Serzone), venlafaxine (Effexor XR), atomoxetine (Strattera)

**monoamine oxidase inhibitor (MAOI)***mo-no-AH-mene OK-sib-dase*

Blocks an enzyme that breaks down norepinephrine and serotonin, thus prolonging their action; examples are phenelzine (Nardil), tranylcypromine (Parnate), isocarboxazid (Marplan)

**neuroleptic***nu-ro-LEP-tik*

Drug used to treat psychosis, including schizophrenia; examples are clozapine (Clozaril), haloperidol (Haldol), risperidone (Risperdal), olanzapine (Zyprexa); antipsychotic; action mechanism unknown, but may interfere with neurotransmitters

**selective serotonin reuptake inhibitor (SSRI)***ser-o-TO-nin*

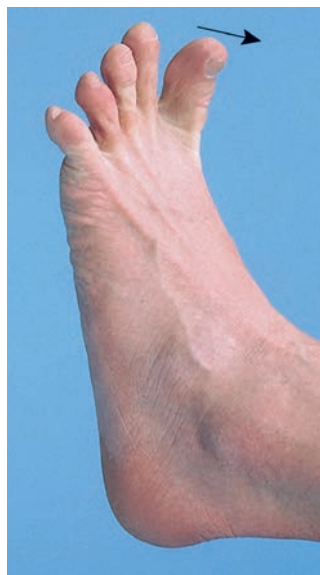Blocks the reuptake of serotonin in the brain, thus increasing levels; examples are fluoxetine (Prozac), citalopram (Celexa), paroxetine (Paxil), sertraline (Zoloft)

**stimulant***STIM-u-lant*

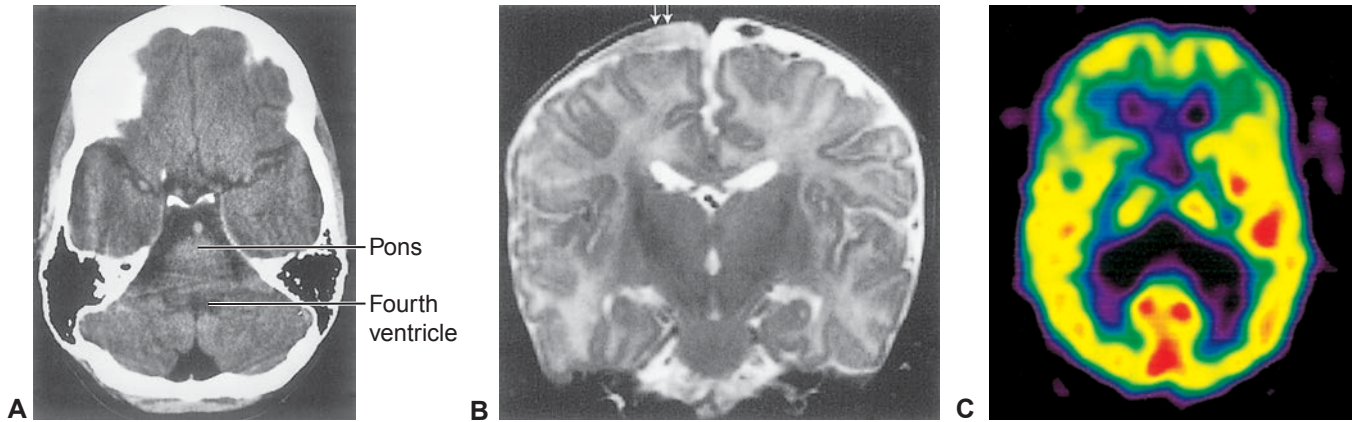
Promotes activity and a sense of well-being; examples are methylphenidate (Ritalin), dextroamphetamine (Dexedrine), amphetamine + dextroamphetamine (Adderall)

**tricyclic antidepressant (TCA)***tri-SI-klik*

Blocks the reuptake of norepinephrine, serotonin, or both; examples are amitriptyline (Elavil), clomipramine (Anafranil), imipramine (Tofranil), doxepin (Sinequan), trimipramine (Surmontil)



**FIGURE 7-17 Babinski reflex.** The big toe bends backward and the other toes spread out when the sole of the foot is stroked. This response is normal in infants but indicates a motor lesion in adults.



**FIGURE 7-18 Brain images.** **A.** CT scan of a normal adult brain. **B.** MRI of the brain showing a subdural hematoma (*arrows*). **C.** PET scan showing regions of different metabolic activity.

## Terminology

## Abbreviations

The abbreviations listed below are emphasized in this chapter. These are also found, collectively, with all chapter abbreviations in Appendix 2.

<b>Ach</b>	Acetylcholine	<b>LP</b>	Lumbar puncture
<b>AD</b>	Alzheimer disease	<b>MAOI</b>	Monoamine oxidase inhibitor
<b>ADHD</b>	Attention deficit hyperactivity disorder	<b>MID</b>	Multi-infarct dementia
<b>ALS</b>	Amyotrophic lateral sclerosis	<b>MTBI</b>	Mild traumatic brain injury
<b>ANS</b>	Autonomic nervous system	<b>MS</b>	Multiple sclerosis
<b>ASD</b>	Autism spectrum disorder	<b>NICU</b>	Neurologic intensive care unit; also neonatal intensive care unit
<b>BAEP</b>	Brainstem auditory evoked potentials	<b>NPH</b>	Normal pressure hydrocephalus
<b>CBF</b>	Cerebral blood flow	<b>NREM</b>	Nonrapid eye movement (sleep)
<b>CJD</b>	Creutzfeldt–Jakob disease	<b>OCD</b>	Obsessive–compulsive disorder
<b>CNS</b>	Central nervous system	<b>PDD</b>	Pervasive developmental disorder
<b>CP</b>	Cerebral palsy	<b>PET</b>	Positron emission tomography
<b>CSF</b>	Cerebrospinal fluid	<b>PNS</b>	Peripheral nervous system
<b>CTE</b>	Chronic traumatic encephalopathy	<b>PTSD</b>	Posttraumatic stress disorder
<b>CVA</b>	Cerebrovascular accident	<b>RAS</b>	Reticular activating system
<b>CVD</b>	Cerebrovascular disease; also cardiovascular disease	<b>REM</b>	Rapid eye movement (sleep)
<b>DSM</b>	<i>Diagnostic and Statistical Manual of Mental Disorders</i>	<b>SSEP</b>	Somatosensory evoked potentials
<b>DTR</b>	Deep tendon reflexes	<b>SSRI</b>	Selective serotonin reuptake inhibitor
<b>EEG</b>	Electroencephalogram; electroencephalograph(y)	<b>TBI</b>	Traumatic brain injury, thrombotic brain infarction
<b>GAD</b>	Generalized anxiety disorder	<b>TCAV</b>	Tricyclic antidepressant
<b>ICP</b>	Intracranial pressure	<b>TIA</b>	Transient ischemic attack
<b>LMN</b>	Lower motor neuron	<b>UMN</b>	Upper motor neuron
<b>LOC</b>	Level of consciousness	<b>VEP</b>	Visual evoked potentials



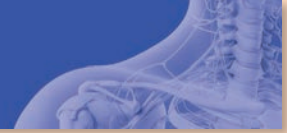## Case Study Revisited

### William's Therapy

From the hospital, William was transferred to a rehabilitation center for further evaluation and therapy. At this point in his recovery, he was unable to move his legs and had limited movement of his arms. He is participating in a plan of care with physical and OT and is working on performing basic activities of daily living. Within therapy, he is practicing wheelchair functional operations, transfers, and safe propulsions. The goal is to progress toward independence within his home lifestyle and regain status as an active member in his school and community.

Recovery from cervical spine injury can take 3 to 6 months and is easier for some individuals than for

others. Because William was active in many sports prior to his injury, his limited mobility in the rehabilitation center was emotionally challenging. In addition to the support and encouragement of his family and many friends, William received psychological counseling to help with his depression and anxiety. After 3 weeks of intense rehabilitation William was able to take small steps and move his shoulders, arms, and fingers. He was discharged home with his parents and after 4 months was able to regain most of his normal functions and participate in moderate activities. After 6 months of recovery, William's surgeon advised him against contact sports, but encouraged him to participate in other sports and pursue a healthy, active lifestyle.



This review tests your understanding of the content introduced in this chapter. Follow the instructions for each exercise and check your answers in Appendix 11.

### LABELING EXERCISE

#### ANATOMIC DIVISIONS OF THE NERVOUS SYSTEM

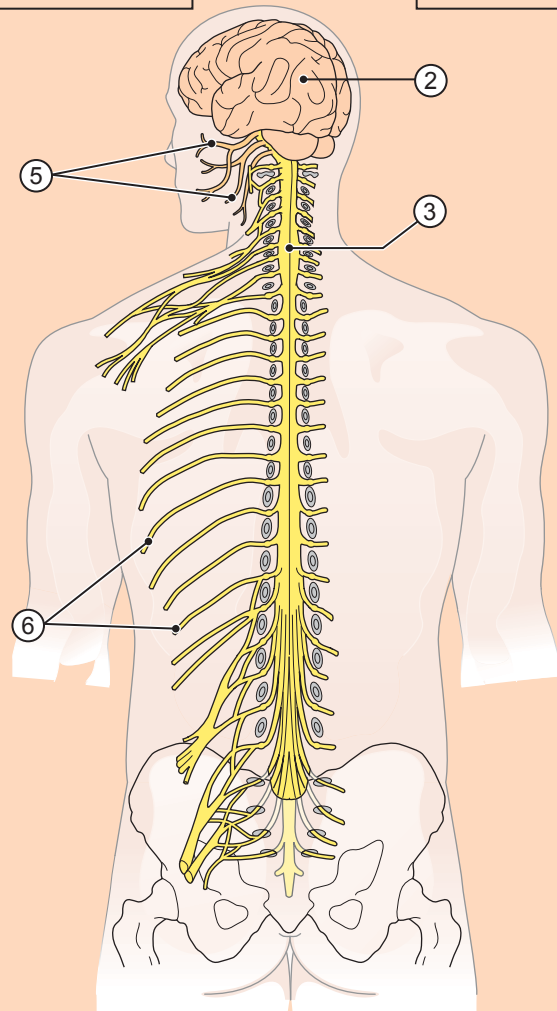
Write the name of each numbered part on the corresponding line.

- |                        |                           |
|------------------------|---------------------------|
| Brain                  | Peripheral nervous system |
| Central nervous system | Spinal cord               |
| Cranial nerves         | Spinal nerves             |

4

1

1. \_\_\_\_\_
2. \_\_\_\_\_
3. \_\_\_\_\_
4. \_\_\_\_\_
5. \_\_\_\_\_
6. \_\_\_\_\_



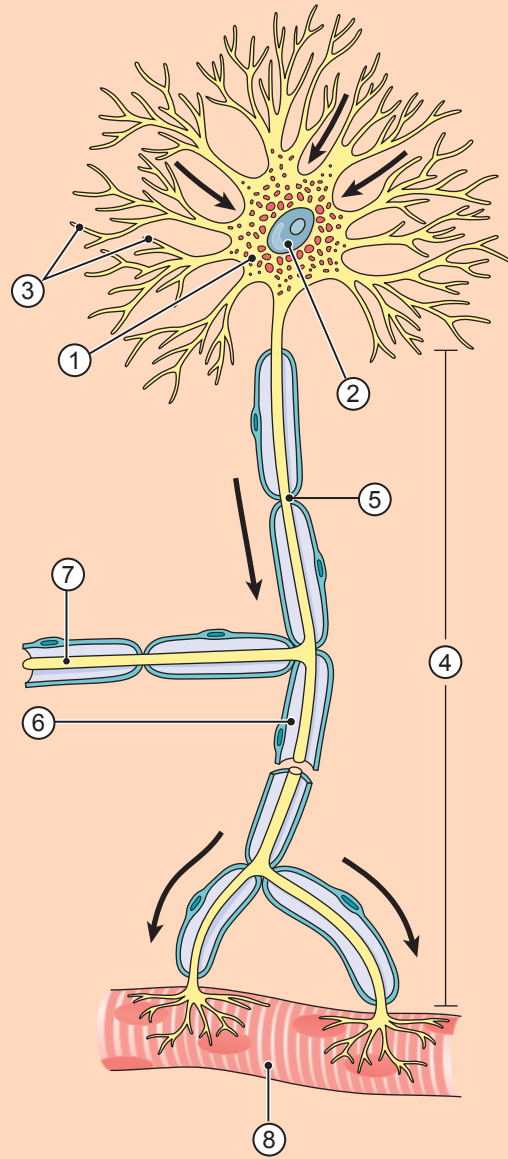
**MOTOR NEURON**

Write the name of each numbered part on the corresponding line.

- Axon branch
- Axon covered with myelin sheath
- Cell body
- Dendrites

- Muscle
- Myelin
- Node
- Nucleus

1. \_\_\_\_\_
2. \_\_\_\_\_
3. \_\_\_\_\_
4. \_\_\_\_\_
5. \_\_\_\_\_
6. \_\_\_\_\_
7. \_\_\_\_\_
8. \_\_\_\_\_

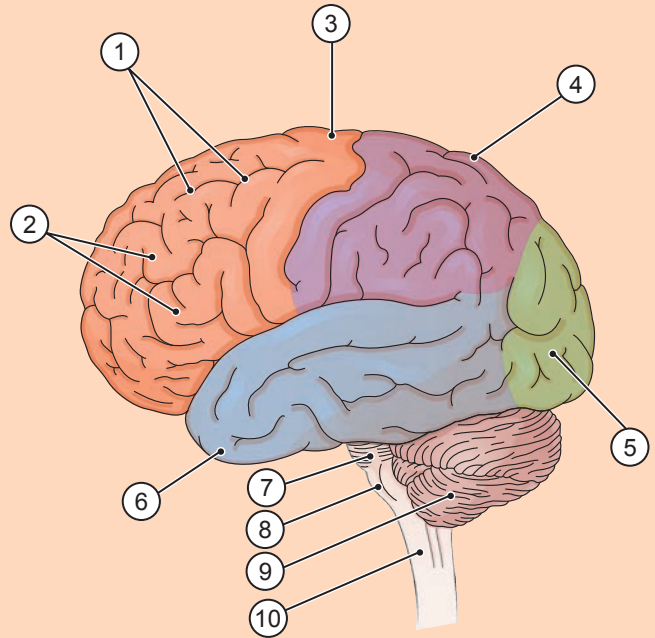


**EXTERNAL SURFACE OF THE BRAIN**

Write the name of each numbered part on the corresponding line.

- |                   |               |
|-------------------|---------------|
| Cerebellum        | Parietal lobe |
| Frontal lobe      | Pons          |
| Gyri              | Spinal cord   |
| Medulla oblongata | Sulci         |
| Occipital lobe    | Temporal lobe |

1. \_\_\_\_\_
2. \_\_\_\_\_
3. \_\_\_\_\_
4. \_\_\_\_\_
5. \_\_\_\_\_
6. \_\_\_\_\_
7. \_\_\_\_\_
8. \_\_\_\_\_
9. \_\_\_\_\_
10. \_\_\_\_\_

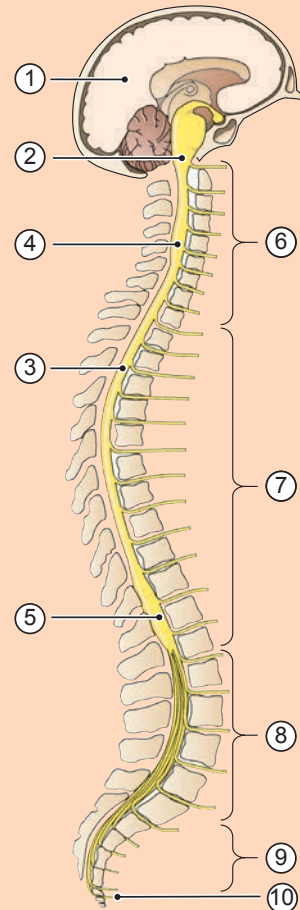


**SPINAL CORD, LATERAL VIEW**

Write the name of each numbered part on the corresponding line.

- |                      |                    |
|----------------------|--------------------|
| Brain                | Lumbar enlargement |
| Brainstem            | Lumbar nerves      |
| Cervical enlargement | Sacral nerves      |
| Cervical nerves      | Spinal cord        |
| Coccygeal nerve      | Thoracic nerves    |

1. \_\_\_\_\_
2. \_\_\_\_\_
3. \_\_\_\_\_
4. \_\_\_\_\_
5. \_\_\_\_\_
6. \_\_\_\_\_
7. \_\_\_\_\_
8. \_\_\_\_\_
9. \_\_\_\_\_
10. \_\_\_\_\_

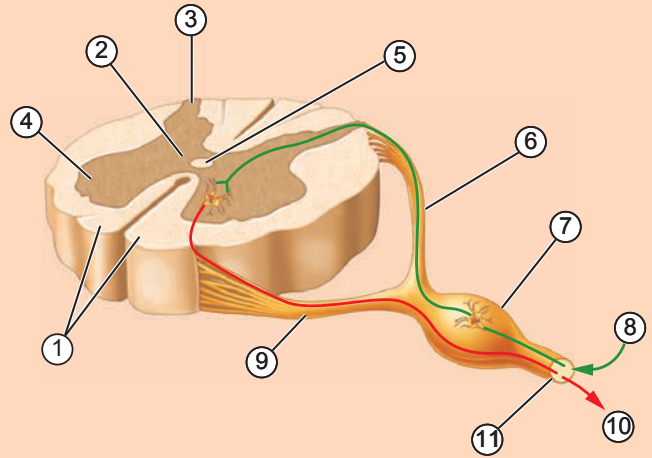


**SPINAL CORD, CROSS-SECTION**

Write the name of each numbered part on the corresponding line.

- |                          |                            |
|--------------------------|----------------------------|
| Central canal            | Sensory (afferent) signals |
| Dorsal horn              | Spinal nerve               |
| Dorsal root              | Ventral horn               |
| Dorsal root ganglion     | Ventral root               |
| Gray matter              | White matter               |
| Motor (efferent) signals |                            |

1. \_\_\_\_\_
2. \_\_\_\_\_
3. \_\_\_\_\_
4. \_\_\_\_\_
5. \_\_\_\_\_
6. \_\_\_\_\_
7. \_\_\_\_\_
8. \_\_\_\_\_
9. \_\_\_\_\_
10. \_\_\_\_\_
11. \_\_\_\_\_

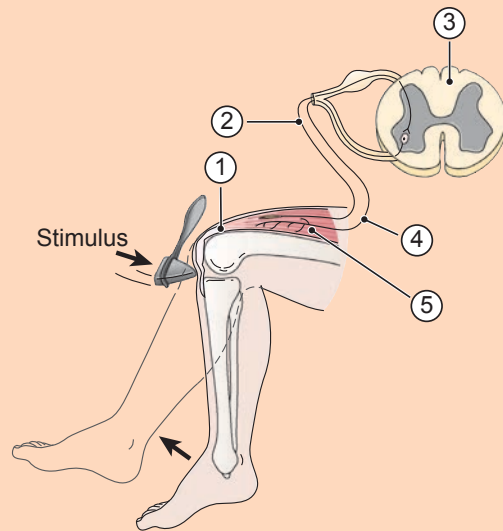


**REFLEX PATHWAY**

Write the name of each numbered part on the corresponding line.

- |              |                   |
|--------------|-------------------|
| Effector     | Sensory neuron    |
| Motor neuron | Spinal cord (CNS) |
| Receptor     |                   |

1. \_\_\_\_\_
2. \_\_\_\_\_
3. \_\_\_\_\_
4. \_\_\_\_\_
5. \_\_\_\_\_



## TERMINOLOGY

### MATCHING

Match the following terms, and write the appropriate letter to the left of each number.

- |                          |  |
|--------------------------|--|
| ___ 1. dendrite          | a. region that connects the brain and spinal cord                |
| ___ 2. medulla oblongata | b. part of the brain that contains the thalamus and pituitary    |
| ___ 3. pons              | c. whitish material that covers some axons                       |
| ___ 4. myelin            | d. rounded area on the ventral surface of the brainstem          |
| ___ 5. diencephalon      | e. fiber of a neuron that conducts impulses toward the cell body |
| ___ 6. contrecoup injury | a. mental disorder associated with delusions of persecution      |
| ___ 7. aphasia           | b. excessive fear of pain  |
| ___ 8. hydrocephalus     | c. loss of speech communication                                  |
| ___ 9. paranoia          | d. accumulation of CSF in the brain                              |
| ___ 10. odynophobia      | e. damage to the brain on the side opposite the point of a blow  |
| ___ 11. cystoplegia      | a. partial paralysis or weakness                                 |
| ___ 12. paresis          | b. paralysis of the bladder                                      |
| ___ 13. meningocele      | c. series of violent, involuntary muscle contractions            |
| ___ 14. convulsion       | d. localized dilation of a blood vessel                          |
| ___ 15. aneurysm         | e. hernia of the meninges and spinal cord                        |

### Enrichment Terms

- |                        |   |
|------------------------|---|
| ___ 16. plexus         | a. a sudden blow or attack                          |
| ___ 17. ipsilateral    | b. a neurotransmitter                               |
| ___ 18. dermatome      | c. area of skin supplied by a spinal nerve          |
| ___ 19. acetylcholine  | d. on the same side; unilateral                     |
| ___ 20. ictus          | e. network  |
| ___ 21. amnesia        | a. fear of being enclosed                           |
| ___ 22. euphoria       | b. state of sluggishness                            |
| ___ 23. claustrophobia | c. loss of memory                                   |
| ___ 24. ataxia         | d. lack of muscle coordination                      |
| ___ 25. lethargy       | e. sense of elation                                 |
| ___ 26. REM            | a. type of psychoactive drug                        |
| ___ 27. SSRI           | b. eye movement during sleep                        |
| ___ 28. DSM            | c. mental disturbances that follow trauma           |
| ___ 29. PTSD           | d. procedure to remove fluid from the spinal column |
| ___ 30. LP             | e. reference for diagnosis of mental disorders      |

**FILL IN THE BLANKS**

*Complete the sentence with the correct term(s).*

31. The largest part of the brain is the \_\_\_\_\_.
32. The fluid that circulates around the central nervous system is \_\_\_\_\_.
33. The support cells of the nervous system are the \_\_\_\_\_.
34. The junction between two nerve cells is a(n) \_\_\_\_\_.
35. The scientific name for a nerve cell is \_\_\_\_\_.
36. The membranes that cover the brain and spinal cord are the \_\_\_\_\_.
37. A simple, rapid, automatic response to a stimulus is a(n) \_\_\_\_\_.
38. The sympathetic and parasympathetic systems make up the \_\_\_\_\_.
39. A chemical that acts at a synapse is a(n) \_\_\_\_\_.
40. The posterior portion of the brain that coordinates muscle movement is the \_\_\_\_\_.
41. The strong, fibrous, outermost cover of the brain and spinal cord is the \_\_\_\_\_.

**DEFINITIONS**

*Define the following words.*

42. corticothalamic (*kor-tih-ko-thah-LAM-ik*) \_\_\_\_\_
43. polyneuritis (*pol-e-nu-RI-tis*) \_\_\_\_\_
44. anencephaly (*an-en-SEF-ah-le*) \_\_\_\_\_
45. hemiparesis (*hem-e-pah-RE-sis*) \_\_\_\_\_
46. radicular (*rah-DIK-u-lar*) \_\_\_\_\_
47. psychotherapy (*si-ko-THER-ah-pe*) \_\_\_\_\_
48. panplegia (*pan-PLE-je-ah*) \_\_\_\_\_
49. encephalomalacia (*en-sef-ah-lo-mah-LA-she-ah*) \_\_\_\_\_
50. dyssomnia (*dis-SOM-ne-ah*) \_\_\_\_\_

*Write words for the following definitions.*

51. study of the nervous system \_\_\_\_\_
52. inflammation of the meninges and spinal cord \_\_\_\_\_
53. excision of a ganglion \_\_\_\_\_
54. any disease of the nervous system \_\_\_\_\_
55. creation of an opening into a brain ventricle \_\_\_\_\_
56. paralysis of one side of the body \_\_\_\_\_
57. within the cerebellum \_\_\_\_\_
58. difficulty in reading \_\_\_\_\_
59. fear of water \_\_\_\_\_
60. paralysis of one limb \_\_\_\_\_

**TRUE-FALSE**

Examine the following statements. If the statement is true, write T in the first blank. If the statement is false, write F in the first blank, and correct the statement by replacing the underlined word in the second blank.

	True or False	Correct Answer
61. <u>Sensory</u> fibers conduct impulses toward the CNS.	_____	_____
62. The spinal nerves are part of the <u>central</u> nervous system.	_____	_____
63. The cervical nerves are in the region of the <u>neck</u> .	_____	_____
64. Myelinated neurons make up the <u>gray</u> matter of the CNS.	_____	_____
65. CSF forms in the <u>ventricles</u> of the brain.	_____	_____
66. The fiber that carries impulses toward the neuron cell body is the <u>axon</u> .	_____	_____
67. There are <u>12</u> pairs of cranial nerves.	_____	_____
68. The innermost layer of the meninges is the <u>pia</u> mater.	_____	_____
69. Hyperlexia refers to increased skill in <u>reading</u> .	_____	_____

**OPPOSITES**

Write a word that means the opposite of the following words.

70. extramedullary	_____
71. ipsilateral	_____
72. postganglionic	_____
73. tachylalia	_____
74. motor	_____
75. dorsal	_____
76. afferent	_____

**ADJECTIVES**

Write the adjective form of the following words.

77. ganglion	_____
78. thalamus	_____
79. dura	_____
80. meninges	_____
81. psychosis	_____

**PLURALS**

Write the plural form of the following words.

82. ganglion	_____
83. ventricle	_____
84. meninx	_____
85. embolus	_____



**ELIMINATIONS**

*In each of the sets below, underline the word that does not fit in with the rest, and explain the reason for your choice.*

86. CVA — lumbar puncture — embolism — thrombus — TIA

\_\_\_\_\_

87. glioma — astrocytoma — meningioma — hematoma — neurilemmoma

\_\_\_\_\_

88. gyri — sulci — mania — ventricles — lobes

\_\_\_\_\_

89. MID — CNS — ADHD — OCD — GAD

\_\_\_\_\_

**WORD BUILDING**

*Write a word for the following definitions using the word parts provided. Each word part can be used more than once.*

-plegia	myel/o	-a-	-itis	dys-	brady-	my/o	tetra-	-paresis	-phasia	gangli/o	hemi-
---------	--------	-----	-------	------	--------	------	--------	----------	---------	----------	-------

90. paralysis of the spinal cord \_\_\_\_\_

91. lack of speech \_\_\_\_\_

92. partial paralysis of one side of the body \_\_\_\_\_

93. muscle weakness \_\_\_\_\_

94. abnormal or difficult speech production \_\_\_\_\_

95. paralysis of a ganglion \_\_\_\_\_

96. paralysis of all four limbs \_\_\_\_\_

97. inflammation of the spinal cord \_\_\_\_\_

98. slowness of speech \_\_\_\_\_

99. paralysis of one side of the body \_\_\_\_\_

100. inflammation of a ganglion \_\_\_\_\_

**WORD ANALYSIS**

*Define each of the following words, and give the meaning of the word parts in each. Use a dictionary if necessary.*

101. hematomyelia (*he-mah-to-mi-E-le-ah*)

a. hemat/o \_\_\_\_\_

b. myel/o \_\_\_\_\_

c. -ia \_\_\_\_\_

102. myelodysplasia (*mi-eh-lo-dis-PLA-se-ah*)

a. myel/o \_\_\_\_\_

b. dys- \_\_\_\_\_

c. plas \_\_\_\_\_

d. -ia \_\_\_\_\_

103. polyneuroradiculitis (*pol-e-nu-ro-rah-dik-u-LI-tis*)

- a. poly- \_\_\_\_\_
- b. neur/o \_\_\_\_\_
- c. radicul/o \_\_\_\_\_
- d. -itis \_\_\_\_\_

104. dyssynergia (*dis-sin-ER-je-ah*)

- a. dys- \_\_\_\_\_
- b. syn- \_\_\_\_\_
- c. erg \_\_\_\_\_
- d. -ia \_\_\_\_\_

# Additional Case Studies

## Case Study 7-1: Cerebrovascular Accident (CVA)

Allen, a 62 y/o man, was admitted to the ED with right hemiplegia and aphasia. He had a history of hypertension and recent transient ischemic attacks (TIAs), yet was in good health when he experienced a sudden onset of right-sided weakness. He arrived in the ED via ambulance within 15 minutes of onset and was received by a member of the hospital's stroke team. He had a rapid general assessment and neuro examination including a Glasgow Coma Scale (GCS) rating to determine his candidacy for fibrinolytic (clot-dissolving) therapy.

He was sent for a noncontrast CT scan to look for evidence of either hemorrhagic or ischemic stroke,

postcardiac arrest ischemia, hypertensive encephalopathy, craniocerebral or cervical trauma, meningitis, encephalitis, brain abscess, tumor, and subdural or epidural hematoma. The CT scan, read by the radiologist, did not show intracerebral or subarachnoid hemorrhage. Allen was diagnosed with probable acute ischemic stroke within 1 hour of the onset of symptoms and was cleared as a candidate for immediate fibrinolytic treatment.

He was admitted to the NICU for 48-hour observation to monitor his neuro status and vital signs. He was discharged after 3 days with a prognosis of full recovery.

### Case Study 7-1 Questions

Follow the instructions for each question and check your answers in Appendix 11.

**Multiple Choice.** Select the best answer, and write the letter of your choice to the left of each number.

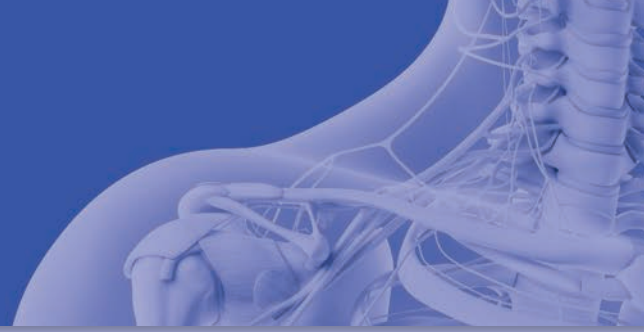- |  |  |
|--|--|
| <p>_____ 1. Ischemic stroke is generally caused by</p> <ul style="list-style-type: none"><li>a. hemorrhage</li><li>b. hematoma</li><li>c. thrombosis</li><li>d. hemangioma</li></ul> <p>_____ 2. Fibrinolytic therapy is directed toward</p> <ul style="list-style-type: none"><li>a. stabilizing blood cells</li><li>b. destroying RBCs</li><li>c. triggering blood clotting</li><li>d. dissolving a blood clot</li></ul> | <p>_____ 3. A general term for any disorder or alteration of brain tissue is</p> <ul style="list-style-type: none"><li>a. encephalopathy</li><li>b. neurocytoma</li><li>c. dysencephaloma</li><li>d. psychosomatic</li></ul> |
|--|--|

Write terms from the case study with the following meanings.

- 4. pertaining to a lack of blood supply \_\_\_\_\_
- 5. inflammation of the meninges \_\_\_\_\_
- 6. collection of blood below the dura mater \_\_\_\_\_
- 7. inability to speak or understand speech \_\_\_\_\_
- 8. partial paralysis on one side \_\_\_\_\_

Define the following abbreviations.

- 9. GCS \_\_\_\_\_
- 10. CT \_\_\_\_\_
- 11. NICU \_\_\_\_\_
- 12. CVA \_\_\_\_\_
- 13. TIA \_\_\_\_\_



## Case Study 7-2: Neuroleptic Malignant Syndrome

Jane, a 21 y/o woman with chronic paranoid schizophrenia, was admitted to the hospital with a diagnosis of pneumonia. She was brought to the ED by her mother, who said Jane had been very lethargic, had a temperature of 104°F, and had had muscular rigidity for 3 days. Her daily medications included Haldol (haloperidol) and Cogentin (benztropine mesylate). Her mother stated that Jane's psychiatrist had changed her neuroleptic medication the week before. Her secondary diagnosis was stated as neuroleptic malignant syndrome, a rare and life-threatening disorder associated with the use of antipsychotic medications. This drug-induced condition is usually characterized by alterations in mental status, temperature regulation, and autonomic and extrapyramidal functions.

Jane was monitored for potential hypotension, tachycardia, diaphoresis, dyspnea, dysphagia, and changes in her LOC. Her medications were discontinued, she was hydrated with IV fluids, and her body temperature was monitored for fluctuations. She was treated with bromocriptine, a dopamine antagonist, and dantrolene, a muscle relaxant and antispasmodic.

After 5 days, Jane was transferred to a mental health facility and restarted on low-dose neuroleptics. She was monitored to prevent a recurrence of the syndrome. Both Jane and her family were educated about neuroleptic malignant syndrome in preparation for her discharge back home in 2 weeks.

7

### Case Study 7-2 Questions

Follow the instructions for each question and check your answers in Appendix 11.

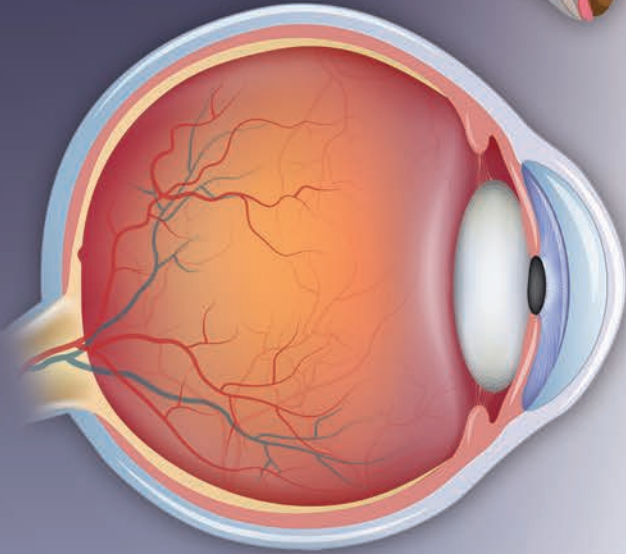
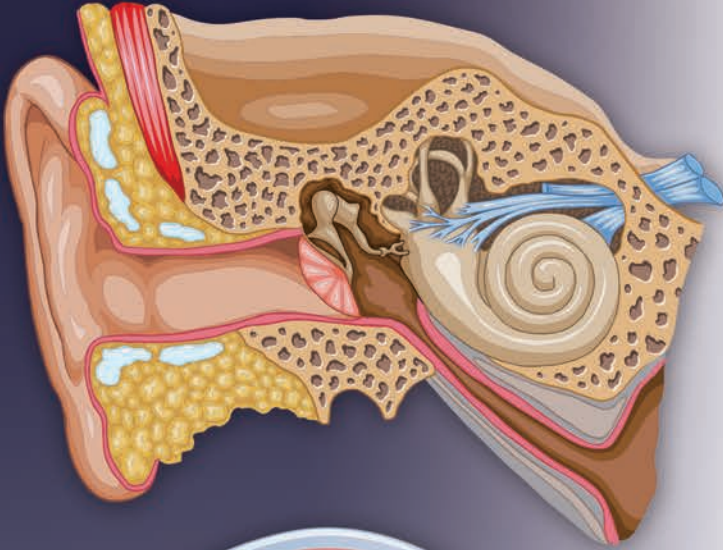
**Multiple Choice.** Select the best answer, and write the letter of your choice to the left of each number.

- |   |   |
|---|---|
| <p>_____ 1. Jane had disease manifestations related to involuntary functions and to movement controlled by motor fibers outside the pyramidal tracts. These functions are</p> <ul style="list-style-type: none"><li>a. autonomic and neuroleptic</li><li>b. autonomic and voluntary</li><li>c. extrapyramidal and pyramidal</li><li>d. autonomic and extrapyramidal</li></ul> | <p>_____ 2. Neuroleptic malignant syndrome is associated with the use of</p> <ul style="list-style-type: none"><li>a. steroids</li><li>b. antipsychotic medications</li><li>c. fibrinolytic therapy</li><li>d. pain medications</li></ul> |
|---|---|

Write terms from the case study with the following meanings.

- 3. describing a state of sluggishness or stupor \_\_\_\_\_
- 4. physician who treats psychiatric disorders \_\_\_\_\_
- 5. antipsychotic medications \_\_\_\_\_
- 6. pertaining to a perceived feeling of threat or harm \_\_\_\_\_
- 7. drug that relieves muscle spasms \_\_\_\_\_
- 8. profuse sweating \_\_\_\_\_

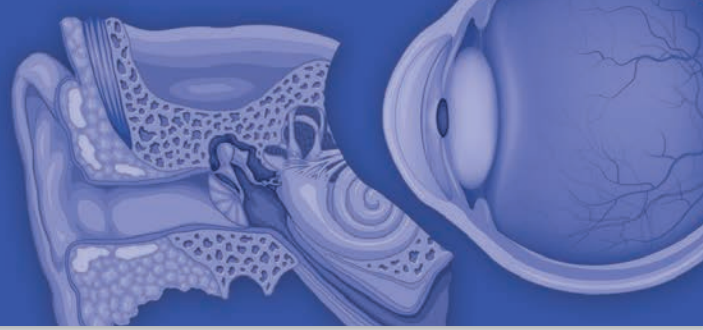
## Special Senses: Ear and Eye



## Pretest

**Multiple Choice.** Select the best answer, and write the letter of your choice to the left of each number. To check your answers go to Appendix 11.

- \_\_\_\_\_ 1. The scientific name for the sense of smell is  
 a. osmosis  
 b. olfaction  
 c. gustation  
 d. dialysis
- \_\_\_\_\_ 2. The term *tactile* refers to the sense of  
 a. touch  
 b. taste  
 c. pain  
 d. temperature
- \_\_\_\_\_ 3. The two senses located in the ear are  
 a. hearing and pressure  
 b. vision and hearing  
 c. balance and taste  
 d. hearing and equilibrium
- \_\_\_\_\_ 4. The receptor layer of the eye is the  
 a. lens  
 b. cornea  
 c. retina  
 d. pinna
- \_\_\_\_\_ 5. The scientific name for the white of the eye is  
 a. pupil  
 b. vitreous body  
 c. sclera  
 d. conjunctiva
- \_\_\_\_\_ 6. Clouding of the lens is termed  
 a. vertigo  
 b. cataract  
 c. tinnitus  
 d. glaucoma
- \_\_\_\_\_ 7. The scientific name for the sense of taste is  
 a. gustation  
 b. olfaction  
 c. proprioception  
 d. osmosis
- \_\_\_\_\_ 8. Acoustic neuroma is a tumor of which cranial nerve sheath?  
 a. fifth  
 b. sixth  
 c. seventh  
 d. eighth



## Learning Objectives

After careful study of this chapter, you should be able to:

- 1 Explain the role of the sensory system. **P260**
- 2 List the parts of the ear and the eye, and briefly describe the function of each structure. **P261**
- 3 Describe the pathway of nerve impulses from the ear to the brain. **P262**
- 4 Describe the roles of the retina and the optic nerve in vision. **P270**
- 5 Identify and use word parts pertaining to the senses. **P273**
- 6 Describe the main disorders pertaining to the ear and the eye. **P273**
- 7 Interpret abbreviations used in the study of the ear and the eye. **P282**
- 8 Analyze medical terms in several case studies pertaining to hearing or vision. **PP259, 290**

## Case Study: Kelly's Amblyopia

E  
H N  
D F N  
P T X Z  
W B I P  
U V



### Chief Complaint

Kelly, a recently adopted 7 y/o female, was seeing a pediatrician, Dr. McLaren, for the first time. Her new family was concerned that Kelly might have visual problems resulting in self-image and schoolwork issues as one of her eyes appeared to deviate inward. Her physical examination was unremarkable except for the eye examination. Dr. McLaren explained to the parents that Kelly had a condition known as strabismic amblyopia, or a “lazy eye,” and made a referral to an ophthalmologist.

### Examination

Upon examining Kelly, the ophthalmologist noted that the left eye deviated toward the medial canthus (angle). A complete visual examination was conducted, and the diagnosis was confirmed. Kelly did have amblyopia, in which one eye has lower visual acuity and is used less than the other eye. She also had slight hyperopia, commonly known as farsightedness. A treatment plan was devised

and directed toward the development of normal visual acuity. It was discussed with the parents, who decided to move forward with the therapy.

### Clinical Course

The ophthalmologist explained to Kelly that they wanted to make her weak eye stronger so she would see much better. This would be accomplished by putting a patch over the strong eye, which should correct the deviation. She would need to wear the patch for a prescribed number of hours each day, and she would also need to wear glasses. She would need to return to see the ophthalmologist so progress could be measured. While Kelly was not sure of the patch, she was excited about wearing glasses since her new mom and sister also wore glasses. She was fitted for glasses and provided with the “bandaid” type of patch to apply over her right eye.

**Case Study Revisited: Once you complete this chapter, please review the case follow-up on p. 282.**

## Ancillaries *At-A-Glance*

Visit the web resource to access the following resources.

### Learning Resources

- eBook
- A&P Module with Heart & Lung Sounds
- Image Bank
- TestPrep
- Animations
- Audio Pronunciation Glossary

## Introduction

The sensory system is our network for detecting stimuli from the internal and external environments. It is needed to maintain homeostasis, provide us with pleasure, and protect us from harm. Pain, for example, is an important warning sign of tissue damage. The signals generated in the various **sensory receptors** must be transmitted to the central nervous system for interpretation.

## The Senses

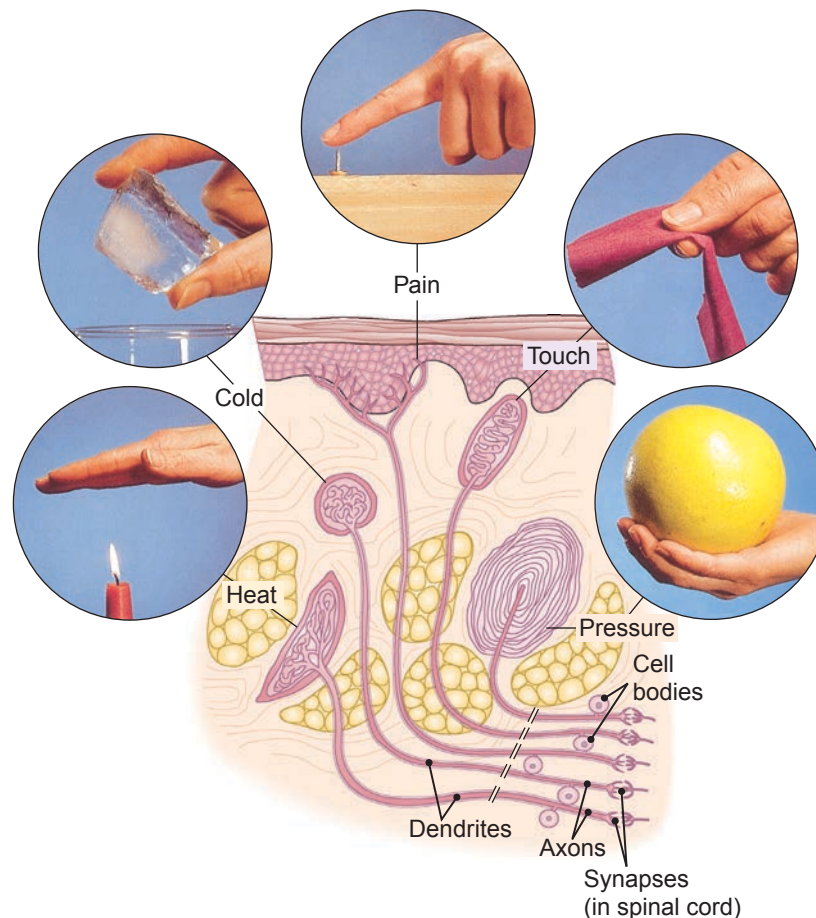
The senses are divided according to whether they are widely distributed or localized in special sense organs. The receptors for the general senses are found throughout the body. Many are located in the skin (**FIG. 8-1**). These senses include the following:

- **Pain.** These receptors are found in the skin and also in muscles, joints, and internal organs.
- **Touch,** the **tactile** sense, located in the skin. Sensitivity to touch depends on the concentration of these receptors in different areas—high on the fingers, lips, and tongue, for example, but low at the back of the neck or back of the hand.

- **Pressure,** or deep touch, located beneath the skin and in deeper tissues.
- **Temperature.** Receptors for heat and cold are located in the skin and also in the hypothalamus, which regulates body temperature.
- **Proprioception,** the awareness of body position. Receptors in muscles, tendons, and joints help to judge body position and coordinate muscle activity. They also help to maintain muscle tone.

The special senses are localized within complex sense organs in the head. These include the following:

- **Gustation** (taste) is located in receptors in taste buds on the tongue. These receptors basically detect only sweet, sour, bitter, salty, and umami (*oo-MOM-e*), a savory flavor triggered by certain amino acids and found in proteins and the flavor enhancer MSG. Researchers have also identified receptors for alkali (bases) and metallic tastes. The senses of smell and taste are chemical senses, that is, they respond to chemicals in solution.
- **Olfaction** (smell) is located in receptors in the nose. Many more chemicals can be discriminated by smell than by taste. Both senses are important in stimulating appetite and warning of harmful substances.



**FIGURE 8-1** Receptors for general senses in the skin. Synapses for these pathways are in the spinal cord.

- **Hearing** receptors are located in the ear. These receptors respond to movement created by sound waves as they travel through the ear.
- **Equilibrium** receptors are also located in the ear. These receptors are activated by changes in the position of cells in the inner ear as we move.
- **Vision** receptors are light-sensitive and located deep within the eye, protected by surrounding bone and other

support structures. The coordinated actions of external and internal eye muscles help in the formation of a clear image.

Suffixes pertaining to the senses are listed in **TABLE 8-1**. The remainder of this chapter concentrates on hearing and vision, the senses that have received the most clinical attention.

## Terminology

## Key Terms

The terms listed below are emphasized in this chapter. Knowing them will help you organize and prioritize your learning. These boldface terms are also found, collectively, with all chapter key terms in the Glossary.

### Senses

#### Normal Structure and Function

<b>equilibrium</b> <i>e-kwih-LIB-re-um</i>	The sense of balance
<b>gustation</b> <i>gus-TA-shun</i>	The sense of taste (Latin <i>geusis</i> means “taste”)
<b>hearing</b> <i>HERE-ing</i>	The sense or perception of sound
<b>olfaction</b> <i>ol-FAK-shun</i>	The sense of smell (root <i>osm/o</i> means “smell”)
<b>proprioception</b> <i>pro-pre-o-SEP-shun</i>	The awareness of posture, movement, and changes in equilibrium; receptors are located in muscles, tendons, and joints
<b>sensory receptor</b> <i>re-SEP-tor</i>	A sensory nerve ending or a specialized structure associated with a sensory nerve that responds to a stimulus
<b>tactile</b> <i>TAK-til</i>	Pertaining to the sense of touch
<b>vision</b> <i>VIZH-un</i>	The sense by which the shape, size, and color of objects are perceived by means of the light they give off

Table 8-1

### Suffixes Pertaining to the Senses

Suffix	Meaning	Example	Definition of Example
-esthesia	sensation	cryesthesia <i>kri-es-THE-ze-ab</i>	sensitivity to cold
-algisia	pain	hypalgisia <sup>a</sup> <i>hi-pal-JE-ze-ab</i>	decreased sensitivity to pain
-osmia	sense of smell	pseudosmia <i>su-DOS-me-ab</i>	false sense of smell
-geusia	sense of taste	parageusia <i>par-ab-GU-ze-ab</i>	abnormal (para-) sense of taste

<sup>a</sup>Prefix hyp/o.



## Exercise 8-1

Complete the exercise. To check your answers go to Appendix 11.

Define the following words.

1. analgesia (*an-al-JE-ze-ab*)
2. parosmia (*par-OZ-me-ab*)
3. ageusia (*ah-GU-ze-ab*)

---



---



---

Write words for the following definitions.

4. muscular (my/o-) sensation
5. false sense of taste
6. sensitivity to temperature
7. excess sensitivity to pain
8. abnormal (dys-) sense of taste
9. lack (an-) of sensation

---



---



---



---



---



---

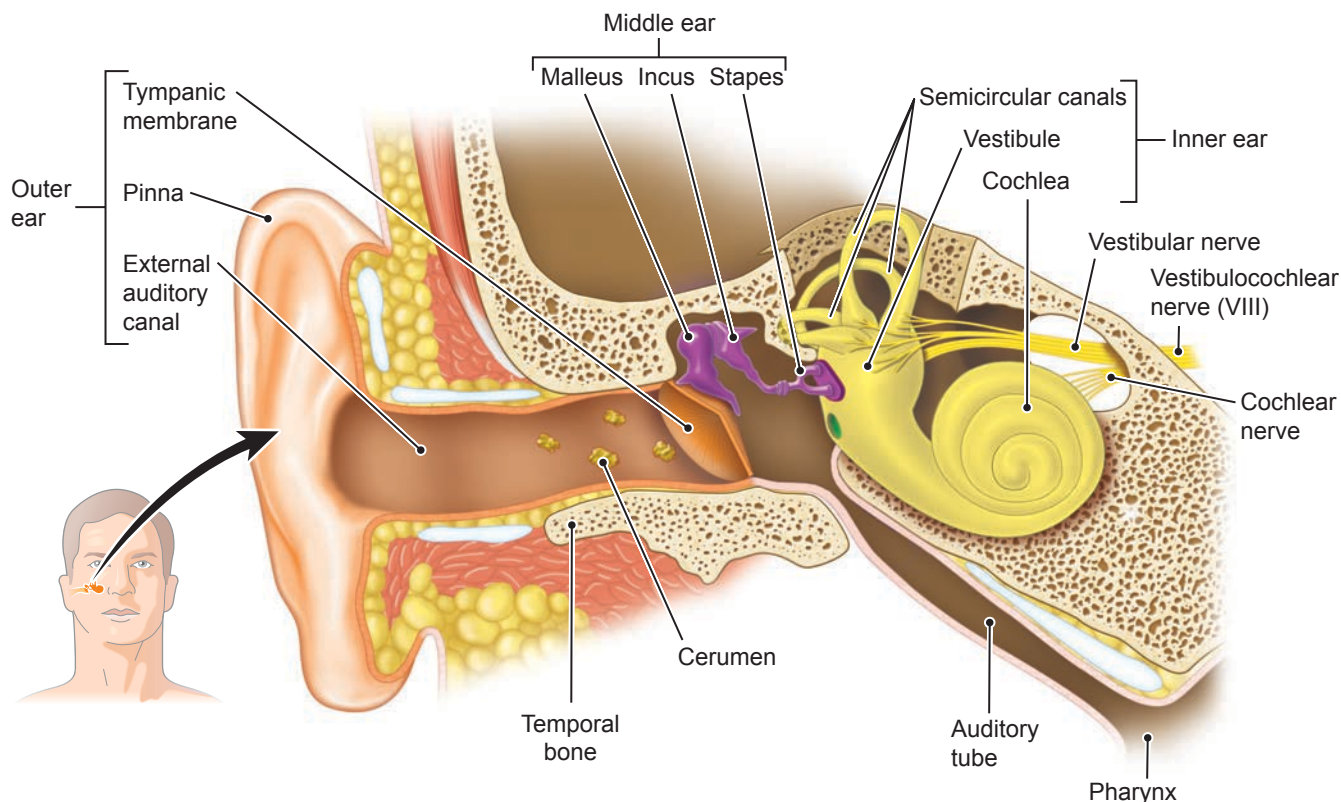
## The Ear

The ear has the receptors for both hearing and equilibrium. For study purposes, it may be divided into three parts: the outer, middle, and inner ear (FIG. 8-2).

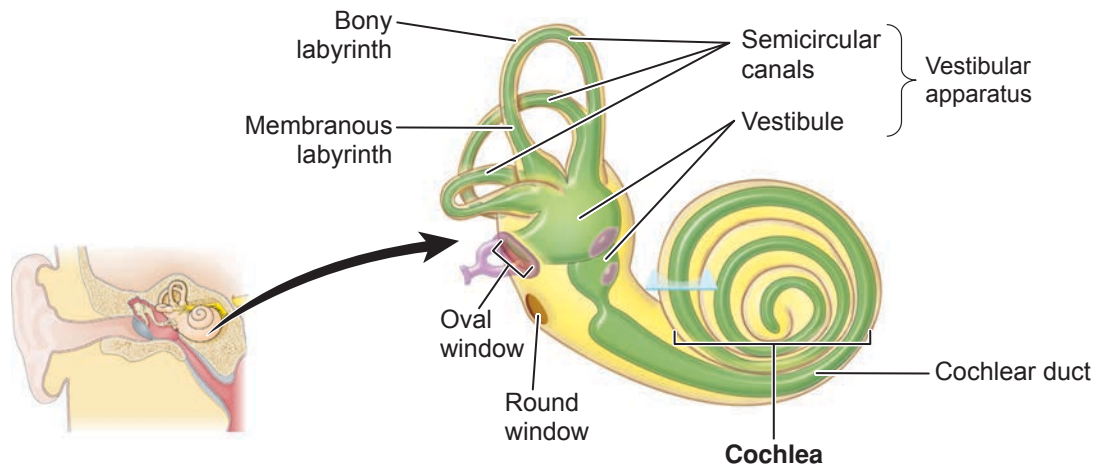
The outer ear consists of the projecting **pinna** (auricle) and the **external auditory canal** (meatus). This canal ends

at the **tympanic membrane**, or eardrum, which transmits sound waves to the middle ear. Glands in the external canal produce a waxy material, **cerumen**, which protects the ear and helps to prevent infection.

Spanning the middle ear cavity are three **ossicles** (small bones), each named for its shape: the **malleus** (hammer), **incus** (anvil), and **stapes** (stirrup) (see FIG. 8-2). Sound waves



**FIGURE 8-2** The ear. Structures in the outer, middle, and inner divisions are shown.



**FIGURE 8-3 The inner ear.** The outer bony labyrinth contains the membranous labyrinth. Receptors for equilibrium are in the vestibule and the semicircular canals. The cochlea contains the hearing receptor, the spiral organ. Sound waves enter the cochlea through the oval window, travel through the cochlea, and exit through the round window. The inner ear transmits impulses to the brain in the vestibulocochlear nerve (eighth cranial nerve).

traveling over the ossicles are transmitted from the footplate of the stapes to the inner ear. The **auditory tube**, also called the *eustachian tube*, connects the middle ear with the nasopharynx and serves to equalize pressure between the outer ear and the middle ear.

The inner ear, because of its complex shape, is described as a **labyrinth**, which means “maze” (FIG. 8-3). It consists of an outer bony framework containing a similarly shaped membranous channel. The entire labyrinth is filled with fluid.

The **cochlea**, shaped like a snail’s shell, has the specialized **spiral organ** (organ of Corti), which is concerned with hearing. Cells in this receptor organ respond to sound waves traveling through the cochlea’s fluid-filled ducts. Sound waves enter the cochlea from the base of the stapes

through an opening, the oval window, and leave through another opening, the round window (see FIG. 8-3).

The sense of equilibrium is localized in the **vestibular apparatus**. This structure consists of the chamber-like **vestibule** and three projecting **semicircular canals**. Special cells within the vestibular apparatus respond to movement. (The senses of vision and proprioception are also important in maintaining balance.)

Nerve impulses are transmitted from the ear to the brain by way of the **vestibulocochlear nerve**, the eighth cranial nerve, also called the acoustic or auditory nerve. The cochlear branch of this nerve transmits impulses for hearing from the cochlea; the vestibular branch transmits impulses concerned with equilibrium from the vestibular apparatus (see FIG. 8-3). Roots pertaining to the ear and hearing are in TABLE 8-2.

## Terminology

## Key Terms

The terms listed below are emphasized in this chapter. Knowing them will help you organize and prioritize your learning. These boldface terms are also found, collectively, with all chapter key terms in the Glossary.

### The Ear

#### Normal Structure and Function

<b>auditory tube</b> <i>aw-dih-TO-re</i>	The tube that connects the middle ear with the nasopharynx and serves to equalize pressure between the outer and middle ear (root: salping/o); pharyngotympanic tube; originally called the eustachian ( <i>u-STA-shen</i> ) tube
<b>cerumen</b> <i>seh-RU-men</i>	The brownish, wax-like secretion formed in the external ear canal to protect the ear and prevent infection (adjective: ceruminous [ <i>seh-RU-mih-nus</i> ])
<b>cochlea</b> <i>KOK-le-ah</i>	The coiled portion of the inner ear that contains the receptors for hearing (root: cochle/o)
<b>external auditory canal</b> <i>aw-dih-TO-re</i>	Tube that extends from the pinna of the ear to the tympanic membrane; external auditory meatus

(continued)

## Terminology

## Key Terms (Continued)

<b>incus</b> <i>ING-kus</i>	The middle ossicle of the ear
<b>labyrinth</b> <i>LAB-ib-rinth</i>	The inner ear, named for its complex structure, which resembles a maze
<b>malleus</b> <i>MAL-e-us</i>	The ossicle of the middle ear that is in contact with the tympanic membrane and the incus
<b>ossicles</b> <i>OS-ih-klz</i>	The small bones of the middle ear; the malleus, incus, and stapes
<b>pinna</b> <i>PIN-ab</i>	The projecting part of the outer ear; auricle ( <i>AW-ri-kl</i> )
<b>semicircular canals</b>	The three curved channels of the inner ear that hold receptors for equilibrium
<b>spiral organ</b> <i>SPI-ral</i>	The hearing receptor, which is located in the cochlea of the inner ear; organ of Corti ( <i>KOR-te</i> )
<b>stapes</b> <i>STA-peze</i>	The ossicle that is in contact with the inner ear (roots: staped/o, stapedi/o)
<b>tympanic membrane</b> <i>tim-PAN-ik</i>	The membrane between the external auditory canal and the middle ear (tympanic cavity); the eardrum; it serves to transmit sound waves to the ossicles of the middle ear (roots: myring/o, tympan/o)
<b>vestibular apparatus</b> <i>ves-TIB-u-lar</i>	The portion of the inner ear that is concerned with the sense of equilibrium; it consists of the vestibule and the semicircular canals (root: vestibul/o)
<b>vestibule</b> <i>VES-tih-bule</i>	The chamber in the inner ear that holds some of the receptors for equilibrium
<b>vestibulocochlear nerve</b> <i>ves-tib-u-lo-KOK-le-ar</i>	The nerve that transmits impulses for hearing and equilibrium from the ear to the brain; eighth cranial nerve; auditory or acoustic nerve

Table 8-2

## Roots Pertaining to the Ear and Hearing

Root	Meaning	Example	Definition of Example
audi/o	hearing	audiology <i>aw-de-OL-o-je</i>	the study of hearing
acous, acus, cus	sound, hearing	acoustic <i>ah-KU-stik</i>	pertaining to sound or hearing
ot/o	ear	ototoxic <i>o-to-TOKS-ik</i>	poisonous or harmful to the ear
myring/o	tympanic membrane	myringotome <i>mih-RING-go-tome</i>	knife used for surgery on the eardrum
tympan/o	tympanic cavity (middle ear), tympanic membrane	tympanometry <i>tim-pah-NOM-eh-tre</i>	measurement of transmission through the tympanic membrane and middle ear
salping/o	tube, auditory tube	salpingoscopy <i>sal-ping-GOS-ko-pe</i>	endoscopic examination of the auditory tube
staped/o, stapedi/o	stapes	stapedoplasty <i>sta-pe-do-PLAS-te</i>	plastic repair of the stapes

Table 8-2

## Roots Pertaining to the Ear and Hearing (Continued)

Root	Meaning	Example	Definition of Example
labyrinth/o	labyrinth (inner ear)	labyrinthitis <i>lab-ih-rin-THI-tis</i>	inflammation of the inner ear (labyrinth)
vestibul/o	vestibule, vestibular apparatus	vestibulotomy <i>ves-tib-u-LOT-o-me</i>	incision of the vestibule of the inner ear
cochle/o	cochlea (of inner ear)	retrocochlear <i>ret-ro-KOK-le-ar</i>	behind the cochlea

## Exercise 8-2

8

Complete the exercise. To check your answers go to Appendix 11.

Fill in the blanks.

1. Audition (*aw-DISH-un*) is the act of \_\_\_\_\_.
2. Hyperacusis (*hi-per-ah-KU-sis*) is abnormally high sensitivity to \_\_\_\_\_.
3. Otopathy (*o-TOP-ah-the*) means any disease of the \_\_\_\_\_.

Define the following adjectives.

4. stapedial (*sta-PE-de-al*) \_\_\_\_\_
5. cochlear (*KOK-le-ar*) \_\_\_\_\_
6. vestibular (*ves-TIB-u-lar*) \_\_\_\_\_
7. auditory (*AW-dih-tor-e*) \_\_\_\_\_
8. labyrinthine (*lab-ih-RIN-thene*) \_\_\_\_\_
9. otic (*O-tik*) \_\_\_\_\_

Write words for the following definitions.

10. pain in the ear \_\_\_\_\_
11. incision of the labyrinth \_\_\_\_\_
12. endoscope for examining the auditory tube \_\_\_\_\_
13. instrument used to examine the ear \_\_\_\_\_
14. within the cochlea \_\_\_\_\_
15. pertaining to the vestibular apparatus and cochlea \_\_\_\_\_
16. measurement of hearing (audi/o-) \_\_\_\_\_
17. plastic repair of the middle ear \_\_\_\_\_
18. excision of the stapes \_\_\_\_\_

Define the following words.

19. tympanitis (*tim-pah-NI-tis*) \_\_\_\_\_
20. audiometer (*aw-de-OM-eh-ter*) \_\_\_\_\_
21. vestibulopathy (*ves-tib-u-LOP-ah-the*) \_\_\_\_\_
22. salpingopharyngeal (*sal-ping-go-fah-RIN-je-al*) \_\_\_\_\_
23. myringostapediopexy (*mih-RING-go-sta-pe-de-o-PEK-se*) \_\_\_\_\_

## Clinical Aspects of Hearing

### HEARING LOSS

Hearing impairment may result from disease, injury, or developmental problems that affect the ear itself or any nervous pathways concerned with the sense of hearing.

**Sensorineural hearing loss** results from damage to the inner ear, the eighth cranial nerve, or central auditory pathways. Heredity, toxins, exposure to loud noises, and the aging process are possible causes for this type of hearing loss. It may range from inability to hear certain sound frequencies to a complete loss of hearing (deafness). People with extreme hearing loss that originates in the inner ear may benefit from a cochlear implant. This prosthesis stimulates the cochlear nerve directly, bypassing the receptor cells of the inner ear, and may allow the recipient to hear medium to loud sounds.

**Conductive hearing loss** results from blockage in sound transmission to the inner ear. Causes include obstruction, severe infection, or fixation of the middle ear ossicles. Often, physicians can successfully treat the conditions that cause conductive hearing loss.

**BOX 8-1** has information on careers in audiology, the study, and treatment of hearing disorders.

### OTITIS

Otitis is any inflammation of the ear. **Otitis media** refers to an infection that leads to fluid accumulation in the middle ear cavity. One cause is malfunction or obstruction of the auditory tube, as by allergy, enlarged adenoids, injury, or congenital abnormalities. Another cause is infection that spreads to the middle ear, most commonly from the upper respiratory tract. Continued infection may lead to accumulation of pus and perforation of the eardrum. Otitis media usually affects children under 5 years of age and may result in hearing loss. If not treated with antibiotics, the infection may spread to other regions of the ear and head. An incision, a **myringotomy**, and placement of a tube in the tympanic membrane helps to ventilate and drain the middle ear cavity in cases of otitis media.

**Otitis externa** is inflammation of the external auditory canal caused by repeated fungal or bacterial infections. It is most common among those living in hot climates and among swimmers, leading to the alternative name, “swimmer’s ear.”

### OTOSCLEROSIS

In **otosclerosis**, the bony structure of the inner ear deteriorates and then reforms into spongy bone tissue that may eventually harden. Most commonly, the stapes becomes fixed against the inner ear and is unable to vibrate, resulting in conductive hearing loss. The cause of otosclerosis is unknown, but some cases are hereditary. Surgeons usually can remove the damaged bone. In a **stapedectomy**, the stapes is removed, and a prosthetic bone is inserted.

### MÉNIÈRE DISEASE

**Ménière disease** is a disorder that affects the inner ear. It seems to involve production and circulation of the fluid that fills the inner ear, but the cause is unknown. The symptoms include **vertigo** (dizziness), hearing loss, **tinnitus** (ringing in the ears), and a feeling of pressure in the ear. The course of the disease is uneven, and symptoms may become less severe with time. Ménière disease is treated with drugs to control nausea and dizziness, such as those used to treat motion sickness. In severe cases, the inner ear or part of the eighth cranial nerve may be surgically destroyed.

### ACOUSTIC NEUROMA

An **acoustic neuroma** (also called schwannoma or neurilemmoma) is a tumor that arises from the neurilemma (sheath) of the eighth cranial nerve. As the tumor enlarges, it presses on surrounding nerves and interferes with blood supply. This leads to tinnitus, dizziness, and progressive hearing loss. Other symptoms develop as the tumor presses on the brainstem and other cranial nerves. Usually, it is necessary to remove the tumor surgically.



## HEALTH PROFESSIONS

### Audiologists

#### BOX 8-1

Audiologists specialize in preventing, diagnosing, and treating hearing disorders that may be caused by injury, infection, birth defects, noise, or aging. They take a complete patient history to diagnose hearing disorders and use specialized equipment to measure hearing acuity. Audiologists design and implement individualized treatment plans, which may include fitting clients with assistive listening devices, such as hearing aids, or teaching alternative communication skills, such as lip reading. Audiologists also measure workplace and community noise levels and teach the public how to prevent hearing loss. Whereas in the past, audiologists had to have a master’s degree, a doctoral degree is becoming more commonly the

entry degree required for licensure in the United States. All 50 states require practicing audiologists to pass a national licensing exam and be registered or licensed. In some states, audiologists who dispense hearing aids must have a hearing aid dispenser license, which is separate from their license to practice audiology.

Audiologists work in a variety of settings, such as hospitals, nursing care facilities, schools, clinics, and industry. Job prospects are good, as the need for audiologists’ specialized skills will increase as populations age. The American Academy of Audiology at [audiology.org](http://audiology.org) has more information on this career.

## Terminology

### Key Terms

The terms listed below are emphasized in this chapter. Knowing them will help you organize and prioritize your learning. These boldface terms are also found, collectively, with all chapter key terms in the Glossary.

#### The Ear

##### Disorders

<b>acoustic neuroma</b> <i>ah-KU-stik nu-RO-mah</i>	A tumor of the eighth cranial nerve sheath; although benign, it can press on surrounding tissue and produce symptoms; also called an acoustic or vestibular schwannoma or acoustic neurilemmoma
<b>conductive hearing loss</b>	Hearing impairment that results from blockage of sound transmission to the inner ear
<b>Ménière disease</b> <i>men-NYARE</i>	A disease associated with increased fluid pressure in the inner ear and characterized by hearing loss, vertigo, and tinnitus
<b>otitis externa</b> <i>o-TI-tis ex-TER-nah</i>	Inflammation of the external auditory canal; swimmer's ear
<b>otitis media</b> <i>o-TI-tis ME-de-ah</i>	Inflammation of the middle ear with accumulation of serous (watery) or mucoid fluid
<b>otosclerosis</b> <i>o-to-skleh-RO-sis</i>	Formation of abnormal and sometimes hardened bony tissue in the ear; it usually occurs around the oval window and the footplate (base) of the stapes, causing immobilization of the stapes and progressive hearing loss
<b>sensorineural hearing loss</b> <i>sen-so-re-NU-ral</i>	Hearing impairment that results from damage to the inner ear, eighth cranial nerve, or auditory pathways in the brain
<b>tinnitus</b> <i>TIN-ih-tus</i>	A sensation of noises, such as ringing or tinkling, in the ear; also pronounced <i>tih-NI-tus</i>
<b>vertigo</b> <i>VER-tih-go</i>	An illusion of movement, as of the body moving in space or the environment moving about the body; usually caused by disturbances in the vestibular apparatus; used loosely to mean dizziness or lightheadedness

##### Treatment

<b>myringotomy</b> <i>mir-in-GOT-o-me</i>	Surgical incision of the tympanic membrane; performed to drain the middle ear cavity or to insert a tube into the tympanic membrane for drainage
<b>stapedectomy</b> <i>sta-pe-DEK-to-me</i>	Surgical removal of the stapes; it may be combined with insertion of a prosthesis to correct otosclerosis

## Terminology

### Enrichment Terms

The terms listed below expand on the key terms to increase your knowledge of this chapter topic.

#### Normal Structure and Function

<b>aural</b> <i>AW-ral</i>	Pertaining to or perceived by the ear
<b>decibel (dB)</b> <i>DES-ih-bel</i>	A unit for measuring the relative intensity of sound
<b>hertz (Hz)</b>	A unit for measuring the frequency (pitch) of sound
<b>mastoid process</b>	A small projection of the temporal bone behind the external auditory canal; it consists of loosely arranged bony material and small, air-filled cavities
<b>stapedius</b> <i>sta-PE-de-us</i>	A small muscle attached to the stapes; it contracts in the presence of a loud sound, producing the acoustic reflex

#### Symptoms and Conditions

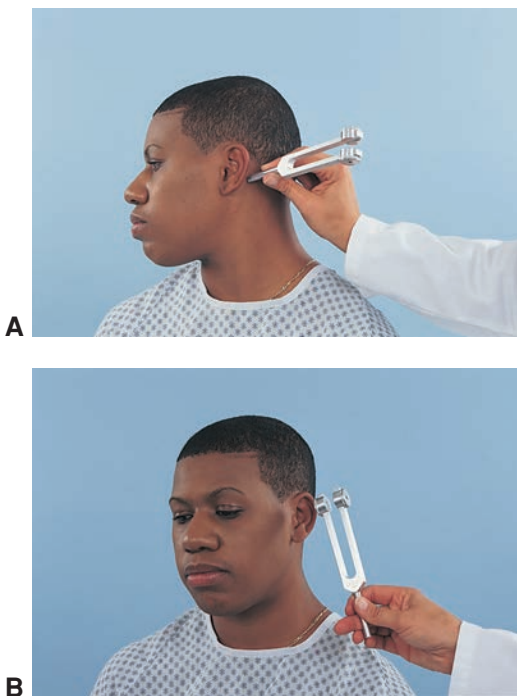
<b>cholesteatoma</b> <i>ko-les-te-ah-TO-mah</i>	A cyst-like mass containing cholesterol that is most common in the middle ear and mastoid region; a possible complication of chronic middle ear infection
--	---

(continued)

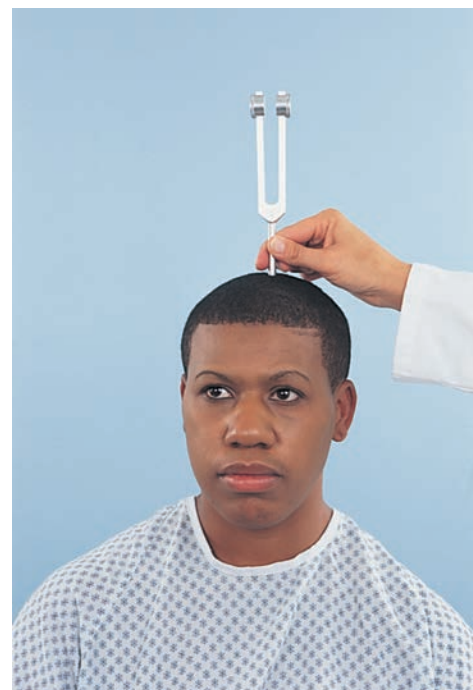## Terminology

## Enrichment Terms (Continued)

<b>labyrinthitis</b> <i>lab-ih-rin-THI-tis</i>	Inflammation of the ear's labyrinth (inner ear); otitis interna
<b>mastoiditis</b> <i>mas-toyd-I-tis</i>	Inflammation of the air cells of the mastoid process
<b>presbycusis</b> <i>prez-be-ab-KU-sis</i>	Loss of hearing caused by aging
<b>Diagnosis and Treatment</b>	
<b>audiometry</b> <i>aw-de-OM-eh-tre</i>	Measurement of hearing
<b>electronystagmography (ENG)</b> <i>e-lek-tro-nis-tag-MOG-rah-fe</i>	A method for recording eye movements by means of electrical responses; such movements may reflect vestibular dysfunction
<b>otorhinolaryngology (ORL)</b> <i>o-to-ri-no-lar-in-GOL-o-je</i>	The branch of medicine that deals with diseases of the ear(s), nose, and throat (ENT); also called otolaryngology (OL)
<b>otoscope</b> <i>O-to-skope</i>	Instrument for examining the ear (see <b>FIG. 3-11B</b> )
<b>Rinne test</b> <i>RIN-ne</i>	Test that measures hearing by comparing results of bone conduction and air conduction ( <b>FIG. 8-4</b> ); bone conduction is tested through the mastoid process behind the ear
<b>spondee</b> <i>spou-de</i>	A two-syllable word with equal stress on each syllable; used in hearing tests; examples are toothbrush, baseball, cowboy, pancake
<b>Weber test</b>	Test for hearing loss that uses a vibrating tuning fork placed at the center of the head ( <b>FIG. 8-5</b> )



**FIGURE 8-4 The Rinne test.** This test assesses both bone and air conduction of sound. **A.** Test of bone conduction through the mastoid process behind the ear. **B.** Test of air conduction.



**FIGURE 8-5 The Weber test.** This test assesses bone conduction of sound.

## Terminology *Abbreviations*

The abbreviations listed below are emphasized in this chapter. These are also found, collectively, with all chapter abbreviations in Appendix 2.

### The Ear

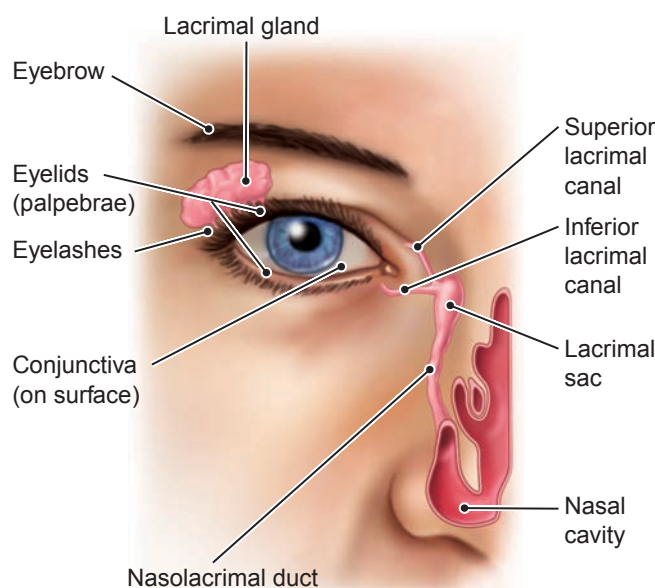
<b>ABR</b>	Auditory brainstem response	<b>Hz</b>	Hertz
<b>AC</b>	Air conduction	<b>OL</b>	Otolaryngology
<b>BAEP</b>	Brainstem auditory evoked potentials	<b>OM</b>	Otitis media
<b>BC</b>	Bone conduction	<b>ORL</b>	Otorhinolaryngology
<b>dB</b>	Decibel	<b>ST</b>	Speech threshold
<b>ENG</b>	Electronystagmography	<b>TM</b>	Tympanic membrane
<b>ENT</b>	Ear(s), nose, and throat	<b>TTS</b>	Temporary threshold shift
<b>HL</b>	Hearing level		

## The Eye and Vision

The eye is protected by its position within a bony socket or **orbit**. It is also protected by the eyelids, or **palpebrae**; eyebrows; and eyelashes (**FIG. 8-6**). The **lacrimal** (tear) **glands** constantly bathe and cleanse the eyes with a lubricating fluid that drains into the nose. The protective **conjunctiva** is a thin membrane that lines the eyelids and covers the anterior portion of the eye. This membrane folds back to form a narrow space between the eyeball and the eyelids. Medications, such as eye drops and eye ointments, can be instilled into this conjunctival sac.

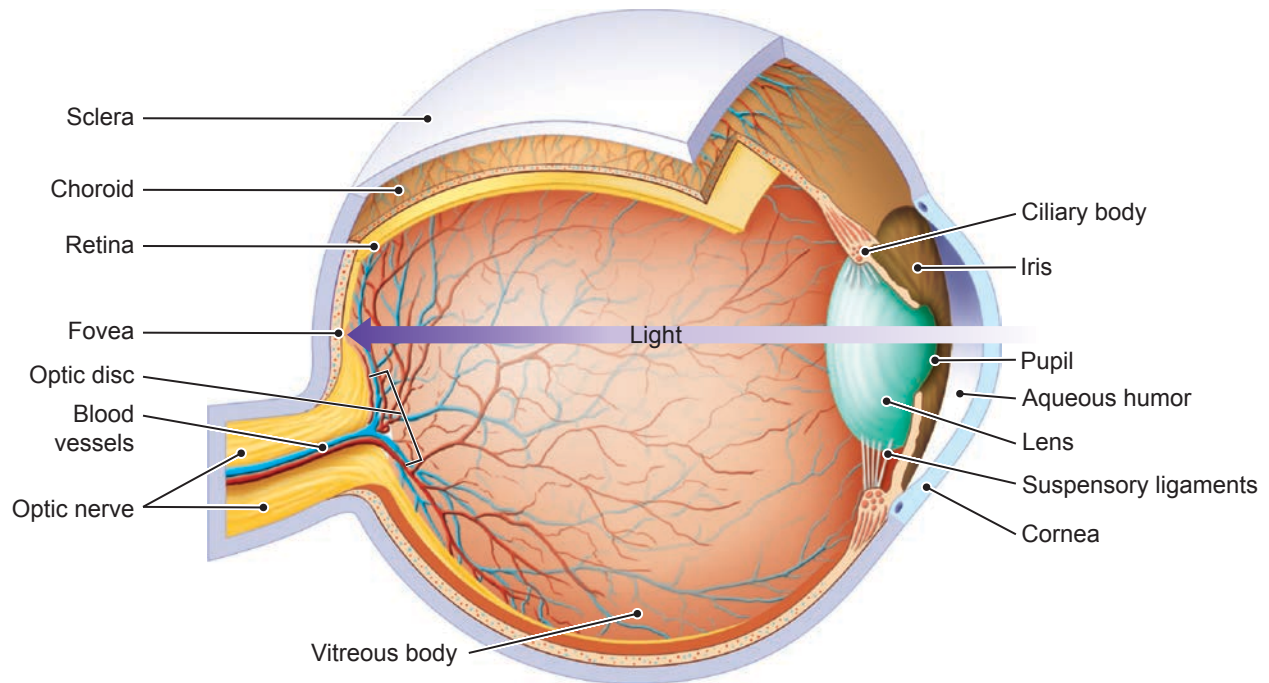
The wall of the eye is composed of three layers (**FIG. 8-7**). Named from outermost to innermost, they are as follows:

1. The **sclera**, commonly called the *white of the eye*, is the tough surface protective layer. The sclera extends over the eye's anterior portion as the transparent **cornea**.
2. The **uvea** is the middle layer, which consists of the:
  - **Choroid**, a vascular and pigmented layer located in the posterior portion of the eyeball. The choroid provides nourishment for the retina.



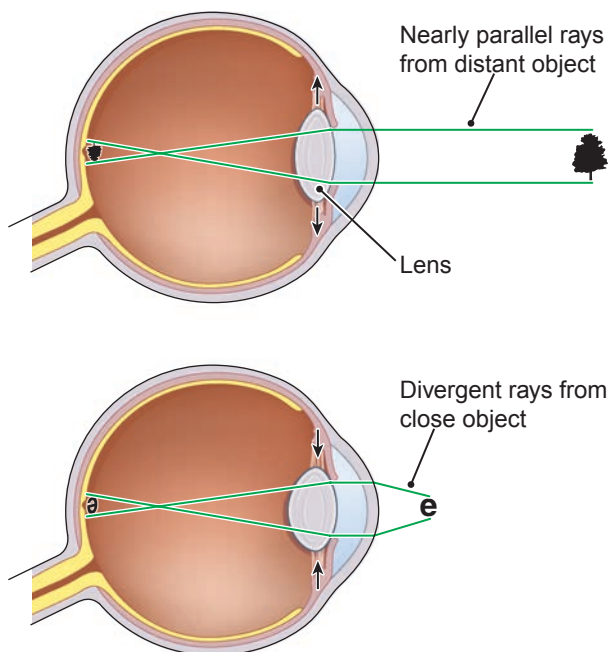
**FIGURE 8-6** The eye's protective structures. The lacrimal gland produces tears that flow across the eye and drain into the lacrimal canals.



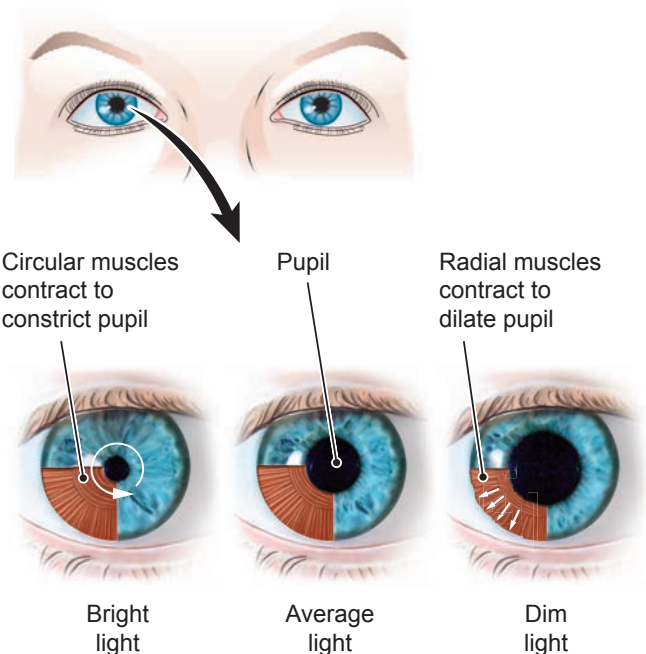


**FIGURE 8-7 The eye.** The three layers of the eyeball are shown along with other structures involved in vision.

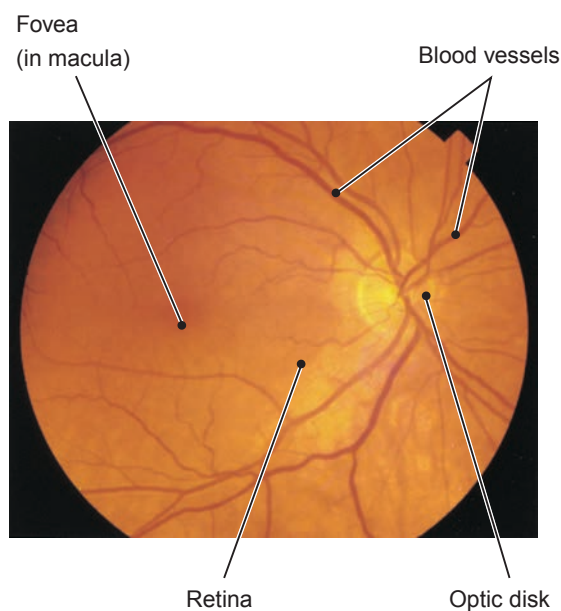
- **Ciliary body**, which contains a muscle that controls the shape of the **lens** to allow for near and far vision, a process known as **accommodation** (FIG. 8-8). The lens must become more rounded for viewing close objects.
  - **Iris**, a muscular ring that controls the size of the **pupil**, thus regulating the amount of light that enters the eye (FIG. 8-9). The genetically controlled pigments of the iris determine eye color.
3. The **retina** is the innermost layer and the actual visual receptor. It consists of two types of specialized cells that respond to light:
    - The **rods** function in dim light, provide low **visual acuity** (sharpness), and do not respond to color.
    - The **cones** are active in bright light, have high visual acuity, and respond to color.



**FIGURE 8-8 Accommodation for near vision.** When viewing a close object, the lens must become more rounded to focus light rays on the retina.



**FIGURE 8-9 Function of the iris.** In bright light, muscles in the iris constrict the pupil, limiting the light that enters the eye. In dim light, the iris dilates the pupil to allow more light to enter the eye.



**FIGURE 8-10** The fundus (back) of the eye as seen through an ophthalmoscope. The optic disk (blind spot) is shown as well as the fovea, the point of sharpest vision, in the retina.

Proper vision requires the **refraction** (bending) of light rays as they pass through the eye to focus on a specific point on the retina. The impulses generated within the rods and cones are transmitted to the brain by way of the optic nerve (second cranial nerve). Where the optic nerve connects to the retina, there are no rods or cones. This point, at which there is no visual perception, is called the **optic disk**, or *blind spot* (see FIG. 8-7). The **fovea** is a tiny depression in the retina near the optic nerve that has a high concentration of cones and is the point of greatest visual acuity. The fovea is surrounded by a yellowish spot called the **macula** (FIG. 8-10).

The eyeball is filled with a jelly-like **vitreous body** (see FIG. 8-7), which helps maintain the shape of the eye and also refracts light. The **aqueous humor** is the fluid that fills the eye anterior to the lens, maintaining the cornea's shape and refracting light. This fluid is constantly produced and drained from the eye.

Six muscles attached to the outside of each eye coordinate eye movements to achieve **convergence**, that is, coordinated movement of the eyes so that they both are fixed on the same point.

**BOX 8-2** explores the Greek origins of some medical words, including some pertaining to the eye.



## FOCUS ON WORDS

### The Greek Influence

BOX 8-2

Some of our most beautiful (and difficult to spell and pronounce) words come from Greek. *Esthesi/o* means “sensation.” It appears in the word *anesthesia*, a state in which there is lack of sensation, particularly pain. It is found in the word *esthetics* (also spelled *aesthetics*), which pertains to beauty, artistry, and appearance. The prefix *presby*, in the terms *presbycusis* and *presbyopia*, means “old,” and these conditions appear with aging. The root *cycl/o*, pertaining to the ring-like ciliary body of the eye, is from the Greek word for circle or wheel. The same root appears in the words *bicycle* and *tricycle*. Also pertaining to the eye, the term *iris* means “rainbow” in Greek, and the iris is the colored part of the eye.

The root *-sthen/o* means “strength” and occurs in the words *asthenia*, meaning lack of strength, or weakness, and *neurasthenia*, an old term for vague “nervous exhaustion” now applied to

conditions involving chronic symptoms of generalized fatigue, anxiety, and pain. The root also appears in the word *calisthenics* in combination with the root *cali-*, meaning “beauty.” So the rhythmic strengthening and conditioning exercises that are done in calisthenics literally give us beauty through strength.

The Greek root *steth/o* means “chest,” although a stethoscope is used to listen to sounds in other parts of the body as well as the chest.

*Asphyxia* is derived from the Greek root *sphygm/o* meaning “pulse.” The word is literally “stoppage of the pulse,” which is exactly what happens when one suffocates. This same root is found in *sphygmomanometer*, the apparatus used to measure blood pressure. One look at the word and one attempt to pronounce it makes it clear why most people call the device a blood pressure cuff!

## Terminology

## Key Terms

The terms listed below are emphasized in this chapter. Knowing them will help you organize and prioritize your learning. These boldface terms are also found, collectively, with all chapter key terms in the Glossary.

## The Eye

## Normal Structure and Function

<b>accommodation</b> <i>ah-kom-o-DA-shun</i>	Adjustment of the lens's curvature to allow for vision at various distances
<b>aqueous humor</b> <i>AK-we-us</i>	Fluid that fills the eye anterior to the lens
<b>choroid</b> <i>KOR-oyd</i>	The dark, vascular, middle layer of the eye (roots: chori/o, choroid/o); part of the uvea (see below)
<b>ciliary body</b> <i>SIL-e-ar-e</i>	The muscular portion of the uvea that surrounds the lens and adjusts its shape for near and far vision (root: cycl/o)
<b>cone</b>	A specialized cell in the retina that responds to light; cones have high visual acuity, function in bright light, and respond to colors
<b>conjunctiva</b> <i>kon-junk-TI-vah</i>	The mucous membrane that lines the eyelids and covers the eyeball's anterior surface
<b>convergence</b> <i>kon-VER-jens</i>	Coordinated movement of the eyes toward fixation on the same point
<b>cornea</b> <i>KOR-ne-ab</i>	The clear, anterior portion of the sclera (roots: corne/o, kerat/o)
<b>fovea</b> <i>FO-ve-ab</i>	The tiny depression in the retina that is the point of sharpest vision; fovea centralis, central fovea
<b>iris</b> <i>I-ris</i>	The muscular colored ring between the lens and the cornea; regulates the amount of light that enters the eye by altering the size of the pupil at its center (roots: ir, irid/o, irit/o) (plural: irides [ <i>IR-ih-deze</i> ])
<b>lacrimal gland</b> <i>LAK-rib-mal</i>	A gland above the eye that produces tears (roots: lacrim/o, dacry/o)
<b>lens</b> <i>lenz</i>	The transparent, biconvex structure in the anterior portion of the eye that refracts light and functions in accommodation (roots: lent/i, phak/o)
<b>macula</b> <i>MAK-u-lah</i>	A small spot or colored area; used alone to mean the yellowish spot in the retina that contains the fovea
<b>optic disk</b>	The point where the optic nerve joins the retina; at this point, there are no rods or cones; also called the blind spot or optic papilla
<b>orbit</b> <i>OR-bit</i>	The bony cavity that contains the eyeball
<b>palpebra</b> <i>PAL-peh-brah</i>	An eyelid; a protective fold (upper or lower) that closes over the anterior surface of the eye (roots: palpebr/o, blephar/o) (adjective: palpebral) (plural: palpebrae [ <i>pal-PE-bre</i> ])
<b>pupil</b> <i>PU-pil</i>	The opening at the center of the iris (root: pupil/o)
<b>refraction</b> <i>re-FRAK-shun</i>	The bending of light rays as they pass through the eye to focus on a specific point on the retina; also the determination and correction of ocular refractive errors
<b>retina</b> <i>RET-ih-nah</i>	The innermost, light-sensitive layer of the eye; contains the rods and cones, the specialized receptor cells for vision (root: retin/o)
<b>rod</b>	A specialized cell in the retina that responds to light; rods have low visual acuity, function in dim light, and do not respond to color

## Terminology

## Key Terms (Continued)

<b>sclera</b> <i>SKLE-rah</i>	The tough, white, fibrous outermost layer of the eye; the white of the eye (root: scler/o)
<b>uvea</b> <i>U-ve-ah</i>	The middle, vascular layer of the eye (root: uve/o); consists of the choroid, ciliary body, and iris
<b>visual acuity</b> <i>ah-KU-ih-te</i>	Sharpness of vision
<b>vitreous body</b> <i>VIT-re-us</i>	The transparent jelly-like mass that fills the eyeball's main cavity; also called vitreous humor

## Word Parts Pertaining to the Eye and Vision

See TABLES 8-3 to 8-5.

Table 8-3

## Roots for External Eye Structures

Root	Meaning	Example	Definition of Example
blephar/o	eyelid	symblepharon <i>sim-BLEF-ab-ron</i>	adhesion of the eyelid to the eyeball (sym- means "together")
palpebr/o	eyelid	palpebral <i>PAL-peb-bral</i>	pertaining to an eyelid
dacry/o	tear, lacrimal apparatus	dacryorrhea <i>dak-re-o-RE-ah</i>	discharge from the lacrimal apparatus
dacryocyst/o	lacrimal sac	dacryocystocele <i>dak-re-o-SIS-to-sele</i>	hernia of the lacrimal sac
lacrim/o	tear, lacrimal apparatus	lacrimation <i>lak-rih-MA-shun</i>	secretion of tears

## Exercise

## 8-3

Complete the exercise. To check your answers go to Appendix 11.

Define the following words.

- nasolacrimal (*na-zo-LAK-rih-mal*) \_\_\_\_\_
- interpalpebral (*in-ter-PAL-peb-bral*) \_\_\_\_\_
- blepharoplasty (*blef-ab-ro-PLAS-te*) \_\_\_\_\_
- dacryocystectomy (*dak-re-o-sis-TEK-to-me*) \_\_\_\_\_

Use the roots indicated to write words that mean the following.

- paralysis of the eyelid (blephar/o) \_\_\_\_\_
- stone in the lacrimal apparatus (dacry/o) \_\_\_\_\_
- inflammation of a lacrimal sac \_\_\_\_\_

Table 8-4

## Roots for the Eye and Vision

Root	Meaning	Example	Definition of Example
opt/o	eye, vision	optometer <i>op-TOM-eh-ter</i>	instrument for measuring the refractive power of the eye
ocul/o	eye	sinistroular <i>sih-nis-TROK-u-lar</i>	pertainig to the left eye
ophthalm/o	eye	exophthalmos <i>eks-of-THAL-mos</i>	protrusion of the eyeball
scler/o	sclera	episcleritis <i>ep-ih-skle-RI-tis</i>	inflammation of the tissue on the surface of the sclera
corne/o	cornea	circumcorneal <i>sir-kum-KOR-ne-al</i>	around the cornea
kerat/o	cornea	keratoplasty <i>KER-ab-to-plas-te</i>	plastic repair of the cornea; corneal transplant
lent/i	lens	lentiform <i>LEN-tib-form</i>	resembling a lens
phak/o, phac/o	lens	aphakia <i>ah-FA-ke-ah</i>	absence of a lens
uve/o	uvea	uveal <i>U-ve-al</i>	pertainig to the uvea
chori/o, choroid/o	choroid	subchoroidal <i>sub-kor-OYD-al</i>	below the choroid
cycl/o	ciliary body, ciliary muscle	cycloplegic <i>si-klo-PLE-jik</i>	pertainig to or causing paralysis of the ciliary muscle
ir, irit/o, irid/o	iris	iridoschisis <i>ir-ih-DOS-kih-sis</i>	splitting of the iris
pupill/o	pupil	iridopupillary <i>ir-ih-do-PU-pib-lar-e</i>	pertainig to the iris and the pupil
retin/o	retina	retinoscopy <i>ret-in-OS-ko-pe</i>	examination of the retina

## Exercise 8-4

Complete the exercise. To check your answers go to Appendix 11.

Fill in the blanks.

- In the opening case study, the medical specialist Kelly saw for her vision problems was a(n) \_\_\_\_\_.
- Lenticonus is conical protrusion of the \_\_\_\_\_.
- The oculomotor (*ok-u-lo-MO-tor*) nerve controls movements of the \_\_\_\_\_.
- The science of orthoptics (*or-THOP-tiks*) deals with correcting defects in \_\_\_\_\_.
- The term *phacolysis* (*fah-KOL-ih-sis*) means destruction of the \_\_\_\_\_.
- A keratometer (*ker-ab-TOM-eh-ter*) is an instrument for measuring the curves of the \_\_\_\_\_.

**Exercise 8-4 (Continued)**

Identify and define the roots pertaining to the eye in the following words.

	Root	Meaning of Root
7. optometrist ( <i>op-TOM-eb-trist</i> )	_____	_____
8. microphthalmos ( <i>mi-krof-THAL-mus</i> )	_____	_____
9. interpupillary ( <i>in-ter-PU-pih-ler-e</i> )	_____	_____
10. retrolental ( <i>ret-ro-LEN-tal</i> )	_____	_____
11. iridodilator ( <i>ir-id-o-DI-la-tor</i> )	_____	_____
12. uveitis ( <i>u-ve-I-tis</i> )	_____	_____
13. phacotoxic ( <i>fak-o-TOK-sik</i> )	_____	_____

Write words for the following definitions.

14. inflammation of the uvea and sclera	_____
15. hardening of the lens (use phac/o)	_____
16. pertaining to the cornea	_____
17. surgical fixation of the retina	_____
18. inflammation of the ciliary body	_____

Use the root *ophthalm/o* to write words for the following definitions.

19. an instrument used to examine the eye	_____
20. the medical specialty that deals with the eye and diseases of the eye	_____

Use the root *irid/o* to write words for the following definitions.

21. surgical removal of (part of) the iris	_____
22. paralysis of the iris	_____

Define the following words.

23. dextrocular ( <i>deks-TROK-u-lar</i> )	_____
24. lenticular ( <i>len-TIK-u-lar</i> )	_____
25. iridocyclitis ( <i>ir-ih-do-si-KLI-tis</i> )	_____
26. chorioretinal ( <i>kor-e-o-RET-ih-nal</i> )	_____
27. keratitis ( <i>ker-ab-TI-tis</i> )	_____
28. cyclotomy ( <i>si-KLOT-o-me</i> )	_____
29. optical ( <i>OP-tih-kal</i> )	_____
30. sclerotome ( <i>SKLERE-o-tome</i> )	_____
31. retinoschisis ( <i>ret-ih-NOS-kih-sis</i> )	_____

Table 8-5

Suffixes for the Eye and Vision<sup>a</sup>

Suffix	Meaning	Example	Definition of Example
-opsia	condition of vision	heteropsia <i>het-er-OP-se-ab</i>	unequal vision in the two eyes
-opia	condition of the eye, vision	hemianopia <i>hem-e-an-O-pe-ab</i>	blindness in half the visual field

<sup>a</sup>Compounds of -ops (eye) + -ia.

## Exercise 8-5

Complete the exercise. To check your answers go to Appendix 11.

Use the suffix *-opsia* to write words for the following definitions.

1. a visual defect in which objects seem larger (macr/o) than they are \_\_\_\_\_
2. lack of (a-) color (chromat/o) vision (complete color blindness) \_\_\_\_\_

Use the suffix *-opia* to write words for the following definitions.

3. double vision \_\_\_\_\_
4. changes in vision due to old age (use the prefix presby- meaning “old”) \_\_\_\_\_
5. In the opening case study, Kelly was diagnosed with “lazy eye,” technically known as \_\_\_\_\_

The suffix *-opia* is added to the root *metr/o* (measure) to form words pertaining to the refractive power of the eye. Add a prefix to *-metropia* to form words for the following.

6. a lack of refractive power in the eye \_\_\_\_\_
7. unequal refractive powers in the two eyes \_\_\_\_\_

## Clinical Aspects of Vision

### ERRORS OF REFRACTION

If the eyeball is too long, images will form in front of the retina. To focus clearly, one must bring an object closer to the eye. This condition of *nearsightedness* is technically called **myopia** (FIG. 8-11). The opposite condition is **hyperopia**, or *farsightedness*, in which the eyeball is too short and images form behind the retina. One must move an object away from the eye for clear focus. The same effect is produced by **presbyopia**, which accompanies aging. The lens loses elasticity and can no longer accommodate for near vision, so a person gradually becomes farsighted.

**Astigmatism** is an irregularity in the curve of the cornea or lens that distorts light entering the eye and blurs vision.

Glasses can compensate for most of these refractive impairments, as shown for nearsightedness and farsightedness in FIGURE 8-11. See also BOX 8-3 for information on a surgical technique to correct refractive errors.

### INFECTION

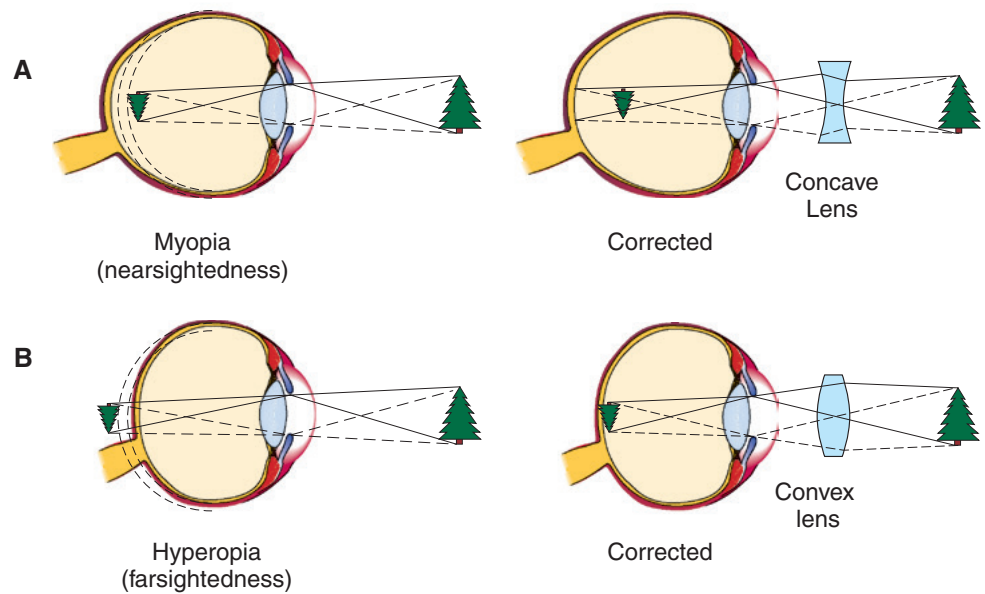
Several microorganisms can cause **conjunctivitis** (inflammation of the conjunctiva). This is a highly infectious disease commonly called “pink eye.”

The bacterium *Chlamydia trachomatis* causes **trachoma**, inflammation of the cornea and conjunctiva that results in scarring. This disease is rare in the United States and other industrialized countries but is a common cause of blindness in underdeveloped countries, although it is easily cured with sulfa drugs and antibiotics.

Gonorrhea is the usual cause of an acute conjunctivitis in newborns called **ophthalmia neonatorum**. An antibiotic ointment is routinely used to prevent such eye infections in newborns.

### DISORDERS OF THE RETINA

In cases of **retinal detachment**, the retina separates from the underlying choroid layer of the eye as a result of trauma or an accumulation of fluid or tissue between the layers (FIG. 8-12). This disorder may develop slowly or may occur suddenly. If it is left untreated, complete detachment can occur, resulting in blindness. Treatment includes use of an electric current or weak laser beam to create pinpoint scars that reattach the retina. Posterior detachment of the vitreous body, as may occur in middle age and beyond, can



**FIGURE 8-11** Errors of refraction. **A.** Myopia (nearsightedness). **B.** Hyperopia (farsightedness). A concave (inwardly curved) lens corrects for myopia; a convex (outwardly curved) lens corrects for hyperopia.



## CLINICAL PERSPECTIVES

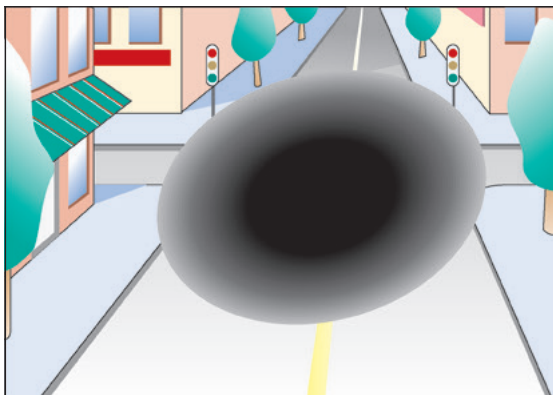
### Eye Surgery: A Glimpse of the Cutting Edge

BOX 8-3

Cataracts, glaucoma, and refractive errors are common eye disorders. In the past, cataract and glaucoma treatments concentrated on managing the diseases. Refractive errors were corrected using eyeglasses and, more recently, contact lenses. Today, using laser and microsurgical techniques, ophthalmologists can remove cataracts, reduce glaucoma, and allow people with refractive errors to put their eyeglasses and contacts away. These cutting-edge procedures include:

- LASIK (laser in situ keratomileusis) to correct refractive errors. During this procedure, a surgeon uses a laser to reshape the cornea so that it refracts light directly onto the retina, rather than in front of or behind it. A microkeratome (surgical knife) is used to cut a flap in the cornea's outer layer. A computer-controlled laser sculpts the middle layer of the cornea and then the flap is replaced. The procedure takes only a few minutes, and patients recover their vision quickly and usually with little postoperative pain.

- Phacoemulsification to remove cataracts. During this procedure, a surgeon makes a very small incision (~3 mm long) through the sclera near the cornea's outer edge. An ultrasonic probe is inserted through this opening and into the center of the lens. The probe uses sound waves to emulsify the lens's central core, which is then suctioned out. An artificial lens is then permanently implanted in the lens capsule (see FIG. 8-14). The procedure is typically painless, although the patient may feel some discomfort for one to two days afterward.
- Laser trabeculoplasty to treat glaucoma. This procedure uses a laser to help drain fluid from the eye and lower intraocular pressure. The laser is aimed at drainage canals located between the cornea and iris and makes several burns that are believed to open the canals and allow better fluid drainage. The procedure is typically painless and takes only a few minutes.



**FIGURE 8-12** Retinal detachment.

also pull the retina away. Danger signs include light flashes with eye movement, floater showers, or the appearance of a “black curtain” over part of the visual field. If any of these symptoms appear, a person should consult an ophthalmologist immediately.

Degeneration of the macula, the point of sharpest vision, is a common cause of visual problems in the elderly. When associated with aging, this deterioration is described as **age-related macular degeneration (AMD)**. In nonexudative (“dry”) macular degeneration, material accumulates on the retina. Vitamins C and E, beta carotene, and zinc supplements may delay this process. In neovascular (“wet”) AMD, abnormal blood vessels grow under the retina, causing it to detach. Laser surgery may stop the growth of these





**FIGURE 8-13** A–D. Visual disorders.

vessels and delay vision loss. More recently, ophthalmologists have had success in delaying the progress of wet AMD with regular intraocular injections of a drug (e.g., Lucentis) that inhibits blood vessel formation. Macular degeneration typically affects central vision but not peripheral vision (FIG. 8-13B). Other causes of macular degeneration are drug toxicity and hereditary diseases.

Circulatory problems associated with diabetes mellitus eventually cause changes in the retina referred to as **diabetic retinopathy**. In addition to vascular damage, there is a yellowish, waxy exudate high in lipoproteins. With time, new blood vessels form and penetrate the vitreous humor, causing hemorrhage, detachment of the retina, and blindness. The visual effects of diabetic retinopathy can be seen in FIGURE 8-13C.

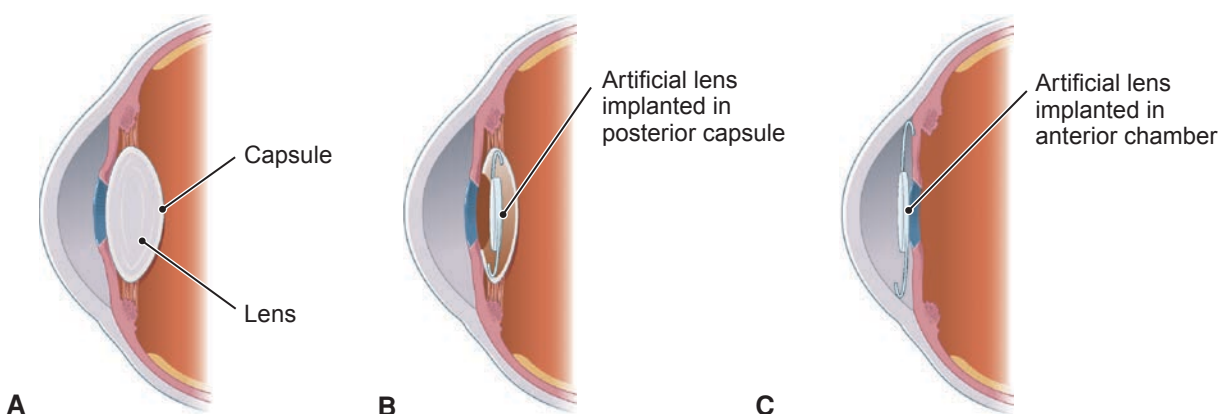
## CATARACT

A **cataract** is an opacity (cloudiness) of the lens that blurs vision (see FIG. 8-13D). Causes of cataract include disease, injury, chemicals, and exposure to physical forces, especially the ultraviolet radiation in sunlight. The cataracts that frequently appear with age may result from exposure to environmental factors in combination with degeneration attributable to aging.

To prevent blindness, an ophthalmologist must remove the cloudy lens surgically. Commonly, the lens's anterior capsule is removed along with the cataract, leaving the posterior capsule in place (FIG. 8-14). In **phacoemulsification**, the lens is fragmented with high-frequency ultrasound and extracted through a small incision (see BOX 8-3). After cataract removal, an artificial intraocular lens (IOL) is usually implanted to compensate for the missing lens. The original type of implant provides vision only within a fixed distance; newer implants are designed to allow for near and far accommodation. Alternatively, a person can wear a contact lens or special glasses.

## GLAUCOMA

**Glaucoma** is an abnormal increase in pressure within the eyeball. It occurs when more aqueous humor is produced than can be drained away from the eye. There is pressure on blood vessels in the eye and on the optic nerve, leading to blindness. There are many causes of glaucoma, and screening for this disorder should be a part of every routine eye examination. Fetal infection with rubella (German measles) early in pregnancy can cause glaucoma, as well as cataracts and hearing impairment. Glaucoma is usually treated with medication to reduce pressure in the eye and occasionally is treated with surgery (see BOX 8-3).



**FIGURE 8-14** Cataract extraction surgeries. **A.** Cross-section of normal eye anatomy. **B.** Extracapsular lens extraction involves removing the lens but leaving the posterior capsule intact to receive a synthetic intraocular lens. **C.** Intracapsular lens extraction involves removing the lens and lens capsule and implanting a synthetic intraocular lens in the anterior chamber.

## Terminology

## Key Terms

The terms listed below are emphasized in this chapter. Knowing them will help you organize and prioritize your learning. These boldface terms are also found, collectively, with all chapter key terms in the Glossary.

### The Eye

#### Disorders

<b>age-related macular degeneration (AMD)</b> <i>MAK-u-lar de-jen-er-A-shun</i>	Deterioration of the macula associated with aging; macular degeneration impairs central vision
<b>astigmatism</b> <i>ab-STIG-mah-tizm</i>	An error of refraction caused by irregularity in the curvature of the cornea or lens
<b>cataract</b> <i>KAT-ab-rakt</i>	Opacity of the lens of the eye
<b>conjunctivitis</b> <i>kon-junk-tih-VI-tis</i>	Inflammation of the conjunctiva; pink eye
<b>diabetic retinopathy</b> <i>ret-ih-NOP-ab-the</i>	Degenerative changes in the retina associated with diabetes mellitus
<b>glaucoma</b> <i>glaw-KO-mah</i>	An eye disease caused by increased intraocular pressure that damages the optic disk and causes vision loss; usually results from faulty fluid drainage from the anterior eye
<b>hyperopia</b> <i>hi-per-O-pe-ab</i>	A refractive error in which light rays focus behind the retina and objects can be seen clearly only when far from the eye; farsightedness; also called hypermetropia
<b>myopia</b> <i>mi-O-pe-ab</i>	A refractive error in which light rays focus in front of the retina and objects can be seen clearly only when very close to the eye; nearsightedness
<b>ophthalmia neonatorum</b> <i>of-THAL-me-ab ne-o-na-TOR-um</i>	Severe conjunctivitis usually caused by infection with gonococcus during birth
<b>phacoemulsification</b> <i>fak-o-e-MUL-sih-fih-ka-shun</i>	Removal of a cataract by ultrasonic destruction and extraction of the lens
<b>presbyopia</b> <i>prez-be-O-pe-ab</i>	Changes in the eye that occur with age; the lens loses elasticity and the ability to accommodate for near vision
<b>retinal detachment</b>	Separation of the retina from its underlying layer
<b>trachoma</b> <i>trah-KO-mah</i>	An infection caused by <i>Chlamydia trachomatis</i> leading to inflammation and scarring of the cornea and conjunctiva; a common cause of blindness in underdeveloped countries

## Terminology

## Enrichment Terms

The terms listed below expand on the key terms to increase your knowledge of this chapter topic.

### The Eye

#### Normal Structure and Function

<b>canthus</b> <i>KAN-thus</i>	The angle at either end of the slit between the eyelids
<b>diopter</b> <i>DI-op-ter</i>	A measurement unit for the refractive power of a lens
<b>emmetropia</b> <i>em-eh-TRO-pe-ab</i>	The normal condition of the eye in refraction, in which parallel light rays focus exactly on the retina
<b>fundus</b> <i>FUN-dus</i>	A bottom or base; the region farthest from the opening of a structure; the eye's fundus is the posterior portion of the interior eyeball as seen with an ophthalmoscope
<b>meibomian gland</b> <i>mi-BO-me-an</i>	A sebaceous gland in the eyelid
<b>tarsus</b> <i>TAR-sus</i>	The framework of dense connective tissue that gives shape to the eyelid; tarsal plate
<b>zonule</b> <i>ZONE-ule</i>	A system of fibers that holds the lens in place; also called suspensory ligaments

#### Symptoms and Conditions

<b>amblyopia</b> <i>am-ble-O-pe-ab</i>	A condition that occurs when visual acuity is not the same in the two eyes in children (prefix ambly means “dim”); disuse of the poorer eye will result in blindness if not corrected; also called “lazy eye”; see Kelly’s opening case study on amblyopia
<b>anisocoria</b> <i>an-i-so-KO-re-ab</i>	Condition in which the two pupils (root: cor/o) are not of equal size
<b>blepharoptosis</b> <i>blef-ab-rop-TO-sis</i>	Drooping of the eyelid (see <b>FIG. 3-5</b> )
<b>chalazion</b> <i>kah-LA-ze-on</i>	A small mass on the eyelid resulting from inflammation and blockage of a meibomian gland
<b>drusen</b> <i>DRU-zen</i>	Small growths that appear as tiny yellowish spots beneath the retina of the eye; typically occur with age but also occur in certain abnormal conditions
<b>floater</b> <i>FLO-ter</i>	A small moving object in the field of vision that originates in the vitreous body; floaters appear as spots or threads and are caused by benign degenerative or embryonic deposits in the vitreous body that cast a shadow on the retina
<b>hordeolum</b> <i>hor-DE-o-lum</i>	Inflammation of a sebaceous gland of the eyelid; a sty
<b>keratoconus</b> <i>ker-ab-to-KO-nus</i>	Conical protrusion of the corneal center
<b>miosis</b> <i>mi-O-sis</i>	Abnormal contraction of the pupils (from Greek <i>meiosis</i> meaning “diminution”)
<b>mydriasis</b> <i>mih-DRI-ab-sis</i>	Pronounced or abnormal dilation of the pupil
<b>nyctalopia</b> <i>nik-tah-LO-pe-ab</i>	Night blindness; inability to see well in dim light or at night (root: nyct/o); often due to lack of vitamin A, which is used to make the pigment needed for vision in dim light
<b>nystagmus</b> <i>nis-TAG-mus</i>	Rapid, involuntary, rhythmic movements of the eyeball; may occur in neurologic diseases or disorders of the inner ear’s vestibular apparatus
<b>papilledema</b> <i>pap-il-eh-DE-mah</i>	Swelling of the optic disk (papilla); choked disk
<b>phlyctenule</b> <i>FLIK-ten-ule</i>	A small blister or nodule on the cornea or conjunctiva

## Terminology

## Enrichment Terms (Continued)

<b>pseudophakia</b> <i>su-do-FA-ke-ab</i>	A condition in which a cataractous lens has been removed and replaced with a plastic lens implant
<b>retinitis</b> <i>ret-in-I-tis</i>	Inflammation of the retina; causes include systemic disease, infection, hemorrhage, exposure to light
<b>retinitis pigmentosa</b> <i>ret-in-I-tis pig-men-TO-sah</i>	A hereditary chronic degenerative disease of the retina that begins in early childhood; there is atrophy of the optic nerve and clumping of pigment in the retina
<b>retinoblastoma</b> <i>ret-in-o-blas-TO-mah</i>	A malignant glioma of the retina; usually appears in early childhood and is sometimes hereditary; fatal if untreated, but current cure rates are high
<b>scotoma</b> <i>sko-TO-mah</i>	An area of diminished vision within the visual field
<b>strabismus</b> <i>strah-BIZ-mus</i>	A deviation of the eye in which the visual lines of each eye are not directed to the same object at the same time; also called heterotropia or squint; the various forms are referred to as -tropias, with the direction of turning (trop/o) indicated by a prefix, such as esotropia (inward), exotropia (outward), hypertropia (upward), and hypotropia (downward); the suffix -phoria is also used, as in esophoria.
<b>synechia</b> <i>sin-EK-e-ab</i>	Adhesion of parts, especially adhesion of the iris to the lens and cornea (plural: synechiae)
<b>xanthoma</b> <i>zan-THO-mah</i>	A soft, slightly raised, yellowish patch or nodule usually on the eyelids; occurs in the elderly; also called xanthelasma
<b>Diagnosis and Treatment</b>	
<b>canthotomy</b> <i>kan-THOT-o-me</i>	Surgical division of a canthus
<b>cystotome</b> <i>SIS-tih-tome</i>	Instrument for incising the lens capsule
<b>electroretinography (ERG)</b> <i>e-lek-tro-ret-ih-NOG-rah-fe</i>	Study of the retina's electrical response to light stimulation
<b>enucleation</b> <i>e-nu-kle-A-shun</i>	Surgical removal of the eyeball
<b>gonioscopy</b> <i>go-ne-OS-ko-pe</i>	Examination of the angle between the cornea and the iris (anterior chamber angle) in which fluids drain out of the eye (root <i>goni/o</i> means "angle")
<b>keratometer</b> <i>ker-ab-TOM-eh-ter</i>	An instrument for measuring the curvature of the cornea
<b>mydriatic</b> <i>mid-re-AT-ik</i>	A drug that causes dilation of the pupil
<b>phorometer</b> <i>fo-ROM-eh-ter</i>	An instrument for determining the degree and kind of strabismus
<b>retinoscope</b> <i>RET-in-o-skope</i>	An instrument used to determine refractive errors of the eye; also called a skiascope ( <i>SKI-ab-skope</i> )
<b>slit-lamp biomicroscope</b>	An instrument for examining the eye under magnification
<b>Snellen chart</b> <i>SNEL-en</i>	A chart printed with letters of decreasing size used to test visual acuity when viewed from a set distance; results reported as a fraction giving a subject's vision compared with normal vision at a distance of 20 ft
<b>tarsorrhaphy</b> <i>tar-SOR-ab-fe</i>	Suturing together of all or part of the upper and lower eyelids
<b>tonometer</b> <i>to-NOM-eh-ter</i>	An instrument used to measure fluid pressure in the eye

## Terminology *Abbreviations*

The abbreviations listed below are emphasized in this chapter. These are also found, collectively, with all chapter abbreviations in Appendix 2.

### The Eye

<b>A, Acc</b>	Accommodation	<b>HM</b>	Hand movements
<b>AMD</b>	Age-related macular degeneration	<b>IOL</b>	Intraocular lens
<b>ARC</b>	Abnormal retinal correspondence	<b>IOP</b>	Intraocular pressure
<b>As, AST</b>	Astigmatism	<b>NRC</b>	Normal retinal correspondence
<b>cc</b>	With correction	<b>NV</b>	Near vision
<b>Em</b>	Emmetropia	<b>sc</b>	Without correction
<b>EOM</b>	Extraocular movement, muscles	<b>VA</b>	Visual acuity
<b>ERG</b>	Electroretinography	<b>VF</b>	Visual field
<b>ET</b>	Esotropia	<b>XT</b>	Exotropia
<b>FC</b>	Finger counting		

### Case Study Revisited

#### Kelly's Follow-Up

Kelly started wearing the patch on her right eye during waking hours. She progressed to wearing it 4 to 5 hours a day as ordered by the ophthalmologist. The glasses she obtained from the optician were helping her to focus, and she was able to read her schoolwork. Kelly's mother made sure the glasses were fun and attractive for Kelly to wear and found some colorful patches that helped Kelly accept wearing a patch to school. She also met with the school counselor and Kelly's teacher to explain why her daughter had been falling behind

in her schoolwork and had some self-image issues. The counselor said she would come up with ideas to involve Kelly in fun school activities with her classmates. And, the teacher said she would help guide Kelly through her schoolwork while her vision was being corrected.

A month later Kelly had an appointment with her ophthalmologist. The physician said she had adjusted well to the treatment plan and showed improved vision. Kelly's schoolwork also improved and she had made new friends.

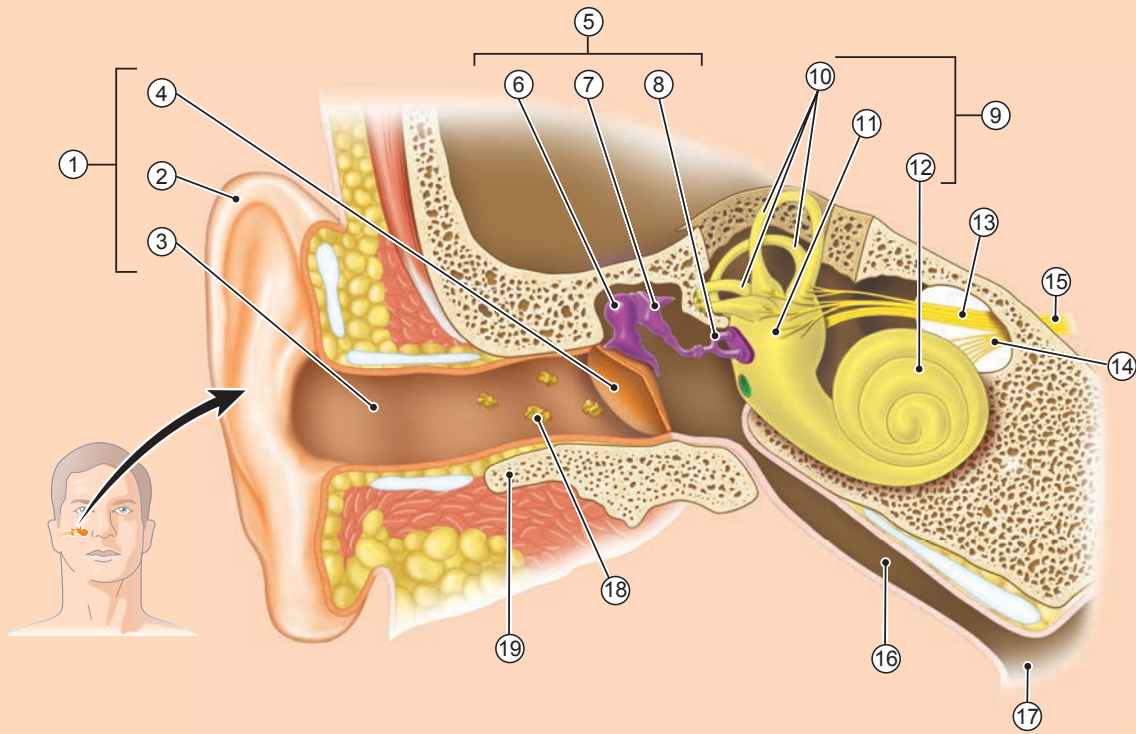


This review tests your understanding of the content introduced in this chapter. Follow the instructions for each exercise and check your answers in Appendix 11.

**LABELING EXERCISE**

**THE EAR**

Write the name of each numbered part on the corresponding line.



Auditory tube  
Cerumen  
Cochlea  
Cochlear nerve  
External auditory canal

Incus  
Inner ear  
Malleus  
Middle ear  
Outer ear

Pharynx  
Pinna  
Semicircular canals  
Temporal bone  
Tympanic membrane

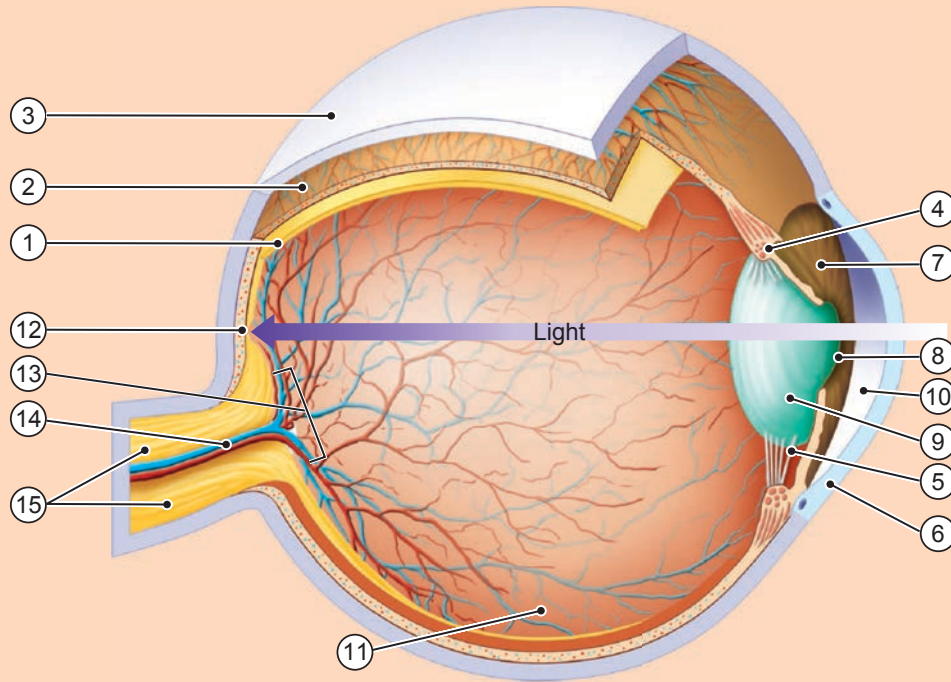
Stapes  
Vestibular nerve  
Vestibulocochlear nerve (VIII)  
Vestibule

- 1. \_\_\_\_\_
- 2. \_\_\_\_\_
- 3. \_\_\_\_\_
- 4. \_\_\_\_\_
- 5. \_\_\_\_\_
- 6. \_\_\_\_\_
- 7. \_\_\_\_\_
- 8. \_\_\_\_\_
- 9. \_\_\_\_\_
- 10. \_\_\_\_\_

- 11. \_\_\_\_\_
- 12. \_\_\_\_\_
- 13. \_\_\_\_\_
- 14. \_\_\_\_\_
- 15. \_\_\_\_\_
- 16. \_\_\_\_\_
- 17. \_\_\_\_\_
- 18. \_\_\_\_\_
- 19. \_\_\_\_\_

THE EYE

Write the name of each numbered part on the corresponding line.



Aqueous humor  
 Blood vessels  
 Choroid  
 Ciliary body  
 Cornea  
 Fovea  
 Iris  
 Lens

Optic disk  
 Optic nerve  
 Pupil  
 Retina  
 Sclera  
 Suspensory ligaments  
 Vitreous body

- 1. \_\_\_\_\_
- 2. \_\_\_\_\_
- 3. \_\_\_\_\_
- 4. \_\_\_\_\_
- 5. \_\_\_\_\_
- 6. \_\_\_\_\_
- 7. \_\_\_\_\_
- 8. \_\_\_\_\_

- 9. \_\_\_\_\_
- 10. \_\_\_\_\_
- 11. \_\_\_\_\_
- 12. \_\_\_\_\_
- 13. \_\_\_\_\_
- 14. \_\_\_\_\_
- 15. \_\_\_\_\_

## TERMINOLOGY

### MATCHING

Match the following terms, and write the appropriate letter to the left of each number.

- |                             |   |
|-----------------------------|---|
| ___ 1. palpebra             | a. small bone   |
| ___ 2. ossicle              | b. structure that changes shape for near and far vision |
| ___ 3. rods and cones       | c. an eyelid  |
| ___ 4. vestibular apparatus | d. location of equilibrium receptors                    |
| ___ 5. lens                 | e. vision receptors                                     |
| ___ 6. tactile              | a. increased sensation                                  |
| ___ 7. tinnitus             | b. blindness in half the visual field                   |
| ___ 8. hyperesthesia        | c. point of sharpest vision                             |
| ___ 9. fovea                | d. pertaining to touch                                  |
| ___ 10. hemianopia          | e. sensation of noises in the ear                       |
| ___ 11. anacusis            | a. corneal transplant                                   |
| ___ 12. ophthalmoplegia     | b. abnormal smell perception                            |
| ___ 13. phacomalacia        | c. paralysis of an eye muscle                           |
| ___ 14. parosmia            | d. softening of the lens                                |
| ___ 15. keratoplasty        | e. total loss of hearing                                |

### Enrichment Terms

- |                         |  |
|-------------------------|--|
| ___ 16. diopter         | a. angle between the eyelids                           |
| ___ 17. mastoid process | b. small muscle attached to an ear ossicle             |
| ___ 18. stapedius       | c. projection of the temporal bone                     |
| ___ 19. canthus         | d. unit of sound intensity                             |
| ___ 20. decibel         | e. unit for measuring the refractive power of the lens |
| ___ 21. emmetropia      | a. abnormal dilation of the pupil                      |
| ___ 22. nystagmus       | b. small growths beneath the retina                    |
| ___ 23. mydriasis       | c. rapid, involuntary eye movements                    |
| ___ 24. drusen          | d. normal refraction of the eye                        |
| ___ 25. amblyopia       | e. commonly called “lazy eye”                          |
| ___ 26. AMD             | a. irregularity in the curve of the eye                |
| ___ 27. Hz              | b. an implanted lens                                   |
| ___ 28. AST             | c. otorhinolaryngology                                 |
| ___ 29. ENT             | d. eye disorder associated with aging                  |
| ___ 30. IOL             | e. a unit for measuring pitch of sound                 |



**FILL IN THE BLANKS**

*Complete the sentence with the correct term(s).*

31. The scientific name for the eardrum is \_\_\_\_\_.
32. The type of hearing loss resulting from damage to the eighth cranial nerve is described as \_\_\_\_\_.
33. The ossicle that is in contact with the inner ear is the \_\_\_\_\_.
34. The outermost layer of the eye wall is the \_\_\_\_\_.
35. The bending of light rays as they pass through the eye is \_\_\_\_\_.
36. The innermost layer of the eye that contains the receptors for vision is the \_\_\_\_\_.
37. The transparent extension of the sclera that covers the front of the eye is the \_\_\_\_\_.
38. The sense of awareness of body position is \_\_\_\_\_.

**DEFINITIONS**

*Define the following words.*

39. audiologist (*aw-de-OL-o-jist*) \_\_\_\_\_
40. ophthalmometer (*of-thal-MOM-eh-ter*) \_\_\_\_\_
41. aphakia (*ah-FA-ke-ah*) \_\_\_\_\_
42. subscleral (*sub-skle-ral*) \_\_\_\_\_
43. iridotomy (*ir-ih-DOT-o-me*) \_\_\_\_\_
44. myringoscope (*mih-RING-go-skope*) \_\_\_\_\_
45. peridental (*per-e-LEN-til*) \_\_\_\_\_
46. dacryorrhea (*dak-re-o-RE-ah*) \_\_\_\_\_
47. presbycusis (*pres-be-KU-sis*) \_\_\_\_\_
48. keratoiritis (*ker-ah-to-i-RI-tis*) \_\_\_\_\_

*Write words for the following definitions.*

49. softening of the lens \_\_\_\_\_
50. measurement of the pupil \_\_\_\_\_
51. surgical removal of the stapes \_\_\_\_\_
52. drooping of the eyelid \_\_\_\_\_
53. plastic repair of the ear \_\_\_\_\_
54. pertaining to the vestibular apparatus and cochlea \_\_\_\_\_
55. any disease of the retina \_\_\_\_\_
56. absence of pain \_\_\_\_\_
57. pertaining to tears \_\_\_\_\_
58. excision of (part of) the ciliary body \_\_\_\_\_
59. endoscopic examination of the auditory tube \_\_\_\_\_
60. technical name for farsightedness \_\_\_\_\_

**ADJECTIVES**

Write the adjective form of the following words.

61. cochlea \_\_\_\_\_

62. palpebra \_\_\_\_\_

63. choroid \_\_\_\_\_

64. uvea \_\_\_\_\_

65. cornea \_\_\_\_\_

66. sclera \_\_\_\_\_

67. pupil \_\_\_\_\_

**OPPOSITES**

Write words that mean the opposite of the following.

68. hyperesthesia \_\_\_\_\_

69. hypalgesia \_\_\_\_\_

70. cc \_\_\_\_\_

71. hyperopia \_\_\_\_\_

72. mydriasis \_\_\_\_\_

73. esotropia \_\_\_\_\_

**WORD BUILDING**

Write words for the following definitions using the word parts provided. Each word part can be used more than once.

-pexy -ia osm/o kerat/o -al -schisis -scopy pseud/o- retin/o an- -plasty salping/o sub -myring/o

74. false sense of smell \_\_\_\_\_

75. plastic repair of the tympanic membrane \_\_\_\_\_

76. examination of the retina \_\_\_\_\_

77. examination of the auditory tube \_\_\_\_\_

78. absence of the sense of smell \_\_\_\_\_

79. splitting of the retina \_\_\_\_\_

80. examination of the tympanic membrane \_\_\_\_\_

81. beneath the retina \_\_\_\_\_

82. surgical fixation of the retina \_\_\_\_\_

83. examination of the cornea \_\_\_\_\_

**TRUE-FALSE**

Examine the following statements. If the statement is true, write T in the first blank. If the statement is false, write F in the first blank, and correct the statement by replacing the underlined word in the second blank.

	True or False	Correct Answer
84. The spiral organ is located in the <u>vestibule</u> of the inner ear.	_____	_____
85. An osmoceptor is a receptor for the sense of <u>smell</u> .	_____	_____
86. The malleus is located in the <u>middle ear</u> .	_____	_____
87. Gustation is the sense of <u>taste</u> .	_____	_____
88. Hypergeusia is an abnormal increase in the sense of <u>touch</u> .	_____	_____
89. In bright light the pupils <u>dilate</u> .	_____	_____
90. A myringotomy is incision of the <u>stapes</u> .	_____	_____
91. The lacrimal gland produces <u>aqueous humor</u> .	_____	_____

**ELIMINATION**

In each of the sets below, underline the word that does not fit in with the rest, and explain the reason for your choice.

92. pressure — temperature — smell — touch — pain

\_\_\_\_\_

93. cochlea — pinna — vestibule — oval window — semicircular canals

\_\_\_\_\_

94. incus — lacrimal gland — eyelash — conjunctiva — palpebra

\_\_\_\_\_

95. glaucoma — myopia — cataract — macular degeneration — presbycusis

\_\_\_\_\_

**WORD ANALYSIS**

Define the following words, and give the meaning of the word parts in each. Use a dictionary if necessary.

96. asthenopia (*as-the-NO-pe-ah*)

a. a- \_\_\_\_\_

b. sthen/o \_\_\_\_\_

c. -op(s) \_\_\_\_\_

d. -ia \_\_\_\_\_

97. pseudophakia (*su-do-FA-ke-ah*)

a. pseudo \_\_\_\_\_

b. phak/o \_\_\_\_\_

c. -ia \_\_\_\_\_

98. cholesteatoma (*ko-les-te-ah-TO-mah*)

a. chol/e \_\_\_\_\_

b. steat/o \_\_\_\_\_

c. -oma \_\_\_\_\_

99. exotropia (*ek-so-TRO-pe-ah*)

a. ex/o- \_\_\_\_\_

b. trop/o \_\_\_\_\_

c. -ia \_\_\_\_\_

100. anisometropia (*an-i-so-meh-TRO-pe-ah*)

a. an- \_\_\_\_\_

b. iso- \_\_\_\_\_

c. metr/o \_\_\_\_\_

d. op(s) \_\_\_\_\_

e. -ia \_\_\_\_\_

# Additional Case Studies

## Case Study 8-1: Audiology Report

George, a 55 y/o man, reported decreased hearing sensitivity in his left ear for the past 3 years. In addition to hearing loss, he was experiencing tinnitus and aural fullness. Pure-tone test results revealed normal hearing sensitivity for the right ear and a moderate sensorineural hearing loss in the left ear. Speech thresholds were appropriate for the degree of hearing loss noted. Word recognition was excellent for the right ear and poor for the left ear when the signal was present at a suprathreshold level. Tympanograms were characterized by normal shape, amplitude,

and peak pressure points bilaterally. The contralateral acoustic reflex was normal for the right ear but absent for the left ear at the frequencies tested (500 to 4,000 Hz). The ipsilateral acoustic reflex was present with the probe in the right ear and absent with the probe in the left ear. Brainstem auditory evoked potentials (BAEPs) were within normal range for the right ear. No repeatable response was observed from the left ear. A subsequent MRI showed a 1-cm acoustic neuroma.

### Case Study 8-1 Questions

Follow the instructions for each question and check your answers in Appendix 11.

**Multiple Choice.** Select the best answer, and write the letter of your choice to the left of each number.

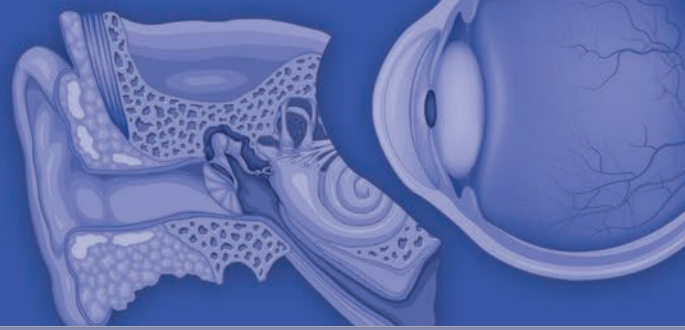
- |   |   |
|---|---|
| <p>_____ 1. The study of hearing is termed</p> <ul style="list-style-type: none"><li>a. acousticology</li><li>b. radio frequency</li><li>c. audiology</li><li>d. otology</li></ul> <p>_____ 2. Sensorineural hearing loss may result from</p> <ul style="list-style-type: none"><li>a. damage to the second cranial nerve</li><li>b. damage to the eighth cranial nerve</li><li>c. otosclerosis</li><li>d. otitis media</li></ul> | <p>_____ 3. The term that means “on the same side” is</p> <ul style="list-style-type: none"><li>a. contralateral</li><li>b. bilateral</li><li>c. distal</li><li>d. ipsilateral</li></ul> <p>_____ 4. Another name for an acoustic neuroma is</p> <ul style="list-style-type: none"><li>a. macular degeneration</li><li>b. acoustic neurilemmoma</li><li>c. auditory otosclerosis</li><li>d. acoustic glaucoma</li></ul> |
|---|---|

Write terms from the case study with the following meanings.

- 5. above a minimum level \_\_\_\_\_
- 6. pertaining to or perceived by the ear \_\_\_\_\_
- 7. record obtained by tympanometry \_\_\_\_\_
- 8. pertaining to sound or hearing \_\_\_\_\_
- 9. perception of sounds, such as ringing or tinkling in the ear \_\_\_\_\_

Define the following abbreviations.

- 10. Hz \_\_\_\_\_
- 11. BAEP \_\_\_\_\_



## Case Study 8-2: Phacoemulsification With Intraocular Lens Implant

Ginny, a 68 y/o, was scheduled for surgery for a cataract and relief from “floaters,” which she had noticed in her visual field since her surgery for a retinal detachment the previous year. She reported to the ambulatory surgery center an hour before her scheduled procedure. Before transfer to the operating room, she spoke with her ophthalmologist, who reviewed the surgical plan. Her right eye was identified as the operative eye, and it was marked with a “yes” and the surgeon’s initials on the lid. She was given anesthetic drops in the right eye and an intravenous bolus of 2 mg of midazolam (Versed).

In the OR, Ginny and her operative eye were again identified by the surgeon, anesthetist, and nurses. After anesthesia and akinesia were achieved, the eye area was prepped and draped in sterile sheets. An operating microscope with video system was positioned over her eye. A 5-0 silk suture was placed through the superior

rectus muscle to retract the eye. A lid speculum was placed to open the eye. A minimal conjunctival peritomy was performed, and hemostasis was achieved with wet-field cautery. The anterior chamber was entered at the 10:30 o’clock position. A capsulotomy was performed after Healon was placed in the anterior chamber. Phacoemulsification was carried out without difficulty. The remaining cortex was removed by irrigation and aspiration.

An intraocular lens (IOL) was placed into the posterior chamber. Miochol was injected to achieve papillary miosis, and the wound was closed with one 10-0 suture. Subconjunctival Celestone and Garamycin were injected. The lid speculum and retraction suture were removed. After application of Eserine and Bacitracin ointments, the eye was patched, and a shield was applied. Ginny left the OR in good condition and was discharged to home 4 hours later.

8

### Case Study 8-2 Questions

Follow the instructions for each question and check your answers in Appendix 11.

**Multiple Choice.** Select the best answer, and write the letter of your choice to the left of each number.

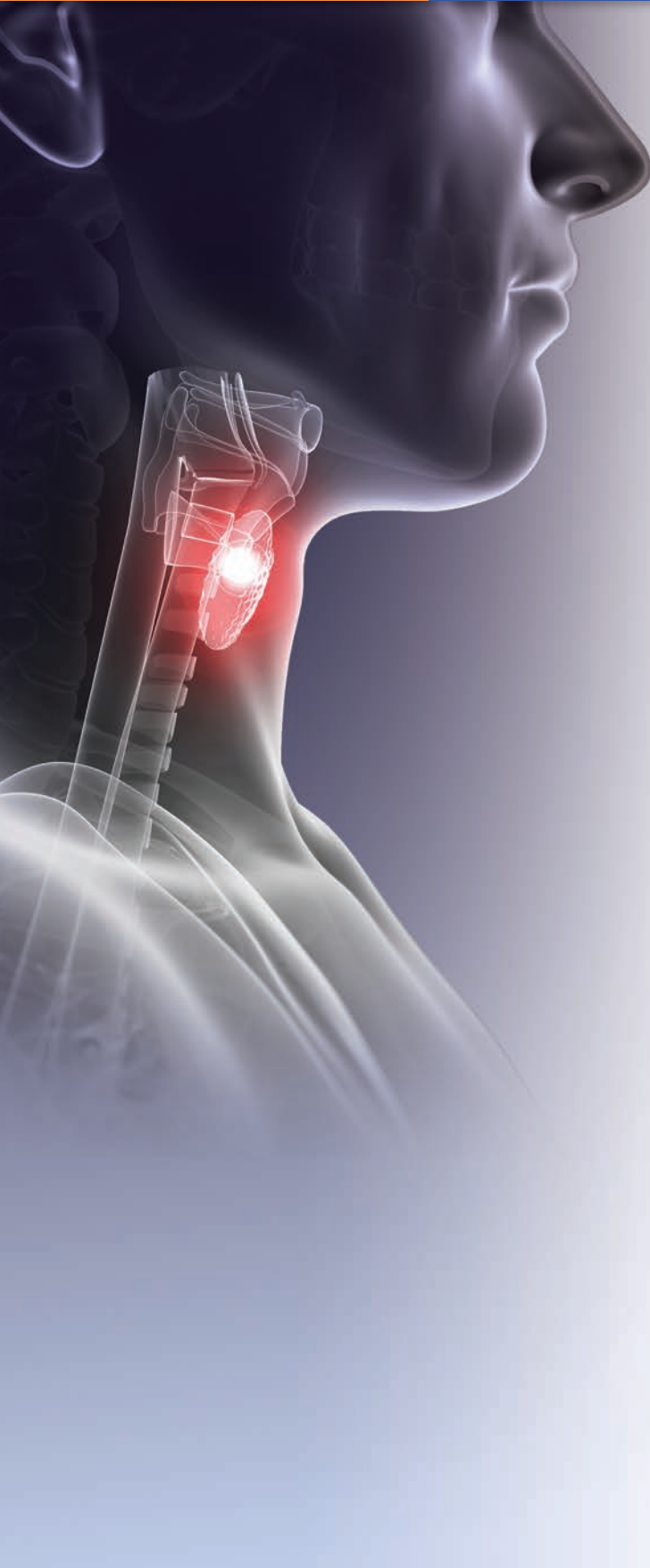
- |  |                                  |
|--|----------------------------------|
| _____ 1. Ultrasound destruction and aspiration of the lens is called | _____ 2. The term akinesia means |
| a. cataractomy   | a. movement                      |
| b. phacoemulsification   | b. lack of sensation             |
| c. stapedectomy  | c. washing                       |
| d. radial keratotomy   | d. lack of movement              |

Write terms from the case study with the following meanings.

3. physician who specializes in conditions of the eye \_\_\_\_\_
4. a circular incision through the conjunctiva \_\_\_\_\_
5. within the eye \_\_\_\_\_
6. abnormal contraction of the pupil \_\_\_\_\_
7. below the conjunctiva \_\_\_\_\_

Define the following abbreviation.

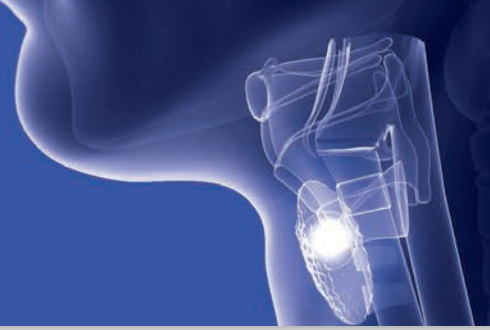8. IOL \_\_\_\_\_



## Pretest

**Multiple Choice.** Select the best answer, and write the letter of your choice to the left of each number. To check your answers go to Appendix 11.

- \_\_\_\_\_ 1. The secretions of the endocrine glands are called
  - a. enzymes
  - b. sera
  - c. lymph
  - d. hormones
- \_\_\_\_\_ 2. The small gland in the brain that controls other glands is the
  - a. thymus
  - b. pituitary
  - c. appendix
  - d. corpus luteum
- \_\_\_\_\_ 3. The glands that are located above the kidneys are the
  - a. adrenals
  - b. thyroid
  - c. follicles
  - d. fimbriae
- \_\_\_\_\_ 4. Gigantism results from overproduction of
  - a. erythropoietin
  - b. oxytocin
  - c. growth hormone
  - d. prolactin
- \_\_\_\_\_ 5. Diabetes mellitus involves the hormone insulin, which is made in the
  - a. kidney
  - b. seminal vesicle
  - c. thymus
  - d. pancreas
- \_\_\_\_\_ 6. A goiter involves the
  - a. zygote
  - b. calyx
  - c. adrenal
  - d. thyroid
- \_\_\_\_\_ 7. Parathyroid hormone regulates
  - a. magnesium
  - b. calcium
  - c. cortisol
  - d. glucose
- \_\_\_\_\_ 8. Cushing disease is overactivity of the
  - a. thyroid
  - b. parathyroid
  - c. adrenal cortex
  - d. adrenal medulla



## Learning Objectives

After careful study of this chapter, you should be able to:

- 1 Define hormones. **P294**
- 2 Compare steroid and amino acid hormones. **P294**
- 3 Give the location and structure of the endocrine glands. **P294**
- 4 Name the hormones produced by the endocrine glands, and briefly describe the function of each. **P295**
- 5 Identify and use roots pertaining to the endocrine system. **P299**
- 6 Describe the main disorders of the endocrine system. **P300**
- 7 Interpret abbreviations used in endocrinology. **P307**
- 8 Analyze medical terms in several case studies concerning the endocrine system. **PP293, 312**

## Case Study: Jasmine's Graves Disease



### Chief Complaint

Jasmine is a 35 y/o second grade teacher. Her husband has been noticing that she has been very energetic over the past few months, more so than usual. She is constantly working or cleaning, and she is up during the night, unable to sleep. Jasmine says that she has felt nervous and jittery for the past few months. Her husband encouraged her to make an appointment with her physician.

### Examination

Jasmine's internist, Dr. Gilbert, was able to make a few observations when he walked into the examination room. Jasmine had lost weight since her last appointment, and her eyes were protruding. Normally a quiet and happy person, she appeared irritable and abrupt. She complained about her edginess, dry eyes, and inability to sleep. She also mentioned that she cannot tolerate the heat and frequently perspires. She said she just has not been "feeling herself" as of late. Dr. Gilbert examined

her, and when palpating her neck, he noted an enlarged thyroid. He also noted a dermatopathy on her shins where the skin had thickened and had red patches. Her vital signs were pretty consistent with previous examinations, except that she was a bit tachycardic. Dr. Gilbert suspected hyperthyroidism. He ordered some blood work to check her thyroid levels and confirm his diagnosis.

### Clinical Course

Results of the laboratory work verified Dr. Gilbert's suspicion. He discussed with Jasmine and her husband the diagnosis of Graves disease, an autoimmune disorder that is the most common form of hyperthyroidism. He provided them the results of the  $T_3$  and  $T_4$  laboratory work and explained that the high levels meant her thyroid was overactive. He then explained the treatment options, including antithyroid medication, partial or total thyroidectomy, or radiation therapy. Dr. Gilbert felt that a medical regime would be appropriate for Jasmine and ordered the antithyroid drug Tapazole. He also ordered eye drops for the exophthalmos.

**Case Study Revisited: Once you complete this chapter, please review the case follow-up on p. 307.**

## Ancillaries *At-A-Glance*

Visit the web resource to access the following resources.

### Learning Resources

- eBook
- A&P Module with Heart & Lung Sounds
- Image Bank
- TestPrep
- Animations
- Audio Pronunciation Glossary



## Introduction

The body's main controlling systems are the endocrine system and the nervous system (discussed in this chapter and Chapter 7, respectively). The endocrine system consists of a widely distributed group of glands that secrete regulatory substances called **hormones**. Because hormones are released into the blood, the **endocrine glands** are known as the *ductless glands*, as compared to exocrine glands such as sweat glands and digestive glands, that secrete through ducts to the outside. Despite the fact that hormones circulating in the blood reach all parts of the body, only certain tissues respond to a specific hormone. The tissue that is influenced by a specific hormone is called the **target tissue**. The cells in a target tissue have specific **receptors** on their membranes or within the cell to which the hormone attaches, enabling it to act.

## Hormones

Hormones are produced in extremely small amounts and are highly potent. By means of their actions on various target tissues, they affect growth, metabolism, reproductive activity, and behavior. (BOX 9-1 describes some old ideas about the effects of substances circulating in the blood.)

Chemically, hormones fall into two categories:

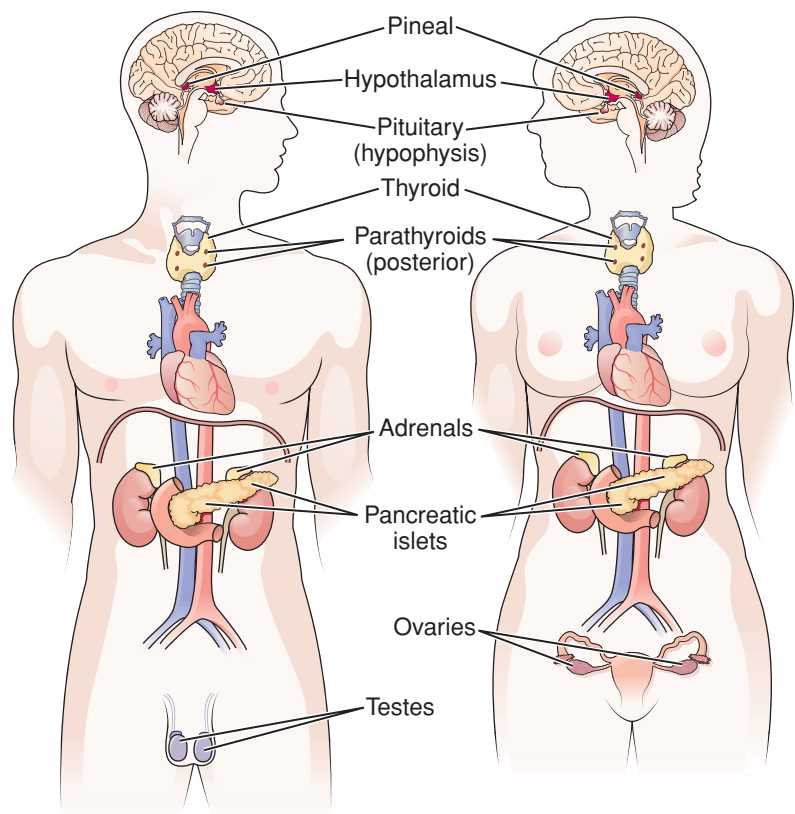
- **Steroid hormones**, which are made from lipids. Steroids are produced by the sex glands (gonads) and the outer region (cortex) of the **adrenal glands**.
- Hormones made of amino acids, which include proteins and protein-like compounds. All of the endocrine glands aside from the gonads and adrenal cortex produce amino acid hormones.

The production of hormones is controlled mainly by negative feedback—that is, the

hormone itself, or some product of hormone activity, acts as a control over further manufacture of the hormone—a self-regulating system. Hormone production may also be controlled by the nervous system or by other hormones.

## The Endocrine Glands

Refer to **FIGURE 9-1** to locate the endocrine glands described below. **BOX 9-2** lists the endocrine glands, along with the hormones they secrete and their functions.



**FIGURE 9-1** The endocrine glands.



### FOCUS ON WORDS

#### Are You in a Good Humor?

BOX 9-1

In ancient times, people accepted the theory that a person's state of health depended on the balance of four body fluids. These fluids, called "humors," were yellow bile, black bile, phlegm, and blood. A predominance of any one of these humors would determine a person's mood or temperament. Yellow bile caused anger; black bile caused depression; phlegm (mucus) made a person sluggish; blood resulted in cheerfulness and optimism.

Although we no longer believe in humoralism, we still have adjectives in our vocabulary that reflect these early

beliefs. Choleric describes a person under the influence of yellow bile; melancholic describes the effects of black bile (melan/o- means black or dark); a phlegmatic person is slow to respond; a sanguine individual "goes with the flow." (*Sanguine* is derived from the Greek word for blood.)

The humors persist today in the adjective *humoral*, which describes substances carried in the blood or other body fluids. The term applies to hormones and other circulating materials that influence body responses. Humoral immunity is immunity based on antibodies carried in the bloodstream.

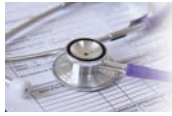

## FOR YOUR REFERENCE

### Endocrine Glands and Their Hormones

BOX 9-2

Gland	Hormone	Principal Functions
<b>anterior pituitary</b> <i>pih-TU-ih-tar-e</i>	GH (growth hormone), also called somatotropin <i>(so-mah-to-TRO-pin)</i>	Promotes growth of all body tissues
	TSH (thyroid-stimulating hormone) ACTH (adrenocorticotrophic hormone) <i>(ah-dre-no-kor-tih-ko-TRO-pik)</i> FSH (follicle-stimulating hormone)	Stimulates thyroid gland to produce thyroid hormones Stimulates adrenal cortex to produce cortical hormones; aids in protecting body in stress situations (injury, pain) Stimulates growth and hormonal activity of ovarian follicles; stimulates growth of testes; promotes sperm cell development
	LH (luteinizing hormone) <i>(LU-te-in-i-zing)</i>  PRL (prolactin) <i>(pro-LAK-tin)</i>	Causes development of corpus luteum at the site of ruptured ovarian follicle in female; stimulates testosterone secretion in male Stimulates milk secretion by mammary glands
<b>posterior pituitary</b>	ADH (antidiuretic hormone; vasopressin) <i>(an-te-di-u-RET-ik; va-so-PRES-in)</i> oxytocin <i>(ok-se-TO-sin)</i>	Promotes water reabsorption in kidney tubules; causes blood vessels to constrict Causes uterine contraction; causes milk ejection from mammary glands
<b>thyroid</b>	thyroxine or tetraiodothyronine (T <sub>4</sub> ) and triiodothyronine (T <sub>3</sub> ) <i>(thi-ROK-sin; tri-i-o-do-THI-ro-nene)</i>	Increase metabolic rate and heat production, influencing both physical and mental activities; required for normal growth
<b>parathyroid</b>	parathyroid hormone (PTH) <i>(par-ah-THI-royd)</i>	Regulates calcium exchange between blood and bones; increases blood calcium level
<b>adrenal cortex</b>	cortisol (hydrocortisone) <i>(KOR-tih-sol)</i> aldosterone <i>(al-DOS-ter-one)</i> sex hormones	Aids in metabolism of carbohydrates, proteins, and fats; active during stress Aids in regulating electrolytes and water balance  May influence secondary sexual characteristics
	<b>adrenal medulla</b>	epinephrine ( <i>adrenaline</i> ) <i>(ep-ih-NEF-rin; ah-DREN-ah-lin)</i>
<b>pancreatic islet</b>	insulin <i>(IN-su-lin)</i>	Aids glucose transport into cells; required for cellular metabolism of nutrients, especially glucose; decreases blood glucose levels
	glucagon <i>(GLU-kah-gon)</i>	Stimulates liver to release glucose, thereby increasing blood glucose levels
<b>pineal</b>	melatonin <i>(mel-ah-TONE-in)</i>	Regulates mood, sexual development, and daily cycles in response to environmental light
<b>testis</b>	testosterone <i>(tes-TOS-teh-rone)</i>	Stimulates growth and development of sexual organs plus development of secondary sexual characteristics; stimulates maturation of sperm cells
<b>ovary</b>	estrogen <i>(ES-tro-jen)</i> progesterone <i>(pro-JES-ter-one)</i>	Stimulates growth of primary sexual organs and development of secondary sexual characteristics Prepares uterine lining for implantation of fertilized ovum; aids in maintaining pregnancy; stimulates development of mammary glands' secretory tissue



## CLINICAL PERSPECTIVES

### Growth Hormone: Its Clinical Use Is Growing

**BOX 9-3**

Growth hormone (GH) is produced by the anterior pituitary. It is released mainly at the beginning of deep sleep, so the old belief that you grow while you sleep has some basis in fact. Although GH primarily affects bone and muscle development during early growth, it has a general stimulating effect on most other tissues throughout life. Its alternative name, somatotropin, comes from *soma* meaning “body” and *tropin* meaning “acting on.” GH is released during times of stress to boost the liver’s output of energy-rich fatty acids when blood glucose levels drop. A lack of GH in childhood results in dwarfism, and

the hormone was initially prescribed only for children with a GH deficiency. Now it has also been approved for children who are in the lowest percentile of height for their age. If a child is still growing, as shown by x-rays of the hand and wrist, GH will lead to some ultimate increase in height. Because GH increases lean muscle mass, it is also touted as a bodybuilding and anti-aging medication. However, it may have some side effects, and its long-term effects are not known. GH for clinical use was initially obtained from cadaver pituitaries, but it is now made by genetic engineering.

## PITUITARY

The **pituitary gland**, or **hypophysis**, is a small gland beneath the brain. It is divided into an anterior lobe (adenohypophysis) and a posterior lobe (neurohypophysis). The **hypothalamus**, a part of the brain that regulates homeostasis, is connected to and controls both lobes. Because the hypothalamus secretes hormones and is active in controlling the pituitary gland, it is considered to be part of the endocrine system as well as the nervous system.

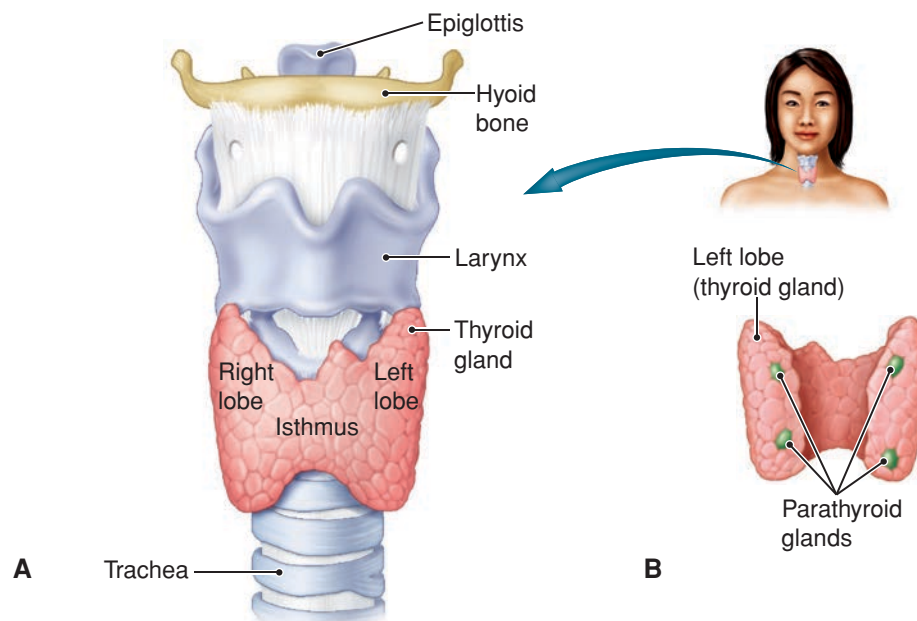
The anterior pituitary produces six hormones. One of these is growth hormone (somatotropin), which stimulates bone growth and acts on other tissues as well (**BOX 9-3**). The remainder of the pituitary hormones regulate other glands, including the thyroid, adrenals, gonads, and mammary glands (see **BOX 9-2**). The ending *-tropin*, as in *gonadotropin*, indicates a hormone that acts on another gland. The adjective ending is *-tropic*, as in *adrenocorticotropic*.

The posterior pituitary releases two hormones that are actually produced in the hypothalamus. These hormones are stored in the posterior pituitary until they are needed:

- Antidiuretic hormone (ADH) acts on the kidneys to conserve water and also promotes constriction of blood vessels. Both of these actions increase blood pressure.
- Oxytocin stimulates uterine contractions and promotes milk “letdown” in the breasts during lactation.

## THYROID AND PARATHYROIDS

The **thyroid gland** consists of two lobes on either side of the larynx and upper trachea. The lobes are connected by a narrow band (isthmus) (**FIG. 9-2**). The thyroid secretes a mixture of hormones, mainly thyroxine ( $T_4$ ) and triiodothyronine ( $T_3$ ). Because thyroid hormones contain iodine, laboratories



**FIGURE 9-2** The thyroid and parathyroid glands. **A.** The thyroid has two lobes connected by an isthmus. This anterior view shows the gland in relation to other structures in the throat. **B.** The parathyroid glands are embedded in the posterior portion of the thyroid.

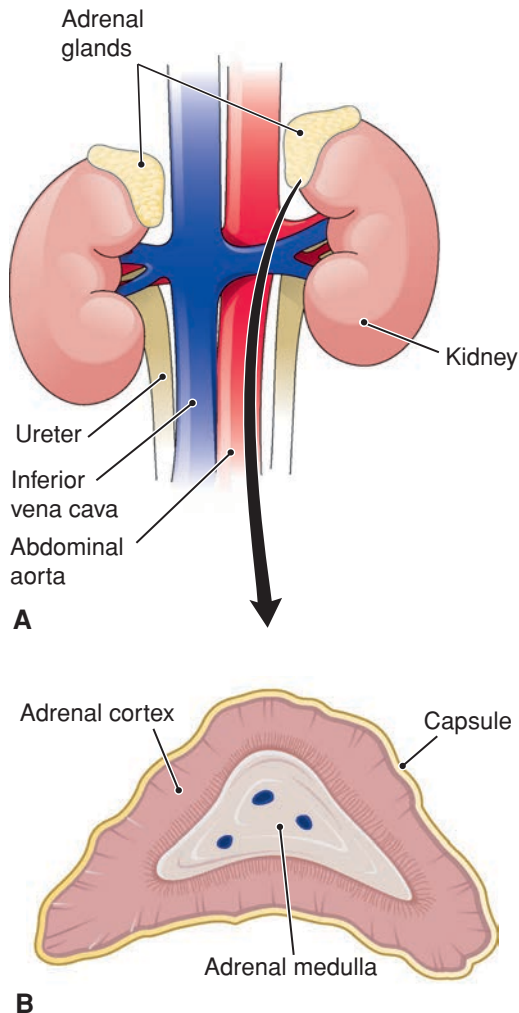
can measure these hormones and study thyroid gland activity by following iodine levels. Most thyroid hormone in the blood is bound to protein, primarily thyroxine-binding globulin (TBG).

On the posterior surface of the thyroid are four to six tiny **parathyroid glands** that affect calcium metabolism (see **FIG. 9-2**). Parathyroid hormone (PTH) regulates calcium exchange between the blood and bones. It increases the blood level of calcium when needed.

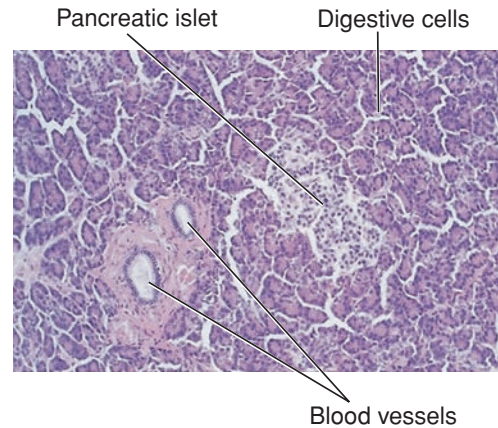
## ADRENALS

The adrenal glands, located atop the kidneys, are divided into two distinct regions: an outer cortex and an inner medulla (**FIG. 9-3**). The hormones produced by this gland are involved in the body's response to stress. The cortex produces steroid hormones:

- Cortisol (hydrocortisone) mobilizes fat and carbohydrate reserves to increase these nutrients in the blood. It also reduces inflammation and is used clinically for this purpose.



**FIGURE 9-3 Adrenal glands.** **A.** The adrenal glands shown on top of the kidneys. **B.** The adrenal gland is divided into a medulla and cortex, each secreting different hormones.



**FIGURE 9-4 Pancreatic cells, microscopic view.** Light-staining islet cells are seen among the cell clusters that produce digestive juices.

- Aldosterone causes the kidneys to conserve sodium and water while eliminating potassium.
- Sex hormones, mainly testosterone, are also produced in small amounts, but their importance is not well understood. Some athletes, illegally and dangerously, take testosterone-like steroids to increase muscle size, strength, and endurance (see **BOX 6-1**).

The medulla of the adrenal gland produces the hormone epinephrine (adrenaline) in response to stress. Epinephrine works with the nervous system to help the body meet physical and emotional challenges.

## PANCREAS

The endocrine portions of the pancreas are the **pancreatic islets**, small cell clusters within the pancreatic tissue. The term *islet*, meaning “small island,” is used because these cells look like little islands in the midst of the many pancreatic cells that secrete digestive juices (**FIG. 9-4**). The islet cells produce two hormones, insulin and glucagon, that regulate glucose metabolism. Insulin increases cellular use of glucose, thus decreasing blood glucose levels. Glucagon has the opposite effect, increasing blood glucose levels.

## Other Endocrine Tissues

There are three additional types of glands that secrete hormones:

- The **pineal gland** is a small gland in the brain (see **FIG. 9-1**). It regulates mood, daily rhythms, and sexual development in response to environmental light. Its hormone is melatonin, which some people take to help regulate sleep–wake cycles when they travel between time zones.
- The **thymus**, described in Chapter 10, secretes the hormone thymosin that aids in the development of the immune system's T cells. The thymus lies in the upper

chest above the heart. It is important in early years but shrinks and becomes less important in adults.

- The gonads, testes, and ovaries, described in Chapters 15 and 16, are also included because they secrete hormones in addition to producing the sex cells.

Other organs, including the stomach, kidney, heart, and small intestine, also produce hormones. However, they have

other major functions and are discussed with the systems to which they belong.

Finally, **prostaglandins** are a group of hormones produced by many cells. They have a variety of effects, including stimulation of uterine contractions, promotion of inflammation, and vasomotor activities. They are called prostaglandins because they were first discovered in the prostate gland.

## Terminology

## Key Terms

The terms listed below are emphasized in this chapter. Knowing them will help you organize and prioritize your learning. These boldface terms are also found, collectively, with all chapter key terms in the Glossary.

### Normal Structure and Function

<b>adrenal gland</b> <i>ab-DRE-nal</i>	A gland on the superior surface of the kidney; the outer region (cortex) secretes steroid hormones; the inner region (medulla) secretes epinephrine (adrenaline) in response to stress (root: adren/o)
<b>endocrine</b> <i>EN-do-krin</i>	Pertaining to a ductless gland that secretes hormones into the blood
<b>hormone</b> <i>HOR-mone</i>	A secretion of an endocrine gland; a substance that travels in the blood and has a regulatory effect on tissues, organs, or glands
<b>hypophysis</b> <i>hi-POF-ih-sis</i>	The pituitary gland; named from <i>hypo</i> , meaning “below,” and <i>physis</i> , meaning “growing,” because the gland develops below the hypothalamus (root: hypophysi/o)
<b>hypothalamus</b> <i>hi-po-THAL-ab-mus</i>	A portion of the brain that controls the pituitary gland, produces hormones, and is active in maintaining homeostasis
<b>pancreatic islet</b> <i>I-let</i>	Cluster of endocrine cells in the pancreas that secretes hormones to regulate glucose metabolism; also called islet of Langerhans or islet cells (root: <i>insul/o</i> means “island”)
<b>parathyroid gland</b> <i>par-ab-THI-royd</i>	A small endocrine gland on the posterior thyroid that acts to increase blood calcium levels; there are usually four to six parathyroid glands (roots: <i>parathyr/o</i> , <i>parathyroid/o</i> ); the name literally means “near the thyroid”
<b>pineal gland</b> <i>PIN-e-al</i>	A small gland in the brain (see <b>FIG. 9-1</b> ); appears to regulate mood, daily rhythms, and sexual development in response to environmental light; secretes the hormone melatonin
<b>pituitary gland</b> <i>pih-TU-ih-tar-e</i>	A small endocrine gland at the base of the brain; the anterior lobe secretes growth hormone and hormones that stimulate other glands; the posterior lobe releases ADH and oxytocin manufactured in the hypothalamus (root: <i>pituitar/i</i> ); hypophysis
<b>prostaglandins</b> <i>pros-tab-GLAN-dinz</i>	A group of hormones produced throughout the body that have a variety of effects, including stimulation of uterine contractions and regulation of blood pressure, blood clotting, and inflammation
<b>receptor</b> <i>re-SEP-tor</i>	A site on the cell membrane or within the cell to which a substance, such as a hormone, attaches
<b>steroid hormone</b> <i>STER-oyd</i>	A hormone made from lipids; includes the sex hormones and the hormones of the adrenal cortex
<b>target tissue</b>	The specific tissue on which a hormone acts; may also be called the target organ
<b>thyroid gland</b> <i>THI-royd</i>	An endocrine gland on either side of the larynx and upper trachea; it secretes hormones that affect metabolism and growth (roots: <i>thyr/o</i> , <i>thyroid/o</i> )

## Roots Pertaining to the Endocrine System

See TABLE 9-1.

Root	Meaning	Example	Definition of Example
endocrin/o	endocrine glands or system	endocrinopathy <i>en-do-krih-NOP-ab-the</i>	any disease of the endocrine glands
pituitar/i	pituitary gland, hypophysis	pituitarism <i>pib-TU-ih-tab-rizm</i>	condition caused by any disorder of pituitary function
hypophysi/o	pituitary gland, hypophysis	hypophysial <i>hi-po-FIZ-e-al</i> (also spelled hypophyseal)	pertaining to the pituitary gland
thyr/o, thyroid/o	thyroid gland	thyrolytic <i>thi-ro-LIT-ik</i>	destroying the thyroid gland
parathyr/o, parathyroid/o	parathyroid gland	hyperparathyroidism <i>hi-per-par-ab-THI-royd-izm</i>	overactivity of a parathyroid gland
adren/o, adrenal/o	adrenal gland, epinephrine	adrenergic <i>ad-ren-ER-jik</i>	activated (erg) by or related to epinephrine (adrenaline)
adrenocortic/o	adrenal cortex	adrenocorticotropic <i>ab-dre-no-kor-tih-ko-TRO-pik</i>	acting on the adrenal cortex
insul/o	pancreatic islets	insular <i>IN-su-lar</i>	pertaining to islet cells

### Exercise 9-1

Complete the exercise. To check your answers go to Appendix 11.

Define the following words.

1. hypoadrenalism (*hi-po-ab-DRE-nal-izm*) \_\_\_\_\_
2. thyrotropic (*thi-ro-TROP-ik*) \_\_\_\_\_
3. hypophysectomy (*hi-pof-ih-SEK-to-me*) \_\_\_\_\_
4. endocrinology (*en-do-krim-OL-o-je*) \_\_\_\_\_
5. insuloma (*in-su-LO-mah*) \_\_\_\_\_

Words for conditions resulting from endocrine dysfunctions are formed by adding the suffix *-ism* to the name of the gland or its root and adding the prefix *hyper-* or *hypo-* for overactivity or underactivity of the gland. Use the full name of the gland to form words with the following definitions.

6. condition of overactivity of the thyroid gland, as seen in Jasmine's opening case study \_\_\_\_\_
7. condition of underactivity of the parathyroid gland \_\_\_\_\_
8. condition of overactivity of the adrenal gland \_\_\_\_\_

Use the word root for the gland to form words with the following definitions.

9. condition of overactivity of the adrenal cortex \_\_\_\_\_
10. condition of underactivity of the pituitary gland (use pituitar/i) \_\_\_\_\_

(continued)

## Exercise 9-1 (Continued)

Write a word for the following definitions.

11. enlargement of the adrenal gland \_\_\_\_\_
12. excision of the thyroid gland, as mentioned in Jasmine's opening case study \_\_\_\_\_
13. any disease of the adrenal gland \_\_\_\_\_
14. physician who specializes in study of the endocrine system \_\_\_\_\_
15. inflammation of the pancreatic islets \_\_\_\_\_

## Clinical Aspects of the Endocrine System

Endocrine diseases usually result from the overproduction (hypersecretion) or underproduction (hyposecretion) of hormones. They may also result from secretion at the wrong time or from an inadequate target tissue response. The causes of abnormal secretion may originate in the gland itself or may result from failure of the hypothalamus or the pituitary to release the proper amount of stimulating hormones. Some of the common endocrine disorders are described below. Conditions resulting from hypersecretion or hyposecretion of hormones are summarized in **BOX 9-4**.

### PITUITARY

A pituitary **adenoma** (glandular tumor) usually increases secretion of growth hormone or adrenocorticotropic hormone (ACTH). Less commonly, a tumor affects the secretion of prolactin. An excess of growth hormone in children causes **gigantism**. In adults it causes **acromegaly**,

characterized by enlargement of the hands, feet, jaw, and facial features. Treatment is by surgery to remove the tumor (adenomectomy) or by drugs to reduce the blood levels of growth hormone. Excess ACTH overstimulates the adrenal cortex, resulting in Cushing disease. Increased prolactin causes milk secretion (galactorrhea) in both males and females. Radiographic studies in cases of pituitary adenoma usually show enlargement of the bony socket (sella turcica) that contains the pituitary.

Pituitary hypofunction, as caused by tumor or interruption of blood supply to the gland, may involve a single hormone but usually affects all functions and is referred to as **panhypopituitarism**. This condition's widespread effects include dwarfism (from lack of growth hormone), lack of sexual development and sexual function, fatigue, and weakness.

A specific lack of ADH from the posterior pituitary results in **diabetes insipidus** in which the kidneys have a decreased ability to conserve water. Symptoms are polyuria (excessive urination) and polydipsia (excessive thirst). Diabetes insipidus should not be confused with **diabetes**



## FOR YOUR REFERENCE

BOX 9-4

### Disorders Associated With Endocrine Dysfunction<sup>a</sup>

Hormone	Hypersecretion	Hyposecretion
growth hormone	gigantism (children), acromegaly (adults)	dwarfism (children)
antidiuretic hormone	syndrome of inappropriate ADH (SIADH)	diabetes insipidus
aldosterone	aldosteronism	Addison disease
cortisol	Cushing syndrome	Addison disease
thyroid hormone	Graves disease, thyrotoxicosis	congenital and adult hypothyroidism
insulin	hypoglycemia	diabetes mellitus
parathyroid hormone	bone degeneration	tetany (muscle spasms)

<sup>a</sup>Refer to key terms for pronunciations and descriptions.

mellitus (DM), a disorder of glucose metabolism described later. The two diseases share the symptoms of polyuria and polydipsia but have entirely different causes. DM is the more common disorder, and when the term *diabetes* is used alone, it generally refers to DM. The word *diabetes* is from the Greek meaning “siphon,” referring to the large urinary output in both forms of diabetes.

## THYROID

Because thyroid hormone affects the growth and function of many tissues, a deficiency of this hormone in infancy causes physical and mental retardation as well as other symptoms that together constitute **congenital hypothyroidism**, also called *infantile hypothyroidism*. If not diagnosed at birth and treated, hypothyroidism will lead to mental retardation within 6 months. The United States and other developed countries now require testing of all newborns for hypothyroidism.

In adults, thyroid deficiency causes weight gain; lethargy; rough, dry skin; hair loss; and facial swelling. There may be reproductive problems and muscular weakness, pain, and stiffness. A common cause of **adult hypothyroidism** is autoimmune destruction of the thyroid. Hypothyroidism in both children and adults is easily treated with thyroid hormone.

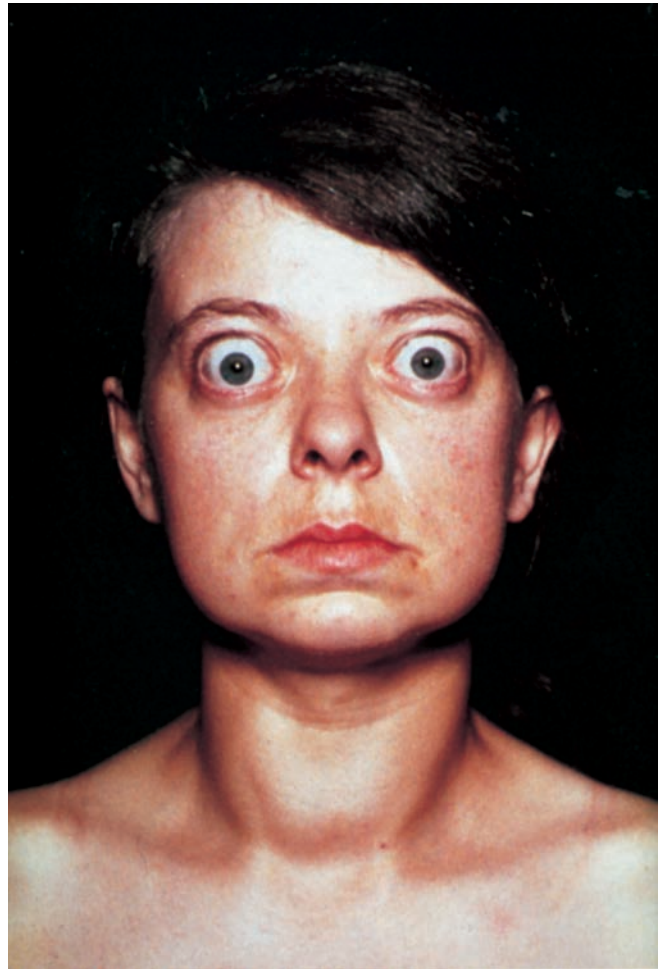
The most common form of hyperthyroidism is **Graves disease**, also called *diffuse toxic goiter*. This is an autoimmune disorder in which antibodies stimulate an increased production of thyroid hormone. There is weight loss, irritability, hand tremor, and rapid heart rate (tachycardia). A most distinctive sign is bulging eyeballs, termed **exophthalmos**, caused by swelling of the tissues behind the eyes (FIG. 9-5). Treatment for Graves disease may include antithyroid drugs, surgical removal of all or part of the thyroid, or radiation delivered in the form of radioactive iodine.

A common sign in thyroid disease is an enlarged thyroid, or **goiter**. However, a goiter is not necessarily accompanied by thyroid malfunction. A simple or nontoxic goiter is caused by a dietary iodine deficiency. Such cases are rare in industrialized countries because of iodine addition to salt and other commercial foods.

Thyroid function is commonly tested by measuring the gland’s radioactive iodine uptake (RAIU). Laboratories use radioimmunoassays to measure blood levels of pituitary thyroid-stimulating hormone (TSH), which varies with changing levels of thyroid hormones. Total and free thyroxine ( $T_4$ ) and triiodothyronine ( $T_3$ ) are also measured, as are the levels of TBG, a blood protein that binds to thyroid hormones. Thyroid scans following administration of radioactive iodine are also used to study this gland’s activity.

## PARATHYROIDS

Overactivity of the parathyroid glands, usually from a tumor, causes a high level of calcium in the blood. Because this calcium is obtained from the bones, there is also skeletal degeneration and bone pain. A common side effect is



**FIGURE 9-5 Graves disease.** A young woman with hyperthyroidism showing a mass in the neck and exophthalmos.

the development of kidney stones from the high levels of circulating calcium.

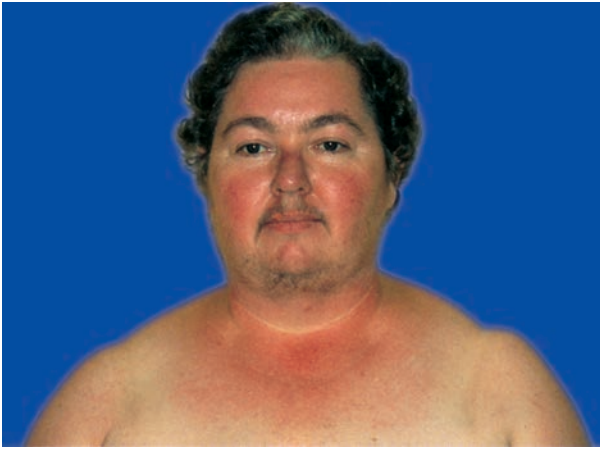Damage to the parathyroids or their surgical removal, as during thyroid surgery, results in a decrease in blood calcium levels. This causes numbness and tingling in the arms and legs and around the mouth (perioral), as well as **tetany** (muscle spasms). Treatment consists of supplying calcium.

## ADRENALS

Hypofunction of the adrenal cortex, or **Addison disease**, is usually caused by autoimmune destruction of the gland. It may also result from a deficiency of pituitary ACTH. The lack of aldosterone results in water loss, low blood pressure, and electrolyte imbalance. There is also weakness and nausea and an increase in brown pigmentation. This last symptom is caused by release of a pituitary hormone that stimulates the skin’s pigment cells (melanocytes). Once diagnosed, Addison disease is treated with replacement of cortical hormones.

An excess of adrenal cortical hormones results in **Cushing syndrome**. Patients with this syndrome have moon-shaped faces, obesity localized in the torso, weakness, excess hair





**FIGURE 9-6 Cushing syndrome.** The woman has a moon face, buffalo hump, increased facial hair, and thinning of the scalp hair.

growth (hirsutism), and fluid retention (**FIG. 9-6**). The most common cause of Cushing syndrome is the therapeutic administration of steroid hormones. An adrenal tumor is another possible cause. If the disorder is caused by a pituitary tumor that increases ACTH production, it is referred to as **Cushing disease**.

## THE PANCREAS AND DIABETES

The most common endocrine disorder, and a serious public health problem, is diabetes mellitus (DM), a failure of the body cells to use glucose effectively. The excess glucose accumulates in the blood, causing **hyperglycemia**. Increased urination (polyuria) marks the effort to eliminate the excess glucose in the urine, a condition termed **glycosuria**. The result is dehydration and excessive thirst (polydipsia). There is also weakness, weight loss, and extreme hunger (polyphagia). Unable to use carbohydrates, the body burns more fat. This leads to accumulation of ketone bodies in the blood and a shift toward acidosis, a condition termed **ketoacidosis**. If untreated, diabetes will lead to starvation of the central nervous system and coma. Diabetic patients are prone to cardiovascular, neurologic, and visual problems; infections; and renal failure.

### Types of Diabetes Mellitus

There are two main types of DM:

- Type 1 diabetes mellitus (T1DM) is caused by autoimmune destruction of pancreatic islet cells and failure of the pancreas to produce insulin. It has an abrupt onset and usually appears in children and teenagers. Because insulin levels are very low or absent, patients need careful monitoring and regular administration of this hormone.
- Type 2 diabetes mellitus (T2DM) accounts for about 90% of diabetes cases. Heredity plays a much greater role in this form of diabetes than in type 1. Type 2 diabetes is initiated by cellular resistance to insulin.

Feedback stimulation of the pancreatic islets leads to insulin overproduction followed by a failure of the overworked cells to produce enough insulin. Most cases of type 2 diabetes are linked to obesity, especially upper-body obesity. Although seen mostly in older people, the incidence of type 2 diabetes is increasing among younger generations, presumably because of increased obesity, poor diet, and sedentary habits.

**Metabolic syndrome**, also called *syndrome X* or *insulin resistance syndrome*, is related to T2DM and describes a state of hyperglycemia caused by insulin resistance in association with some metabolic disorders, including high levels of plasma triglycerides (fats), low levels of high-density lipoproteins (HDLs), hypertension, and coronary heart disease.

Gestational diabetes mellitus (GDM) refers to glucose intolerance during pregnancy. This imbalance usually appears in women with family histories of diabetes and in those who are obese. Women, especially those with predisposing factors, must be monitored during pregnancy for signs of DM because this condition can cause complications for both the mother and the fetus. Gestational diabetes usually disappears after childbirth, but it may be a sign that diabetes will develop later in life. As with other forms of diabetes, a proper diet is the first step to management, with insulin treatment if needed.

DM may also follow other endocrine disorders or treatment with corticosteroids and may be caused by a genetic disorder of the pancreatic islets.

### Diagnosis

Diabetes is diagnosed by measuring glucose levels in blood plasma with or without fasting. The standard for diagnosis of diabetes in a random test is greater than 200 mg/dL and for a fasting plasma glucose (FPG) greater than 126 mg/dL. Measuring blood glucose levels after oral administration of glucose is an oral glucose tolerance test (OGTT). Categories of impaired fasting blood glucose (IFG) and impaired glucose tolerance (IGT) are intermediate stages between a normal response to glucose and confirmed diabetes.

### Treatment

People with T1DM must monitor blood glucose levels four to eight times a day. Traditionally, this is done with blood obtained by a finger stick, but new methods of monitoring glucose through the skin are available. Systems for continuous monitoring are also available, and these can alert patients to high and low blood glucose levels. Readings can be sent wirelessly to a cell phone, which is a boon to parents of juvenile diabetics who previously had to wake their children several times a night to check on blood glucose levels.

Insulin may be given in divided doses by injection or by means of an insulin pump that delivers the hormone around the clock as continuous subcutaneous insulin infusion (CSII). The pump delivers a basal dose of insulin hourly, supplemented by the patient before each meal based the meal's anticipated carbohydrate content. The device injects



## HEALTH PROFESSIONS

### Dietitians and Nutritionists

BOX 9-5

Dietitians and nutritionists specialize in planning and supervising food programs for institutions, such as hospitals, schools, and nursing care facilities, and for individuals with specific disease states, such as diabetes, renal disease, or heart disease. They assess their clients' nutritional needs and design individualized meal plans. Dietitians and nutritionists also work in community settings, educating the public about disease prevention through healthy eating. Increased public awareness about food and nutrition has also led to new opportunities in the food manufacturing industry. To perform their duties, dietitians and nutritionists need a

thorough scientific and clinical background. Most dietitians and nutritionists in the United States receive their training from colleges or universities, complete internships, and take licensing or registration examinations.

Job prospects for dietitians and nutritionists are good. As the American population continues to age, the need for nutritional planning in hospital and nursing care settings is expected to rise. In addition, many people now place an emphasis on healthy eating and may consult nutritionists privately. The Academy of Nutrition and Dietetics at eatright.org has information about these careers.

insulin through tubing into the subcutaneous tissues of the abdomen. Diet must be carefully regulated to keep glucose levels as steady as possible.

While managing diabetes, patients monitor their own glucose levels on a daily basis. Every few months, physicians obtain more precise indications of long-term glucose control with a **glycated hemoglobin (HbA1c) test**. This test is based on glucose uptake by red blood cells and reflects the average blood glucose levels for 2 to 3 months before the test.

Exercise and weight loss for those who are overweight are the first approaches to treating type 2 DM, and these measures often lead to management of the disorder. Drugs for increasing insulin production or improving cellular responses to insulin may also be prescribed, with insulin treatment given if necessary.

Insulin is now made by genetic engineering. There are various forms with different action times that can be alternated to achieve glucose regulation. Excess insulin may result from a pancreatic tumor, but more often it occurs after administration of too much hormone to a diabetic patient.

The resultant **hypoglycemia** leads to **insulin shock**, which is treated by the administration of glucose. People taking insulin injections should carry notification of their disease. A novel approach to preventing hypoglycemic episodes is through the help of dogs. These assist animals are trained to detect breath odors associated with hypoglycemia and alert their owners by nudging or pawing them, most importantly when the person is asleep and unaware of the danger.

Methods of administering insulin in pills or capsules, inhaler spray, or skin patches are under study. Researchers are also studying the possibility of transplanting healthy islet cells to compensate for failed cells. Another area of research is the use of immunosuppression to halt T1DM.

Also used to diagnose endocrine disorders are imaging techniques; other measurements of hormones or their metabolites in plasma and urine; and studies involving hormone stimulation or suppression.

**BOX 9-5** has information on dieticians and nutritionists. These healthcare professionals work with people, including those with diabetes and other metabolic disorders, to plan healthful diets.

9

## Terminology

## Key Terms

The terms listed below are emphasized in this chapter. Knowing them will help you organize and prioritize your learning. These boldface terms are also found, collectively, with all chapter key terms in the Glossary.

### Disorders

#### **acromegaly**

*ak-ro-MEG-ab-le*

Overgrowth of bone and soft tissue, especially in the hands, feet, and face, caused by excess growth hormone in an adult; the name comes from *acro* meaning “extremity” and *megal/o* meaning “enlargement”

#### **Addison disease**

A disease resulting from deficiency of adrenocortical hormones; it is marked by darkening of the skin, weakness, and alterations in salt and water balance

#### **adenoma**

*ad-eh-NO-mah*

A neoplasm of a gland

(continued)

## Terminology

## Key Terms (Continued)

<b>adult hypothyroidism</b> <i>hi-po-THI-royd-izm</i>	A condition caused by hypothyroidism in an adult; there is dry, waxy swelling, most notable in the face; formerly called myxedema ( <i>miks-eh-DE-mah</i> )
<b>congenital hypothyroidism</b> <i>kon-JEN-ib-tal hi-po-THI-royd-izm</i>	A condition caused by lack of thyroid secretion during development and marked by arrested physical and mental growth; also called infantile hypothyroidism
<b>Cushing disease</b>	Overactivity of the adrenal cortex resulting from excess production of ACTH by the pituitary
<b>Cushing syndrome</b>	A condition resulting from an excess of hormones from the adrenal cortex; it is associated with obesity, weakness, hyperglycemia, hypertension, and hirsutism (excess hair growth)
<b>diabetes insipidus</b> <i>di-ab-BE-teze in-SIP-ib-dus</i>	A disorder caused by insufficient release of ADH from the posterior pituitary; it results in excessive thirst and production of large amounts of very dilute urine; <i>insipidus</i> means “tasteless,” referring to the dilution of the urine
<b>diabetes mellitus (DM)</b> <i>MEL-ib-tus</i>	A disorder of glucose metabolism caused by deficiency of insulin production or inadequate tissue response to insulin; type 1 results from autoimmune destruction of pancreatic islet cells; it generally appears in children and requires insulin administration; type 2 generally occurs in obese adults; it is treated with diet, exercise, and drugs to improve insulin production or activity, and sometimes insulin; <i>mellitus</i> comes from the Latin root for honey, referring to the urine’s glucose content
<b>exophthalmos</b> <i>ek-sof-THAL-mos</i>	Protrusion of the eyeballs, as seen in Graves disease
<b>gigantism</b> <i>JI-gan-tizm</i>	Overgrowth caused by excess growth hormone from the pituitary during childhood; also called gigantism
<b>glycated hemoglobin (HbA1c) test</b> <i>GLI-ka-ted</i>	A test that measures the binding of glucose to hemoglobin during the lifespan of a red blood cell; it reflects the average blood glucose level over 2 to 3 months and is useful in evaluating long-term therapy for diabetes mellitus; also called A1c test
<b>glycosuria</b> <i>gli-ko-SU-re-ab</i>	Excess glucose in the urine
<b>goiter</b> <i>GOY-ter</i>	Enlargement of the thyroid gland; a simple (nontoxic) goiter is caused by iodine deficiency
<b>Graves disease</b>	An autoimmune disease resulting in hyperthyroidism; a prominent symptom is exophthalmos (protrusion of the eyeballs); also called diffuse toxic goiter
<b>hyperglycemia</b> <i>bi-per-gli-SE-me-ab</i>	Excess glucose in the blood
<b>hypoglycemia</b> <i>hi-po-gli-SE-me-ab</i>	Abnormally low level of glucose in the blood
<b>insulin shock</b>	A condition resulting from an overdose of insulin, causing hypoglycemia
<b>ketoacidosis</b> <i>ke-to-as-ib-DO-sis</i>	Acidosis (increased acidity of body fluids) caused by excess ketone bodies, as in diabetes mellitus; diabetic acidosis
<b>metabolic syndrome</b>	A state of hyperglycemia caused by cellular resistance to insulin, as seen in type 2 diabetes, in association with other metabolic disorders; also called syndrome X or insulin resistance syndrome
<b>panhypopituitarism</b> <i>pan-hi-po-pih-TU-ib-tab-rism</i>	Underactivity of the entire pituitary gland
<b>tetany</b> <i>TET-ab-ne</i>	Irritability and spasms of muscles; may be caused by low blood calcium and other factors

## Terminology

## Enrichment Terms

The terms listed below expand on the key terms to increase your knowledge of this chapter topic.

### Normal Structure and Function

**sella turcica**  
*SEL-ab TUR-sib-kah* A saddle-shaped depression in the sphenoid bone that contains the pituitary gland (literally means “Turkish saddle”)

**sphenoid bone**  
*SFE-noyd* A bone at the base of the skull that houses the pituitary gland

### Symptoms and Conditions

**adrenogenital syndrome**  
*ad-re-no-JEN-ih-tal* Condition caused by overproduction of androgens from the adrenal cortex, resulting in masculinization; may be congenital or acquired, usually as a result of an adrenal tumor

**Conn syndrome** Hyperaldosteronism caused by an adrenal tumor

**craniopharyngioma**  
*kra-ne-o-far-in-je-O-mah* A benign tumor of the pituitary gland

**Hashimoto disease**  
*hab-she-MO-to* A chronic thyroiditis of autoimmune origin

**impaired glucose tolerance (IGT)** High blood glucose levels after glucose intake that may signal borderline diabetes mellitus

**ketosis**  
*ke-TO-sis* Accumulation of ketone bodies, such as acetone, in the body; usually results from deficiency or faulty metabolism of carbohydrates, as in cases of diabetes mellitus and starvation

**multiple endocrine neoplasia (MEN)** A hereditary disorder that causes tumors in several endocrine glands; classified according to the combination of glands involved

**pheochromocytoma**  
*fe-o-kro-mo-si-TO-mah* A usually benign tumor of the adrenal medulla or other structures containing chromaffin cells (cells that stain with chromium salts) (phe/o means “brown” or “dusky”); the adrenal tumor causes increased production of epinephrine

**pituitary apoplexy**  
*AP-o-plek-se* Sudden massive hemorrhage and degeneration of the pituitary gland associated with a pituitary tumor; common symptoms include severe headache, visual problems, and loss of consciousness

**seasonal affective disorder (SAD)** A mood disorder with lethargy, depression, excessive need for sleep, and overeating that generally occurs in winter; thought to be related to melatonin levels as influenced by environmental light (**BOX 9-6**)

**Simmonds disease** Hypofunction of the anterior pituitary (panhypopituitarism), usually because of an infarction; pituitary cachexia (*ka-KEK-se-a*)

**thyroid storm** A sudden onset of thyrotoxicosis symptoms occurring in patients with hyperthyroidism who are untreated or poorly treated; may be brought on by illness or trauma; also called thyroid crisis

**thyrotoxicosis**  
*thi-ro-tok-sib-KO-sis* Condition resulting from overactivity of the thyroid gland; symptoms include anxiety, irritability, weight loss, and sweating; the main example of thyrotoxicosis is Graves disease

**von Recklinghausen disease**  
*REK-ling-how-zen* Bone degeneration caused by excess production of parathyroid hormone; also called Recklinghausen disease of bone

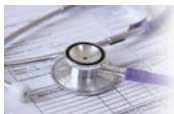(continued)

## Terminology

## Enrichment Terms (Continued)

## Diagnosis and Treatment

<b>fasting plasma glucose (FPG)</b>	Measurement of blood glucose after a fast of at least 8 hours; a reading equal to or greater than 126 mg/dL indicates diabetes; also called fasting blood glucose (FBG) or fasting blood sugar (FBS)
<b>free thyroxine index (FTI, T<sub>7</sub>)</b>	Calculation based on the amount of T <sub>4</sub> present and T <sub>3</sub> uptake, used to diagnose thyroid dysfunction
<b>oral glucose tolerance test (OGTT)</b>	Measurement of glucose levels in blood plasma after administration of a challenge dose of glucose to a fasting patient; used to measure patient's ability to metabolize glucose; a value equal to or greater than 200 mg/dL in the two-hour sample indicates diabetes
<b>radioactive iodine uptake test (RAIU)</b>	A test that measures thyroid uptake of radioactive iodine as an evaluation of thyroid function
<b>radioimmunoassay (RIA)</b>	A method of measuring very small amounts of a substance, especially hormones, in blood plasma using radioactively labeled hormones and specific antibodies
<b>thyroid scan</b>	Visualization of the thyroid gland after administration of radioactive iodine
<b>thyroxine-binding globulin (TBG) test</b>	Test that measures the main protein that binds T <sub>4</sub> in the blood
<b>transsphenoidal adenomectomy</b> <i>trans-sfe-NOY-dal ad-eh-no-MEK-to-me</i>	Removal of a pituitary tumor through the sphenoid sinus (space in the sphenoid bone)



## CLINICAL PERSPECTIVES

BOX 9-6

## Seasonal Affective Disorder: Some Light on the Subject

We all sense that long dark days make us blue and sap our motivation. Are these learned responses, or is there a physical basis for them? Studies have shown that the amount of light in the environment does have a physical effect on behavior. Evidence that light alters mood comes from people who are intensely affected by the dark days of winter—people who suffer from *seasonal affective disorder*, aptly abbreviated SAD. When days shorten, these people feel sleepy, depressed, and anxious. They tend to overeat, especially carbohydrates.

As light strikes the retina of the eye, it starts nerve impulses that decrease the amount of melatonin produced by the pineal gland in the brain. Because melatonin depresses mood, the final effect of light is to elevate mood. Daily exposure to bright lights has been found to improve the mood of most people with SAD. Exposure for 15 minutes after rising in the morning may be enough, but some people require longer sessions both morning and evening. Other aids include aerobic exercise, stress management techniques, and antidepressant medications.

## Terminology *Abbreviations*

The abbreviations listed below are emphasized in this chapter. These are also found, collectively, with all chapter abbreviations in Appendix 2.

<b>A1c</b>	Glycated hemoglobin (test)
<b>ACTH</b>	Adrenocorticotrophic hormone
<b>ADH</b>	Antidiuretic hormone
<b>BS</b>	Blood sugar
<b>CSII</b>	Continuous subcutaneous insulin infusion
<b>DM</b>	Diabetes mellitus
<b>FBG</b>	Fasting blood glucose
<b>FBS</b>	Fasting blood sugar
<b>FBG</b>	Fasting plasma glucose
<b>FSH</b>	Follicle-stimulating hormone
<b>FTI</b>	Free thyroxine index
<b>GDM</b>	Gestational diabetes mellitus
<b>GH</b>	Growth hormone
<b>HbA1c</b>	Hemoglobin A1c; glycated hemoglobin
<sup>131</sup> I	Iodine-131 (radioactive iodine)
<b>IFG</b>	Impaired fasting blood glucose
<b>IGT</b>	Impaired glucose tolerance

<b>LH</b>	Luteinizing hormone
<b>MEN</b>	Multiple endocrine neoplasia
<b>NPH</b>	Neutral protamine Hagedorn (insulin)
<b>OGTT</b>	Oral glucose tolerance test
<b>PRL</b>	Prolactin
<b>PTH</b>	Parathyroid hormone
<b>RAIU</b>	Radioactive iodine uptake
<b>RIA</b>	Radioimmunoassay
<b>SIADH</b>	Syndrome of inappropriate antidiuretic hormone (secretion)
<b>T1DM</b>	Type 1 diabetes mellitus
<b>T2DM</b>	Type 2 diabetes mellitus
<b>T<sub>3</sub></b>	Triiodothyronine
<b>T<sub>4</sub></b>	Thyroxine; tetraiodothyronine
<b>T<sub>7</sub></b>	Free thyroxine index
<b>TBG</b>	Thyroxine-binding globulin
<b>TSH</b>	Thyroid-stimulating hormone

## Case Study Revisited

### Jasmine's Follow-Up

Jasmine stopped by her local pharmacy to pick up her prescription for Tapazole. She asked the pharmacist to clarify the information Dr. Gilbert had given her about the medication. The pharmacist told Jasmine that Tapazole (generic name: methimazole) acts to prevent the thyroid gland from producing too much thyroid hormone. Some common side effects include nausea, vomiting, upset stomach; headache, dizziness, drowsiness; muscle or joint pain, and decreased sense of taste. Jasmine was told to get emergency help if she had signs of an allergic reaction: hives, difficulty breathing, swelling of the face, lips, tongue, or throat. The pharmacist dispensed the medication and emphasized the importance of following

the directions on the prescription label. Since Jasmine was around young school children during the day the medication was dispensed in a child proof container.

After beginning her antithyroid medication therapy Jasmine began to feel better and told her husband she was able to concentrate more at work and found she was not as irritable with the children in school. She was sleeping better and began to add a few of the pounds she had previously lost. Her husband said he also noticed the difference. At her follow-up appointment with Dr. Gilbert, Jasmine was told that the medication was working. Her dosage would be the same over the next several months and would be reevaluated at her next appointment.

This review tests your understanding of the content introduced in this chapter. Follow the instructions for each exercise and check your answers in Appendix 11.

## LABELING EXERCISE

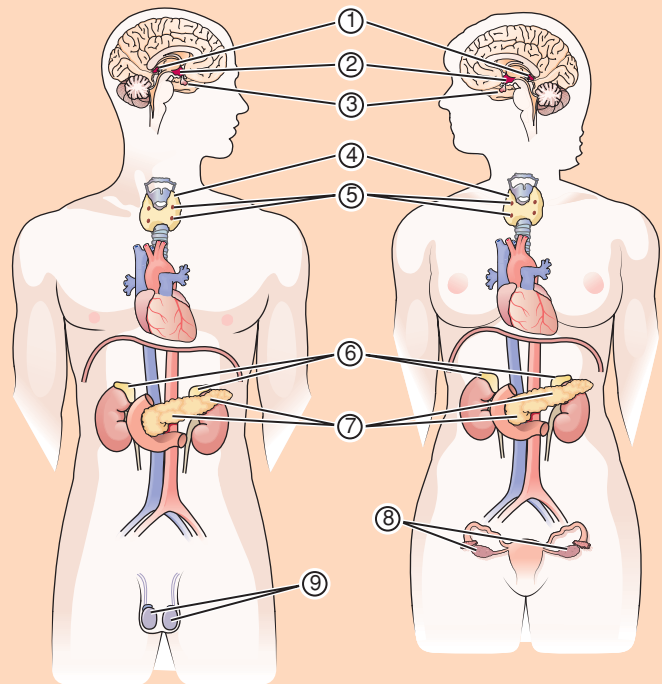
### GLANDS OF THE ENDOCRINE SYSTEM

Write the name of each numbered part on the corresponding line.

Adrenals  
Hypothalamus  
Ovaries  
Pancreatic islets  
Parathyroids

Pineal  
Pituitary (hypophysis)  
Testes  
Thyroid

1. \_\_\_\_\_
2. \_\_\_\_\_
3. \_\_\_\_\_
4. \_\_\_\_\_
5. \_\_\_\_\_
6. \_\_\_\_\_
7. \_\_\_\_\_
8. \_\_\_\_\_
9. \_\_\_\_\_



## TERMINOLOGY

### MATCHING

Match the following terms, and write the appropriate letter to the left of each number.

- |                              |   |
|------------------------------|---|
| _____ 1. parathyroid         | a. gland that is regulated by light                       |
| _____ 2. posterior pituitary | b. small gland that acts to increase blood calcium levels |
| _____ 3. hypothalamus        | c. part of the brain that controls the pituitary          |
| _____ 4. anterior pituitary  | d. gland that secretes ACTH                               |
| _____ 5. pineal              | e. gland that releases oxytocin                           |
| _____ 6. epinephrine         | a. hormone produced by the adrenal cortex                 |
| _____ 7. growth hormone      | b. somatotropin   |
| _____ 8. cortisol            | c. pancreatic hormone that regulates glucose metabolism   |
| _____ 9. glucagon            | d. hormone produced by the adrenal medulla                |
| _____ 10. melatonin          | e. hormone from the pineal gland                          |

- |                            |  |
|----------------------------|--|
| ___ 11. ADH                | a. substance used to monitor blood glucose levels        |
| ___ 12. T <sub>4</sub>     | b. pituitary hormone that regulates water balance        |
| ___ 13. ACTH               | c. a form of diabetes                                    |
| ___ 14. T2DM               | d. thyroxine   |
| ___ 15. HbA1c              | e. hormone that stimulates the adrenal cortex            |
| ___ 16. ketoacidosis       | a. disorder that results from excess growth hormone      |
| ___ 17. adenoma            | b. disorder caused by insufficient release of ADH        |
| ___ 18. Cushing syndrome   | c. a result of uncontrolled diabetes                     |
| ___ 19. acromegaly         | d. disorder caused by overactivity of the adrenal cortex |
| ___ 20. diabetes insipidus | e. neoplasm of a gland                                   |

**Enrichment Terms**

- |                           |   |
|---------------------------|---|
| ___ 21. craniopharyngioma | a. panhypopituitarism                       |
| ___ 22. Simmonds disease  | b. tumor of the pituitary gland             |
| ___ 23. pheochromocytoma  | c. chronic thyroiditis                      |
| ___ 24. Hashimoto disease | d. bony depression that holds the pituitary |
| ___ 25. sella turcica     | e. tumor of the adrenal medulla             |

**FILL IN THE BLANKS**

*Complete the sentence with the correct term(s).*

26. The gland under the brain that controls other glands is the \_\_\_\_\_.
27. The gland in the neck that affects metabolic rate is the \_\_\_\_\_.
28. The endocrine glands located above the kidneys are the \_\_\_\_\_.
29. The most common endocrine disorder is \_\_\_\_\_.
30. Excess glucose in the blood is called \_\_\_\_\_.

**DEFINITIONS**

*Define the following words.*

31. thyrotomy (*thi-ROT-o-me*) \_\_\_\_\_
32. hypopituitarism (*hi-po-pih-TU-ih-tab-rizm*) \_\_\_\_\_
33. hypophysiotropic (*hi-po-fiz-e-o-TROP-ik*) \_\_\_\_\_
34. adrenopathy (*ab-dre-NOP-ab-the*) \_\_\_\_\_
35. adrenomegaly (*ab-dre-no-MEG-ab-le*) \_\_\_\_\_
36. endocrinologist (*en-do-krib-NOL-o-jist*) \_\_\_\_\_

*Write words for the following definitions.*

37. tumor of the pancreatic islets \_\_\_\_\_
38. destroying the thyroid gland \_\_\_\_\_
39. pertaining to the adrenal cortex \_\_\_\_\_

*Use the full name of the gland as the root to write words for the following definitions.*

40. inflammation of the thyroid gland \_\_\_\_\_
41. removal of one half (hemi-) of the thyroid gland \_\_\_\_\_
42. surgical removal of parathyroid gland \_\_\_\_\_
43. overactivity of the adrenal gland \_\_\_\_\_



Use the root *thyr/o* to write words for the following definitions.

44. acting on the thyroid gland \_\_\_\_\_
45. downward displacement of the thyroid gland \_\_\_\_\_
46. any disease of the thyroid gland \_\_\_\_\_

### TRUE-FALSE

Examine the following statements. If the statement is true, write T in the first blank. If the statement is false, write F in the first blank, and correct the statement by replacing the underlined word in the second blank.

	True or False	Correct Answer
47. Diabetes insipidus is caused by a lack of <u>thymosin</u> .	_____	_____
48. The hypophysis is the <u>pituitary</u> gland.	_____	_____
49. The outer region of an organ is the <u>medulla</u> .	_____	_____
50. The parathyroids regulate the element <u>sodium</u> .	_____	_____
51. Goiter is an enlargement of the <u>pineal</u> gland.	_____	_____
52. <u>Type 1</u> diabetes mellitus always requires insulin.	_____	_____
53. Thyroid hormones contain the element <u>iodine</u> .	_____	_____
54. The adrenal cortex produces <u>steroid</u> hormones.	_____	_____
55. Exophthalmos is protrusion of the <u>eyes</u> .	_____	_____
56. <u>Melatonin</u> regulates mood and daily cycles.	_____	_____

### ELIMINATIONS

In each of the sets below, underline the term that does not fit in with the rest, and explain the reason for your choice.

57. GH — TSH — FSH — PTH — ACTH

\_\_\_\_\_

58. Cushing syndrome — gigantism — dwarfism — acromegaly — thyrotoxicosis

\_\_\_\_\_

59. TBG — GDM — FPG — IGT — IFG

\_\_\_\_\_

60. testis — spleen — adrenals — parathyroids — pituitary

\_\_\_\_\_

### WORD BUILDING

Write words for the following definitions using the word parts provided. Each word part can be used more than once.

-ar	adren/o	-megal/o	-oma	thyr/o	-ic	-al	trop	-y	insul/o	path/o	-lytic
-----	---------	----------	------	--------	-----	-----	------	----	---------	--------	--------

61. any disease of the thyroid gland \_\_\_\_\_
62. acting on the adrenal gland \_\_\_\_\_
63. enlargement of the thyroid gland \_\_\_\_\_
64. pertaining to the gland above the kidney \_\_\_\_\_
65. enlargement of the adrenal gland \_\_\_\_\_
66. tumor of islet cells \_\_\_\_\_

67. destructive of thyroid tissue \_\_\_\_\_
68. any disease of the adrenal gland \_\_\_\_\_
69. acting on the thyroid gland \_\_\_\_\_
70. pertaining to pancreatic islet cells \_\_\_\_\_

### WORD ANALYSIS

Define each of the following words, and give the meaning of the word parts in each. Use a dictionary if necessary.

71. craniopharyngioma (*kra-ne-o-fah-rin-je-O-mah*)
- crani/o \_\_\_\_\_
  - pharyng/i \_\_\_\_\_
  - oma \_\_\_\_\_
72. panhypopituitarism (*pan-bi-po-pih-TU-ih-tah-rism*)
- pan- \_\_\_\_\_
  - hypo- \_\_\_\_\_
  - pituitar \_\_\_\_\_
  - ism \_\_\_\_\_
73. pheochromocytoma (*fe-o-kro-mo-si-TO-mah*)
- phe/o \_\_\_\_\_
  - chrom/o \_\_\_\_\_
  - cyt/o \_\_\_\_\_
  - oma \_\_\_\_\_
74. thyrotoxicosis (*thi-ro-tok-sih-KO-sis*)
- thyr/o \_\_\_\_\_
  - toxic/o \_\_\_\_\_
  - sis \_\_\_\_\_
75. acromegaly
- act/o \_\_\_\_\_
  - megal/o \_\_\_\_\_
  - y \_\_\_\_\_

### NAME THE GLAND

Identify the gland associated with the following conditions.

76. diabetes mellitus \_\_\_\_\_
77. Addison disease \_\_\_\_\_
78. Graves disease \_\_\_\_\_
79. tetany \_\_\_\_\_
80. Simmonds disease \_\_\_\_\_

## Additional Case Studies

### Case Study 9-1: Hyperparathyroidism

Beth, a 58 y/o woman with a history of hypertension (HTN), had a partial nephrectomy 4 years ago for renal calculi. During a routine physical examination, her total serum calcium level was 10.8 mg/dL. Her parathyroid hormone level was WNL; she was in no apparent distress, and the remainder of her physical examination and laboratory data were noncontributory.

Beth underwent exploratory surgery for an enlarged right superior parathyroid gland. The remaining three

glands appeared normal. The enlarged gland was excised, and a biopsy was performed on the remaining glands. The pathology report showed an adenoma of the abnormal gland. On her first postoperative day, she reported perioral numbness and tingling. She had no other symptoms, but her serum calcium level was subnormal. She was given one ampule of calcium gluconate. Within 2 days, her calcium level had improved, and she was discharged.

### Case Study 9-1 Questions

Follow the instructions for each question and check your answers in Appendix 11.

**Multiple Choice.** Select the best answer, and write the letter of your choice to the left of each number.

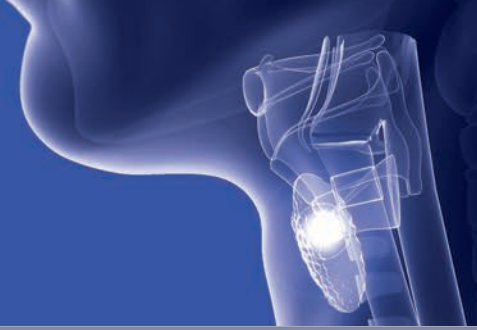- |  |   |
|--|---|
| <p>_____ 1. Renal calculi are</p> <ul style="list-style-type: none"><li>a. kidney stones</li><li>b. gallstones</li><li>c. stomach ulcers</li><li>d. bile obstructions</li></ul> <p>_____ 2. Beth's serum calcium was 10.8 mg/dL, which is</p> <ul style="list-style-type: none"><li>a. 5.4 <math>\mu</math>g of calcium in her serous fluid</li><li>b. 10.8 g of electrolytes in parathyroid hormone</li><li>c. 10.8 mg of calcium in 100 mL of blood</li><li>d. 21.6 L of calcium in 100 g of serum</li></ul> | <p>_____ 3. Beth had perioral numbness and tingling. Perioral is</p> <ul style="list-style-type: none"><li>a. peripheral to any orifice</li><li>b. lateral to the eye</li><li>c. within the buccal mucosa</li><li>d. around the mouth</li></ul> |
|--|---|

Write the terms from the case study with the following meanings.

- 4. surgical excision of a kidney \_\_\_\_\_
- 5. tumor of a gland \_\_\_\_\_
- 6. single-use glass injectable medication container \_\_\_\_\_

Define the following abbreviations.

- 7. HTN \_\_\_\_\_
- 8. WNL \_\_\_\_\_



## Case Study 9-2: Diabetes Treatment With an Insulin Pump

Maria, a 32 y/o marketing executive, was diagnosed with type 1 diabetes at the age of 3. She vividly remembers her mother taking her to the doctor because she had an illness that caused her to feel extremely tired and very thirsty and hungry. She also had begun to wet her bed and had a cut on her knee that would not heal. Her mother had had gestational diabetes during her pregnancy with Maria, and at birth, Maria was described as having “macrosomia” because she weighed 10 pounds.

Maria has managed her disease with meticulous attention to her diet, exercise, preventive health care, regular blood glucose monitoring, and twice-daily injections of regular and NPH insulin, which she rotates among her upper arms, thighs, and abdomen. She continues in a smoking cessation program supported

by weekly acupuncture treatments. She maintains good control of her disease in spite of the inconvenience and time it consumes each day. She will be married next summer and would like to start a family. Maria’s doctor suggested she try an insulin pump to give her more freedom and enhance her quality of life. After intensive training, she has received her pump. It is about the size of a deck of cards with a thin catheter that she introduces through a needle into her abdominal subcutaneous tissue. She can administer her insulin in a continuous subcutaneous insulin infusion (CSII) and in calculated meal bolus doses. She still has to test her blood for hyperglycemia and hypoglycemia and her urine for ketones when her blood glucose is too high. She hopes one day to have an islet transplantation.

### Case Study 9-2 Questions

Follow the instructions for each question and check your answers in Appendix 11.

**Multiple Choice.** Select the best answer, and write the letter of your choice to the left of each number.

- \_\_\_\_\_ 1. Gestational diabetes occurs
  - a. in a pregnant woman
  - b. to any large fetus
  - c. during menopause
  - d. in a large baby with high blood glucose
- \_\_\_\_\_ 2. The term macrosomia describes
  - a. excessive weight gain during pregnancy
  - b. a large body
  - c. an excessive amount of sleep
  - d. inability to sleep during pregnancy
- \_\_\_\_\_ 3. Maria injected the insulin into the subcutaneous tissue, which is
  - a. present only in the abdomen, thighs, and upper arms
  - b. a topical application
  - c. below the skin
  - d. above the pubic bone
- \_\_\_\_\_ 4. An islet transplantation refers to
  - a. transfer of insulin-secreting cells into a pancreas
  - b. transfer of parathyroid cells to the liver
  - c. surgical insertion of an insulin pump into the abdomen
  - d. a total pancreas and kidney transplantation

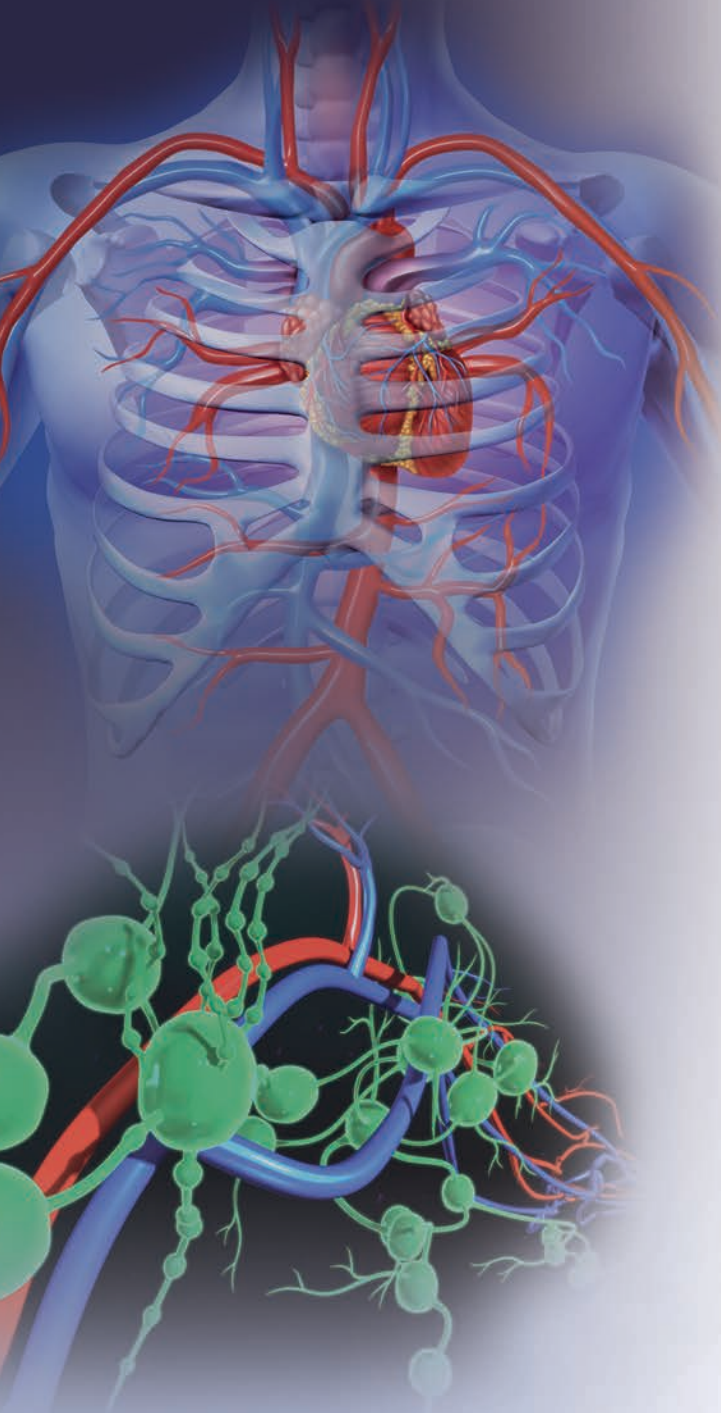Write the terms from the case study with the following meanings.

- 5. high serum glucose \_\_\_\_\_
- 6. a large dose of a therapeutic agent \_\_\_\_\_

Define the following abbreviations.

- 7. NPH \_\_\_\_\_
- 8. CSII \_\_\_\_\_

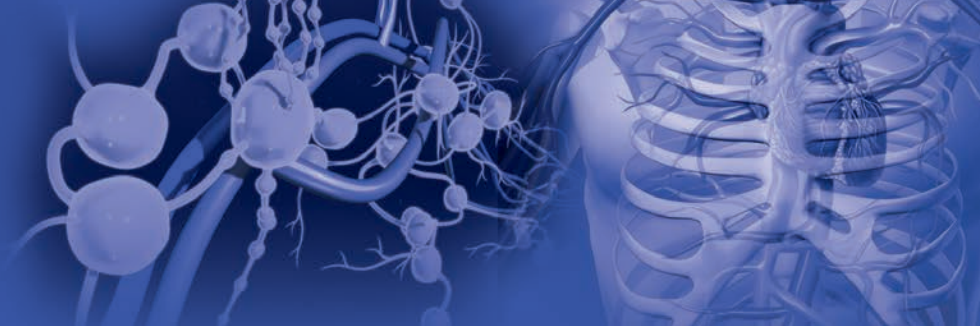# Cardiovascular and Lymphatic Systems



## Pretest

**Multiple Choice.** Select the best answer, and write the letter of your choice to the left of each number. To check your answers go to Appendix 11.

- \_\_\_\_\_ 1. The cardiovascular system includes the heart and
  - a. lungs
  - b. digestive organs
  - c. blood vessels
  - d. endocrine system
- \_\_\_\_\_ 2. The thick, muscular layer of the heart wall is the
  - a. endocardium
  - b. valve
  - c. myocardium
  - d. apex
- \_\_\_\_\_ 3. An upper chamber of the heart is a(n)
  - a. ventricle
  - b. atrium
  - c. base
  - d. systole
- \_\_\_\_\_ 4. A vessel that carries blood away from the heart is a(n)
  - a. vein
  - b. chamber
  - c. lymph node
  - d. artery
- \_\_\_\_\_ 5. The tonsils, spleen, and thymus are part of the
  - a. digestive system
  - b. endocrine system
  - c. epicardium
  - d. lymphatic system
- \_\_\_\_\_ 6. The medical term for a "heart attack" is
  - a. cerebrovascular accident
  - b. myocardial infarction
  - c. aneurysm
  - d. pneumonia
- \_\_\_\_\_ 7. The accumulation of fatty deposits in the lining of a vessel is called
  - a. obesity
  - b. stent
  - c. atherosclerosis
  - d. angiogenesis
- \_\_\_\_\_ 8. Phlebitis is inflammation of a
  - a. vein
  - b. heart
  - c. blood cell
  - d. nerve



## Learning Objectives

After careful study of this chapter, you should be able to:

- 1 Describe the structure of the heart. **P317**
- 2 Trace the path of blood flow through the heart. **P317**
- 3 Trace the path of electrical conduction through the heart. **P319**
- 4 Identify the components of an electrocardiogram. **P319**
- 5 Differentiate among arteries, arterioles, capillaries, venules, and veins. **P321**
- 6 Explain blood pressure and describe how blood pressure is measured. **P321**
- 7 Identify and use the roots pertaining to the cardiovascular and lymphatic systems. **PP326, 340**
- 8 Describe the main disorders that affect the cardiovascular and lymphatic systems. **PP328, 341**
- 9 Define medical terms pertaining to the cardiovascular and lymphatic systems. **PP334, 342**
- 10 List the functions and components of the lymphatic system. **P337**
- 11 Interpret medical abbreviations referring to circulation. **P346**
- 12 Analyze medical terms in case studies involving circulation. **PP315, 354**

## Case Study: Carlos's Arrhythmia During Army Boot Camp



### Chief Complaint

Carlos, a 19 y/o man recently enlisted into the army, successfully passed the army physicals and reported to Fort Knox for basic training. The first 2 weeks were uneventful as Carlos

became acclimated to the vigorous daily schedules of army life. As the physical training progressed, the platoon would go on long runs in full gear. Carlos passed out during two of these runs. The first time he was taken to the infirmary, where he was examined, cleared, and returned to duty. With the second incident, he was put on a sick leave and sent home for additional follow-up.

### Examination

When Carlos came home, his family took him to see his primary care physician, who referred him to a cardiologist. Carlos explained to the physician that on some of the long, rigorous runs with full gear he would become short of breath and feel his heart start to race. He would then become dizzy and pass out. When he woke up, he would be lying on the ground with his sergeant standing over him.

The physician ordered some laboratory tests and also a Holter monitor that Carlos was to wear for the next 48 hours. The physician explained that the Holter monitor is a portable electrocardiogram (ECG) that continuously records the

heart's electrical activity. Electrodes (small, plastic patches that stick to the skin) were placed at certain locations on Carlos's chest and abdomen. The electrodes were attached to the small ECG box by wires. The physician further explained to Carlos and his family that he suspected an abnormal heartbeat had caused the fainting spells. The monitor would record any arrhythmias or other abnormalities that might occur during the next 48 hours. He told Carlos to keep a diary of his activities and symptoms during the test.

### Clinical Course

At the conclusion of the 48-hour test, Carlos saw the cardiologist again. The results of the Holter monitor indicated that he had an abnormal heart rhythm known as atrial fibrillation. The physician explained the two methods of treatment for the condition: a medical approach using anticoagulants to prevent blood clots and medication to slow the heart rate, and a surgical procedure called an ablation. It was decided after reviewing the test results and discussion with family on the pros and cons of the various treatment options that a pulmonary vein catheter ablation was the treatment of choice for Carlos.

**Case Study Revisited: Once you complete this chapter, please review the case follow-up on p. 347.**

## Ancillaries *At-A-Glance*

Visit the web resource to access the following resources.

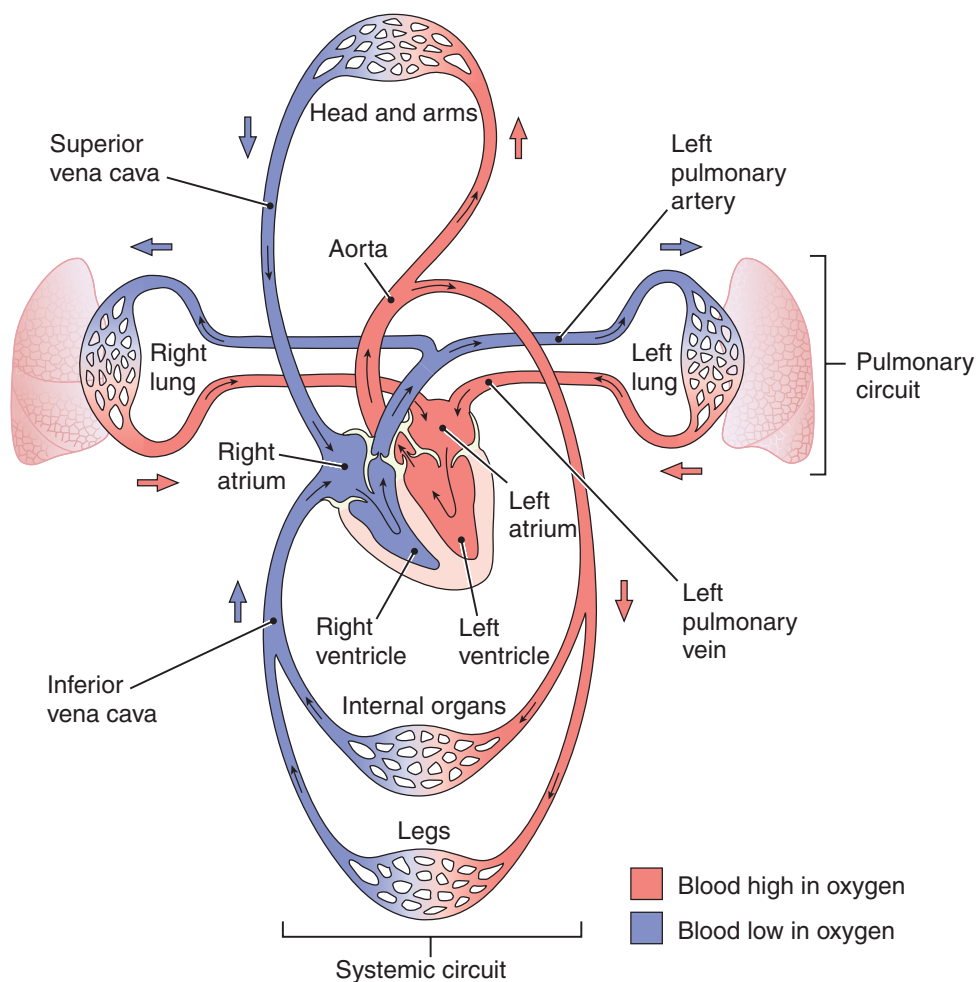
### Learning Resources

- eBook
- A&P Module with Heart & Lung Sounds
- Image Bank
- TestPrep
- Animations
- Audio Pronunciation Glossary

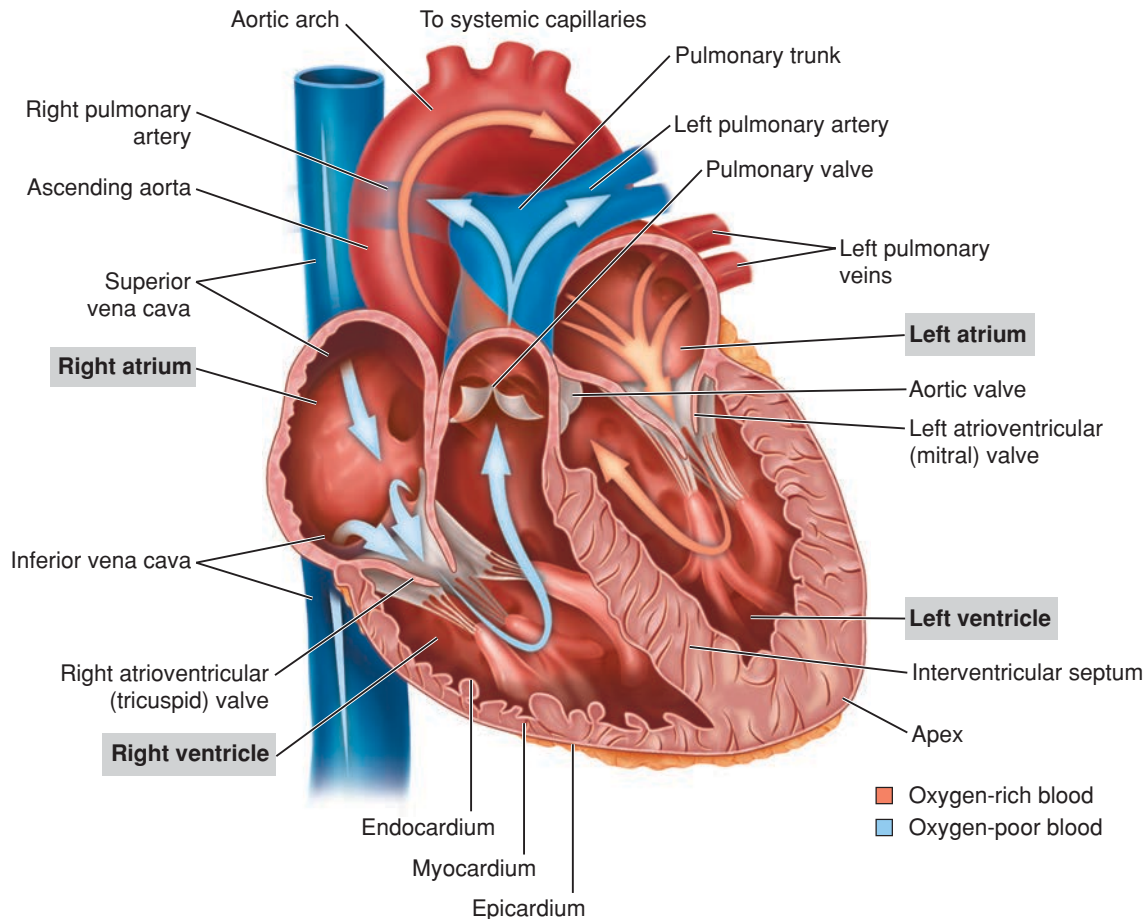
## Introduction

Blood circulates throughout the body in the **cardiovascular system**, which consists of the **heart** and the **blood vessels** (FIG. 10-1). This system forms a continuous circuit that delivers oxygen and nutrients to all cells and carries away waste products. The lymphatic system also functions in

circulation. Its vessels drain fluid and proteins left in the tissues and return them to the bloodstream. The lymphatic system plays a part in immunity and in the digestive process as well, as explained in Chapters 11 and 13. This chapter discusses the circulatory system in detail, in both its normal and clinical aspects, and then proceeds to study the lymphatic system.



**FIGURE 10-1** The cardiovascular system. The pulmonary circuit carries blood to and from the lungs; the systemic circuit carries blood to and from all other parts of the body.



**FIGURE 10-2 The heart and great vessels.** The arrows show the direction of blood flow through the heart. The right heart has blood low in oxygen; the left heart has blood high in oxygen.

## The Heart

The heart is located between the lungs, with its point, or **apex**, directed toward the inferior and left (FIG. 10-2). The wall of the heart consists of three layers, all named with the root *cardi*, meaning “heart.” Moving from the innermost to the outermost layer, these are the:

1. **Endocardium**—a thin membrane that lines the chambers and valves (the prefix *endo-* means “within”).
2. **Myocardium**—a thick muscle layer that makes up most of the heart wall (the root *my/o* means “muscle”).
3. **Epicardium**—a thin membrane that covers the heart (the prefix *epi-* means “on”).

A fibrous sac, the **pericardium**, contains the heart and anchors it to surrounding structures, such as the sternum (breastbone) and diaphragm (the prefix *peri-* means “around”).

Each of the heart’s upper receiving chambers is an **atrium** (plural: atria). Each of the lower pumping chambers is a **ventricle** (plural: ventricles). The chambers of the heart are divided by walls, each of which is called a **septum**. The interventricular septum separates the two ventricles; the interatrial septum divides the two atria. There

is also a septum between the atrium and ventricle on each side.

The heart pumps blood through two circuits. The right side pumps blood to the lungs to be oxygenated through the **pulmonary circuit**. The left side pumps to the remainder of the body through the **systemic circuit** (see FIG. 10-1).

### BLOOD FLOW THROUGH THE HEART

The pathway of blood through the heart is shown by the arrows in FIGURE 10-2. The sequence is as follows.

1. The right atrium receives blood low in oxygen from all body tissues through the **superior vena cava** and the **inferior vena cava**.
2. The blood then enters the right ventricle and is pumped to the lungs through the **pulmonary artery**.
3. Blood returns from the lungs high in oxygen and enters the left atrium through the **pulmonary veins**.
4. Blood enters the left ventricle and is forcefully pumped into the **aorta** to be distributed to all tissues.

One-way **valves** in the heart keep blood moving in a forward direction. The valves between the atrium and ventricle on each side are the **atrioventricular (AV) valves** (see FIG. 10-2).



The valve between the right atrium and ventricle is the **right AV valve**, also known as the tricuspid valve because it has three cusps (flaps). The valve between the left atrium and ventricle is the **left AV valve**, which is a bicuspid valve with two cusps; it is often called the **mitral valve** (named for a miter, the pointed, two-sided hat worn by bishops).

The valves leading into the pulmonary artery and the aorta have three cusps. Each cusp is shaped like a half-moon, so these valves are described as *semilunar valves* (*lunar* refers to the moon). The valve at the entrance to the pulmonary artery is specifically named the **pulmonary valve**; the valve at the entrance to the aorta is the **aortic valve**.

**Heart sounds** are produced as the heart functions. The loudest of these, the familiar “lub” and “dup” that can be heard through the chest wall, are produced by alternate closings of the valves. The first heart sound ( $S_1$ ) is heard when the valves between the chambers close. The second heart sound ( $S_2$ ) is produced when the valves leading into the aorta and pulmonary artery close. Any sound made as the heart functions normally is termed a **functional murmur**. (The word *murmur* used alone with regard to the heart describes an abnormal sound.)

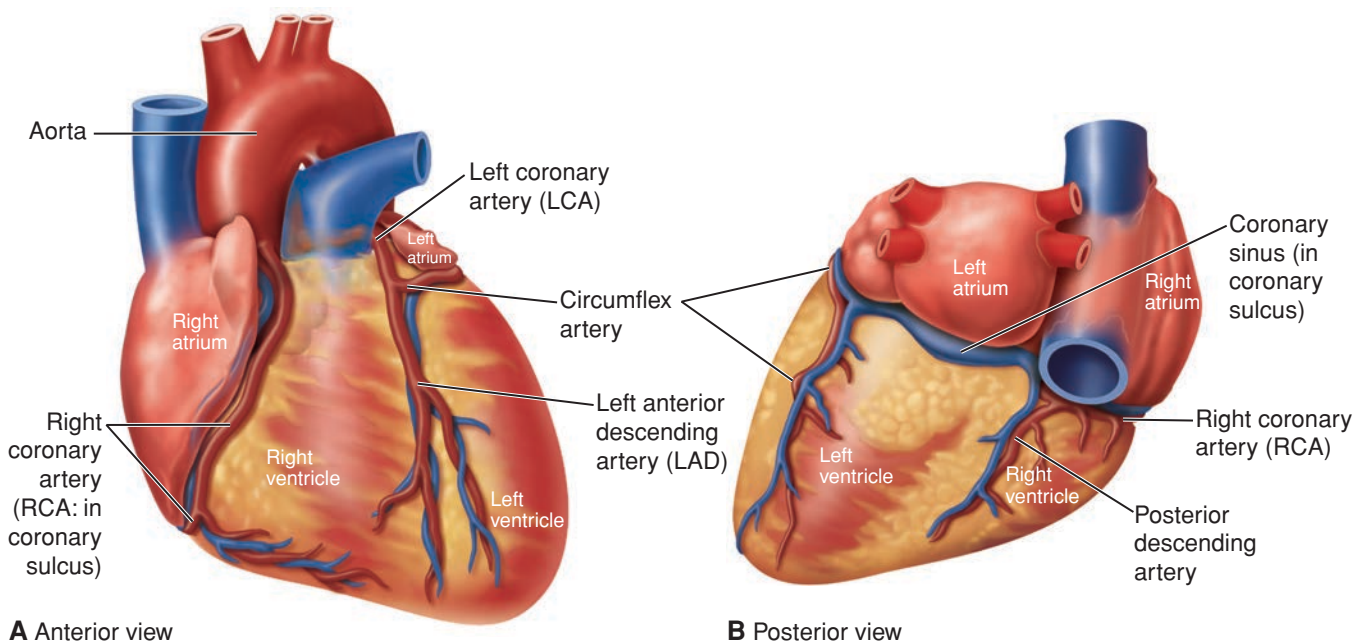
## BLOOD SUPPLY TO THE MYOCARDIUM

Only the endocardium comes into contact with the blood that flows through the heart chambers. Therefore, the myocardium must have its own blood vessels to provide

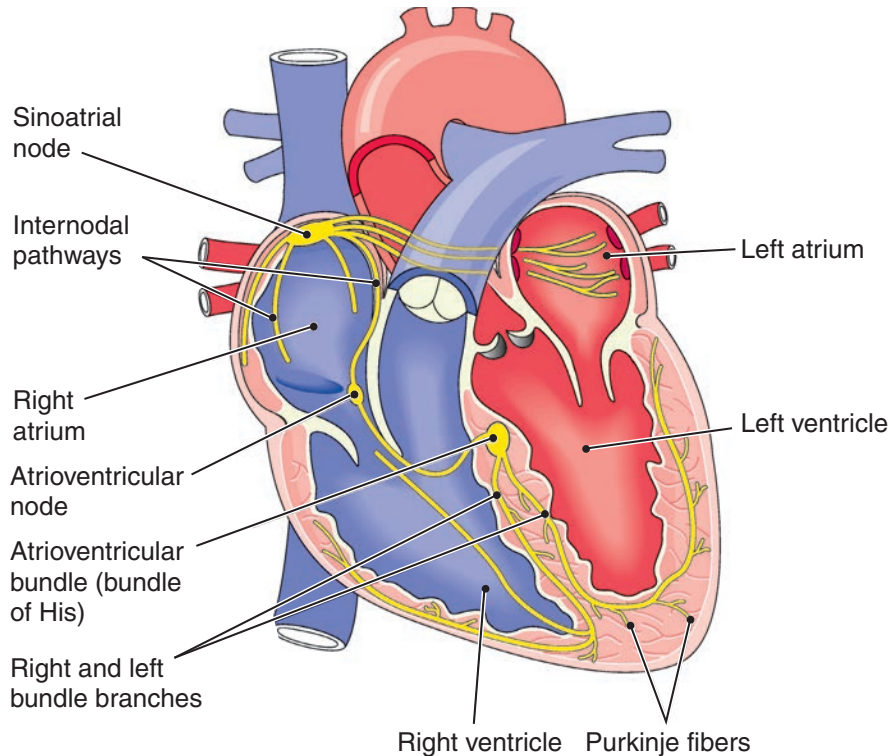
oxygen and nourishment and to remove waste products. Together, these blood vessels form the **coronary circulation**. The main arteries that supply blood to the heart muscle are the right and left coronary arteries (**FIG. 10-3**), named because they encircle the heart like a crown. These arteries, which are the first to branch off the aorta, arise just above the cusps of the aortic valve and branch to all regions of the heart muscle. They receive blood only when the ventricles relax because the aortic valve must be closed to expose the entrance to these vessels. The left coronary artery (LCA) branches into the circumflex artery and the left anterior descending (LAD) artery (also known as the anterior interventricular branch of the LCA). The right coronary artery (RCA) snakes around the heart just inferior to the right atrium, giving off a major branch called the posterior descending artery (also known as the posterior interventricular artery). After passing through the capillaries in the myocardium, blood drains into a system of cardiac veins that brings blood back toward the right atrium. Blood finally collects in the coronary sinus, a dilated vein that opens into the right atrium near the inferior vena cava.

## THE HEARTBEAT

Each contraction of the heart, termed **systole** (*SIS-to-le*), is followed by a relaxation phase, **diastole** (*di-AS-to-le*), during which the chambers fill. Each time the heart beats,



**FIGURE 10-3** Blood vessels that supply the myocardium. Coronary arteries and cardiac veins constitute the heart’s circulatory pathways. **A.** Anterior view. **B.** Posterior view.



**FIGURE 10-4 The heart's electrical conduction system.** Impulses travel from the sinoatrial (SA) node to the atrioventricular (AV) node, then to the atrioventricular bundle, bundle branches, and Purkinje fibers. Internodal pathways carry impulses throughout the atria.

both atria contract, and immediately thereafter both ventricles contract. The number of times the heart contracts per minute is the **heart rate**. The wave of increased pressure produced in the vessels each time the ventricles contract is the **pulse**. Pulse rate is usually counted by palpating a peripheral artery, such as the radial artery at the wrist or the carotid artery in the neck (see **FIG. 3-9**).

Cardiac contractions are stimulated by a built-in system that regularly transmits electrical impulses through the heart. The components of this conduction system are shown in **FIGURE 10-4**. In the sequence of action, they include the:

1. **Sinoatrial (SA) node**, located in the upper right atrium and called the *pacemaker* because it sets the rate of the heartbeat.
2. **Atrioventricular (AV) node**, located at the bottom of the right atrium near the ventricle. Internodal fibers between the SA and AV nodes carry stimulation throughout both atria.
3. **AV bundle** (bundle of His) at the top of the interventricular septum.
4. **Left and right bundle branches**, which travel along the left and right sides of the septum.
5. **Purkinje** (*pur-KIN-je*) **fibers**, which carry stimulation throughout the walls of the ventricles (see information on naming in **BOX 10-1**).

Although the heart itself generates the heartbeat, factors such as nervous system stimulation, hormones, and drugs can influence the rate and the force of contractions.

## ELECTROCARDIOGRAPHY

**Electrocardiography (ECG)** measures the heart's electrical activity as it functions (**FIG. 10-5**). Electrodes (leads) placed on the body's surface detect the electrical signals, which are then amplified and recorded as a tracing. A normal, or **sinus rhythm**, which originates at the SA node, is shown in **FIGURE 10-5A**. **FIGURE 10-5B** shows the letters assigned to individual components of one complete cycle:

1. The P wave represents electrical change, or **depolarization**, of the atrial muscles.
2. The QRS component shows depolarization of the ventricles.
3. The T wave shows return, or **repolarization**, of the ventricles to their resting state. Atrial repolarization is hidden by the QRS wave.
4. The small U wave, if present, follows the T wave. It is of uncertain origin.

An *interval* measures the distance from one wave to the next; a *segment* is a smaller component of the tracing. Many heart disorders, some of which are described later in the chapter, appear as abnormalities in ECG components.



## FOCUS ON WORDS

### Name That Structure

BOX 10-1

An eponym (*EP-o-nim*) is a name that is based on the name of a person, usually the one who discovered a particular structure, disease, principle, or procedure. Everyday examples are graham cracker, Ferris wheel, and boycott. In the heart, the bundle of His and Purkinje fibers are part of that organ's electrical conduction system. Korotkoff sounds are heard in the vessels when taking blood pressure. Cardiovascular disorders named for people include the tetralogy of Fallot, a combination of four congenital heart defects; Raynaud disease of small vessels; and the cardiac arrhythmia known as Wolff–Parkinson–White syndrome. In treatment, Doppler echocardiography is named for a physicist of the 19th century. The Holter monitor and the Swan–Ganz catheter give honors to their developers.

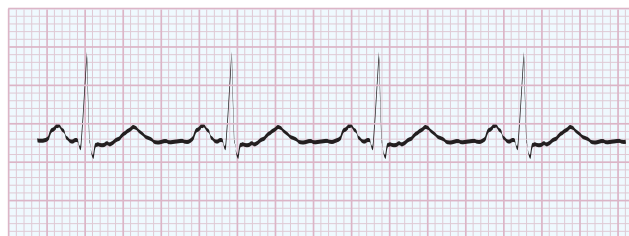In other systems, the islets of Langerhans are cell clusters in the pancreas that secrete insulin. The graafian follicle in the ovary surrounds a mature egg cell. The eustachian tube connects the middle ear to the throat.

Many disease names are eponymic: Parkinson and Alzheimer, which affect the brain; Graves, a disorder of the

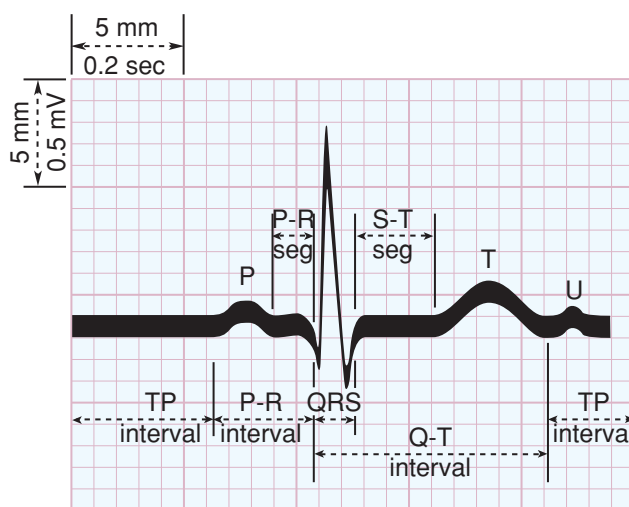
thyroid; Addison and Cushing, involving the adrenal cortex; and Down syndrome, a hereditary disorder. The genus and species names of microorganisms often are based on the names of their discoverers: *Escherichia*, *Salmonella*, *Pasteurella*, and *Rickettsia* to name a few.

Many reagents, instruments, and procedures are named for their developers too. The original name for a radiograph was roentgenograph (*RENT-jen-o-graf*), named for Wilhelm Roentgen, discoverer of x-rays. A curie is a measure of radiation, derived from the name of Marie Curie, a co-discoverer of radioactivity.

Although eponyms give honor to physicians and scientists of the past, they do not convey any information and may be more difficult to learn. There is a trend to replace these names with more descriptive ones; for example, auditory tube instead of eustachian tube, mature ovarian follicle for graafian follicle, pancreatic islets for islets of Langerhans, and trisomy 21 for Down syndrome.



A



B

**FIGURE 10-5 Electrocardiography (ECG).** **A.** ECG tracing showing a normal sinus rhythm. **B.** Components of a normal ECG tracing. Shown are the P, QRS, T, and U waves, which represent electrical activity in different parts of the heart. Intervals measure from one wave to the next; segments are smaller components of the tracing.

## The Vascular System

The vascular system consists of:

1. **Arteries** that carry blood away from the heart (FIG. 10-6)
2. **Arterioles**, vessels smaller than arteries that lead into the capillaries
3. **Capillaries**, the smallest vessels, through which exchanges take place between the blood and the tissues
4. **Venules**, small vessels that receive blood from the capillaries and drain into the veins
5. **Veins** that carry blood back to the heart (FIG. 10-7)

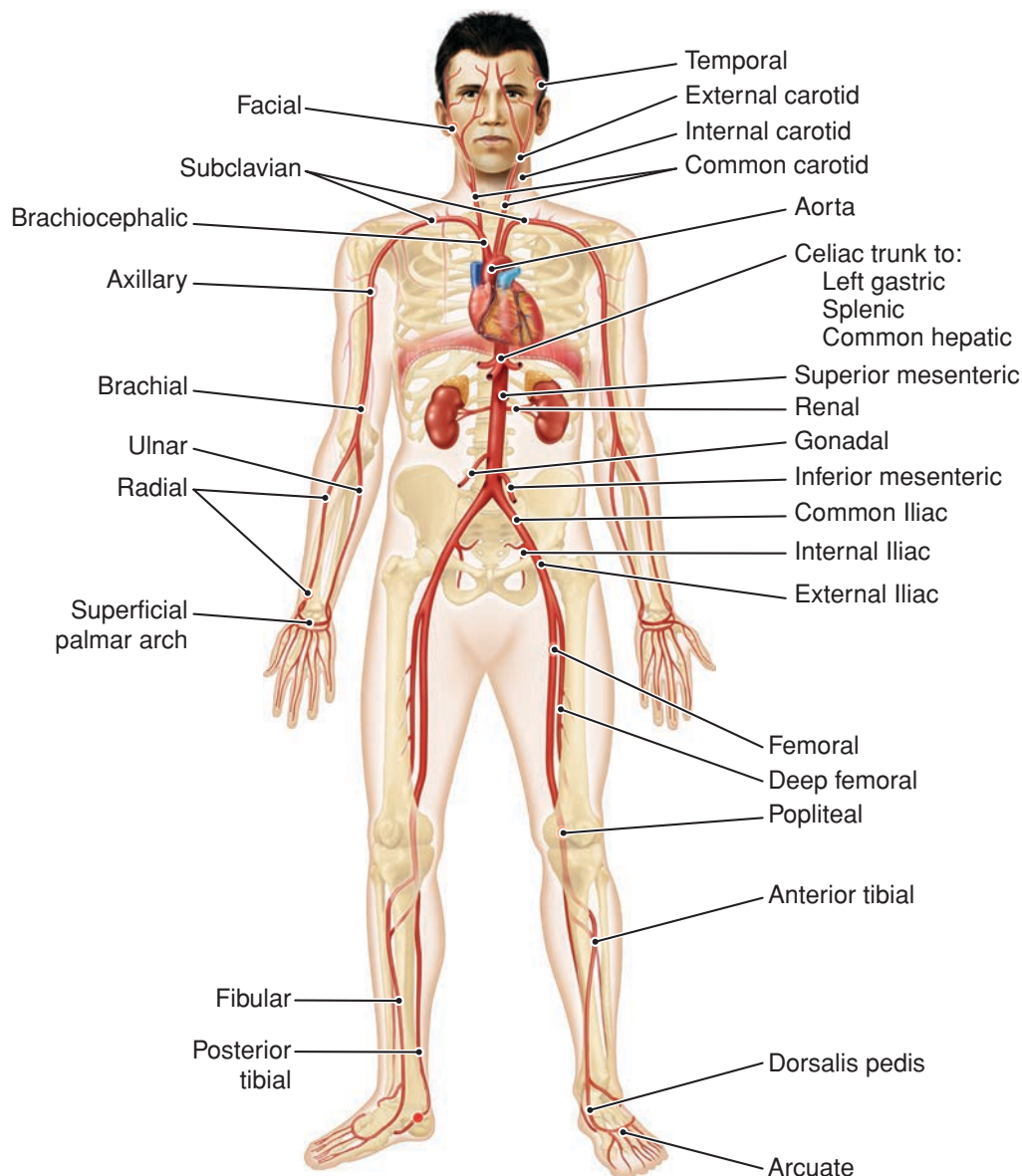
All arteries, except the pulmonary artery (and the umbilical artery in the fetus), carry highly oxygenated blood. They are thick-walled, elastic vessels that carry blood

under high pressure. All veins, except the pulmonary vein (and the umbilical vein in the fetus), carry blood low in oxygen. Veins have thinner, less elastic walls and tend to give way under pressure. Like the heart, veins have one-way valves that keep blood flowing forward. Veins are classified as superficial or deep. The deep veins usually parallel arteries and carry the same names (see FIG. 10-7).

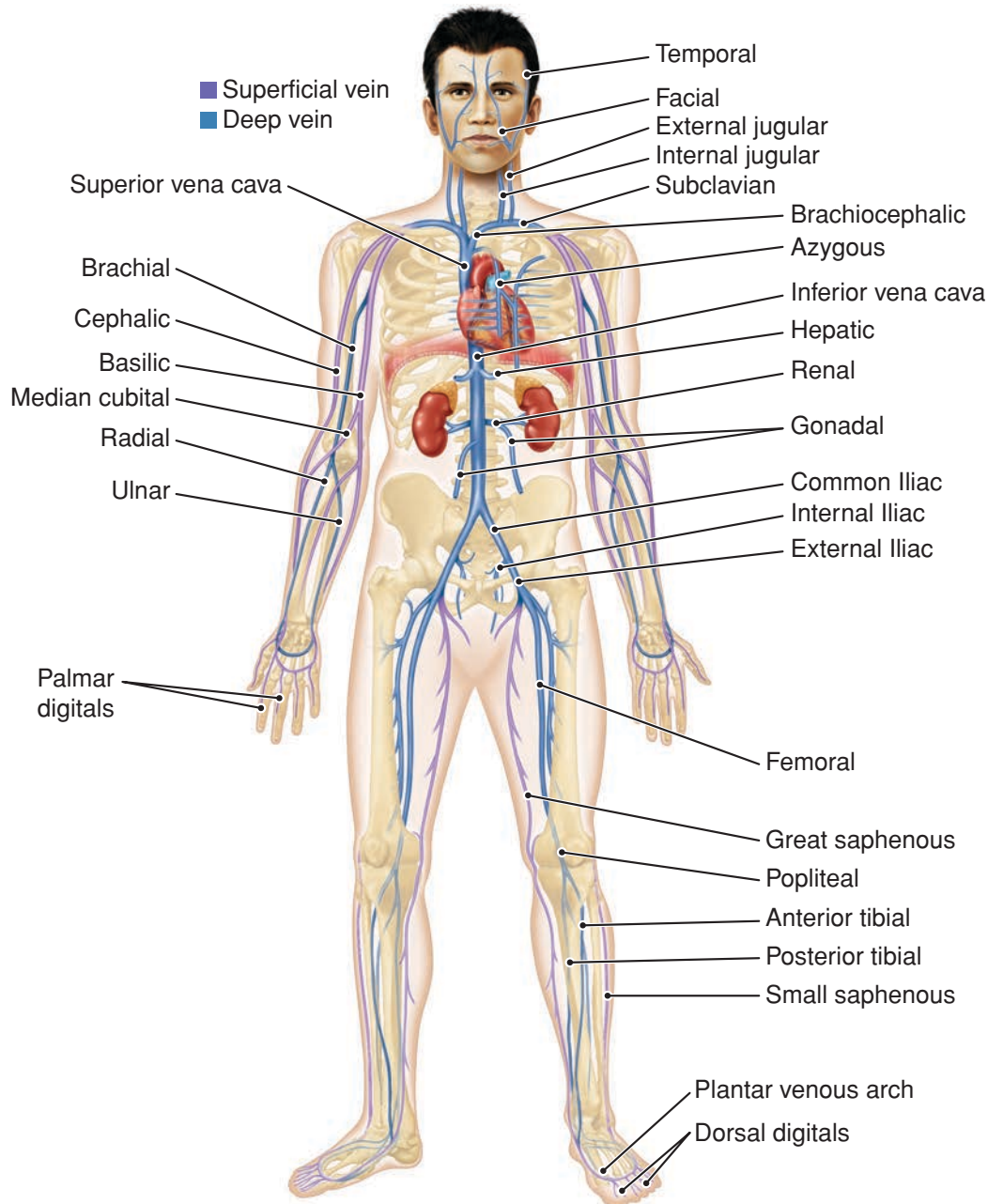
Nervous system stimulation can cause the diameter of a vessel to increase (vasodilation) or decrease (vasoconstriction). These changes alter blood flow to the tissues and affect blood pressure.

## BLOOD PRESSURE

**Blood pressure (BP)** is the force exerted by blood against the wall of a blood vessel. It falls as the blood travels away from the heart and is influenced by a variety of factors,



**FIGURE 10-6** Principal systemic arteries.



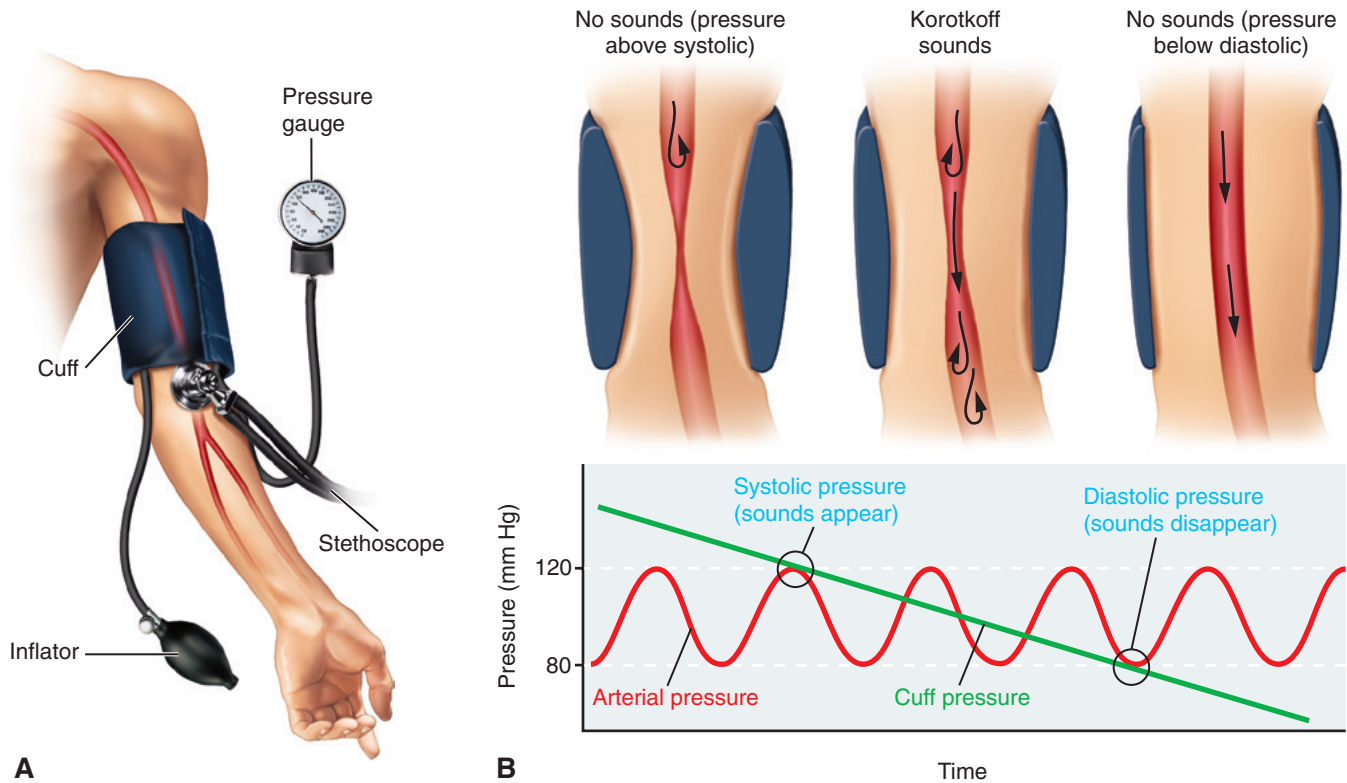
**FIGURE 10-7** Principal systemic veins.

including cardiac output, vessel diameters, and total blood volume. Vasoconstriction increases BP in a vessel; vasodilation decreases pressure.

The most common site for BP measurement is the brachial artery of the arm. In taking blood pressure, both systolic (heart contracts) and diastolic (heart relaxes) pressures are measured.

The instrument used to measure blood pressure is a **sphygmomanometer** (*sfig-mo-mab-NOM-eh-ter*) (FIG. 10-8), more simply called a blood pressure cuff or blood pressure apparatus. The sphygmomanometer is an inflatable cuff attached to a pressure gauge. Pressure is expressed in

millimeters mercury (mm Hg), that is, the height to which the pressure can push a column of mercury in a tube. The examiner wraps the cuff around the patient's upper arm and inflates it with air until the brachial artery is compressed and the blood flow is cut off. Then, listening with a stethoscope, he or she slowly lets air out of the cuff until the first pulsations (Korotkoff sounds) are heard. At this point, the pressure in the cuff is equal to the systolic pressure, and this pressure is read. Then, more air is let out gradually until a characteristic muffled sound indicates that the vessel is open and the diastolic pressure is read off of a gauge or digital display. Newer devices measure blood pressure electronically:



**FIGURE 10-8 Measurement of blood pressure.** **A.** A sphygmomanometer, or blood pressure cuff set to measure pressure in the left brachial artery. **B.** As the clinician lowers the cuff pressure, Korotkoff sounds begin at the systolic pressure and disappear at the diastolic pressure.

the examiner simply applies the cuff, which self-inflates and provides a digital reading. A typical normal systolic pressure is less than 120 mm Hg; a typical normal diastolic pressure is less than 80 mm Hg. Blood pressure is reported as systolic

pressure first, then diastolic pressure, separated by a slash, such as 120/80. This reading would be reported verbally as “120 over 80.” (See **BOX 10-2** for more information on blood pressure measurement.)



## CLINICAL PERSPECTIVES

### Hemodynamic Monitoring: Measuring Blood Pressure From Within

BOX 10-2

Because arterial blood pressure decreases as blood flows farther away from the heart, measurement of blood pressure with a simple inflatable cuff around the arm is only a reflection of the pressure in the heart and pulmonary arteries. Precise measurement of pressure in these parts of the cardiovascular system is useful in diagnosing certain cardiac and pulmonary disorders.

More accurate readings can be obtained using a catheter (thin tube) inserted directly into the heart and large vessels. One type commonly used is the pulmonary artery catheter (also known as the Swan-Ganz catheter), which has an inflatable balloon at the tip. This device is threaded into the right side of the heart through a large vein. Typically, the right internal jugular vein is used because it is the shortest and most

direct route to the heart, but the subclavian and femoral veins may also be used. The catheter's position in the heart is confirmed by a chest x-ray, and when appropriately positioned, the atrial and ventricular blood pressures are recorded. As the catheter continues into the pulmonary artery, pressure in this vessel is readable. When the balloon is inflated, the catheter becomes wedged in a branch of the pulmonary artery, blocking blood flow. The reading obtained is called the pulmonary capillary wedge pressure (PCWP). It gives information on pressure in the heart's left side and on resistance in the lungs. Combined with other tests, hemodynamic monitoring with a Swan-Ganz catheter can be used to diagnose cardiac and pulmonary disorders such as shock, pericarditis, congenital heart disease, and heart failure.

## Terminology

## Key Terms

The terms listed below are emphasized in this chapter. Knowing them will help you organize and prioritize your learning. These boldface terms are also found, collectively, with all chapter key terms in the Glossary.

## Cardiovascular System

## Normal Structure and Function

<b>aorta</b> <i>a-OR-tab</i>	The largest artery; it receives blood from the left ventricle and branches to all parts of the body (root: aort/o)
<b>aortic valve</b> <i>a-OR-tik</i>	The valve at the entrance to the aorta
<b>apex</b> <i>A-peks</i>	The point of a cone-shaped structure (adjective: apical); the apex of the heart is formed by the left ventricle and is pointed toward the inferior and left
<b>artery</b> <i>AR-teh-re</i>	A vessel that carries blood away from the heart; all except the pulmonary and umbilical arteries carry oxygenated blood (roots: arter, arteri/o)
<b>arteriole</b> <i>ar-TE-re-ole</i>	A small vessel that carries blood from the arteries into the capillaries (root: arteriol/o)
<b>atrioventricular (AV) node</b> <i>a-tre-o-ven-TRIK-u-lar</i>	A small mass in the lower septum of the right atrium that passes impulses from the sinoatrial (SA) node toward the ventricles
<b>atrioventricular (AV) valve</b>	A valve between the atrium and ventricle on the right and left sides of the heart; the right AV valve is the tricuspid valve; the left is the mitral valve
<b>atrium</b> <i>A-tre-um</i>	An entrance chamber, one of the two upper receiving chambers of the heart (root: atri/o)
<b>AV bundle</b>	A band of fibers that transmits impulses from the atrioventricular (AV) node to the top of the interventricular septum; it divides into the right and left bundle branches, which descend along the two sides of the septum; the bundle of His
<b>blood pressure</b>	The force exerted by blood against the wall of a vessel
<b>bundle branches</b>	Branches of the AV bundle that divide to the right and left sides of the interventricular septum
<b>capillary</b> <i>KAP-ih-lar-e</i>	A microscopic blood vessel through which materials are exchanged between the blood and the tissues
<b>cardiovascular system</b> <i>kar-de-o-VAS-ku-lar</i>	The part of the circulatory system that consists of the heart and the blood vessels
<b>coronary circulation</b> <i>KOR-o-na-re</i>	The blood vessels in the heart that provide oxygen and nourishment and remove waste products from the myocardium
<b>depolarization</b> <i>de-po-lar-ih-ZA-shun</i>	A change in electrical charge from the resting state in nerves or muscles
<b>diastole</b> <i>di-AS-to-le</i>	The relaxation phase of the heartbeat cycle (adjective: diastolic)
<b>electrocardiography (ECG)</b> <i>e-lek-tro-kar-de-OG-rab-fe</i>	Study of the electrical activity of the heart as detected by electrodes (leads) placed on the surface of the body; also abbreviated EKG from the German electrocardiography
<b>endocardium</b> <i>en-do-KAR-de-um</i>	The thin membrane that lines the chambers of the heart and covers the valves
<b>epicardium</b> <i>ep-ih-KAR-de-um</i>	The thin outermost layer of the heart wall
<b>functional murmur</b>	Any sound produced as the heart functions normally
<b>heart</b> <i>hart</i>	The muscular organ with four chambers that contracts rhythmically to propel blood through vessels to all parts of the body (root: cardi/o)

## Terminology

## Key Terms (Continued)

<b>heart rate</b>	The number of times the heart contracts per minute; recorded as beats per minute (bpm)
<b>heart sounds</b>	Sounds produced as the heart functions: the two loudest sounds are produced by alternate closing of the valves and are designated S <sub>1</sub> and S <sub>2</sub>
<b>inferior vena cava</b> <i>VE-nah KA-vah</i>	The large inferior vein that brings blood low in oxygen back to the right atrium of the heart from the lower body
<b>left AV valve</b>	The valve between the left atrium and the left ventricle; the mitral valve or bicuspid valve
<b>mitral valve</b> <i>MI-tral</i>	The valve between the left atrium and the left ventricle; the left AV valve or bicuspid valve
<b>myocardium</b> <i>mi-o-KAR-de-um</i>	The thick middle layer of the heart wall composed of cardiac muscle
<b>pericardium</b> <i>per-ih-KAR-de-um</i>	The fibrous sac that surrounds the heart
<b>pulmonary artery</b> <i>PUL-mo-nar-e</i>	The vessel that carries blood from the right side of the heart to the lungs
<b>pulmonary circuit</b> <i>SER-kit</i>	The system of vessels that carries blood from the right side of the heart to the lungs to be oxygenated and then back to the left side of the heart
<b>pulmonary veins</b>	The vessels that carry blood from the lungs to the left side of the heart
<b>pulmonary valve</b>	The valve at the entrance to the pulmonary artery
<b>pulse</b> <i>puls</i>	The wave of increased pressure produced in the vessels each time the ventricles contract
<b>Purkinje fibers</b> <i>pur-KIN-je</i>	The terminal fibers of the cardiac conducting system; they carry impulses through the walls of the ventricles
<b>repolarization</b> <i>re-po-lar-ih-ZA-shun</i>	A return of electrical charge to the resting state in nerves or muscles
<b>right AV valve</b>	The valve between the right atrium and right ventricle; the tricuspid valve
<b>septum</b> <i>SEP-tum</i>	A wall dividing two cavities, such as two chambers of the heart
<b>sinus rhythm</b> <i>SI-nus RITH-um</i>	Normal heart rhythm
<b>sinoatrial (SA) node</b> <i>si-no-A-tre-al</i>	A small mass in the upper part of the right atrium that initiates the impulse for each heartbeat; the pacemaker
<b>sphygmomanometer</b> <i>sfig-mo-mah NOM-eh-ter</i>	An instrument for determining arterial blood pressure (root sphygm/o means “pulse”); blood pressure apparatus or cuff
<b>superior vena cava</b> <i>VE-nah KA-vah</i>	The large superior vein that brings blood low in oxygen back to the right atrium from the upper body
<b>systemic circuit</b> <i>sis-TEM-ik SER-kit</i>	The system of vessels that carries oxygenated blood from the left side of the heart to all tissues except the lungs and returns deoxygenated blood to the right side of the heart
<b>systole</b> <i>SIS-to-le</i>	The contraction phase of the heartbeat cycle (adjective: systolic)
<b>valve</b> <i>valv</i>	A structure that keeps fluid flowing in a forward direction (roots: valv/o, valvul/o)
<b>vein</b> <i>vane</i>	A vessel that carries blood back to the heart. All except the pulmonary and umbilical veins carry blood low in oxygen (roots: ven/o, phleb/o)

(continued)



## Terminology

## Key Terms (Continued)

<b>ventricle</b> <i>VEN-trik-l</i>	A small cavity. One of the two lower pumping chambers of the heart (root: ventricul/o)
<b>venule</b> <i>VEN-ule</i>	A small vessel that carries blood from the capillaries to the veins
<b>vessel</b> <i>VES-el</i>	A tube or duct to transport fluid (roots: angi/o, vas/o, vascul/o)

## Roots Pertaining to the Cardiovascular System

See TABLES 10-1 and 10-2.

Table 10-1

### Roots for the Heart

Root	Meaning	Example	Definition of Example
cardi/o	heart	cardiomyopathy <sup>a</sup> <i>kar-de-o-mi-OP-ab-the</i>	any disease of the heart muscle
atri/o	atrium	atriotomy <i>a-tre-OT-o-me</i>	surgical incision of an atrium
ventricul/o	cavity, ventricle	supraventricular <i>su-prab-ven-TRIK-u-lar</i>	above a ventricle
valv/o, valvul/o	valve	valvulotome <i>VAL-vu-lo-tome</i>	instrument for incising a valve

<sup>a</sup>Preferred over myocardopathy.

## Exercise

### 10-1

Complete the exercise. To check your answers go to Appendix 11.

Fill in the blanks.

1. A valvuloplasty (*val-vu-lo-PLAS-te*) is plastic repair of a(n) \_\_\_\_\_ .
2. Atriotomy (*a-tre-OT-to-me*) means surgical incision of a(n) \_\_\_\_\_ .
3. Interventricular (*in-ter-ven-TRIK-u-lar*) means between the \_\_\_\_\_ .
4. The word *cardiomegaly* (*kar-de-o-MEG-ab-le*) means enlargement of the \_\_\_\_\_ .

Write the adjective for the following definitions. The proper suffix is given for each.

5. Pertaining to an atrium (-al) \_\_\_\_\_
6. Pertaining to the myocardium (-al; ending differs from adjective ending for the heart) \_\_\_\_\_
7. Pertaining to the heart (-ac) \_\_\_\_\_
8. Pertaining to a valve (-ar) \_\_\_\_\_
9. Pertaining to a ventricle (-ar) \_\_\_\_\_
10. Pertaining to the pericardium (-al) \_\_\_\_\_

## Exercise 10-1 (Continued)

Following the example, write a word for the following definitions pertaining to the tissues of the heart.

11. Inflammation of the fibrous sac around the heart \_\_\_\_\_
12. Inflammation of the heart's lining (usually at a valve) \_\_\_\_\_
13. Inflammation of the heart muscle \_\_\_\_\_

Write a word for the following definitions.

14. Originating (-genic) in the heart \_\_\_\_\_
15. Surgical incision of a valve \_\_\_\_\_
16. Pertaining to an atrium and a ventricle \_\_\_\_\_
17. Between (inter-) the atria \_\_\_\_\_
18. Study (-logy) of the heart \_\_\_\_\_

Table 10-2 Roots for the Blood Vessels

Root	Meaning	Example	Definition of Example
angi/o <sup>a</sup>	vessel	angiography <i>an-je-OG-rab-fe</i>	x-ray imaging of a vessel
vas/o, vascul/o	vessel, duct	vasospasm <i>VA-so-spazm</i>	sudden contraction of a vessel
arter/o, arteri/o	artery	endarterial <i>end-ar-TE-re-al</i>	within an artery
arteriol/o	arteriole	arteriolar <i>ar-te-re-O-lar</i>	pertaining to an arteriole
aort/o	aorta	aortoptosis <i>a-or-top-TO-sis</i>	downward displacement of the aorta
ven/o, ven/i	vein	venous <i>VE-nus</i>	pertaining to a vein
phleb/o	vein	phlebotomy <i>fleh-BOT-o-me</i>	incision of a vein to withdraw blood

<sup>a</sup>The root *angi/o* usually refers to a blood vessel but is used for other types of vessels as well. *Hemangi/o* refers specifically to a blood vessel.

## Exercise 10-2

Complete the exercise. To check your answers go to Appendix 11.

Fill in the blanks.

1. Angioedema (*an-je-o-eh-DE-mah*) is localized swelling caused by changes in \_\_\_\_\_ .
2. Vasodilation (*vas-o-DI-la-shun*) means dilation of a(n) \_\_\_\_\_ .
3. Aortostenosis (*a-or-to-steh-NO-sis*) is narrowing of \_\_\_\_\_ .
4. Endarterectomy (*end-ar-ter-EK-to-me*) is removal of the inner lining of a(n) \_\_\_\_\_ .
5. Arteriolitis (*ar-te-re-o-LI-tis*) is inflammation of a(n) \_\_\_\_\_ .
6. Phlebectasia (*fleh-ek-TA-ze-ah*) is dilatation of a(n) \_\_\_\_\_ .
7. The term *microvascular* (*mi-kro-VAS-ku-lar*) means pertaining to small \_\_\_\_\_ .

(continued)

## Exercise 10-2 (Continued)

Define the following words.

8. arteriorrhexis (*ar-te-re-o-REK-sis*) \_\_\_\_\_
9. intraaortic (*in-trah-a-OR-tik*) \_\_\_\_\_
10. angiitis (*an-je-I-tis*) (note spelling); also angitis or vasculitis \_\_\_\_\_
11. phlebitis (*fleb-I-tis*) \_\_\_\_\_
12. cardiovascular (*kar-de-o-VAS-ku-lar*) \_\_\_\_\_

Use the ending *-gram* to form a word for a radiograph of the following.

13. vessels (use *angi/o*) \_\_\_\_\_
14. aorta \_\_\_\_\_
15. veins \_\_\_\_\_

Use the root *angi/o* to write words with the following meanings.

16. Plastic repair (*-plasty*) of a vessel \_\_\_\_\_
17. Any disease (*-pathy*) of a vessel \_\_\_\_\_
18. Dilatation (*-ectasis*) of a vessel \_\_\_\_\_
19. Formation (*-genesis*) of a vessel \_\_\_\_\_

Use the appropriate root to write words with the following meanings.

20. Excision of a vein \_\_\_\_\_
21. Hardening (*-sclerosis*) of the aorta \_\_\_\_\_
22. Within (*intra-*) a vein \_\_\_\_\_
23. Incision of an artery \_\_\_\_\_

## Clinical Aspects of the Cardiovascular System

### ATHEROSCLEROSIS

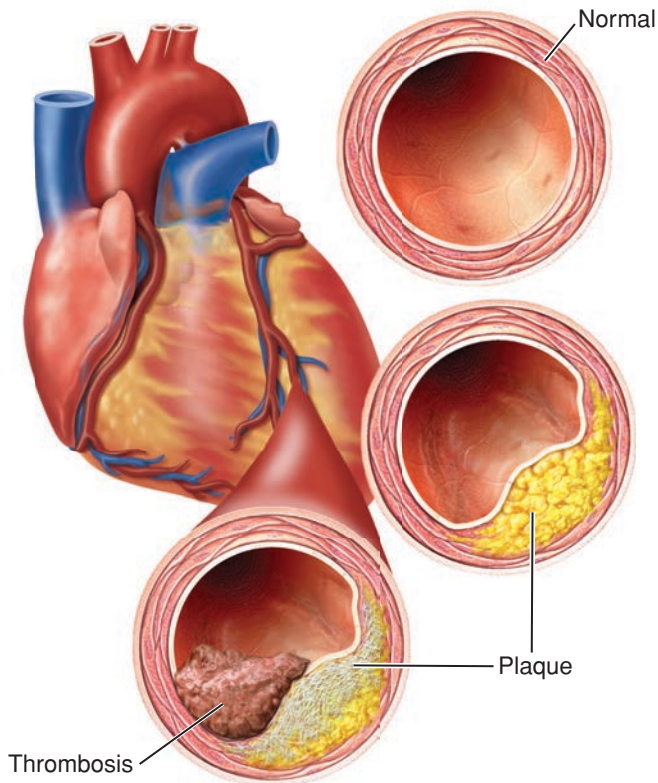
The accumulation of fatty deposits within the lining of an artery is termed **atherosclerosis** (FIG. 10-9). This type of deposit, called **plaque** (*plak*), begins to form when a vessel receives tiny injuries, usually at a point of branching. Plaques gradually thicken and harden with fibrous material, cells, and other deposits, restricting the vessel's lumen (opening) and reducing blood flow to the tissues, a condition known as **ischemia** (*is-KE-me-ah*). A major risk factor for the development of atherosclerosis is **dyslipidemia**, abnormally high levels or imbalance in **lipoproteins** that are carried in the blood, especially high levels of cholesterol-containing, low-density lipoproteins (LDLs). Other risk factors for atherosclerosis include smoking, high blood pressure, poor diet, inactivity, stress, and a family history of the disorder. Atherosclerosis may involve any arteries,

but most of its effects are seen in the coronary vessels of the heart, the aorta, the carotid arteries in the neck, and vessels in the brain. The techniques described later for treating coronary artery disease (CAD) are used for these other vessels as well.

Atherosclerosis is the most common form of a more general condition known as **arteriosclerosis** in which vessel walls harden from any cause. In addition to plaque, calcium salts and scar tissue may contribute to arterial wall thickening, with a narrowing of the lumen and loss of elasticity.

### THROMBOSIS AND EMBOLISM

Atherosclerosis predisposes a person to **thrombosis**, the formation of a blood clot within a vessel (see FIG. 10-9). The clot, called a **thrombus**, interrupts blood flow to the tissues supplied by that vessel, resulting in necrosis (tissue death). Blockage of a vessel by a thrombus or other mass carried in the bloodstream is **embolism**, and the mass



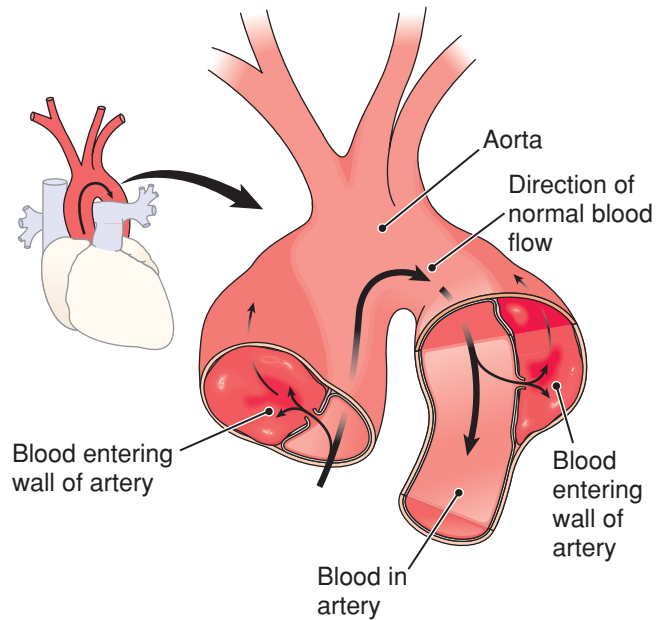
**FIGURE 10-9 Coronary atherosclerosis.** In this example, a branch of the left coronary artery is shown in cross-section during three stages of atherosclerosis: no plaque present (**top**), a well-formed plaque blocking 30% of the vessel lumen (**middle**), and formation of a thrombus (blood clot) (**bottom**).

itself is called an **embolus**. Usually, the mass is a blood clot that breaks loose from a vessel's wall, but it may also be air (as from injection or trauma), fat (as from marrow released after a bone break), bacteria, or other solid materials. Often a venous thrombus will travel through the heart and then lodge in an artery of the lungs, resulting in a life-threatening pulmonary embolism. An embolus from a carotid artery often blocks a cerebral vessel, causing a **cerebrovascular accident (CVA)**, commonly called **stroke** (Chapter 7).

The use of anticoagulant drugs (“blood thinners”) when appropriate has greatly reduced the incidence of these conditions. These drugs include heparin, which inhibits thrombin formation; warfarin (Coumadin), which inhibits formation of vitamin K; and newer oral anticoagulants that interfere with thrombin formation and do not require regular tests of blood levels, as does Coumadin.

## ANEURYSM

An arterial wall weakened by atherosclerosis, malformation, injury, or other changes may balloon out, forming an **aneurysm**. If an aneurysm ruptures, hemorrhage results. Rupture of a cerebral artery is another cause of stroke. The abdominal aorta and carotid arteries are also common



**FIGURE 10-10 Dissecting aortic aneurysm.** Blood separates the layers of the arterial wall.

aneurysm sites. In a **dissecting aneurysm** (FIG. 10-10), blood hemorrhages into the arterial wall's thick middle layer, separating the muscle as it spreads and sometimes rupturing the vessel. The aorta is most commonly involved. Surgeons can replace the damaged arterial segment of a dissecting aneurysm surgically with a graft. In many cases they can insert a stent (small tube) to seal off the aneurysm and carry blood through the expanded portion of the vessel.

## HYPERTENSION

High blood pressure, or **hypertension (HTN)**, is a contributing factor in all of the conditions described above. In simple terms, HTN is defined as a systolic pressure greater than 140 mm Hg or a diastolic pressure greater than 90 mm Hg. HTN causes the left ventricle to enlarge (hypertrophy) as a result of increased work. Some cases of HTN are secondary to other disorders, such as kidney malfunction or endocrine disturbance, but most of the time, the causes are unknown, a condition described as primary, or essential, HTN.

### Treatment of Hypertension

Even though there is much individual variation in blood pressure, physicians have established guidelines for the diagnosis and treatment of hypertension. Blood pressure readings of 120/80 to 139/89 describe *prehypertension*, a warning sign for the future development of high blood pressure. This condition is treated by lifestyle modifications such as increased physical exercise, a low-salt, low-fat diet, and if necessary, weight loss and smoking cessation. Any confirmed blood pressure over 140/90 (at least two readings on two separate occasions) is treated with medication as well as lifestyle changes. A physician may opt to prescribe anti-hypertensive medication for someone in the upper range of

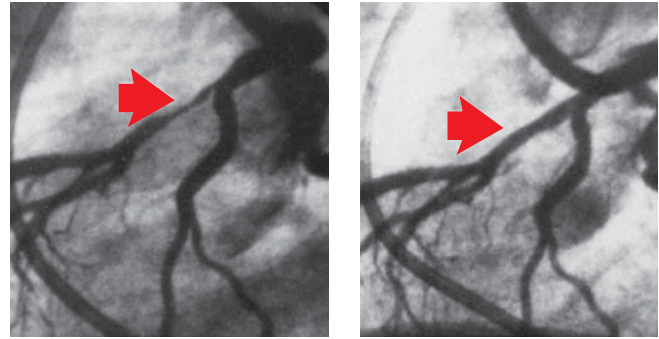
prehypertension who is at risk of a heart attack or stroke. Drugs used to treat hypertension include the following:

- Diuretic (*di-u-RET-ik*) drugs that promote salt and water loss through the kidneys
- Drugs that limit production of renin or block its action
- Drugs that relax blood vessels, including adrenergic blockers and calcium channel blockers

## HEART DISEASE

### Coronary Artery Disease

Coronary artery disease (CAD) results from atherosclerosis in the vessels that supply blood to the heart muscle. It is a leading cause of death in industrialized countries (see FIG. 10-9). An early sign of CAD is the type of chest pain known as **angina pectoris**. This is a feeling of constriction around the heart or pain that may radiate to the left arm or shoulder, usually brought on by exertion. Often there is anxiety, **diaphoresis** (profuse sweating), and **dyspnea** (difficulty in breathing). CAD is diagnosed by ECG, **stress tests**, **echocardiography**, and **coronary angiography**. This invasive x-ray imaging method requires injection of a dye into the coronary arteries by means of a catheter threaded through blood vessels into the heart (FIG. 10-11). Coronary CT angiography (CTA) is a noninvasive procedure that can be used in the diagnosis of heart disease. It employs computed tomography scans following injection of a small amount of dye into the arm. A **coronary calcium scan** (heart scan) reveals vessel-narrowing calcium deposits in the coronary arterial walls. Researchers have also found that a substance called **C-reactive protein** (CRP) is associated with poor cardiovascular health. This protein is produced during systemic inflammation, which may contribute to atherosclerosis. CRP levels can indicate cardiovascular disease and predict its outcome (prognosis). A more specific test for heart attack risk is the more accurate hs-CRP (high-sensitivity CRP) test.



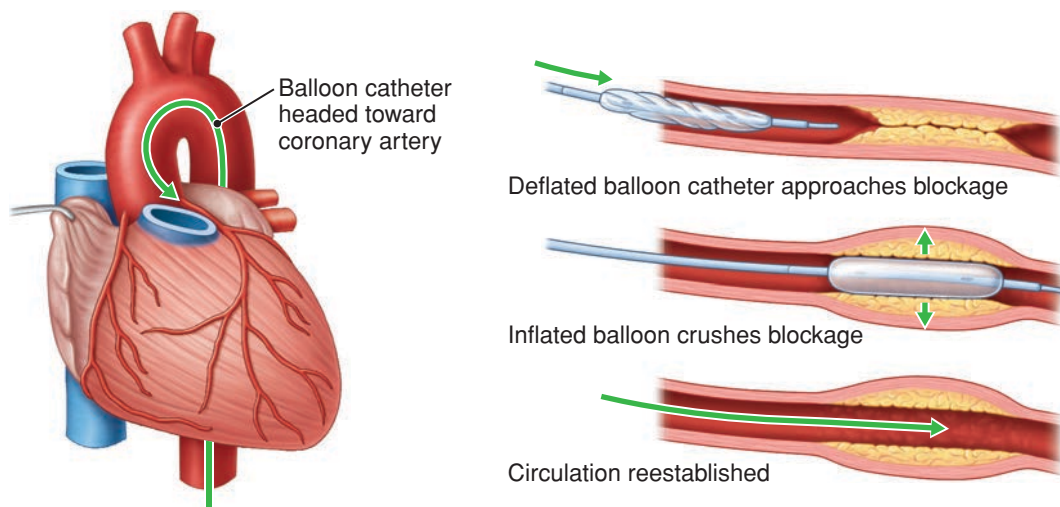
A

B

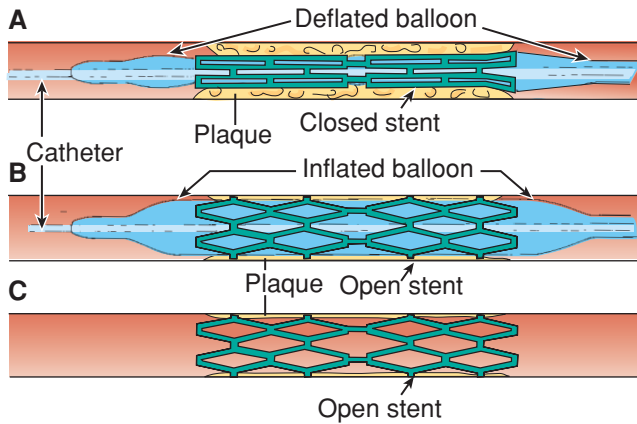
**FIGURE 10-11 Coronary angiography.** Coronary vessels are imaged after administration of a dye during cardiac catheterization. **A.** Angiography shows narrowing in the mid-left anterior descending (LAD) artery (*arrow*). **B.** The same vessel after angioplasty, a procedure to distend narrowed vessels. Note the improved blood flow through the artery distal to the repair.

CAD is treated by control of exercise and diet and by drug therapy and surgical intervention when appropriate. Drugs, such as nitroglycerin, may be used to dilate coronary vessels. Other drugs may be used to regulate the heartbeat, strengthen the force of heart contraction, lower cholesterol, or prevent blood clot formation.

Patients with severe CAD may be candidates for **angioplasty**, surgical dilatation of the blocked vessel by means of a balloon catheter, a procedure technically called **percutaneous transluminal coronary angioplasty** (PTCA) (FIGS. 10-11 and 10-12). Angioplasty may include placement of a **stent**, a small mesh tube, to keep the vessel open (FIG. 10-13). Stents prevent recoil of the vessel and are available in different versions. The basic type is the bare metal stent; another is the drug-eluting stent, which releases drugs to prevent vascular restenosis. The newest form of stent is a completely



**FIGURE 10-12 Coronary angioplasty (PTCA).**



**FIGURE 10-13 Arterial stent.** **A.** Stent closed, before balloon inflation. **B.** Stent open, balloon inflated; stent will remain expanded after balloon is deflated and removed. **C.** Stent open, balloon removed.

bioabsorbable device that is gradually metabolized and absorbed into the body.

If further intervention is required, surgeons can bypass the blocked vessel or vessels with a vascular graft (**FIG. 10-14**). In this procedure, known as a **coronary artery bypass graft (CABG)**, another vessel or a piece of another vessel, usually the left internal mammary artery or part of the leg's saphenous vein, is grafted to carry blood from the aorta to a point past the coronary vessel obstruction.

### Myocardial Infarction

Degenerative changes in the arteries predispose a person to thrombosis and sudden coronary artery occlusion

(obstruction). The resultant area of myocardial necrosis is termed an **infarct**, and the process is known as **myocardial infarction (MI)**, the “heart attack” that may cause sudden death. Symptoms of MI include pain over the heart (precordial pain) or upper part of the abdomen (epigastric pain) that may extend to the jaw or arms, pallor (paleness), diaphoresis, nausea, fatigue, anxiety, and dyspnea. There may be a burning sensation similar to indigestion or heartburn. In women, because degenerative changes more commonly affect multiple small vessels rather than the major coronary pathways, MI symptoms are often more long-term and are more subtle and diffuse than the intense chest pain that is more typical in men.

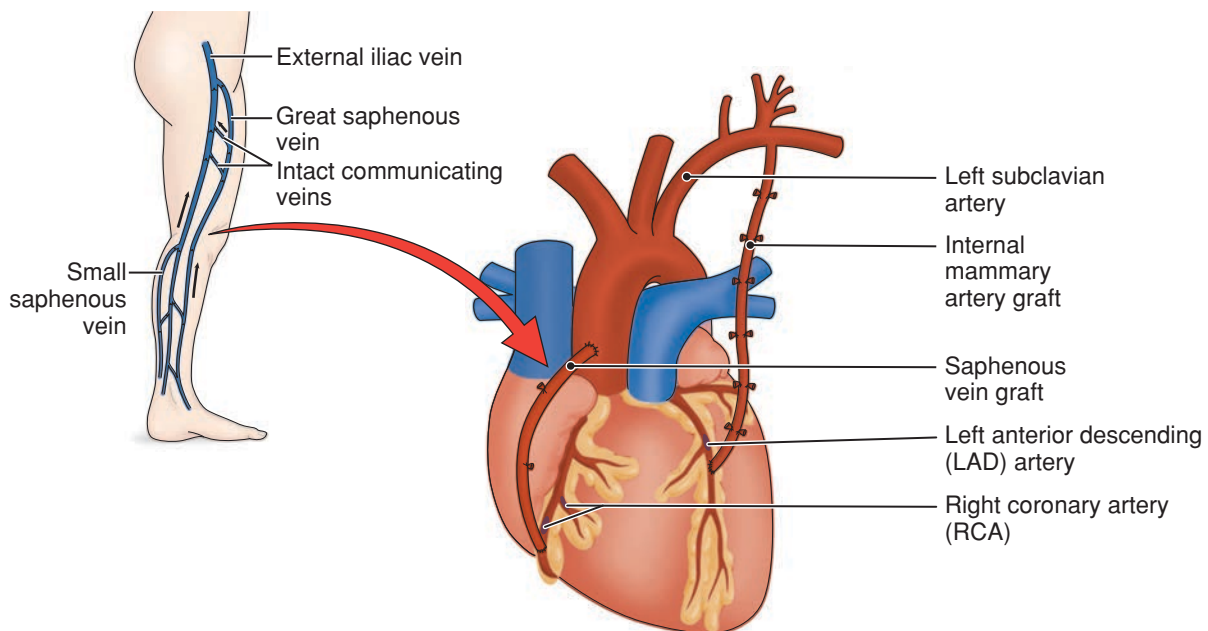
MI is diagnosed by ECG and assays for specific substances in the blood. Creatine kinase (CK) is an enzyme normal to muscle cells. It is released in increased amounts when muscle tissue is injured. The form of CK specific to cardiac muscle cells is **creatin kinase MB (CK-MB)**. **Troponin (Tn)** is a protein that regulates contraction in muscle cells. Increased serum levels, particularly the forms TnT and TnI, indicate MI.

Patient outcome is based on the degree of damage and the speed of treatment to dissolve the clot and to reestablish normal blood flow and heart rhythm.

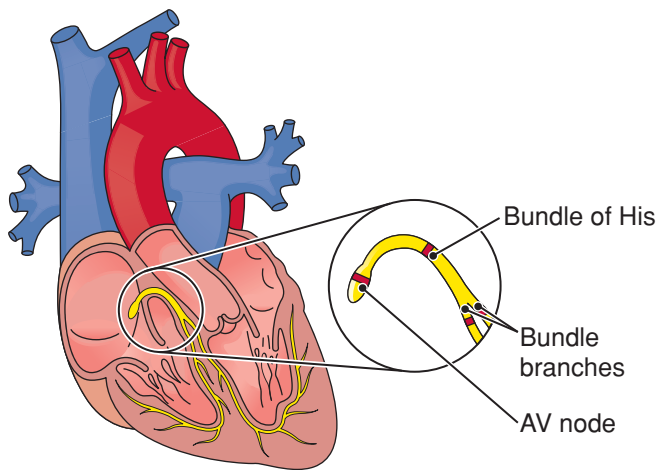
### Arrhythmia

**Arrhythmia** is any irregularity of heart rhythm, such as an altered heart rate, extra beats, or a change in the pattern of the beat. **Bradycardia** is a slower-than-average rate, and **tachycardia** is a higher-than-average rate.

Damage to cardiac tissue, as by MI, may result in **heart block**, an interruption in the heart's electrical conduction



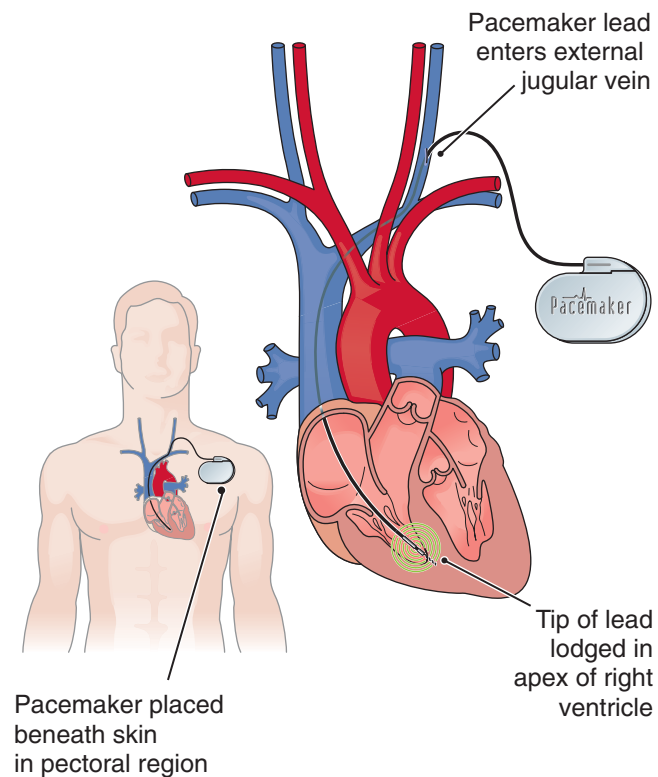
**FIGURE 10-14 Coronary artery bypass graft (CABG).** In a bypass graft, a healthy vessel segment is used to carry blood around an arterial blockage. This figure shows two CABGs. On the left, a segment of the saphenous vein is used to carry blood from the aorta to a part of the right coronary artery that is distal to the occlusion. On the right, the mammary artery is grafted to bypass an obstruction in the LAD artery.



**FIGURE 10-15** Potential sites for heart block in the atrioventricular (AV) portion of the heart's conduction system.

system resulting in arrhythmia (FIG. 10-15). Heart block is classified in order of increasing severity as first-, second-, or third-degree heart block. Block in a bundle branch is designated as a left or right bundle branch block (BBB).

If, for any reason, the SA node is not generating a normal heartbeat or there is heart block, an **artificial pacemaker** may be implanted to regulate the beat (FIG. 10-16). Usually,



**FIGURE 10-16** Placement of a pacemaker. The lead is placed in an atrium or ventricle, usually on the right side. A dual-chamber pacemaker has leads in both chambers.

the pacemaker is inserted under the skin below the clavicle, and leads are threaded through veins into one or both of the right chambers. Some pacemakers act only when the heart is not functioning on its own, and others adjust to the need for a change in heart rate based on activity.

MI is also a common cause of **fibrillation**, an extremely rapid, ineffective heartbeat, especially dangerous when it affects the ventricles. (Carlos in the opening case study had atrial fibrillation.) **Cardioversion** is the general term for restoration of a normal heart rhythm, either by drugs or application of electric current. Hospital personnel use external chest “paddles” or “pads” for emergency electrical **defibrillation**. In addition to **cardiopulmonary resuscitation** (CPR), automated external defibrillators (AEDs) can help save lives when available for high-risk patients or in public places, such as malls, schools, churches, aircrafts, and sports venues. The AED detects fatal arrhythmia and automatically delivers a correct preprogrammed shock. An implantable cardioverter defibrillator (ICD), applied much like a pacemaker, detects potential fibrillation and automatically shocks the heart to restore normal rhythm.

A newer approach to the treatment of heart rhythm irregularities is cardiac **ablation**, destruction of that portion of the conduction pathway that is involved in the arrhythmia. Electrode catheter ablation uses high-frequency sound waves, freezing (cryoablation), or electrical energy delivered through an intravascular catheter to ablate a defect in the conduction pathway.

### Heart Failure

The general term **heart failure** refers to any condition in which the heart fails to empty effectively. The resulting increased pressure in the venous system leads to **edema**, justifying the description *congestive heart failure* (CHF). Left-side failure results in pulmonary edema with breathing difficulties (dyspnea); right-side failure causes peripheral edema with tissue swelling, especially in the legs, along with weight gain from fluid retention. Other symptoms of CHF are **cyanosis** and **syncope** (fainting).

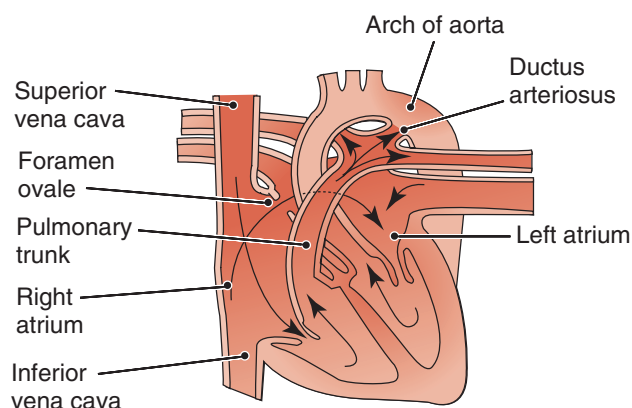
Heart failure is treated with rest, drugs to strengthen heart contractions, diuretics to eliminate fluid, and restriction of salt in the diet.

Heart failure is one cause of **shock**, a severe disturbance in the circulatory system resulting in inadequate blood delivery to the tissues. Shock is classified according to cause as:

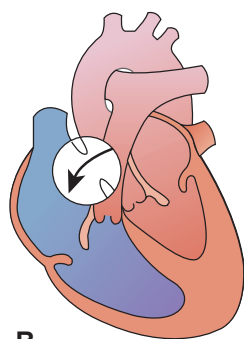
- Cardiogenic shock, caused by heart failure
- Hypovolemic shock, caused by loss of blood volume
- Septic shock, caused by bacterial infection
- Anaphylactic shock, caused by severe allergic reaction

### Congenital Heart Disease

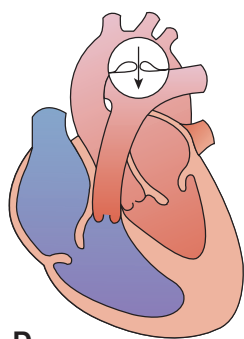
A congenital defect is any defect that is present at birth. The most common type of congenital heart defect is a **septal defect**, a hole in the septum (wall) that separates the atria or



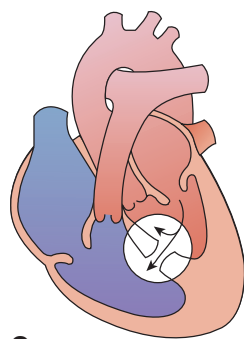
A



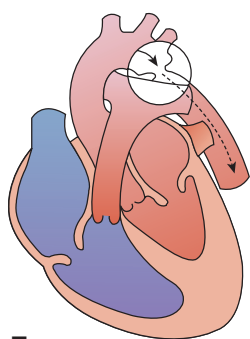
B



D



C



E

**FIGURE 10-17 Congenital heart defects.** **A.** Normal fetal heart showing the foramen ovale and ductus arteriosus. **B.** Persistence of the foramen ovale results in an atrial septal defect. **C.** A ventricular septal defect. **D.** Persistence of the ductus arteriosus (patent ductus arteriosus) forces blood back into the pulmonary artery. **E.** Coarctation of the aorta restricts outward blood flow in the aorta.

the septum that separates the ventricles (FIG. 10-17). An atrial septal defect often results from persistence of an opening, the foramen ovale, that allows blood to bypass the lungs in fetal circulation. A septal defect permits blood to shunt from the left to the right side of the heart and return to the lungs instead of flowing out to the body. The heart has to work harder to meet the tissue's oxygen needs. Symptoms of septal defect include cyanosis (leading to the description “blue baby”), syncope, and **clubbing** of the fingers.

Most U.S. hospitals are now required to screen for congenital heart defects at birth with pulse oximetry, a test that measures oxygen levels in the blood. Low oxygen levels may

indicate heart abnormalities that could be treated immediately but might not otherwise become evident until after the baby leaves the hospital. The test is inexpensive and has a low false-positive rate.

Another congenital defect that results from persistence of a fetal modification is **patent ductus arteriosus** (see FIG. 10-17D). In this case, a small bypass between the pulmonary artery and the aorta fails to close at birth. Blood then can flow from the aorta to the pulmonary artery and return to the lungs.

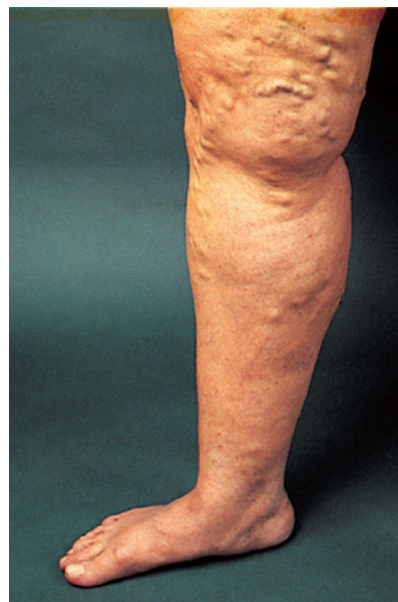Heart valve malformation is another type of congenital heart defect. Failure of a valve to open or close properly is evidenced by a **murmur**, an abnormal sound heard as the heart cycles. A localized aortic narrowing, or **coarctation of the aorta**, is a congenital defect that restricts blood flow through that vessel (see FIG. 10-17E). Most of the congenital defects described now can be corrected surgically. A patent ductus arteriosus may also respond to drug treatment.

### Rheumatic Heart Disease

In **rheumatic heart disease**, infection with a specific type of *Streptococcus* sets up an immune reaction that ultimately damages the heart valves. The infection usually begins as a “strep throat,” and most often the mitral valve is involved. Scar tissue fuses the valve's leaflets, causing a narrowing or **stenosis** that interferes with proper function. People with rheumatic heart disease are subject to repeated valvular infections and may need to take antibiotics prophylactically (preventively) before invasive medical or dental procedures. Severe cases of rheumatic heart disease may require surgical correction or even valve replacement. The incidence of rheumatic heart disease has declined with the use of antibiotics.

### DISORDERS OF THE VEINS

A breakdown in the valves of the veins in combination with a chronic dilatation of these vessels results in **varicose veins** (FIG. 10-18). These appear twisted and swollen under the skin,



**FIGURE 10-18 Varicose veins.**



most commonly in the legs. Contributing factors include heredity, obesity, prolonged standing, and pregnancy, which increase pressure in the pelvic veins. Varicosities can impede blood flow and lead to edema, thrombosis, hemorrhage, or ulceration. Treatment includes the wearing of elastic stockings and, in some cases, surgical removal of the varicose veins, after which collateral circulation is naturally established. A varicose vein in the rectum or anal canal is referred to as a **hemorrhoid**.

**Phlebitis** is any inflammation of the veins and may be caused by infection, injury, poor circulation, or damage to

valves in the veins. Such inflammation typically initiates blood clot formation, resulting in **thrombophlebitis**. Any veins are subject to thrombophlebitis, but the more serious condition involves the deep veins as opposed to the superficial veins, in the condition termed **deep vein thrombosis (DVT)**. The most common sites for DVT are the deep leg veins, causing serious reduction in venous drainage from these areas.

Vascular technologists obtain information on the blood vessels and circulation to aid in diagnosis. **BOX 10-3** for information on this career.



## HEALTH PROFESSIONS

### Vascular Technologists

**BOX 10-3**

Vascular technologists perform noninvasive diagnostic studies to evaluate the blood vessels (arteries and veins) in the head, neck, extremities, and abdomen to help physicians diagnose vascular disorders. Vascular technologists obtain two-dimensional images of the blood vessels using ultrasound and measure the velocity and direction of blood flow using Doppler ultrasound. They use other instrumentation to measure blood pressure, changes in blood volume, and the blood's oxygen saturation.

Most vascular technologists work in hospitals, where they prepare patients for tests, take clinical histories, perform limited physical examinations, carry out diagnostic tests, and report results. They may also work in offices, clinics, or laboratories. Although most of their patients are elderly, vascular studies may be required on patients of any age.

Unlike early workers in this field who were often trained on the job, vascular technologists today complete a 2- or 4-year educational program accredited by the Commission on Accreditation of Allied Health Education Programs (CAAHEP). Certification specific to vascular technology is available from the American Registry for Diagnostic Medical Sonography at [ardms.org](http://ardms.org) and from other organizations. Certification requires appropriate education, clinical experience, examination, and continuing education. Certification will be a requirement of all vascular technologists working in IAC (Intersocietal Accreditation Commission) accredited vascular laboratories beginning in 2017. Additional information on this career is available from the Society for Vascular Ultrasound at [svunet.org](http://svunet.org).

## Terminology

## Key Terms

The terms listed below are emphasized in this chapter. Knowing them will help you organize and prioritize your learning. These boldface terms are also found, collectively, with all chapter key terms in the Glossary.

### Cardiovascular Disorders

<b>aneurysm</b> <i>AN-u-rizm</i>	A localized abnormal dilation of a blood vessel, usually an artery, caused by weakness of the vessel wall; may eventually burst
<b>angina pectoris</b> <i>an-JI-nah PEK-to-ris</i>	A feeling of constriction around the heart or pain that may radiate to the left arm or shoulder, usually brought on by exertion; caused by insufficient blood supply to the heart
<b>arrhythmia</b> <i>ah-RITH-me-ah</i>	Any abnormality in the rate or rhythm of the heartbeat (literally “without rhythm”; note doubled r); also called dysrhythmia
<b>arteriosclerosis</b> <i>ar-tere-e-o-skler-O-sis</i>	Hardening (sclerosis) of the arteries, with loss of capacity and loss of elasticity, as from fatty deposits (plaque), deposit of calcium salts, or scar tissue formation
<b>atherosclerosis</b> <i>ath-er-o-skler-O-sis</i>	The development of fatty, fibrous patches (plaques) in the lining of arteries, causing narrowing of the lumen and hardening of the vessel wall; the most common form of arteriosclerosis (hardening of the arteries) (root ather/o means “porridge” or “gruel”)
<b>bradycardia</b> <i>brad-e-KAR-de-ah</i>	A slow heart rate of less than 60 bpm
<b>cerebrovascular accident (CVA)</b> <i>ser-eh-bro-VAS-ku-lar</i>	Sudden damage to the brain resulting from reduction of blood flow; causes include atherosclerosis, embolism, thrombosis, or hemorrhage from a ruptured aneurysm; commonly called stroke

## Terminology

## Key Terms (Continued)

<b>clubbing</b> <i>KLUB-ing</i>	Enlargement of the ends of the fingers and toes caused by growth of the soft tissue around the nails (see <b>FIG. 3-17</b> ); seen in a variety of diseases in which there is poor peripheral circulation
<b>coarctation of the aorta</b> <i>ko-ark-TA-shun</i>	Localized narrowing of the aorta with restriction of blood flow (see <b>FIG. 10-17E</b> )
<b>C-reactive protein (CRP)</b>	Protein produced during systemic inflammation, which may contribute to atherosclerosis; high CRP levels can indicate cardiovascular disease and its prognosis
<b>cyanosis</b> <i>si-ab-NO-sis</i>	Bluish discoloration of the skin caused by lack of oxygen in the blood (adjective: cyanotic) (see <b>FIG. 1-17</b> )
<b>deep vein thrombosis (DVT)</b> <i>throm-BO-sis</i>	Thrombophlebitis involving the deep veins
<b>diaphoresis</b> <i>di-ab-fo-RE-sis</i>	Profuse sweating
<b>dissecting aneurysm</b>	An aneurysm in which blood enters the arterial wall and separates the layers; usually involves the aorta (see <b>FIG. 10-10</b> )
<b>dyslipidemia</b> <i>dis-lip-ih-DE-me-ab</i>	Disorder in serum lipid levels, which is an important factor in development of atherosclerosis; includes hyperlipidemia (high lipids), hypercholesterolemia (high cholesterol), and hypertriglyceridemia (high triglycerides)
<b>dyspnea</b> <i>DISP-ne-ab</i>	Difficult or labored breathing (-pnea)
<b>edema</b> <i>eh-DE-mab</i>	Swelling of body tissues caused by the presence of excess fluid (see <b>FIG. 3-2</b> ); causes include cardiovascular disturbances, kidney failure, inflammation, and malnutrition
<b>embolism</b> <i>EM-bo-lizm</i>	Obstruction of a blood vessel by a blood clot or other matter carried in the circulation
<b>embolus</b> <i>EM-bo-lus</i>	A mass carried in the circulation; usually a blood clot, but also may be air, fat, bacteria, or other solid matter from within or from outside the body
<b>fibrillation</b> <i>fih-brih-LA-shun</i>	Spontaneous, quivering, and ineffectual contraction of muscle fibers, as in the atria or the ventricles
<b>heart block</b>	An interference in the electrical conduction system of the heart resulting in arrhythmia (see <b>FIG. 10-15</b> )
<b>heart failure</b>	A condition caused by the inability of the heart to maintain adequate blood circulation
<b>hemorrhoid</b> <i>HEM-o-royd</i>	A varicose vein in the rectum
<b>hypertension</b> <i>hi-per-TEN-shun</i>	A condition of higher-than-normal blood pressure; essential (primary, idiopathic) hypertension has no known cause
<b>infarct</b> <i>in-FARKT</i>	An area of localized tissue necrosis (death) resulting from a blockage or a narrowing of the artery that supplies the area
<b>ischemia</b> <i>is-KE-me-ab</i>	Local deficiency of blood supply caused by circulatory obstruction (root: hem/o)
<b>murmur</b>	An abnormal heart sound
<b>myocardial infarction (MI)</b> <i>mi-o-KAR-de-al in-FARK-shun</i>	Localized necrosis (death) of cardiac muscle tissue resulting from blockage or narrowing of the coronary artery that supplies that area; myocardial infarction is usually caused by formation of a thrombus (clot) in a vessel

(continued)

## Terminology

## Key Terms (Continued)

<b>occlusion</b> <i>o-KLU-zhun</i>	A closing off or obstruction, as of a vessel
<b>patent ductus arteriosus</b> <i>PA-tent DUK-tus</i> <i>ar-tere-e-O-sus</i>	Persistence of the ductus arteriosus after birth; the ductus arteriosus is a vessel that connects the pulmonary artery to the descending aorta in the fetus to bypass the lungs (see <b>FIG. 10-17D</b> )
<b>phlebitis</b> <i>fleh-BI-tis</i>	Inflammation of a vein
<b>plaque</b> <i>Plak</i>	A patch; with regard to the cardiovascular system, a deposit of fatty material and other substances on a vessel wall that impedes blood flow and may block the vessel; atheromatous plaque
<b>rheumatic heart disease</b> <i>ru-MAT-ik</i>	Damage to heart valves after infection with a type of <i>Streptococcus</i> (group A hemolytic <i>Streptococcus</i> ); the antibodies produced in response to the infection produce valvular scarring usually involving the mitral valve
<b>septal defect</b> <i>SEP-tal</i>	An opening in the septum between the atria or ventricles; a common cause is persistence of the foramen ovale ( <i>for-A-men o-VAL-e</i> ), an opening between the atria that bypasses the lungs in fetal circulation (see <b>FIG. 10-17B,C</b> )
<b>shock</b>	Circulatory failure resulting in an inadequate blood supply to the tissues; cardiogenic shock is caused by heart failure; hypovolemic shock is caused by a loss of blood volume; septic shock is caused by bacterial infection
<b>stenosis</b> <i>steh-NO-sis</i>	Constriction or narrowing of an opening
<b>stroke</b>	See cerebrovascular accident
<b>syncope</b> <i>SIN-ko-pe</i>	A temporary loss of consciousness caused by inadequate blood flow to the brain; fainting
<b>tachycardia</b> <i>tak-ih-KAR-de-ab</i>	An abnormally rapid heart rate, usually over 100 bpm
<b>thrombophlebitis</b> <i>throm-bo-fleh-BI-tis</i>	Inflammation of a vein associated with formation of a blood clot
<b>thrombosis</b> <i>throm-BO-sis</i>	Development of a blood clot within a vessel
<b>thrombus</b> <i>THROM-bus</i>	A blood clot that forms within a blood vessel (root: thromb/o)
<b>varicose vein</b> <i>VAR-ih-kose</i>	A twisted and swollen vein resulting from breakdown of the valves, pooling of blood, and chronic dilatation of the vessel (root: varic/o); also called varix ( <i>VAR-iks</i> ) or varicosity ( <i>var-ih-KOS-ih-te</i> ) (see <b>FIG. 10-18</b> )
<b>Diagnosis and Treatment</b>	
<b>ablation</b> <i>ab-LA-shun</i>	Removal or destruction. In cardiac ablation, a catheter is used to destroy a portion of the heart's conduction pathway to correct an arrhythmia
<b>angioplasty</b> <i>AN-je-o-plas-te</i>	A procedure that reopens a narrowed vessel and restores blood flow; commonly accomplished by surgically removing plaque, inflating a balloon within the vessel, or installing a device (stent) to keep the vessel open (see <b>FIGS. 10-11 to 10-13</b> )
<b>artificial pacemaker</b>	A battery-operated device that generates electrical impulses to regulate the heartbeat; it may be external or implanted, may be designed to respond to need, and may have the capacity to prevent tachycardia (see <b>FIG. 10-16</b> )

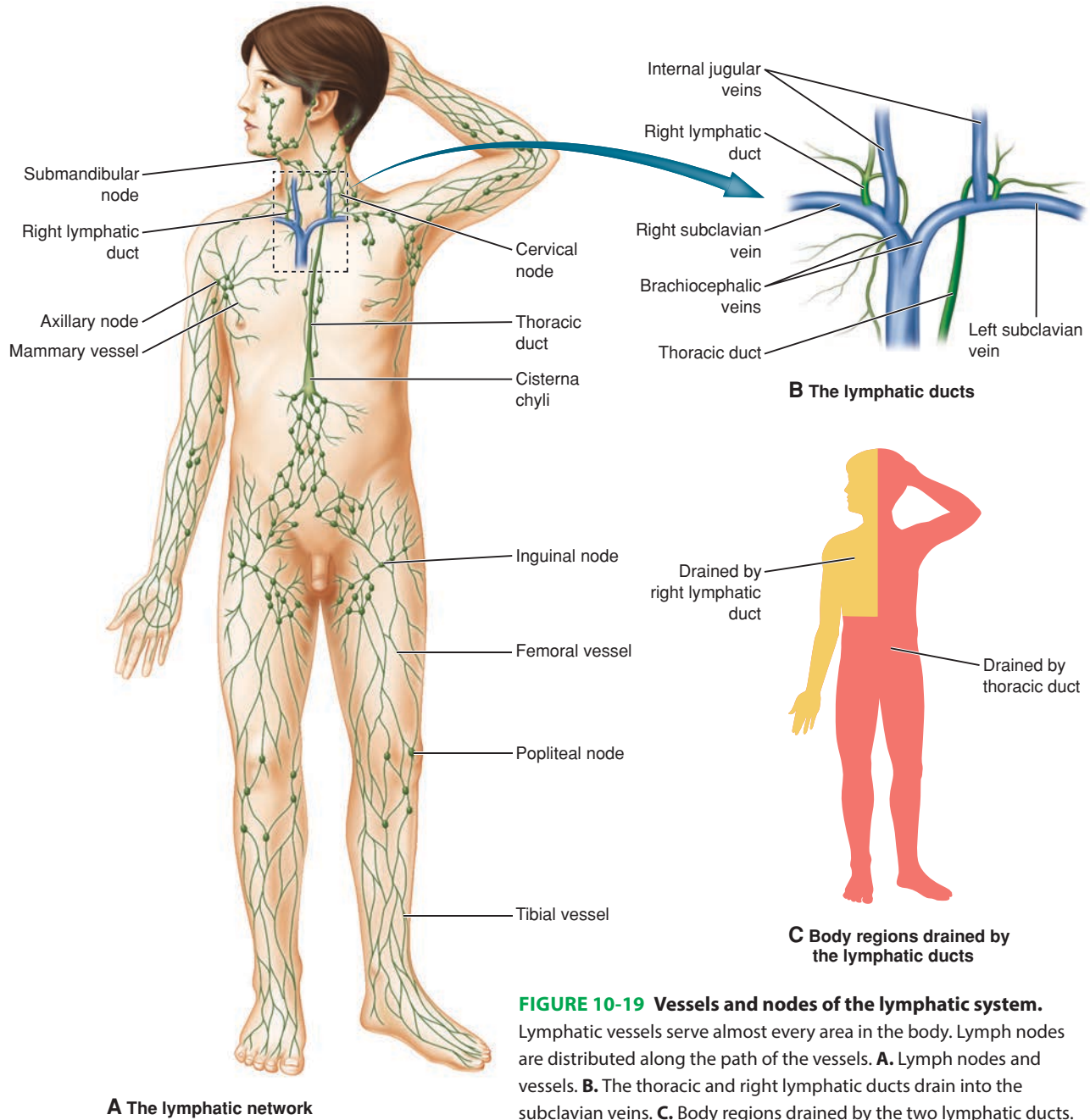
Terminology	Key Terms (Continued)
<b>cardiopulmonary resuscitation (CPR)</b> <i>kar-de-o-PUL-mo-nar-e re-sus-ih-TA-shun</i>	Restoration of cardiac output and pulmonary ventilation after cardiac arrest using artificial respiration and chest compression or cardiac massage
<b>cardioversion</b> <i>KAR-de-o-ver-zhun</i>	Correction of an abnormal cardiac rhythm; may be accomplished pharmacologically, with antiarrhythmic drugs, or by application of electric current (see defibrillation)
<b>coronary angiography</b> <i>KOR-o-na-re an-je-OG-rah-fe</i>	Radiographic study of the coronary arteries after introduction of an opaque dye by means of a catheter threaded through blood vessels into the heart (see FIG. 10-11)
<b>coronary artery bypass graft (CABG)</b>	Surgical creation of a shunt to bypass a blocked coronary artery; the aorta is connected to a point past the obstruction with another vessel or a piece of another vessel, usually the left internal mammary artery or part of the leg's saphenous vein (see FIG. 10-14)
<b>coronary calcium scan</b>	Method for visualizing vessel-narrowing calcium deposits in coronary arteries; useful for diagnosing coronary artery disease in people at moderate risk or those who have undiagnosed chest pain; also known as a heart scan
<b>creatinase kinase MB (CK-MB)</b> <i>KRE-ah-tin KI-naze</i>	Enzyme released in increased amounts from cardiac muscle cells following myocardial infarction (MI); serum assays help diagnose MI and determine the extent of muscle damage
<b>CT angiography (CTA)</b> <i>an-je-OG-rah-fe</i>	Computed tomography scan used to visualize vessels in the heart and other organs; requires only a small amount of dye injected into the arm; can rule out blocked coronary arteries that may cause a myocardial infarction (heart attack) in people with chest pain or abnormal stress tests
<b>defibrillation</b> <i>de-fib-rib-LA-shun</i>	Use of an electronic device (defibrillator) to stop fibrillation by delivering a brief electric shock to the heart; the shock may be delivered to the surface of the chest, as by an automated external defibrillator (AED), or directly into the heart through wire leads, using an implantable cardioverter defibrillator (ICD)
<b>echocardiography</b> <i>ek-o-kar-de-OG-rah-fe</i>	A noninvasive method that uses ultrasound to visualize internal cardiac structures
<b>lipoprotein</b> <i>lip-o-PRO-tene</i>	A compound of protein with lipid; lipoproteins are classified according to density as very low-density (VLDL), low-density (LDL), and high-density (HDL); relatively higher levels of HDLs have been correlated with cardiovascular health
<b>percutaneous transluminal coronary angioplasty (PTCA)</b>	Dilatation of a sclerotic blood vessel by means of a balloon catheter inserted into the vessel and then inflated to flatten plaque against the arterial wall (see FIG. 10-12)
<b>stent</b>	A small metal device in the shape of a coil or slotted tube that is placed inside an artery to keep the vessel open, for example, after balloon angioplasty (see FIG. 10-13)
<b>stress test</b>	Evaluation of physical fitness by continuous ECG monitoring during exercise; in a thallium stress test, a radioactive isotope of thallium is administered to trace blood flow through the heart during exercise
<b>troponin (Tn)</b> <i>tro-PO-nin</i>	A protein in muscle cells that regulates contraction; increased serum levels, primarily in the forms TnT and TnI, indicate recent myocardial infarction (MI)

## The Lymphatic System

The lymphatic system is a widely distributed system with multiple functions (FIG. 10-19). Its role in circulation is to return excess fluid and proteins from the tissues to the bloodstream. Blind-ended lymphatic capillaries pick up these materials in the tissues and carry them into larger vessels (FIG. 10-20). The fluid carried in the lymphatic system is called **lymph**. Lymph drains from the lower part of the body

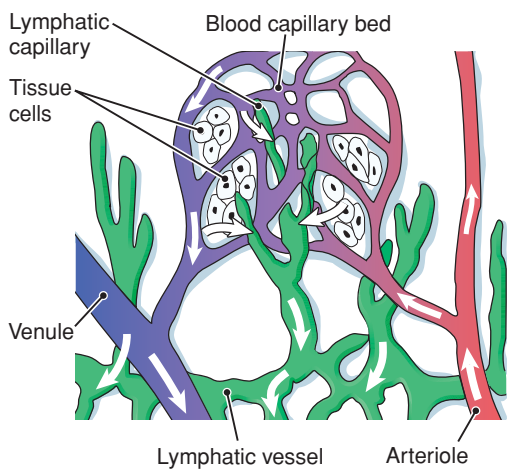
and the upper left side into the **thoracic duct** (left lymphatic duct), which travels upward through the chest and empties into the left subclavian vein near the heart (see FIG. 10-19). The **right lymphatic duct** drains the body's upper right side and empties into the right subclavian vein.

Another major function of the lymphatic system is to protect the body from impurities and invading microorganisms (see discussion of immunity in Chapter 11). Along the path of the lymphatic vessels are small masses of lymphoid



**FIGURE 10-19 Vessels and nodes of the lymphatic system.**

Lymphatic vessels serve almost every area in the body. Lymph nodes are distributed along the path of the vessels. **A.** Lymph nodes and vessels. **B.** The thoracic and right lymphatic ducts drain into the subclavian veins. **C.** Body regions drained by the two lymphatic ducts.

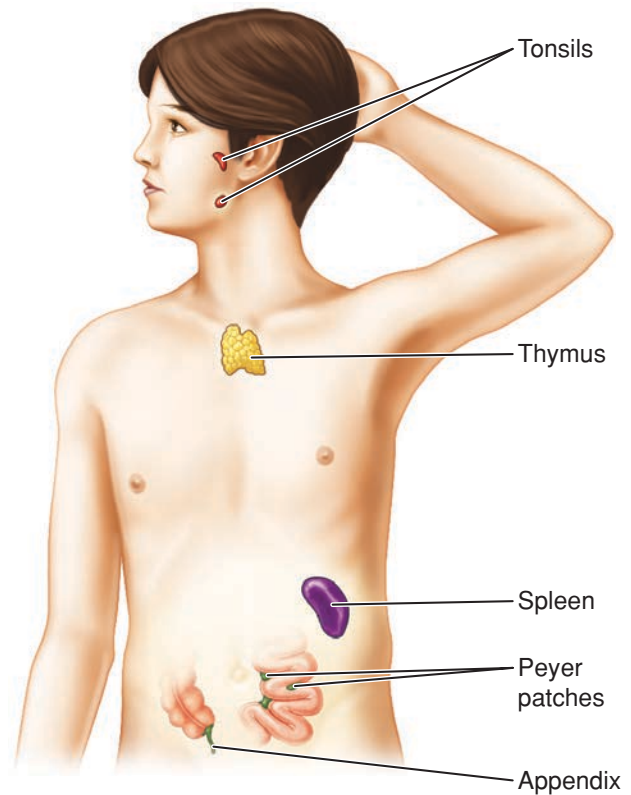


**FIGURE 10-20 Lymphatic drainage in the tissues.** Lymphatic capillaries pick up fluid and proteins left in the tissues and carry them back to the bloodstream.

tissue, the **lymph nodes** (FIG. 10-21). Their function is to filter the lymph as it passes through. They are concentrated in the cervical (neck), axillary (armpit), mediastinal (chest), and inguinal (groin) regions. Other protective organs and tissues of the lymphatic system include the following:

- **Tonsils**, located in the throat (pharynx). They filter inhaled or swallowed materials and aid in immunity early in life. The tonsils are further discussed in Chapter 12.
- **Thymus**, in the chest, above the heart. It processes and stimulates lymphocytes active in immunity.
- **Spleen**, in the upper left region of the abdomen. It filters blood and destroys old red blood cells.
- **Appendix**, attached to the large intestine. It may aid in the development of immunity.
- **Peyer patches**, in the lining of the intestine. They help protect against invading microorganisms.

A final function of the lymphatic system is to absorb digested fats from the small intestine (Chapter 13). These fats are then added to the blood with the lymph that drains from the thoracic duct.



**FIGURE 10-21** Location of lymphoid organs and tissue.

## Terminology

## Key Terms

The terms listed below are emphasized in this chapter. Knowing them will help you organize and prioritize your learning. These boldface terms are also found, collectively, with all chapter key terms in the Glossary.

### Lymphatic System

#### Normal Structure and Function

<b>appendix</b> <i>ah-PEN-diks</i>	A small, finger-like mass of lymphoid tissue attached to the first part of the large intestine
<b>lymph</b> <i>Limf</i>	The thin, plasma-like fluid that drains from the tissues and is transported in lymphatic vessels (root: lymph/o)
<b>lymph node</b>	A small mass of lymphoid tissue along the path of a lymphatic vessel that filters lymph (root: lymphaden/o)
<b>lymphatic system</b> <i>lim-FAT-ik</i>	The system that drains fluid and proteins from the tissues and returns them to the bloodstream; this system also participates in immunity and aids in absorption of fats from the digestive tract
<b>Peyer patches</b> <i>PI-er</i>	Aggregates of lymphoid tissue in the lining of the intestine
<b>right lymphatic duct</b>	The lymphatic duct that drains fluid from the body's upper right side
<b>spleen</b>	A large reddish-brown organ in the upper left region of the abdomen; it filters blood and destroys old red blood cells (root: splen/o)

(continued)

## Terminology

## Key Terms (Continued)

<b>thoracic duct</b>	The lymphatic duct that drains fluid from the upper left side of the body and all of the lower body; left lymphatic duct
<b>thymus</b> <i>THI-mus</i>	A lymphoid organ in the upper part of the chest beneath the sternum; it functions in immunity (root: thym/o)
<b>tonsil</b> <i>TON-sil</i>	Small mass of lymphoid tissue located in region of the throat (pharynx)

## Roots Pertaining to the Lymphatic System

See TABLE 10-3.

Table 10-3

### Roots for the Lymphatic System

Root	Meaning	Example	Definition of Example
lymph/o	lymph, lymphatic system	lymphoid <i>LIM-foyd</i>	resembling lymph or lymphatic tissue
lymphaden/o	lymph node	lymphadenitis <i>lim-fad-eh-NI-tis</i>	inflammation of a lymph node
lymphangi/o	lymphatic vessel	lymphangiogram <i>lim-FAN-je-o-gram</i>	x-ray image of lymphatic vessels
splen/o	spleen	splenalgia <i>sple-NAL-je-ab</i>	pain in the spleen
thym/o	thymus	athymia <i>ab-THI-me-ab</i>	absence of the thymus
tonsil/o	tonsil	tonsillar <i>TON-sil-ar</i>	pertaining to a tonsil

## Exercise

### 10-3

Complete the exercise. To check your answers go to Appendix 11.

Fill in the blanks.

1. Tonsillectomy (*ton-sil-EK-to-me*) is surgical removal of a(n) \_\_\_\_\_ .
2. Thymopathy (*thi-MOP-ab-the*) is any disease of the \_\_\_\_\_ .
3. Lymphadenectomy (*lim-fad-eh-NEK-to-me*) is surgical removal of a(n) \_\_\_\_\_ .
4. Lymphedema (*limf-eh-DE-mah*) means swelling caused by obstruction of the flow of \_\_\_\_\_ .
5. A lymphangioma (*lim-fan-je-O-mah*) is a tumor of \_\_\_\_\_ .
6. Splenic (*SPLEN-ik*) means pertaining to the \_\_\_\_\_ .

## Exercise 10-3 (Continued)

Identify and define the root in the following words.

	Root	Definition
7. lymphangial ( <i>lim-FAN-je-al</i> )	_____	_____
8. perisplenitis ( <i>per-e-sple-NI-tis</i> )	_____	_____
9. lymphadenography ( <i>lim-fad-eh-NOG-rah-fe</i> )	_____	_____
10. tonsillectomy ( <i>ton-sil-EK-to-me</i> )	_____	_____
11. hypothyroidism ( <i>hi-po-THI-mizm</i> )	_____	_____

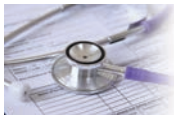Use the appropriate root to write words with the following meanings.

12. Enlargement (-megaly) of the spleen	_____	_____
13. Inflammation of a tonsil	_____	_____
14. Any disease (-pathy) of the lymph nodes	_____	_____
15. Inflammation of lymphatic vessels	_____	_____
16. Pertaining to (-ic) the thymus	_____	_____
17. A tumor (-oma) of lymphatic tissue	_____	_____

## Clinical Aspects of the Lymphatic System

Changes in the lymphatic system are often related to infection and may consist of inflammation and enlargement of the nodes, called **lymphadenitis**, or inflammation of the

vessels, called **lymphangitis**. Obstruction of lymphatic vessels because of surgical excision or infection results in tissue swelling, or **lymphedema** (**BOX 10-4**). Any neoplastic disease involving lymph nodes is termed **lymphoma**. These neoplastic disorders affect the white blood cells found in the lymphatic system, and they are discussed more fully in Chapter 11.



### CLINICAL PERSPECTIVES

#### Lymphedema: When Lymph Stops Flowing

BOX 10-4

Fluid balance in the body requires appropriate distribution of fluid among the cardiovascular system, lymphatic system, and the tissues. Edema occurs when the balance is tipped toward excess fluid in the tissues. Often, edema is due to heart failure. However, blockage of lymphatic vessels (with resulting fluid accumulation in the tissues) can cause another form of edema, called lymphedema. The clinical hallmark of lymphedema is chronic swelling of an arm or leg, whereas heart failure usually causes swelling of both legs.

Lymphedema may be either primary or secondary. Primary lymphedema is a rare congenital condition caused by abnormal development of lymphatic vessels. Secondary lymphedema, or acquired lymphedema, can develop as a result of trauma to a limb, surgery, radiation therapy, or infection of the lymphatic vessels (lymphangitis). One of the most common causes of lymphedema is the removal of axillary lymph nodes

during mastectomy, which disrupts lymph flow from the adjacent arm. Lymphedema may also occur following prostate surgery.

Therapies that encourage the flow of fluid through the lymphatic vessels are useful in treating lymphedema. These therapies may include elevation of the affected limb, manual lymphatic drainage through massage, light exercise, and firm wrapping of the limb to apply compression. In addition, changes in daily habits can lessen the effects of lymphedema. For example, further blockage of lymph drainage can be prevented by wearing loose clothing and jewelry, carrying a purse or handbag on the unaffected arm, and not crossing the legs when sitting. Lymphangitis requires the use of appropriate antibiotics. Prompt treatment is necessary because in addition to swelling, other complications include poor wound healing, skin ulcers, and increased risk of infection.



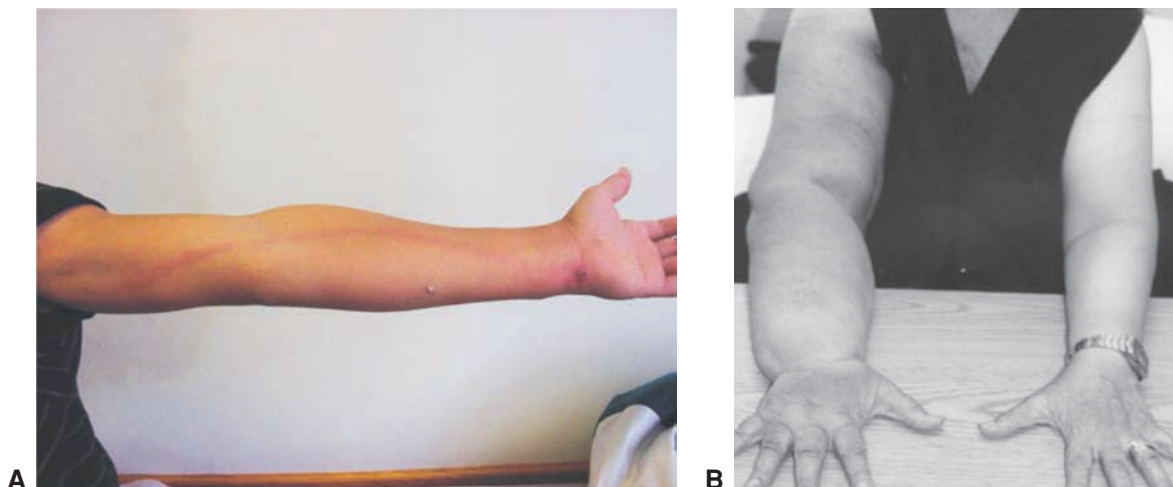
## Terminology

## Key Terms

The terms listed below are emphasized in this chapter. Knowing them will help you organize and prioritize your learning. These boldface terms are also found, collectively, with all chapter key terms in the Glossary.

## Lymphatic Disorders

<b>lymphadenitis</b> <i>lim-fad-eb-NI-tis</i>	Inflammation and enlargement of lymph nodes, usually as a result of infection
<b>lymphangitis</b> <i>lim-fan-JI-tis</i>	Inflammation of lymphatic vessels as a result of bacterial infection; appears as painful red streaks under the skin ( <b>FIG. 10-22A</b> )
<b>lymphedema</b> <i>lim-feh-DE-mah</i>	Swelling of tissues with lymph caused by obstruction or excision of lymphatic vessels (see <b>FIG. 10-22B</b> and <b>BOX 10-4</b> )
<b>lymphoma</b> <i>lim-FO-mah</i>	Any neoplastic disease of lymphoid tissue



**FIGURE 10-22 Lymphatic disorders.** **A.** Lymphangitis is inflammation of lymphatic vessels. Note the linear red streak proximal to a skin infection. **B.** Lymphedema of the upper right extremity following removal of axillary lymph nodes and blockage of lymph flow.

## Terminology

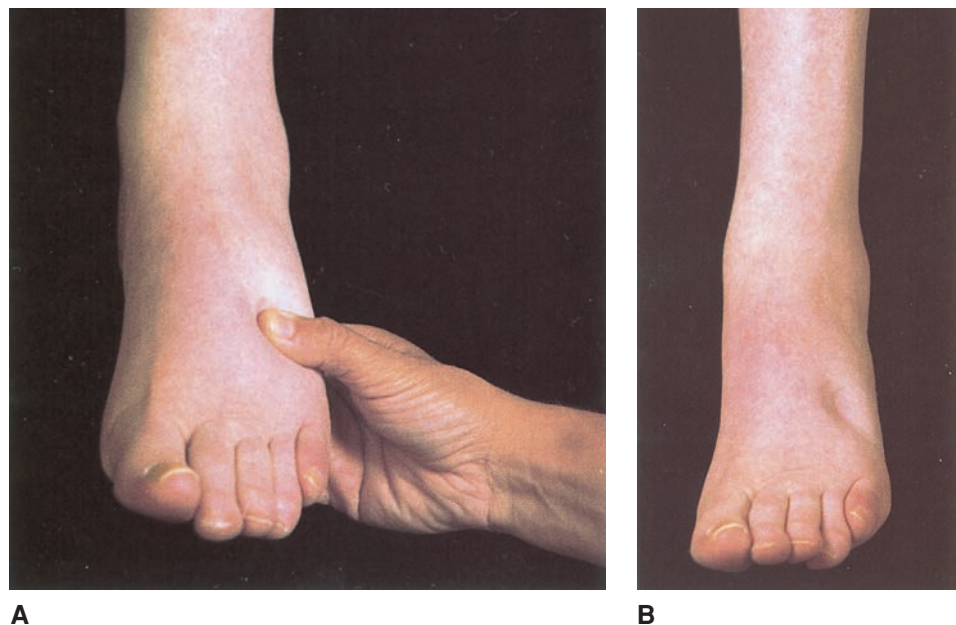
## Enrichment Terms

The terms listed below expand on the key terms to increase your knowledge of this chapter topic.

## Normal Structure and Function

<b>apical pulse</b> <i>AP-ih-kal</i>	Pulse felt or heard over the heart's apex; it is measured in the fifth left intercostal space (between the ribs) about 8 to 9 cm from the midline
<b>cardiac output</b>	The amount of blood pumped from the right or left ventricle per minute
<b>compliance</b>	The ease with which a structure expands under pressure, as in a blood vessel expanding to receive blood
<b>Korotkoff sounds</b> <i>ko-ROT-kof</i>	Arterial sounds heard with a stethoscope during determination of blood pressure with a cuff
<b>perfusion</b> <i>per-FU-zhun</i>	The passage of fluid, such as blood, through an organ or tissue
<b>precordium</b> <i>pre-KOR-de-um</i>	The anterior region over the heart and the lower part of the thorax; adjective: precordial

Terminology	Enrichment Terms (Continued)
<b>pulse pressure</b>	The difference between systolic and diastolic pressure
<b>stroke volume</b>	The amount of blood ejected by the left ventricle with each beat
<b>Valsalva maneuver</b> <i>val-SAL-vah</i>	Bearing down, as in childbirth or defecation, by attempting to exhale forcefully with the nose and throat closed; this action has an effect on the cardiovascular system
<b>Symptoms and Conditions</b>	
<b>bruit</b> <i>brwe</i>	An abnormal sound heard in auscultation
<b>cardiac tamponade</b> <i>tam-pon-ADE</i>	Pathologic accumulation of fluid in the pericardial sac; may result from pericarditis or injury to the heart or great vessels
<b>ectopic beat</b> <i>ek-TOP-ik</i>	A heartbeat that originates from some part of the heart other than the SA node
<b>extrasystole</b> <i>eks-trah-SIS-to-le</i>	Premature heart contraction that occurs separately from the normal beat and originates from a part of the heart other than the SA node
<b>flutter</b>	Very rapid (200–300 bpm) but regular contractions, as in the atria or the ventricles
<b>hypotension</b> <i>hi-po-TEN-shun</i>	A condition of lower-than-normal blood pressure
<b>intermittent claudication</b> <i>claw-dib-KA-shun</i>	Pain in a muscle during exercise caused by inadequate blood supply; the pain disappears with rest
<b>mitral valve prolapse</b> <i>PRO-laps</i>	Movement of the mitral valve cusps into the left atrium when the ventricles contract
<b>occlusive vascular disease</b>	Arteriosclerotic disease of the vessels, usually peripheral vessels
<b>palpitation</b> <i>pal-pib-TA-shun</i>	A sensation of abnormally rapid or irregular heartbeat
<b>pitting edema</b>	Edema that retains the impression of a finger pressed firmly into the skin ( <b>FIG. 10-23</b> )

*(continued)***FIGURE 10-23** Pitting edema.

When the skin is pressed firmly with the finger (**A**), a pit remains after the finger is removed (**B**).

## Terminology

## Enrichment Terms (Continued)

<b>polyarteritis nodosa</b> <i>no-DO-sah</i>	Potentially fatal collagen disease causing inflammation of small visceral arteries; symptoms depend on the organ affected
<b>Raynaud disease</b> <i>ra-NO</i>	A disorder characterized by abnormal constriction of peripheral vessels in the arms and legs on exposure to cold
<b>regurgitation</b> <i>re-gur-jih-TA-shun</i>	A backward flow, such as the backflow of blood through a defective valve
<b>stasis</b> <i>STA-sis</i>	Stoppage of normal flow, as of blood or urine; blood stasis may lead to dermatitis and ulcer formation
<b>subacute bacterial endocarditis (SBE)</b>	Bacterial growth in a heart or valves previously damaged by rheumatic fever
<b>tetralogy of Fallot</b> <i>fal-O</i>	A combination of four congenital heart abnormalities: pulmonary artery stenosis, interventricular septal defect, displacement of the aorta to the right, and right ventricular hypertrophy
<b>thromboangiitis obliterans</b>	Inflammation and thrombus formation resulting in occlusion of small vessels, especially in the legs; most common in young men and correlated with heavy smoking; thrombotic occlusion of leg vessels may lead to gangrene of the feet; patients show a hypersensitivity to tobacco; also called Buerger disease
<b>vegetation</b>	Irregular bacterial outgrowths on the heart valves; associated with rheumatic fever
<b>Wolff–Parkinson–White syndrome (WPW)</b>	A cardiac arrhythmia consisting of tachycardia and a premature ventricular beat caused by an alternative conduction pathway
<b>Diagnosis</b>	
<b>cardiac catheterization</b>	Passage of a catheter into the heart through a vessel to inject a contrast medium for imaging, diagnosis, obtaining samples, or measuring pressure
<b>central venous pressure (CVP)</b>	Pressure in the superior vena cava
<b>cinéangiography</b> <i>sin-eh-an-je-o-kar-de-OG-rah-fe</i>	The photographic recording of fluoroscopic images of the heart and large vessels using motion picture techniques
<b>Doppler echocardiography</b>	An imaging method used to study the rate and pattern of blood flow
<b>Holter monitor</b>	A portable device that can record from 24 hours to 1 month of an individual's ECG readings during normal activity
<b>homocysteine</b> <i>ho-mo-SIS-te-ene</i>	An amino acid in the blood that at higher-than-normal levels is associated with increased risk of cardiovascular disease
<b>phlebotomist</b> <i>fleh-BOT-o-mist</i>	Technician who specializes in drawing blood
<b>phonocardiography</b> <i>fo-no-kar-de-OG-rah-fe</i>	Electronic recording of heart sounds
<b>plethysmography</b> <i>pleh-thiz-MOG-rah-fe</i>	Measurement of changes in the size of a part based on the amount of blood contained in or passing through it; impedance plethysmography measures changes in electrical resistance and is used in the diagnosis of deep vein thrombosis
<b>pulmonary capillary wedge pressure (PCWP)</b>	Pressure measured by a catheter in a branch of the pulmonary artery. It is an indirect measure of pressure in the left atrium (see <b>BOX 10-2</b> )
<b>radionuclide heart scan</b>	Imaging of the heart after injection of a radioactive isotope; the PYP (pyrophosphate) scan using technetium-99m ( <sup>99m</sup> Tc) is used to test for myocardial infarction because the isotope is taken up by damaged tissue; the MUGA (multigated acquisition) scan gives information on heart function
<b>Swan–Ganz catheter</b>	A cardiac catheter with a balloon at the tip that is used to measure pulmonary arterial pressure; it is flow guided through a vein into the right side of the heart and then into the pulmonary artery

**Terminology****Enrichment Terms (Continued)**

<b>transesophageal echocardiography (TEE)</b> <i>ech-o-car-di-og-ra-phy (TEE)</i>	Use of an ultrasound transducer placed endoscopically into the esophagus to obtain images of the heart
<b>triglyceride</b> <i>tri-GLIS-er-ide</i>	Simple fat that circulates in the bloodstream
<b>ventriculography</b> <i>ven-trik-u-LOG-rah-fe</i>	X-ray study of the heart's ventricles after introduction of an opaque dye by means of a catheter

**Treatment and Surgical Procedures**

<b>atherectomy</b> <i>ath-er-EK-to-me</i>	Removal of atheromatous plaque from the lining of a vessel; may be done by open surgery or through the vessel's lumen
<b>commissurotomy</b> <i>kom-ib-shur-OT-o-me</i>	Surgical incision of a scarred mitral valve to increase the size of the valvular opening
<b>embolectomy</b> <i>em-bo-LEK-to-me</i>	Surgical removal of an embolus
<b>intraaortic balloon pump (IABP)</b>	A mechanical assist device that consists of an inflatable balloon pump inserted through the femoral artery into the thoracic aorta; it inflates during diastole to improve coronary circulation and deflates before systole to allow blood ejection from the heart
<b>ventricular assist device (VAD)</b>	A pump that takes over a ventricle's function in delivering blood into the pulmonary or systemic circuit; these devices are used to assist patients awaiting heart transplantation or those who are recovering from heart failure; most common is a left ventricular assist device (LVAD)

**Drugs**

<b>angiotensin-converting enzyme (ACE) inhibitor</b>	A drug that lowers blood pressure by blocking the formation of angiotensin II, a substance that normally acts to increase blood pressure
<b>angiotensin receptor blocker (ARB)</b>	A drug that blocks tissue receptors for angiotensin II; angiotensin II receptor antagonist
<b>antiarrhythmic agent</b>	A drug that regulates the rate and rhythm of the heartbeat
<b>beta-adrenergic blocking agent</b>	Drug that decreases the rate and strength of heart contractions; beta-blocker
<b>calcium-channel blocker</b>	Drug that controls the rate and force of heart contraction by regulating calcium entrance into the cells
<b>Coumadin</b> <i>KU-mab-din</i>	Drug that inhibits clotting by inhibiting formation of vitamin K, a factor necessary for blood coagulation. Trade name for the generic warfarin
<b>digitalis</b> <i>dij-ib-TAL-is</i>	A drug that slows and strengthens heart muscle contractions
<b>diuretic</b> <i>di-u-RET-ik</i>	Drug that eliminates fluid by increasing the kidney's output of urine; lowered blood volume decreases the heart's workload
<b>heparin</b> <i>HEP-ab-rin</i>	Substance that inhibits blood clotting by interfering with the conversion of prothrombin to thrombin (Chapter 11)
<b>hypolipidemic agent</b> <i>hi-po-lip-ih-DE-mik</i>	Drug that lowers serum cholesterol
<b>lidocaine</b> <i>LI-do-kane</i>	A local anesthetic that is used intravenously to treat cardiac arrhythmias
<b>loop diuretic</b>	Drug that increases urine output by inhibiting electrolyte reabsorption in the kidney nephrons (loops) (Chapter 14)

*(continued)*

## Terminology

## Enrichment Terms (Continued)

<b>nitroglycerin</b> <i>ni-tro-GLIS-er-in</i>	A drug used in the treatment of angina pectoris to dilate coronary vessels
<b>statins</b>	Drugs that act to lower lipids in the blood; the drug names end with <i>-statin</i> , such as lovastatin, pravastatin, and atorvastatin
<b>streptokinase (SK)</b> <i>strep-to-KI-nase</i>	An enzyme used to dissolve blood clots
<b>tissue plasminogen activator (tPA)</b>	A drug used to dissolve blood clots; it activates production of a substance (plasmin) in the blood that normally dissolves clots
<b>vasodilator</b> <i>vas-o-di-LA-tor</i>	A drug that widens blood vessels and improves blood flow

## Terminology

## Abbreviations

The abbreviations listed below are emphasized in this chapter. These are also found, collectively, with all chapter abbreviations in Appendix 2.

<b>ACE</b>	Angiotensin-converting enzyme	<b>CPR</b>	Cardiopulmonary resuscitation
<b>AED</b>	Automated external defibrillator	<b>CRP</b>	C-reactive protein
<b>AF</b>	Atrial fibrillation	<b>CTA</b>	Computed tomography angiography
<b>AMI</b>	Acute myocardial infarction	<b>CVA</b>	Cerebrovascular accident
<b>APC</b>	Atrial premature complex	<b>CVD</b>	Cardiovascular disease
<b>AR</b>	Aortic regurgitation	<b>CVI</b>	Chronic venous insufficiency
<b>ARB</b>	Angiotensin receptor blocker	<b>CVP</b>	Central venous pressure
<b>AS</b>	Aortic stenosis; arteriosclerosis	<b>DOE</b>	Dyspnea on exertion
<b>ASCVD</b>	Arteriosclerotic cardiovascular disease	<b>DVT</b>	Deep vein thrombosis
<b>ASD</b>	Atrial septal defect	<b>ECG (EKG)</b>	Electrocardiogram, electrocardiography
<b>ASHD</b>	Arteriosclerotic heart disease	<b>HDL</b>	High-density lipoprotein
<b>AT</b>	Atrial tachycardia	<b>hs-CRP</b>	High-sensitivity C-reactive protein (test)
<b>AV</b>	Atrioventricular	<b>HTN</b>	Hypertension
<b>BBB</b>	Bundle branch block (left or right)	<b>IABP</b>	Intra-aortic balloon pump
<b>BP</b>	Blood pressure	<b>ICD</b>	Implantable cardioverter defibrillator
<b>bpm</b>	Beats per minute	<b>IVCD</b>	Intraventricular conduction delay
<b>CABG</b>	Coronary artery bypass graft	<b>JVP</b>	Jugular venous pulse
<b>CAD</b>	Coronary artery disease	<b>LAD</b>	Left anterior descending (coronary artery)
<b>CCU</b>	Coronary/cardiac care unit	<b>LAHB</b>	Left anterior hemiblock
<b>CHD</b>	Coronary heart disease	<b>LDL</b>	Low-density lipoprotein
<b>CHF</b>	Congestive heart failure	<b>LV</b>	Left ventricle
<b>CK-MB</b>	Creatine kinase MB	<b>LVAD</b>	Left ventricular assist device

## Terminology

## Abbreviations (Continued)

<b>LVEDP</b>	Left ventricular end-diastolic pressure	<b>PVD</b>	Peripheral vascular disease
<b>LVH</b>	Left ventricular hypertrophy	<b>PYP</b>	Pyrophosphate (scan)
<b>MI</b>	Myocardial infarction	<b>S<sub>1</sub></b>	First heart sound
<b>mm Hg</b>	Millimeters of mercury	<b>S<sub>2</sub></b>	Second heart sound
<b>MR</b>	Mitral regurgitation, reflux	<b>SA</b>	Sinoatrial
<b>MS</b>	Mitral stenosis	<b>SBE</b>	Subacute bacterial endocarditis
<b>MUGA</b>	Multigated acquisition (scan)	<b>SK</b>	Streptokinase
<b>MVP</b>	Mitral valve prolapse	<b>SVT</b>	Supraventricular tachycardia
<b>MVR</b>	Mitral valve replacement	<b><sup>99m</sup>Tc</b>	Technetium-99m
<b>NSR</b>	Normal sinus rhythm	<b>TEE</b>	Transesophageal echocardiography
<b>P</b>	Pulse	<b>Tn</b>	Troponin
<b>PAC</b>	Premature atrial contraction	<b>tPA</b>	Tissue plasminogen activator
<b>PAP</b>	Pulmonary arterial pressure	<b>VAD</b>	Ventricular assist device
<b>PCI</b>	Percutaneous coronary intervention	<b>VF, v fib</b>	Ventricular fibrillation
<b>PCWP</b>	Pulmonary capillary wedge pressure	<b>VLDL</b>	Very-low-density lipoprotein
<b>PMI</b>	Point of maximal impulse	<b>VPC</b>	Ventricular premature complex
<b>PSVT</b>	Paroxysmal supraventricular tachycardia	<b>VSD</b>	Ventricular septal defect
<b>PTCA</b>	Percutaneous transluminal coronary angioplasty	<b>VT</b>	Ventricular tachycardia
<b>PVC</b>	Premature ventricular contraction	<b>VTE</b>	Venous thromboembolism
		<b>WPW</b>	Wolff–Parkinson–White syndrome

## Case Study Revisited

## Carlos's Follow-Up

Carlos was scheduled the next day for his procedure. He arrived at the hospital in the morning and was taken to the operating room after the nurse prepared him for surgery. His cardiologist performed a pulmonary vein catheter ablation. The procedure involved destruction of that portion of the heart's conduction pathway that is involved in the arrhythmia. The surgery was uneventful with no complications and Carlos was released to go home that day. He was told he might feel some discomfort at the catheter insertion site and might also experience mild chest discomfort, mild shortness of breath, and fatigue. Discharge instructions included restricted activity during the next week, including not lifting an object weighing more than 10 pounds, no

pushing or pulling heavy objects, such as mowing the lawn, and to stop any activity before becoming tired. Before his parents took him home, Carlos scheduled a follow-up appointment with the cardiologist in 1 week.

At his 1-week follow-up appointment Carlos said he initially had some mild chest pain for 2 days following the surgery but that pain had since gone away. His procedure site had healed nicely and his ECG showed normal sinus rhythm. At his extended follow-up appointments with the cardiologist he had no recurrence of the atrial fibrillation. Carlos's pre-existing heart condition, however, prohibited him from performing required duties in the army, so he was not able to return to boot camp. He was released from the service and returned to civilian life.



This review tests your understanding of the content introduced in this chapter. Follow the instructions for each exercise and check your answers in Appendix 11.

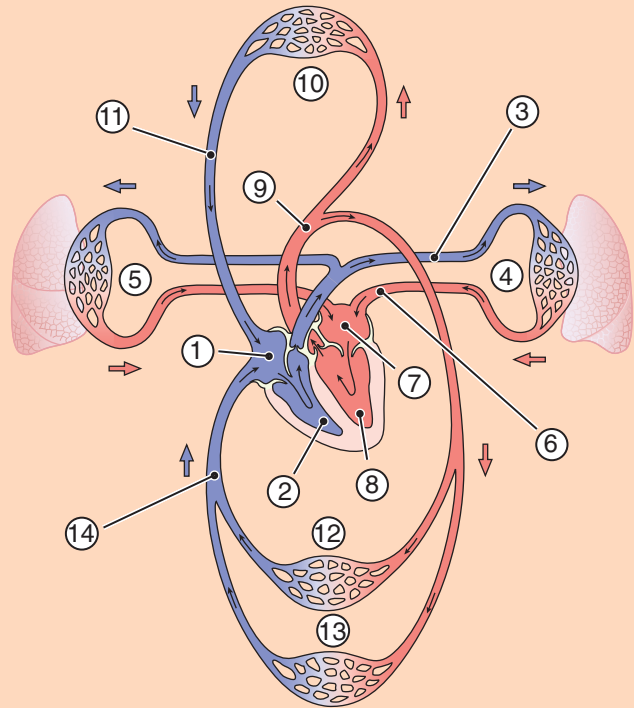
### LABELING EXERCISE

#### THE CARDIOVASCULAR SYSTEM

Write the name of each numbered part on the corresponding line of the answer sheet.

- |                       |                     |
|-----------------------|---------------------|
| Aorta                 | Left pulmonary vein |
| Head and arms         | Left ventricle      |
| Inferior vena cava    | Legs                |
| Internal organs       | Right atrium        |
| Left atrium           | Right lung          |
| Left lung             | Right ventricle     |
| Left pulmonary artery | Superior vena cava  |

1. \_\_\_\_\_
2. \_\_\_\_\_
3. \_\_\_\_\_
4. \_\_\_\_\_
5. \_\_\_\_\_
6. \_\_\_\_\_
7. \_\_\_\_\_
8. \_\_\_\_\_
9. \_\_\_\_\_
10. \_\_\_\_\_
11. \_\_\_\_\_
12. \_\_\_\_\_
13. \_\_\_\_\_
14. \_\_\_\_\_



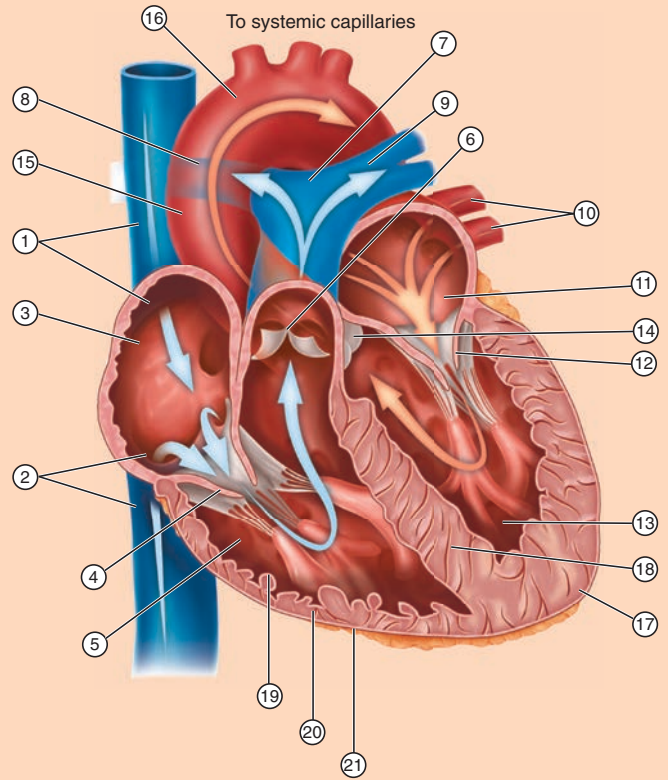
■ Blood high in oxygen  
■ Blood low in oxygen

**THE HEART AND GREAT VESSELS**

Write the name of each numbered part on the corresponding line of the answer sheet.

- |  |  |
|--|--|
| Aortic arch                            | Left pulmonary veins                     |
| Aortic valve                           | Left ventricle                           |
| Apex                                   | Myocardium                               |
| Ascending aorta                        | Pulmonary trunk                          |
| Endocardium                            | Pulmonary valve                          |
| Epicardium                             | Right atrioventricular (tricuspid) valve |
| Inferior vena cava                     | Right atrium                             |
| Interventricular septum                | Right pulmonary artery                   |
| Left atrioventricular (bicuspid) valve | Right ventricle                          |
| Left atrium                            | Superior vena cava                       |
| Left pulmonary artery                  |  |

1. \_\_\_\_\_
2. \_\_\_\_\_
3. \_\_\_\_\_
4. \_\_\_\_\_
5. \_\_\_\_\_
6. \_\_\_\_\_
7. \_\_\_\_\_
8. \_\_\_\_\_
9. \_\_\_\_\_
10. \_\_\_\_\_
11. \_\_\_\_\_
12. \_\_\_\_\_
13. \_\_\_\_\_
14. \_\_\_\_\_
15. \_\_\_\_\_



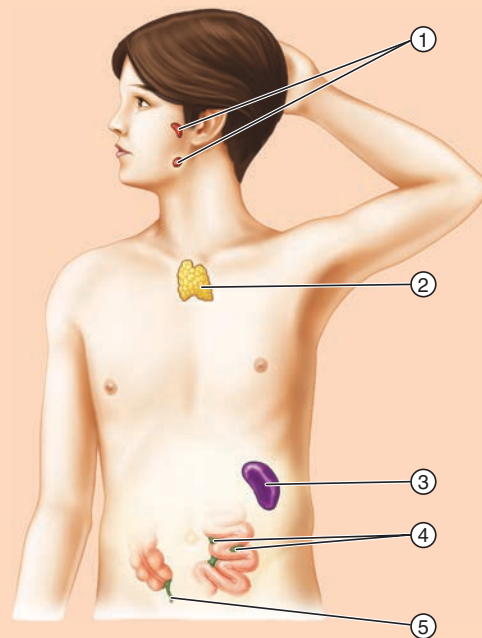
16. \_\_\_\_\_
17. \_\_\_\_\_
18. \_\_\_\_\_
19. \_\_\_\_\_
20. \_\_\_\_\_
21. \_\_\_\_\_

**LOCATION OF LYMPHOID ORGANS AND TISSUE**

Write the name of each numbered part on the corresponding line of the answer sheet.

- |               |         |
|---------------|---------|
| Appendix      | Thymus  |
| Peyer patches | Tonsils |
| Spleen        |         |

1. \_\_\_\_\_
2. \_\_\_\_\_
3. \_\_\_\_\_
4. \_\_\_\_\_
5. \_\_\_\_\_





## TERMINOLOGY

### MATCHING

Match the following terms, and write the appropriate letter to the left of each number.

- |                        |  |
|------------------------|--|
| ___ 1. atherosclerosis | a. twisted and swollen vessel                |
| ___ 2. varix           | b. blockage                                  |
| ___ 3. occlusion       | c. absence of a heartbeat                    |
| ___ 4. aneurysm        | d. localized dilatation of a vessel          |
| ___ 5. asystole        | e. accumulation of fatty deposits            |
| ___ 6. thrombosis      | a. ineffective quivering of muscle           |
| ___ 7. myocarditis     | b. formation of a blood clot in a vessel     |
| ___ 8. infarction      | c. inflammation of the heart muscle          |
| ___ 9. fibrillation    | d. local deficiency of blood                 |
| ___ 10. ischemia       | e. local death of tissue                     |
| ___ 11. lumen          | a. vessel that empties into the right atrium |
| ___ 12. pericardium    | b. fibrous sac around the heart              |
| ___ 13. apex           | c. structure that keeps fluid moving forward |
| ___ 14. vena cava      | d. central opening of a vessel               |
| ___ 15. valve          | e. lower, pointed region of the heart        |
| ___ 16. HDL            | a. stroke                                    |
| ___ 17. HTN            | b. a type of blood lipid                     |
| ___ 18. VT             | c. rapid beat in the heart's lower chambers  |
| ___ 19. CVA            | d. high blood pressure                       |
| ___ 20. CABG           | e. surgery to bypass a blocked vessel        |

### Enrichment Terms

- |                       |                                       |
|-----------------------|---------------------------------------|
| ___ 21. diuretic      | a. removal of plaque                  |
| ___ 22. regurgitation | b. drug that increases urinary output |
| ___ 23. streptokinase | c. premature contraction              |
| ___ 24. atherectomy   | d. drug used to dissolve blood clots  |
| ___ 25. extrasystole  | e. backward flow                      |

### FILL IN THE BLANKS

Complete the sentence with the correct term(s).

26. The heart muscle is the \_\_\_\_\_.
27. A microscopic vessel through which materials are exchanged between the blood and the tissues is a(n) \_\_\_\_\_.
28. Each upper receiving chamber of the heart is a(n) \_\_\_\_\_.
29. A sinus rhythm originates in the \_\_\_\_\_.
30. The largest artery is the \_\_\_\_\_.
31. A phlebotomist (*fleh-BOT-o-mist*) is one who drains blood from a(n) \_\_\_\_\_.
32. The term *varicoid* pertains to a(n) \_\_\_\_\_.
33. The lymphoid organ in the chest is the \_\_\_\_\_.
34. Blood returning to the heart from the systemic circuit enters the chamber called the \_\_\_\_\_.
35. At its termination in the abdomen, the aorta divides into the right and left (see FIG. 10-6) \_\_\_\_\_.
36. The large artery in the neck that supplies blood to the brain is the (see FIG. 10-6) \_\_\_\_\_.

37. The large vein that drains the lower body and empties into the heart is the (see FIG. 10-7) \_\_\_\_\_ .
38. The right lymphatic duct and the thoracic duct drain into vessels called the (see FIG. 10-19) \_\_\_\_\_ .
39. In Carlos's case study, the device he wore to record his heart rhythm is called a(n) \_\_\_\_\_ .
40. The abnormal heart rhythm that prevented Carlos from completing basic training is termed \_\_\_\_\_ .
41. The catheterization technique used to correct Carlos's arrhythmia is termed cardiac \_\_\_\_\_ .

### TRUE-FALSE

Examine the following statements. If the statement is true, write T in the first blank. If the statement is false, write F in the first blank, and correct the statement by replacing the underlined word in the second blank.

	True or False	Correct Answer
42. The left AV valve is the <u>aortic</u> valve.	_____	_____
43. The pulmonary vein carries blood to the <u>lungs</u> .	_____	_____
44. The brachial artery supplies blood to the <u>leg</u> .	_____	_____
45. <u>Diastole</u> is the relaxation phase of the heart cycle.	_____	_____
46. The <u>left ventricle</u> pumps blood into the aorta.	_____	_____
47. Blood returning from the lungs to the heart enters the <u>left atrium</u> .	_____	_____
48. The <u>systemic circuit</u> pumps blood to the lungs.	_____	_____
49. An <u>artery</u> is a vessel that carries blood back to the heart.	_____	_____
50. Peyer patches are in the <u>intestine</u> .	_____	_____
51. <u>Bradycardia</u> is a lower-than-average heart rate.	_____	_____
52. A beta-adrenergic blocking agent <u>slows</u> the heart rate.	_____	_____

### ELIMINATIONS

In each of the sets below, underline the word that does not fit in with the rest and explain the reason for your choice.

53. SA node — Purkinje fibers — apex — AV node — AV bundle
- \_\_\_\_\_

54. murmur — systolic — sphygmomanometer — mm Hg — diastolic
- \_\_\_\_\_

55. U — S<sub>1</sub> — QRS — T — P
- \_\_\_\_\_

56. thymus — spleen — cusp — tonsil — Peyer patches
- \_\_\_\_\_

### DEFINITIONS

Define the following terms.

57. avascular (*a-VAS-ku-lar*) \_\_\_\_\_
58. atriotomy (*a-tre-OT-o-me*) \_\_\_\_\_
59. splenectomy (*sple-NEK-to-me*) \_\_\_\_\_
60. supraventricular (*su-prah-ven-TRIK-u-lar*) \_\_\_\_\_
61. phlebectasis (*fleb-EK-tah-sis*) \_\_\_\_\_

*Write words for the following definitions.*

62. An instrument (-tome) for incising a valve \_\_\_\_\_
63. Suture (-rhaphy) of the aorta \_\_\_\_\_
64. Excision of a lymph node \_\_\_\_\_
65. Physician who specializes in study and treatment of the heart \_\_\_\_\_
66. Stoppage (-stasis) of lymph flow \_\_\_\_\_
67. Surgical fixation (-pexy) of the spleen \_\_\_\_\_

*Use the root aort/o to write words with the following meanings.*

68. Narrowing (-stenosis) of the aorta \_\_\_\_\_
69. Downward displacement (-ptosis) of the aorta \_\_\_\_\_
70. Radiograph (-gram) of the aorta \_\_\_\_\_
71. Before or in front of (pre-) the aorta \_\_\_\_\_

### ADJECTIVES

*Write the adjective form of the following words.*

72. ventricle \_\_\_\_\_
73. septum \_\_\_\_\_
74. valve \_\_\_\_\_
75. thymus \_\_\_\_\_
76. sclerosis \_\_\_\_\_
77. spleen \_\_\_\_\_

### PLURALS

*Write the plural form of the following words.*

78. thrombus \_\_\_\_\_
79. varix \_\_\_\_\_
80. stenosis \_\_\_\_\_
81. septum \_\_\_\_\_

### ABBREVIATIONS

*Write the meaning of the following abbreviations as they apply to the cardiovascular system.*

82. AED \_\_\_\_\_
83. LVAD \_\_\_\_\_
84. DVT \_\_\_\_\_
85. VF \_\_\_\_\_
86. BBB \_\_\_\_\_
87. PTCA \_\_\_\_\_

**WORD BUILDING**

Write words for the following definitions using the word parts given. Each word part can be used more than once.

-pathy phleb lymph/o -oma angi/o -itis aden/o -plasty

88. inflammation of a vein \_\_\_\_\_
89. any disease of a lymph node \_\_\_\_\_
90. neoplasm involving the lymphatic system \_\_\_\_\_
91. plastic repair of any vessel \_\_\_\_\_
92. inflammation of a lymphatic vessel \_\_\_\_\_
93. any disease of a vessel \_\_\_\_\_
94. inflammation of a lymph node \_\_\_\_\_
95. plastic repair of a vein \_\_\_\_\_
96. neoplasm of a lymph node \_\_\_\_\_
97. tumor involving any vessels \_\_\_\_\_

**WORD ANALYSIS**

Define the following words and give the meaning of the word parts in each. Use a dictionary if necessary.

98. phonocardiography (*fo-no-kar-de-OG-rah-fe*)
- a. phon/o \_\_\_\_\_
- b. cardi/o \_\_\_\_\_
- c. -graphy \_\_\_\_\_
99. endarterectomy (*end-ar-ter-EK-to-me*)
- a. end/o \_\_\_\_\_
- b. arteri/o \_\_\_\_\_
- c. ecto- \_\_\_\_\_
- d. -tomy \_\_\_\_\_
100. telangiectasia (*tel-an-je-ek-TA-ze-ah*)
- a. tel- \_\_\_\_\_
- b. angi/o \_\_\_\_\_
- c. -ectasia \_\_\_\_\_
101. lymphangiophlebitis (*lim-fan-je-o-fleb-BI-tis*)
- a. lymph/o \_\_\_\_\_
- b. angi/o \_\_\_\_\_
- c. phleb/o \_\_\_\_\_
- d. -itis \_\_\_\_\_

## Additional Case Studies

### Case Study 10-1A: Percutaneous Transluminal Coronary Angioplasty (PTCA) and Echocardiogram

Greta, a 68 y/o woman, was admitted to the coronary care unit (CCU) with chest pain, dyspnea, diaphoresis, syncope, and nausea. She had taken three sublingual doses of nitroglycerin tablets within a 10-minute time span without relief before dialing 911. A previous stress test and thallium uptake scan suggested cardiac disease.

Her family history was significant for cardiovascular disease. Her father died at the age of 62 of an acute myocardial infarction (AMI). Her mother had bilateral carotid endarterectomies and a femoral popliteal bypass procedure and died at the age of 72 of congestive heart failure (CHF). Greta's elder sister died from a ruptured aortic aneurysm at the age of 65. Greta's electrocardiogram (ECG) on admission showed tachycardia with a rate of 126 bpm with inverted T waves. A murmur was heard at  $S_1$ . Her skin color was dusky to cyanotic on her lips and fingertips. Her

admitting diagnosis was possible coronary artery disease (CAD), acute myocardial infarction, and valvular disease.

Cardiac catheterization with balloon angioplasty (PTCA) was performed the next day. Significant stenosis of the left anterior descending coronary artery was shown and treated with angioplasty and stent placement. Left ventricular function was normal.

Echocardiography, 2 days later, showed normal-sized left and enlarged right ventricular cavities. The mitral valve had normal amplitude of motion. The anterior and posterior leaflets moved in opposite directions during diastole. There was a late systolic prolapse of the mitral leaflet at rest. The left atrium was enlarged. The impression of the study was mitral prolapse with regurgitation. Surgery was recommended.

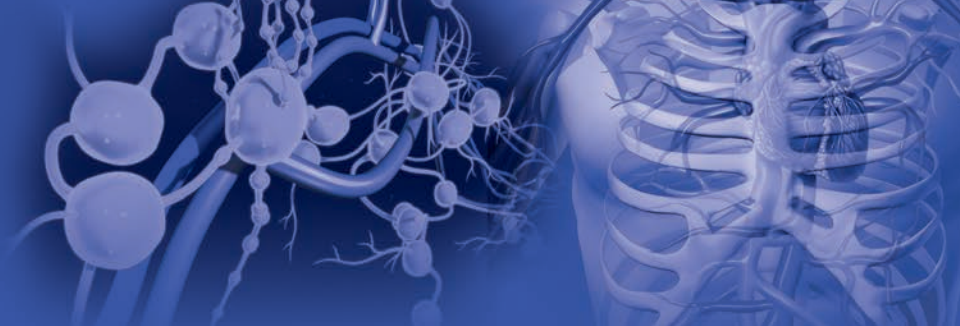### Case 10-1B: Mitral Valve Replacement (MVR) Operative Report

Greta was transferred to the operating room, placed in a supine position, and given general endotracheal anesthesia. The surgeon entered her pericardium longitudinally through a median sternotomy and found that her heart was enlarged, with a dilated right ventricle. The left atrium was dilated. Preoperative transesophageal echocardiography revealed severe mitral regurgitation with severe posterior and anterior prolapse. Extracorporeal circulation was established. The aorta was cross-clamped, and cardioplegic solution (to stop the heartbeat) was given into the aortic root intermittently for myocardial protection.

The left atrium was entered via the interatrial groove on the right, exposing the mitral valve. The middle scallop of the posterior leaflet was resected. The remaining leaflets were removed to the areas of the commissures and preserved for the sliding plasty. The elongated chordae were shortened to better anchor the valve cusps. The

surgeon slid the posterior leaflet across the midline and sutured it in place. A no. 30 annuloplasty ring was sutured in place with interrupted no. 2-0 Dacron suture. The valve was tested by inflating the ventricle with NSS and proved to be competent. The left atrium was closed with continuous no. 4-0 Prolene suture. Air was removed from the heart. The cross-clamp was removed. Cardiac action resumed with normal sinus rhythm. After a period of cardiac recovery and attainment of normothermia, cardiopulmonary bypass was discontinued.

Protamine was given to counteract the heparin. Pacer wires were placed in the right atrium and ventricle. Silicone catheters were placed in the pleural and substernal spaces. The sternum and soft tissue wound was closed. Greta recovered from her surgery and was discharged 6 days later.



## Case Studies 10-1A and 10-1B Questions

Follow the instructions for each question and check your answers in Appendix 11.

**Multiple Choice.** Select the best answer, and write the letter of your choice to the left of each number.

- |   |  |
|---|--|
| _____ 1. The word transluminal means                        | _____ 5. Sternotomy is   |
| a. across a wall  | a. incision into the sternum   |
| b. between branches   | b. removal of the sternum  |
| c. through a valve  | c. narrowing of the sternum  |
| d. through a central opening                                | d. surgical fixation of the sternum  |
| _____ 2. The term that means backflow, as of blood, is      | _____ 6. Extracorporeal circulation occurs   |
| a. infarction   | a. within the brain  |
| b. regurgitation  | b. within the pericardium  |
| c. amplitude  | c. outside the body  |
| d. prolapse   | d. in the legs   |
| _____ 3. The term for a narrowing of the bicuspid valve is  | _____ 7. Protamine was given to counteract the action of the heparin. This drug action is described as |
| a. atrial stenosis  | a. antagonistic  |
| b. tricuspid prolapse                                       | b. synergy   |
| c. mitral stenosis  | c. potentiating  |
| d. pulmonic prolapse  | d. simulation  |
| _____ 4. Blowout of a dilated segment of the main artery is |  |
| a. peritoneal infarction                                    |  |
| b. coarctation of the aorta                                 |  |
| c. cardiac tamponade  |  |
| d. ruptured aortic aneurysm                                 |  |

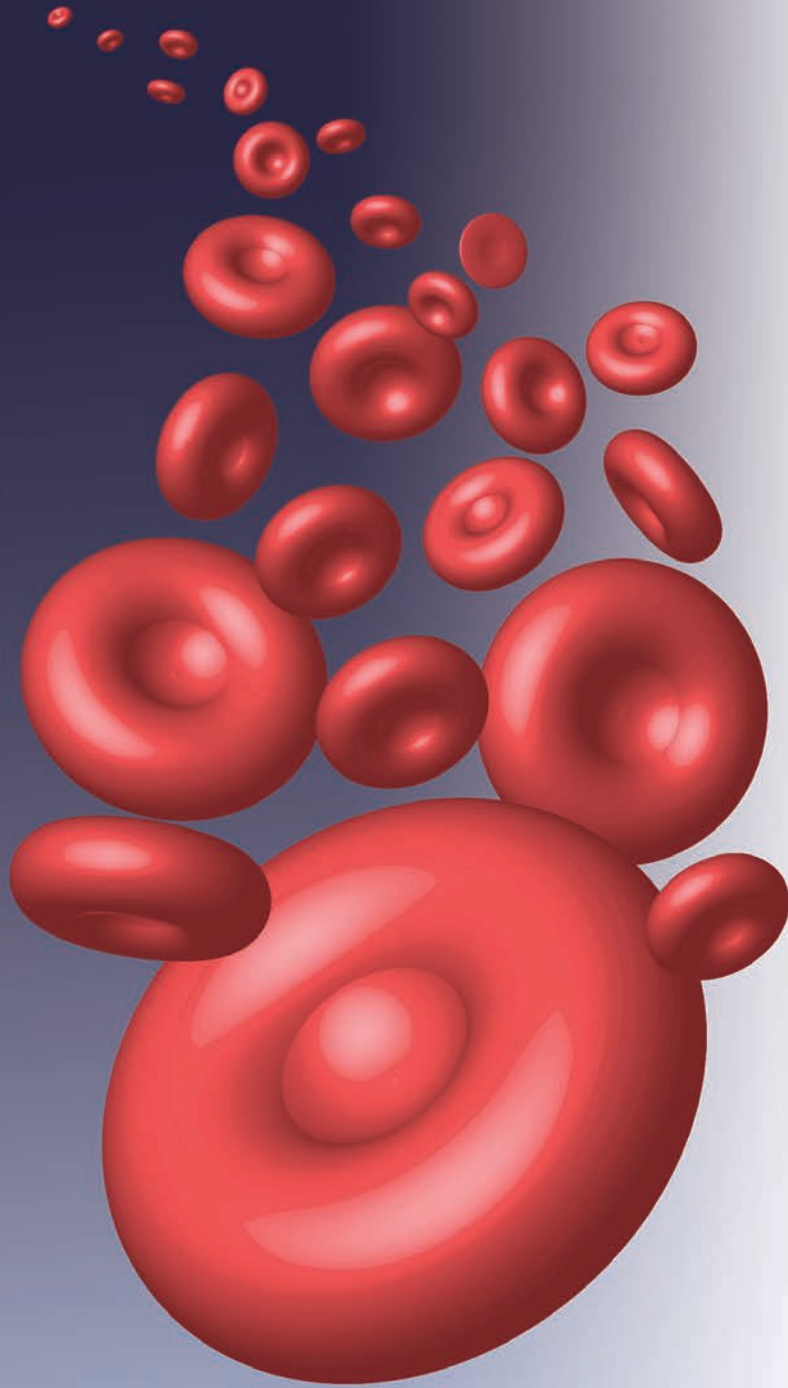
Write the word or phrase from the case studies that means each of the following.

8. Shortness of breath \_\_\_\_\_
9. An abnormal heart sound \_\_\_\_\_
10. Test of cardiac function during physical exertion \_\_\_\_\_
11. Pertaining to both the heart and blood vessels \_\_\_\_\_
12. Excision of the inner lining along with atherosclerotic plaque from an artery (plural) \_\_\_\_\_
13. Under the tongue \_\_\_\_\_
14. Bluish discoloration of the skin due to lack of oxygen \_\_\_\_\_
15. The state of profuse perspiration \_\_\_\_\_
16. Between the atria \_\_\_\_\_
17. Below the sternum \_\_\_\_\_

Define the following abbreviations.

18. ECG \_\_\_\_\_
19. AMI \_\_\_\_\_
20. CAD \_\_\_\_\_
21. LAD \_\_\_\_\_
22. CHF \_\_\_\_\_
23. TEE \_\_\_\_\_
24. MVR \_\_\_\_\_
25. CCU \_\_\_\_\_

# Blood and Immunity



## Pretest

**Multiple Choice.** Select the best answer, and write the letter of your choice to the left of each number. To check your answers go to Appendix 11.

- \_\_\_\_\_ 1. Erythrocyte is the scientific name for a
  - a. white blood cell
  - b. lymphocyte
  - c. red blood cell
  - d. muscle cell
- \_\_\_\_\_ 2. Platelets, or thrombocytes, are involved in
  - a. digestion
  - b. inflammation
  - c. immunity
  - d. blood clotting
- \_\_\_\_\_ 3. The white blood cells active in immunity are the
  - a. chondrocytes
  - b. lymphocytes
  - c. adipose cells
  - d. hematids
- \_\_\_\_\_ 4. Substances produced by immune cells that counteract microorganisms and other foreign materials are called
  - a. antigens
  - b. antibodies
  - c. anticoagulants
  - d. Rh factors
- \_\_\_\_\_ 5. A deficiency of hemoglobin results in the disorder called
  - a. hypertension
  - b. chromatosis
  - c. anemia
  - d. hemophilia
- \_\_\_\_\_ 6. A neoplastic overgrowth of white blood cells is called
  - a. leukemia
  - b. anemia
  - c. fibrosis
  - d. cystitis

## Learning Objectives

After careful study of this chapter, you should be able to:

- 1 Describe the composition of the blood plasma. **P358**
- 2 Describe and give the functions of the three types of blood cells. **P358**
- 3 Differentiate the five different types of leukocytes. **P360**
- 4 Explain the basis of blood types. **P361**
- 5 Define immunity, and list the possible sources of immunity. **P364**
- 6 Identify and use roots and suffixes pertaining to the blood and immunity. **P367**
- 7 Identify and use roots pertaining to blood chemistry. **P369**
- 8 List and describe three major disorders of the blood. **P370**
- 9 Describe the major tests used to study blood. **P370**
- 10 List and describe three major disorders of the immune system. **P374**
- 11 Interpret abbreviations used in blood studies. **P380**
- 12 Analyze medical terms in several case studies involving the blood. **PP357, 388**

## Case Study: Nurse Anesthetist Olivia With Latex Allergy



### Chief Complaint

Olivia, a 36 y/o certified registered nurse anesthetist (CRNA), noticed that her hands had a red patchy rash when she removed her gloves

following cases in the OR. They began to itch after a few minutes of donning the gloves, so she figured she might have developed an allergy to the latex they contained. When she began to have a runny nose and itchy swollen eyes, she was worried and sought medical advice from her primary care physician, who referred her to an allergist.

### Examination

The allergist examined Olivia's hands and observed a localized red crusty rash that stopped at the wrists. There were a few blisters spread over the hand region. Along with the examination, a history indicated Olivia had noticed the contact dermatitis for a while when she wore powdered latex gloves in the OR, and she more recently had noted generalized allergic symptoms during surgical cases. During a recent case, she experienced some

tachycardia, urticaria (hives), and rhinitis when she came in contact with latex gloves.

### Clinical Course

Olivia was diagnosed with a type I hypersensitivity, IgE, T cell-mediated latex allergy, as shown by both immunologic and skin-prick tests. Although Olivia is a CRNA, she was educated on the course of latex allergies. She was reminded that there is no cure and that the only way to prevent an allergic reaction is to avoid coming into contact with latex.

This chapter describes the composition and characteristics of blood, the life-sustaining fluid that circulates throughout the body. A discussion of immunity is included because many components of the immune system are carried in the blood. Olivia's case of allergy is an example of immunologic hyperactivity. One of the symptoms, tachycardia, was discussed in Chapter 10 and rhinitis will be introduced in the next chapter on the respiratory system.

**Case Study Revisited:** Once you complete this chapter, please review the case follow-up on p. 381.

## Ancillaries At-A-Glance

Visit the web resource to access the following resources.



### Learning Resources

- eBook
- A&P Module with Heart & Lung Sounds
- Image Bank
- TestPrep
- Animations
- Audio Pronunciation Glossary

## Introduction

**Blood** is the fluid that circulates through the vessels, bringing oxygen and nourishment to all cells and carrying away carbon dioxide and other waste products. The blood also distributes body heat and carries special substances, such as antibodies and hormones. Certain blood cells are a major component of the immune system, which protects against disease. This chapter thus includes a discussion of the immune system.

## Blood

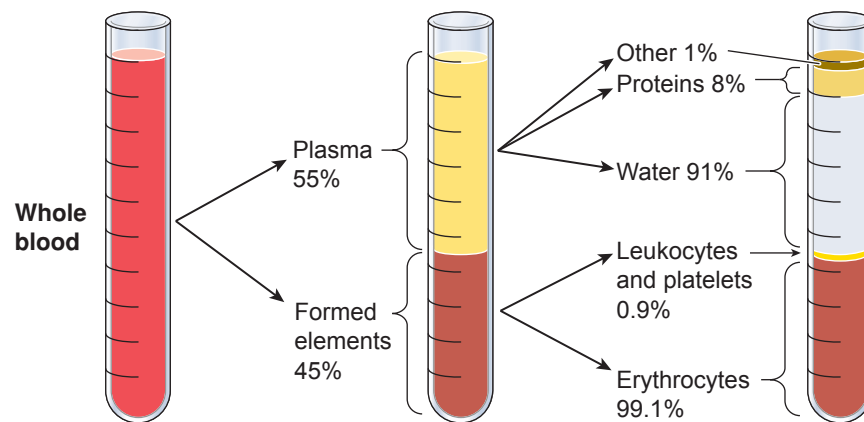
The total adult blood volume is about 5 L (5.2 qt). Whole blood can be divided into two main components: the liquid portion, or **plasma** (55%), and **formed elements**, more commonly known as blood cells (45%) (**FIG. 11-1**).

## BLOOD PLASMA

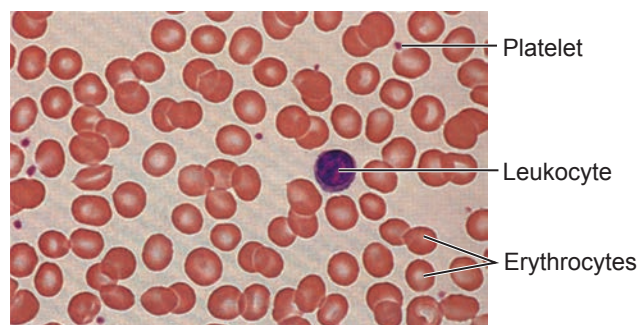
Plasma is about 90% water. The remaining 10% contains nutrients, **electrolytes** (dissolved salts), gases, **albumin** (a protein), clotting factors, antibodies, wastes, enzymes, and hormones. Laboratories test for a multitude of these substances in blood chemistry tests. The pH (relative acidity) of the plasma remains steady at about 7.4.

## BLOOD CELLS

The blood cells (**FIG. 11-2**) include **erythrocytes**, or red blood cells (RBCs); **leukocytes**, or white blood cells (WBCs); and **platelets**, also called **thrombocytes**. All blood cells are produced in red bone marrow. Some WBCs multiply in lymphoid tissue as well. For Your Reference **BOX 11-1** summarizes the different types of blood cells; **BOX 11-2** discusses time-saving acronyms, such as RBC and WBC.



**FIGURE 11-1** Composition of whole blood. Percentages show the relative proportions of the different components of plasma and formed elements.



**FIGURE 11-2** Blood cells. When viewed under a microscope, all three types of formed elements are visible.



## FOR YOUR REFERENCE

### Blood Cells

BOX 11-1

Cell Type	Number Per Microliter of Blood	Description	Function
Erythrocyte (red blood cell)	5 million	Tiny (7 $\mu\text{m}$ diameter), biconcave disk without nucleus (anuclear)	Carries oxygen bound to hemoglobin; also carries some carbon dioxide and buffers blood
Leukocyte (white blood cell)	5,000 to 10,000	Larger than red cell with prominent nucleus that may be segmented (granulocyte) or unsegmented (agranulocyte); types vary in staining properties	Immunity; protects against pathogens and destroys foreign matter and debris; located in blood, tissues, and lymphatic system
Platelet (thrombocyte)	150,000 to 450,000	Fragment of large cell (megakaryocyte)	Hemostasis; forms a platelet plug and starts blood clotting (coagulation)



## FOCUS ON WORDS

### Acronyms

BOX 11-2

Acronyms are abbreviations that use the first letters of the words in a name or phrase. They have become very popular because they save time and space in writing as the number and complexity of technical terms increases. Some examples that apply to studies of the blood are CBC (complete blood count) and RBC and WBC for red and white blood cells. Some other common acronyms are CNS (central nervous system or clinical nurse specialist), ECG (electrocardiogram), NIH (National Institutes of Health), and STI (sexually transmitted infection).

If the acronym has vowels and lends itself to pronunciation, it may be used as a word in itself, such as AIDS (acquired immunodeficiency syndrome); ELISA (enzyme-linked immunosorbent

assay); *JAMA* (*Journal of the American Medical Association*); NSAID (nonsteroidal antiinflammatory drug), pronounced “en-sayd”; and CABG (coronary artery bypass graft), which inevitably becomes “cabbage.” Few people even know that LASER is an acronym that means “light amplification by stimulated emission of radiation.”

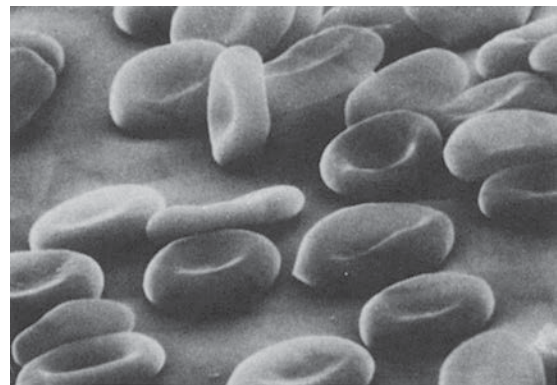
An acronym is usually introduced the first time a phrase appears in an article and is then used without explanation. If you have spent time searching back through an article in frustration for the meaning of an acronym, you probably wish, as do other readers, that all the acronyms used and their meanings would be listed at the beginning of each article.

### Erythrocytes

The major function of erythrocytes is to carry oxygen to cells. This oxygen is bound to an iron-containing pigment in the cells called **hemoglobin**. Erythrocytes are small, disk-shaped cells with no nuclei (FIG. 11-3). Their concentration of about 5 million per microliter ( $\mu\text{L}$  or  $\text{m}\mu\text{L}$ ) of blood makes them by far the most numerous of the blood cells. The hemoglobin that they carry averages 15 g/dL (100 mL) of blood. An RBC gradually wears out and dies in about 120 days, so these cells must be constantly replaced. Production of red cells in the bone marrow is regulated by the hormone **erythropoietin** (EPO), which is made in the kidneys.

### Leukocytes

All WBCs show prominent nuclei when stained. They total about 5,000 to 10,000/ $\mu\text{L}$ , but their number may increase



**FIGURE 11-3 Erythrocytes (red blood cells).** The cells are seen under a scanning electron microscope, which gives a three-dimensional view.

during infection. There are five types of leukocytes that vary in their relative percentages and their functions. The different types are identified by the size and appearance of the nucleus, by their staining properties, and by whether or not they show visible granules in the cytoplasm when stained. The five types are illustrated and compared in **BOX 11-3**. Classified as granulocytes or agranulocytes, they are as follows:

- **Granulocytes**, or granular leukocytes, have visible granules in the cytoplasm when stained. A granulocyte has a segmented nucleus. There are three types of granulocytes, named for the kind of stain (dye) the granules take up:
  - **Neutrophils** stain weakly with both acidic and basic dyes.
  - **Eosinophils** stain strongly with acidic dyes.
  - **Basophils** stain strongly with basic dyes.



## FOR YOUR REFERENCE

### Leukocytes (White Blood Cells)

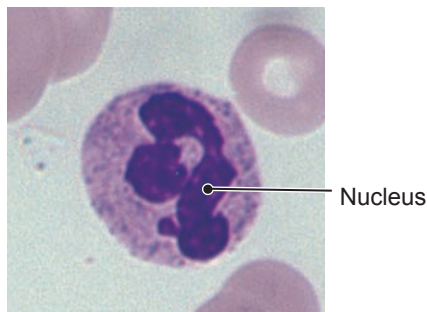BOX 11-3

Cell Type	Relative Percentage (Adult)	Function
<b>GRANULOCYTE</b>		
<b>Neutrophil</b> <i>NU-tro-fil</i>	54 to 62 percent	phagocytosis
<b>Eosinophil</b> <i>e-o-SIN-o-fil</i>	1 to 3 percent	allergic reactions; defense against parasites
<b>Basophil</b> <i>BA-so-fil</i>	less than 1 percent	allergic reactions
<b>AGRANULOCYTE</b>		
<b>Lymphocyte</b> <i>LIM-fo-site</i>	25 to 38 percent	immunity (T cells and B cells)
<b>Monocyte</b> <i>MON-o-site</i>	3 to 7 percent	phagocytosis

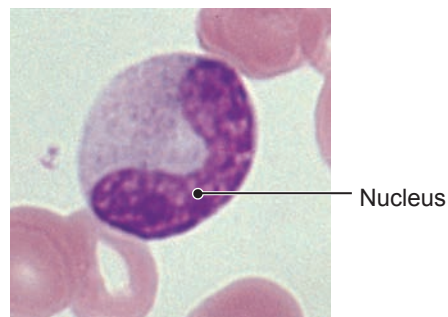- **Agranulocytes** do not show visible granules when stained. An agranulocyte's nucleus is large and either round or curved. There are two types of agranulocytes:
  - **Lymphocytes** are the smaller agranulocytes.
  - **Monocytes** are the largest of all the WBCs.

WBCs protect against foreign substances. Some engulf foreign material by the process of **phagocytosis** (see Fig. 3-3); others have different functions in the immune system. In diagnosis, it is important to know not only the total number of leukocytes but also the relative number of each type, because these numbers can change in different disease conditions. Laboratories report these numbers as a differential count (Diff), which is part of a complete blood count (CBC).

The most numerous WBCs, neutrophils, are called *polymorphs* because of the various shapes of their nuclei. They are also referred to as *segs*, *polys*, or *PMNs* (*polymorphonuclear leukocytes*). A **band cell**, also called a *stab cell*, is an immature neutrophil with a solid curved nucleus



**A** Mature neutrophil



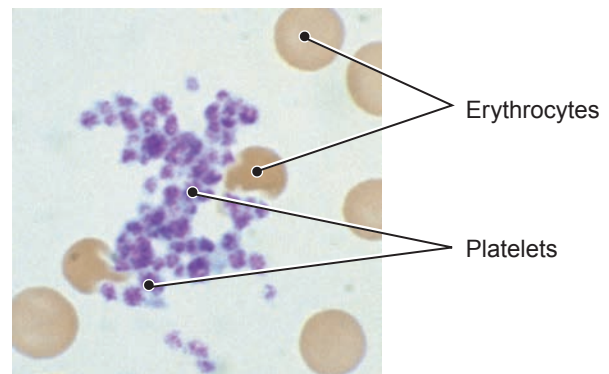
**B** Band cell  
(immature neutrophil)

(FIG. 11-4). Large numbers of band cells in the blood indicate an active infection.

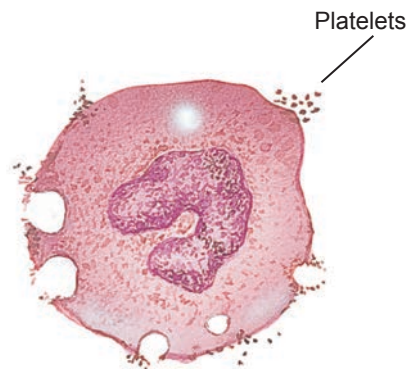
### Platelets

The blood platelets (thrombocytes) are not complete cells, but fragments of large cells named **megakaryocytes**, which form in bone marrow (FIG. 11-5). They number from 200,000 to 400,000/ $\mu\text{L}$  of blood. Platelets are important in **hemostasis**, the prevention of blood loss, which includes the process of blood clotting, or **coagulation**.

When a vessel is injured, platelets stick together to form a plug at the site. Substances released from the platelets and from damaged tissue then interact with clotting factors in the plasma to produce a wound-sealing clot. Clotting factors are inactive in the blood until an injury occurs. To protect against unwanted clot formation, 12 factors must interact before blood coagulates. The final reaction is the conversion of **fibrinogen** to threads of **fibrin** that trap blood cells and plasma to produce the clot (FIG. 11-6). The plasma that remains after blood coagulates is **serum**.



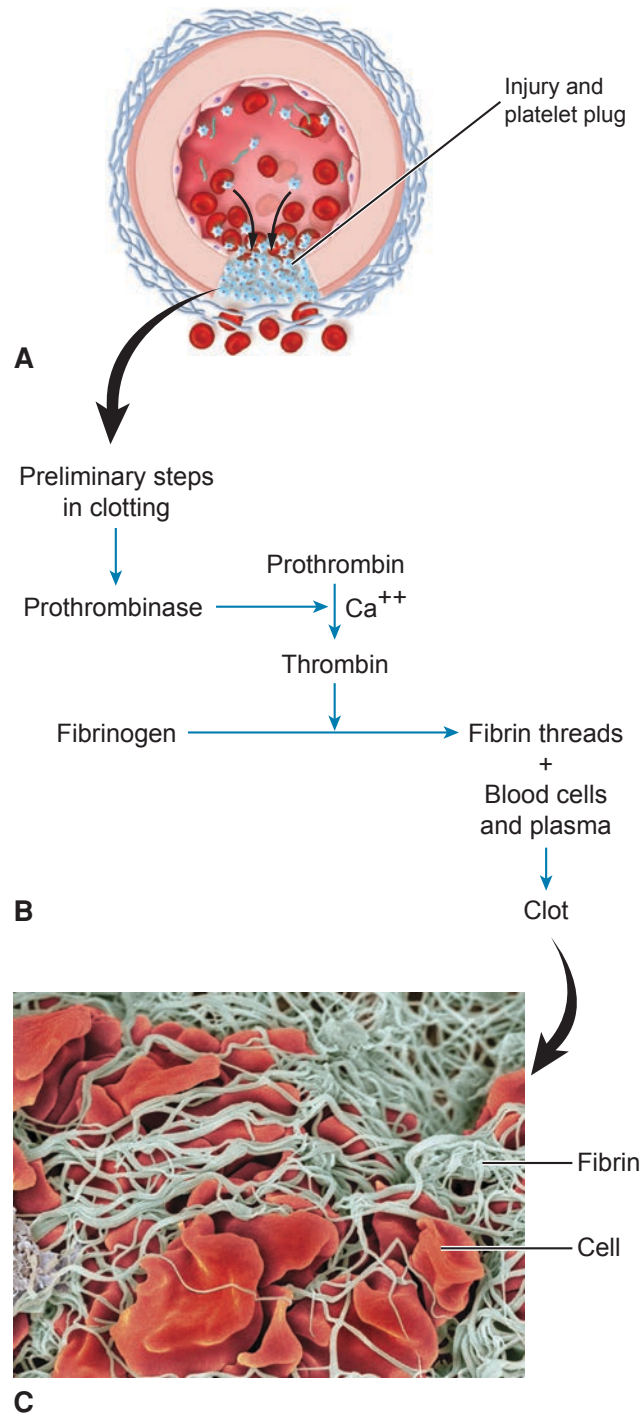
**A** Platelets



**B** Megakaryocyte

**FIGURE 11-4 Band cell.** **A.** A mature neutrophil. **B.** A band cell, or stab cell, is an immature neutrophil with a thick curved nucleus.

**FIGURE 11-5 Platelets (thrombocytes).** **A.** Platelets seen in a blood smear under the microscope. **B.** A megakaryocyte releases platelets.



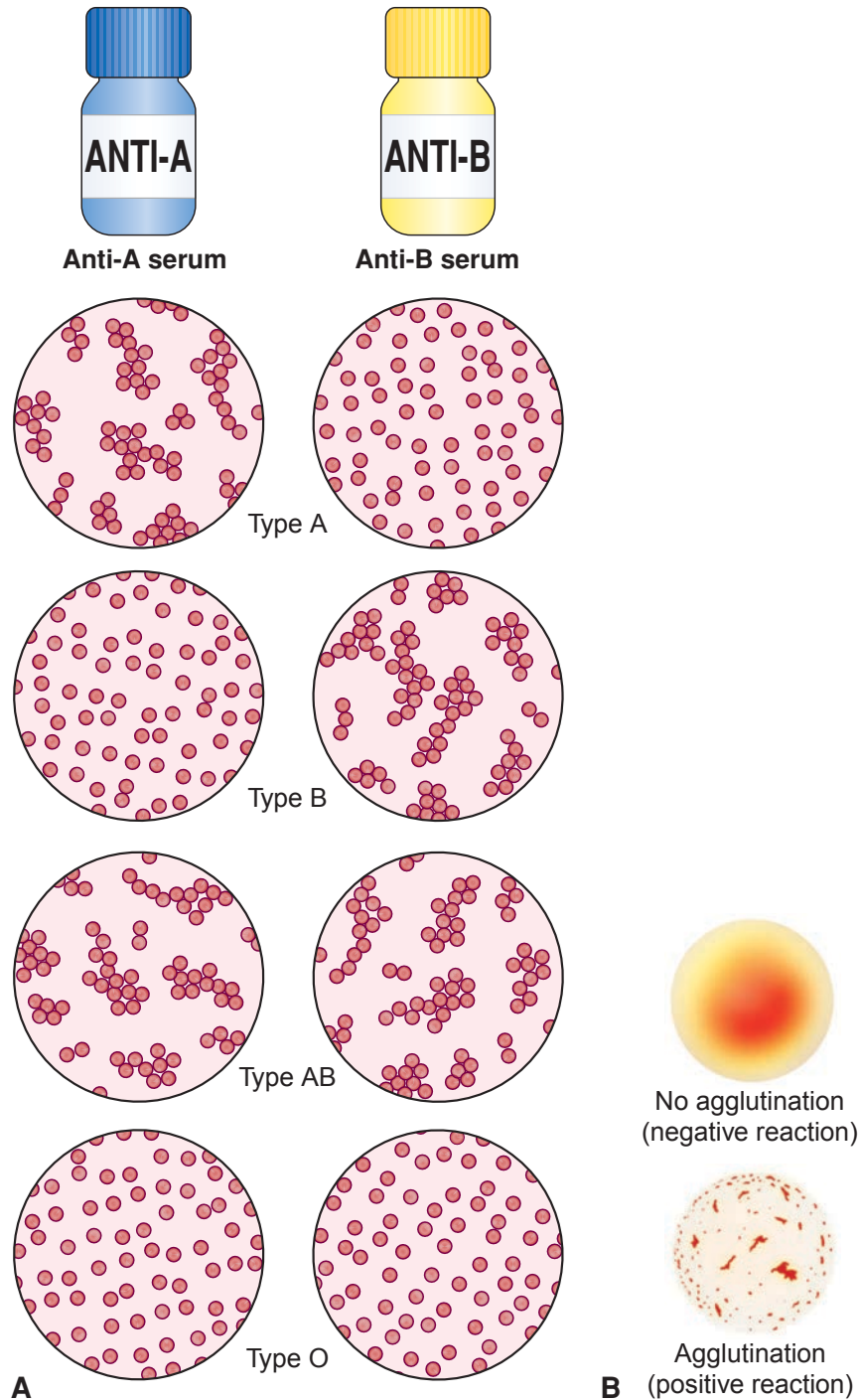
**FIGURE 11-6 Blood clotting (coagulation).** Blood coagulation involves a complex series of reactions that leads to formation of fibrin threads. The fibrin traps blood cells to form a clot. **A.** Substances released from damaged tissue start the clotting process. **B.** The final steps in formation of fibrin. One of these steps requires calcium ( $\text{Ca}^{++}$ ). **C.** Microscopic view of blood cells trapped in fibrin.

## BLOOD TYPES

Genetically inherited proteins on the surface of RBCs determine blood type. More than 20 groups of these proteins have now been identified, but the most familiar are the ABO and Rh blood groups. The ABO system includes types A, B, AB, and O. The Rh types are Rh positive ( $\text{Rh}^+$ ) and

Rh negative ( $\text{Rh}^-$ ). Blood is typed by mixing samples separately with different prepared antisera. Red cells in the sample will agglutinate (clump) with the antiserum that corresponds to the blood type, as shown in **FIGURE 11-7** for the ABO system.

In giving blood transfusions, it is important to use blood that is the same type as the recipient's blood or a

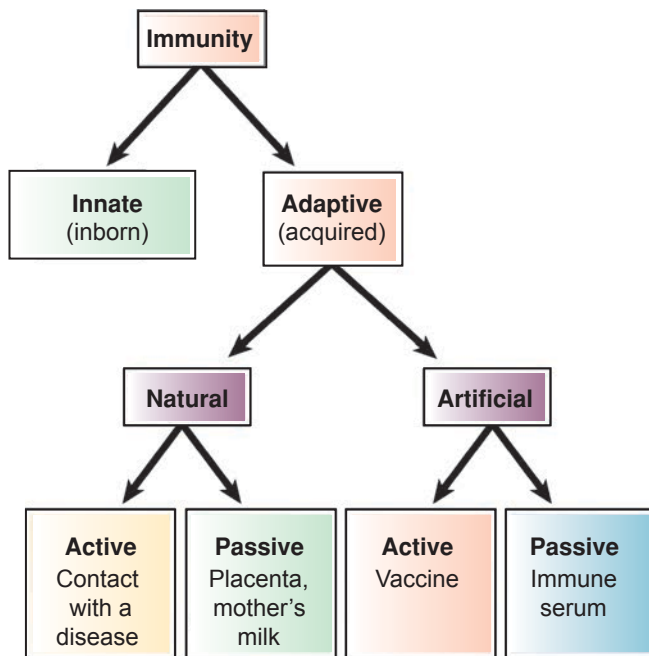


**FIGURE 11-7 Blood typing.** Blood type is determined by mixing samples separately with antisera prepared against the different red cell antigens. Clumping (agglutination) with an antiserum indicates the presence of the corresponding antigen. **A.** Labels at the top of each column denote the kind of antiserum added to the blood samples. Anti-A serum agglutinates red cells in type A blood, but anti-B serum does not. Anti-B serum agglutinates red cells in type B blood, but anti-A serum does not. Both sera agglutinate type AB blood cells, and neither serum agglutinates type O blood. **B.** Photographs of blood typing reactions.

type to which the recipient will not have an immune reaction. In an emergency, type O, Rh-negative blood can be used because these red cells will not induce an immune response. When there is time, laboratories perform more complete tests for compatibility that take additional blood proteins into account. In this process of **cross-matching**,

donor red cells are mixed with recipient serum to test for a reaction.

Whole blood may be used to replace a large volume of blood lost, but in most cases requiring blood transfusion, a blood fraction, such as packed red cells, platelets, plasma, or specific clotting factors, is administered.



**FIGURE 11-8** Types of immunity.

## Immunity

**Immunity** is protection against disease. It includes defenses against harmful microorganisms, their products, or any other foreign substance. These defenses may be inborn or acquired during life (FIG. 11-8).

### INNATE IMMUNITY

Innate defense mechanisms protect against any invading organism or harmful foreign substance, not any particular one. Thus, they are described as *nonspecific*. These defenses are inborn and are based on an individual's inherited genetic makeup. Most of these protections are physical barriers or chemical defenses and include the following:

- Unbroken skin, which acts as a barrier
- Cilia, tiny cell projections that sweep impurities out of the body, as in the respiratory tract
- Mucus that traps foreign material
- Bactericidal body secretions, as found in tears, skin, digestive tract, and reproductive tract
- Reflexes, such as coughing and sneezing, which expel impurities
- Lymphoid tissue, which filters impurities from blood and lymph, as described in Chapter 10
- Phagocytes, cells that attack, ingest, and destroy foreign organisms

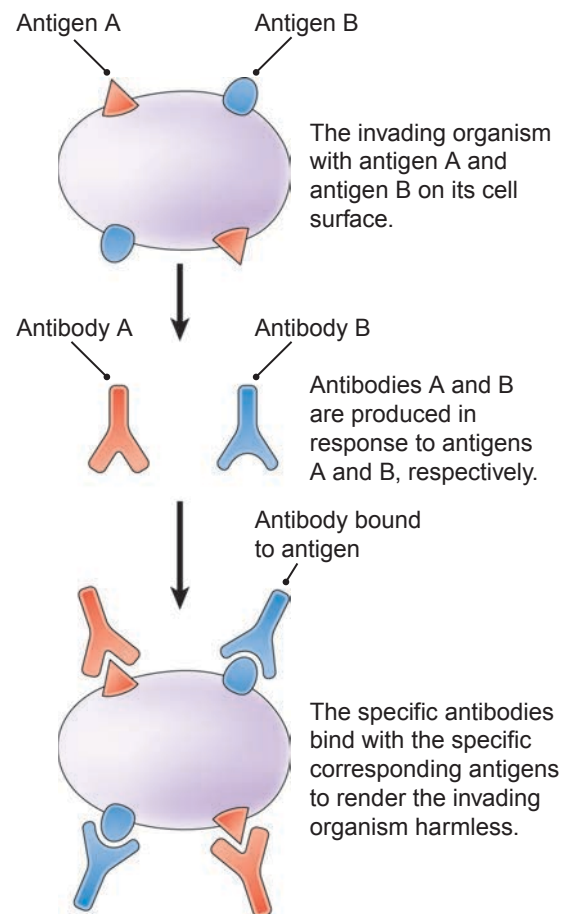
### ADAPTIVE IMMUNITY

Adaptive immunity is acquired during life and is *specific*, that is, directed toward a particular disease organism or other

foreign substance. Protection against measles, for example, will not protect against chickenpox or any other disease.

The adaptive immune response involves complex interactions between components of the lymphatic system and the blood. Any foreign particle, but mainly proteins, may act as an **antigen**, a substance that provokes an immune response. This response comes from two types of lymphocytes that circulate in the blood and lymphatic system:

- **T cells** (T lymphocytes) mature in the thymus. They are capable of attacking a foreign cell directly, producing *cell-mediated immunity*. Immune cells known as **antigen-presenting cells** (APCs), which take in and process foreign antigens, are important to T cell function. A T cell is activated when it contacts an antigen on an APC's surface in combination with some of the body's own proteins. Examples of APCs are dendritic cells and macrophages, which are descendants of monocytes.
- **B cells** (B lymphocytes) mature in bone marrow. When they meet a foreign antigen, they multiply rapidly and mature into **plasma cells**. These cells produce **antibodies**, also called **immunoglobulins** (Ig), that inactivate antigens (FIG. 11-9). Antibodies remain in the blood, often providing long-term immunity to the specific organism against



**FIGURE 11-9** The antigen–antibody reaction. Antibodies produced by immune cells bind with specific antigens to aid in their inactivation and elimination.

which they were formed. Antibody-based immunity is referred to as *humoral immunity*.

## TYPES OF ADAPTIVE IMMUNITY

Adaptive immunity may be acquired either naturally or artificially (see **FIG. 11-8**). In addition, each avenue for acquiring such immunity may be either active or passive. In active immunity, a person makes his or her own antibodies in response to contact with an antigen. In passive immunity, an antibody, known as an immune serum, is transferred from an outside source. Immune sera may come from other people or from immunized animals. The portion of the blood plasma that contains antibodies is the **gamma globulin** fraction. The types of adaptive immunity are:

- Natural adaptive immunity
  - Active—from contact with a disease organism or other foreign antigen

- Passive—by transfer of antibodies from a mother to her fetus through the placenta or through the mother's milk
- Artificial adaptive immunity
  - Active—by administration of a vaccine, which may be a killed or weakened organism, part of an organism, or an altered toxin (toxoid)
  - Passive—by administration of an immune serum obtained from other people or animals

Immunology has long been a very active area of research. The above description is only the barest outline of the events that are known to occur in the immune response, and there is still much to be discovered. Some of the areas of research include autoimmune diseases, in which an individual produces antibodies to his or her own body tissues; hereditary and acquired immunodeficiency diseases; the relationship between cancer and immunity; and the development of techniques for avoiding rejection of transplanted tissue.

## Terminology

## Key Terms

The terms listed below are emphasized in this chapter. Knowing them will help you organize and prioritize your learning. These boldface terms are also found, collectively, with all chapter key terms in the Glossary.

### Normal Structure and Function

<b>agranulocyte</b> <i>A-gran-u-lo-site</i>	A white blood cell that does not have visible granules in its cytoplasm; agranulocytes include lymphocytes and monocytes (see <b>BOX 11-3</b> )
<b>albumin</b> <i>al-BU-min</i>	A simple protein found in blood plasma
<b>antibody</b> <i>AN-tib-bod-e</i>	A protein produced in response to and interacting specifically with an antigen
<b>antigen</b> <i>AN-tib-jen</i>	A substance that induces the formation of an antibody
<b>antigen-presenting cell (APC)</b>	Immune cell that takes in a foreign antigen, processes it, and presents it on the cell surface in combination with the body's own proteins, thus activating a T cell; examples are dendritic cells and macrophages, which are descendants of monocytes
<b>B cell</b>	A lymphocyte that matures in bone marrow and is active in producing antibodies; B lymphocyte ( <i>LIM-fo-site</i> )
<b>band cell</b>	An immature neutrophil with a nucleus in the shape of a band; also called a stab cell; band cell counts are used to trace infections and other diseases (see <b>FIG. 11-4</b> )
<b>basophil</b> <i>BA-so-fil</i>	A granular leukocyte that stains strongly with basic dyes; active in allergic reactions
<b>blood</b> <i>blud</i>	The fluid that circulates in the cardiovascular system (roots: hem/o, hemat/o)
<b>coagulation</b> <i>ko-ag-u-LA-shun</i>	Blood clotting
<b>cross-matching</b>	Testing the compatibility of donor and recipient blood in preparation for a transfusion; donor red cells are mixed with recipient serum to look for an immunologic reaction; similar tests are done on tissues before transplantation

(continued)



## Terminology

## Key Terms (Continued)

<b>electrolyte</b> <i>e-LEK-tro-lite</i>	A substance that separates into charged particles (ions) in solution; a salt; term also applied to ions in body fluids
<b>eosinophil</b> <i>e-o-SIN-o-fil</i>	A granular leukocyte that stains strongly with acidic dyes; active in allergic reactions and defense against parasites
<b>erythrocyte</b> <i>eh-RITH-ro-site</i>	A red blood cell (roots: erythr/o, erythrocyt/o) (see <b>FIGS. 11-2</b> and <b>11-3</b> )
<b>erythropoietin (EPO)</b> <i>eh-ritb-ro-POY-eh-tin</i>	A hormone produced in the kidneys that stimulates red blood cell production in the bone marrow; this hormone is now made by genetic engineering for clinical use
<b>fibrin</b> <i>FI-brin</i>	The protein that forms a clot in the blood coagulation process
<b>fibrinogen</b> <i>fi-BRIN-o-jen</i>	The inactive precursor of fibrin
<b>formed elements</b>	The cellular components of blood
<b>gamma globulin</b> <i>GLOB-u-lin</i>	The fraction of the blood plasma that contains antibodies; given for passive transfer of immunity
<b>granulocyte</b> <i>GRAN-u-lo-site</i>	A white blood cell that has visible granules in its cytoplasm; granulocytes include neutrophils, basophils, and eosinophils (see <b>BOX 11-3</b> )
<b>hemoglobin (Hb, Hgb)</b> <i>HE-mo-glo-bin</i>	The iron-containing pigment in red blood cells that transports oxygen
<b>hemostasis</b> <i>he-mo-STA-sis</i>	The stoppage of bleeding
<b>immunity</b> <i>ih-MU-nih-te</i>	The state of being protected against a disease (root: immun/o)
<b>immunoglobulin (Ig)</b> <i>im-u-no-GLOB-u-lin</i>	An antibody; immunoglobulins fall into five classes, each abbreviated with a capital letter: IgG, IgM, IgA, IgD, IgE
<b>leukocyte</b> <i>LU-ko-site</i>	A white blood cell (roots: leuk/o, leukocyt/o)
<b>lymphocyte</b> <i>LIM-fo-site</i>	An agranular leukocyte active in immunity (T and B cells); found in both the blood and in lymphoid tissue (roots: lymph/o, lymphocyt/o)
<b>megakaryocyte</b> <i>meg-ab-KAR-e-o-site</i>	A large bone marrow cell that fragments to release platelets
<b>monocyte</b> <i>MON-o-site</i>	An agranular phagocytic leukocyte
<b>neutrophil</b> <i>NU-tro-fil</i>	A granular leukocyte that stains weakly with both acidic and basic dyes; the most numerous of the white blood cells; a type of phagocyte
<b>phagocytosis</b> <i>fag-o-si-TO-sis</i>	The engulfing of foreign material by white blood cells
<b>plasma</b> <i>PLAZ-mah</i>	The liquid portion of the blood
<b>plasma cell</b>	A mature form of a B cell that produces antibodies
<b>platelet</b> <i>PLATE-let</i>	A formed element of the blood that is active in hemostasis; a thrombocyte (root: thrombocyt/o)

## Terminology

## Key Terms (Continued)

<b>serum</b> <i>SERE-um</i>	The fraction of the plasma that remains after blood coagulation; it is the equivalent of plasma without its clotting factors (plural: sera, serums)
<b>T cell</b>	A lymphocyte that matures in the thymus and attacks foreign cells directly; T lymphocyte
<b>thrombocyte</b> <i>THROM-bo-site</i>	A blood platelet (root: thrombocyt/o)

## Word Parts Pertaining to Blood and Immunity

See TABLES 11-1 to 11-3.

11

Table 11-1

## Suffixes for Blood

Suffix	Meaning	Example	Definition of Example
-emia, <sup>a</sup> -hemia	condition of blood	polycythemia <i>pol-e-si-THE-me-ah</i>	increase of cells (cyt) in the blood
-penia	decrease in, deficiency of	cytopenia <i>si-to-PE-ne-ah</i>	deficiency of cells
-poiesis	formation, production	hemopoiesis <i>he-mo-poy-E-sis</i>	production of blood cells

<sup>a</sup>A shortened form of the root hem plus the suffix *-ia*.

## Exercise

## 11-1

Complete the exercise. To check your answers go to Appendix 11.

Define the following terms.

- thrombocytopenia (*throm-bo-si-to-PE-ne-ah*) \_\_\_\_\_
- bacteremia (*bak-ter-E-me-ah*) \_\_\_\_\_
- leukocytopenia (*lu-ko-si-to-PE-ne-ah*) \_\_\_\_\_
- erythropoiesis (*eh-rith-ro-poy-E-sis*) \_\_\_\_\_
- toxemia (*tok-SE-me-ah*) \_\_\_\_\_
- hypoproteinemia (*hi-po-pro-tene-E-me-ah*) \_\_\_\_\_
- hyperalbuminemia (*hi-per-al-bu-mih-NE-me-ah*) \_\_\_\_\_

Use the suffix *-emia* to write words for the following definitions.

- Presence of viruses in the blood \_\_\_\_\_
- Presence of excess white cells (leuk/o) in the blood \_\_\_\_\_
- Presence of pus in the blood \_\_\_\_\_

Many of the words relating to blood cells can be formed either with or without including the root *cyt/o*, as in erythro-*penia* or erythrocytopenia, leukopoiesis or leukocytopenia.

The remaining types of blood cells are designated by easily recognized roots such as *agranulocyt/o*, *monocyt/o*, *granulo/o*, and so on (TABLE 11-2).

Table 11-2		Roots for Blood and Immunity	
Root	Meaning	Example	Definition of Example
myel/o	bone marrow	myelogenous <i>mi-eh-LOJ-eh-nus</i>	originating in bone marrow
hem/o, hemat/o	blood	hemopathy <i>he-MOP-ah-the</i>	any disorder of blood
erythr/o, erythrocyt/o	red blood cell	erythroblast <i>eh-RITH-ro-blast</i>	immature red blood cell
leuk/o, leukocyt/o	white blood cell	leukocytosis <i>lu-ko-si-TO-sis</i>	increase in the number of leukocytes in the blood
lymph/o, lymphocyt/o	lymphocyte	lymphocytic <i>lim-fo-SIT-ik</i>	pertaining to lymphocytes
thromb/o	blood clot	thrombolytic <i>throm-bo-LIT-ik</i>	dissolving a blood clot
thrombocyt/o	platelet, thrombocyte	thrombopoiesis <i>throm-bo-poy-E-sis</i>	formation of platelets
immun/o	immunity, immune system	immunization <i>im-u-nih-ZA-shun</i>	production of immunity

## Exercise 11-2

Complete the exercise. To check your answers go to Appendix 11.

Identify and define the root in the following words.

- leukocytosis (*lu-ko-si-TO-sis*) \_\_\_\_\_
- ischemia (*is-KE-me-ah*) \_\_\_\_\_
- preimmunization (*pre-im-u-nih-ZA-shun*) \_\_\_\_\_
- hematology (*he-mah-TOL-o-je*) \_\_\_\_\_
- prothrombin (*pro-THROM-bin*) \_\_\_\_\_
- panmyeloid (*pan-MI-eh-loyd*) \_\_\_\_\_

Fill in the blanks.

- Lymphokines (*LIM-fo-kines*) are chemicals active in immunity that are produced by \_\_\_\_\_ .
- A hematoma (*he-mah-TO-mah*) is a swelling caused by collection of \_\_\_\_\_ .
- Hemorrhage (*HEM-or-ij*) is a profuse flow (-rhage) of \_\_\_\_\_ .
- Myelofibrosis (*mi-eh-lo-fi-BRO-sis*) is formation of fibrous tissue in \_\_\_\_\_ .
- Erythroclasis (*er-ih-THROK-lah-sis*) is the breaking (-clasis) of \_\_\_\_\_ .
- An immunocyte (*im-u-no-SITE*) is a cell active in \_\_\_\_\_ .
- The term thrombocytopenia (*throm-bo-si-THE-me-ah*) refers to a blood decrease in the number of \_\_\_\_\_ .
- Leukopoiesis (*lu-ko-poy-E-sis*) refers to the production of \_\_\_\_\_ .

## Exercise 11-2 (Continued)

Write words for the following definitions.

15. Decrease in white blood cells
16. Tumor of bone marrow
17. Immature lymphocyte
18. Dissolving (-lysis) of a blood clot
19. Formation (-poiesis) of bone marrow

---



---



---



---



---

The suffix *-osis* added to a root for a type of cell means an increase in that type of cell in the blood. Use this suffix to write a word that means each of the following.

20. Increase in granulocytes in the blood
21. Increase in lymphocytes in the blood
22. Increase in red blood cells
23. Increase in monocytes in the blood
24. Increase in platelets in the blood

---



---



---



---



---

Table 11-3

Roots for Blood Chemistry

Root	Meaning	Example	Definition of Example
azot/o	nitrogenous compounds	azoturia <i>aze-o-TU-re-ah</i>	increased nitrogenous compounds in the urine (-uria)
calc/i	calcium (symbol Ca)	calcification <i>kal-sih-fih-KA-shun</i>	deposition of calcium salts
ferr/o, ferr/i	iron (symbol Fe)	ferrous <i>FER-ous</i>	pertaining to or containing iron
sider/o	iron	sideroderma <i>sid-er-o-DER-mah</i>	deposition of iron into the skin
kali	potassium (symbol K)	hyperkalemia <sup>a</sup> <i>hi-per-kah-LE-me-ah</i>	excess of potassium in the blood
natri	sodium (symbol Na)	natriuresis <i>na-tre-u-RE-sis</i>	excretion of sodium in the urine (ur/o)
ox/y	oxygen (symbol O)	hypoxia <i>hi-POK-se-ah</i>	deficiency of oxygen in the tissues

<sup>a</sup>The *i* in the root is dropped.

## Exercise 11-3

Complete the exercise. To check your answers go to Appendix 11.

Fill in the blanks.

1. A sideroblast (*SID-er-o-blast*) is an immature cell containing \_\_\_\_\_ .
2. The term hypokalemia (*hi-po-kab-LE-me-ah*) refers to a blood deficiency of \_\_\_\_\_ .
3. The bacterial species *Azotobacter* is named for its ability to metabolize \_\_\_\_\_ .
4. Hypoxemia (*hi-pok-SE-me-ah*) is a blood deficiency of \_\_\_\_\_ .
5. Ferritin (*FER-ih-tin*) is a compound that contains \_\_\_\_\_ .
6. A calcareous (*kal-KAR-e-us*) substance contains \_\_\_\_\_ .

Use the suffix *-emia* to form words with the following meanings.

7. Presence of sodium in the blood \_\_\_\_\_
8. Presence of nitrogenous compounds in the blood \_\_\_\_\_
9. Presence of potassium in the blood \_\_\_\_\_
10. Presence of calcium in the blood \_\_\_\_\_

## Clinical Aspects of Blood

### ANEMIA

Anemia is defined as an abnormally low amount of hemoglobin in the blood. Anemia may result from too few RBCs

or from cells that are too small (microcytic) or have too little hemoglobin (hypochromic). Key tests in diagnosing anemia are blood counts, mean corpuscular volume (MCV), and mean corpuscular hemoglobin concentration (MCHC). **BOX 11-4** describes these and other blood tests. **BOX 11-5** has information on careers in hematology.



### FOR YOUR REFERENCE Common Blood Tests

BOX 11-4

Test	Abbreviation	Description
red blood cell count	RBC	number of red blood cells per microliter of blood
white blood cell count	WBC	number of white blood cells per microliter of blood
differential count	Diff	relative percentage of the different types of leukocytes
hematocrit (FIG. 11-10)	Ht, Hct, crit	relative percentage of packed red cells in a given volume of blood
packed cell volume	PCV	hematocrit
hemoglobin	Hb, Hgb	amount of hemoglobin in g/dL (100 mL) of blood
mean corpuscular volume	MCV	volume of an average red cell
mean corpuscular hemoglobin	MCH	average weight of hemoglobin in red cells
mean corpuscular hemoglobin concentration	MCHC	average concentration of hemoglobin in red blood cells
erythrocyte sedimentation rate	ESR	rate of erythrocyte settling per unit of time; used to detect infection or inflammation
complete blood count	CBC	series of tests including cell counts, hematocrit, hemoglobin, and cell volume measurements



## HEALTH PROFESSIONS

### Careers in Hematology

BOX 11-5

Hematologists are physicians and other scientists who specialize in the study of blood and blood diseases. In medical practice, hematology is often combined with the study and treatment of blood cancers as the specialty of hematology-oncology.

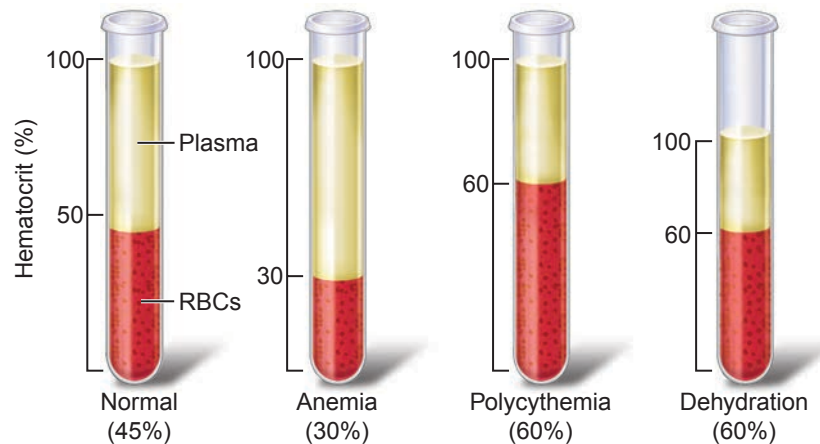
Other healthcare professionals who work in hematology perform different roles depending upon their academic preparation. These careers include medical technologists, medical technicians, and phlebotomists, who are employed in hospitals, clinics, outpatient laboratories, and private offices.

Medical technologists and technicians may specialize in various clinical settings, such as blood banks and microbiology and chemistry laboratories. Each of these positions requires an advanced skill set and working knowledge of electronic equipment, instrumentation, and computers. Those working in hematology test blood for abnormalities or infections and may do cross-matching for transfusions. They examine blood cells for signs of cancer and other diseases. They must be familiar

with laboratory safety policies and procedures and must exercise appropriate precautions when working with body fluids and tissues. For information on careers in medical laboratory technology, contact the American Society for Clinical Laboratory Science at [ascls.org](http://ascls.org).

A phlebotomist is a healthcare professional who draws blood for testing, transfusions, or research. Phlebotomists work in hospitals, laboratories, private physicians' offices, clinics, and blood banks. They often draw blood from a vein (venipuncture), but may also draw it from an artery or by skin puncture, such as a finger or heel stick. Phlebotomists must be trained in sterile techniques and safety precautions to prevent the spread of infectious diseases. They must take specimens without harming the patient or interfering with medical care and must accurately label and transport specimens to the proper laboratory. Educational requirements vary among states. Often, in-house training with certification by the National Phlebotomy Association is acceptable ([nationalphlebotomy.org](http://nationalphlebotomy.org)).

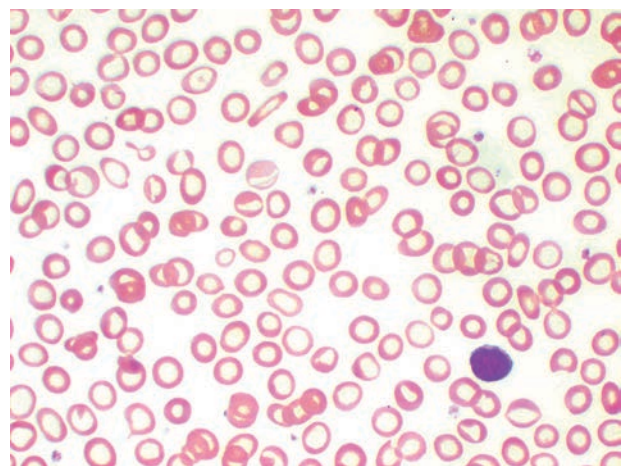
**FIGURE 11-10 Hematocrit.** The hematocrit tests the volume percentage of red cells in whole blood. The tube on the far left shows a normal hematocrit. The two middle tubes illustrate abnormal hematocrits. One shows a low percentage of red blood cells, indicating anemia, and the other shows an excessively high percentage of red blood cells, as seen in polycythemia. The tube on the far right shows a relatively high percentage of red cells due to dehydration.



The general symptoms of anemia include fatigue, shortness of breath, heart palpitations, pallor, and irritability. There are many different types of anemia, some of which are caused by faulty production of red cells and others by loss or destruction of red cells.

### Anemia due to Impaired Production of Red Cells

- **Aplastic anemia** results from bone marrow destruction and affects all blood cells (pancytopenia). It may be caused by drugs, toxins, viruses, radiation, or bone marrow cancer. Aplastic anemia has a high mortality rate but has been treated successfully with bone marrow transplantation.
- **Nutritional anemia** may result from a deficiency of vitamin B<sub>12</sub> or folate, B vitamins needed for RBC development. Most commonly, it is caused by a deficiency of iron, needed to make hemoglobin (FIG. 11-11). Folate



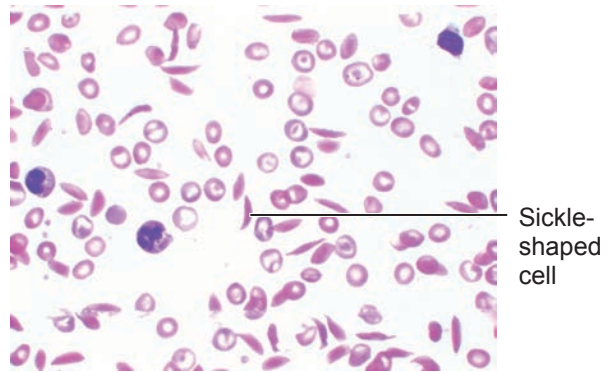
**FIGURE 11-11 Iron deficiency anemia.** Red cells are small (microcytic) and are lacking in hemoglobin (hypochromic).

deficiency commonly appears in those with poor diet, in pregnant and lactating women, and in those who abuse alcohol. Iron deficiency anemia results from poor diet, poor iron absorption, or blood loss. Both folate deficiency and iron deficiency respond to dietary supplementation.

- **Pernicious anemia** is a specific form of B<sub>12</sub> deficiency. It results from the lack of **intrinsic factor** (IF), a substance produced in the stomach that aids in the intestinal absorption of B<sub>12</sub>. Pernicious anemia must be treated with regular B<sub>12</sub> injections.
- In **sideroblastic anemia**, adequate iron is available, but the iron is not used properly to manufacture hemoglobin. This disorder may be hereditary or acquired, as by exposure to toxins or drugs. It may also be secondary to another disease. The excess iron precipitates out in immature red cells (normoblasts).

### Anemia due to Loss or Destruction of Red Cells

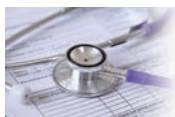- **Hemorrhagic anemia** results from blood loss. This may be a sudden loss, as from injury, or loss from chronic internal bleeding, as from the digestive tract in cases of ulcers or cancer.
- **Thalassemia** is a hereditary disease that appears mostly in Mediterranean populations. A genetic mutation causes abnormal hemoglobin production and **hemolysis** (destruction) of red cells. Thalassemia is designated as  $\alpha$  (alpha) or  $\beta$  (beta), according to the part of the hemoglobin molecule affected. Severe  $\beta$  thalassemia is also called **Cooley anemia** or *thalassemia major*.
- In **sickle cell anemia**, a mutation alters the hemoglobin molecule so that it precipitates (settles out) when it gives up oxygen, distorting the RBCs into a crescent shape (FIG. 11-12). The altered cells block small blood vessels



**FIGURE 11-12** A blood smear in sickle cell anemia. Abnormal cells take on a crescent (sickle) shape when they give up oxygen.

and deprive tissues of oxygen, an episode termed *sickle cell crisis*. The misshapen cells are also readily destroyed (hemolyzed). The disease predominates in black populations. Genetic carriers of the defect, those with one normal and one abnormal gene, show *sickle cell trait*. They usually have no symptoms, except when oxygen is low, such as at high altitudes. They can, however, pass the defective gene to offspring. Sickle cell anemia, as well as many other genetic diseases, can be diagnosed in carriers and in a fetus before birth.

**Reticulocyte counts** are useful in diagnosing the causes of anemia. Reticulocytes are immature RBCs that normally appear as a small percentage of the total erythrocytes. An increase in the reticulocyte count indicates increased red cell formation, as in response to hemorrhage or cell destruction. A decrease in reticulocytes indicates a failure in red cell production, as caused by nutritional deficiency or aplastic anemia (BOX 11-6).



## CLINICAL PERSPECTIVES

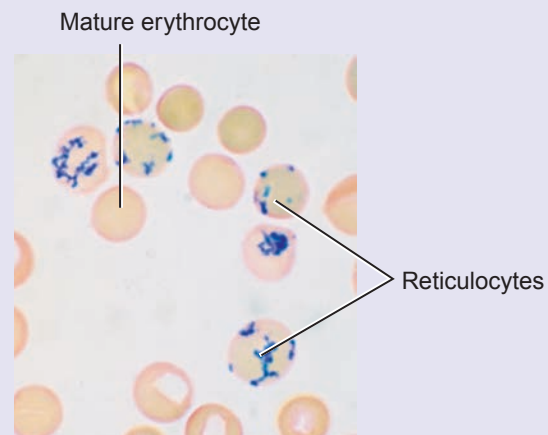
### Use of Reticulocytes in Diagnosis

#### BOX 11-6

As erythrocytes mature in the red bone marrow, they go through a series of stages in which they lose their nuclei and most other organelles, maximizing the space available for hemoglobin. In one of the last stages of development, small numbers of ribosomes and some rough endoplasmic reticulum remain in the cell and appear as a network, or reticulum, when stained. Cells at this stage are called reticulocytes. Reticulocytes leave the red bone marrow and enter the bloodstream, where they become fully mature erythrocytes in about 24 to 48 hours. The average number of red cells maturing through the reticulocyte stage at any given time is about 1 to 2%. Changes in these numbers can be used in diagnosing certain blood disorders.

When erythrocytes are lost or destroyed, as from chronic bleeding or some form of hemolytic anemia, red cell production is “stepped up” to compensate for the loss. Greater numbers of reticulocytes are then released into the blood before reaching full maturity, and counts increase to above normal. On the other hand, a decrease in the number of circulating

reticulocytes suggests a problem with red cell production, as in cases of deficiency anemias or suppression of bone marrow activity.



## COAGULATION DISORDERS

The most common cause of coagulation problems is a deficiency in the number of circulating platelets, a condition termed **thrombocytopenia**. Possible causes include aplastic anemia, infections, bone marrow cancer, and agents that destroy bone marrow, such as x-rays or certain drugs. This disorder results in bleeding into the skin and mucous membranes, variously described as **petechiae** (pinpoint spots), **ecchymoses** (bruises), and **purpura** (purple lesions).

In **disseminated intravascular coagulation (DIC)**, widespread clotting in the vessels obstructs circulation to the tissues. This is followed by diffuse hemorrhages as clotting factors are removed and the coagulation process is impaired. DIC may result from a variety of causes, including infection, cancer, hemorrhage, injury, and **allergy**.

**Hemophilia** is a hereditary deficiency of a specific clotting factor. It is a genetically sex-linked disease that is passed from mother to son. There is bleeding into the tissues, especially into the joints (hemarthrosis). Hemophilia must be treated with transfusions of the necessary clotting factors, which are now produced in purified form from blood products or by genetic engineering. Genetic engineering may one day provide a cure by inserting a normal gene into the patient's body to produce the deficient clotting factor.

**BOX 11-7** lists tests done for these and other coagulation disorders.

## NEOPLASMS

**Leukemia** is a neoplasm of WBCs. The rapidly dividing but incompetent white cells accumulate in the tissues and crowd out the other blood cells. The symptoms of leukemia include anemia, fatigue, easy bleeding, **splenomegaly**, and sometimes **hepatomegaly** (enlargement of the liver). The causes of leukemia are unknown but may include exposure to radiation or harmful chemicals, hereditary factors, and perhaps viral infection.

The two main categories of leukemia are determined by origin and the cells involved:

- Myelogenous leukemia originates in the bone marrow and involves mainly the granular leukocytes.

- Lymphocytic leukemia affects B cells and the lymphatic system, causing **lymphadenopathy** (lymph node disease) and adverse effects on the immune system.

Leukemias are further differentiated as acute or chronic based on clinical progress. Acute leukemia is the most common form of cancer in young children. The acute forms are:

- Acute myeloblastic (myelogenous) leukemia (AML). The prognosis in AML is poor for both children and adults.
- Acute lymphoblastic (lymphocytic) leukemia (ALL). With treatment, the ALL remission rate is high.

The chronic forms of leukemia are:

- Chronic myelogenous leukemia, also called chronic granulocytic leukemia, affects young to middle-aged adults (**FIG 11-13A**). Most cases show the **Philadelphia chromosome (Ph)**, an inherited anomaly in which part of chromosome 22 shifts to chromosome 9.
- Chronic lymphocytic leukemia (CLL) appears mostly in the elderly and is the most slowly growing form of the disease (**FIG. 11-13B**).

Leukemia treatment includes chemotherapy, radiation therapy, and bone marrow transplantation. Bone marrow contains stem cells, immature cells that can develop into mature, functional cells. After the patient's bone marrow stem cells are destroyed, donor bone marrow can repopulate the recipient's bone marrow with normal, healthy blood-forming cells. Another option for transplantation is the use of umbilical cord blood to replace blood-forming cells in bone marrow. This blood is more readily available than bone marrow and does not have to match as closely to avoid rejection.

**Hodgkin lymphoma** is a cancer of the B cells in lymph nodes. In the U.S. population the incidence of the disease peaks at about 20 years of age and again at about 65 years of age. The cause is unknown, but in some cases may involve a viral infection. The disease appears as painless enlargement of a lymph node or group of nodes, often in the neck, armpit, thorax, and groin. If untreated, it may spread throughout the lymphatic system to other tissues. Early signs are weight loss, fever, night sweats, fatigue,



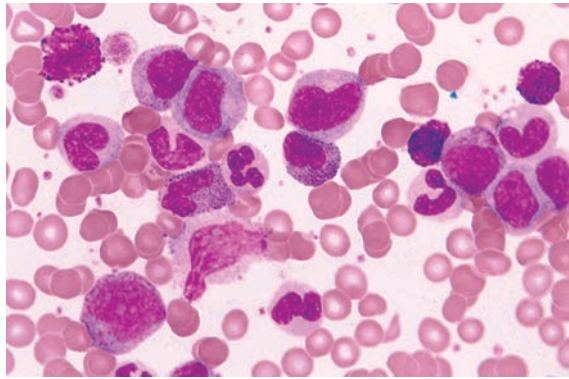
## FOR YOUR REFERENCE

### Coagulation Tests

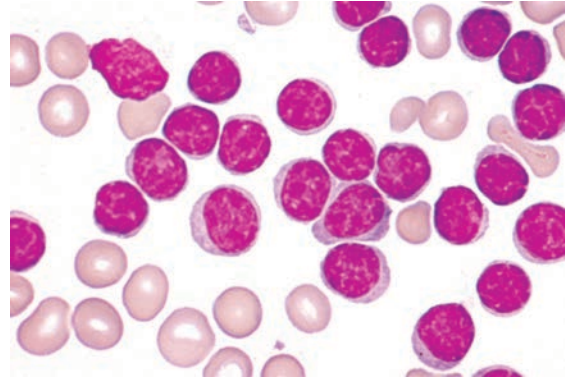
**BOX 11-7**

Test	Abbreviation	Description
<b>activated partial thromboplastin time</b>	APTT	Measures time required for clot formation; used to evaluate clotting factors and monitor heparin therapy
<b>bleeding time</b>	BT	Measures capacity of platelets to stop bleeding after a standard skin incision
<b>partial thromboplastin time</b>	PTT	Evaluates clotting factors; similar to APTT, but less sensitive
<b>prothrombin time</b>	PT, pro time	Indirectly measures prothrombin; used to monitor anticoagulant therapy; also called Quick test
<b>thrombin time (thrombin clotting time)</b>	TT (TCT)	Measures how quickly a clot forms





A



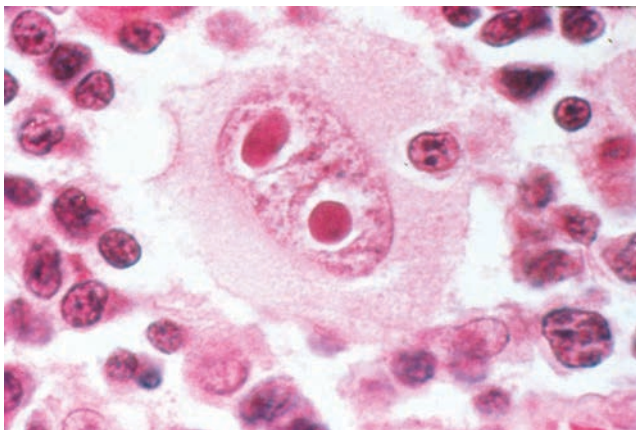
B

**FIGURE 11-13 Leukemia.** Leukemia is a malignant overgrowth of white cells originating in the bone marrow (myelogenous) or lymphatic system (lymphocytic). **A.** Chronic myelogenous leukemia showing overproduction of all categories of white cells. **B.** Chronic lymphocytic leukemia showing numerous lymphocytes.

anemia, and a weakened immune system. A feature of Hodgkin lymphoma is giant cells in the lymph nodes called **Reed–Sternberg cells** (FIG. 11-14). Symptoms include fever, night sweats, weight loss, and skin itching (pruritus). Most cases can be cured with radiation and chemotherapy.

**Non-Hodgkin lymphoma** (NHL) is also a malignant enlargement of lymph nodes but does not show Reed–Sternberg cells. It is more common than Hodgkin disease and has a higher mortality rate. Cases vary in severity and prognosis. It is most prevalent in the older adult population and in those with AIDS and other forms of immunodeficiency. NHL involves the T or B lymphocytes, and some cases may be related to infection with certain viruses. It requires systemic chemotherapy and sometimes bone marrow transplantation.

**Multiple myeloma** is a cancer of the blood-forming cells in bone marrow, mainly the plasma cells that produce antibodies. The disease causes anemia, bone pain, and bone weakening. Patients have a greater susceptibility to infection because of immunodeficiency. Abnormally high levels of calcium and protein in the blood often lead to kidney failure. Multiple myeloma is treated with radiation and chemotherapy, but the prognosis is generally poor.



**FIGURE 11-14 Reed–Sternberg cell.** These cells are typical of Hodgkin disease.

## Clinical Aspects of Immunity

### HYPERSENSITIVITY

**Hypersensitivity** is any harmful overreaction of the immune system. Its forms include allergy, autoimmune disease, and transplantation reactions. In cases of **allergy**, a person is more sensitive to a particular antigen than the average individual. Common **allergens** are pollen, animal dander, dust, and foods, but there are many more. A seasonal allergy to inhaled pollens is commonly called “hay fever.” Responses may include itching, redness, or tearing of the eyes (conjunctivitis), skin rash, asthma, runny nose (rhinitis), sneezing, **urticaria** (hives), and **angioedema**, a reaction similar to hives but involving deeper layers of tissue.

An **anaphylactic reaction** is a severe generalized allergic response that can rapidly lead to death as a result of shock and respiratory distress. It must be treated by immediate administration of **epinephrine** (adrenaline) and maintenance of open airways. Oxygen, antihistamines, and corticosteroids may also be given. Common causes of anaphylaxis are drugs, especially penicillin and other antibiotics, vaccines, diagnostic chemicals, foods, and insect venom.

A **delayed hypersensitivity reaction** involves T cells and takes at least 12 hours to develop. A common example is the reaction to contact with plant irritants such as those of poison ivy and poison oak.

### IMMUNODEFICIENCY

The term **immunodeficiency** refers to any failure in the immune system. This may be congenital (present at birth) or acquired and may involve any components of the system. The deficiency may vary in severity but is always evidenced by an increased susceptibility to disease.

**Acquired immunodeficiency syndrome** (AIDS) is acquired by infection with **human immunodeficiency virus** (HIV), which attacks certain T cells. These cells have a specific surface attachment site, the CD4 receptor, for the virus. HIV is spread by sexual contact, use of contaminated needles, blood transfusions, and passage from an infected mother to her fetus. It leaves the host susceptible to opportunistic infections such

as pneumonia caused by the fungus *Pneumocystis jirovecii*; thrush, an oral fungal infection caused by *Candida albicans*; and infection with *Cryptosporidium*, a protozoan that causes cramps and diarrhea. It also predisposes the patient to **Kaposi sarcoma**, a once-rare form of skin cancer. AIDS may also induce autoimmunity or attack the nervous system.

AIDS is diagnosed and monitored by **CD4+ T lymphocyte counts**, a measure of cells with the HIV receptor. A count of less than 200/ $\mu$ L of blood signifies severe immunodeficiency. HIV antibody levels and direct viral blood counts are also used to track the disease's course. At present there is no vaccine or cure for AIDS, but drugs can delay its progress.

## AUTOIMMUNE DISEASES

A disorder that results from an immune response to one's own tissues is classified as an **autoimmune disease**. The cause may be a failure in the immune system or a reaction to body cells that have been slightly altered by mutation or disease. The list of diseases that are believed to be caused, at least in part, by autoimmunity is long. Some, such as **systemic lupus erythematosus (SLE)**, **systemic sclerosis (scleroderma)**, and **Sjögren syndrome**, affect tissues in multiple systems. Others target more specific organs or systems. Examples are pernicious anemia, rheumatoid arthritis, Graves disease (of the thyroid), myasthenia gravis (a muscle disease), fibromyalgia syndrome (a musculoskeletal disorder), rheumatic heart disease, and glomerulonephritis (a kidney disease). These diseases are discussed in more detail in other chapters.

## Terminology

## Key Terms

The terms listed below are emphasized in this chapter. Knowing them will help you organize and prioritize your learning. These boldface terms are also found, collectively, with all chapter key terms in the Glossary.

### Disorders

<b>acquired immunodeficiency syndrome (AIDS)</b> <i>ab-KWI-erd im-u-no-de-FISH-en-se SIN-drome</i>	Immune system failure caused by infection with HIV (human immunodeficiency virus); the virus infects certain T cells and thus interferes with immunity
<b>allergen</b> <i>AL-er-jen</i>	A substance that causes an allergic response
<b>allergy</b> <i>AL-er-je</i>	Hypersensitivity
<b>anaphylactic reaction</b> <i>an-ab-fih-LAK-tik</i>	An exaggerated allergic reaction to a foreign substance; it may lead to death caused by circulatory collapse and respiratory distress if untreated; also called anaphylaxis (from Greek <i>phylaxis</i> , meaning “protection”)
<b>anemia</b> <i>ab-NE-me-ab</i>	A deficiency in the amount of hemoglobin in the blood; may result from blood loss, malnutrition, a hereditary defect, environmental factors, and other causes (see <b>FIGS. 11-11</b> and <b>11-12</b> )
<b>angioedema</b> <i>an-je-o-eh-DE-mah</i>	A localized edema with large hives (wheals) similar to urticaria but involving deeper layers of the skin and subcutaneous tissue
<b>aplastic anemia</b> <i>a-PLAS-tik</i>	Anemia caused by bone marrow failure resulting in deficient blood cell production, especially of red cells; pancytopenia
<b>autoimmune disease</b> <i>aw-to-ih-MUNE</i>	A condition in which the immune system produces antibodies against an individual's own tissues (prefix <i>auto</i> means “self”)
<b>Cooley anemia</b>	A form of thalassemia (hereditary anemia) that affects production of the $\beta$ (beta) hemoglobin chain; thalassemia major
<b>delayed hypersensitivity reaction</b>	An allergic reaction involving T cells that takes at least 12 hours to develop; examples are various types of contact dermatitis, such as poison ivy or poison oak; the tuberculin reaction (test for TB); and rejections of transplanted tissue
<b>disseminated intravascular coagulation (DIC)</b>	Widespread clot formation in the microscopic vessels; may be followed by bleeding caused by depletion of clotting factors
<b>ecchymosis</b> <i>ek-ih-MO-sis</i>	A collection of blood under the skin caused by leakage from small vessels (root <i>chym</i> means “juice”)

(continued)

## Terminology

## Key Terms (Continued)

<b>hemolysis</b> <i>he-MOL-ih-sis</i>	The rupture of red blood cells and the release of hemoglobin (adjective: hemolytic)
<b>hemophilia</b> <i>he-mo-FIL-e-ah</i>	A hereditary blood disease caused by lack of a clotting factor resulting in abnormal bleeding
<b>hemorrhagic anemia</b> <i>hem-o-RAJ-ik</i>	Anemia that results from blood loss, as from an injury or internal bleeding
<b>human immunodeficiency virus (HIV)</b>	The virus that causes AIDS
<b>Hodgkin lymphoma</b>	A neoplastic disease of B cells that involves the lymph nodes, spleen, liver, and other tissues; characterized by the presence of giant Reed–Sternberg cells (see <b>FIG. 11-14</b> )
<b>hypersensitivity</b> <i>hi-per-sen-sih-TIV-ih-te</i>	An immunologic reaction to a substance that is harmless to most people; allergy
<b>immunodeficiency</b> <i>im-u-no-de-FISH-en-se</i>	A congenital or acquired failure of the immune system to protect against disease
<b>intrinsic factor</b> <i>In-TRIN-sik</i>	A substance produced in the stomach that aids in the intestinal absorption of vitamin B <sub>12</sub> , necessary for the manufacture of red blood cells; lack of intrinsic factor causes pernicious anemia
<b>Kaposi sarcoma</b> <i>KAP-o-se</i>	Cancerous lesion of the skin and other tissues, seen most often in patients with AIDS
<b>leukemia</b> <i>lu-KE-me-ah</i>	Malignant overgrowth of immature white blood cells; may be chronic or acute; may affect bone marrow (myelogenous leukemia) or lymphoid tissue (lymphocytic leukemia)
<b>lymphadenopathy</b> <i>lim-fad-eh-NOP-ah-the</i>	Any disease of the lymph nodes
<b>multiple myeloma</b> <i>mi-eh-LO-mah</i>	A tumor of the blood-forming tissue in bone marrow
<b>non-Hodgkin lymphoma (NHL)</b>	A widespread malignant disease of lymph nodes that involves lymphocytes; it differs from Hodgkin disease in that giant Reed–Sternberg cells are absent
<b>nutritional anemia</b> <i>nu-TRISH-un-al</i>	Anemia resulting from a dietary deficiency, usually of iron, vitamin B <sub>12</sub> , or folate
<b>Philadelphia chromosome (Ph)</b>	An abnormal chromosome found in the cells of most individuals with chronic granulocytic (myelogenous) leukemia
<b>pernicious anemia</b> <i>per-NISH-us</i>	Anemia caused by failure of the stomach to produce intrinsic factor, a substance needed for the absorption of vitamin B <sub>12</sub> ; this vitamin is required for the formation of erythrocytes
<b>petechiae</b> <i>pe-E-ke-e</i>	Pinpoint, flat, purplish-red spots caused by bleeding within the skin or mucous membrane (singular: petechia)
<b>purpura</b> <i>PUR-pu-rah</i>	A condition characterized by hemorrhages into the skin, mucous membranes, internal organs, and other tissues (from Greek word meaning “purple”); thrombocytopenic purpura is caused by a deficiency of platelets
<b>sickle cell anemia</b> <i>SIK-l</i>	A hereditary anemia caused by the presence of abnormal hemoglobin; red blood cells become sickle-shaped when they give up oxygen and interfere with normal blood flow to the tissues (see <b>FIG. 11-12</b> ); most common in black populations of West African descent
<b>sideroblastic anemia</b> <i>sid-eh-ro-BLAS-tik</i>	Anemia caused by inability to use available iron to manufacture hemoglobin; the excess iron precipitates in normoblasts (developing red blood cells)
<b>Sjögren syndrome</b> <i>SHO-gren</i>	An autoimmune disease involving dysfunction of the exocrine glands and affecting secretion of tears, saliva, and other body fluids; deficiency leads to dry mouth, tooth decay, corneal damage, eye infections, and difficulty in swallowing

## Terminology

## Key Terms (Continued)

<b>splenomegaly</b> <i>sple-no-MEG-ah-le</i>	Enlargement of the spleen
<b>systemic lupus erythematosus</b> <i>LU-pus er-ih-the-mah-TO-sus</i>	Inflammatory connective tissue disease affecting the skin and multiple organs; patients are sensitive to light and may have a red butterfly-shaped rash over the nose and cheeks
<b>systemic sclerosis</b>	A diffuse connective tissue disease that may involve any system causing inflammation, degeneration, and fibrosis; also called scleroderma because it causes thickening of the skin
<b>thalassemia</b> <i>thal-ab-SE-me-ah</i>	A group of hereditary anemias mostly found in populations of Mediterranean descent (the name comes from the Greek word for “sea”)
<b>thrombocytopenia</b> <i>throm-bo-si-to-PE-ne-ah</i>	A deficiency of thrombocytes (platelets) in the blood
<b>urticaria</b> <i>ur-tih-KAR-e-ah</i>	A skin reaction consisting of round, raised eruptions (wheals) with itching; hives
<b>Diagnosis and Treatment</b>	
<b>adrenaline</b> <i>ah-DREN-ab-lin</i>	See epinephrine
<b>CD4+ T lymphocyte count</b>	A count of the T cells that have the CD4 receptors for the AIDS virus (HIV); a count of less than 200/ $\mu$ L of blood signifies severe immunodeficiency
<b>epinephrine</b> <i>ep-ih-NEF-rin</i>	A powerful stimulant produced by the adrenal gland and sympathetic nervous system; activates the cardiovascular, respiratory, and other systems needed to meet stress; used as a drug to treat severe allergic reactions and shock; also called adrenaline
<b>reticulocyte counts</b> <i>re-TIK-u-lo-site</i>	Blood counts of reticulocytes, a type of immature red blood cell; reticulocyte counts are useful in diagnosis to indicate the rate of erythrocyte formation (see <b>BOX 11-6</b> )
<b>Reed–Sternberg cells</b> <i>rede SHTERN-berg</i>	Giant cells that are characteristic of Hodgkin disease; they usually have two large nuclei and are surrounded by a halo (see <b>FIG. 11-14</b> )

## Terminology

## Enrichment Terms

The terms listed below expand on the key terms to increase your knowledge of this chapter topic.

## Normal Structure and Function

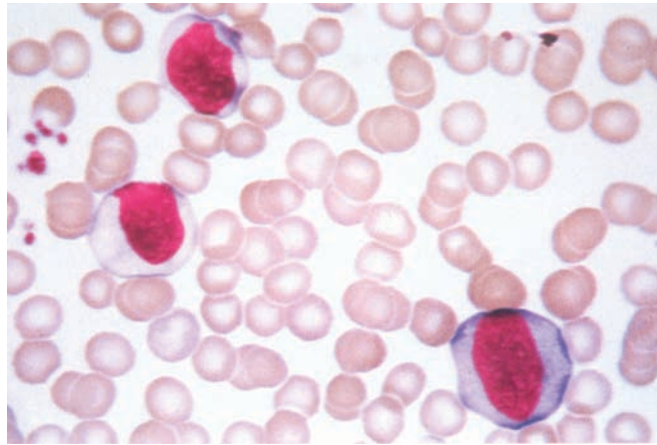
<b>agglutination</b> <i>ah-glu-tih-NA-shun</i>	The clumping of cells or particles in the presence of specific antibodies
<b>bilirubin</b> <i>bil-ih-RU-bin</i>	A pigment derived from the breakdown of hemoglobin and eliminated by the liver in bile
<b>complement</b> <i>COM-pleh-ment</i>	A group of plasma enzymes that interacts with antibodies
<b>corpuscle</b> <i>KOR-pus-l</i>	A small mass or body; a blood corpuscle is a blood cell
<b>hemopoietic stem cell</b> <i>he-mo-poy-EH-tik</i>	A primitive bone marrow cell that gives rise to all varieties of blood cells
<b>heparin</b> <i>HEP-ab-rin</i>	A substance found throughout the body that inhibits blood coagulation; an anticoagulant

(continued)

## Terminology

## Enrichment Terms (Continued)

<b>plasmin</b> <i>PLAZ-min</i>	An enzyme that dissolves clots; also called fibrinolysin
<b>thrombin</b> <i>THROM-bin</i>	The enzyme derived from prothrombin that converts fibrinogen to fibrin
<b>Symptoms and Conditions</b>	
<b>agranulocytosis</b> <i>a-gran-u-lo-si-TO-sis</i>	A condition involving a decrease in the number of granulocytes in the blood; also called granulocytopenia
<b>erythrocytosis</b> <i>eh-rith-ro-si-TO-sis</i>	Increase in the number of red cells in the blood; may be normal, such as to compensate for life at high altitudes, or abnormal, such as in cases of pulmonary or cardiac disease
<b>Fanconi syndrome</b> <i>fan-KO-ne</i>	Congenital aplastic anemia that appears between birth and 10 years of age; may be hereditary or caused by damage before birth, as by a virus
<b>graft versus host reaction (GVHR)</b>	An immunologic reaction of transplanted lymphocytes against tissues of the host; a common complication of bone marrow transplantation
<b>hairy cell leukemia</b>	A form of leukemia in which cells have filaments, making them look hairy
<b>hematoma</b> <i>he-mah-TO-mah</i>	A localized collection of blood, usually clotted, caused by a break in a blood vessel
<b>hemolytic disease of the newborn (HDN)</b>	Disease that results from incompatibility between the blood of a mother and her fetus, usually involving Rh factor; an Rh-negative mother produces antibody to an Rh-positive fetus that, in later pregnancies, will destroy the red cells of an Rh-positive fetus; the problem is usually avoided by treating the mother with antibodies to remove the Rh antigen; also called erythroblastosis fetalis
<b>hemosiderosis</b> <i>he-mo-sid-er-O-sis</i>	A condition involving the deposition of an iron-containing pigment (hemosiderin) mainly in the liver and the spleen; the pigment comes from hemoglobin released from disintegrated red blood cells
<b>idiopathic thrombocytopenic purpura (ITP)</b>	A clotting disorder caused by destruction of platelets that usually follows a viral illness; causes petechiae and hemorrhages into the skin and mucous membranes
<b>infectious mononucleosis</b> <i>mon-o-nu-kle-O-sis</i>	An acute infectious disease caused by Epstein–Barr virus (EBV); characterized by fever, weakness, lymphadenopathy, hepatosplenomegaly, and atypical lymphocytes (resembling monocytes) (see <b>FIG. 11-10</b> )
<b>lymphocytosis</b> <i>lim-fo-si-TO-sis</i>	An increase in the number of circulating lymphocytes
<b>myelodysplastic syndrome</b> <i>mi-eh-lo-dis-PLAS-tik</i>	Bone marrow dysfunction resulting in anemia and deficiency of neutrophils and platelets; may develop in time into leukemia; preleukemia
<b>myelofibrosis</b> <i>mi-eh-lo-fi-BRO-sis</i>	Condition in which bone marrow is replaced with fibrous tissue
<b>neutropenia</b> <i>nu-tro-PE-ne-ah</i>	A decrease in the number of neutrophils with increased susceptibility to infection; causes include drugs, irradiation, and infection; may be a side effect of treatment for malignancy
<b>pancytopenia</b> <i>pan-si-to-PE-ne-ah</i>	A decrease in all cells of the blood, as in aplastic anemia
<b>polycythemia</b> <i>pol-e-si-THE-me-ah</i>	Any condition in which there is a relative increase in the percent of red blood cells in whole blood; may result from excessive production of red cells because of oxygen lack, as caused by high altitudes, breathing obstruction, heart failure, or certain forms of poisoning. Apparent polycythemia results from concentration of the blood, as by dehydration ( <b>FIG. 11-15</b> )
<b>polycythemia vera</b> <i>pol-e-si-THE-me-ah VE-rah</i>	A condition in which overactive bone marrow produces too many red blood cells (see <b>FIG. 11-15</b> ) that interfere with circulation and promote thrombosis and hemorrhage; treated by blood removal; also called erythremia and Vaquez–Osler disease



**FIGURE 11-15 Infectious mononucleosis.** Atypical lymphocytes characterize this viral disease.

Terminology	Enrichment Terms (Continued)
<b>septicemia</b> <i>sep-tib-SE-me-ah</i>	Presence of microorganisms in the blood
<b>spherocytic anemia</b> <i>sfer-o-SIT-ik</i>	Hereditary anemia in which red blood cells are round instead of disk shaped and rupture (hemolyze) excessively
<b>thrombotic thrombocytopenic purpura (TTP)</b>	An often fatal disorder in which multiple clots form in blood vessels
<b>von Willebrand disease</b>	A hereditary bleeding disease caused by lack of von Willebrand factor, a substance necessary for blood clotting
<b>Diagnosis (see also BOXES 11-4 and 11-7)</b>	
<b>Bence Jones protein</b>	A protein that appears in the urine of patients with multiple myeloma
<b>Coombs test</b>	A test for detection of antibodies to red blood cells, such as those appearing in cases of autoimmune hemolytic anemias
<b>electrophoresis</b> <i>e-lek-tro-fo-RE-sis</i>	Separation of particles in a liquid by application of an electrical field; used to separate components of blood
<b>ELISA</b>	Enzyme-linked immunosorbent assay; a highly sensitive immunologic test used to diagnose HIV infection, hepatitis, and Lyme disease, among others
<b>monoclonal antibody</b> <i>mon-o-KLO-nal</i>	A pure antibody produced in the laboratory; used for diagnosis and treatment
<b>pH</b>	A scale that measures the relative acidity or alkalinity of a solution; represents the amount of hydrogen ion in the solution
<b>Schilling test</b> <i>SHIL-ing</i>	Test used to determine absorption of vitamin B <sub>12</sub> by measuring excretion of radioactive B <sub>12</sub> in the urine; used to distinguish pernicious from nutritional anemia
<b>seroconversion</b> <i>se-ro-con-VER-zhun</i>	The appearance of antibodies in the serum in response to a disease or an immunization
<b>Western blot assay</b>	A very sensitive test used to detect small amounts of antibodies in the blood
<b>Wright stain</b>	A commonly used blood stain; see <b>FIGURE 11-2</b> shows blood cells stained with Wright stain

(continued)

## Terminology

## Enrichment Terms (Continued)

## Treatment

<b>anticoagulant</b> <i>an-ti-ko-AG-u-lant</i>	An agent that prevents or delays blood coagulation
<b>antihistamine</b> <i>an-tih-HIS-tah-meme</i>	A drug that counteracts the effects of histamine and is used to treat allergic reactions
<b>apheresis</b> <i>af-eh-RE-sis</i>	A procedure in which blood is withdrawn, a portion is separated and retained, and the remainder is returned to the donor; apheresis may be used as a suffix with a root meaning the fraction retained, such as plasmapheresis, leukapheresis
<b>autologous blood</b> <i>aw-TOL-o-gus</i>	A person's own blood; may be donated in advance of surgery and transfused if needed
<b>cryoprecipitate</b> <i>kri-o-pre-SIP-ih-tate</i>	A sediment obtained by cooling; the fraction obtained by freezing blood plasma contains clotting factors
<b>desensitization</b> <i>de-sen-sih-tih-ZA-shun</i>	Treatment of allergy by small injections of the offending allergen, causing an increase of antibody to destroy the antigen rapidly on contact
<b>homologous blood</b> <i>ho-MOL-o-gus</i>	Blood from animals of the same species, such as human blood used for transfusion from one person to another; blood used for transfusions must be compatible with the recipient's blood
<b>immunosuppression</b> <i>im-u-no-su-PRESH-un</i>	Depression of the immune response; may be correlated with disease but also may be induced therapeutically to prevent rejection in cases of tissue transplantation
<b>protease inhibitor</b> <i>PRO-te-ase</i>	An anti-HIV drug that acts by inhibiting an enzyme the virus needs to multiply

## Terminology

## Abbreviations

The abbreviations listed below are emphasized in this chapter. These are also found, collectively, with all chapter abbreviations in Appendix 2.

<b>Ab</b>	Antibody	<b>CLL</b>	Chronic lymphocytic leukemia
<b>Ag</b>	Antigen, also silver	<b>CML</b>	Chronic myelogenous leukemia
<b>AIDS</b>	Acquired immunodeficiency syndrome	<b>crit</b>	Hematocrit
<b>ALL</b>	Acute lymphoblastic (lymphocytic) leukemia	<b>DIC</b>	Disseminated intravascular coagulation
<b>AML</b>	Acute myeloblastic (myelogenous) leukemia	<b>Diff</b>	Differential count
<b>APC</b>	Antigen-presenting cell	<b>EBV</b>	Epstein–Barr virus
<b>APTT</b>	Activated partial thromboplastin time	<b>ELISA</b>	Enzyme-linked immunosorbent assay
<b>BT</b>	Bleeding time	<b>EPO, EP</b>	Erythropoietin
<b>CBC</b>	Complete blood count	<b>ESR</b>	Erythrocyte sedimentation rate
<b>CGL</b>	Chronic granulocytic leukemia	<b>FFP</b>	Fresh frozen plasma

## Terminology

## Abbreviations (Continued)

<b>Hb, Hgb</b>	Hemoglobin	<b>PCV</b>	Packed cell volume
<b>Hct, Ht</b>	Hematocrit	<b>pH</b>	Scale for measuring hydrogen ion concentration (acidity or alkalinity)
<b>HDN</b>	Hemolytic disease of the newborn	<b>Ph</b>	Philadelphia chromosome
<b>HIV</b>	Human immunodeficiency virus	<b>PMN</b>	Polymorphonuclear (neutrophil)
<b>IF</b>	Intrinsic factor	<b>poly</b>	Neutrophil
<b>Ig</b>	Immunoglobulin	<b>polymorph</b>	Neutrophil
<b>ITP</b>	Idiopathic thrombocytopenic purpura	<b>PT</b>	Prothrombin time; pro time
<b>lytes</b>	Electrolytes	<b>PTT</b>	Partial thromboplastin time
<b>MCH</b>	Mean corpuscular hemoglobin	<b>RBC</b>	Red blood cell; red blood (cell) count
<b>MCHC</b>	Mean corpuscular hemoglobin concentration	<b>seg</b>	Neutrophil
<b>μL, mL</b>	Microliter	<b>SLE</b>	Systemic lupus erythematosus
<b>μm, mcm</b>	Micrometer	<b>T(C)T</b>	Thrombin (clotting) time
<b>MCV</b>	Mean corpuscular volume	<b>TTP</b>	Thrombotic thrombocytopenic purpura
<b>MDS</b>	Myelodysplastic syndrome	<b>vWF</b>	von Willebrand factor
<b>mEq</b>	Milliequivalent	<b>WBC</b>	White blood cell; white blood (cell) count
<b>NHL</b>	Non-Hodgkin lymphoma		

## Case Study Revisited

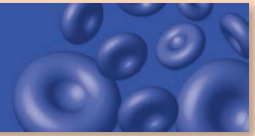
**Olivia's Case Study Follow-Up**

After her diagnosis, Olivia did some further research on her type I hypersensitivity to latex. She understands that she needs to avoid latex products. She also knows that the cornstarch used in powdered latex gloves serves as a carrier for allergenic proteins from latex. The powder may become airborne resulting in inhalation and subsequent allergic response in a sensitized person. However, Olivia remembers that her hospital has been latex-free for over 3 months. Too many people are allergic to it so the hospital established latex-free guidelines for employee and patient safety. For example, there are signs by the elevators reminding visitors not to bring in latex balloons for patients and the hospital gift shop only sells mylar (a nonlatex product) balloons.

Olivia spoke to the OR manager who said "Latex gloves were removed over 3 months ago in compliance with the hospital's latex-free guidelines." But another nurse stepped forward holding up a stack of sterile latex gloves. It was discovered that some of the latex gloves had not been removed from all of the ORs. By the end of the shift, any latex gloves that were accidentally overlooked were removed from all areas of the hospital.

Latex safety is important for Olivia in performing her job as a CRNA but she also needs to be aware to avoid all contact with any natural rubber latex in her home and out in the community. She wears a medical alert bracelet, uses a bronchodilator inhaler at the first symptom of bronchospasm, and carries a syringe of epinephrine at all times.





This review tests your understanding of the content introduced in this chapter. Follow the instructions for each exercise and check your answers in Appendix 11.

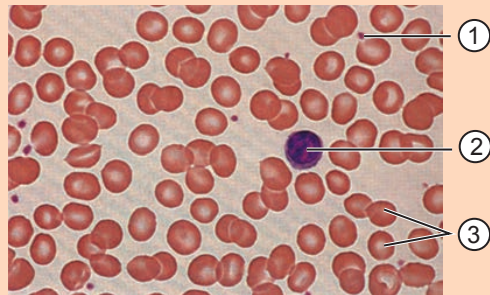
### LABELING EXERCISE

#### BLOOD CELLS

Write the name of each numbered part on the corresponding line of the answer sheet.

- Erythrocyte
- Leukocyte
- Platelet

1. \_\_\_\_\_
2. \_\_\_\_\_
3. \_\_\_\_\_



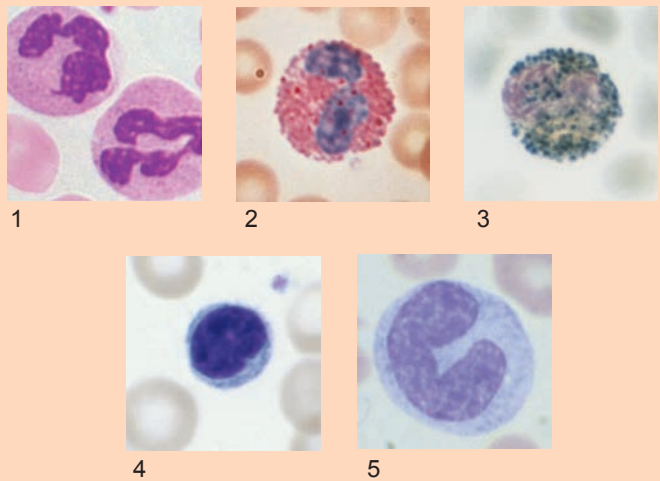
#### LEUKOCYTES (WHITE BLOOD CELLS)

Write the name of each numbered part on the corresponding line of the answer sheet.

- Basophil
- Eosinophil
- Lymphocyte
- Monocyte
- Neutrophil

1. \_\_\_\_\_
2. \_\_\_\_\_
3. \_\_\_\_\_
4. \_\_\_\_\_
5. \_\_\_\_\_

Leukocytes (white blood cells)



**TERMINOLOGY****MATCHING**

Match the following terms, and write the appropriate letter to the left of each number.

- |                          |  |
|--------------------------|--|
| ___ 1. anemia            | a. substance active in blood clotting                  |
| ___ 2. thrombolytic      | b. cell that produces platelets                        |
| ___ 3. antibody          | c. deficiency in the amount of hemoglobin in the blood |
| ___ 4. megakaryocyte     | d. able to dissolve a blood clot                       |
| ___ 5. prothrombin       | e. substance active in an immune response              |
|                          |  |
| ___ 6. hypokalemia       | a. condition involving iron deposits                   |
| ___ 7. natriuresis       | b. deficiency of potassium in the blood                |
| ___ 8. ferric            | c. urinary excretion of sodium                         |
| ___ 9. siderosis         | d. urinary excretion of nitrogenous compounds          |
| ___ 10. azoturia         | e. pertaining to iron                                  |
|                          |  |
| ___ 11. hemophilia       | a. allergy   |
| ___ 12. hemostasis       | b. hereditary form of anemia                           |
| ___ 13. hypersensitivity | c. stoppage of blood flow                              |
| ___ 14. thalassemia      | d. hereditary clotting disorder                        |
| ___ 15. purpura          | e. bleeding into the tissues                           |
|                          |  |
| ___ 16. pH               | a. laboratory test of blood                            |
| ___ 17. HIV              | b. a form of leukemia                                  |
| ___ 18. ALL              | c. hematocrit  |
| ___ 19. PCV              | d. virus that causes an immunodeficiency disease       |
| ___ 20. CBC              | e. scale for measuring acidity or alkalinity           |
|                          |  |
| <i>Enrichment Terms</i>  |  |
| ___ 21. erythrocytosis   | a. separation of blood and use of components           |
| ___ 22. heparin          | b. increase in the number of RBCs in the blood         |
| ___ 23. apheresis        | c. anticoagulant                                       |
| ___ 24. ELISA            | d. method for separating components of a solution      |
| ___ 25. electrophoresis  | e. sensitive immunologic test                          |

**FILL IN THE BLANKS**

Complete the sentence with the correct term(s).

26. The engulfing of foreign material by white cells is called \_\_\_\_\_.
27. The iron-containing pigment in red blood cells that carries oxygen is called \_\_\_\_\_.
28. A substance that separates into ions in solution is a(n) \_\_\_\_\_.
29. The cell fragments active in blood clotting are the \_\_\_\_\_.
30. A hemocytometer is used to count \_\_\_\_\_.
31. Oxyhemoglobin is hemoglobin combined with \_\_\_\_\_.
32. A hematoma is a localized collection of \_\_\_\_\_.
33. A disorder involving lack of hemoglobin in the blood is \_\_\_\_\_.
34. A myeloma is a neoplasm that involves the \_\_\_\_\_.
35. The abbreviation Ig means \_\_\_\_\_.

**MULTIPLE CHOICE**

Refer to Olivia's opening case study, select the best answer, and write the letter of your choice to the left of each number.

- |  |   |
|--|---|
| <p>_____ 36. Anaphylaxis, a life-threatening physiologic response, is an extreme form of</p> <ul style="list-style-type: none"><li>a. remission</li><li>b. hemostasis</li><li>c. hypersensitivity</li><li>d. homeostasis</li></ul> | <p>_____ 39. The natural latex protein in latex gloves may act as a(n)</p> <ul style="list-style-type: none"><li>a. antibody</li><li>b. allergen</li><li>c. purpura</li><li>d. immunocyte</li></ul> |
| <p>_____ 37. Urticaria is commonly called</p> <ul style="list-style-type: none"><li>a. hives</li><li>b. dermatitis</li><li>c. rhinitis</li><li>d. congenital</li></ul>   | <p>_____ 40. The common name for epinephrine is</p> <ul style="list-style-type: none"><li>a. cortisone</li><li>b. adrenaline</li><li>c. heparin</li><li>d. antihistamine</li></ul>                  |
| <p>_____ 38. The cells involved in a T cell-mediated allergic response are</p> <ul style="list-style-type: none"><li>a. basophils</li><li>b. monocytes</li><li>c. lymphocytes</li><li>d. B cells</li></ul>                         |   |

**TRUE-FALSE**

Examine the following statements. If the statement is true, write T in the first blank. If the statement is false, write F in the first blank, and correct the statement by replacing the underlined word in the second blank.

	True or False	Correct Answer
41. A leukocyte is also called a <u>platelet</u> .	_____	_____
42. A plasma cell produces <u>antibodies</u> .	_____	_____
43. The liquid that remains after blood coagulates is called <u>serum</u> .	_____	_____
44. Blood that does not react with either A or B antiserum is <u>type O</u> .	_____	_____
45. A band cell is an immature <u>monocyte</u> .	_____	_____
46. The root kali- pertains to <u>potassium</u> .	_____	_____

**DEFINITIONS**

The suffixes *-ia*, *-osis*, and *-hemia* all denote an increase in the type of cell indicated by the word root. Define the following terms.

47. leukocytosis (*lu-ko-si-TO-sis*) \_\_\_\_\_
48. eosinophilia (*e-o-sin-o-FIL-e-ah*) \_\_\_\_\_
49. erythrocytosis (*eh-rith-ro-si-TO-sis*) \_\_\_\_\_
50. thrombocythemia (*throm-bo-si-THE-me-ah*) \_\_\_\_\_
51. neutrophilia (*nu-tro-FIL-e-ah*) \_\_\_\_\_
52. monocytosis (*mon-o-si-TO-sis*) \_\_\_\_\_

Write a word for the following definitions.

53. An immature red blood cell \_\_\_\_\_
54. A decrease in the number of platelets (thrombocytes) in the blood \_\_\_\_\_
55. Presence of pus in the blood \_\_\_\_\_
56. Specialist in the study of immunity \_\_\_\_\_
57. Profuse flow of blood \_\_\_\_\_

Define each of the following.

58. hemolysis \_\_\_\_\_
59. neutropenia \_\_\_\_\_
60. myelotoxin \_\_\_\_\_
61. autoimmunity \_\_\_\_\_
62. viremia \_\_\_\_\_

**ADJECTIVES**

Use the ending *-ic* to write the adjective form of the following words.

63. hemolysis \_\_\_\_\_
64. leukemia \_\_\_\_\_
65. basophil \_\_\_\_\_
66. septicemia \_\_\_\_\_
67. thrombosis \_\_\_\_\_
68. lymphocyte \_\_\_\_\_

**ELIMINATIONS**

In each of the sets below, underline the word that does not fit in with the rest and explain the reason for your choice.

69. fibrin — thrombin — thrombolysis — prothrombin — fibrinogen  
\_\_\_\_\_
70. Diff — Hct — MCV — EPO — MCH  
\_\_\_\_\_
71. eosinophil — reticulocyte — monocyte — basophil — lymphocyte  
\_\_\_\_\_
72. allergy — hypersensitivity — gamma globulin — urticaria — anaphylaxis  
\_\_\_\_\_

**WORD BUILDING**

Write a word for the following definitions using the word parts given. Each word part can be used more than once.

-penia	-blast	leuk/o	-oid	-poiesis	myel/o	gen-	-emia	erythr/o	-ic	-oma	cyt/o
--------	--------	--------	------	----------	--------	------	-------	----------	-----	------	-------

73. pertaining to a red blood cell \_\_\_\_\_
74. an immature white blood cell \_\_\_\_\_
75. pertaining to bone marrow \_\_\_\_\_
76. originating in bone marrow \_\_\_\_\_
77. an immature bone marrow cell \_\_\_\_\_
78. neoplastic overgrowth of white cells in the blood \_\_\_\_\_
79. deficiency of white cells in the blood \_\_\_\_\_
80. cancer of bone marrow \_\_\_\_\_
81. formation of red blood cells \_\_\_\_\_
82. pertaining to bone marrow cells \_\_\_\_\_

**WORD ANALYSIS**

Define the following words, and give the meaning of the word parts in each. Use a dictionary if necessary.

83. pancytopenia (*pan-si-to-PE-ne-ah*)

- a. pan- \_\_\_\_\_
- b. cyt/o \_\_\_\_\_
- c. -penia \_\_\_\_\_

84. polycythemia (*pol-e-si-THE-me-ah*)

- a. poly- \_\_\_\_\_
- b. cyt/o \_\_\_\_\_
- c. hem/o \_\_\_\_\_
- d. -ia \_\_\_\_\_

85. anisochromia (*an-i-so-KRO-me-ah*)

- a. an- \_\_\_\_\_
- b. iso- \_\_\_\_\_
- c. chrom/o \_\_\_\_\_
- d. -ia \_\_\_\_\_

86. myelodysplastic (*mi-eh-lo-dis-PLAS-tic*)

- a. myel/o \_\_\_\_\_
- b. dys- \_\_\_\_\_
- c. plast(y) \_\_\_\_\_
- d. -ic \_\_\_\_\_

# Additional Case Studies

## Case Study 11-1: Blood Replacement

Lisa, a 16 y/o, sustained a ruptured liver when she hit a tree while sledding. Emergency surgery was needed to stop the internal bleeding. During surgery, the ruptured segment of the liver was removed, and the laceration was sutured with a heavy, absorbable suture on a large smooth needle. Before surgery, her hemoglobin was 10.2 g/dL, but the reading decreased to 7.6 g/dL before hemostasis was attained. Cell salvage, or autotransfusion, was set up. In this procedure, the free blood was suctioned from her abdomen and mixed with an anticoagulant (heparin). The RBCs were washed in a sterile centrifuge with NS and transfused back to her through tubing fitted with a filter. She also received six units of homologous,

leukocyte-reduced whole blood, five units of fresh frozen plasma, and two units of platelets. During the surgery, the CRNA repeatedly tested her Hgb and Hct as well as prothrombin time and partial thromboplastin time to monitor her clotting mechanisms.

Lisa is B-positive. Fortunately, there was enough B-positive blood in the hospital blood bank for her surgery. The laboratory informed her surgeon that they had two units of B-negative and six units of O-negative blood, which she could have received safely if she needed more blood during the night. However, her hemoglobin level increased to 12 g/dL, and she was stable during her recovery. She was monitored for DIC and pulmonary emboli.

### Case Study 11-1 Questions

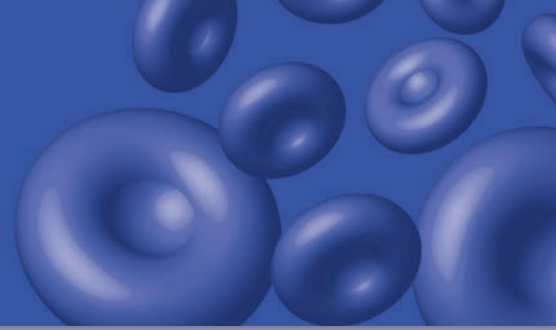
Follow the instructions for each question and check your answers in Appendix 11.

**Multiple Choice.** Select the best answer, and write the letter of your choice to the left of each number.

- |  |   |
|--|---|
| <p>_____ 1. The unit for hemoglobin measurement (g/dL) means</p> <ul style="list-style-type: none"><li>a. grams in decimal point</li><li>b. grains in a deciliter</li><li>c. drops in 50 mL</li><li>d. grams in 100 mL</li></ul> <p>_____ 2. Heparin, an anticoagulant, is a drug that</p> <ul style="list-style-type: none"><li>a. increases the rate of blood clotting</li><li>b. takes the place of fibrin</li><li>c. makes blood thinner than water</li><li>d. interferes with blood clotting</li></ul> <p>_____ 3. The RBCs were washed with NS. This means the _____ were washed with _____.</p> <ul style="list-style-type: none"><li>a. reticulocytes, heparin</li><li>b. red blood cells, nutritional solution</li><li>c. erythrocytes, normal saline</li><li>d. red blood cells, heparin</li></ul> | <p>_____ 4. Autotransfusion is transfusion of autologous blood, that is, the patient's own blood. Homologous blood is taken from</p> <ul style="list-style-type: none"><li>a. another human</li><li>b. synthetic chemicals</li><li>c. plasma with clotting factors</li><li>d. IV fluid with electrolytes</li></ul> <p>_____ 5. Patients who lose significant amounts of blood may lose clotting ability. Effective therapy in such cases would be replacement of</p> <ul style="list-style-type: none"><li>a. IV solution with electrolytes</li><li>b. packed RBCs</li><li>c. platelets</li><li>d. heparin</li></ul> <p>_____ 6. Lisa's blood type is B-positive. The best blood for her to receive is</p> <ul style="list-style-type: none"><li>a. A-negative</li><li>b. AB-positive</li><li>c. B-negative</li><li>d. B-positive</li></ul> |
|--|---|

Define the following abbreviations.

- 7. PT \_\_\_\_\_
- 8. PTT \_\_\_\_\_
- 9. FFP \_\_\_\_\_
- 10. DIC \_\_\_\_\_



## Case Study 11-2: Myelofibrosis

Ada, a 52 y/o kindergarten teacher, had myelofibrosis that had been in remission for 25 years. She had seen her hematologist regularly and had had routine blood testing since the age of 27. After several weeks of fatigue, idiopathic joint and muscle aching, weakness, and a frightening episode of syncope, she saw her hematologist for evaluation. Her hemoglobin was 9.0 g/dL and her hematocrit was 29%. Concerned that she was having an exacerbation, her doctor scheduled a bone marrow aspiration, and the results were positive for myelofibrosis.

Ada went through a 6-month therapy regimen of iron supplements in the form of ferrous sulfate tablets and received weekly vitamin B<sub>12</sub> injections. Interferon was given every other week in addition to erythropoiesis therapy,

which was unsuccessful. She was treated for presumed aplastic anemia. During treatment, splenomegaly developed, which compromised her abdominal organs and pulmonary function. She continued to lose weight, and her hemoglobin dropped as low as 6.0 g/dL. Weekly transfusions of packed RBCs did not improve her hemoglobin and hematocrit.

After a regimen of high-dose chemotherapy to shrink the fibers in her bone marrow and a splenectomy, Ada received a stem cell transplant. The stem cells were obtained from blood donated by her brother, who was a perfect immunologic match. After a 6-month period of recovery in a protected environment, required because of her immunocompromised state, Ada returned home and has been free of disease symptoms for over 1 year.

### Case Study 11-2 Questions

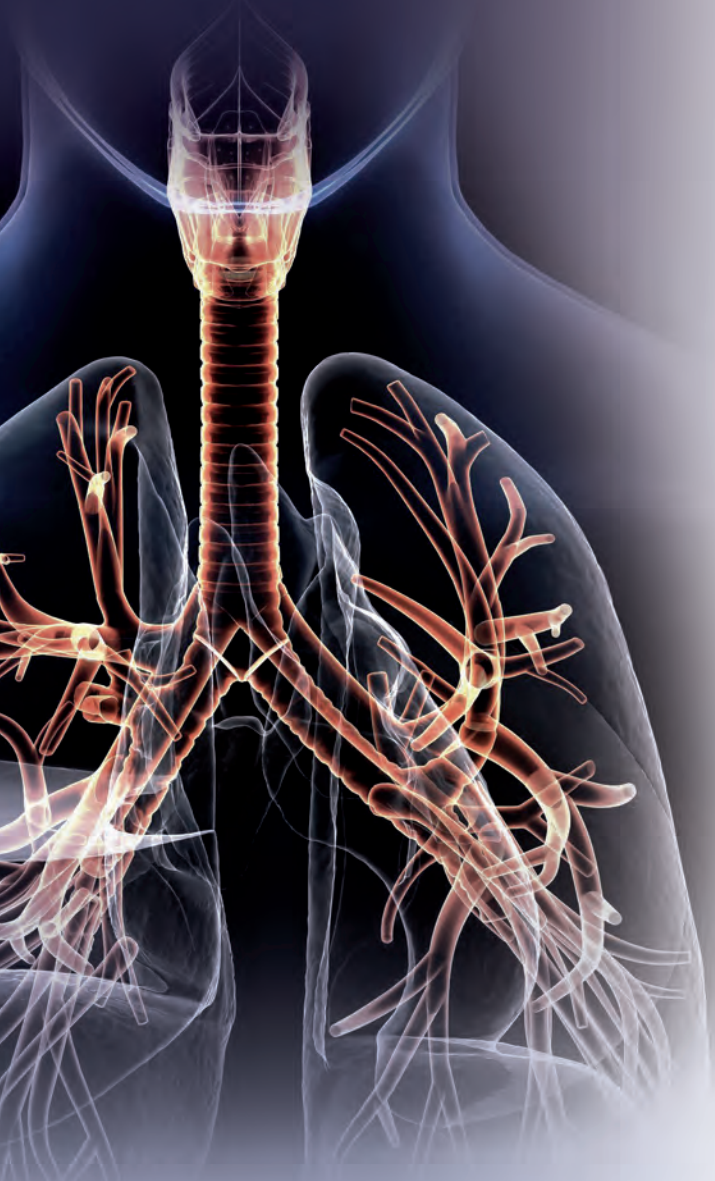**Multiple Choice.** Select the best answer, and write the letter of your choice to the left of each number.

- \_\_\_\_\_ 1. Myelofibrosis, like aplastic anemia, is a disease in which there is
  - a. overgrowth of RBCs
  - b. destruction of the bone marrow
  - c. dangerously high hemoglobin and hematocrit
  - d. absence of bone marrow
- \_\_\_\_\_ 2. Erythropoiesis is
  - a. production of blood
  - b. production of red cells
  - c. destruction of platelets
  - d. destruction of white cells
- \_\_\_\_\_ 3. The “ferrous” in ferrous sulfate represents
  - a. electrolytes
  - b. B vitamins
  - c. iron
  - d. oxygen
- \_\_\_\_\_ 4. Hemoglobin and hematocrit values pertain to
  - a. leukocytes
  - b. fibrinogen
  - c. granulocytes
  - d. red blood cells
- \_\_\_\_\_ 5. Splenomegaly is
  - a. prolapse of the spleen
  - b. movement of the spleen
  - c. enlargement of the lymph glands
  - d. enlargement of the spleen
- \_\_\_\_\_ 6. The stem cells Ada received were expected to develop into new
  - a. spleen cells
  - b. bone marrow cells
  - c. hemoglobin
  - d. cartilage
- \_\_\_\_\_ 7. Ada’s health was compromised because the high-dose chemotherapy caused
  - a. immunodeficiency
  - b. electrolyte imbalance
  - c. anoxia
  - d. autoimmunity

Define the following abbreviations.

- 8. Hgb \_\_\_\_\_
- 9. Hct \_\_\_\_\_
- 10. RBC \_\_\_\_\_

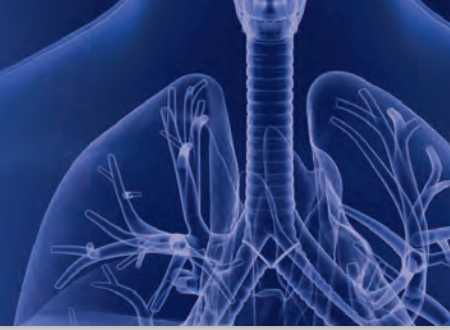



## Pretest

**Multiple Choice.** Select the best answer, and write the letter of your choice to the left of each number. To check your answers go to Appendix 11.

- \_\_\_\_\_ 1. The gas that is supplied to tissues by the respiratory system is
  - a. sulfur
  - b. neon
  - c. oxygen
  - d. carbon dioxide
- \_\_\_\_\_ 2. The gas that is eliminated by the respiratory system is
  - a. chlorine
  - b. carbon dioxide
  - c. hydrogen
  - d. fluoride
- \_\_\_\_\_ 3. The air sacs through which gases are exchanged in the lungs are the
  - a. trachea
  - b. bronchi
  - c. bursae
  - d. alveoli
- \_\_\_\_\_ 4. The structure that holds the vocal folds is the
  - a. larynx
  - b. tongue
  - c. uvula
  - d. tonsils
- \_\_\_\_\_ 5. The tubes that carry air from the trachea into the lungs are the
  - a. arteries
  - b. nares
  - c. veins
  - d. bronchi
- \_\_\_\_\_ 6. The dome-shaped muscle under the lungs is the
  - a. palate
  - b. hiatus
  - c. diaphragm
  - d. esophagus
- \_\_\_\_\_ 7. The membrane around the lungs is the
  - a. peritoneum
  - b. mucosa
  - c. pleura
  - d. mediastinum
- \_\_\_\_\_ 8. A term for inflammation of the lungs is
  - a. bronchitis
  - b. pneumonia
  - c. pleurisy
  - d. laryngitis



## Learning Objectives

After careful study of this chapter, you should be able to:

- 1 Compare external and internal gas exchange. **P392**
- 2 Describe and give the functions of the structures in the respiratory tract. **P392**
- 3 Describe the mechanism of breathing, including the roles of the diaphragm and phrenic nerve. **P395**
- 4 Explain how oxygen and carbon dioxide are carried in the blood. **P396**
- 5 Identify and use word parts pertaining to the respiratory system. **P398**
- 6 Discuss nine disorders of the respiratory system. **P401**
- 7 Name three types of organisms that can infect the respiratory system and give examples of each. **P401**
- 8 List and define 10 volumes and capacities commonly used to measure pulmonary function. **P407**
- 9 Interpret abbreviations commonly used with reference to the respiratory system. **P414**
- 10 Analyze medical terms in case studies pertaining to respiration. **PP391, 422**

## Case Study: Preoperative Respiratory Testing for Allison, a Young Girl With Asthma



### Chief Complaint

Allison, a 13 y/o, was seen in the preadmission testing unit in preparation for her elective spinal surgery for scoliosis. She has a history of mild asthma since age 4 with at least one attack a week.

In an acute attack, she will have mild dyspnea, diffuse wheezing, yet an adequate air exchange that responds to bronchodilators. She was sent to pulmonary health services for a consult with a pulmonologist and pulmonary function studies to clear her for the upcoming spinal surgery.

### Examination

Her physical examination was unremarkable except for her respiratory status. Her prebronchodilator spirometry showed a mild reduction in vital capacity but with a moderate to severe decrease in FEV<sub>1</sub> and FEV<sub>1</sub>/FVC ratio. After bronchodilator administration, there was a mild but

insignificant improvement in FEV<sub>1</sub>. The postbronchodilator FEV<sub>1</sub> was 55% of predicted value and was considered moderately abnormal. The flow volume loops and spirographic curves were consistent with airflow obstruction.

### Clinical Course

The anesthesiologist reviewed the pulmonologist's report. Allison's respiratory status was compromised for the surgical procedure and would require medical intervention prior to going to the OR. When the FEV<sub>1</sub> was acceptable, he spoke with Allison and the family and explained that her respiratory status would be closely monitored during and after surgery. Additional medications would be needed to maintain optimal airflow and oxygenation.

**Case Study Revisited: Once you complete this chapter, please review the case follow-up on p. 415.**

## Ancillaries *At-A-Glance*

Visit the web resource to access the following resources.

### Learning Resources

- eBook
- A&P Module with Heart & Lung Sounds
- Image Bank
- TestPrep
- Animations
- Audio Pronunciation Glossary

## Introduction

The main function of the respiratory system is to provide oxygen to body cells for energy metabolism and to eliminate **carbon dioxide**, a byproduct of metabolism. Because these gases must be carried to and from the cells in the blood, the respiratory system works closely with the cardiovascular system to accomplish gas exchange (FIG. 12-1). This activity has two phases:

- External gas exchange occurs between the outside atmosphere and the blood.
- Internal gas exchange occurs between the blood and the tissues.

External exchange takes place in the **lungs**, located in the thoracic cavity. The remainder of the respiratory tract consists of a series of passageways that conduct air to and from the lungs. No gas exchange occurs in these regions. Refer to **FIGURE 12-2** as you read the following description of the respiratory tract.

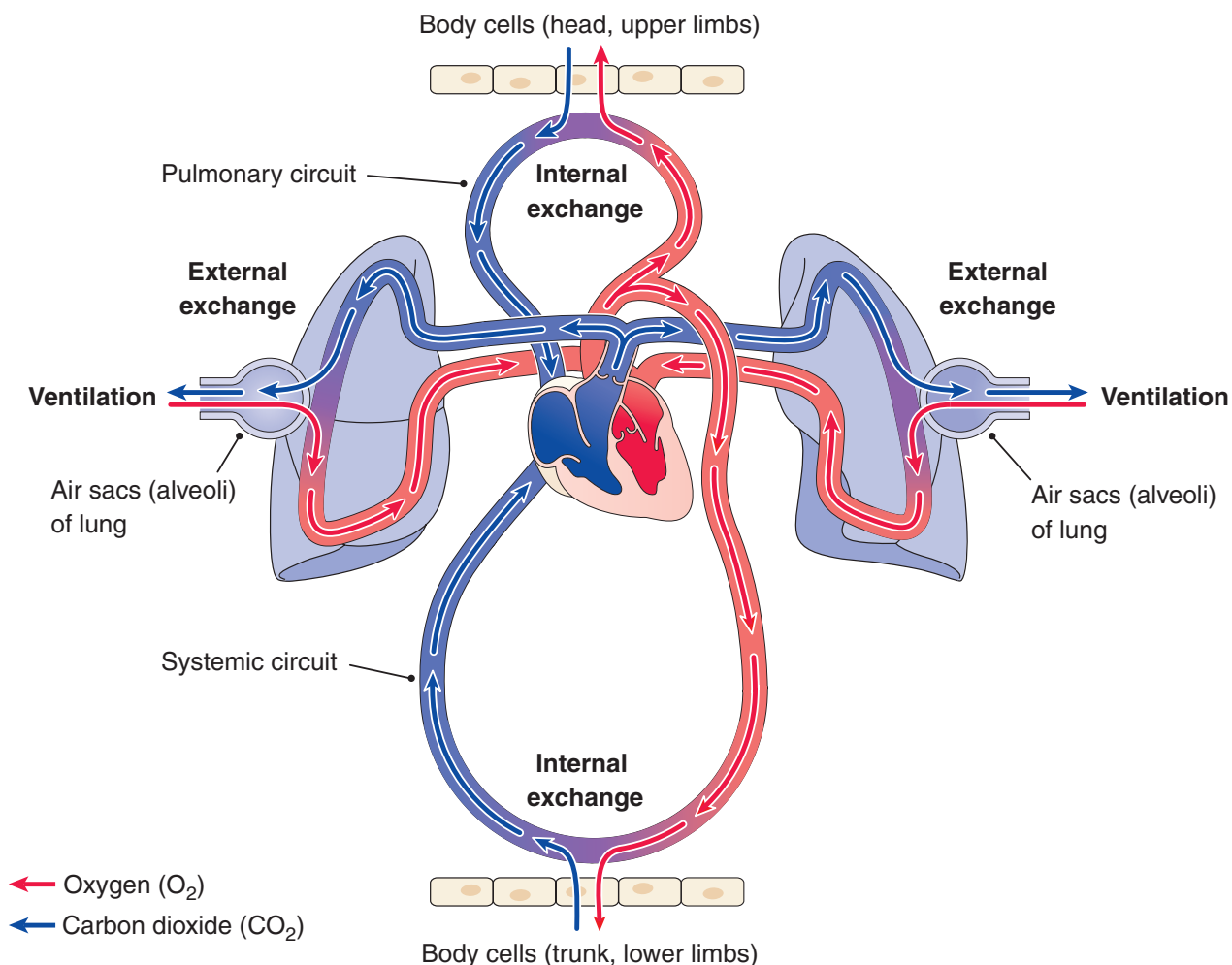
## Upper Respiratory Passageways

The upper respiratory passageways consist of the **nose** and **pharynx** (throat). Air can also be exchanged through the mouth, but there are fewer mechanisms for cleansing the air taken in by this route.

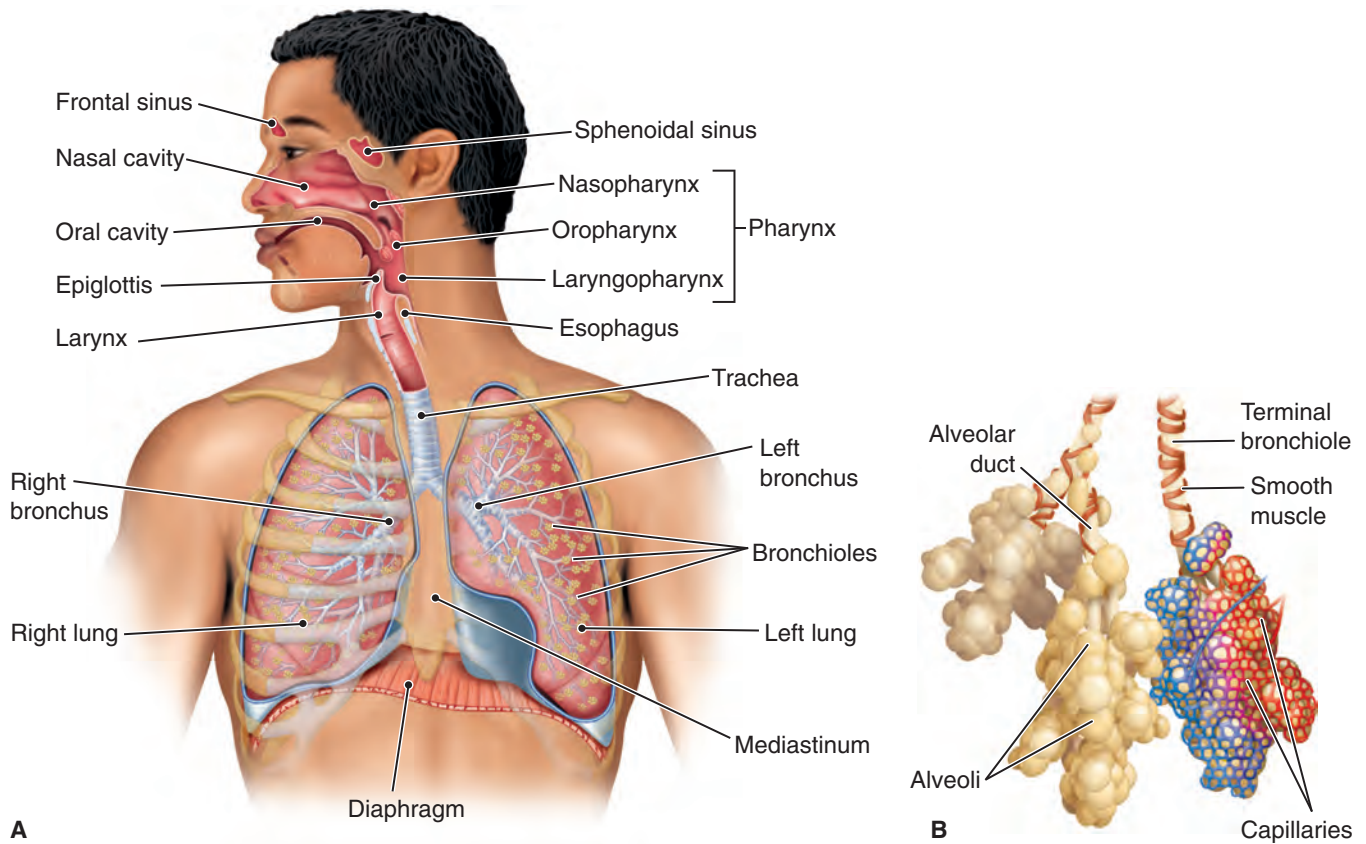
### THE NOSE

Air enters through the nose, where it is warmed, filtered, and moistened as it passes over the hair-covered mucous membranes of the nasal cavity. Cilia—microscopic hair-like projections from the cells that line the nasal passageways—sweep dirt and foreign material toward the throat for elimination. Material that is eliminated from the respiratory tract by coughing or clearing the throat is called **sputum**. Receptors for the sense of smell are located within bony side projections of the nasal cavity called **turbinate bones** or **conchae**.

In the bones of the skull and face near the nose are air-filled cavities lined with a mucous membrane that drain into



**FIGURE 12-1 Respiration.** In ventilation, gases are moved into and out of the lungs. In external exchange, gases move between the air sacs (alveoli) of the lungs and the blood. In internal exchange, gases move between the blood and body cells. The circulation transports gases in the blood.



**FIGURE 12-2** The respiratory system. **A.** Overview including some nearby structures. **B.** Enlarged section of lung tissue showing the relationship between the alveoli (air sacs) and the blood capillaries.

the nasal cavity. These chambers lighten the bones and provide resonance for speech production. These cavities, called **sinuses**, are named specifically for the bones in which they are located, such as the frontal, sphenoidal, ethmoidal, and maxillary sinuses. Together, because they are near the nose, these cavities are referred to as the paranasal sinuses. **FIGURE 12-2** shows the location of the frontal and sphenoidal sinuses.

## THE PHARYNX

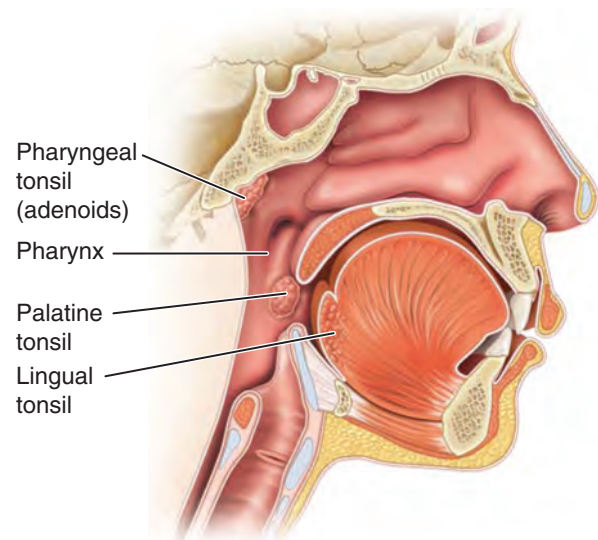
Inhaled air passes into the throat, or pharynx, where it mixes with air that enters through the mouth and also with food destined for the digestive tract. The pharynx is divided into three regions, which are shown in **FIGURE 12-2**:

- The nasopharynx is the superior portion located behind the nasal cavity.
- The oropharynx is the middle portion located behind the mouth.
- The laryngopharynx is the inferior portion located behind the larynx.

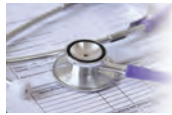The tonsils, lymphoid tissue described in Chapter 10, are in the region of the pharynx (**FIG. 12-3**):

- The **palatine tonsils** are on either side of the soft palate in the oropharynx.

- The single pharyngeal tonsil, commonly known as the **adenoids**, is in the nasopharynx.
- The **lingual tonsils** are small mounds of lymphoid tissue at the posterior of the tongue.



**FIGURE 12-3** The tonsils. All of the tonsils are located in the vicinity of the pharynx (throat).



## CLINICAL PERSPECTIVES

### Tonsillectomy: A Procedure Reconsidered

BOX 12-1

Tonsillitis, a bacterial infection of the tonsils, is a common childhood illness. In past years, surgical removal of the infected tonsils was a standard procedure, as tonsillectomy was thought to prevent severe infections like strep throat. Because tonsils were thought to have little function, surgeons often removed infected tonsils—even healthy tonsils, in order to prevent tonsillitis later. With the discovery that tonsils play an important immune function, the number of tonsillectomies performed in the United States dropped dramatically, reaching an all-time low in the 1980s.

Today, although many cases of tonsillitis are successfully treated with appropriate antibiotics, tonsillectomy is becoming more frequent; in fact, it is the second most common surgical procedure among American children. Surgery is considered if an infection recurs or if enlarged tonsils make swallowing

or breathing difficult. Many tonsillectomies are performed in children to treat obstructive sleep apnea, a condition in which the child stops breathing for a few seconds at a time during sleep. Recent studies suggest that tonsillectomy may also be beneficial for children suffering from otitis media (middle ear infection), because bacteria infecting the tonsils may travel to this region of the ear.

Most tonsillectomies are performed by electrocautery, a technique that uses an electrical current to burn the tonsils away from the throat. Now that this operation is becoming more common, surgeons are developing new techniques. For example, coblation tonsillectomy uses radio waves to break down tonsillar tissue. Studies suggest that this procedure results in a faster recovery, fewer complications, and decreased postoperative pain compared with electrocautery.

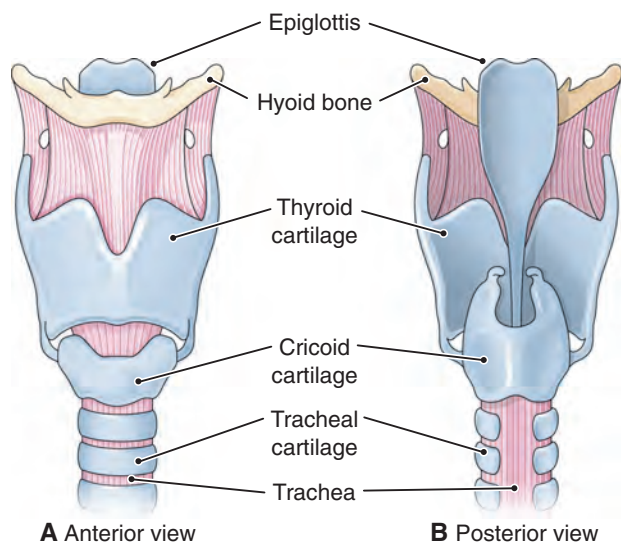
Opinions on the advisability of removing the tonsils have changed over time, as described in **BOX 12-1**.

## Lower Respiratory Passageways and Lungs

Air moves from the pharynx into the larynx, commonly called the voice box, because it contains the **vocal folds**, or cords. The larynx is at the top of the **trachea**, commonly called the windpipe, which conducts air into the bronchial system toward the lungs.

### THE LARYNX

The larynx is shaped by nine cartilages, the most prominent of which is the anterior thyroid cartilage that forms the



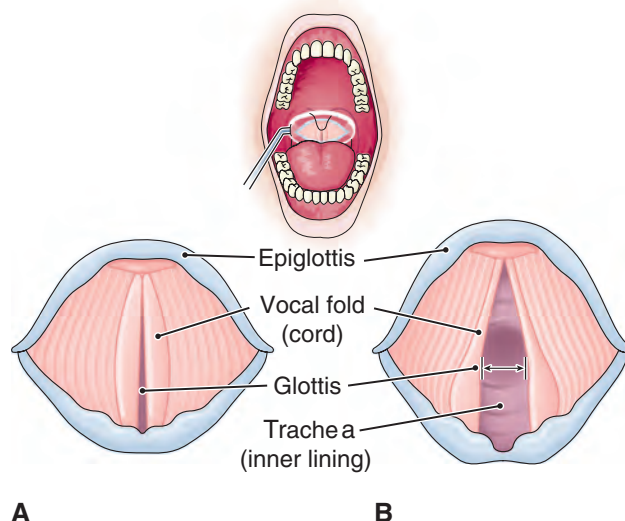
**FIGURE 12-4** The larynx from anterior (A) and posterior (B) views.

“Adam’s apple” (**FIG. 12-4**). The small leaf-shaped cartilage at the top of the larynx is the **epiglottis**. When one swallows, the epiglottis covers the opening of the larynx and helps prevent food from entering the respiratory tract.

The larynx contains the vocal folds, bands of tissue that are important in speech production (**FIG. 12-5**). Vibrations produced by air passing over the vocal folds form the basis for voice production, although portions of the throat and mouth are needed for proper speech articulation. The opening between the vocal folds is the **glottis** (the epiglottis is above the glottis).

### THE TRACHEA

The trachea is a tube reinforced with C-shaped rings of cartilage to prevent its collapse (you can feel these rings if you



**FIGURE 12-5** The vocal folds, superior view. A. The glottis in closed position. B. The glottis in open position.

press your fingers gently against the front of your throat). Cilia in the trachea's lining move impurities up toward the throat, where they can be eliminated by swallowing or by **expectoration**, coughing them up.

The trachea is contained in a region known as the **mediastinum**, which consists of the space between the lungs together with the organs contained in this space (see FIG. 12-2). In addition to the trachea, the mediastinum contains the heart, esophagus, large vessels, and other tissues.

## THE BRONCHIAL SYSTEM

At its lower end, the trachea divides into a right and a left primary **bronchus**, which enter the lungs. The right bronchus is shorter and wider; it divides into three secondary bronchi in the right lung. The left bronchus divides into two branches that supply the left lung. Further divisions produce an increasing number of smaller tubes that supply air to smaller subdivisions of lung tissue. As the air passageways progress through the lungs, the cartilage in the walls gradually disappears and is replaced by smooth (involuntary) muscle.

The smallest of the conducting tubes, the **bronchioles**, carry air into the microscopic air sacs, the **alveoli**, through which gases are exchanged between the lungs and the blood. It is through the ultrathin walls of the alveoli and their surrounding capillaries that **oxygen** ( $O_2$ ) diffuses into the blood and carbon dioxide diffuses out of the blood for elimination (see FIG. 12-2).

## THE LUNGS

The cone-shaped lungs occupy the major portion of the thoracic cavity. The right lung is larger and divided into

three lobes. The left lung, which is smaller to accommodate the heart, is divided into two lobes. The lobes are further subdivided to correspond to divisions of the bronchial network.

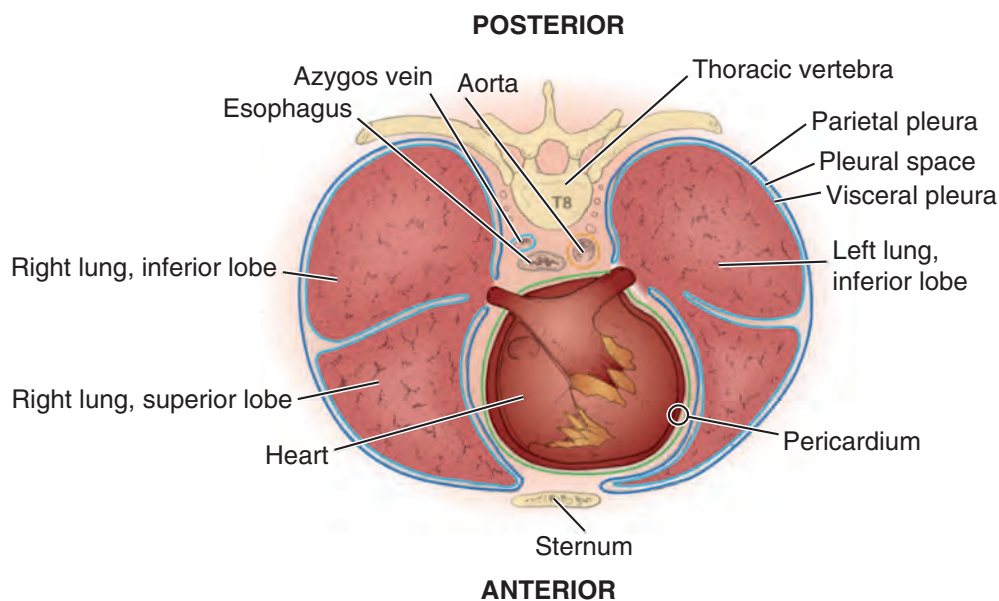
A double membrane, the **pleura**, covers the lungs and lines the thoracic cavity (FIG. 12-6). There are two pleural layers:

- The **parietal pleura**, the outer layer, is attached to the wall of the thoracic cavity.
- The **visceral pleura**, the inner layer, is attached to the surface of the lungs.

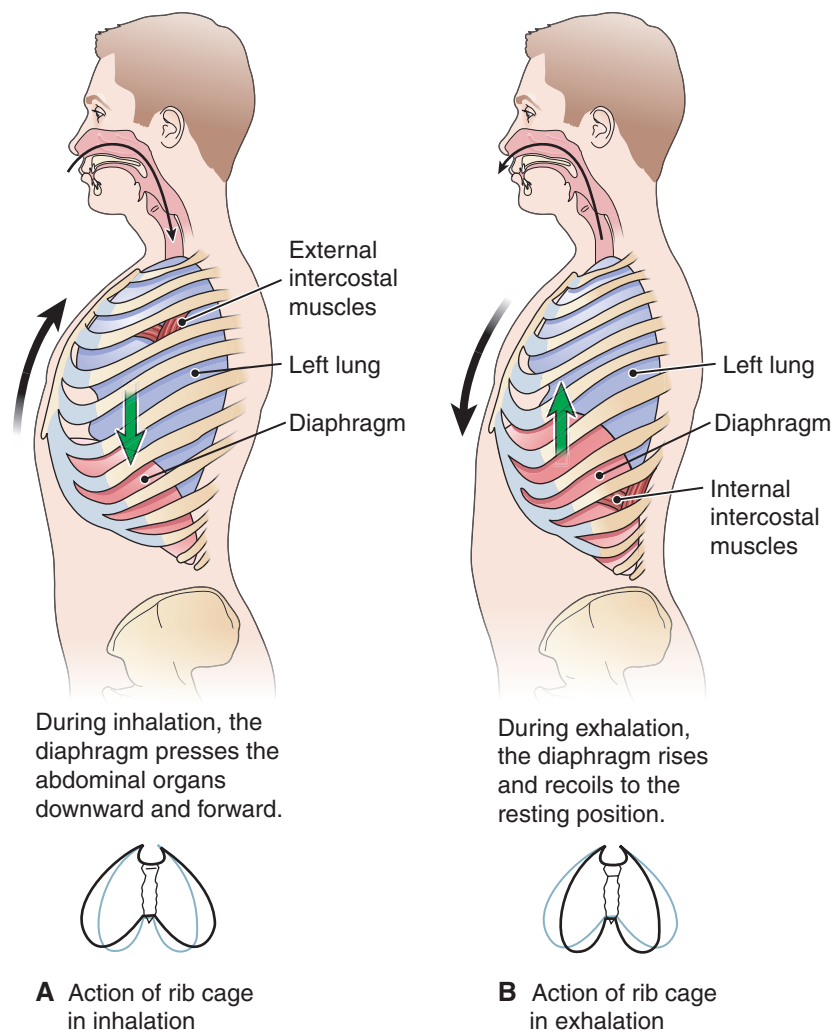
The very narrow, fluid-filled space between the two layers is the **pleural space**. The moist pleural membranes slide easily over each other within the chest cavity, allowing the lungs to expand during breathing.

## Breathing

Air is moved into and out of the lungs by the process of breathing, technically called **pulmonary ventilation**. This consists of a steady cycle of **inspiration** (inhalation) and **expiration** (exhalation), separated by a period of rest. Breathing is normally regulated unconsciously by centers in the brainstem. These centers adjust the rate and rhythm of breathing according to changes in the blood composition, especially the concentration of carbon dioxide.



**FIGURE 12-6 The pleura.** A transverse section through the lungs shows the parietal and visceral layers of the pleura as well as structures in the mediastinum.



**FIGURE 12-7 Pulmonary ventilation.** **A.** In inhalation, the diaphragm lowers, and the external intercostals elevate the rib cage. **B.** In exhalation, the breathing muscles relax, the diaphragm rises, and the lungs spring back to their original size. The internal intercostals draw the ribs downward in forceful exhalation.

## INSPIRATION

The breathing cycle begins when the **phrenic nerve** stimulates the **diaphragm** to contract and flatten, enlarging the chest cavity. At the same time, external intercostal muscles between the ribs elevate and expand the rib cage. A resulting decrease in pressure within the thorax causes air to flow into the lungs (FIG. 12-7). Muscles of the neck and thorax are used in addition for forceful inhalation.

The measure of how easily the lungs expand under pressure is **compliance**. Fluid produced in the lungs, known as **surfactant**, aids in compliance by reducing surface tension within the alveoli.

## EXPIRATION

Expiration occurs as the breathing muscles relax and the elastic lungs spring back to their original size. Increased

pressure in the smaller thorax forces air out of the lungs. In forceful exhalation, the internal intercostal muscles contract to lower the rib cage, and the abdominal muscles contract, pressing internal organs upward against the diaphragm.

## Gas Transport

Oxygen is carried in the blood bound to **hemoglobin** in red blood cells. The oxygen is released to the cells as needed. Carbon dioxide is carried in several ways but is mostly converted to **carbonic acid**. The amount of carbon dioxide that is exhaled is important in regulating the blood's acidity or alkalinity, based on the amount of carbonic acid that is formed. Dangerous shifts in blood pH can result from exhalation of too much or too little carbon dioxide.

## Terminology

## Key Terms

The terms listed below are emphasized in this chapter. Knowing them will help you organize and prioritize your learning. These boldface terms are also found, collectively, with all chapter key terms in the Glossary.

## Normal Structure and Function

<b>adenoids</b> <i>AD-eh-noyds</i>	Lymphoid tissue located in the nasopharynx; the pharyngeal tonsils
<b>alveoli</b> <i>al-VE-o-li</i>	The tiny air sacs in the lungs through which gases are exchanged between the atmosphere and the blood in respiration (singular: alveolus); an alveolus, in general, is a small hollow or cavity; the term also applies to the bony socket for a tooth
<b>bronchiole</b> <i>BRONG-ke-ole</i>	One of the smaller subdivisions of the bronchial tubes (root: bronchiol/o)
<b>bronchus</b> <i>BRONG-kus</i>	One of the larger air passageways in the lungs; the bronchi begin as two branches of the trachea and then subdivide within the lungs (plural: bronchi) (root: bronch/o)
<b>carbon dioxide (CO<sub>2</sub>)</b> <i>KAR-bon di-OK-side</i>	A gas produced by energy metabolism in cells and eliminated through the lungs
<b>carbonic acid</b> <i>kar-BON-ik</i>	An acid formed when carbon dioxide dissolves in water; H <sub>2</sub> CO <sub>3</sub>
<b>compliance</b> <i>kom-PLI-ans</i>	A measure of how easily the lungs expand under pressure; compliance is reduced in many types of respiratory disorders
<b>diaphragm</b> <i>DI-ah-fragm</i>	The dome-shaped muscle under the lungs that flattens during inspiration (root: phren/o)
<b>epiglottis</b> <i>ep-ih-GLOT-is</i>	A leaf-shaped cartilage that covers the larynx during swallowing to prevent food from entering the trachea
<b>expectoration</b> <i>ek-spek-to-RA-shun</i>	The act of coughing up material from the respiratory tract; also the material thus released; sputum
<b>expiration</b> <i>ek-spih-RA-shun</i>	The act of breathing out or expelling air from the lungs; exhalation
<b>glottis</b> <i>GLOT-is</i>	The opening between the vocal folds
<b>hemoglobin</b> <i>HE-mo-glo-bin</i>	The iron-containing pigment in red blood cells that transports oxygen
<b>inspiration</b> <i>in-spih-RA-shun</i>	The act of drawing air into the lungs; inhalation
<b>larynx</b> <i>LAR-inks</i>	The enlarged, superior portion of the trachea that contains the vocal folds (root: laryng/o)
<b>lingual tonsils</b>	Small mounds of lymphoid tissue at the posterior of the tongue
<b>lung</b>	A cone-shaped, spongy respiratory organ contained within the thorax (roots: pneum/o, pulm/o)
<b>mediastinum</b> <i>me-de-as-TI-num</i>	The space between the lungs together with the organs contained in this space
<b>nose</b>	The organ of the face used for breathing and housing receptors for the sense of smell; includes an external portion and an internal nasal cavity (roots: nas/o, rhin/o)
<b>oxygen (O<sub>2</sub>)</b> <i>OK-sih-jen</i>	The gas needed by cells to release energy from food during metabolism
<b>palatine tonsils</b> <i>PAL-ah-tine</i>	The paired masses of lymphoid tissue located on either side of the oropharynx; usually meant when the term tonsils is used alone

(continued)



## Terminology

## Key Terms (Continued)

<b>pharynx</b> <i>FAR-inks</i>	The throat; a common passageway for food entering the esophagus and air entering the larynx (root: pharyng/o)
<b>phrenic nerve</b> <i>FREN-ik</i>	The nerve that activates the diaphragm (root: phrenic/o)
<b>pleura</b> <i>PLURE-ab</i>	A double-layered membrane that lines the thoracic cavity (parietal pleura) and covers the lungs (visceral pleura) (root: pleur/o)
<b>pleural space</b>	The thin, fluid-filled space between the two layers of the pleura; pleural cavity
<b>pulmonary ventilation</b> <i>PUL-mo-nare-e ven-tib-LA-shun</i>	The movement of air into and out of the lungs
<b>sinus</b> <i>SI-nus</i>	A cavity or channel; the paranasal sinuses are located near the nose and drain into the nasal cavity
<b>sputum</b> <i>SPU-tum</i>	The substance released by coughing or clearing the throat; expectoration; it may contain a variety of materials from the respiratory tract
<b>surfactant</b> <i>sur-FAK-tant</i>	A substance that decreases surface tension within the alveoli and eases lung expansion
<b>trachea</b> <i>TRA-ke-ab</i>	The air passageway that extends from the larynx to the bronchi (root: trache/o)
<b>turbinate bones</b> <i>TUR-bih-nate</i>	The bony projections in the nasal cavity that contain receptors for the sense of smell; also called conchae ( <i>KON-ke</i> ) (singular: concha [ <i>KON-kah</i> ])
<b>vocal folds</b> <i>VO-kal</i>	Membranous folds on either side of the larynx that are important in speech production; also called vocal cords

## Word Parts Pertaining to the Respiratory System

See TABLES 12-1 to 12-3.

Table 12-1		Suffixes for Respiration	
Suffix	Meaning	Example	Definition of Example
-pnea	breathing	dyspnea <i>disp-NE-ab</i>	shortness of breath; painful or difficult breathing
-oxia <sup>a</sup>	level of oxygen	hypoxia <i>hi-POK-se-ab</i>	decreased amount of oxygen in the tissues
-capnia <sup>a</sup>	level of carbon dioxide	hypocapnia <i>hi-po-KAP-ne-ab</i>	decreased carbon dioxide in the tissues
-phonia	voice	aphonia <i>ab-FO-ne-ab</i>	loss of voice

<sup>a</sup>When referring to levels of oxygen and carbon dioxide in the blood, the suffix *-emia* is used as in hypoxemia, hypercapnemia.

## Exercise 12-1

Complete the exercise. To check your answers go to Appendix 11.

Use the suffix *-pnea* to form words with the following meanings.

- breathing difficulty that is relieved by assuming an upright position (ortho) \_\_\_\_\_
- slow (brady-) rate of breathing \_\_\_\_\_
- easy, normal (eu-) breathing \_\_\_\_\_
- painful or difficult breathing \_\_\_\_\_

Use the ending *-pneic* to write the adjective form of the above words.

- \_\_\_\_\_
- \_\_\_\_\_
- \_\_\_\_\_
- \_\_\_\_\_

Use the suffixes in TABLE 12-1 to write a word for each of the following definitions.

- difficulty speaking \_\_\_\_\_
- decreased carbon dioxide in the tissues \_\_\_\_\_
- lack of (an-) oxygen in the tissues \_\_\_\_\_
- increased levels of carbon dioxide in the tissues \_\_\_\_\_

Table 12-2 Roots for the Respiratory Passageways

Root	Meaning	Example	Definition of Example
nas/o	nose	intranasal <i>in-trab-NA-zal</i>	within the nose
rhin/o	nose	rhinoplasty <i>RI-no-plas-te</i>	plastic repair of the nose
pharyng/o <sup>a</sup>	pharynx	pharyngeal <i>fab-RIN-je-al</i>	pertaining to the pharynx
laryng/o <sup>a</sup>	larynx	laryngospasm <i>lah-RIN-go-spazm</i>	spasm (sudden contraction) of the larynx
trache/o	trachea	tracheotome <i>TRA-ke-o-tome</i>	instrument used to incise the trachea
bronch/o, bronch/i	bronchus	bronchogenic <i>brong-ko-GEN-ik</i>	originating in a bronchus
bronchiol	bronchiole	bronchiolectasis <i>brong-ke-o-LEK-tah-sis</i>	dilatation of the bronchioles

<sup>a</sup>An *e* is added to the root before the adjective ending *-al*.

## Exercise 12-2

Complete the exercise. To check your answers go to Appendix 11.

Write words for the following definitions.

- discharge from the nose \_\_\_\_\_
- pertaining to the larynx (see *pharynx* in TABLE 12-2) \_\_\_\_\_
- inflammation of the bronchi \_\_\_\_\_

(continued)

## Exercise 12-2 (Continued)

4. endoscopic examination of the pharynx \_\_\_\_\_
5. plastic repair of the larynx \_\_\_\_\_
6. surgical incision of the trachea \_\_\_\_\_
7. narrowing of a trachea \_\_\_\_\_
8. inflammation of the bronchioles \_\_\_\_\_

Define the following words (note the adjectival endings).

9. bronchiolar (*brong-KE-o-lar*) \_\_\_\_\_
10. paranasal (*par-ab-NA-zal*) \_\_\_\_\_
11. peribronchial (*per-ib-BRONG-ke-al*) \_\_\_\_\_
12. endotracheal (*en-do-TRA-ke-al*) \_\_\_\_\_
13. nasopharyngeal (*na-zo-fab-RIN-je-al*) \_\_\_\_\_
14. bronchiectasis (*brong-ke-EK-tab-sis*) \_\_\_\_\_

Table 12-3 Roots for the Lungs and Breathing

Root	Meaning	Example	Definition of Example
phren/o	diaphragm	phrenic <i>FREN-ik</i>	pertaining to the diaphragm
phrenic/o	phrenic nerve	phrenicectomy <i>fren-ih-SEK-to-me</i>	partial excision of the phrenic nerve
pleur/o	pleura	pleurodesis <i>plu-ROD-eh-sis</i>	fusion of the pleura
pulm/o, pulmon/o	lung	extrapulmonary <i>EKS-trah-pul-mo-nar-e</i>	outside the lungs
pneumon/o	lung	pneumonitis <i>nu-mo-NI-tis</i>	inflammation of the lung; pneumonia
pneum/o, pneumat/o	air, gas; also respiration, lung	pneumothorax <i>nu-mo-THO-raks</i>	presence of air in the thorax (pleural space)
spir/o	breathing	spirometer <i>spi-ROM-eh-ter</i>	instrument for measuring breathing volumes

## Exercise 12-3

Complete the exercise. To check your answers go to Appendix 11.

Define the following words.

1. pleuralgia (*plu-RAL-je-ab*) \_\_\_\_\_
2. intrapulmonary (*in-trah-PUL-mo-ner-e*) \_\_\_\_\_
3. pneumonectomy (*nu-mo-NEK-to-me*) \_\_\_\_\_
4. pneumoplasty (*NU-mo-plas-te*) \_\_\_\_\_
5. pulmonology (*pul-mo-NOL-o-je*) \_\_\_\_\_
6. apneumia (*ap-NU-me-ab*) \_\_\_\_\_
7. phrenicotomy (*fren-ih-KOT-o-me*) \_\_\_\_\_

## Exercise 12-3 (Continued)

Write words for the following definitions.

8. within the pleura
9. above the diaphragm
10. surgical puncture of the pleural space
11. any disease of the lungs (pneumon/o)
12. crushing of the phrenic nerve
13. record of breathing volumes

---



---



---



---



---



---

## Clinical Aspects of the Respiratory System

Any disorder that causes resistance to airflow through the respiratory tract or that limits chest expansion will affect pulmonary function. These disorders may involve the respiratory system directly, such as infection, injury, allergy, **aspiration** (inhalation) of foreign bodies, or cancer; they may also originate in other systems, such as in the skeletal, muscular, cardiovascular, or nervous systems.

As noted above, changes in ventilation can affect the blood's pH (acidity or alkalinity). If too much carbon dioxide

is exhaled by **hyperventilation**, the blood tends to become too alkaline, a condition termed **alkalosis**. If too little carbon dioxide is exhaled as a result of **hypoventilation**, the blood tends to become too acidic, a condition termed **acidosis**.

### INFECTIONS

A variety of organisms infect the respiratory system. For your reference, some of these organisms are listed along with the diseases they cause in **BOX 12-2**. Childhood immunizations have dramatically reduced the incidence of some infectious respiratory diseases, such as **diphtheria** and **pertussis** (the “D”



### FOR YOUR REFERENCE

BOX 12-2

#### Organisms That Infect the Respiratory System

Organism	Disease
<b>BACTERIA</b>	
<b>Streptococcus pneumoniae</b> <i>strep-to-KOK-us nu-MO-ne-e</i>	Most common cause of pneumonia; streptococcal pneumonia
<b>Haemophilus influenzae</b> <i>he-MOF-ih-lus in-flu-EN-ze</i>	Pneumonia, especially in debilitated patients
<b>Klebsiella pneumoniae</b> <i>kleb-se-EL-ah nu-MO-ne-e</i>	Pneumonia in elderly and debilitated patients
<b>Mycoplasma pneumoniae</b> <i>mi-ko-PLAZ-mah nu-MO-ne-e</i>	Mild pneumonia, usually in young adults and children; “walking pneumonia”
<b>Legionella pneumophila</b> <i>le-juh-NEL-lah nu-MOH-fih-lah</i>	Legionellosis (Legionnaire disease); respiratory disease spread through water sources, such as air conditioners, pools, humidifiers
<b>Chlamydia psittaci</b> <i>klah-MID-e-ah SIH-tah-se</i>	Psittacosis (ornithosis); carried by birds
<b>Streptococcus pyogenes</b> <i>strep-to-KOK-us pi-OJ-eh-neze</i>	“Strep throat,” scarlet fever
<b>Mycobacterium tuberculosis</b> <i>mi-ko-bak-TE-re-e-um tu-ber-ku-LO-sis</i>	Tuberculosis
<b>Bordetella pertussis</b> <i>bor-deh-TEL-ah per-TUS-sis</i>	Pertussis (whooping cough)

(continued)



## FOR YOUR REFERENCE (Continued)

### Organisms That Infect the Respiratory System

BOX 12-2

Organism	Disease
<b>Corynebacterium diphtheriae</b> <i>ko-RI-ne-bak-te-re-e-um dif-THE-re-e</i>	Diphtheria
<b>VIRUSES</b>	
<b>Rhinoviruses</b> <i>RI-no-vi-rus-es</i>	Major cause of common cold; also caused by coronaviruses, adenoviruses, and others
<b>Influenzavirus</b> <i>in-flu-EN-zah-vi-rus</i>	Influenza
<b>Respiratory syncytial virus (RSV)</b> <i>sin-SISH-al</i>	Common cause of respiratory disease in infants
<b>SARS coronavirus</b> <i>ko-RO-nah-vi-rus</i>	Severe acute respiratory syndrome; highly infectious disease that appeared in 2003 and spreads from small mammals to humans
<b>Hantavirus</b> <i>HAN-tah-vi-rus</i>	Hantavirus pulmonary syndrome (HPS); spread by inhalation of virus released from dried rodent droppings
<b>FUNGI</b>	
<b>Histoplasma capsulatum</b> <i>his-to-PLAS-mahkap-su-LATE-um</i>	Histoplasmosis; spread by airborne spores
<b>Coccidioides immitis</b> <i>kok-sid-e-OY-deze IM-ih-tis</i>	Coccidioidomycosis (valley fever, San Joaquin fever); found in dry, alkaline soils
<b>Blastomyces dermatitidis</b> <i>blas-to-MI-seze der-mah-TIT-ih-dis</i>	Blastomycosis; rare but often fatal fungal disease
<b>Pneumocystis jirovecii (formerly carinii)</b> <i>nu-mo-SIS-tis jir-o-VEH-se</i>	<i>Pneumocystis</i> pneumonia (PCP); seen in immunocompromised hosts

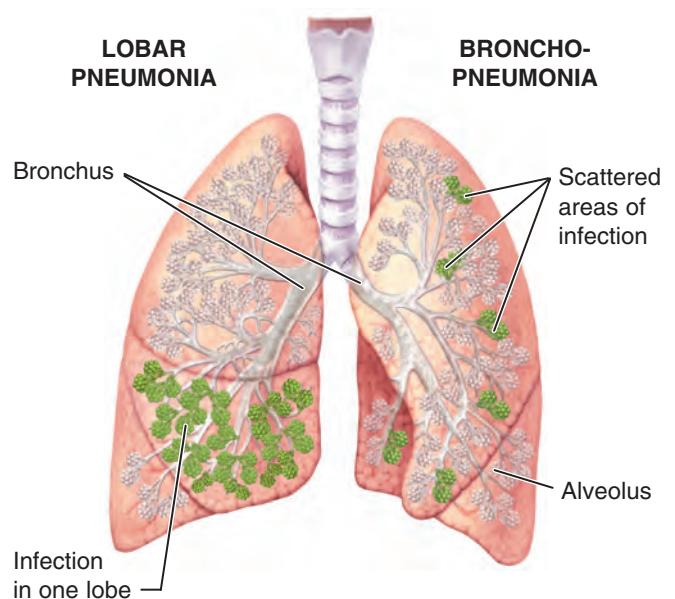
and “P” in the DTaP vaccine; the “T” is for tetanus). Selected infectious diseases are described in greater detail below.

### Pneumonia

**Pneumonia** is caused by many different microorganisms, usually bacteria or viruses. Bacterial agents are most commonly *Streptococcus pneumoniae* and *Klebsiella pneumoniae*. Viral pneumonia is more diffuse and is commonly caused by influenza virus and adenovirus. There are two forms of pneumonia (FIG. 12-8):

- Lobar pneumonia, an acute disease, involves one or more lobes of the lung.
- Bronchopneumonia (bronchial pneumonia) occurs throughout the lung. It begins in terminal bronchioles that become clogged with exudate and form consolidated (solidified) patches.

Pneumonia can usually be treated successfully in otherwise healthy people, but in debilitated patients, it is a



**FIGURE 12-8 Pneumonia.** In lobar pneumonia (right lung), an entire lobe is consolidated. In bronchopneumonia (left lung), patchy areas of consolidation occur throughout the lung.

leading cause of death. Immunocompromised patients, such as those with AIDS, are often subject to a form of fungal pneumonia called *Pneumocystis pneumonia* (PCP).

The term *pneumonia* is also applied to noninfectious lung inflammation, such as that caused by asthma, allergy, or inhalation of irritants. In these cases, however, the more general term **pneumonitis** is often used.

### Respiratory Syncytial Virus

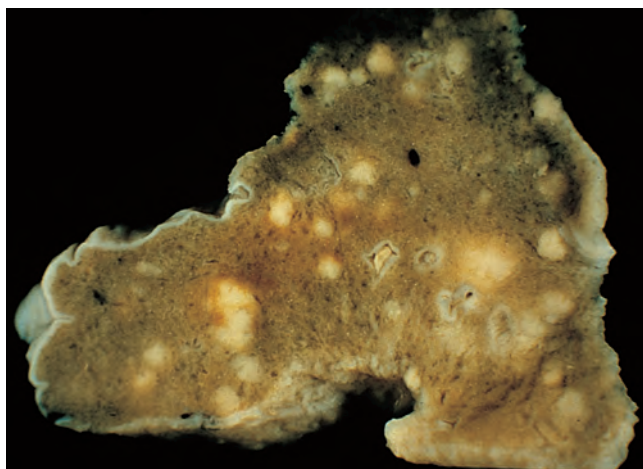
Respiratory syncytial virus (RSV) is the most common cause of lower respiratory tract infections in infants and young children worldwide. The name comes from the fact that the virus induces fusion of cultured cells (formation of a syncytium) when grown in the laboratory. Infection may result in bronchiolitis or pneumonia, but the virus may affect the upper respiratory tract as well. Most susceptible are premature infants, those with congenital heart disease, and those who are immunodeficient. Exposure to cigarette smoke is a definite risk factor.

The virus usually enters through the eyes and nose following contact with contaminated air, nasal secretions, or objects. The incubation period is 3 to 5 days, and an infected person sheds virus particles during the incubation period and up to 2 weeks thereafter. Infection usually resolves in 5 to 7 days, although some cases require hospitalization and antiviral drug treatments.

### Tuberculosis

The incidence of **tuberculosis** (TB) has increased in recent years, along with the increase of AIDS and the appearance of antibiotic resistance in the causative organism, *Mycobacterium tuberculosis* (MTB). (This organism, because of its staining properties, is also referred to as AFB, meaning *acid-fast bacillus*.) The name *tuberculosis* comes from the small lesions, or tubercles, that characterize the infection. The tubercles can liquefy in the center and then rupture to release bacteria into the bloodstream. Generalized TB is known as *miliary tuberculosis* because of the many tubercles that are the size of millet seeds in infected tissue (FIG. 12-9).

TB symptoms include fever, weight loss, weakness, cough, and **hemoptysis**, the coughing up of blood-containing



**FIGURE 12-9 Tuberculosis.** The cut surface of the lung reveals numerous white nodules in miliary (generalized) tuberculosis.

sputum. Accumulation of exudate in the alveoli may result in consolidation of lung tissue. Active TB is diagnosed by chest x-ray and laboratory culture of sputum samples to isolate, stain, and identify any causative organisms. If found, the organisms can be tested for drug susceptibility. These laboratory studies can take up to 8 weeks, as the TB organism is very slow growing, so clinicians also use several quick tests to identify tuberculosis infections. These include:

- The **tuberculin test**, a skin test, also known as a Mantoux (*man-TOO*) test. The test material, tuberculin, is made from byproducts of the tuberculosis organism. PPD (purified protein derivative) is the form of tuberculin commonly used. In 48 to 72 hours after tuberculin is injected below the skin, a hard, raised lump appears if a person has been infected with the TB organism. This test does not distinguish active from inactive cases.
- IGRA, a rapid blood test to diagnose TB. This is an immunologic test with the full name interferon-gamma release assay. It is used to confirm results of a negative skin test in people at high risk of having TB.
- NAA, a sputum test that can confirm a positive TB diagnosis within 24 hours. The full name is nucleic acid amplification test.

BCG vaccine is used worldwide to help to prevent TB; it is not used routinely in the United States because the incidence of TB in this country is relatively low and also because it invalidates the tuberculin test. The bacillus (B) used for the vaccine is named for Calmette (C) and Guérin (G), discoverers of this avirulent mycobacterium strain.

### Influenza

**Influenza** (“flu”) is a viral respiratory disease associated with chills, fever, headaches, muscular aches, and cold-like symptoms. It usually resolves in several days, but severe forms of influenza have caused fatal pandemics, most recently in 1918, 1957, and 1968. The virus can mutate readily and spread among animals, such as birds or pigs, and humans.

Because influenza viruses change so rapidly, scientists must prepare vaccines against the strains most likely to cause an epidemic in any given year. The virus strains are grouped into categories A to C, with A the most severe and C the least. They are further designated H and N with numbers, such as H3N2 and H5N1. The “H” and “N” represent surface proteins that the virus uses to infect a host.

Medical personnel combat influenza with vaccines, isolation of infected populations, destruction of infected animals, and antiviral medications.

### Croup

Croup usually affects children under 3 years of age and is associated with a number of different infections that result in upper respiratory inflammation. Airway constriction produces a loud, barking cough, wheezing, difficulty in breathing, and hoarseness. If croup is severe, the child may produce a harsh, squeaking noise (stridor) when breathing in through a narrowed trachea. Viral infections, such as those involving parainfluenza, adenovirus, RSV, influenza, or measles, are



## FOCUS ON WORDS

### Don't Breathe a Word

BOX 12-3

Some lay terms for respiratory symptoms and conditions are so old fashioned and quaint that you might see them today only in Victorian novels. Catarrh (*kah-TAR*) is an old word for an upper respiratory infection with much mucus production. Quinsy (*KWIN-ze*) referred to a sore throat or tonsillar abscess. Consumption was tuberculosis, and dropsy referred to generalized edema. The grippe (*grip*) meant influenza, which we more often abbreviate as “flu.”

Some unscientific words are still in use. These include whooping cough for pertussis, croup for laryngeal spasm, cold sore or fever blister for a herpes lesion, and phlegm for sputum.

Many people use informal terms instead of scientific words to describe their symptoms. Health professionals should be familiar with the slang or colloquialisms that patients might use so that they can better communicate with them.

usually the cause. Although croup may be frightening to parents and children, recovery is complete in most cases within a week. However, medical treatment is warranted if the child's respiratory rate is very high and if the ribs become visible with each inhalation. Home treatments include humidifying room air or having the child breathe in steam. Also, cool air may shrink the respiratory tissues enough to bring relief. Medical interventions usually involve the administration of corticosteroids and bronchodilators.

### Common Cold

More than 200 viruses are known to cause the common cold. About one half of these are rhinoviruses, and the others include adenoviruses and coronaviruses. The symptoms, known to all, are sneezing; **acute rhinitis**, which is inflammation of the nasal passageways with copious secretion of watery mucus; tearing of the eyes; and congestion. The infection may spread from the nose and throat to the sinuses, middle ear, and lower respiratory tract.

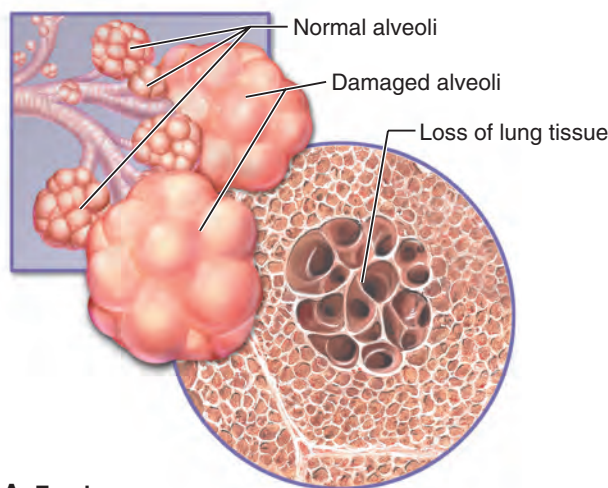
Cold viruses are mostly spread by airborne virus-filled droplets released by an infected person's coughs and sneezes. Frequent hand washing and not touching one's hands to any part of the face are good preventive measures.

The disorder usually resolves in about a week. Because colds are caused by viruses, antibiotics do not cure them. Rest, fluid intake, symptomatic treatment, and time work best. The large variety of cold viruses and their frequent mutation have prevented the development of an effective vaccine.

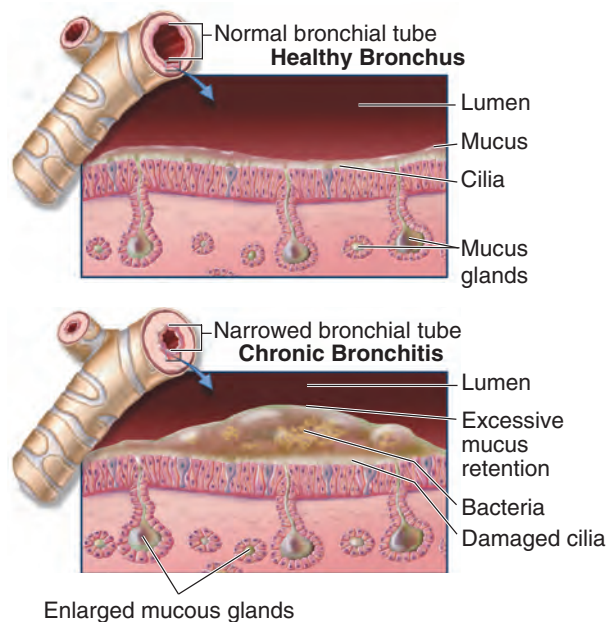
**BOX 12-3** has some history on terminology related to respiratory infections and other disorders.

### EMPHYSEMA

**Emphysema** is a chronic disease associated with overexpansion and destruction of the alveoli (**FIG. 12-10A**). Common causes are exposure to cigarette smoke and other forms of pollution as well as chronic infection. Emphysema is the main disorder included under the heading of **chronic**



**A. Emphysema**



**B. Chronic Bronchitis**

**FIGURE 12-10** Types of chronic obstructive pulmonary disease (COPD). **A.** Emphysema results in dilation and destruction of alveoli. **B.** Chronic bronchitis involves airway inflammation, damage to cilia, and excess mucus secretion.

**obstructive pulmonary disease (COPD).** Other conditions included in this category are **asthma**, **bronchiectasis**, and **chronic bronchitis** (FIG. 12-10B).

## ASTHMA

Asthma attacks result from narrowing of the bronchial tubes. This constriction, along with edema (swelling) of the bronchial linings, inflammation, and mucus accumulation, results in wheezing, extreme **dyspnea** (difficulty in breathing), and **cyanosis**.

Asthma is most common in children. Although its causes are uncertain, a main factor is irritation caused by allergy. Heredity may also play a role. Treatment of asthma includes:

- removal of allergens
- administration of bronchodilators to widen the airways
- administration of corticosteroids to reduce inflammation

## PNEUMOCONIOSIS

Chronic irritation and inflammation caused by dust inhalation is termed **pneumoconiosis**. This is an occupational hazard seen mainly in people working in mining and stone-working industries. Different forms of pneumoconiosis are named for the specific type of dust inhaled: **silicosis** (silica or quartz), **anthracosis** (coal dust), **asbestosis** (asbestos fibers).

Although the term *pneumoconiosis* is limited to conditions caused by inhalation of inorganic dust, lung irritation may also result from inhalation of organic dusts, such as textile or grain dusts.

## LUNG CANCER

Lung cancer is the leading cause of cancer-related deaths in both men and women. The incidence of lung cancer has increased steadily over the past 50 years, especially in women. Cigarette smoking is a major risk factor in this as well as other types of cancer. The most common form of lung cancer is **squamous carcinoma**, originating in the lining of the bronchi (bronchogenic). Lung cancer usually cannot be detected early, and it metastasizes rapidly. The overall long-term survival rate is low.

Methods used to diagnose lung cancer include radiographic studies, computed tomography (CT) scans, and sputum examination for cancer cells. Physicians can use a **bronchoscope** to examine the airways and to collect tissue samples for study. They may also take samples by surgical or needle biopsies.

## RESPIRATORY DISTRESS SYNDROME

**Respiratory distress syndrome (RDS)** of the newborn occurs in premature infants and is the most common cause of death in this group. It results from a lack of lung surfactant, which reduces compliance. **Acute respiratory distress**

**syndrome (ARDS)**, also known as *shock lung*, may result from trauma, allergic reactions, infection, and other causes. It involves edema that can lead to respiratory failure and death if untreated.

## CYSTIC FIBROSIS

**Cystic fibrosis (CF)** is the most common fatal hereditary disease among white children. The flawed gene that causes CF affects glandular secretions by altering chloride transport across cell membranes. Thickening of bronchial secretions leads to infection and other respiratory disorders. Other mucus-secreting glands, sweat glands, and the pancreas are also involved, causing electrolyte imbalance and digestive disturbances.

CF is diagnosed by the increased amounts of sodium and chloride in the sweat. Geneticists also can identify the gene that causes CF by DNA analysis. There is no cure at present for CF. Patients are treated to relieve their symptoms, by postural drainage, aerosol mists, bronchodilators, antibiotics, and mucolytic (mucus-dissolving) agents.

## SUDDEN INFANT DEATH SYNDROME

**Sudden infant death syndrome (SIDS)**, also called “crib death,” is the unexplained death of a seemingly healthy infant under 1 year of age. Death usually occurs during sleep, leaving no signs of its cause. Neither autopsy nor careful investigation of family history and circumstances of death provides any clues.

Certain maternal conditions during pregnancy are associated with an increased risk of SIDS, although none is a sure predictor. These include cigarette smoking, age under 20, low weight gain, anemia, illegal drug use, and reproductive or urinary tract infections.

Some practices that have reduced the incidence of SIDS are:

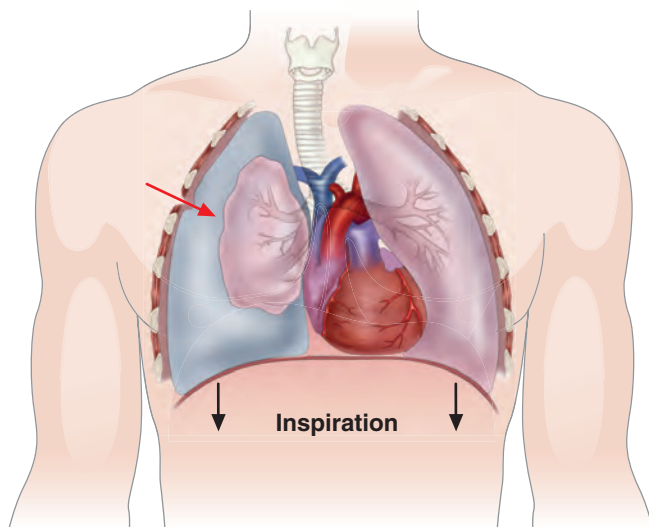
- Place the baby on his or her back (supine) for sleep (“back to sleep”).
- Keep the baby in a smoke-free environment.
- Use a firm, flat baby mattress.
- Don’t overheat the baby.

## PLEURAL DISORDERS

**Pleurisy**, also called **pleuritis**, is an inflammation of the pleura, usually associated with infection. Pain is the common symptom of pleurisy. Because this pain is intensified by breathing or coughing as the inflamed membranes move, breathing becomes rapid and shallow. Analgesics and anti-inflammatory drugs are used to treat the symptoms of pleurisy.

As a result of injury, infection, or weakness in the pleural membrane, substances may accumulate between the layers of the pleura. When air or gas collects in this space, the condition is termed **pneumothorax** (FIG. 12-11). Compression may cause collapse of the lung, termed **atelectasis**.



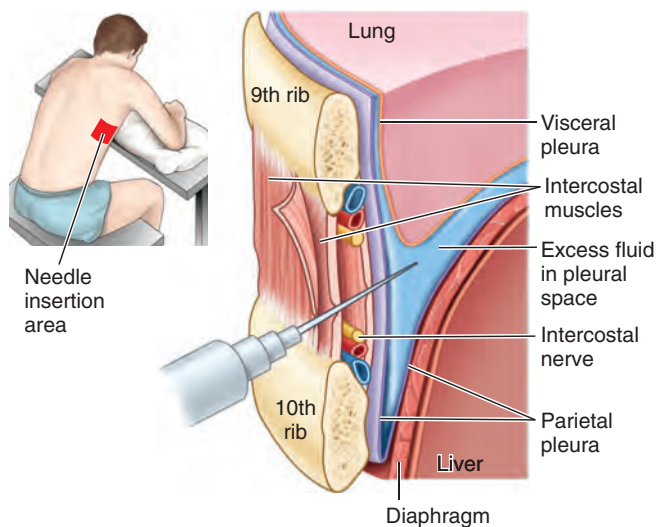


**FIGURE 12-11 Pneumothorax.** Injury to the chest wall or lung tissue allows air to leak into the pleural space (red arrow) and put pressure on the lung. This may result in partial or complete collapse of the lung.

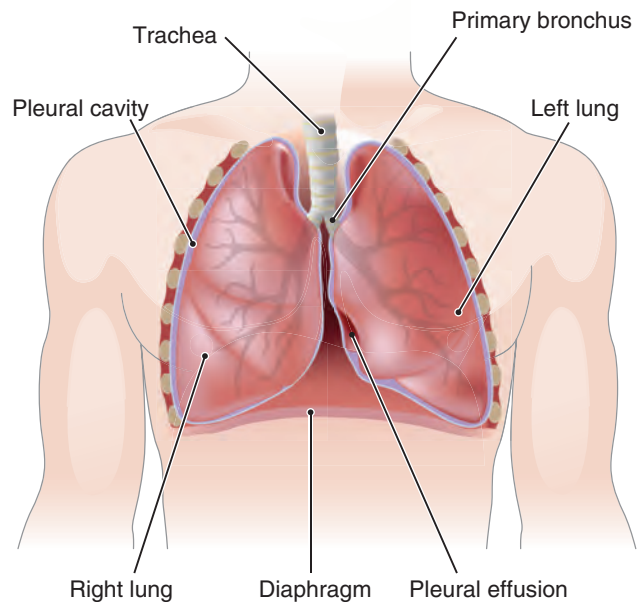
In **pleural effusion**, other materials accumulate in the pleural space (FIG. 12-12). Depending on the substance involved, these are described as **empyema** (pus), also termed **pyothorax**; **hemothorax** (blood); or **hydrothorax** (fluid). Causes of these conditions include injury, infection, heart failure, and pulmonary embolism. **Thoracentesis**, needle puncture of the chest to remove fluids (FIG. 12-13), or fusion of the pleural membranes (pleurodesis) may be required. A chest tube may be inserted to remove air and fluid from the pleural space.

## DIAGNOSIS OF RESPIRATORY DISORDERS

In addition to chest radiographs, CT scans, and magnetic resonance imaging (MRI) scans, methods for diagnosing respiratory disorders include **lung scans**, bronchoscopy,



**FIGURE 12-13 Thoracentesis.** A needle is inserted into the pleural space to withdraw fluid.

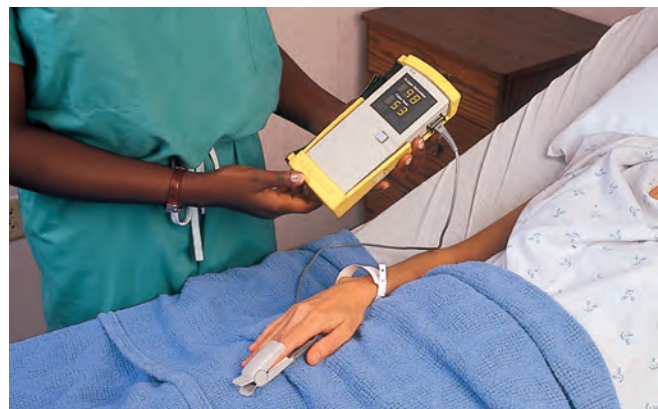

**FIGURE 12-12 Pleural effusion.** An abnormal volume of fluid collects in the pleural space.

and tests of pleural fluid removed by thoracentesis. **Arterial blood gases (ABGs)** are used to evaluate gas exchange in the lungs by measuring carbon dioxide, oxygen, bicarbonate, and pH in an arterial blood sample. **Pulse oximetry** is routinely used to measure the oxygen saturation of arterial blood by means of an oximeter, a simple device placed on a thin part of the body, usually the finger or the ear (FIG. 12-14).

**Pulmonary function tests** are used to assess breathing, usually by means of a **spirometer**. They measure the volumes of air that can be moved into or out of the lungs with different degrees of effort. Often used to monitor treatment in cases of allergy, asthma, emphysema, and other respiratory conditions, they are also used to measure progress in smoking cessation. The main volumes and capacities measured in these tests are summarized in **BOX 12-4** and illustrated in **FIGURE 12-15**. A capacity is the sum of two or more volumes.

See **BOX 12-5** for information on respiratory therapists, who perform many of these tests.



**FIGURE 12-14 Pulse oximetry.** The oximeter measures the oxygen saturation of arterial blood.



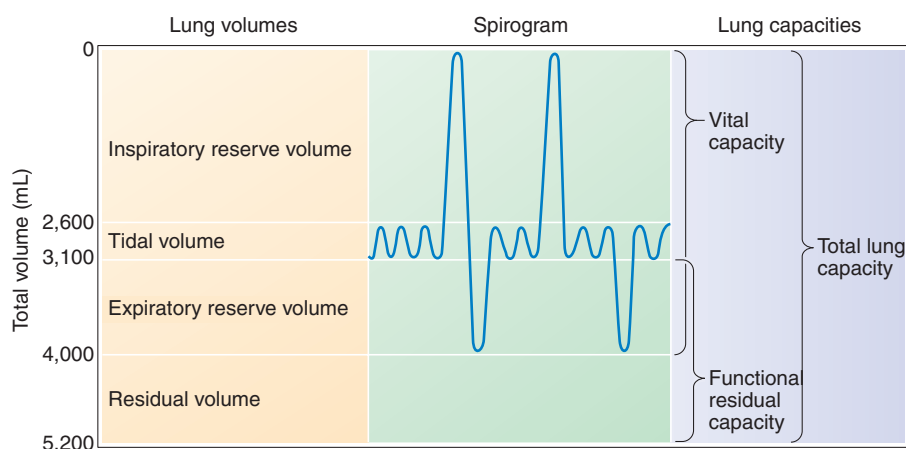
## FOR YOUR REFERENCE

BOX 12-4

### Volumes and Capacities (Sums of Volumes) Used in Pulmonary Function Tests

Volume or Capacity	Definition
<b>tidal volume (TV)</b>	amount of air breathed into or out of the lungs in quiet, relaxed breathing
<b>residual volume (RV)</b>	amount of air that remains in the lungs after maximum exhalation
<b>expiratory reserve volume (ERV)</b>	amount of air that can be exhaled after a normal exhalation
<b>inspiratory reserve volume (IRV)</b>	amount of air that can be inhaled above a normal inspiration
<b>total lung capacity (TLC)</b>	total amount of air that can be contained in the lungs after maximum inhalation
<b>inspiratory capacity (IC)</b>	amount of air that can be inhaled after normal exhalation
<b>vital capacity (VC)</b>	amount of air that can be expelled from the lungs by maximum exhalation after maximum inhalation
<b>functional residual capacity (FRC)</b>	amount of air remaining in the lungs after normal exhalation
<b>forced expiratory volume (FEV)</b>	volume of gas exhaled with maximum force within a given interval of time; the time interval is shown as a subscript, such as FEV <sub>1</sub> (1 second) and FEV <sub>3</sub> (3 seconds)
<b>forced vital capacity (FVC)</b>	the volume of gas exhaled as rapidly and completely as possible after a complete inhalation

12



**FIGURE 12-15 A spirogram.** A spirometer produces a tracing of lung volumes and capacities (sums of volumes).



## HEALTH PROFESSIONS

BOX 12-5

### Careers in Respiratory Therapy

Respiratory therapists and respiratory therapy technicians specialize in evaluating and treating breathing disorders. Respiratory therapists evaluate the severity of their patients' conditions by taking complete histories and testing respiratory function with specialized equipment. Based on their findings, and in consultation with a physician, therapists design and implement individualized treatment plans, which may include oxygen therapy and chest physiotherapy. They also educate patients on the use of ventilators and other medical devices. Respiratory therapy technicians assist in carrying out evaluations and treatments.

To perform their duties, both types of practitioners need a thorough scientific background. Most respiratory therapists in the United States receive their training from an accredited college or university and take a national licensing exam. Respiratory therapists and technicians work in a variety of settings, such as hospitals, nursing-care facilities, and private clinics. For additional information about careers in respiratory therapy, visit the American Association for Respiratory Care at [aarc.org](http://aarc.org).

## Terminology

## Key Terms

The terms listed below are emphasized in this chapter. Knowing them will help you organize and prioritize your learning. These boldface terms are also found, collectively, with all chapter key terms in the Glossary.

### Disorders

<b>acidosis</b> <i>as-ih-DO-sis</i>	Abnormal acidity of body fluids; respiratory acidosis is caused by abnormally high carbon dioxide levels
<b>acute respiratory distress syndrome (ARDS)</b>	Pulmonary edema that can lead rapidly to fatal respiratory failure; causes include trauma, aspiration into the lungs, viral pneumonia, and drug reactions; shock lung
<b>acute rhinitis</b> <i>ri-NI-tis</i>	Inflammation of the nasal mucosa with sneezing, tearing, and profuse secretion of watery mucus, as seen in the common cold
<b>alkalosis</b> <i>al-kah-LO-sis</i>	Abnormal alkalinity of body fluids; respiratory alkalosis is caused by abnormally low carbon dioxide levels
<b>aspiration</b> <i>as-pih-RA-shun</i>	The accidental inhalation of food or other foreign material into the lungs; also means the withdrawal of fluid from a cavity by suction
<b>asthma</b> <i>AZ-mah</i>	A disease characterized by dyspnea and wheezing caused by spasm of the bronchial tubes or swelling of their mucous membranes
<b>atelectasis</b> <i>at-eh-LEK-tab-sis</i>	Incomplete expansion of a lung or part of a lung; lung collapse; may be present at birth (as in respiratory distress syndrome) or may be caused by bronchial obstruction or compression of lung tissue (prefix atel/o means “imperfect”)
<b>bronchiectasis</b> <i>brong-ke-EK-tah-sis</i>	Chronic dilatation of a bronchus or bronchi
<b>bronchitis</b> <i>brong-KI-tis</i>	Inflammation of a bronchus
<b>chronic obstructive pulmonary disease (COPD)</b>	Any of a group of chronic, progressive, and debilitating respiratory diseases, which includes emphysema, asthma, bronchitis, and bronchiectasis (see <b>FIG. 12-10</b> )
<b>croup</b> <i>krupe</i>	A childhood disease usually caused by a viral infection that involves upper airway inflammation and obstruction; croup is characterized by a barking cough, difficulty breathing, and laryngeal spasm
<b>cyanosis</b> <i>si-ab-NO-sis</i>	Bluish discoloration of the skin caused by lack of oxygen in the blood (adjective: cyanotic) (see <b>FIG. 1-17</b> )
<b>cystic fibrosis (CF)</b> <i>SIS-tik fi-BRO-sis</i>	An inherited disease that affects the pancreas, respiratory system, and sweat glands; characterized by mucus accumulation in the bronchi causing obstruction and leading to infection
<b>diphtheria</b> <i>dif-THERE-e-ab</i>	Acute infectious disease, usually limited to the upper respiratory tract, characterized by the formation of a surface pseudomembrane composed of cells and coagulated material
<b>dyspnea</b> <i>disp-NE-ab</i>	Difficult or labored breathing (-pnea), sometimes with pain; “air hunger”
<b>emphysema</b> <i>em-fib-SE-mah</i>	A chronic pulmonary disease characterized by enlargement and destruction of the alveoli
<b>empyema</b> <i>em-pi-E-mah</i>	Accumulation of pus in a body cavity, especially the pleural space; pyothorax
<b>hemoptysis</b> <i>he-MOP-tih-sis</i>	The spitting of blood from the mouth or respiratory tract (ptysis means “spitting”)
<b>hemothorax</b> <i>he-mo-THOR-aks</i>	Presence of blood in the pleural space
<b>hydrothorax</b> <i>hi-dro-THOR-aks</i>	Presence of fluid in the pleural space

## Terminology

## Key Terms (Continued)

<b>hyperventilation</b> <i>hi-per-ven-tib-LA-shun</i>	Increase in the rate and depth of breathing to above optimal levels, with blood carbon dioxide decreasing to levels below normal
<b>hypoventilation</b> <i>hi-po-ven-tib-LA-shun</i>	Condition in which the amount of air entering the alveoli is insufficient to meet metabolic needs and blood carbon dioxide increases to levels above normal
<b>influenza</b> <i>in-flu-EN-zah</i>	An acute, contagious respiratory infection causing fever, chills, headache, and muscle pain; “flu”
<b>pertussis</b> <i>per-TUS-is</i>	An acute, infectious disease characterized by a cough ending in a whooping inspiration; whooping cough
<b>pleural effusion</b> <i>PLURE-al eh-FU-zhun</i>	Accumulation of fluid in the pleural space; the fluid may contain blood (hemothorax) or pus (pyothorax or empyema) (see <b>FIG. 12-12</b> )
<b>pleurisy</b> <i>PLURE-ih-se</i>	Inflammation of the pleura; pleuritis; a symptom of pleurisy is sharp pain on breathing
<b>pneumoconiosis</b> <i>nu-mo-ko-ne-O-sis</i>	Disease of the respiratory tract caused by inhalation of dust particles; named more specifically by the type of dust inhaled, such as silicosis, anthracosis, asbestosis
<b>pneumonia</b> <i>nu-MO-ne-ab</i>	Inflammation of the lungs generally caused by infection; may involve the bronchioles and alveoli (bronchopneumonia) or one or more lobes of the lung (lobar pneumonia) (see <b>FIG. 12-8</b> )
<b>pneumonitis</b> <i>nu-mo-NI-tis</i>	Inflammation of the lungs; may be caused by infection, asthma, allergy, or inhalation of irritants
<b>pneumothorax</b> <i>nu-mo-THOR-aks</i>	Accumulation of air or gas in the pleural space; may result from injury or disease or may be produced artificially to collapse a lung (see <b>FIG. 12-11</b> )
<b>pyothorax</b> <i>pi-o-THOR-aks</i>	Accumulation of pus in the pleural space; empyema
<b>respiratory distress syndrome (RDS)</b>	A respiratory disorder that affects premature infants born without enough surfactant in the lungs; it is treated with respiratory support and surfactant administration
<b>sudden infant death syndrome (SIDS)</b>	The sudden and unexplained death of an apparently healthy infant; crib death
<b>tuberculosis</b> <i>tu-ber-ku-LO-sis</i>	An infectious disease caused by the tubercle bacillus, <i>Mycobacterium tuberculosis</i> ; often involves the lungs but may involve other parts of the body as well; miliary ( <i>MIL-e-ar-e</i> ) tuberculosis is an acute generalized form of the disease with formation of minute tubercles that resemble millet seeds (see <b>FIG. 12-9</b> )
<b>Diagnosis</b>	
<b>arterial blood gases (ABGs)</b>	The concentrations of gases, specifically oxygen and carbon dioxide, in arterial blood; reported as the partial pressure (P) of the gas in arterial (a) blood, such as PaO <sub>2</sub> or PaCO <sub>2</sub> ; these measurements are important in measuring acid–base balance
<b>bronchoscope</b> <i>BRONG-ko-skope</i>	An endoscope used to examine the tracheobronchial passageways. Also allows access for tissue biopsy or removal of a foreign object ( <b>FIG. 12-16</b> )
<b>lung scan</b>	Study based on the accumulation of radioactive isotopes in lung tissue; a ventilation scan measures ventilation after inhalation of radioactive material; a perfusion scan measures blood supply to the lungs after injection of radioactive material; also called a pulmonary scintiscan
<b>pulse oximetry</b> <i>ok-SIM-eh-tre</i>	Determination of the oxygen saturation of arterial blood by means of a photoelectric apparatus (oximeter), usually placed on the finger or the ear; reported as SpO <sub>2</sub> in percent (see <b>FIG. 12-14</b> )
<b>pulmonary function tests</b>	Tests done to assess breathing, usually by spirometry

(continued)

## Terminology

## Key Terms (Continued)

**spirometer***spi-ROM-eh-ter*

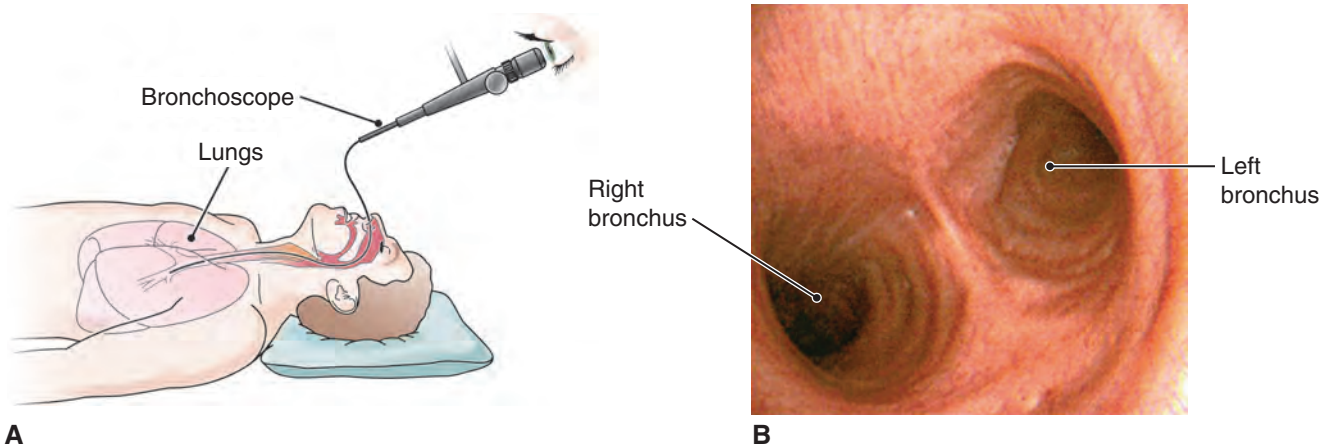
An apparatus used to measure breathing volumes and capacities; record of test is a spirogram (see FIG. 12-15)

**thoracentesis***thor-ab-sen-TE-sis*

Surgical puncture of the chest for removal of air or fluids, such as may accumulate after surgery or as a result of injury, infection, or cardiovascular problems; also called thoracocentesis (see FIG. 12-13)

**tuberculin test***tu-BER-ku-lin*

A skin test for tuberculosis; tuberculin (PPD), the test material made from products of the tuberculosis organism, is injected below the skin; a hard, raised lump appearing within 48 to 72 hours indicates an active or inactive TB infection; also called the Mantoux (*man-TOO*) test



**FIGURE 12-16 Use of a bronchoscope.** **A.** A bronchoscope is a lighted tube used to inspect the bronchi, remove specimens, and remove foreign objects. **B.** View of the bronchial openings through a bronchoscope. Note the larger right bronchus.

## Terminology

## Enrichment Terms

The terms listed below expand on the key terms to increase your knowledge of this chapter topic.

**Normal Structure and Function****carina***kah-RI-nah*

A projection of the lowest tracheal cartilage that forms a ridge between the two bronchi; used as a landmark for endoscopy; any ridge or ridge-like structure (from a Latin word that means “keel”)

**hilum***HI-lum*

An anatomic depression in an organ where vessels and nerves enter

**hyperpnea***hi-PERP-ne-ab*

Increase in the depth and rate of breathing to meet the body’s needs, as in exercise

**hypopnea***hi-POP-ne-ab*

Decrease in the rate and depth of breathing

**nares***NA-reze*

The external openings of the nose; the nostrils (singular: naris)

**nasal septum**

The partition that divides the nasal cavity into two parts (root sept/o means “septum”)

**tachypnea***tak-IP-ne-ab*

Excessive rate of breathing, which may be normal, as in exercise

## Terminology

## Enrichment Terms (Continued)

## Symptoms and Conditions

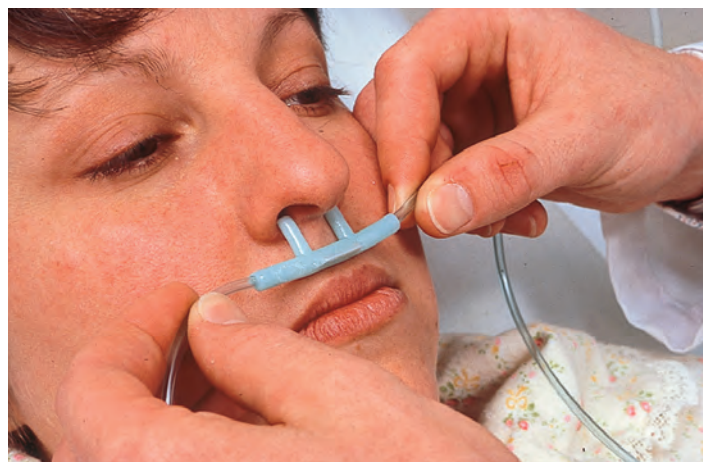<b>anoxia</b> <i>an-OK-se-ah</i>	Lack or absence of oxygen in the tissues; often used incorrectly to mean hypoxia
<b>asphyxia</b> <i>as-FIK-se-ah</i>	Condition caused by inadequate intake of oxygen; suffocation (literally “lack of pulse”)
<b>Biot respirations</b> <i>be-O</i>	Deep, fast breathing interrupted by sudden pauses; seen in spinal meningitis and other central nervous system disorders
<b>bradypnea</b> <i>brad-IP-ne-ah</i>	Abnormally slow rate of breathing
<b>bronchospasm</b> <i>BRONG-ko-spazm</i>	Narrowing of the bronchi caused by smooth muscle spasms; common in cases of asthma and bronchitis
<b>Cheyne–Stokes respiration</b> <i>chane stokes</i>	A repeating cycle of gradually increased and then decreased respiration followed by a period of apnea; caused by depression of the breathing centers in the brainstem; seen in cases of coma and in terminally ill patients
<b>cor pulmonale</b> <i>korpul-mo-NA-le</i>	Enlargement of the heart’s right ventricle caused by disease of the lungs or pulmonary blood vessels
<b>coryza</b> <i>ko-RI-zah</i>	Acute inflammation of the nasal passages with profuse nasal discharge; acute rhinitis
<b>deviated septum</b>	A shifted nasal septum; may require surgical correction
<b>epiglottitis</b> <i>ep-ih-glob-TI-tis</i>	Inflammation of the epiglottis that may lead to upper airway obstruction; commonly seen in croup (also spelled epiglottiditis)
<b>epistaxis</b> <i>ep-ib-STAK-sis</i>	Hemorrhage from the nose; nosebleed (Greek: staxis means “dripping”)
<b>fremitus</b> <i>FREM-ih-tus</i>	A vibration, especially as felt through the chest wall on palpation
<b>Kussmaul respiration</b> <i>KOOS-mawl</i>	Rapid and deep gasping respiration without pause; characteristic of severe acidosis
<b>pleural friction rub</b>	A sound heard on auscultation that is produced by the rubbing together of the two pleural layers; a common sign of pleurisy
<b>rales</b> <i>rahlz</i>	Abnormal chest sounds heard when air enters small airways or alveoli containing fluid; usually heard during inspiration (singular: rale [ <i>rahll</i> ]); also called crackles
<b>rhonchi</b> <i>RONG-ki</i>	Abnormal chest sounds produced in airways with accumulated fluids; more noticeable during expiration (singular: rhonchus)
<b>stridor</b> <i>STRI-dor</i>	A harsh, high-pitched sound caused by obstruction of an upper air passageway
<b>tussis</b> <i>TUS-is</i>	A cough; an antitussive drug is one that relieves or prevents coughing
<b>wheeze</b>	A whistling or sighing sound caused by narrowing of a respiratory passageway
<b>Disorders</b>	
<b>byssinosis</b> <i>bis-ih-NO-sis</i>	Obstructive airway disease caused by reaction to the dust in unprocessed plant fibers

(continued)

## Terminology

## Enrichment Terms (Continued)

<b>sleep apnea</b> <i>AP-ne-ah</i>	Intermittent periods of breathing cessation during sleep; central sleep apnea arises from failure of the brainstem to stimulate breathing; obstructive sleep apnea results from airway obstruction during deep sleep, as from obesity or enlarged tonsils
<b>small cell carcinoma</b>	A highly malignant type of bronchial tumor involving small, undifferentiated cells; “oat cell” carcinoma
<b>Diagnosis</b>	
<b>mediastinoscopy</b> <i>me-de-as-tih-NOS-ko-pe</i>	Examination of the mediastinum by means of an endoscope inserted through an incision above the sternum
<b>plethysmograph</b> <i>pleh-THIZ-mo-graf</i>	An instrument that measures changes in gas volume and pressure during respiration
<b>pneumotachometer</b> <i>nu-mo-tak-OM-eh-ter</i>	A device for measuring air flow
<b>thoracoscopy</b> <i>thor-ab-KOS-ko-pe</i>	Examination of the pleural cavity through an endoscope; pleuroscopy
<b>Treatment</b>	
<b>aerosol therapy</b>	Treatment by inhalation of a drug or water in spray form
<b>continuous positive airway pressure (CPAP)</b>	Use of a mechanical respirator to maintain pressure throughout the respiratory cycle in a patient who is breathing spontaneously
<b>extubation</b>	Removal of a previously inserted tube
<b>intermittent positive pressure breathing (IPPB)</b>	Use of a ventilator to inflate the lungs at intervals under positive pressure during inhalation
<b>intermittent positive pressure ventilation (IPPV)</b>	Use of a mechanical ventilator to force air into the lungs while allowing for passive exhalation
<b>nasal cannula</b> <i>KAN-u-lab</i>	A two-pronged plastic device inserted into the nostrils for delivery of oxygen ( <b>FIG. 12-17</b> )
<b>orthopneic position</b> <i>or-thop-NE-ik</i>	An upright or semi-upright position that aids breathing



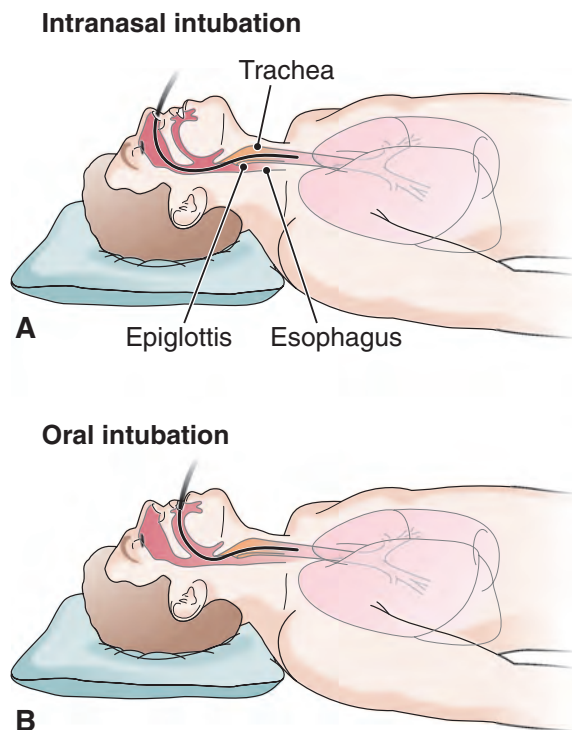
**FIGURE 12-17** A nasal cannula.

## Terminology

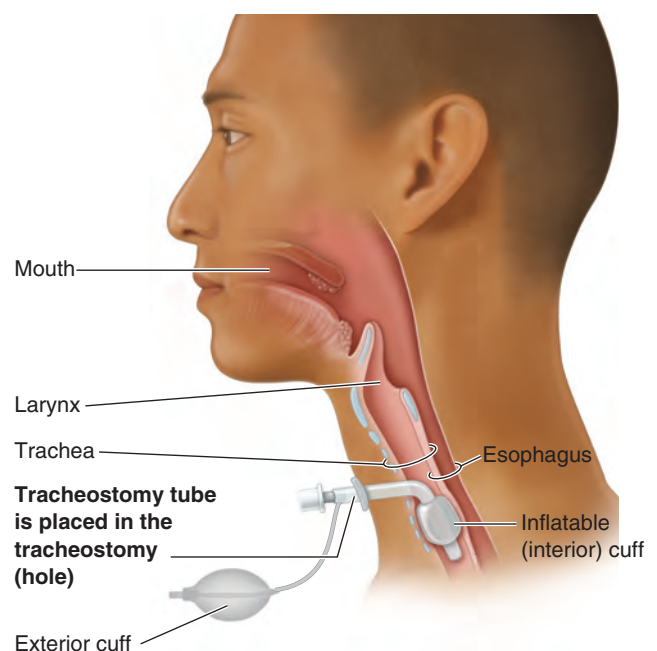
## Enrichment Terms (Continued)

<b>positive end-expiratory pressure (PEEP)</b>	Use of a mechanical ventilator to increase the volume of gas in the lungs at the end of exhalation, thus improving gas exchange
<b>postural drainage</b> <i>POS-tu-ral</i>	Use of body position to drain secretions from the lungs by gravity; the patient is placed so that secretions will move passively into the larger airways for elimination
<b>thoracic gas volume (TGV, <math>V_{TG}</math>)</b>	The volume of gas in the thoracic cavity calculated from measurements made with a body plethysmograph
<b>Surgery</b>	
<b>adenoidectomy</b> <i>ad-eh-noyd-EK-to-me</i>	Surgical removal of the adenoids
<b>intubation</b> <i>in-tu-BA-shun</i>	Insertion of a tube into a hollow organ, such as into the larynx or trachea for entrance of air ( <b>FIG. 12-18</b> ); patients may be intubated during surgery for administration of anesthesia or to maintain an airway; endotracheal intubation may be used as an emergency measure when airways are blocked
<b>lobectomy</b> <i>lo-BEK-to-me</i>	Surgical removal of a lobe of the lung or of another organ
<b>pneumoplasty</b> <i>NU-mo-plas-te</i>	Plastic surgery of the lung; in reduction pneumoplasty, nonfunctional portions of the lung are removed, as in cases of advanced emphysema
<b>tracheotomy</b> <i>tra-ke-OT-o-me</i>	Incision of the trachea through the neck, usually to establish an airway in cases of tracheal obstruction
<b>tracheostomy</b> <i>tra-ke-OS-to-me</i>	Surgical creation of an opening into the trachea to form an airway or to prepare for the insertion of a tube for ventilation ( <b>FIG. 12-19</b> ); also the opening thus created

(continued)



**FIGURE 12-18 Endotracheal intubation.** A. Nasal endotracheal catheter in proper position. B. Oral endotracheal intubation.



**FIGURE 12-19 A tracheostomy tube in place.**



## Terminology

## Enrichment Terms (Continued)

## Drugs

<b>antihistamine</b> <i>an-te-HIS-tab-mene</i>	Agent that prevents responses mediated by histamine, such as allergic and inflammatory reactions
<b>antitussive</b> <i>an-te-TUS-iv</i>	Drug that prevents or relieves coughing
<b>asthma maintenance drug</b>	Agent used to prevent asthma attacks and for chronic treatment of asthma
<b>bronchodilator</b> <i>brong-ko-DI-la-tor</i>	Drug that relieves bronchial spasm and widens the bronchi
<b>corticosteroid</b> <i>kor-tib-ko-STARE-oyd</i>	Hormone from the adrenal cortex; used to reduce inflammation
<b>decongestant</b> <i>de-kon-JES-tant</i>	Agent that reduces congestion or swelling
<b>expectorant</b> <i>ek-SPEK-to-rant</i>	Agent that aids in removal of bronchopulmonary secretions
<b>isoniazid (INH)</b> <i>i-so-NI-ab-zid</i>	Drug used to treat tuberculosis
<b>leukotriene antagonist</b> <i>lu-ko-TRI-ene</i>	Drug that prevents or reduces inflammation by inhibiting leukotrienes, substances made in white blood cells that promote inflammation, constrict the bronchi, and increase mucus production; used in asthma treatment
<b>mucolytic</b> <i>mu-ko-LIT-ik</i>	Agent that loosens mucus to aid in its removal
<b>rifampin (rifampicin)</b> <i>RIF-am-pin</i>	Drug used to treat tuberculosis

## Terminology

## Abbreviations

The abbreviations listed below are emphasized in this chapter. These are also found, collectively, with all chapter abbreviations in Appendix 2.

<b>ABG(s)</b>	Arterial blood gas(es)	<b>CO<sub>2</sub></b>	Carbon dioxide
<b>AFB</b>	Acid-fast bacillus (usually <i>Mycobacterium tuberculosis</i> )	<b>COPD</b>	Chronic obstructive pulmonary disease
<b>ARDS</b>	Acute respiratory distress syndrome; shock lung	<b>CPAP</b>	Continuous positive airway pressure
<b>ARF</b>	Acute respiratory failure	<b>CXR</b>	Chest radiograph, chest x-ray
<b>BCG</b>	Bacillus Calmette–Guérin (tuberculosis vaccine)	<b>DTaP</b>	Diphtheria, tetanus, pertussis (vaccine)
<b>BS</b>	Breath sounds	<b>ERV</b>	Expiratory reserve volume
<b>C</b>	Compliance	<b>FEV</b>	Forced expiratory volume
<b>CF</b>	Cystic fibrosis	<b>FRC</b>	Functional residual capacity

## Terminology

## Abbreviations (Continued)

<b>FVC</b>	Forced vital capacity
<b>HPS</b>	<i>Hantavirus</i> pulmonary syndrome
<b>IC</b>	Inspiratory capacity
<b>IGRA</b>	Interferon-gamma release assay (test for TB)
<b>INH</b>	Isoniazid
<b>IPPB</b>	Intermittent positive pressure breathing
<b>IPPV</b>	Intermittent positive pressure ventilation
<b>IRV</b>	Inspiratory reserve volume
<b>LLL</b>	Left lower lobe (of lung)
<b>LUL</b>	Left upper lobe (of lung)
<b>MEFR</b>	Maximal expiratory flow rate
<b>MMFR</b>	Maximum midexpiratory flow rate
<b>NAA</b>	Nucleic acid amplification (test) (for TB)
<b>O<sub>2</sub></b>	Oxygen
<b>PaCO<sub>2</sub></b>	Arterial partial pressure of carbon dioxide
<b>PaO<sub>2</sub></b>	Arterial partial pressure of oxygen
<b>PCP</b>	<i>Pneumocystis</i> pneumonia
<b>PEEP</b>	Positive end-expiratory pressure
<b>PEFR</b>	Peak expiratory flow rate
<b>PFT</b>	Pulmonary function test(s)
<b>PIP</b>	Peak inspiratory pressure

<b>PND</b>	Paroxysmal nocturnal dyspnea
<b>PPD</b>	Purified protein derivative (tuberculin)
<b>R</b>	Respiration
<b>RDS</b>	Respiratory distress syndrome
<b>RLL</b>	Right lower lobe (of lung)
<b>RML</b>	Right middle lobe (of lung)
<b>RSV</b>	Respiratory syncytial virus
<b>RUL</b>	Right upper lobe (of lung)
<b>RV</b>	Residual volume
<b>SARS</b>	Severe acute respiratory syndrome
<b>SIDS</b>	Sudden infant death syndrome
<b>SpO<sub>2</sub></b>	Oxygen percent saturation
<b>T &amp; A</b>	Tonsils and adenoids; tonsillectomy and adenoidectomy
<b>TB</b>	Tuberculosis
<b>TGV</b>	Thoracic gas volume
<b>TLC</b>	Total lung capacity
<b>TV</b>	Tidal volume
<b>URI</b>	Upper respiratory infection
<b>VC</b>	Vital capacity
<b>V<sub>TG</sub></b>	Thoracic gas volume

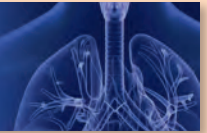## Case Study Revisited

**Allison's Follow-Up to Surgery**

Allison's surgery went well and there were no complications. The anesthesiologist closely monitored her respiratory status to make certain it was not compromised. He administered additional medications to maintain optimal airflow. Postoperatively, Allison's asthma was kept under control. The postoperative spirometry was adequate. Her discharge instructions were to resume preoperative medications and to follow up with her pediatrician if there were any problems.

Allison followed the postoperative instructions. After a month of physical therapy, she was able to

resume normal activities which included walking her dog and playing with friends. She did notice that her asthma attacks were more frequent so her mom made an appointment with Allison's pediatrician. The pediatrician made slight adjustments to Allison's medications and scheduled a follow-up appointment. In between appointments, Allison with the help of her mom, was asked by the pediatrician to put together a daily diary. The diary includes Allison's activities and lists any medication that is used and any triggers that may cause an asthma attack.



This review tests your understanding of the content introduced in this chapter. Follow the instructions for each exercise and check your answers in Appendix 11.

### LABELING EXERCISE

#### THE RESPIRATORY SYSTEM

Write the name of each numbered part on the corresponding line of the answer sheet.

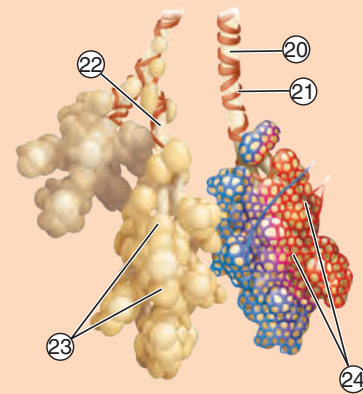
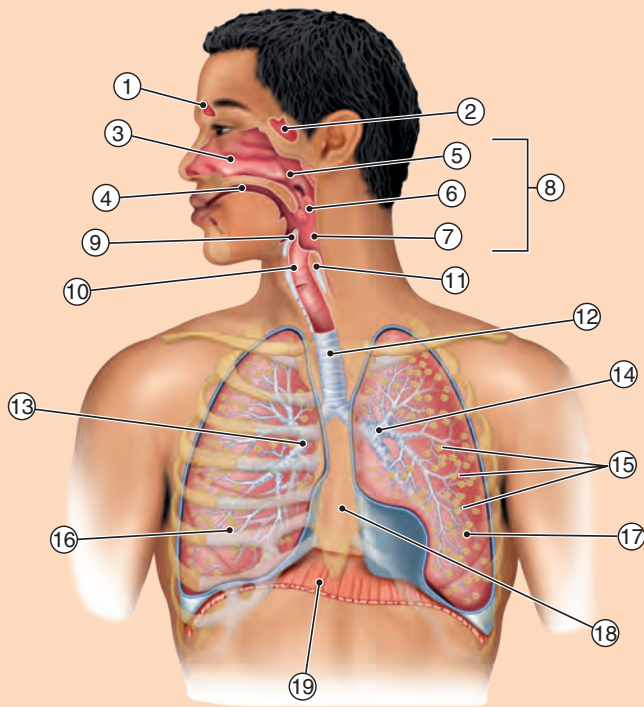
Alveolar duct  
Alveoli  
Bronchioles  
Capillaries  
Diaphragm

Epiglottis  
Esophagus  
Frontal sinus  
Laryngopharynx  
Larynx

Left bronchus  
Left lung  
Mediastinum  
Nasal cavity  
Nasopharynx

Oral cavity  
Oropharynx  
Pharynx  
Right bronchus  
Right lung

Smooth muscle  
Sphenoidal sinus  
Terminal bronchiole  
Trachea



1. \_\_\_\_\_
2. \_\_\_\_\_
3. \_\_\_\_\_
4. \_\_\_\_\_
5. \_\_\_\_\_
6. \_\_\_\_\_
7. \_\_\_\_\_
8. \_\_\_\_\_
9. \_\_\_\_\_
10. \_\_\_\_\_
11. \_\_\_\_\_
12. \_\_\_\_\_

13. \_\_\_\_\_
14. \_\_\_\_\_
15. \_\_\_\_\_
16. \_\_\_\_\_
17. \_\_\_\_\_
18. \_\_\_\_\_
19. \_\_\_\_\_
20. \_\_\_\_\_
21. \_\_\_\_\_
22. \_\_\_\_\_
23. \_\_\_\_\_
24. \_\_\_\_\_

## TERMINOLOGY

### MATCHING

Match the following terms, and write the appropriate letter to the left of each number.

- |                      |   |
|----------------------|---|
| ___ 1. atelectasis   | a. pulmonary disease with destruction of alveoli            |
| ___ 2. emphysema     | b. increased carbon dioxide in the blood                    |
| ___ 3. hypercapnemia | c. decreased rate and depth of breathing                    |
| ___ 4. hypopnea      | d. whooping cough   |
| ___ 5. pertussis     | e. incomplete expansion of lung tissue                      |
| ___ 6. mediastinum   | a. accidental inhalation of foreign material into the lungs |
| ___ 7. aspiration    | b. space between the lungs                                  |
| ___ 8. sputum        | c. substance that reduces surface tension                   |
| ___ 9. surfactant    | d. a measure of how easily the lungs expand                 |
| ___ 10. compliance   | e. expectoration  |
| ___ 11. PCP          | a. childhood vaccine  |
| ___ 12. DTaP         | b. tuberculosis vaccine                                     |
| ___ 13. CF           | c. hereditary disease that affects respiration              |
| ___ 14. IPPB         | d. pneumonia seen in compromised patients                   |
| ___ 15. BCG          | e. a form of respiratory treatment                          |

### Enrichment Terms

- |                       |  |
|-----------------------|--|
| ___ 16. epistaxis     | a. suffocation   |
| ___ 17. intubation    | b. nosebleed   |
| ___ 18. asphyxia      | c. insertion of a tube into a hollow organ               |
| ___ 19. stridor       | d. harsh, high-pitched respiratory sound                 |
| ___ 20. expectorant   | e. agent that helps remove bronchial secretions          |
| ___ 21. mucolytic     | a. irregular respiration seen in terminally ill patients |
| ___ 22. Cheyne–Stokes | b. agent that loosens mucus to aid in its removal        |
| ___ 23. rales         | c. acute rhinitis  |
| ___ 24. orthopneic    | d. pertaining to an upright position                     |
| ___ 25. coryza        | e. abnormal chest sounds                                 |

### FILL IN THE BLANKS

Complete the sentence with the correct term(s).

26. The trachea divides into a right and a left primary \_\_\_\_\_.
27. The phrenic nerve activates the \_\_\_\_\_.
28. The gas produced in the tissues and exhaled in respiration is \_\_\_\_\_.
29. The double membrane that covers the lungs and lines the thoracic cavity is the \_\_\_\_\_.
30. The small air sacs in the lungs through which gases are exchanged between the atmosphere and the blood are the \_\_\_\_\_.
31. The turbinate bones contain receptors for the sense of \_\_\_\_\_.
32. A pneumotropic virus is one that invades the \_\_\_\_\_.
33. The term *acid-fast bacillus* (AFB) is commonly applied to the organism that causes \_\_\_\_\_.

34. The apparatus used to measure Allison's breathing volumes in the opening case study is called a(n) \_\_\_\_\_.

35. The amount of air that Allison could expel from her lungs by maximum exhalation after maximum inhalation is termed the \_\_\_\_\_.

### Enrichment Terms

36. A thoracoscopy is an examination of the \_\_\_\_\_ through an endoscope.

37. An antitussive agent prevents \_\_\_\_\_.

38. A mucolytic agent dissolves \_\_\_\_\_.

39. Intermittent periods of not breathing during sleep are termed sleep \_\_\_\_\_.

40. Allison was given a drug to widen the bronchi. This type of drug is called a(n) \_\_\_\_\_.

### TRUE-FALSE

Examine the following statements. If the statement is true, write T in the first blank. If the statement is false, write F in the first blank, and correct the statement by replacing the underlined word in the second blank.

	True or False	Correct Answer
41. The pharynx is the <u>throat</u> .	_____	_____
42. The diaphragm flattens during <u>exhalation</u> .	_____	_____
43. The vocal folds are located in the <u>pharynx</u> .	_____	_____
44. The right lung has <u>three</u> lobes.	_____	_____
45. The opening between the vocal folds is the <u>glottis</u> .	_____	_____
46. The adenoids are in the <u>nasopharynx</u> .	_____	_____

### DEFINITIONS

Write words for the following definitions.

47. incision of the phrenic nerve \_\_\_\_\_

48. decrease in rate and depth of breathing \_\_\_\_\_

49. inflammation of the throat \_\_\_\_\_

50. inflammation of the bronchioles \_\_\_\_\_

51. creation of an opening into the trachea \_\_\_\_\_

The word *thorax* (*chest*) is used as an ending in compound words that mean the accumulation of substances in the pleural space. Define the following terms.

52. pneumothorax \_\_\_\_\_

53. hydrothorax \_\_\_\_\_

54. pyothorax \_\_\_\_\_

55. hemothorax \_\_\_\_\_

*Define the following words.*

56. tracheostenosis \_\_\_\_\_
57. hemoptysis \_\_\_\_\_
58. hypoxia \_\_\_\_\_
59. pneumonopathy \_\_\_\_\_
60. tachypnea \_\_\_\_\_
61. bronchiectasis \_\_\_\_\_
62. rhinoplasty \_\_\_\_\_
63. pleurodynia \_\_\_\_\_

*Identify and define the root in the following words.*

	Root	Meaning of Root
64. rhinoplasty	_____	_____
65. pulmonologist	_____	_____
66. respiration	_____	_____
67. phrenicotomy	_____	_____
68. pneumatic	_____	_____

### OPPOSITES

*Write a word that means the opposite of the following.*

69. bradypnea \_\_\_\_\_
70. hypocapnia \_\_\_\_\_
71. expiration \_\_\_\_\_
72. extrapulmonary \_\_\_\_\_
73. extubation \_\_\_\_\_

### ADJECTIVES

*Write the adjective form of the following words.*

74. larynx \_\_\_\_\_
75. alveolus \_\_\_\_\_
76. nose \_\_\_\_\_
77. trachea \_\_\_\_\_
78. pleura \_\_\_\_\_
79. bronchus \_\_\_\_\_

**PLURALS**

*Write the plural form of the following words.*

80. naris \_\_\_\_\_
81. pleura \_\_\_\_\_
82. alveolus \_\_\_\_\_
83. concha \_\_\_\_\_
84. bronchus \_\_\_\_\_

**ELIMINATIONS**

*In each of the sets below, underline the word that does not fit in with the rest and explain the reason for your choice.*

85. turbinates — septum — nares — tonsil — conchae  
\_\_\_\_\_
86. sinus — thyroid cartilage — epiglottis — cricoid cartilage — vocal folds  
\_\_\_\_\_
87. diphtheria — tuberculosis — asthma — common cold — influenza  
\_\_\_\_\_
88. RUL — URI — LUL — LLL — RML  
\_\_\_\_\_
89. TLC — FRC — FEV — TV — RDS  
\_\_\_\_\_

**WORD BUILDING**

*Write words for the following definitions using the word parts given. Each word part can be used more than once.*

-pnea -ia ox/i a- -metry phon/o hyper- dys- capn/o hypo- eu- tachy-

90. loss of voice \_\_\_\_\_
91. increased levels of carbon dioxide \_\_\_\_\_
92. difficulty in speaking \_\_\_\_\_
93. increased rate and depth of breathing \_\_\_\_\_
94. measurement of oxygen levels \_\_\_\_\_
95. difficulty in breathing \_\_\_\_\_
96. low levels of oxygen in the tissues \_\_\_\_\_
97. normal, regular breathing \_\_\_\_\_
98. rapid breathing \_\_\_\_\_
99. excessive voice production \_\_\_\_\_

**WORD ANALYSIS**

Define the following words and give the meaning of the word parts in each. Use a dictionary if necessary.

100. pneumotachometer (*nu-mo-tak-OM-eh-ter*)

a. pneum/o \_\_\_\_\_

b. tach/o \_\_\_\_\_

c. -meter \_\_\_\_\_

101. atelectasis (*at-eh-LEK-tab-sis*)

a. atel/o- \_\_\_\_\_

b. -ectasis \_\_\_\_\_

102. pneumatocardia (*nu-mah-to-KAR-de-ah*)

a. pneumat/o \_\_\_\_\_

b. cardi \_\_\_\_\_

c. -ia \_\_\_\_\_

103. pneumoconiosis (*nu-mo-ko-ne-O-sis*)

a. pneum/o \_\_\_\_\_

b. conio \_\_\_\_\_

c. -sis \_\_\_\_\_



# Additional Case Studies

## Case Study 12-1: Giant Cell Sarcoma of the Lung

Morgan, a 68 y/o man, was admitted to the pulmonary unit with chest pain on inspiration, dyspnea, and diaphoresis. He had smoked one and a half packs of cigarettes per day for 52 years and had quit 3 months ago. Morgan retired from the advertising industry and was admitted to occasional alcohol use. He was treated for primary giant cell sarcoma of the left lung 3 years ago with a lobectomy of the left lung followed by radiation and chemotherapy.

Physical examination was unremarkable except for a thoracotomy scar in the left hemithorax, decreased breath sounds, and dullness to percussion of the left base. There was no hemoptysis. Chest and upper abdomen CT scan showed findings compatible with recurrent sarcoma of the left hemithorax. Abnormal mediastinal nodes were evident. A thoracentesis was attempted but did not yield fluid. Morgan was scheduled for a left thoracoscopy, mediastinoscopy, and biopsy.

### Case Study 12-1 Questions

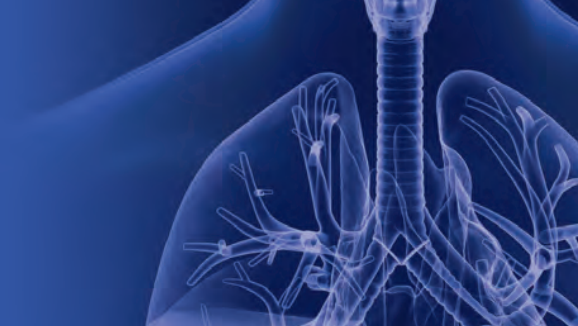To check your answers go to Appendix 11.

**Multiple Choice.** Select the best answer, and write the letter of your choice to the left of each number.

- |  |                          |
|--|--------------------------|
| _____ 1. The root <i>pulmon</i> , as in <i>pulmonary</i> , means | _____ 2. Hemoptysis is   |
| a. chest   | a. drooping eyelids      |
| b. air   | b. discoloration of skin |
| c. lung  | c. blue nail beds        |
| d. breath sound  | d. spitting of blood     |

Write words from the case study with the following meanings.

3. Removal of a lobe \_\_\_\_\_
4. Profuse sweating \_\_\_\_\_
5. Surgical incision of the chest \_\_\_\_\_
6. Endoscopic examination of the chest cavity \_\_\_\_\_
7. Half of the chest \_\_\_\_\_
8. Endoscopic examination of the space between the lungs \_\_\_\_\_



## Case Study 12-2: Terminal Dyspnea

Ella, a 76 y/o woman, was in the ICU in the terminal stage of multisystem organ failure. She had been admitted to the hospital for bacterial pneumonia, which had not resolved with antibiotic therapy. She had a 20-year history of COPD. She was not conscious and was unable to breathe on her own. Her ABGs were abnormal, and she was diagnosed with refractory ARDS. The decision was made to support her breathing with endotracheal intubation and mechanical ventilation. After 1 week and several unsuccessful attempts to wean her from the ventilator, the pulmonologist suggested a permanent tracheostomy and discussed with the family the options of continuing or withdrawing life support. Her physiologic status met the criteria of remote or no chance for recovery.

Ella's family discussed her condition and decided not to pursue aggressive life-sustaining therapies. Ella was assigned do not resuscitate (DNR) status. After the written orders were read and signed by the family, the endotracheal tube, feeding tube, pulse oximeter, and ECG electrodes were removed, and a morphine IV drip was started with prn boluses ordered to promote comfort and relieve pain. The family sat with her for many hours, providing comfort and support. After a while, they noticed that her breathing had become shallow with Cheyne–Stokes respirations. Ella died quietly in the presence of her family and the hospital chaplain.

12

### Case Study 12-2 Questions

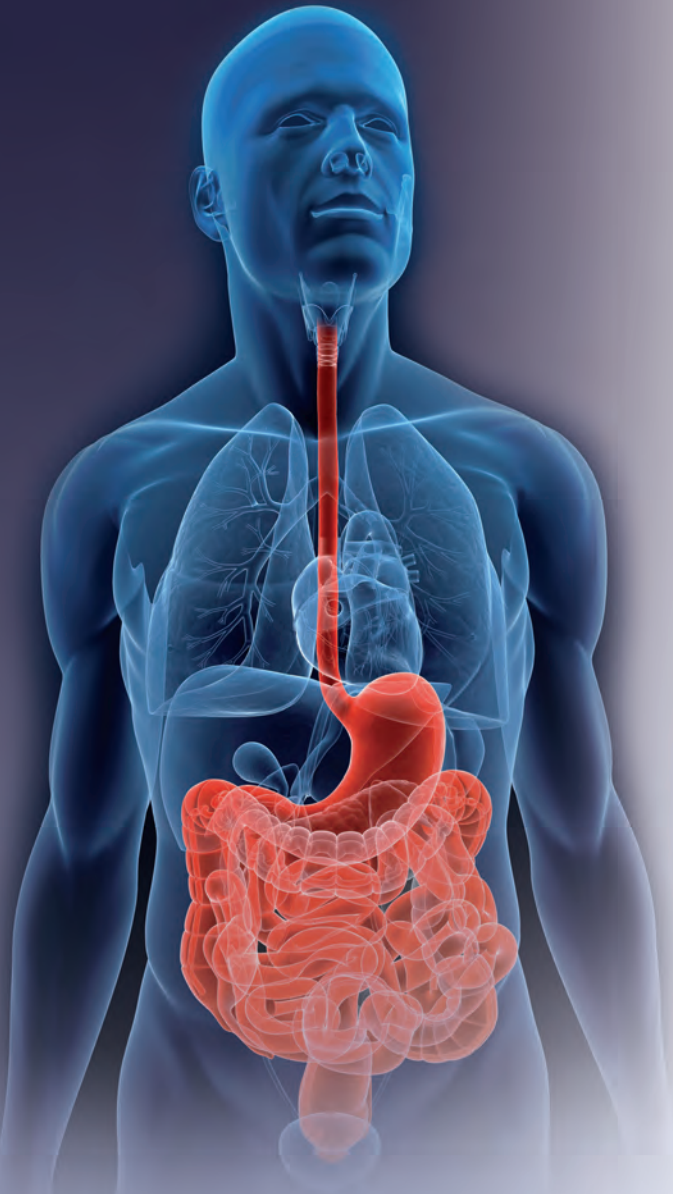To check your answers go to Appendix 11.

**Multiple Choice.** Select the best answer, and write the letter of your choice to the left of each number.

- |   |   |
|---|---|
| <p>_____ 1. Dyspnea could NOT be described as</p> <ul style="list-style-type: none"><li>a. difficulty breathing</li><li>b. eupnea</li><li>c. air hunger</li><li>d. Cheyne–Stokes respirations</li></ul> <p>_____ 2. Pulse oximetry is used to measure</p> <ul style="list-style-type: none"><li>a. forced expiratory volume</li><li>b. tidal volume</li><li>c. positive end-expiratory pressure</li><li>d. oxygen saturation of blood</li></ul> | <p>_____ 3. An endotracheal tube is placed</p> <ul style="list-style-type: none"><li>a. within the trachea</li><li>b. beyond the carina</li><li>c. within the bronchus</li><li>d. under the trachea</li></ul> |
|---|---|

Define the following abbreviations.

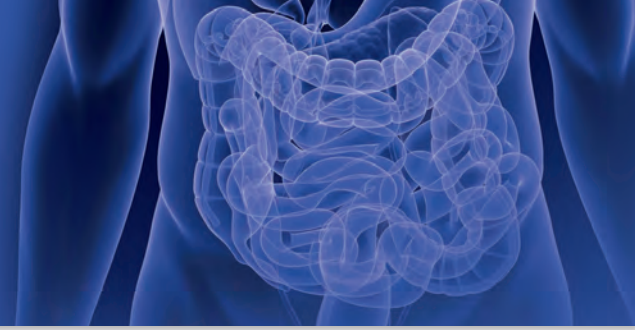- 4. COPD \_\_\_\_\_
- 5. ABG \_\_\_\_\_
- 6. ARDS \_\_\_\_\_
- 7. DNR \_\_\_\_\_



## Pretest

**Multiple Choice.** Select the best answer, and write the letter of your choice to the left of each number. To check your answers go to Appendix 11.

- \_\_\_\_\_ 1. An organic catalyst is a(n)
  - a. enzyme
  - b. sugar
  - c. nucleic acid
  - d. saliva
- \_\_\_\_\_ 2. The organ that carries food from the pharynx to the stomach is the
  - a. trachea
  - b. larynx
  - c. esophagus
  - d. intestine
- \_\_\_\_\_ 3. The word root for stomach is
  - a. hepat/o
  - b. ren/o
  - c. gastr/o
  - d. cardi/o
- \_\_\_\_\_ 4. The word root *enter/o* refers to the
  - a. gallbladder
  - b. intestine
  - c. kidney
  - d. heart
- \_\_\_\_\_ 5. The wave-like action that moves substances through an organ is called
  - a. pulmonary
  - b. peristalsis
  - c. parotid
  - d. mastication
- \_\_\_\_\_ 6. The process of moving digested nutrients from the intestine into the circulation is called
  - a. lymphedema
  - b. digestion
  - c. egestion
  - d. absorption
- \_\_\_\_\_ 7. The organ that secretes bile is the
  - a. kidney
  - b. spleen
  - c. liver
  - d. stomach
- \_\_\_\_\_ 8. Cholecystitis is inflammation of the
  - a. gallbladder
  - b. throat
  - c. diaphragm
  - d. small intestine



## Learning Objectives

After careful study of this chapter, you should be able to:

- 1 Describe the organs of the digestive tract, and give the function of each. **P426**
- 2 Describe the accessory organs of digestion and explain the role of each. **P429**
- 3 Identify and use the roots pertaining to the digestive system and accessory organs. **P432**
- 4 Describe the major disorders of the digestive system. **P436**
- 5 Define medical terms used in reference to the digestive system. **P442**
- 6 Interpret abbreviations used in referring to the gastrointestinal system. **P449**
- 7 Analyze the medical terms in case studies related to the digestive system. **PP425, 456**

## Case Study: Abe's Gastroesophageal Reflux Disease and Erosive Esophagitis



### Chief Complaint

Abe is a 51 y/o businessman with complaints of epigastric pain. He has a 10-year history of heartburn that he notes has become worse over the last year. The heartburn

occurs both after meals and at bedtime. His sleep has been interrupted by nighttime symptoms, and he feels generally fatigued. Intermittently he says he feels that things come back up into his throat, but he lacks clear signs of aspiration into the respiratory tract. He is aware that gastroesophageal reflux disease (GERD) is a chronic condition and may be associated with a risk for complications that include serious morbidity and mortality. Due to his required travel for business, he has put off making a doctor's appointment but realizes he needs to see his physician. The heartburn has increased in frequency (daily now) and severity, so he finally schedules an office visit.

### Examination

Abe is seen by his primary care physician and describes his daily episodes of discomfort. Abe is 6-foot-1-inch and weighs 230 pounds. The physician reviews a colonoscopy from last year with him that was normal. His blood pressure and other physical examination findings at this visit are within normal ranges. Results of a complete blood count, chemistry profile, and lipid profile are all within

normal limits. He describes his self-medication by taking over-the-counter (OTC) drugs including antacids, histamine-2 receptor antagonists (H2 blockers), and the OTC proton pump inhibitor (PPI) omeprazole. He notes the latter helped "a little bit," but he discontinued use after 2 weeks, as noted in the packaging instructions. He has no history of smoking or alcohol abuse. He has an unremarkable past medical and family history.

### Clinical Course

The physician explained to Abe that he is experiencing classic esophageal symptoms that are highly specific to GERD, heartburn, and regurgitation. The physician also informed him that GERD might be associated with erosive esophagitis, which is best diagnosed on endoscopy via esophagogastroduodenoscopy (EGD). Because Abe is 51 and has been experiencing heartburn for more than 10 years with daily symptoms for the past year, he should be evaluated thoroughly. He has been referred for the endoscopy procedure, but the appointment is not for 7 weeks. He is prescribed a PPI and is instructed to return to the office in approximately 4 weeks while still on therapy for assessment of symptoms prior to his appointment.

**Case Study Revisited:** Once you complete this chapter, please review the case follow-up on p. 449.

## Ancillaries *At-A-Glance*

Visit the web resource to access the following resources.

### Learning Resources

- eBook
- A&P Module with Heart & Lung Sounds
- Image Bank

- TestPrep
- Animations
- Audio Pronunciation Glossary

## Introduction

The function of the digestive system is to prepare food for intake by body cells. Nutrients must be broken down by mechanical and chemical means into molecules that are small enough to be absorbed into circulation. Within cells, the nutrients are used for energy and for rebuilding vital cell components. The digestive system also stores undigested waste materials and then eliminates them from the body.

## Digestion

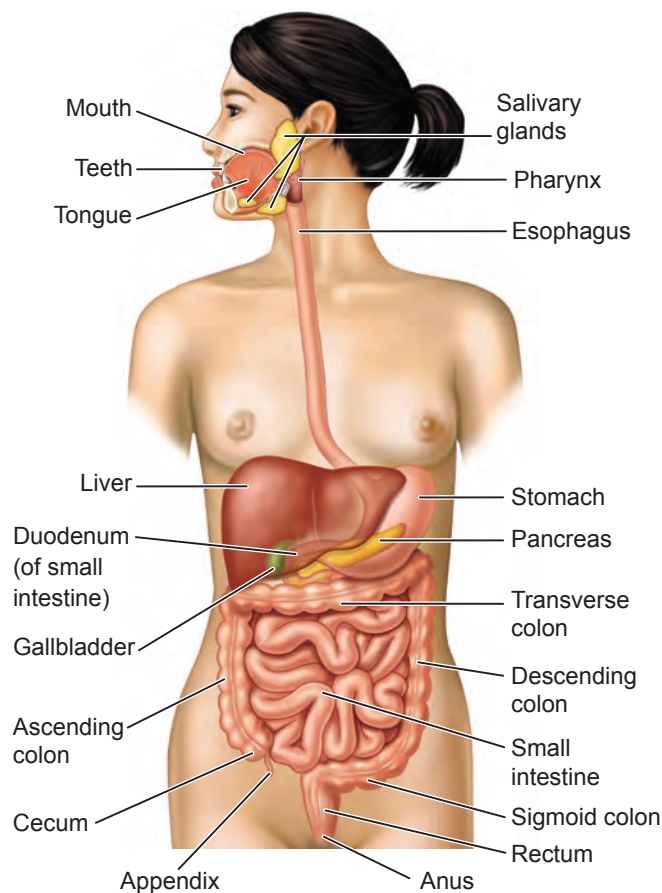
Digestion takes place in the digestive tract proper, which extends from the **mouth** to the **anus** (FIG. 13-1). **Peristalsis**, wave-like contractions of the organ walls, moves food

through the digestive tract and also moves undigested waste material out of the body. Also contributing to digestion are several accessory organs that release secretions into the digestive tract.

**Enzymes** are needed throughout the digestive process. These compounds are organic catalysts that speed the rate of food's chemical breakdown. The names of most enzymes can be recognized by the ending *-ase*.

## The Digestive Tract

The digestive tract, also known as the alimentary canal or gastrointestinal (GI) tract, is essentially a long tube modified into separate organs with special functions (see FIG. 13-1). **BOX 13-1** summarizes the activities of the digestive organs



**FIGURE 13-1 Digestive system.** Divisions of the gastrointestinal tract are shown along with the accessory organs, the salivary glands, liver, gallbladder, and pancreas.



## FOR YOUR REFERENCE

### Organs of the Digestive Tract

BOX 13-1

Organ	Digestive Actions
<b>mouth</b>	Used to bite and chew food. Mixes food with saliva, which contains salivary amylase, an enzyme that begins the digestion of starch. Shapes food into small portions, which the tongue pushes into the pharynx.
<b>pharynx</b>	Swallows food by reflex action and moves it into the esophagus.
<b>esophagus</b>	Moves food into the stomach by peristalsis.
<b>stomach</b>	Stores food; churns to mix food with water and digestive juices. Secretes protein-digesting hydrochloric acid (HCl) and the enzyme pepsin.
<b>small intestine</b>	Secretes enzymes. Receives secretions from the accessory organs, which digest and neutralize food. Site of most digestion and absorption of nutrients into the circulation.
<b>large intestine</b>	Forms, stores, and eliminates undigested waste material.

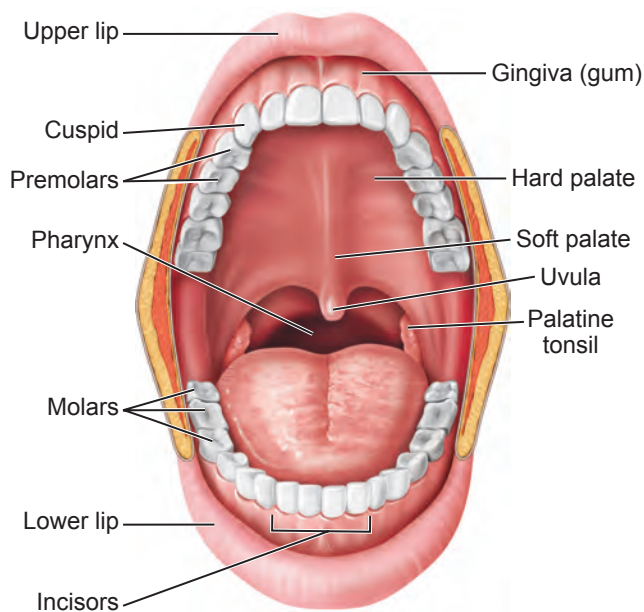
described below. A large serous membrane, the **peritoneum** (*per-ib-to-NE-um*), covers the organs in the abdominal cavity, supporting and separating them.

## THE MOUTH TO THE STOMACH

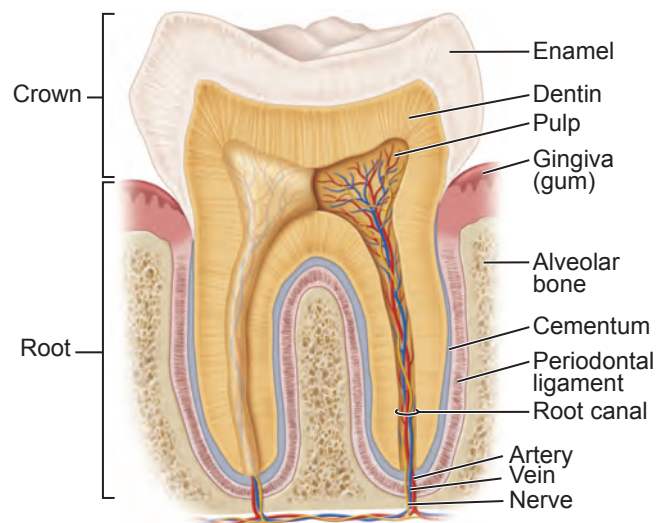
Digestion begins in the mouth (**FIG. 13-2**), also called the oral cavity. Here, food is chewed into small bits by the teeth. There are 32 teeth in a complete adult set, including incisors and canines to bite food and molars for grinding. The structural features of a molar tooth and its surrounding tissue are shown in **FIGURE 13-3**. The **palate** is the roof of

the mouth; the anterior portion (hard palate) is formed by bone, and the posterior part (soft palate) is made of soft tissue. The fleshy **uvula**, used in speech production, hangs from the soft palate. Dental hygienists help in care of the mouth and teeth. **BOX 13-2** has information on careers in dental hygiene.

In the process of chewing, or **mastication**, the tongue, lips, cheeks, and palate also help to break up food and mix it with **saliva**, a secretion that moistens the food and begins starch digestion. The salivary glands (see **FIG. 13-1**) secrete saliva into the mouth and are considered to be accessory digestive organs.



**FIGURE 13-2 The mouth.** The teeth, pharynx, tonsils, and other structures in the oral cavity are shown.



**FIGURE 13-3 A molar tooth.** The bony socket, gingiva, blood vessels, and nerve supply are shown as well as portions of the tooth.



## HEALTH PROFESSIONS

### Dental Hygienist

BOX 13-2

Dental hygienists focus primarily on dental health maintenance and preventive dental care. They examine patients' dentition and periodontium (supporting structures of the teeth); take radiographic images; and perform oral prophylaxis using hand and ultrasonic instruments to remove deposits, such as calculus, stains, and plaque. They may also apply fluorides to prevent caries. They work independently or along with a dentist to administer local anesthesia and nitrous oxide sedation and to do oral screenings, polish restorations, remove sutures, apply dental sealants, and perform periodontal procedures. Dental hygienists must be knowledgeable about safety concerning x-ray equipment, anesthesia, and infectious diseases. They wear safety glasses, surgical masks, and gloves to protect themselves and their patients. A major component of the dental hygienist's work is patient education for maintenance of good oral health. They may give instruction on nutrition and proper oral care, such as brushing, flossing, and the use of antimicrobial rinses.

Most dental hygiene programs award an associate degree; some offer bachelor's or master's degrees. The higher degrees are required for research, teaching, or practice in public or school health facilities. The professional program requires 1 year of college-level prerequisite courses. The curriculum includes courses in radiography, dental anatomy, pharmacology, head and neck anatomy, and other health- and dental-related sciences. Additional material on the legal and ethical aspects of dental hygiene practice and extensive clinical training are included in the program. After graduation, dental hygienists must be licensed in their states by passing clinical and written examinations administered by the American Dental Association's (ADA) Joint Commission on National Dental Examinations.

Almost all hygienists work in dental offices. One advantage of this field is scheduling flexibility and the opportunity for part-time work. Job prospects are good; dental hygiene is among the fastest growing occupations. Benefits vary with place of employment. For additional information, contact the American Dental Hygienists' Association at [adha.org](http://adha.org).

Portions of moistened food are moved toward the **pharynx** (throat), where swallowing reflexes push them into the **esophagus**. Peristalsis moves the food through the esophagus and into the stomach. At its distal end, where it joins the **stomach**, the esophagus has muscle tissue that contracts to keep stomach contents from refluxing (flowing backward). This **lower esophageal sphincter (LES)** is also called the "cardiac sphincter" because it lies above the cardia of the stomach, the region around its upper opening.

In the stomach, food is further broken down as it is churned and mixed with secretions containing the enzyme pepsin and powerful hydrochloric acid (HCl), both of

which break down proteins. The partially digested food then passes through the stomach's lower portion, the **pylorus**, into the **intestine**.

## THE SMALL INTESTINE

Food leaving the stomach enters the **duodenum**, the first portion of the **small intestine**. As the food continues through the **jejunum** and **ileum**, the small intestine's remaining sections, digestion is completed. (Ileum sounds like ilium, a large bone of the pelvis. For information on these and other homonyms, see **BOX 13-3**.) The digestive substances active in



## FOCUS ON WORDS

### Homonyms

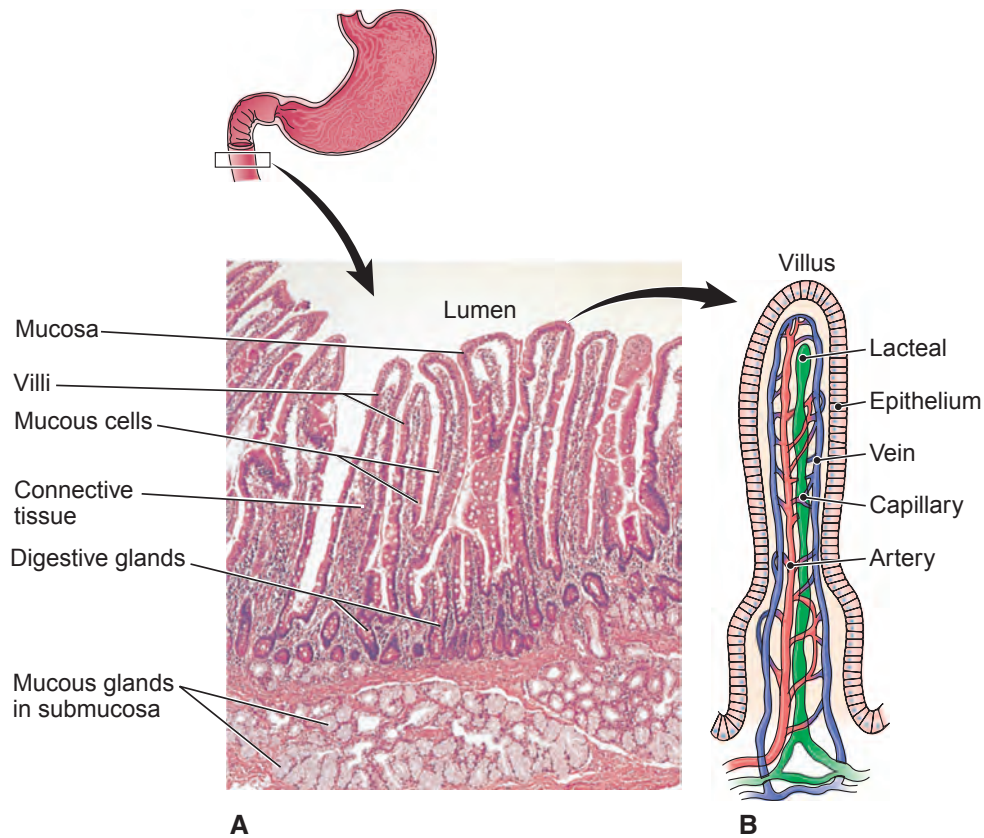
BOX 13-3

Homonyms are words that sound alike but have different meanings. One must know the context in which they are used in order to understand the intended meaning. For example, the ilium is the upper portion of the pelvis, but the ileum is the last portion of the small intestine. Different adjectives are preferred for each—iliac for the first and ileal for the second. The word *meiosis* refers to the type of cell division that halves the chromosomes to form the gametes, but *miosis* means abnormal contraction of the pupil. Both words come from the Greek word that means a decrease.

Similar-sounding names lead to some funny misspellings. The large bone of the upper arm is the humerus, but this bone is often written as "humorous." The vagus nerve (cranial nerve X) is named with a root that means "wander," as in the words vague and vagabond, because this nerve branches to many of the internal organs. Students often

write the name as if it had some relation to the famous gambling city in Nevada.

Homonyms may have a more serious side as well. Drug names may sound or look so similar that clinicians could confuse them, leading to dangerous, potentially fatal, complications. For example, a 50 y/o woman was hospitalized after she took Flomax, which is used to treat symptoms for an enlarged prostate instead of Volmax, which is used to relieve bronchospasm. Another example involved two drugs used to treat schizophrenia, clozapine and olanzapine; a young man was given the wrong drug and suffered severe complications. The FDA and the United States Adopted Names Council regulate sound-alike or look-alike drug names. The World Health Organization (WHO) has rejected many proposed names, and has even changed drug names after they have been marketed, when they have led to medication errors.



**FIGURE 13-4 Intestinal villi.** **A.** Microscopic view of the small intestine's lining showing villi and glands that secrete mucus and digestive juices. The lumen is the central opening. **B.** An intestinal villus. Each villus has blood vessels and a lacteal (lymphatic capillary) for nutrient absorption.

the small intestine include enzymes from the intestine itself and products from accessory organs that secrete into the duodenum.

The digested nutrients, including water, minerals, and vitamins, are absorbed into the circulation, aided by small projections in the intestinal lining called **villi** (FIG. 13-4). Each villus has blood capillaries to absorb nutrients into the bloodstream and lymphatic capillaries, or **lacteals**, to absorb small molecules of digested fats into the lymph. These fats join the blood when lymph flows into the bloodstream near the heart.

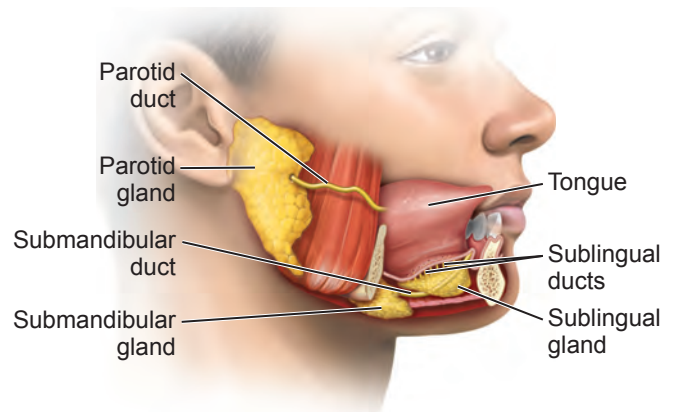
## THE LARGE INTESTINE

Any food that has not been digested, along with water and digestive juices, passes into the **large intestine**. This part of the digestive tract begins in the lower right region of the abdomen with a small pouch, the **cecum**, to which the **appendix** is attached. (The appendix does not aid in digestion, but contains lymphatic tissue and may function in immunity.) The large intestine continues as the **colon**, a name that is often used alone to mean the large intestine, because the colon constitutes such a large portion of that organ. The colon travels upward along the right side of the abdomen as the ascending colon, crosses below the stomach as the transverse colon, and then continues down the left side of the abdomen as the descending colon. As food is

pushed through the colon, water is reabsorbed, and stool or feces is formed. This waste material passes into the S-shaped **sigmoid colon** and is stored in the **rectum** until eliminated through the anus.

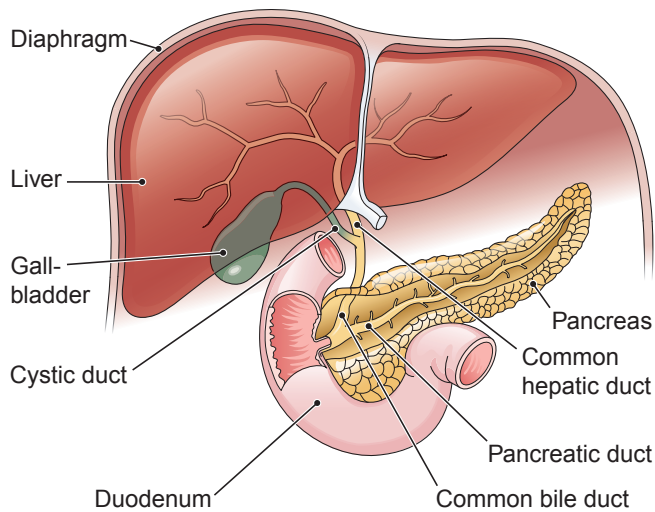
## The Accessory Organs

The salivary glands, which secrete into the mouth, are the first accessory organs to act on food (FIG. 13-5). They



**FIGURE 13-5 Salivary glands.** These accessory organs of digestion secrete into the mouth.






**FIGURE 13-6** Accessory organs of digestion, which secrete into the small intestine. The organs and ducts are shown. The diaphragm is shown for reference.

secrete an enzyme (salivary amylase) that begins starch digestion. The remaining accessory organs are in the abdomen and secrete into the duodenum (**FIG. 13-6**). The liver is a large gland with many functions. A major activity is to process blood, removing toxins and converting nutrients into new compounds. A special circulatory pathway, the **hepatic portal system**, carries blood to the liver from the other abdominal organs. The liver functions in digestion by secreting **bile**, which emulsifies fats, that is, breaks them down into smaller units. The **gallbladder** stores bile until it is needed in digestion. The common hepatic duct from the liver and the cystic duct from the gallbladder merge to form the **common bile duct**, which empties into the duodenum.

The **pancreas** produces a mixture of digestive enzymes that is delivered into the duodenum through the pancreatic duct. It also secretes large amounts of bicarbonate, which neutralizes the strong stomach acid. **BOX 13-4** summarizes the functions of the accessory organs.



## FOR YOUR REFERENCE

### The Accessory Organs

BOX 13-4

Organ	Digestive Actions
salivary glands	Secrete saliva, which moistens food and contains salivary amylase, an enzyme that begins the digestion of starch.
liver	Secretes bile salts that break down (emulsify) fats.
gallbladder	Stores bile and releases it into the digestive tract when needed.
pancreas	Secretes a variety of digestive enzymes. Also secretes bicarbonate to neutralize stomach acid and water to dilute food.

## Terminology

## Key Terms

The terms listed below are emphasized in this chapter. Knowing them will help you organize and prioritize your learning. These boldface terms are also found, collectively, with all chapter key terms in the Glossary.

### Normal Structure and Function

<b>anus</b> <i>A-nus</i>	The distal opening of the digestive tract (root: an/o)
<b>appendix</b> <i>ab-PEN-diks</i>	An appendage; usually means the narrow tube of lymphatic tissue attached to the cecum, the vermiform (worm-like) appendix
<b>bile</b>	The fluid secreted by the liver that emulsifies fats and aids in their absorption (roots: chol/e, bili)
<b>cecum</b> <i>SE-kum</i>	A blind pouch at the beginning of the large intestine (root: cec/o)
<b>colon</b> <i>KO-lon</i>	The major portion of the large intestine; extends from the cecum to the rectum and is formed by ascending, transverse, and descending portions (roots: col/o, colon/o)
<b>common bile duct</b>	The duct that carries bile into the duodenum; formed by the union of the cystic duct and the common hepatic duct (root: choledoch/o)

## Terminology

## Key Terms (Continued)

<b>duodenum</b> <i>du-o-DE-num</i>	The first portion of the small intestine (root: duoden/o); also pronounced <i>du-OD-eh-num</i>
<b>enzyme</b> <i>EN-zime</i>	An organic catalyst; speeds the rate of chemical reactions
<b>esophagus</b> <i>e-SOF-ah-gus</i>	The muscular tube that carries food from the pharynx to the stomach
<b>feces</b> <i>FE-seze</i>	The waste material eliminated from the intestine (adjective: fecal); stool
<b>gallbladder</b>	A sac on the undersurface of the liver that stores bile (root: cholecyst/o)
<b>hepatic portal system</b>	A special circulatory pathway that brings blood directly from the abdominal organs to the liver for processing (also called simply the portal system); the vessel that enters the liver is the hepatic portal vein (portal vein)
<b>ileum</b> <i>IL-e-um</i>	The terminal portion of the small intestine (root: ile/o)
<b>intestine</b> <i>in-TES-tin</i>	The portion of the digestive tract between the stomach and the anus; it consists of the small and large intestines; it functions in digestion, absorption, and elimination of waste (root: enter/o); the bowel ( <i>BOW-el</i> )
<b>jejunum</b> <i>jeh-JU-num</i>	The middle portion of the small intestine (root: jejun/o)
<b>lacteal</b> <i>lak-TELE</i>	A lymphatic capillary in a villus of the small intestine; lacteals absorb digested fats into the lymph
<b>large intestine</b> <i>in-TES-tin</i>	The terminal portion of the digestive tract, consisting of the cecum, colon, rectum, and anus; it stores and eliminates undigested waste material (feces)
<b>liver</b> <i>LIV-er</i>	The large gland in the upper right abdomen; in addition to many other functions, it secretes bile needed for digestion and absorption of fats (root: hepat/o)
<b>lower esophageal sphincter (LES)</b> <i>e-sof-ah-JE-al SFINK-ter</i>	Muscle tissue at the distal end of the esophagus (gastroesophageal junction) that prevents stomach contents from refluxing into the esophagus; also called the cardiac sphincter
<b>mastication</b> <i>mas-tih-KA-shun</i>	Chewing
<b>mouth</b>	The oral cavity; contains the tongue and teeth; used to take in and chew food, mix it with saliva, and move it toward the throat to be swallowed
<b>palate</b> <i>PAL-at</i>	The roof of the mouth; the partition between the mouth and nasal cavity; consists of an anterior portion formed by bone, the hard palate, and a posterior portion formed of tissue, the soft palate (root: palat/o)
<b>pancreas</b> <i>PAN-kre-as</i>	A large, elongated gland posterior to the stomach; it produces hormones that regulate sugar metabolism and also produces digestive enzymes (root: pancreat/o)
<b>peristalsis</b> <i>per-ih-STAL-sis</i>	Wave-like contractions of an organ's walls; moves material through an organ or duct
<b>peritoneum</b> <i>per-ih-to-NE-um</i>	The large serous membrane that lines the abdominal cavity and supports the abdominal organs
<b>pharynx</b> <i>FAR-inks</i>	The throat; a common passageway for food entering the esophagus and air entering the larynx (root: pharyng/o)
<b>pylorus</b> <i>pi-LOR-us</i>	The stomach's distal opening into the duodenum (root: pylor/o); the opening is controlled by a ring of muscle, the pyloric sphincter
<b>rectum</b> <i>REK-tum</i>	The distal portion of the large intestine; it stores and eliminates undigested waste (roots: rect/o, proct/o)

(continued)

## Terminology

## Key Terms (Continued)

<b>saliva</b> <i>sab-LI-vah</i>	The clear secretion released into the mouth that moistens food and contains a starch-digesting enzyme (root: sial/o); saliva is produced by three pairs of glands: the parotid, submandibular, and sublingual glands (see FIG. 13-1)
<b>sigmoid colon</b>	Distal S-shaped portion of the large intestine located between the descending colon and the rectum
<b>small intestine</b> <i>in-TES-tin</i>	The portion of the intestine between the stomach and the large intestine; comprised of the duodenum, jejunum, and ileum; accessory organs secrete into the small intestine, and almost all digestion and absorption occur there
<b>stomach</b> <i>STUM-ak</i>	A muscular sac-like organ below the diaphragm that stores food and secretes juices that digest proteins (root: gastr/o)
<b>uvula</b> <i>U-vu-lah</i>	The fleshy mass that hangs from the soft palate; aids in speech production (literally “little grape”) (root: uvul/o)
<b>villi</b> <i>VIL-i</i>	Tiny projections in the lining of the small intestine that absorb digested foods into the circulation (singular: villus)

## Roots Pertaining to the Digestive System

See TABLES 13-1 to 13-3.

Table 13-1		Roots for the Mouth	
Root	Meaning	Example	Definition of Example
bucc/o	cheek	buccoconversion <i>buk-ko-VER-zhun</i>	turning toward the cheek
dent/o, dent/i	tooth, teeth	edentulous <i>e-DEN-tu-lus</i>	without teeth
odont/o	tooth, teeth	periodontics <i>per-e-o-DON-tiks</i>	dental specialty that deals with the study and treatment of the tissues around the teeth
gingiv/o	gum (gingiva)	gingivectomy <i>jim-jih-VEK-to-me</i>	excision of gum tissue
gloss/o	tongue	glossoplegia <i>glos-o-PLÉ-je-ab</i>	paralysis (-plegia) of the tongue
lingu/o	tongue	orolingual <i>or-o-LING-gwal</i>	pertaining to the mouth and tongue
gnath/o	jaw	prognathous <i>PROG-nah-thus</i>	having a projecting jaw
labi/o	lip	labium <i>LA-be-um</i>	lip or lip-like structure
or/o	mouth	circumoral <i>sir-kum-OR-al</i>	around the mouth
stoma, stomat/o	mouth	xerostomia <i>ze-ro-STO-me-ab</i>	dryness (xero-) of the mouth
palat/o	palate	palatine <i>PAL-ab-tine</i>	pertaining to the palate (also palatal)
sial/o	saliva, salivary gland, salivary duct	sialogram <i>si-AL-o-gram</i>	radiograph of the salivary glands and ducts
uvul/o	uvula	uvulotome <i>U-vu-lo-tome</i>	instrument (-tome) for incising the uvula

## Exercise 13-1

Complete the exercise. To check your answers go to Appendix 11.

Use the adjective suffix *-al* to write a word that has the same meaning as the following.

1. pertaining to the gums \_\_\_\_\_
2. pertaining to the tongue \_\_\_\_\_
3. pertaining to the teeth \_\_\_\_\_
4. pertaining to the cheek \_\_\_\_\_
5. pertaining to the lip \_\_\_\_\_
6. pertaining to the mouth \_\_\_\_\_

Fill in the blanks.

7. Dentistry (*DEN-tis-tre*) is the profession that studies, diagnoses, and treats the \_\_\_\_\_.
8. Micrognathia (*mi-krog-NATH-e-ah*) is excessive smallness of the \_\_\_\_\_.
9. An orthodontist (*or-tho-DON-tist*) specializes in straightening (ortho-) of the \_\_\_\_\_.
10. The oropharynx is the part of the pharynx that is located behind \_\_\_\_\_.
11. Stomatoplasty (*STO-mah-to-plas-te*) is any plastic repair of the \_\_\_\_\_.
12. Hemiglossal (*hem-e-GLOS-al*) means pertaining to one half of the \_\_\_\_\_.
13. A sialolith (*si-AL-o-lith*) is a stone formed in a(n) \_\_\_\_\_ gland or duct.

Define the following words.

14. buccopharyngeal (*BUK-oh-far-in-je-al*) \_\_\_\_\_
15. gingivoplasty (*jim-jih-vo-PLAS-te*) \_\_\_\_\_
16. sublingual (*sub-LING-gwal*) \_\_\_\_\_
17. labiodental (*la-be-o-DEN-tal*) \_\_\_\_\_
18. uvuloptosis (*u-vu-lop-TO-sis*) \_\_\_\_\_
19. hypoglossal (*bi-po-GLOS-al*) \_\_\_\_\_
20. palatorrhaphy (*pal-at-OR-ah-fe*) \_\_\_\_\_

Table 13-2 Roots for the Digestive Tract (Except the Mouth)

Root	Meaning	Example	Definition of Example
esophag/o	esophagus	esophageal <sup>a</sup> <i>e-sof-ah-JE-al</i>	pertaining to the esophagus
gastr/o	stomach	gastroparesis <i>gas-tro-pah-RE-sis</i>	partial paralysis (paresis) of the stomach
pylor/o	pylorus	pyloroplasty <i>pi-LOR-o-plas-te</i>	plastic repair of the pylorus
enter/o	intestine	dysentery <i>DIS-en-ter-e</i>	infectious disease of the intestine
duoden/o	duodenum	duodenostomy <i>du-o-deh-NOS-to-me</i>	surgical creation of an opening into the duodenum
jejun/o	jejunum	jejunectomy <i>jeh-ju-NEK-to-me</i>	excision of the jejunum

(continued)

Table 13-2

## Roots for the Digestive Tract (Except the Mouth) (Continued)

Root	Meaning	Example	Definition of Example
ile/o	ileum	ileitis <i>il-e-I-tis</i>	inflammation of the ileum
cec/o	cecum	cectoptosis <i>se-kop-TO-sis</i>	downward displacement of the cecum
col/o, colon/o	colon	coloclysis <i>ko-lo-KLI-sis</i>	irrigation (-clysis) of the colon
sigmoid/o	sigmoid colon	sigmoidoscope <i>sig-MOY-do-sko-pe</i>	an endoscope for examining the sigmoid colon
rect/o	rectum	rectocele <i>REK-to-sele</i>	hernia of the rectum
proct/o	rectum	proctopexy <i>PROK-to-pek-se</i>	surgical fixation of the rectum
an/o	anus	perianal <i>per-e-A-nal</i>	around the anus

<sup>a</sup>Note addition of e before -al.

## Exercise 13-2

Complete the exercise. To check your answers go to Appendix 11.

Use the adjective suffix *-ic* to write a word for the following definitions.

1. pertaining to the pylorus \_\_\_\_\_
2. pertaining to the colon \_\_\_\_\_
3. pertaining to the stomach \_\_\_\_\_
4. pertaining to the intestine \_\_\_\_\_

Use the adjective suffix *-al* to write a word for the following definitions.

5. pertaining to the rectum \_\_\_\_\_
6. pertaining to the jejunum \_\_\_\_\_
7. pertaining to the ileum \_\_\_\_\_
8. pertaining to the cecum \_\_\_\_\_
9. pertaining to the anus \_\_\_\_\_

Write a word for the following definitions.

10. pertaining to the stomach and duodenum \_\_\_\_\_
11. inflammation of the esophagus \_\_\_\_\_
12. surgical creation of an opening in the intestine \_\_\_\_\_
13. study of the stomach and intestines \_\_\_\_\_
14. endoscopic examination of the stomach \_\_\_\_\_
15. downward displacement of the pylorus \_\_\_\_\_
16. inflammation of the jejunum and ileum \_\_\_\_\_
17. excision of the ileum \_\_\_\_\_
18. pertaining to the anus and rectum \_\_\_\_\_

**Exercise 13-2 (Continued)**

Use the root *col/o* to write a word for the following definitions.

19. inflammation of the colon \_\_\_\_\_
20. surgical creation of an opening into the colon \_\_\_\_\_
21. surgical fixation of the colon \_\_\_\_\_
22. surgical puncture of the colon \_\_\_\_\_

Use the root *colon/o* to write a word for the following definitions.

23. any disease of the colon \_\_\_\_\_
24. endoscopic examination of the colon \_\_\_\_\_

Two organs of the digestive tract or even two parts of the same organ may be surgically connected by a passage (anastomosis) after removal of damaged tissue. Such a procedure is named for the connected organs plus the ending *-stomy*. Use two roots plus the suffix *-stomy* to write a word for the following definitions.

25. surgical creation of a passage between the esophagus and stomach \_\_\_\_\_
26. surgical creation of a passage between the stomach and intestine \_\_\_\_\_
27. surgical creation of a passage between two portions of the jejunum \_\_\_\_\_
28. surgical creation of a passage between the duodenum and the ileum \_\_\_\_\_
29. surgical creation of a passage between the sigmoid colon and the rectum (proct/o) \_\_\_\_\_

Table 13-3

Roots for the Accessory Organs

Root	Meaning	Example	Definition of Example
hepat/o	liver	hepatocyte <i>HEP-ah-to-site</i>	a liver cell
bili	bile	biliary <i>BIL-e-ar-e</i>	pertaining to the bile or bile ducts
chol/e, chol/o	bile, gall	cholestasis <i>ko-le-STA-sis</i>	stoppage of bile flow
cholecyst/o	gallbladder	cholecystogram <i>ko-le-SIS-to-gram</i>	radiograph of the gallbladder
cholangi/o	bile duct	cholangioma <i>ko-lan-je-O-mah</i>	cancer of the bile ducts
choledoch/o	common bile duct	choledochal <i>KO-le-dok-al</i>	pertaining to the common bile duct
pancreat/o	pancreas	pancreatotropic <i>pan-kre-at-o-TROP-ik</i>	acting on the pancreas

## Exercise 13-3

Complete the exercise. To check your answers go to Appendix 11.

Use the suffix *-ic* to write a word for the following definitions.

1. pertaining to the liver \_\_\_\_\_
2. pertaining to the gallbladder \_\_\_\_\_
3. pertaining to the pancreas \_\_\_\_\_

Use the suffix *-graphy* to write a word for the following definitions.

4. radiographic study of the liver \_\_\_\_\_
5. radiographic study of the gallbladder \_\_\_\_\_
6. radiographic study of the bile ducts \_\_\_\_\_
7. radiographic study of the pancreas \_\_\_\_\_

Use the suffix *-lithiasis* to write a word for the following definitions.

8. condition of having a stone in the common bile duct \_\_\_\_\_
9. condition of having a stone in the pancreas \_\_\_\_\_

Fill in the blanks.

10. Inflammation of the liver is called \_\_\_\_\_ .
11. The word biligenesis (*bil-ih-JEN-eh-sis*) means the formation of \_\_\_\_\_ .
12. A cholelith (*KO-le-lith*) is a(n) \_\_\_\_\_ .
13. Choledochotomy (*ko-led-o-KOT-o-me*) is incision of the \_\_\_\_\_ .
14. Cholecystectomy (*ko-le-sis-TEK-to-me*) is removal of the \_\_\_\_\_ .
15. Hepatomegaly (*hep-ab-to-MEG-ab-le*) is enlargement of the \_\_\_\_\_ .
16. Cholangitis (*ko-lan-JI-tis*) is inflammation of a(n) \_\_\_\_\_ .
17. Pancreatolysis (*pan-kre-ab-TOL-ih-sis*) is dissolving of the \_\_\_\_\_ .

## Clinical Aspects of the Digestive System

### DIGESTIVE TRACT

#### Infection

A variety of organisms can infect the GI tract, from viruses and bacteria to protozoa and worms. In the mouth, bacterial infection contributes to tooth decay or **caries**. It may cause a mild gum infection (gingivitis) or more extensive involvement of the deeper tissues and bony support around the tooth (periodontitis). Infections of the stomach or intestine may produce short-lived upsets with **gastroenteritis**, **nausea**, **diarrhea**, and **emesis** (vomiting). Other infectious diseases of the GI tract, such as typhoid, cholera, and dysentery, are more serious, even fatal.

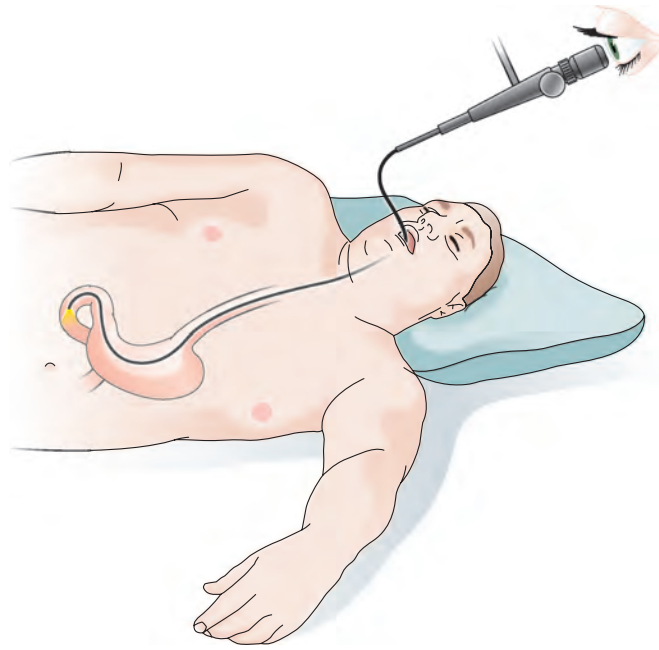
**Appendicitis** results from infection of the appendix, often secondary to its obstruction. Surgery is necessary to

avoid rupture and **peritonitis**, infection of the peritoneal cavity.

#### Ulcers

An ulcer is a lesion of the skin or a mucous membrane marked by inflammation and tissue damage. Ulcers caused by the damaging action of gastric juices, also called peptic juices, on the lining of the GI tract are termed **peptic ulcers**. Most peptic ulcers appear in the first portion of the duodenum. The origins of such ulcers are not completely known, although infection with a bacterium, *Helicobacter pylori*, has been identified as a major cause. Heredity and stress may be factors, as well as chronic inflammation and exposure to damaging drugs, such as aspirin and other NSAIDs, or to irritants in food and drink.

Current ulcer treatment includes the administration of antibiotics to eliminate *H. pylori* infection and use of drugs that inhibit gastric acid secretion. Ulcers may lead to hemorrhage or to perforation of the digestive tract wall.



**FIGURE 13-7 Endoscopy.** A patient undergoing gastroscopy is shown.

Ulcers can be diagnosed by **endoscopy** (FIG. 13-7, BOX 13-5) and by radiographic study of the GI tract using a contrast medium, usually barium sulfate. A **barium study** can reveal a variety of GI disorders in addition to ulcers, including tumors and obstructions. A barium swallow is used for the study of the pharynx and esophagus; an upper GI series examines the esophagus, stomach, and small intestine.

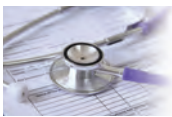### Cancer

Cancer of the mouth generally involves the lips or tongue. Smoking is a major risk factor in these cases. **Leukoplakia**, white patches on mucous membranes, often results from smoking or other irritants and is an early sign of cancer in up to 25% of cases. The most common sites for GI tract cancer are the colon and rectum. Together, these colorectal cancers

rank among the most frequent causes of cancer deaths in the United States in both men and women. A diet low in fiber and calcium and high in fat is a major risk factor in colorectal cancer. Heredity is also a factor, as is chronic inflammation of the colon (colitis). **Polyps** (growths) in the intestine often become cancerous and should be removed. Polyps can be identified and even removed by endoscopy.

One sign of colorectal cancer is bleeding into the intestine, which can be detected by testing the stool for blood. Because this blood may be present in very small amounts, it is described as **occult** (“hidden”) **blood**. Colorectal cancers are staged according to **Dukes classification**, ranging from A to C according to severity.

Examiners can observe the intestine’s interior with various endoscopes named for the specific area in which they



## CLINICAL PERSPECTIVES

### Endoscopy

BOX 13-5

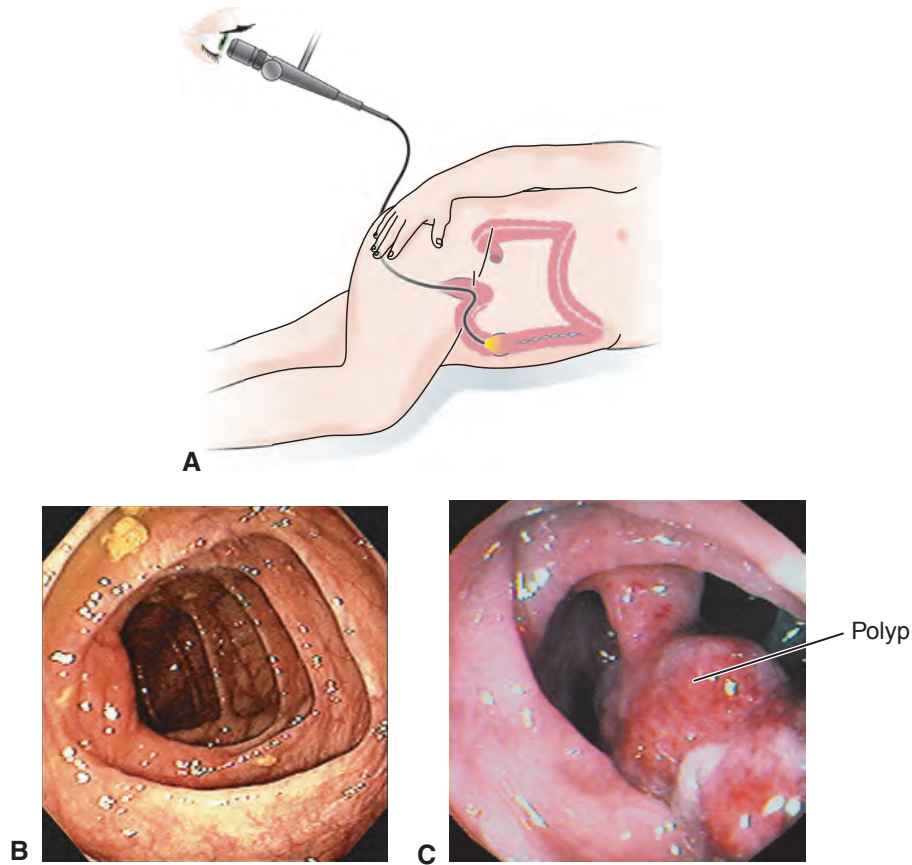
Modern medicine has made great strides toward looking into the body without resorting to surgery. The endoscope, an instrument that is inserted through a body opening or small incision, has allowed the noninvasive examination of passageways, hollow organs, and body cavities. The first endoscopes were rigid, lighted telescopes that could be inserted only a short distance into the body. Today, physicians can navigate the twists and turns of the digestive tract using long fiberoptic endoscopes composed of flexible, light-transmitting bundles of glass or plastic.

Physicians can endoscopically detect structural abnormalities, ulcers, inflammation, and tumors in the GI tract. In addition, they use endoscopes to remove fluid or tissue samples for testing. Some surgery can even be done with an

endoscope, such as polyp removal from the colon or sphincter expansion. Endoscopy can also be used to examine and operate on joints (arthroscopy), the bladder (cystoscopy), respiratory passages (bronchoscopy), and the abdominal cavity (laparoscopy).

A “virtual colonoscopy” uses computerized x-rays to generate detailed images of the colon. This method can provide an adequate screening for most people, although a small percentage might then need a standard colonoscopy for further assessment or surgery. Capsular endoscopy, a recent technological advance, has made examination of the GI tract even easier. It uses a pill-sized camera that a patient can swallow! As the camera moves through the digestive tract, it transmits video images to a data recorder worn on the patient’s belt.



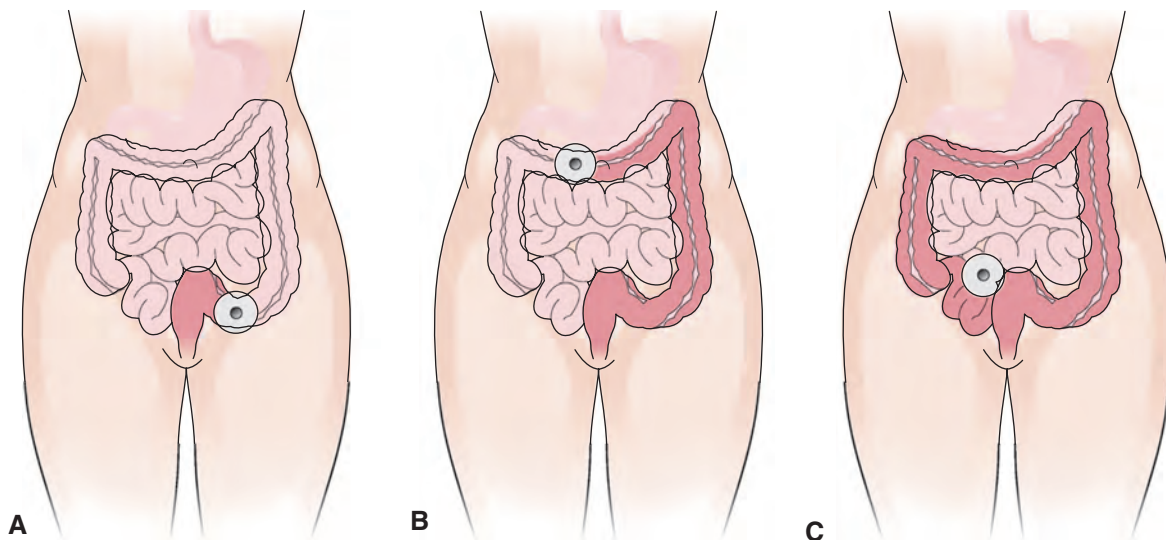


**FIGURE 13-8 Colonoscopy.** **A.** Sigmoidoscopy. The flexible fiberoptic endoscope is advanced past the proximal sigmoid colon and then into the descending colon. **B.** Endoscopic image of the cecum, the first portion of the large intestine. **C.** Endoscopic image of a colonic polyp.

are used, such as proctoscope (rectum), sigmoidoscope (sigmoid colon), and colonoscope (colon) (FIG. 13-8).

In some cases of cancer, and for other reasons as well, it may be necessary to surgically remove a portion of the GI tract and create a **stoma** (opening) on the abdominal wall

for elimination of waste. Such **ostomy** surgery (FIG. 13-9) is named for the organ involved, such as ileostomy (ileum) or colostomy (colon). When an **anastomosis** (connection) is formed between two organs of the tract, both organs are included in naming, such as gastroduodenostomy



**FIGURE 13-9 Ostomy surgery.** Various locations are shown. The shaded portions represent the bowel sections that have been removed or are inactive. **A.** Sigmoid colostomy. **B.** Transverse colostomy. **C.** Ileostomy.

(stomach and duodenum) or coloproctostomy (colon and rectum).

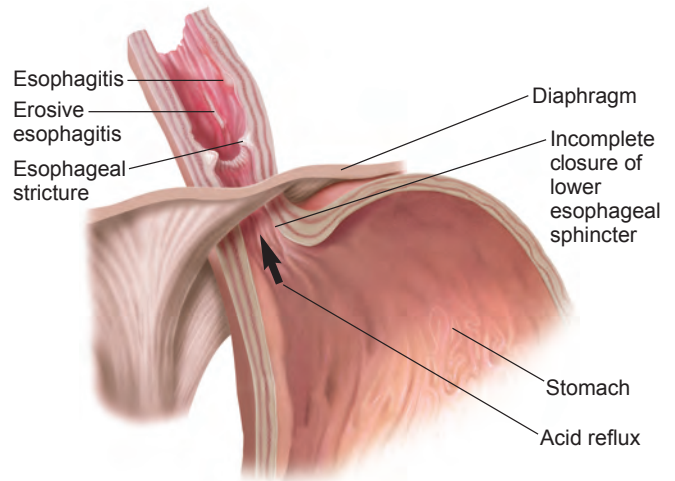
### Obstructions

A hernia is the protrusion of an organ through an abnormal opening. The most common type is an inguinal hernia, described in Chapter 15 (see FIG. 15-7). In a **hiatal hernia**, part of the stomach moves upward into the chest cavity through the space (hiatus) in the diaphragm through which the esophagus passes (see FIG. 3-4). Often this condition produces no symptoms, but it may result in chest pain, **dysphagia** (difficulty in swallowing), or reflux (backflow) of stomach contents into the esophagus.

In **pyloric stenosis**, the opening between the stomach and small intestine is too narrow. This usually occurs in infants and in boys more often than in girls. A sign of pyloric stenosis is projectile vomiting. Surgery may be needed to correct it.

Other types of obstruction include **intussusception** (FIG. 13-10), slipping of an intestinal segment into a part below it; **volvulus**, twisting of the intestine (see FIG. 13-10B); and **ileus**, intestinal obstruction often caused by lack of peristalsis.

**Hemorrhoids** are varicose veins in the rectum associated with pain, bleeding, and, in some cases, rectal prolapse.



**FIGURE 13-11 Gastroesophageal reflux disease (GERD).**

A weak LES allows acidic stomach contents to flow backward into the lower portion of the esophagus causing pain and irritation.

### Gastroesophageal Reflux Disease

**Gastroesophageal reflux disease (GERD)** refers to reflux of gastric juices into the esophagus due to weakness at the gastroesophageal junction, specifically the LES (FIG. 13-11). These acidic secretions irritate the lining of the esophagus and even the throat and mouth if propelled upward by **regurgitation**. A GERD symptom commonly known as **heartburn**, an upward-radiating burning sensation behind the sternum, does not involve the heart, but is experienced in the area near the heart (see Abe's opening case study).

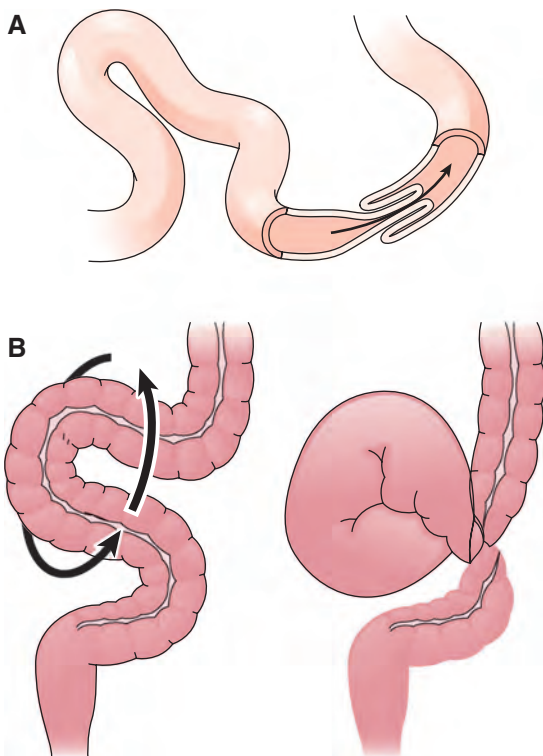
GERD symptoms are more likely to occur when there is increased pressure in the stomach, such as after meals when the stomach is full, when one is lying or bending down, and with obesity and pregnancy. Hiatal hernia can also lead to GERD. Treatment includes weight reduction if needed, elevating the head of the bed 4 to 6 in, avoidance of irritating foods, and drugs to reduce gastric acid secretion. Surgery to repair an incompetent LES might be needed.

Persistent reflux esophagitis may cause injury to the esophageal lining leading to **Barrett syndrome** or *Barrett esophagus*. In this condition, the esophageal mucosa is gradually replaced with epithelium resembling that of the stomach or intestines. Barrett esophagus frequently has no early symptoms, but possible complications include esophageal spasms, formation of scar tissue, esophageal strictures, and increased risk of cancer.

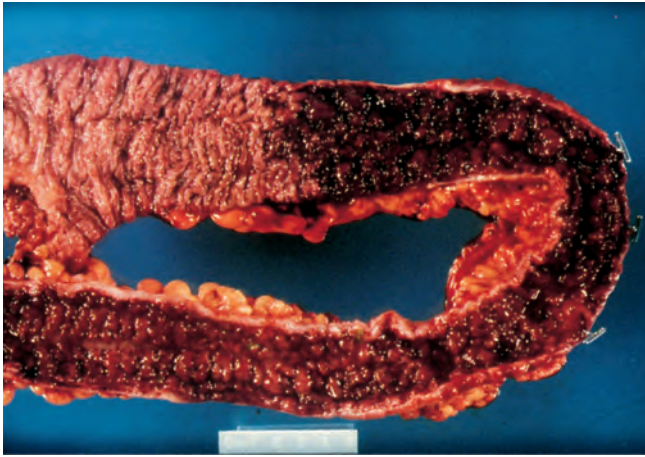### Inflammatory Intestinal Disease

Two similar diseases are included under the heading of inflammatory bowel disease (IBD):

- **Crohn disease** is a chronic inflammation of the intestinal wall, usually in the ileum and colon, causing pain, diarrhea, abscess, and often formation of an abnormal passageway, or **fistula**.
- **Ulcerative colitis** involves a continuous inflammation of the colon's lining that begins in the rectum and extends proximally (FIG. 13-12).



**FIGURE 13-10 Intestinal obstruction. A.** Intussusception. **B.** Volvulus, showing counterclockwise twist.



**FIGURE 13-12 Ulcerative colitis.** Prominent erythema and ulceration of the colon begin in the ascending colon and are most severe in the rectosigmoid area.

Both forms of IBD occur mainly in adolescents and young adults and show a hereditary pattern. They originate with an abnormal immunologic response, perhaps to the normal intestinal flora, along with autoimmunity. Treatment is with anti-inflammatory agents, immunosuppressants, and frequently surgery to remove damaged portions of the colon.

**Celiac disease** is characterized by the inability to absorb foods containing gluten, a protein found in wheat and some other grains. It affects the upper part of the small intestine and originates with an excess immune response to gluten. Mucosal inflammation diminishes the intestinal villi and interferes with absorption. Celiac disease is treated with a gluten-free diet.

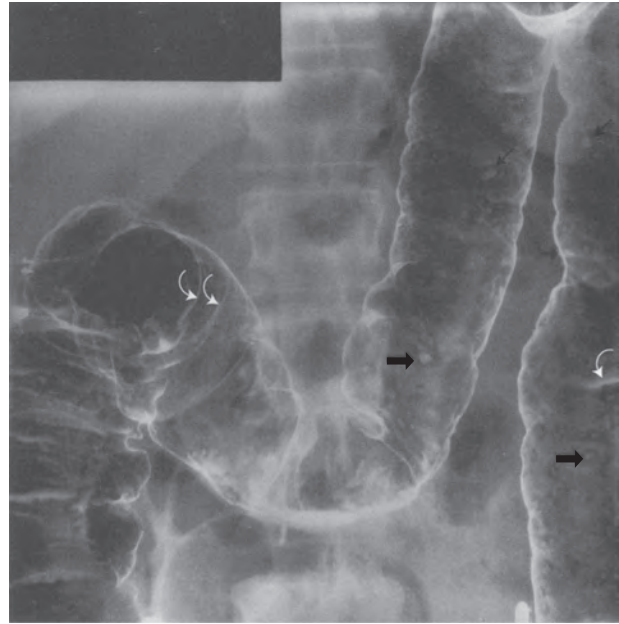
**Diverticulitis** most commonly affects the colon. Diverticula are small pouches in the intestinal wall that commonly appear with age. The presence of these pouches is termed **diverticulosis**, which has been attributed to a diet low in fiber. Collection of waste and bacteria in these sacs leads to diverticulitis, which is accompanied by pain and sometimes bleeding. Diverticula can be seen by radiographic studies of the lower GI tract using barium as a contrast medium, a so-called barium enema (**FIG. 13-13**). Although there is no cure, diverticulitis is treated with a high-fiber diet, stool softeners, and drugs (antispasmodics) to reduce motility. Diverticular infections are treated with antibiotics.

## ACCESSORY ORGANS

### Hepatitis

In the United States and other industrialized countries, **hepatitis** is most often caused by viral infection. More than five types of hepatitis viruses have now been identified. Vaccines are available for hepatitis A and hepatitis B.

- Hepatitis A virus (HAV) is the most common hepatitis virus. It is spread by fecal–oral contamination, often by



**FIGURE 13-13 Lower gastrointestinal (GI) series.** Barium enema shows lesions of enteritis (*straight arrows*) and thickened mucosa (*curved arrows*).

food handlers, and in crowded, unsanitary conditions. It may also be acquired by eating contaminated food, especially seafood.

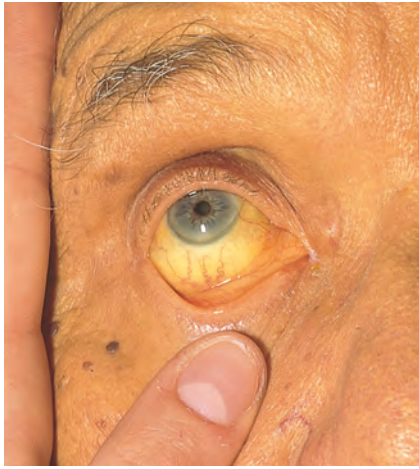
- Hepatitis B virus (HBV) is spread by blood and other body fluids. It may be transmitted sexually, by sharing injection needles, and by close interpersonal contact. Infected individuals may become carriers of the disease. Most patients recover, but the disease may be serious, even fatal, and may lead to liver cancer.
- Hepatitis C is spread through blood and blood products or by close contact with an infected person. Drug treatment is available to cure hepatitis C.
- Hepatitis D, the delta virus, is highly pathogenic but infects only those already infected with hepatitis B.
- Hepatitis E, like HAV, is spread by contaminated food and water. It has caused epidemics in Asia, Africa, and Mexico.

The name *hepatitis* simply means “inflammation of the liver,” but this disease also causes necrosis (death) of liver cells. Other infections as well as drugs and toxins may also cause hepatitis. Liver function tests performed on blood serum are important in diagnosis.

**Jaundice**, or **icterus**, is a symptom of hepatitis and other diseases of the liver and biliary system (**FIG. 13-14**). It appears as yellowness of the skin, whites of the eyes, and mucous membranes due to the presence of bile pigments, mainly **bilirubin**, in the blood.

### Cirrhosis

**Cirrhosis** is a chronic liver disease characterized by **hepatomegaly**, edema, **ascites** (fluid in the abdomen), and jaundice.



**FIGURE 13-14 Jaundice.** Yellowish discoloration due to bile pigments in the blood is seen in the eye.

Disease progression leads to internal bleeding and brain damage caused by changes in the blood's composition. One complication of cirrhosis is **portal hypertension**, increased pressure in the hepatic portal system, the vessels that carry blood from the other abdominal organs to the liver. Portal hypertension causes **splenomegaly** and the formation of varices (varicose veins) in the distal esophagus with possible hemorrhage. The main cause of cirrhosis is the excess consumption of alcohol.

### Gallstones

**Cholelithiasis** refers to the presence of stones in the gallbladder (**FIG. 13-15**) or bile ducts, which is usually associated with **cholecystitis**, inflammation of the gallbladder. Cholelithiasis

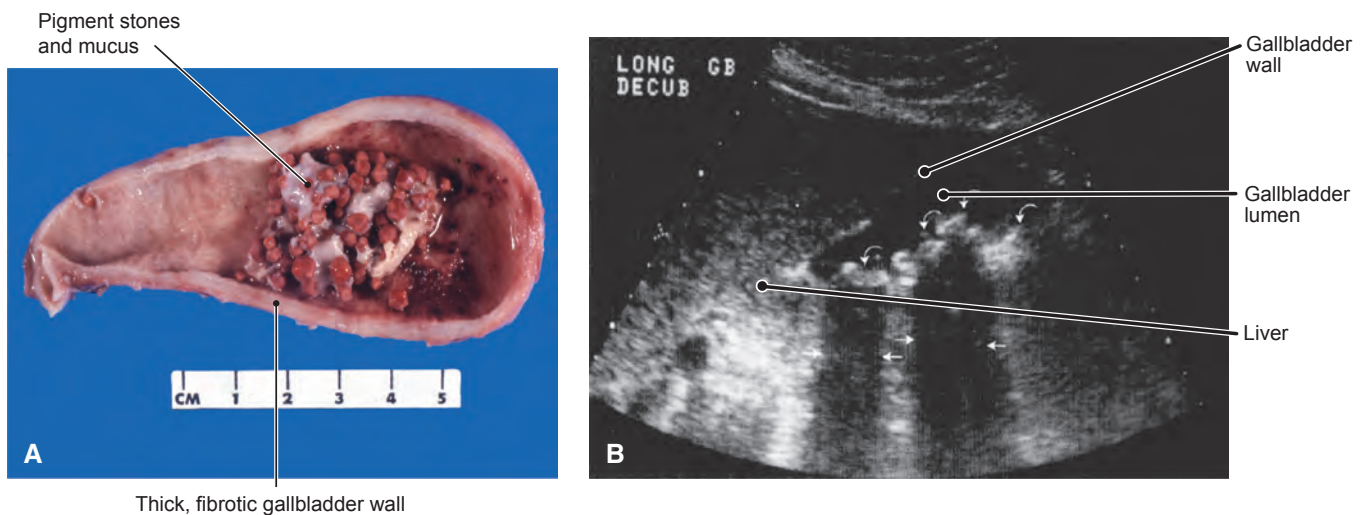
is characterized by **biliary colic** (pain) in the right upper quadrant (RUQ), nausea, and vomiting.

Most gallstones are composed of cholesterol, an ingredient of bile. They form more commonly in women than in men and are promoted by conditions that increase estrogen, as this hormone raises the cholesterol level in bile. These predisposing conditions include pregnancy, use of oral contraceptives, and obesity. Oddly, the rapid weight loss that follows stomach reduction surgery to treat morbid obesity commonly leads to gallstones because of changes in bile production and cholesterol precipitation in the bile. Drugs may dissolve gallstones, but often the cure is removal of the gallbladder in a **cholecystectomy**. Originally, this procedure required an extensive incision, but now the gallbladder is almost always removed laparoscopically through a small abdominal slit. Following gallbladder removal, bile flows directly into the duodenum through the common bile duct.

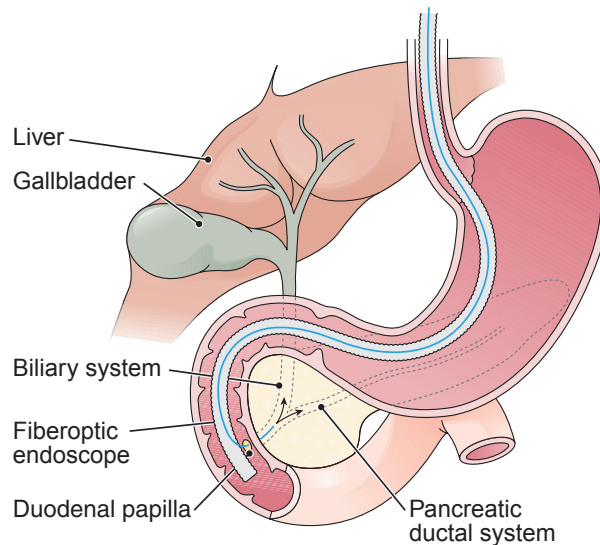
Ultrasonography, radiography, and magnetic resonance imaging are used to diagnose gallstones (see **FIG. 13-14**). **Endoscopic retrograde cholangiopancreatography (ERCP)** (**FIG. 13-16**) is a technique for visualizing and correcting biliary and pancreatic duct obstructions. Contrast medium is injected into the biliary system from the duodenum before imaging.

### Pancreatitis

**Pancreatitis**, or inflammation of the pancreas, may result from alcohol abuse, drug toxicity, bile obstruction, infections, and other causes. Blood tests in acute pancreatitis show increased levels of the enzymes amylase and lipase. Glucose and bilirubin levels may also be elevated. Often the disease subsides with only symptomatic treatment.



**FIGURE 13-15 Cholelithiasis (gallstones).** **A.** Formation of gallstones (cholelithiasis) causes gallbladder inflammation (cholecystitis) and bile obstruction. Numerous gallstones and a thickened gallbladder wall caused by chronic inflammation are evident in this figure. **B.** Sonogram shows dense gallstones (*curved arrows*). Shadows appear (between the *straight arrows*) because the sound waves cannot penetrate the stones (calculi).



**FIGURE 13-16 Endoscopic retrograde cholangiopancreatography (ERCP).** A contrast medium is injected into the pancreatic and bile ducts in preparation for radiography.

## Terminology

## Key Terms

The terms listed below are emphasized in this chapter. Knowing them will help you organize and prioritize your learning. These boldface terms are also found, collectively, with all chapter key terms in the Glossary.

### Disorders

<b>appendicitis</b> <i>ah-pen-dih-SI-tis</i>	Inflammation of the appendix
<b>ascites</b> <i>ah-SI-teze</i>	Accumulation of fluid in the abdominal cavity; a form of edema; may be caused by heart disease, lymphatic or venous obstruction, cirrhosis, or changes in blood plasma composition
<b>Barrett syndrome</b> <i>BAH-ret</i>	Condition resulting from chronic esophagitis, as caused by gastroesophageal reflux disease; inflammatory injury can lead to esophageal spasms, scarring, strictures, and increased risk of cancer; also called Barrett esophagus
<b>biliary colic</b> <i>BIL-e-ar-e KOL-ik</i>	Acute abdominal pain caused by gallstones in the bile ducts
<b>bilirubin</b> <i>bil-ih-RU-bin</i>	A pigment released in the breakdown of hemoglobin from red blood cells; mainly excreted by the liver in bile
<b>caries</b> <i>KAR-eze</i>	Tooth decay
<b>celiac disease</b> <i>SE-le-ak</i>	Inability to absorb foods containing gluten, a protein found in wheat and some other grains; caused by an excess immune response to gluten
<b>cholecystitis</b> <i>ko-le-sis-TI-tis</i>	Inflammation of the gallbladder
<b>cholelithiasis</b> <i>ko-le-lib-THI-ab-sis</i>	The condition of having stones in the gallbladder; also used to refer to stones in the common bile duct
<b>cirrhosis</b> <i>sir-RO-sis</i>	Chronic liver disease with degeneration of liver tissue
<b>Crohn disease</b> <i>krone</i>	A chronic inflammatory disease of the gastrointestinal tract usually involving the ileum and colon

## Terminology

## Key Terms (Continued)

<b>diarrhea</b> <i>di-ab-RE-ab</i>	The frequent passage of watery bowel movements
<b>diverticulitis</b> <i>di-ver-tik-u-LI-tis</i>	Inflammation of diverticula (small pouches) in the wall of the digestive tract, especially in the colon
<b>diverticulosis</b> <i>di-ver-tik-u-LO-sis</i>	The presence of diverticula, especially in the colon
<b>dysphagia</b> <i>dis-FA-je-ab</i>	Difficulty in swallowing
<b>emesis</b> <i>EM-eb-sis</i>	Vomiting
<b>fistula</b> <i>FIS-tu-lah</i>	An abnormal passageway between two organs such as between the rectum and anus (anorectal fistula), or from an organ to the body surface
<b>gastroenteritis</b> <i>gas-tro-en-ter-I-tis</i>	Inflammation of the stomach and intestine
<b>gastroesophageal reflux disease (GERD)</b> <i>gas-tro-e-sof-ah-JE-al</i>	Condition caused by reflux of gastric juices into the esophagus resulting in heartburn, regurgitation, inflammation, and possible damage to the esophagus; caused by weakness of the lower esophageal sphincter (LES) (see <b>FIG. 13-11</b> )
<b>heartburn</b> <i>HART-bern</i>	A warm or burning sensation felt behind the sternum and radiating upward; commonly associated with gastroesophageal reflux; medical name is pyrosis (pyr/o means “heat”)
<b>hemorrhoids</b> <i>HEM-o-roydz</i>	Varicose veins in the rectum associated with pain, bleeding, and sometimes rectal prolapse; piles
<b>hepatitis</b> <i>hep-ab-TI-tis</i>	Inflammation of the liver; commonly caused by a viral infection
<b>hepatomegaly</b> <i>hep-ab-to-MEG-ab-le</i>	Enlargement of the liver
<b>hiatal hernia</b> <i>hi-A-tal</i>	A protrusion of the stomach through the opening (hiatus) in the diaphragm through which the esophagus passes (see <b>FIG. 3-4</b> )
<b>icterus</b> <i>IK-ter-us</i>	Jaundice
<b>ileus</b> <i>IL-e-us</i>	Intestinal obstruction; may be caused by lack of peristalsis (adynamic, paralytic ileus) or by contraction (dynamic ileus); intestinal matter and gas may be relieved by insertion of a drainage tube
<b>intussusception</b> <i>in-tuh-sub-SEP-shun</i>	Slipping of one intestinal segment into another part below it; occurs mainly in male infants in the ileocecal region (see <b>FIG. 13-10A</b> ); may be fatal if untreated for more than 1 day
<b>jaundice</b> <i>JAWN-dis</i>	A yellowish color of the skin, mucous membranes, and whites of the eye caused by bile pigments in the blood (from French <i>jaune</i> meaning “yellow”); the main pigment is bilirubin, a byproduct of erythrocyte destruction (see <b>FIG. 13-14</b> )
<b>leukoplakia</b> <i>lu-ko-PLA-ke-ab</i>	White patches on mucous membranes, as on the tongue or cheeks, often resulting from smoking or other irritants; may be precancerous
<b>nausea</b> <i>NAW-zhah</i>	An unpleasant sensation in the upper abdomen that often precedes vomiting; typically occurs in digestive upset, motion sickness, and sometimes early pregnancy
<b>occult blood</b> <i>o-KULT</i>	Blood present in such small amounts that it can be detected only microscopically or chemically; in the feces, a sign of intestinal bleeding ( <i>occult</i> means “hidden”)
<b>pancreatitis</b> <i>pan-kre-ab-TI-tis</i>	Inflammation of the pancreas

(continued)

## Terminology

## Key Terms (Continued)

<b>peptic ulcer</b> <i>PEP-tik UL-ser</i>	A lesion in the mucous membrane of the esophagus, stomach, or duodenum caused by the action of gastric juice
<b>peritonitis</b> <i>per-ih-to-NI-tis</i>	Inflammation of the peritoneum, the membrane that lines the abdominal cavity and covers the abdominal organs; may result from perforation of an ulcer, ruptured appendix, or reproductive tract infection, among other causes
<b>polyp</b> <i>POL-ip</i>	A tumor that grows on a stalk and bleeds easily
<b>portal hypertension</b>	An abnormal pressure increase in the hepatic portal system; may be caused by cirrhosis, infection, thrombosis, or a tumor
<b>pyloric stenosis</b> <i>pi-LOR-ik</i>	Narrowing of the opening between the stomach and the duodenum; pylorostenosis
<b>regurgitation</b> <i>re-gur-jih-TA-shun</i>	A backward flowing, such as the backflow of undigested food
<b>splenomegaly</b> <i>sple-no-MEG-ab-le</i>	Enlargement of the spleen
<b>ulcerative colitis</b> <i>UL-ser-ab-tiv ko-LI-tis</i>	Chronic ulceration of the rectum and colon; the cause is unknown, but may involve autoimmunity
<b>volvulus</b> <i>VOL-vu-lus</i>	Twisting of the intestine resulting in obstruction; usually involves the sigmoid colon and occurs most often in children and in the elderly; may be caused by congenital malformation, a foreign body, or adhesion; failure to treat immediately may result in death (see <b>FIG. 13-10B</b> )
<b>Diagnosis and Treatment</b>	
<b>anastomosis</b> <i>ah-nas-to-MO-sis</i>	A passage or communication between two vessels or organs; may be normal or pathologic or may be created surgically
<b>barium study</b> <i>BAH-re-um</i>	Use of barium sulfate as a liquid contrast medium for fluoroscopic or radiographic study of the digestive tract; can show obstruction, tumors, ulcers, hiatal hernia, and motility disorders, among other conditions
<b>cholecystectomy</b> <i>ko-le-sis-TEK-to-me</i>	Surgical removal of the gallbladder
<b>Dukes classification</b>	A system for staging colorectal cancer based on degree of bowel wall penetration and lymph node involvement; severity is graded from A to C
<b>endoscopic retrograde cholangiopancreatography (ERCP)</b> <i>ko-lan-je-o-pan-kre-ah-TOG-rah-fe</i>	A technique for viewing the pancreatic and bile ducts and for performing certain techniques to relieve obstructions; contrast medium is injected into the biliary system from the duodenum before radiographs are taken (see <b>FIG. 13-16</b> )
<b>endoscopy</b> <i>en-DOS-ko-pe</i>	Use of a fiberoptic endoscope for direct visual examination; GI studies include esophagogastroduodenoscopy, proctosigmoidoscopy (rectum and distal colon), and colonoscopy (all regions of the colon) (see <b>FIGS. 13-7</b> and <b>13-8</b> )
<b>Ostomy</b> <i>OS-to-me</i>	An opening into the body; generally refers to an opening created for elimination of body waste; also refers to the operation done to create such an opening (see stoma)
<b>stoma</b> <i>STO-mah</i>	A surgically created opening to the body surface or between two organs (literally “mouth”) (see <b>FIG. 13-9</b> )

## Terminology

## Enrichment Terms

The terms listed below expand on the key terms to increase your knowledge of this chapter topic.

## Normal Structure and Function

<b>bolus</b> <i>BO-lus</i>	A mass, such as the rounded mass of food that is swallowed
<b>cardia</b> <i>KAR-de-ab</i>	The part of the stomach near the esophagus, named for its closeness to the heart
<b>chyme</b> <i>kime</i>	The semiliquid partially digested food that moves from the stomach into the small intestine
<b>defecation</b> <i>def-eh-KA-shun</i>	The evacuation of feces from the rectum
<b>deglutition</b> <i>deg-lu-TISH-un</i>	Swallowing
<b>duodenal bulb</b> <i>du-o-DE-nal</i>	The part of the duodenum near the pylorus; the first bend (flexure) of the duodenum
<b>duodenal papilla</b> <i>du-o-DE-nalpap-PIL-lab</i>	The raised area where the common bile duct and pancreatic duct enter the duodenum (see <b>FIG. 13-16</b> ); papilla of Vater ( <i>FAH-ter</i> )
<b>greater omentum</b> <i>o-MEN-tum</i>	A fold of the peritoneum that extends from the stomach over the abdominal organs
<b>hepatic flexure</b> <i>heb-PAT-ik FLEK-shur</i>	The right bend of the colon, forming the junction between the ascending colon and the transverse colon (see <b>FIG. 13-1</b> )
<b>ileocecal valve</b> <i>il-e-o-SE-kal</i>	A valve-like structure between the ileum of the small intestine and the cecum of the large intestine
<b>mesentery</b> <i>MES-en-ter-e</i>	The portion of the peritoneum that folds over and supports the intestine
<b>mesocolon</b> <i>mes-o-KO-lon</i>	The portion of the peritoneum that folds over and supports the colon
<b>papilla of Vater</b>	See duodenal papilla
<b>rugae</b> <i>RU-je</i>	The large folds in the stomach's lining seen when the stomach is empty
<b>sphincter of Oddi</b> <i>OD-e</i>	The muscular ring at the opening of the common bile duct into the duodenum
<b>splenic flexure</b> <i>SPLEN-ik FLEK-shur</i>	The left bend of the colon, forming the junction between the transverse colon and the descending colon (see <b>FIG. 13-1</b> )
<b>Disorders</b>	
<b>achalasia</b> <i>ak-ab-LA-ze-ab</i>	Failure of a smooth muscle to relax, especially the lower esophageal sphincter, so that food is retained in the esophagus
<b>achlorhydria</b> <i>a-klor-HI-dre-ab</i>	Lack of hydrochloric acid in the stomach; opposite is hyperchlorhydria
<b>anorexia</b> <i>an-o-REK-se-ab</i>	Loss of appetite; anorexia nervosa is a psychologically induced refusal or inability to eat (adjectives: anorectic, anorexic)
<b>aphagia</b> <i>ab-FA-je-ab</i>	Inability to swallow or difficulty in swallowing; refusal or inability to eat
<b>aphthous ulcer</b> <i>AF-thus</i>	An ulcer in a mucous membrane, as in the mouth

(continued)



## Terminology

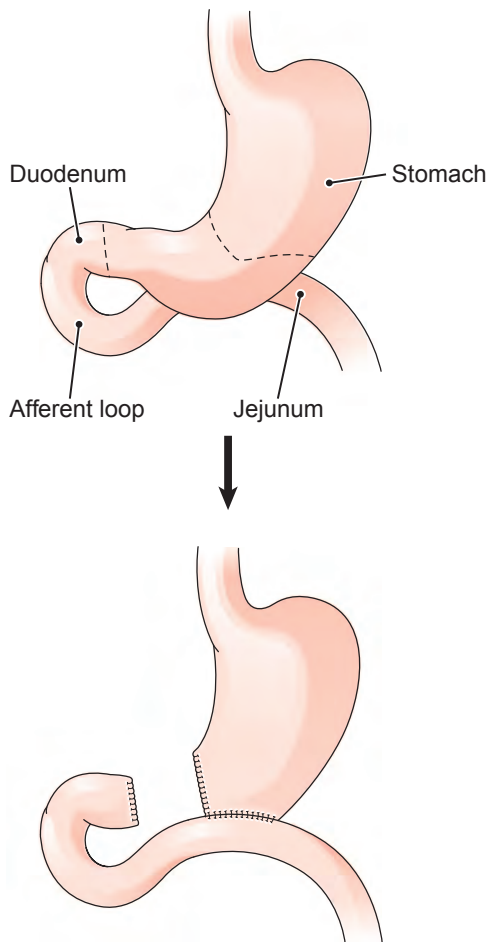
## Enrichment Terms (Continued)

<b>bruxism</b> <i>BRUK-sizm</i>	Clenching and grinding of the teeth, usually during sleep
<b>bulimia</b> <i>bu-LEME-e-ah</i>	Excessive, insatiable appetite; a disorder characterized by overeating followed by induced vomiting, diarrhea, or fasting
<b>cachexia</b> <i>kab-KEK-se-ab</i>	Profound ill health, malnutrition, and wasting
<b>cheilosis</b> <i>ki-LO-sis</i>	Cracking at the corners of the mouth, often caused by B vitamin deficiency (root <i>cheil/o</i> means “lip”)
<b>cholestasis</b> <i>ko-le-STA-sis</i>	Stoppage of bile flow; also pronounced <i>ko-LES-tah-sis</i>
<b>constipation</b> <i>con-stih-PA-shun</i>	Infrequency or difficulty in defecation and the passage of hard, dry feces
<b>dyspepsia</b> <i>dis-PEP-se-ab</i>	Poor or painful digestion
<b>eructation</b> <i>eh-ruk-TA-shun</i>	Belching
<b>familial adenomatous polyposis (FAP)</b> <i>fah-MIL-e-al ad-eh-NO-mah-tus</i> <i>pol-ih-PO-sis</i>	A hereditary condition in which multiple polyps form in the colon and rectum, predisposing one to colorectal cancer
<b>flatulence</b> <i>FLAT-u-lens</i>	Condition of having gas or air in the GI tract
<b>flatus</b> <i>FLA-tus</i>	Gas or air in the gastrointestinal tract; gas or air expelled through the anus
<b>hematemesis</b> <i>he-mah-TEM-eh-sis</i>	Vomiting of blood
<b>irritable bowel syndrome (IBS)</b>	A chronic stress-related disease characterized by diarrhea, constipation, and pain associated with rhythmic intestinal contractions; mucous colitis; spastic colon
<b>megacolon</b> <i>meg-ab-KO-lon</i>	An extremely dilated colon; usually congenital but may occur in acute ulcerative colitis
<b>melena</b> <i>MEL-e-nah</i>	Black tarry feces resulting from blood in the intestines; common in newborns; may also be a sign of gastrointestinal bleeding
<b>obstipation</b> <i>ob-stih-PA-shun</i>	Extreme constipation
<b>pernicious anemia</b> <i>per-NISH-us</i>	A form of anemia caused by the stomach’s failure to secrete intrinsic factor, a substance needed for the absorption of vitamin B <sub>12</sub>
<b>pilonidal cyst</b> <i>pi-lo-NI-dal</i>	A dermal cyst in the sacral region, usually at the top of the cleft between the buttocks; may become infected and begin to drain
<b>thrush</b>	Fungal infection of the mouth and/or throat caused by <i>Candida</i> ; appears as mucosal white patches or ulcers
<b>Vincent disease</b> <i>VIN-sent</i>	Severe gingivitis with necrosis associated with the bacterium <i>Treponema vincentii</i> ; necrotizing ulcerative gingivitis; trench mouth
<b>Diagnosis and Treatment</b>	
<b>appendectomy</b> <i>ap-en-DEK-to-me</i>	Surgical removal of the appendix

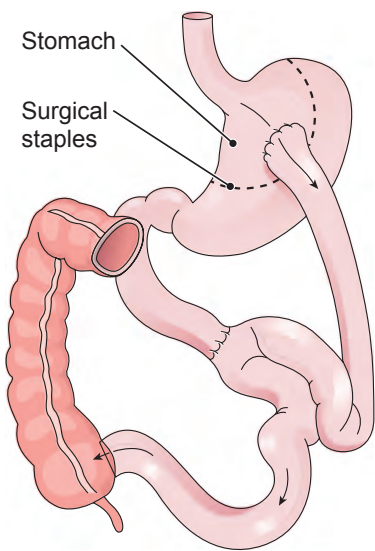
## Terminology

## Enrichment Terms (Continued)

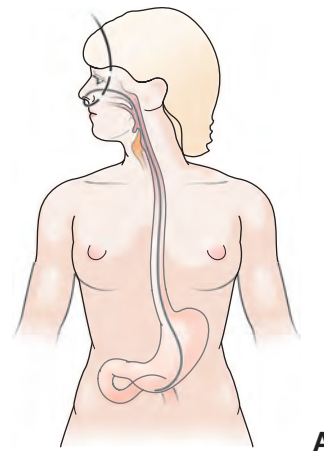
<b>bariatrics</b> <i>bar-e-AT-riks</i>	The branch of medicine concerned with prevention and control of obesity and associated diseases (from Greek <i>baros</i> , meaning “weight”)
<b>bariatric surgery</b>	Surgery to reduce the size of the stomach and reduce nutrient absorption in the treatment of morbid obesity; most common is gastric bypass surgery, which involves division of the stomach and anastomosis of its upper part to the small intestine (jejunum) (FIG. 13-17); other methods are gastric stapling, partitioning of the stomach with rows of staples, and gastric banding, which involves laparoscopic placement of an adjustable loop (Lap-Band) that reduces stomach capacity
<b>Billroth operation</b>	Gastrectomy with anastomosis of the stomach to the duodenum (Billroth I) or to the jejunum (Billroth II) (FIG. 13-18)
<b>gavage</b> <i>gab-VAHZH</i>	Process of feeding through a nasogastric tube into the stomach
<b>lavage</b> <i>lah-VAJ</i>	Washing out of a cavity; irrigation
<b>manometry</b> <i>man-OM-eh-tre</i>	Measurement of pressure; pertaining to the GI tract, measurement of pressure in the portal system as a sign of obstruction
<b>Murphy sign</b>	Inability to take a deep breath when fingers are pressed firmly below the right arch of the ribs (below the liver); signifies gallbladder disease
<b>nasogastric (NG) tube</b> <i>na-zo-GAS-trik</i>	Tube that is passed through the nose into the stomach (FIG. 13-19); may be used for emptying the stomach, administering medication, giving liquids, or sampling stomach contents
<b>parenteral hyperalimentation</b> <i>pah-REN-ter-al</i>	Complete intravenous feeding for one who cannot take in food; total parenteral nutrition (TPN)
<b>percutaneous endoscopic gastrostomy (PEG) tube</b>	Tube inserted into the stomach for long-term feeding (FIG. 13-20)
<b>vagotomy</b> <i>va-GOT-o-me</i>	Interruption of vagal nerve impulses to reduce stomach secretions in the treatment of a gastric ulcer; originally done surgically but may also be done with drugs
<b>Drugs</b>	
<b>antacid</b> <i>ant-AS-id</i>	Agent that counteracts acidity, usually gastric acidity
<b>antidiarrheal</b> <i>an-te-di-ah-RE-al</i>	Drug that treats or prevents diarrhea by reducing intestinal motility or absorbing irritants and soothing the intestinal lining
<b>antiemetic</b> <i>an-te-eh-MET-ik</i>	Agent that relieves or prevents nausea and vomiting
<b>antiflatulent</b> <i>an-te-FLAT-u-lent</i>	Agent that prevents or relieves flatulence
<b>antispasmodic</b> <i>an-te-spas-MOD-ik</i>	Agent that relieves spasm, usually of smooth muscle
<b>emetic</b> <i>eh-MET-ik</i>	An agent that causes vomiting
<b>histamine H<sub>2</sub> antagonist</b>	Drug that decreases secretion of stomach acid by interfering with the action of histamine at H <sub>2</sub> receptors; used to treat ulcers and other gastrointestinal problems; H <sub>2</sub> -receptor–blocking agent
<b>laxative</b> <i>LAK-sah-tiv</i>	Agent that promotes elimination from the large intestine; types include stimulants, substances that retain water (hyperosmotics), stool softeners, and bulk-forming agents
<b>proton pump inhibitor (PPI)</b>	Agent that inhibits gastric acid secretion by blocking the transport of hydrogen ions (protons) into the stomach



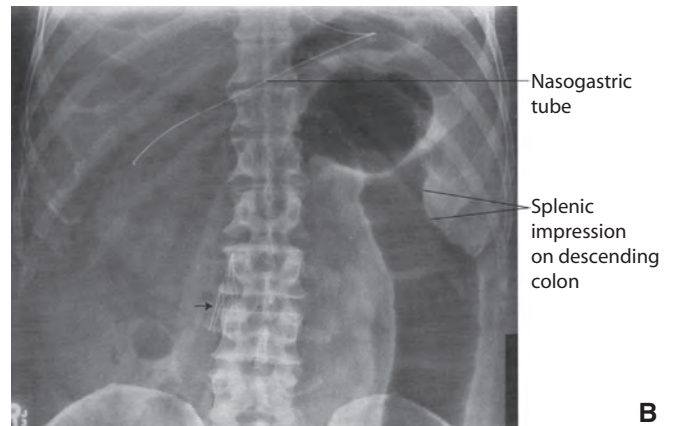
**FIGURE 13-17 Gastric bypass.** For treatment of morbid obesity, a small pouch is created in the stomach to limit food intake. The pouch is attached to the jejunum in a gastrojejunostomy to bypass the stomach and reduce nutrient absorption.



**FIGURE 13-18 Gastrojejunostomy (Billroth II operation).** The dotted lines show the portion removed.

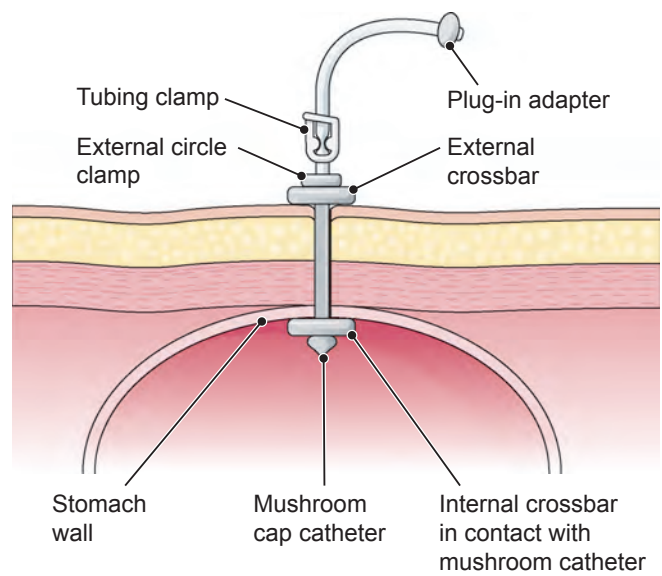


A



B

**FIGURE 13-19 A nasogastric (NG) tube.** A. Diagram showing an NG tube in place. B. Abdominal radiograph showing an NG tube. The filter (arrow) shown in the inferior vena cava is meant to trap emboli that might originate in the lower extremities and pelvis.



**FIGURE 13-20 Percutaneous endoscopic gastrostomy (PEG) tube.** The tube is shown in place in the stomach.

## Terminology *Abbreviations*

The abbreviations listed below are emphasized in this chapter. These are also found, collectively, with all chapter abbreviations in Appendix 2.

<b>BE</b>	Barium enema (for radiographic study of the colon)
<b>BM</b>	Bowel movement
<b>CBD</b>	Common bile duct
<b>EGD</b>	Esophagogastroduodenoscopy
<b>ERCP</b>	Endoscopic retrograde cholangiopancreatography
<b>FAP</b>	Familial adenomatous polyposis
<b>GERD</b>	Gastroesophageal reflux disease
<b>GI</b>	Gastrointestinal
<b>HAV</b>	Hepatitis A virus
<b>HBV</b>	Hepatitis B virus
<b>HCV</b>	Hepatitis C virus
<b>HDV</b>	Hepatitis D virus
<b>HEV</b>	Hepatitis E virus

<b>HCl</b>	Hydrochloric acid
<b>IBD</b>	Inflammatory bowel disease
<b>IBS</b>	Irritable bowel syndrome
<b>LES</b>	Lower esophageal sphincter
<b>NG</b>	Nasogastric (tube)
<b>N&amp;V</b>	Nausea and vomiting
<b>N/V/D</b>	Nausea, vomiting, and diarrhea
<b>PEG</b>	Percutaneous endoscopic gastrostomy (tube)
<b>PONV</b>	Postoperative nausea and vomiting
<b>PPI</b>	Proton pump inhibitor
<b>TPN</b>	Total parenteral nutrition
<b>UGI</b>	Upper gastrointestinal (radiograph series)

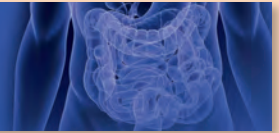## Case Study Revisited

### Abe's Follow-Up Study

When Abe returns after 4 weeks for his follow-up appointment in primary care, he explains that he started feeling better, so he stopped taking the medicine after 3 weeks. Now his symptoms have returned. They are waking him up at night, and he also now reports experiencing mild dysphagia. The physician explained that he must remain on his medication. Medication nonadherence, when patients do not take their medications, is unfortunately fairly common especially among patients with chronic disease. The physician knew this and educated Abe on understanding the importance of following the directions that he was given on the prescription and from his previous appointment. Stopping a medication early, as Abe did, caused his symptoms to return.

Abe's appointment for his endoscopy is in 3 weeks. The physician emphasized that Abe continue his medication and go to his endoscopy appointment. Abe did follow the physician's instructions and the results from the endoscopy indicate that he does indeed have moderate erosive esophagitis. There is a small hiatal hernia present as well.

Following the study, Abe is prescribed a PPI, 40 mg/day and encouraged to take it on a regular basis. He is counseled to decrease the fat in his meals, avoid lying down for at least 2 hours after meals, and limit alcohol intake. He returns 6 weeks later with marked improvement in compliance and total control of his symptoms. He is instructed to continue the PPI and to return in 6 months for reassessment.



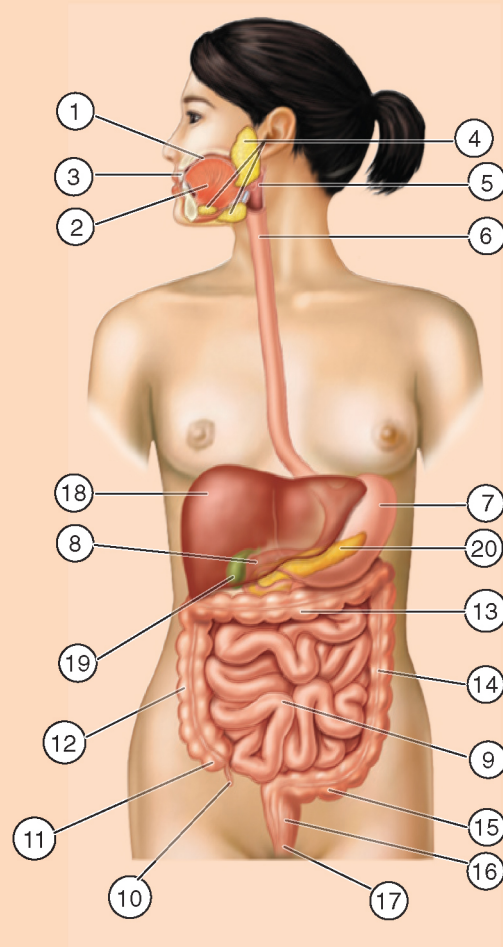
This review tests your understanding of the content introduced in this chapter. Follow the instructions for each exercise and check your answers in Appendix 11.

### LABELING EXERCISE

#### THE DIGESTIVE SYSTEM

Write the name of each numbered part on the corresponding line of the answer sheet.

- |                               |                  |
|-------------------------------|------------------|
| Anus                          | Pancreas         |
| Appendix                      | Pharynx          |
| Ascending colon               | Rectum           |
| Cecum                         | Salivary glands  |
| Descending colon              | Sigmoid colon    |
| Duodenum (of small intestine) | Small intestine  |
| Esophagus                     | Stomach          |
| Gallbladder                   | Teeth            |
| Liver                         | Tongue           |
| Mouth                         | Transverse colon |



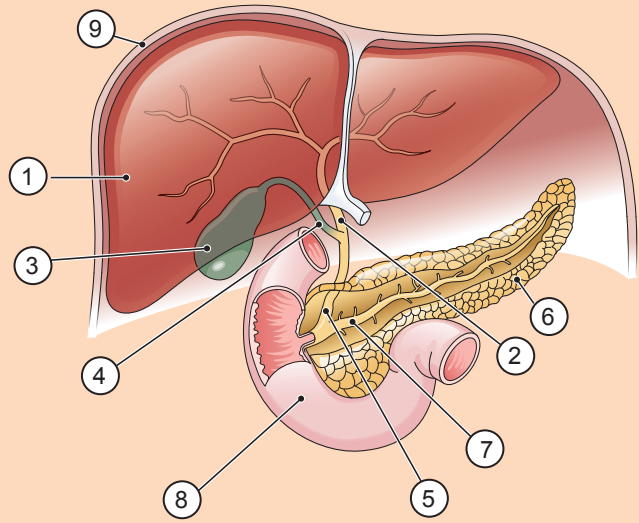
1. \_\_\_\_\_
2. \_\_\_\_\_
3. \_\_\_\_\_
4. \_\_\_\_\_
5. \_\_\_\_\_
6. \_\_\_\_\_
7. \_\_\_\_\_
8. \_\_\_\_\_
9. \_\_\_\_\_
10. \_\_\_\_\_
11. \_\_\_\_\_
12. \_\_\_\_\_
13. \_\_\_\_\_
14. \_\_\_\_\_
15. \_\_\_\_\_
16. \_\_\_\_\_
17. \_\_\_\_\_
18. \_\_\_\_\_
19. \_\_\_\_\_
20. \_\_\_\_\_

**ACCESSORY ORGANS OF DIGESTION**

Write the name of each numbered part on the corresponding line of the answer sheet.

- |                     |                 |
|---------------------|-----------------|
| Common bile duct    | Gallbladder     |
| Common hepatic duct | Liver           |
| Cystic duct         | Pancreas        |
| Diaphragm           | Pancreatic duct |
| Duodenum            |                 |

1. \_\_\_\_\_
2. \_\_\_\_\_
3. \_\_\_\_\_
4. \_\_\_\_\_
5. \_\_\_\_\_
6. \_\_\_\_\_
7. \_\_\_\_\_
8. \_\_\_\_\_
9. \_\_\_\_\_



**TERMINOLOGY**

**MATCHING**

Match the following terms, and write the appropriate letter to the left of each number.

- |                            |  |
|----------------------------|--|
| _____ 1. sublingual        | a. pertaining to the cheek                 |
| _____ 2. emetic            | b. pertaining to the gum                   |
| _____ 3. gingival          | c. substance that induces vomiting         |
| _____ 4. agnathia          | d. hypoglossal                             |
| _____ 5. buccal            | e. absence of the jaw                      |
| _____ 6. enzyme            | a. tooth decay                             |
| _____ 7. caries            | b. wave-like muscular contractions         |
| _____ 8. ileum             | c. organic catalyst                        |
| _____ 9. peristalsis       | d. terminal portion of the small intestine |
| _____ 10. icterus          | e. jaundice                                |
| _____ 11. choledochal      | a. a type of liver disease                 |
| _____ 12. cholelithotripsy | b. pertaining to the common bile duct      |
| _____ 13. cholangiectasis  | c. crushing of a biliary calculus          |
| _____ 14. leukoplakia      | d. dilatation of a bile duct               |
| _____ 15. cirrhosis        | e. white patches on a mucous membrane      |

**Enrichment Terms**

- |                        |   |
|------------------------|---|
| _____ 16. eructation   | a. part of the stomach near the esophagus   |
| _____ 17. cardia       | b. chewing                                  |
| _____ 18. achlorhydria | c. belching                                 |
| _____ 19. bolus        | d. lack of hydrochloric acid in the stomach |
| _____ 20. mastication  | e. a mass, as of food                       |

- |                       |  |
|-----------------------|--|
| ___ 21. gavage        | a. swallowing  |
| ___ 22. bruxism       | b. tooth grinding                                      |
| ___ 23. deglutition   | c. malnutrition and wasting                            |
| ___ 24. cachexia      | d. feeding through a tube                              |
| ___ 25. chyme         | e. partially digested food                             |
| ___ 26. antifatulent  | a. agent that controls loose watery stools             |
| ___ 27. antidiarrheal | b. agent that relieves heartburn, counteracts acidity  |
| ___ 28. antiemetic    | c. agent that relieves or prevents gas                 |
| ___ 29. antacid       | d. agent that relieves spasm                           |
| ___ 30. antispasmodic | e. agent that relieves or prevents nausea and vomiting |

**FILL IN THE BLANKS**

*Complete the sentence with the correct term(s).*

31. Any surgical procedure to reduce the size of the stomach in the treatment of obesity is described as \_\_\_\_\_.
32. The blind pouch at the beginning of the colon is the \_\_\_\_\_.
33. The hepatic portal system carries blood to the \_\_\_\_\_.
34. The organ that stores bile is the \_\_\_\_\_.
35. The large serous membrane that lines the abdominal cavity and supports the abdominal organs is \_\_\_\_\_.
36. Glossorrhaphy is suture of the \_\_\_\_\_.
37. The palatine tonsils are located on either side of the \_\_\_\_\_.
38. Dentin is the main substance of a(n) \_\_\_\_\_.
39. From its name you might guess that the buccinator muscle is in the \_\_\_\_\_.
40. An enterovirus is a virus that infects the \_\_\_\_\_.
41. The anticoagulant heparin is found throughout the body, but it is named for its presence in the \_\_\_\_\_.
42. The substance cholesterol is named for its chemical composition (sterol) and for its presence in the \_\_\_\_\_.

*Refer to Abe's opening case study.*

43. Protrusion of the stomach through an opening in the diaphragm is termed a(n) \_\_\_\_\_.
44. Difficulty in swallowing is technically called \_\_\_\_\_.
45. The histamine-2 receptor antagonist used to treat Abe reduces secretion of (see Appendix 10) \_\_\_\_\_.

**DEFINITIONS**

*Write words for the following definitions.*

46. liver enlargement \_\_\_\_\_
47. a dentist who specializes in treating the tissues around the teeth \_\_\_\_\_
48. surgical excision of the stomach \_\_\_\_\_
49. surgical repair of the palate \_\_\_\_\_
50. narrowing of the pylorus \_\_\_\_\_
51. inflammation of the pancreas \_\_\_\_\_

- 52. medical specialist who treats diseases of the stomach and intestine \_\_\_\_\_
- 53. surgical creation of an opening into the colon \_\_\_\_\_
- 54. surgical creation of a passage between the stomach and the duodenum \_\_\_\_\_
- 55. within (intra-) the liver \_\_\_\_\_

**PLURALS**

*Write the plural form of the following words.*

- 56. diverticulum \_\_\_\_\_
- 57. gingiva \_\_\_\_\_
- 58. calculus \_\_\_\_\_
- 59. anastomosis \_\_\_\_\_

**SPELL CHECK**

*Write the correct spelling on the line to the right of the term.*

- 60. hietal hernia \_\_\_\_\_
- 61. dypepsia \_\_\_\_\_
- 62. inginal herna \_\_\_\_\_
- 63. ikterus \_\_\_\_\_
- 64. pyeloric stenoses \_\_\_\_\_
- 65. diarryhea \_\_\_\_\_

**TRUE-FALSE**

*Examine the following statements. If the statement is true, write T in the first blank. If the statement is false, write F in the first blank, and correct the statement by replacing the underlined word in the second blank.*

	True or False	Correct Answer
66. In the opening case study, Abe is experiencing his epigastric pain in the region <u>below</u> the stomach.	_____	_____
67. The middle portion of the small intestine is the <u>duodenum</u> .	_____	_____
68. Polysialia is the excess secretion of <u>bile</u> .	_____	_____
69. The cystic duct carries bile to and from the <u>gallbladder</u> .	_____	_____
70. The appendix is attached to the <u>cecum</u> .	_____	_____
71. The common hepatic duct and the cystic duct merge to form the <u>common bile duct</u> .	_____	_____
72. An emetic is an agent that promotes <u>diarrhea</u> .	_____	_____
73. A <u>lavage</u> is an irrigation of a cavity.	_____	_____



**ELIMINATIONS**

*In each of the sets below, underline the word that does not fit in with the rest, and explain the reason for your choice.*

74. gingiva — villus — palate — uvula — incisor

---

75. spleen — cecum — colon — rectum — anus

---

76. pancreas — gallbladder — liver — pylorus — salivary glands

---

77. diarrhea — emesis — nausea — regurgitation — amylase

---

**ABBREVIATIONS**

*Write the meaning of the following abbreviations.*

78. N&V \_\_\_\_\_

79. NG \_\_\_\_\_

80. TPN \_\_\_\_\_

81. GERD \_\_\_\_\_

82. EGD \_\_\_\_\_

83. GI \_\_\_\_\_

84. HCl \_\_\_\_\_

85. PPI \_\_\_\_\_

86. PEG (tube) \_\_\_\_\_

87. HAV \_\_\_\_\_

**WORD BUILDING**

*Write a word for the following definitions using the word parts given. Each word part can be used more than once.*

-al	cec/o	r	-pexy	-cele	proct/o	-itis	-rhaphy	ile/o
-----	-------	---	-------	-------	---------	-------	---------	-------

88. inflammation of the cecum \_\_\_\_\_

89. suture of the rectum \_\_\_\_\_

90. fixation of the cecum \_\_\_\_\_

91. hernia of the rectum \_\_\_\_\_

92. pertaining to the ileum and cecum \_\_\_\_\_

93. fixation of the ileum \_\_\_\_\_

94. inflammation of the rectum \_\_\_\_\_

95. suture of the cecum \_\_\_\_\_

96. inflammation of the ileum \_\_\_\_\_

**WORD ANALYSIS**

Define each of the following words and give the meaning of the word parts in each. Use a dictionary if necessary.

97. myenteric (*mi-en-TER-ik*)

a. my/o \_\_\_\_\_

b. enter/o \_\_\_\_\_

c. -ic \_\_\_\_\_

98. cholescintigraphy (*ko-le-sin-TIG-rah-fe*)

a. chole \_\_\_\_\_

b. scinti \_\_\_\_\_

c. -graphy \_\_\_\_\_

99. parenteral (*par-REN-ter-al*)

a. par(a) \_\_\_\_\_

b. enter/o \_\_\_\_\_

c. -al \_\_\_\_\_

100. nasogastric

a. nas/o \_\_\_\_\_

b. gastr/o \_\_\_\_\_

c. -ic \_\_\_\_\_

101. xerostomia

a. xero- \_\_\_\_\_

b. stoma \_\_\_\_\_

c. -ia \_\_\_\_\_

# Additional Case Studies

## Case Study 13-1: Cholecystectomy

Heather, a 42 y/o obese woman, entered the hospital with nausea and vomiting, flatulence and eructation, a fever of 100.5°F, and continuous right upper quadrant (RUQ) and subscapular pain. Examination on admission showed rebound tenderness in the RUQ with a positive Murphy sign. Her skin, nails, and conjunctivae were yellowish, and she reported frequent clay-colored stools. Her leukocyte count was 16,000. An ERCP and ultrasound of the abdomen suggested many small stones in her gallbladder and possibly in the common bile duct. Her diagnosis was cholecystitis with cholelithiasis.

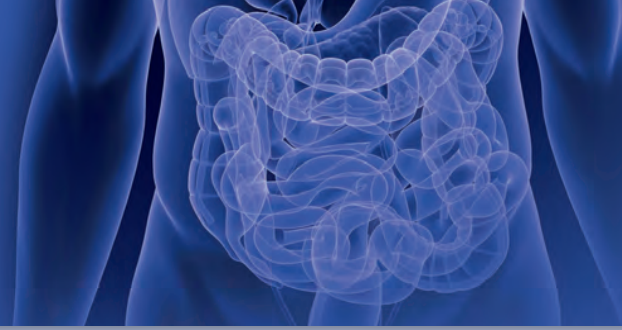A laparoscopic cholecystectomy was attempted with an intraoperative cholangiogram and common bile duct exploration. Because of Heather's size and some unexpected bleeding, visualization was difficult, and the procedure was converted to an open approach. Small stones and granular sludge were irrigated from her common duct, and the gallbladder was removed. She had a T-tube inserted into the duct for bile drainage; this tube was removed on the second postoperative day. An NG tube in place before and during the surgery was also removed on Day 2. She was discharged on the fifth postoperative day with a prescription for prn pain medication.

### Case Study 13-1 Questions

To check your answers go to Appendix 11.

**Multiple Choice.** Select the best answer, and write the letter of your choice to the left of each number.

- |   |  |
|---|--|
| <p>_____ 1. Flatulence and eructation represent</p> <ul style="list-style-type: none"><li>a. regurgitation of chyme</li><li>b. sounds heard only by abdominal auscultation</li><li>c. passage of gas or air from the GI tract</li><li>d. muscular movement of the alimentary tract</li></ul> <p>_____ 2. Subscapular pain is experienced (see FIG. 2-17)</p> <ul style="list-style-type: none"><li>a. above the navel</li><li>b. below the shoulder blade</li><li>c. below the sternum</li><li>d. beside the shoulder blade</li></ul> <p>_____ 3. Yellowish conjunctivae indicate</p> <ul style="list-style-type: none"><li>a. emesis</li><li>b. jaundice</li><li>c. inflammation</li><li>d. ptosis</li></ul> | <p>_____ 4. The common duct is more properly called the</p> <ul style="list-style-type: none"><li>a. common bile duct</li><li>b. common duodenal duct</li><li>c. unified cystic duct</li><li>d. joined bile duct</li></ul> <p>_____ 5. The Murphy sign is a test for pain</p> <ul style="list-style-type: none"><li>a. under the ribs on the left</li><li>b. near the spleen</li><li>c. in the lower right abdomen</li><li>d. under the ribs on the right</li></ul> <p>_____ 6. The NG tube is inserted through the _____ and terminates in the _____.</p> <ul style="list-style-type: none"><li>a. nose, stomach</li><li>b. nostril, gallbladder</li><li>c. glottis, nephron</li><li>d. anus, cecum</li></ul> |
|---|--|



Write the meaning of each of the following abbreviations.

7. ERCP \_\_\_\_\_
8. RUQ \_\_\_\_\_
9. NG \_\_\_\_\_

Give the word or words in the case study with each of the following meanings.

10. presence of stones in the gallbladder \_\_\_\_\_
11. endoscopic surgery of the gallbladder \_\_\_\_\_
12. inflammation of the gallbladder \_\_\_\_\_
13. radiographic study of the gallbladder and biliary system \_\_\_\_\_

13

## Case Study 13-2: Colonoscopy With Biopsy

Sam, a 24 y/o man, had a recent history of lower abdominal pain with frequent loose mucoid stools. He described symptoms of occasional dysphagia, dyspepsia, nausea, and aphthous ulcers of his tongue and buccal mucosa. A previous barium enema (BE) examination showed some irregularities in the sigmoid and rectal segments of his large bowel. Stool samples for culture, ova, and parasites were negative. His tentative diagnosis was irritable bowel syndrome (IBS). He followed a lactose-free, low-residue diet and took Imodium to reduce intestinal motility. His gastroenterologist recommended a colonoscopy. After a 2-day regimen of a soft to clear liquid diet, laxatives, and an enema, the morning of the procedure, he reported to the endoscopy unit. He was transported to the procedure

room. ECG electrodes, a pulse oximeter sensor, and a blood pressure cuff were applied for monitoring, and an IV was inserted in Sam's right arm. An IV bolus of propofol was given, and Sam was positioned on his left side. The colonoscope was gently inserted through the anal sphincter and advanced proximally.

The physician was able to advance past the ileocecal valve, examining the entire length of the colon. Ulcerated granulomatous lesions were seen throughout the colon with a concentration in the sigmoid segment. Many biopsy specimens were taken. The mucosa of the distal ileum was normal. Pathology examination of the biopsy samples was expected to establish a diagnosis of IBD.

### Case Study 13-2 Questions

To check your answers go to Appendix 11.

**Multiple Choice.** Select the best answer, and write the letter of your choice to the left of each number.

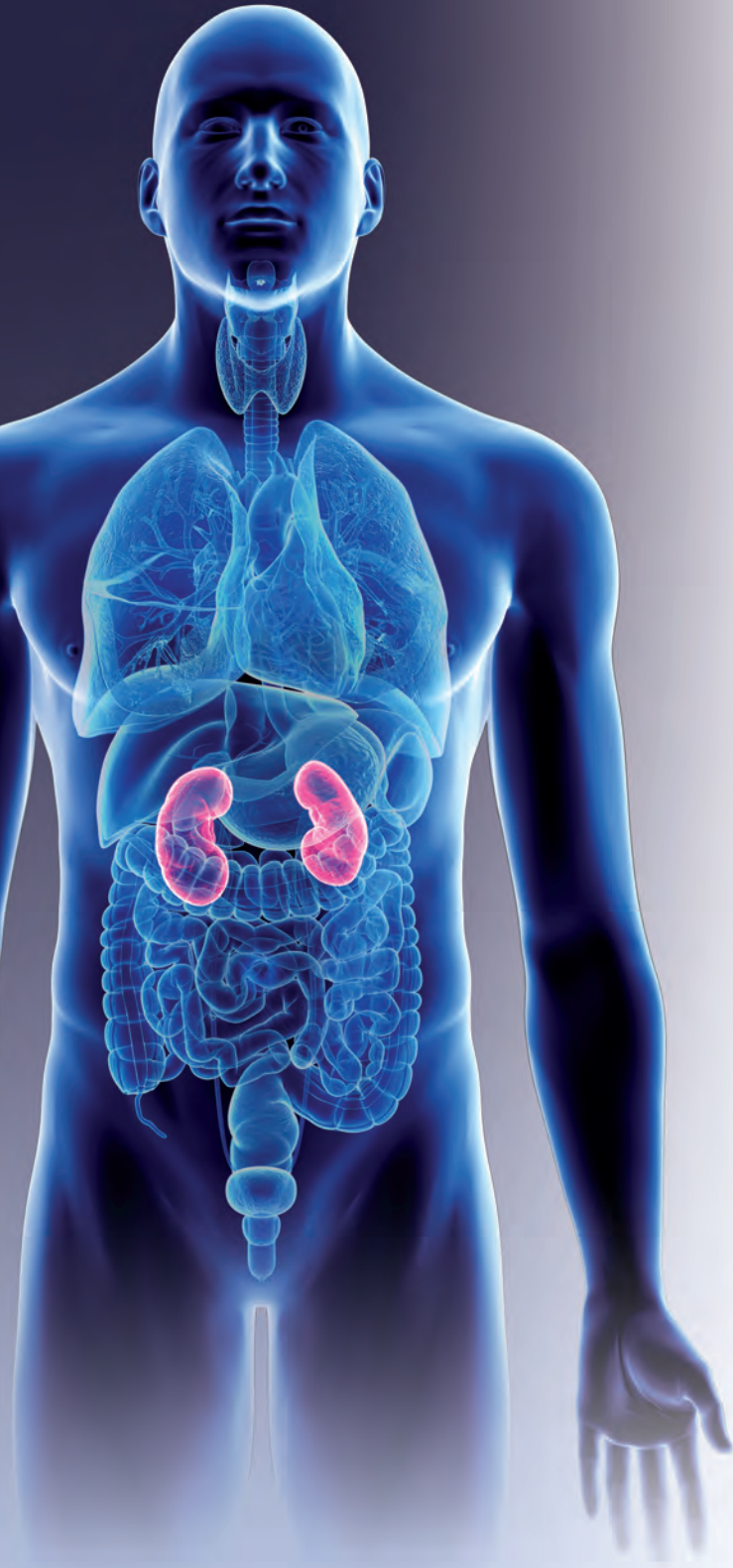- \_\_\_\_\_ 1. Dysphagia and dyspepsia are difficulty or pain with
  - a. chewing and intestinal motility
  - b. swallowing and digestion
  - c. breathing and absorption
  - d. swallowing and nutrition
- \_\_\_\_\_ 2. The buccal mucosa is in the
  - a. nostril, medial side
  - b. mouth, inside of the cheek
  - c. greater curvature of the stomach
  - d. base of the tongue
- \_\_\_\_\_ 3. A gastroenterologist is a physician who specializes in the study of
  - a. mouth and teeth
  - b. stomach, intestines, and related structures
  - c. musculoskeletal system
  - d. nutritional and weight loss diets
- \_\_\_\_\_ 4. The splenic and hepatic flexures are bends in the colon near the
  - a. liver and splanchnic vein
  - b. common bile duct and biliary tree
  - c. spleen and appendix
  - d. spleen and liver
- \_\_\_\_\_ 5. Intestinal motility refers to
  - a. peristalsis
  - b. chewing
  - c. absorption
  - d. ascites
- \_\_\_\_\_ 6. A colonoscopy is
  - a. a radiograph of the small intestine
  - b. an endoscopic study of the esophagus
  - c. an upper endoscopy with biopsy
  - d. an endoscopic examination of the large bowel
- \_\_\_\_\_ 7. The ileocecal valve is
  - a. part of a colonoscope
  - b. at the distal ileum
  - c. in the pylorus
  - d. at the proximal ileum

*Write the meaning of each of the following abbreviations.*

8. IBD \_\_\_\_\_
9. BE \_\_\_\_\_
10. IBS \_\_\_\_\_

*Give the word or words in the case study with each of the following meanings.*

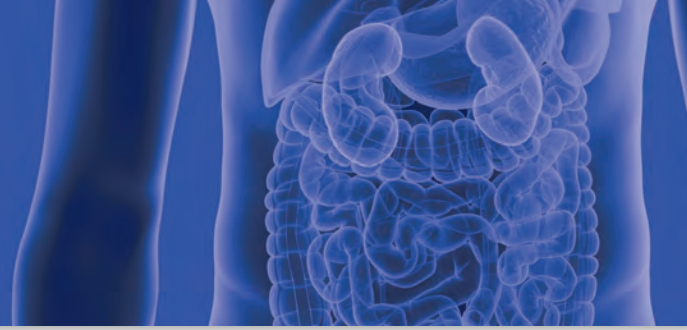11. ring of muscle that regulates the distal opening of the colon \_\_\_\_\_
12. surgical excision of tissue for pathology examination \_\_\_\_\_
13. difficulty in swallowing \_\_\_\_\_



## Pretest

**Multiple Choice.** Select the best answer, and write the letter of your choice to the left of each number. To check your answers go to Appendix 11.

- \_\_\_\_\_ 1. The organ that forms urine is the
  - a. cystic duct
  - b. bladder
  - c. gallbladder
  - d. kidney
- \_\_\_\_\_ 2. The tube that carries urine out of the body is the
  - a. ureter
  - b. pylorus
  - c. urethra
  - d. peristalsis
- \_\_\_\_\_ 3. The hormone erythropoietin stimulates production of
  - a. leukocytes
  - b. saliva
  - c. red blood cells
  - d. platelets
- \_\_\_\_\_ 4. Micturition is the scientific term for
  - a. urination
  - b. digestion
  - c. breathing
  - d. retention
- \_\_\_\_\_ 5. With reference to the urinary system, the root *cyst/o* means
  - a. ureter
  - b. urinary stasis
  - c. urinary bladder
  - d. kidney
- \_\_\_\_\_ 6. Nephritis is inflammation of the
  - a. liver
  - b. intestine
  - c. bladder
  - d. kidney
- \_\_\_\_\_ 7. Separation of substances by passage through a membrane is termed
  - a. absorption
  - b. deglutition
  - c. centrifugation
  - d. dialysis
- \_\_\_\_\_ 8. A substance that promotes urinary output is a(n)
  - a. hypertensive
  - b. diuretic
  - c. channel blocker
  - d. enzyme

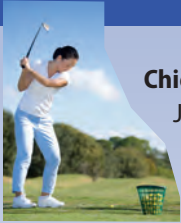

## Learning Objectives

After careful study of this chapter, you should be able to:

- 1 Describe the functions of the urinary system. **P462**
- 2 Name and describe the organs of the urinary tract, and cite the functions of each. **P462**
- 3 Identify the portions of the nephron. **P462**
- 4 Explain the relationship between the kidney and the blood circulation. **P463**
- 5 Describe the processes involved in urine formation. **P464**
- 6 Explain how urine is transported and released from the body. **P465**
- 7 Identify and use the roots pertaining to the urinary system. **P466**
- 8 Describe six major disorders of the urinary system. **P469**
- 9 Interpret abbreviations used in reference to the urinary system. **P479**
- 10 Analyze medical terms in case studies pertaining to the urinary system. **PP461, 486**

## Case Study: Jade's Stress Incontinence



### Chief Complaint

Jade is a 52 y/o female with a history of stress incontinence. The condition has affected her quality of life, as she is not able to be active in athletics without worrying about urinary leakage under physical strain. Jade has cut back on her sports participation and currently is involved in only two golf leagues. Although the incontinence continues to be a problem, she does not want to take medication or have corrective surgery. Jade heard about a minimally invasive clinical research study that could potentially address the incontinence. She decided to investigate to see if she could be a candidate for the study.

### Examination

Jade met with the clinical research nurse who explained the study to her. She was told the study hoped to achieve around 75% improvement, which Jade found acceptable. A urologic history was taken involving questions relating to urinary frequency, urgency, and nocturia (nighttime urination). A few procedures were required at the beginning of the study that would determine eligibility. Jade was required to provide a clean-catch specimen and underwent a cystometrography (CMG) and a cystoscopy. The results indicated that she would be a good candidate for the clinical research study. She was required to maintain

a urinary diary for 2 weeks and record when the stress incontinence and urgency occurred prior to the procedure. In addition, she was required to have follow-up appointments, at various intervals, over the next 3 years. Jade signed the required paperwork and proceeded with the study.

### Clinical Course

The clinical research study involved taking muscle cells from Jade's thigh, growing them in a laboratory, and then reinserting cultured stem cells (myoblasts) into the area surrounding the urethra. Theoretically, these actively growing cells would repair urethral sphincter muscle deficiency and/or damage, thus improving sphincter function and providing greater control of urination. The urologist took a punch biopsy from Jade's thigh muscle to obtain the necessary cells. After laboratory processing, the active cells were injected into place. They were allowed to settle and grow for 3 months, at which time another CMG and cystoscopy were performed. A comparison was made with the original test results to see if there was any improvement in the stress incontinence. All procedures were conducted in the office with minimal discomfort.

**Case Study Revisited: Once you complete this chapter, please review the case follow-up on p. 479.**



## Ancillaries *At-A-Glance*

Visit the web resource to access the following resources.

### Learning Resources

- eBook
- A&P Module with Heart & Lung Sounds
- Image Bank
- TestPrep
- Animations
- Audio Pronunciation Glossary

## Introduction

The urinary system excretes metabolic waste. While forming and eliminating urine, it also regulates the composition, volume, and acid–base balance (pH) of body fluids. In several ways, kidney activity affects the circulation and blood pressure. The urinary system is thus of critical importance in maintaining homeostasis, the state of internal balance. As shown in **FIGURE 14-1**, the urinary system consists of:

- Two kidneys, the organs that form urine
- Two ureters, which transport urine from the kidneys to the bladder
- The urinary bladder, which stores and eliminates urine
- The urethra, which carries urine out of the body

## The Kidneys

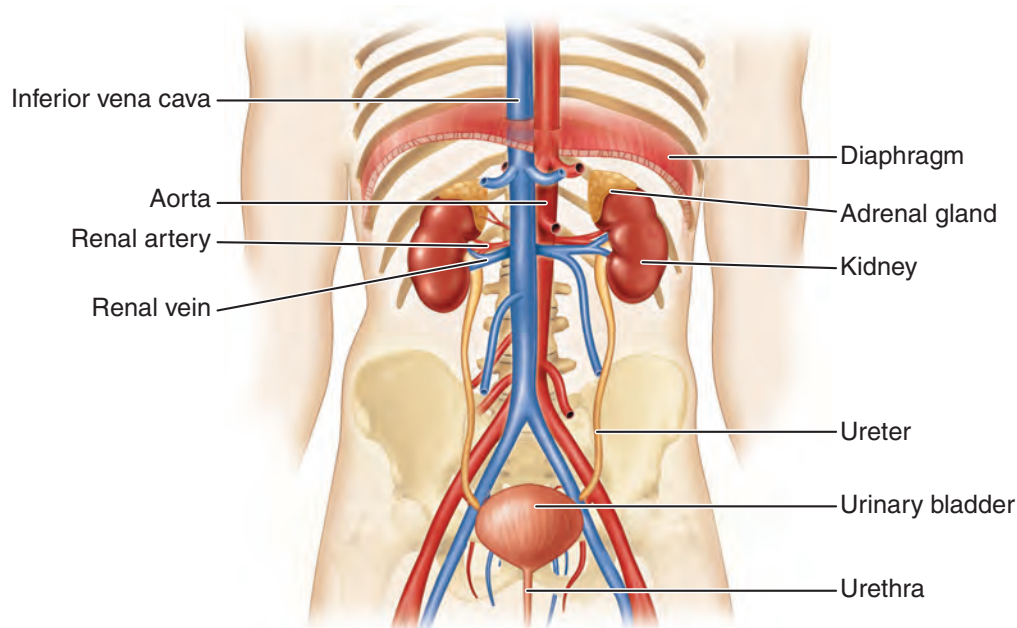
The kidneys are the organs that form **urine** from substances filtered out of the blood. In addition to metabolic wastes,

urine contains water and ions, so its formation is important in regulating the blood's volume and composition. In addition, the kidneys produce two substances that act on the circulatory system:

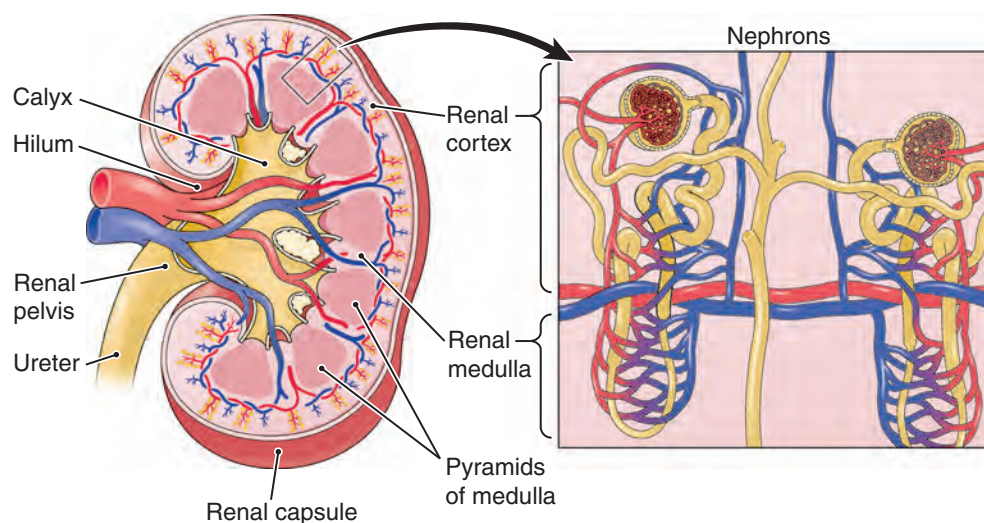
- **Erythropoietin (EPO)**, a hormone that stimulates red blood cell production in the bone marrow.
- **Renin**, an enzyme that functions to raise blood pressure. It activates a blood component called **angiotensin**, which causes constriction of the blood vessels. The drugs known as ACE inhibitors (angiotensin-converting enzyme inhibitors) lower blood pressure by interfering with the production of angiotensin.

## KIDNEY LOCATION AND STRUCTURE

The **kidneys** are located behind the peritoneum in the lumbar region. On the top of each kidney rests an adrenal gland. The kidney is encased in a capsule of fibrous connective tissue overlaid with fat. An outermost layer of connective tissue supports the kidney and anchors it to the body wall.



**FIGURE 14-1** The urinary system. This system consists of the kidneys, ureters, urinary bladder, and urethra. It is shown here along with the diaphragm, nearby blood vessels, and the adrenal glands.



**FIGURE 14-2** The kidney. A longitudinal section (*left*) through the kidney shows its internal structure. The hilum is the point where blood vessels and ducts connect with the kidney. An enlarged diagram of nephrons. Each kidney contains more than 1 million nephrons (*right*).

If you look inside the kidney (**FIG. 14-2**), you will see that it has an outer region, the **renal cortex**, and an inner region, the **renal medulla** (**BOX 14-1**). The medulla is divided into triangular sections, the **renal pyramids**. These pyramids have a lined appearance because they are made up of the loops and collecting tubules of the **nephrons**, the kidney's functional units. Each collecting tubule empties into a urine-collecting area called a **calyx** (from the Latin word meaning “cup”). Several of the smaller minor calices merge to form a major calyx. The major calices then unite to form the **renal pelvis**, the upper funnel-shaped portion of the **ureter**.

## THE NEPHRONS

The tiny working units of the kidneys are the nephrons (**FIG. 14-3**). Each of these microscopic structures is basically a single tubule coiled and folded into various shapes. The tubule begins with a cup-shaped **glomerular** (Bowman) **capsule**, which is part of the nephron's blood-filtering device. The tubule then folds into the proximal tubule, straightens out to form the nephron loop (loop of Henle), coils again

into the distal tubule, and then finally straightens out to form a collecting duct.

## BLOOD SUPPLY TO THE KIDNEY

Blood enters the kidney through a renal artery, a short branch of the abdominal aorta. This vessel subdivides into smaller vessels as it branches throughout the kidney tissue, until finally blood is brought into the glomerular capsule and circulated through a cluster of capillaries, called a **glomerulus**, within the capsule.

Blood leaves the kidney by a series of vessels that finally merge to form the renal vein, which empties into the inferior vena cava.

## Urine Formation

As blood flows through the glomerulus, blood pressure forces materials through the glomerular wall and through the wall of the glomerular capsule into the nephron. The fluid that enters the nephron, the **glomerular filtrate**, consists mainly



## FOCUS ON WORDS

### Words That Serve Double Duty

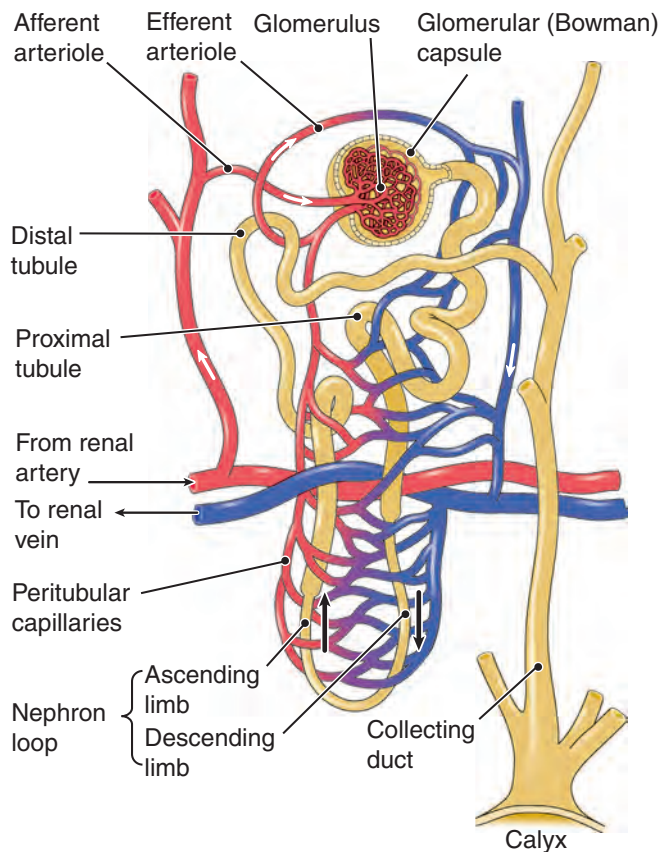
BOX 14-1

Some words appear in more than one body system to represent different structures. The medulla of the kidney is the inner portion of the organ. Other organs, such as the adrenal gland, ovary, and lymph nodes, may also be divided into a central medulla and outer cortex. But *medulla* means “marrow,” and this term also applies to the bone marrow, to the spinal cord, and to the part of the brain that connects with the spinal cord, the medulla oblongata.

A ventricle is a chamber. There are ventricles in the brain and in the heart. The word *fundus* means the back part or base

of an organ. The uterus has a fundus, the upper rounded portion farthest from the cervix, as does the stomach. The fundus of the eye, examined for signs of diabetes and glaucoma, is the innermost layer, where the retina is located. A macula is a spot. There is a macula in the eye, which is the point of sharpest vision. There is also a macula in the ear, which contains receptors for equilibrium.

In interpreting medical terminology, it is often important to know the context in which a word is used.



**FIGURE 14-3 A nephron and its blood supply.** The nephron regulates the proportion of water, waste, and other materials in urine according to the body's constantly changing needs. A nephron consists of a glomerular capsule, convoluted tubules, the nephron loop (loop of Henle), and a collecting duct. Blood filtration occurs through the glomerulus in the glomerular capsule. Materials that enter the nephron can be returned to the blood through the surrounding peritubular capillaries.

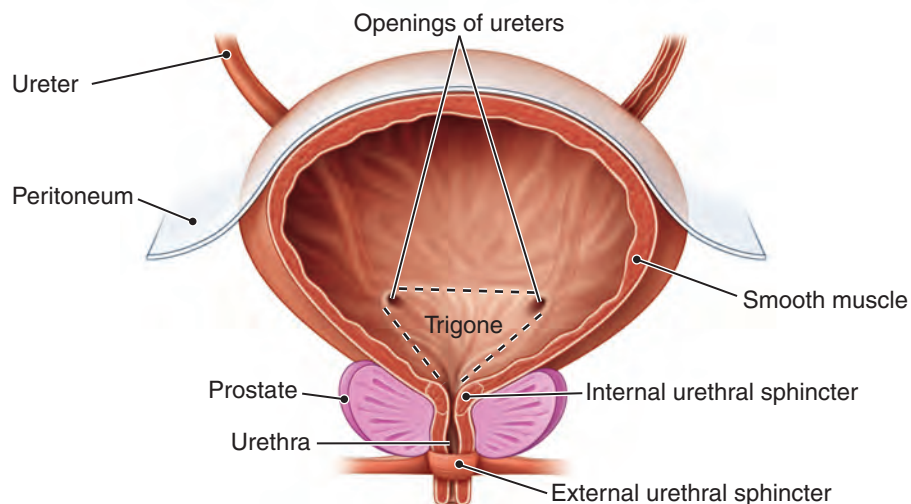
of water, electrolytes, soluble wastes, nutrients, and toxins. The main waste material is **urea**, the nitrogenous (nitrogen-containing) byproduct of protein metabolism. The filtrate should not contain any cells or proteins, such as albumin.

The waste material and the toxins must be eliminated, but most of the water, electrolytes, and nutrients must be returned to the blood, or we would rapidly starve and dehydrate. This return process, termed **tubular reabsorption**, occurs through the peritubular capillaries that surround the nephron.

As the filtrate flows through the nephron, other processes further regulate its composition and pH. For example, the nephron tubule can actively secrete substances from the blood into the urine. Hydrogen ions are moved in this manner, making the urine more acidic and raising the pH of body fluids. Certain drugs can also be removed from the blood and excreted. The filtrate's concentration is also adjusted under the effects of a pituitary hormone. **Antidiuretic hormone (ADH)** promotes reabsorption of water, thus concentrating the filtrate. The final filtrate, now called urine, flows into the collecting ducts to be eliminated. A **diuretic** is a substance that promotes increased urinary output or **diuresis**. Diuretic drugs are used in treating hypertension and heart failure to decrease fluid volume and reduce the heart's workload (see Chapter 10).

## TRANSPORT AND REMOVAL OF URINE

Urine is drained from the renal pelvis and carried by the left and right ureters to the **urinary bladder** (FIG. 14-4), where it is stored. The bladder is located posterior to the pubic bone and below the peritoneum. As the bladder fills, it expands upward from a stable triangle at its base. This triangle, the



**FIGURE 14-4 The urinary bladder.** The interior of the male bladder is shown. The trigone is a triangular region in the bladder floor marked by the openings of the ureters and the urethra. The urethra travels through the prostate gland in the male.

**trigone**, is marked by the ureteral openings and the urethral opening below (see FIG. 14-4). The trigone's stability prevents urine from refluxing into the ureters.

Fullness stimulates a reflex contraction of the bladder muscle and expulsion of urine through the **urethra**. The female urethra is short (4 cm [1.5 in]) and carries only urine. The male urethra is longer (20 cm [8 in]) and carries both urine and semen.

The voiding (release) of urine, called **urination** or more technically, **micturition**, is regulated by two sphincters (circular muscles) that surround the urethra. The superior muscle, the internal urethral sphincter, is around the entrance to the urethra and functions involuntarily; the inferior muscle, the external urethral sphincter, is under conscious control. An inability to retain urine is termed *urinary incontinence*.

## Terminology

## Key Terms

The terms listed below are emphasized in this chapter. Knowing them will help you organize and prioritize your learning. These boldface terms are also found, collectively, with all chapter key terms in the Glossary.

### Normal Structure and Function

<b>antidiuretic hormone (ADH)</b> <i>an-te-di-u-RET-ik</i>	A hormone released from the pituitary gland that causes water reabsorption in the kidneys, thus concentrating the urine
<b>angiotensin</b> <i>an-je-o-TEN-sin</i>	A substance that increases blood pressure; activated in the blood by renin, an enzyme produced by the kidneys
<b>calyx</b> <i>KA-lik</i> s	A cup-like cavity in the pelvis of the kidney; also calix (plural: calices) (roots: cali/o, calic/o)
<b>diuresis</b> <i>di-u-RE-sis</i>	Excretion of urine; usually meaning increased urinary excretion
<b>diuretic</b> <i>di-u-RET-ik</i>	A substance that increases the excretion of urine; pertaining to diuresis
<b>erythropoietin (EPO)</b> <i>eh-rith-ro-POY-eh-tin</i>	A hormone produced by the kidneys that stimulates red blood cell production in the bone marrow
<b>glomerular capsule</b> <i>glo-MER-u-lar KAP-sule</i>	The cup-shaped structure at the beginning of the nephron that surrounds the glomerulus and receives material filtered out of the blood; Bowman ( <i>BO-man</i> ) capsule
<b>glomerular filtrate</b> <i>glo-MER-u-lar FIL-trate</i>	The fluid and dissolved materials that filter out of the blood and enter the nephron through the glomerular capsule
<b>glomerulus</b> <i>glo-MER-u-lus</i>	The cluster of capillaries within the glomerular capsule (plural: glomeruli) (root: glomerul/o)
<b>kidney</b> <i>KID-ne</i>	An organ of excretion (roots: ren/o, nephr/o); the two kidneys filter the blood and form urine, which contains metabolic waste products and other substances as needed to regulate the water, electrolyte, and pH balance of body fluids
<b>micturition</b> <i>mik-tu-RISH-un</i>	The voiding of urine; urination
<b>nephron</b> <i>NEF-ron</i>	A microscopic functional unit of the kidney; working with blood vessels, the nephron filters the blood and balances the composition of urine
<b>renal cortex</b> <i>RE-nal KOR-tex</i>	The kidney's outer portion; contains portions of the nephrons
<b>renal medulla</b> <i>meh-DUL-lah</i>	The kidney's inner portion; contains portions of the nephrons and ducts that transport urine toward the renal pelvis
<b>renal pelvis</b> <i>PEL-vis</i>	The expanded upper end of the ureter that receives urine from the kidney (Greek root <i>pyell/o</i> means "basin")
<b>renal pyramid</b> <i>PERE-ah-mid</i>	A triangular structure in the renal medulla; composed of the nephrons' loops and collecting ducts

(continued)

Terminology	Key Terms (Continued)
<b>renin</b> <i>RE-nin</i>	An enzyme produced by the kidneys that activates angiotensin in the blood
<b>trigone</b> <i>TRI-gone</i>	A triangle at the base of the bladder formed by the openings of the two ureters and the urethra (see <b>FIG. 14-4</b> )
<b>tubular reabsorption</b> <i>TUBE-u-lar re-ab-SORP-shun</i>	The return of substances from the glomerular filtrate to the blood through the peritubular capillaries
<b>urea</b> <i>u-RE-ab</i>	The main nitrogenous (nitrogen-containing) waste product in the urine
<b>ureter</b> <i>U-re-ter</i>	The tube that carries urine from the kidney to the bladder (root: ureter/o)
<b>urethra</b> <i>u-RE-thrah</i>	The duct that carries urine out of the body and also transports semen in the male (root: urethr/o)
<b>urinary bladder</b> <i>u-rib-NAR-e BLAD-der</i>	The organ that stores and eliminates urine excreted by the kidneys (roots: cyst/o, vesic/o)
<b>urination</b> <i>u-rib-NA-shun</i>	The voiding of urine; micturition
<b>urine</b> <i>U-rin</i>	The fluid excreted by the kidneys; it consists of water, electrolytes, urea, other metabolic wastes, and pigments; a variety of other substances may appear in urine in cases of disease (root: ur/o)

## Roots Pertaining to the Urinary System

See **TABLES 14-1** and **14-2**.

Table 14-1		Roots for the Kidney	
Root	Meaning	Example	Definition of Example
ren/o	kidney	suprarenal <i>su-prah-RE-nal</i>	above the kidney
nephro/o	kidney	nephrosis <i>nef-RO-sis</i>	any noninflammatory disease condition of the kidney
glomerul/o	glomerulus	juxtglomerular <i>juks-tah-glo-MER-u-lar</i>	near the glomerulus
pyel/o	renal pelvis	pyelectasis <i>pi-eh-LEK-tah-sis</i>	dilatation of the renal pelvis
cali/o, calic/o	calyx	caliceal <i>kal-ih-SE-al</i>	pertaining to a renal calyx (note addition of <i>e</i> ); also spelled calyceal

## Exercise 14-1

Complete the exercise. To check your answers go to Appendix 11.

Use the root *ren/o* to write a word for the following.

1. before or in front of (pre-) the kidney \_\_\_\_\_
2. behind (post-) the kidney \_\_\_\_\_
3. above the kidneys \_\_\_\_\_
4. around the kidneys \_\_\_\_\_

Use the root *nephr/o* to write a word for the following.

5. the medical specialist who studies the kidney \_\_\_\_\_
6. any disease of the kidney \_\_\_\_\_
7. poisonous or toxic to the kidney \_\_\_\_\_
8. softening of the kidney \_\_\_\_\_
9. enlargement of the kidney \_\_\_\_\_

Use the appropriate root to write a word for the following.

10. incision into the kidney \_\_\_\_\_
11. inflammation of the renal pelvis and kidney \_\_\_\_\_
12. plastic repair of the renal pelvis \_\_\_\_\_
13. radiograph of the renal pelvis \_\_\_\_\_
14. inflammation of a glomerulus \_\_\_\_\_
15. incision of a renal calyx \_\_\_\_\_
16. hardening of a glomerulus \_\_\_\_\_
17. dilatation of a renal calyx \_\_\_\_\_

Table 14-2

Roots for the Urinary Tract (Except the Kidney)

Root	Meaning	Example	Definition of Example
ur/o	urine, urinary tract	urinalysis <i>ur-ib-NAL-ib-sis</i>	laboratory study of urine
urin/o	urine	nocturia <i>nok-TU-re-ab</i>	urination during the night (noct/i)
ureter/o	ureter	ureterostenosis <i>u-re-ter-o-steb-NO-sis</i>	narrowing of the ureter
cyst/o	urinary bladder	cystocele <i>SIS-to-sele</i>	hernia of the urinary bladder
vesic/o	urinary bladder	intravesical <i>in-trah-VES-ib-kal</i>	within the urinary bladder
urethr/o	urethra	urethrotome <i>u-RE-thro-tome</i>	instrument for incising the urethra

## Exercise 14-2

Complete the exercise. To check your answers go to Appendix 11.

Use the root *ur/o* to write a word for the following.

1. any disease of the urinary tract \_\_\_\_\_
2. radiography of the urinary tract \_\_\_\_\_
3. a urinary calculus (stone) \_\_\_\_\_
4. presence of urinary waste products in the blood \_\_\_\_\_

The root *ur/o-* is used in the suffix *-uria*, which means “condition of urine or of urination.” Use *-uria* to write a word for the following.

5. lack of urine \_\_\_\_\_
6. presence of pus in the urine \_\_\_\_\_
7. urination at night \_\_\_\_\_
8. painful or difficult urination \_\_\_\_\_
9. presence of blood (hemat/o) in the urine \_\_\_\_\_

The suffix *-uresis* means “urination.” Use *-uresis* to write a word for the following.

10. increased excretion of urine \_\_\_\_\_
11. lack of urination \_\_\_\_\_
12. excretion of sodium (natri-) in the urine \_\_\_\_\_
13. excretion of potassium (kali-) in the urine \_\_\_\_\_

The adjective ending for the above words is *-uretic*, as in *diuretic* (pertaining to diuresis) and *natriuretic* (pertaining to the excretion of sodium in the urine).

Use the appropriate root to write a word for the following.

14. surgical fixation of the urethra \_\_\_\_\_
15. surgical creation of an opening in the ureter \_\_\_\_\_
16. suture of the urethra \_\_\_\_\_
17. endoscopic examination of the urethra \_\_\_\_\_
18. herniation of the ureter \_\_\_\_\_

Use the root *cyst/o* to write a word for the following.

19. inflammation of the urinary bladder \_\_\_\_\_
20. radiography of the urinary bladder \_\_\_\_\_
21. an instrument for examining the interior of the bladder \_\_\_\_\_
22. incision of the bladder \_\_\_\_\_
23. discharge from the bladder \_\_\_\_\_

Use the root *vesic/o* to write a word for the following.

24. above the urinary bladder \_\_\_\_\_
25. pertaining to the urethra and bladder \_\_\_\_\_

## Exercise 14-2 (Continued)

Define the following terms.

26. cystalgia (*sis-TAL-je-ab*)
27. ureterotomy (*u-re-ter-OT-o-me*)
28. transurethral (*trans-u-RE-thral*)
29. uropoiesis (*u-ro-poy-E-sis*)

---



---



---



---

## Clinical Aspects of the Urinary System

### INFECTIONS

Organisms that infect the urinary tract generally enter through the urethra and ascend toward the bladder, producing **cystitis**. Untreated, the infection can ascend even further into the urinary tract. The infecting organisms are usually colon bacteria carried in feces, particularly *Escherichia coli*. Although urinary tract infections (UTIs) do occur in men, they appear more commonly in women because the female urethra is shorter than the male urethra and its opening is closer to the anus. Poor toilet habits and **urinary stasis** are contributing factors. In hospitals, UTIs may result from procedures involving the urinary system, especially **catheterization**, in which a tube is inserted into the bladder to withdraw urine (FIG. 14-5). Less frequently, UTIs originate in the blood and descend through the urinary system.

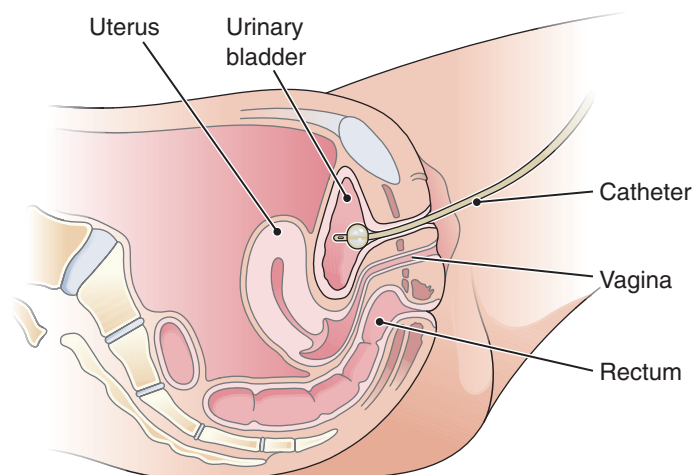
An infection that involves the kidney and renal pelvis is termed **pyelonephritis**. As in cystitis, signs of this condition include **dysuria**, painful or difficult urination, and the

presence of bacteria and pus in the urine, **bacteriuria** and **pyuria**, respectively.

**Urethritis** is inflammation of the urethra, generally associated with sexually transmitted infections such as gonorrhea and chlamydial infections (see Chapter 15).

### GLOMERULONEPHRITIS

Although the name simply means inflammation of the glomeruli and kidney, **glomerulonephritis** is a specific disorder that follows an immunologic reaction. It is usually a response to infection in another system, commonly a streptococcal infection of the respiratory tract or a skin infection. It may also accompany autoimmune diseases such as lupus erythematosus. The symptoms are hypertension, edema, and **oliguria**, the passage of small amounts of urine. This urine is highly concentrated. Because of damage to kidney tissue, blood and proteins escape into the nephrons, causing **hematuria**, blood in the urine, and **proteinuria**, protein in the urine. Blood cells may also form into small molds of the kidney tubule, called **casts**, which can be found in the



**FIGURE 14-5** An indwelling (Foley) catheter. The catheter is shown in place in the female bladder.



urine. Most patients fully recover from glomerulonephritis, but in some cases, especially among the elderly, the disorder may lead to chronic renal failure (CRF) or end-stage renal disease (ESRD). In such cases, urea and other nitrogenous compounds accumulate in the blood, a condition termed **uremia**. These compounds affect the central nervous system, causing irritability, loss of appetite, stupor, and other symptoms. There is also electrolyte imbalance and **acidosis**.

## NEPHROTIC SYNDROME

Glomerulonephritis is one cause of **nephrotic syndrome**, a disease in which the glomeruli become overly permeable and allow the loss of proteins. Other possible causes of nephrotic syndrome are renal vein thrombosis, diabetes, systemic lupus erythematosus, toxins, or any other condition that damages the glomeruli.

Nephrotic syndrome is marked by proteinuria and **hypoproteinemia**, low blood protein. The low plasma protein level affects capillary exchange and results in edema. There is also an increase in blood lipids, as the liver compensates for lost protein by releasing lipoproteins.

## RENAL FAILURE

**Chronic renal failure** results from a gradual loss of nephrons. As more and more nephrons are destroyed, the kidneys slowly lose the ability to perform their normal functions. In many cases, there is a lesser decrease in renal function, known as **renal insufficiency**, that produces fewer symptoms. Injury, shock, exposure to toxins, infections, and other renal disorders may cause sudden damage to the nephrons, resulting in a rapid loss of kidney function, or **acute renal failure (ARF)**. When destruction (necrosis) of kidney tubules is involved, the condition may be referred to as **acute tubular necrosis (ATN)**.

A few of the characteristic signs and symptoms of renal failure are the following:

- **Dehydration** (*de-hi-DRA-shun*). Excessive loss of body fluid may occur early in renal failure, when the kidneys

cannot concentrate the urine and large amounts of water are eliminated.

- **Edema** (*eh-DE-mah*). Accumulation of fluid in the tissue spaces may occur late in chronic renal disease, when the kidneys cannot eliminate water in adequate amounts.
- **Electrolyte imbalance**. The results of such disturbance, as they apply to electrolytes of sodium and potassium, are described in **BOX 14-2**.
- **Hypertension** may occur as the result of sodium and water retention.
- **Anemia** occurs when the kidneys cannot produce the hormone EPO to activate red blood cell production in bone marrow.
- **Uremia** (*u-RE-me-ah*), an excess of nitrogenous waste products in the blood. When these levels are high, urea can be changed into ammonia in the stomach and intestine and cause ulcerations and bleeding.

Renal failure may lead to a need for kidney **dialysis** or, ultimately, **renal transplantation**. Dialysis refers to the movement of substances across a semipermeable membrane; it is a method used to eliminate harmful or unnecessary substances from the body when the kidneys are impaired or have been removed (**FIG. 14-6**). Two approaches are used:

- In **hemodialysis**, blood is cleansed by passage over a membrane surrounded by fluid (dialysate) that draws out unwanted substances. Most people on hemodialysis are treated for 4 hours three times a week in a dialysis center. Some patients are able to use simpler machines at home for daily dialysis. **BOX 14-3** has information on careers in hemodialysis treatment.
- In **peritoneal dialysis**, fluid is introduced into the peritoneal cavity. The fluid, along with waste products, is periodically withdrawn and replaced. Fluid may be exchanged at intervals throughout the day in continuous ambulatory peritoneal dialysis (CAPD) or during the night in continuous cyclic peritoneal dialysis (CCPD).



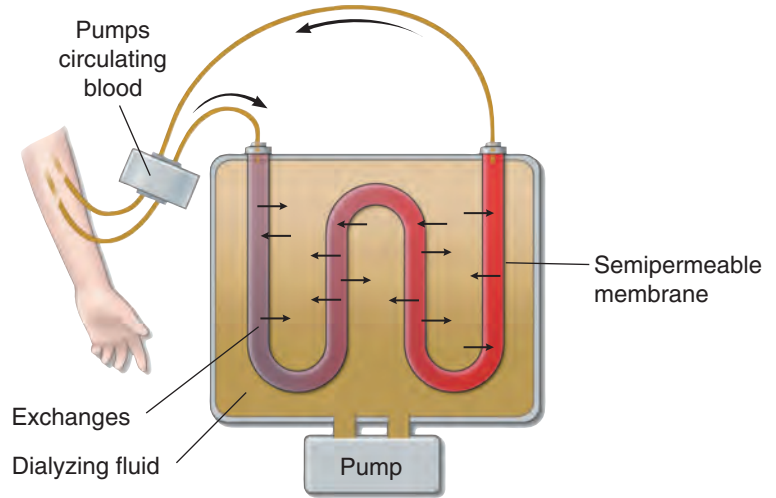
## CLINICAL PERSPECTIVES

### Sodium and Potassium: Causes and Consequences of Imbalance

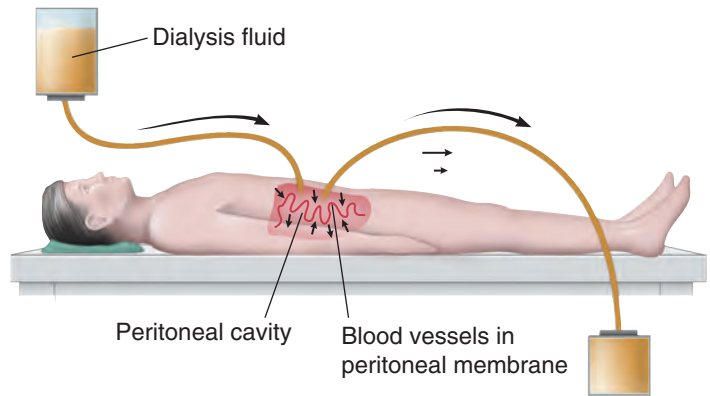
BOX 14-2

Sodium and potassium concentrations in body fluids are important measures of water and electrolyte balance. An excess of sodium in body fluids is termed **hyponatremia**, taken from the Latin name for sodium, *natrium*. This condition accompanies dehydration and severe vomiting and may cause hypertension, edema, convulsions, and coma. **Hyponatremia**, a sodium deficiency in body fluids, can come from water intoxication (overhydration), heart failure, kidney failure, cirrhosis of the liver, pH imbalance, or endocrine disorders. It can cause muscle weakness, hypotension, confusion, shock, convulsions, and coma.

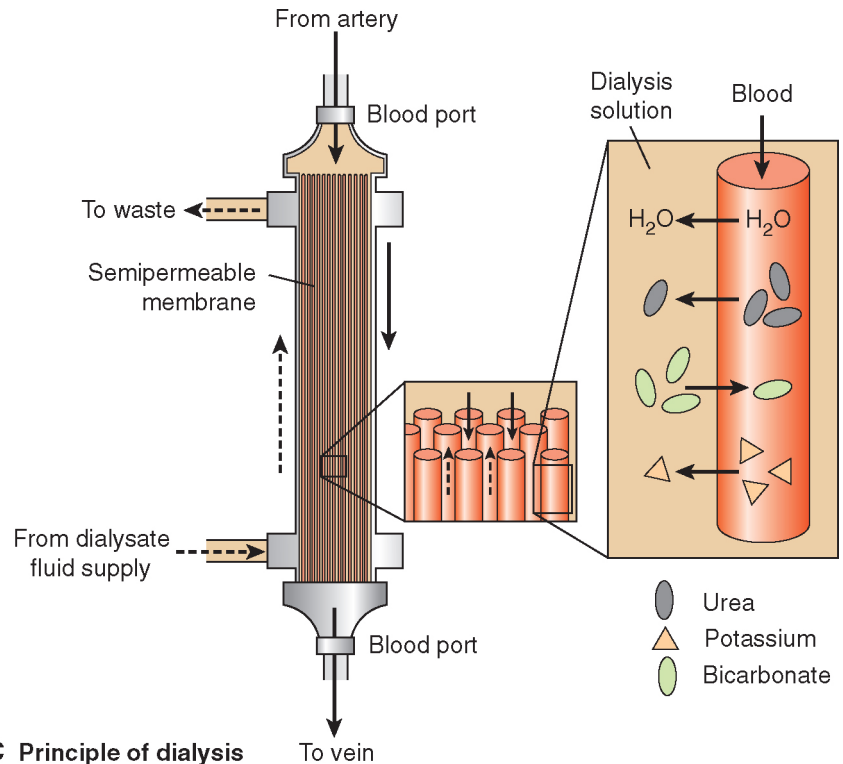
The term **hyperkalemia** is taken from the Latin name for potassium, *kaliium*. It refers to excess potassium in body fluids, which may result from kidney failure, dehydration, and other causes. Its signs and symptoms include nausea, vomiting, muscular weakness, and severe cardiac arrhythmias. **Hypokalemia**, or low potassium in body fluids, may result from taking diuretics that cause potassium to be lost along with water. It may also result from pH imbalance or secretion of too much aldosterone from the adrenal cortex, resulting in potassium excretion. Hypokalemia causes muscle fatigue, paralysis, confusion, hypoventilation, and cardiac arrhythmias.



**A Hemodialysis**



**B Peritoneal dialysis**



**C Principle of dialysis**

**FIGURE 14-6 Dialysis.** A dialyzing fluid (dialysate) draws materials out of the blood through a semipermeable membrane. **A.** Hemodialysis. The patient's blood flows through a dialysis machine. **B.** Peritoneal dialysis. The dialysate is introduced into the peritoneal cavity. The peritoneum acts as the dialysis membrane. **C.** The principle of dialysis. Materials, such as water, electrolytes, and dissolved waste, flow through a semipermeable membrane based on their concentration on either side of the membrane. When kidneys fail, dialysis can restore the blood's proper composition.



## HEALTH PROFESSIONS

### Hemodialysis Technician

BOX 14-3

A hemodialysis technician, also called a renal technician or a nephrology technician, specializes in the safe and effective delivery of renal dialysis therapy to patients suffering from kidney failure. Before treatment begins, the technician prepares the dialysis solutions and ensures that the dialysis machine is clean, sterile, and in proper working order. The technician measures and records the patient's weight, temperature, and vital signs; inserts a catheter into the patient's arm; and connects the dialysis machine to it. During dialysis, the technician monitors the patient for adverse reactions and guards against any equipment malfunction. After the treatment is completed, the technician again measures and

records the patient's weight, temperature, and vital signs. To perform these duties, hemodialysis technicians need thorough scientific and clinical training. Most technicians in the United States receive their training from colleges or technical schools, and many states require that the technician be certified.

Hemodialysis technicians work in a variety of settings, such as hospitals, clinics, and patients' homes. As populations age, the incidence of kidney disease is expected to rise, as will the need for hemodialysis. For more information about this career, contact the American Nephrology Nurses Association (ANNA) at [annanurse.org](http://annanurse.org).

## URINARY STONES

Urinary lithiasis (presence of stones) may be related to infection, irritation, diet, or hormone imbalances that lead to increased calcium in the blood. Most urinary calculi (stones) are made up of calcium salts, but they may be composed of other materials as well. Causes of stone formation include dehydration, infection, abnormal pH of urine, urinary stasis, and metabolic imbalances. The stones generally form in the kidney and may move to the bladder). This results in great pain, termed **renal colic**, and obstruction that can promote infection and cause **hydronephrosis**, collection of urine in the renal pelvis.

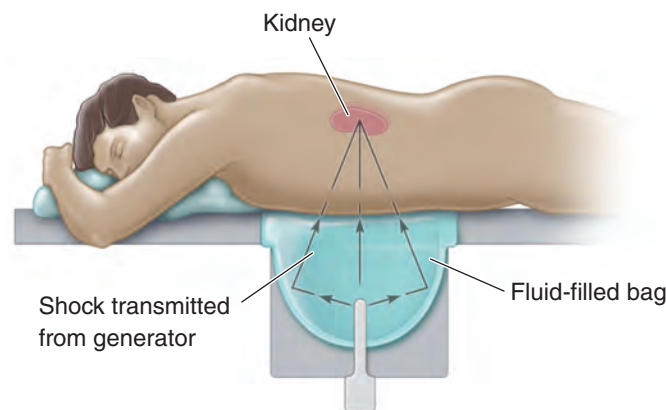
Because they are radiopaque, stones can usually be seen on simple radiographs of the abdomen. Stones may dissolve and pass out of the body on their own. If not, they may be removed surgically, in a **lithotomy**, or by endoscopy.

External shock waves are used to crush stones in the urinary tract in a procedure called extracorporeal (outside the body) shock-wave **lithotripsy** (crushing of stones) (**FIG. 14-7**).

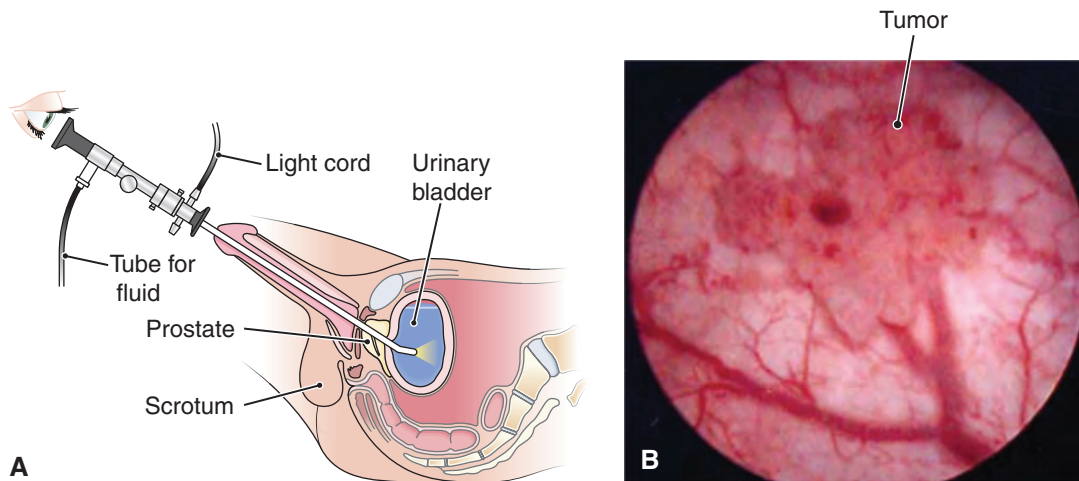
## CANCER

Carcinoma of the bladder has been linked to occupational exposure to chemicals, parasitic infections, and cigarette smoking. A key symptom is sudden, painless hematuria. Often, the cancer can be seen by viewing the bladder lining with a **cystoscope** (**FIG. 14-8**). This instrument can also be used to biopsy tissue for study.

If treatment is not effective in permanently removing the tumor, a **cystectomy** (removal of the bladder) may be necessary. In this case, the ureters must be vented elsewhere, such as directly to the body surface through the ileum in an **ileal conduit** (**FIG. 14-9**), or to some other portion of the intestine.



**FIGURE 14-7 Lithotripsy.** Shock waves are used to break kidney stones and allow for their passage. The procedure is called extracorporeal shock-wave lithotripsy (ESWL).



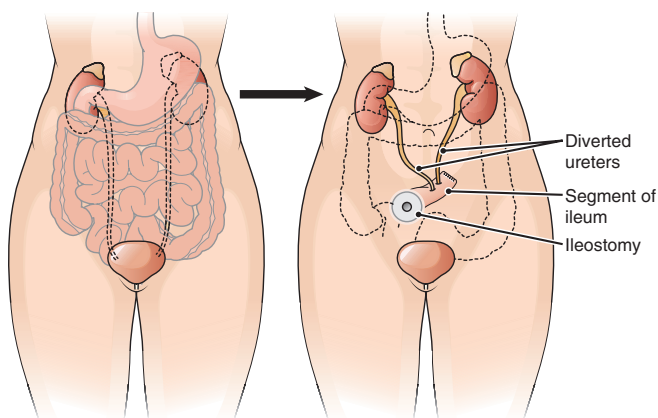
**FIGURE 14-8 Cystoscopy.** **A.** A lighted cystoscope is introduced through the urethra into the bladder of a male subject. Sterile fluid is used to inflate the bladder. Cystoscopes are used to examine the bladder, take biopsy specimens, and remove tumors. **B.** A cancer of the bladder, as viewed through a cystoscope.

Cancer may also involve the kidney and renal pelvis. Additional means for diagnosing cancer and other urinary tract disorders include ultrasound, computed tomography scans, and radiographic studies such as **intravenous urography (IVU)** (FIG. 14-10), also called **intravenous pyelography (IVP)**, and **retrograde pyelography**.

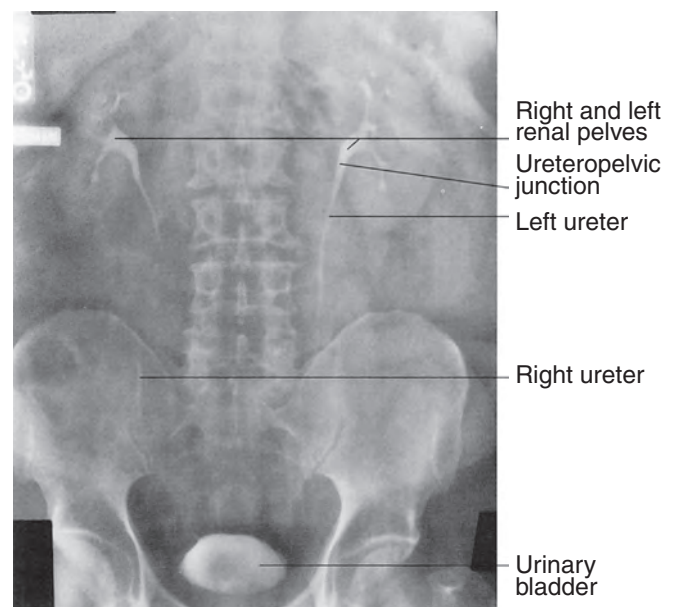
## URINALYSIS

**Urinalysis (UA)** is a simple and widely used method for diagnosing urinary tract disorders. It may also reveal disturbances in other systems when abnormal byproducts are eliminated in the urine. In a routine UA, the urine is grossly

examined for color and turbidity (a sign that bacteria are present); **specific gravity (SG)** (a measure of concentration) and pH are recorded; tests are performed for chemical components such as glucose, ketones, and hemoglobin; and the urine is examined microscopically for cells, crystals, and casts. In more detailed tests, drugs, enzymes, hormones, and other metabolites may be analyzed, and bacterial cultures may be performed.



**FIGURE 14-9 Ileal conduit.** In this surgery, the ureters are vented to the body surface through the ileum when the bladder is removed or nonfunctional.



**FIGURE 14-10 Intravenous urogram.** The image shows the renal pelvis, ureters, and urinary bladder.

## Terminology

## Key Terms

The terms listed below are emphasized in this chapter. Knowing them will help you organize and prioritize your learning. These boldface terms are also found, collectively, with all chapter key terms in the Glossary.

## Disorders

<b>acidosis</b> <i>as-ih-DO-sis</i>	Excessive acidity of body fluids
<b>bacteriuria</b> <i>bak-te-re-U-re-ah</i>	Presence of bacteria in the urine
<b>cast</b>	A solid mold of a renal tubule found in the urine
<b>cystitis</b> <i>sis-TI-tis</i>	Inflammation of the urinary bladder, usually as a result of infection
<b>dysuria</b> <i>dis-U-re-ah</i>	Painful or difficult urination
<b>glomerulonephritis</b> <i>glo-mer-u-lo-nef-RI-tis</i>	Inflammation of the kidney, primarily involving the glomeruli; the acute form usually occurs after an infection elsewhere in the body; the chronic form varies in cause and usually leads to renal failure
<b>hematuria</b> <i>he-mat-U-re-ah</i>	Presence of blood in the urine
<b>hydronephrosis</b> <i>hi-dro-nef-RO-sis</i>	Collection of urine in the renal pelvis caused by obstruction; results in distention and renal atrophy
<b>hypokalemia</b> <i>hi-po-kah-LE-me-ah</i>	Deficiency of potassium in the blood
<b>hyponatremia</b> <i>hi-po-nah-TRE-me-ah</i>	Deficiency of sodium in the blood
<b>hypoproteinemia</b> <i>hi-po-pro-te-NE-me-ah</i>	Decreased amount of protein in the blood; may be caused by kidney damage resulting in protein loss
<b>hyperkalemia</b> <i>hi-per-kah-LE-me-ah</i>	Excess amount of potassium in the blood
<b>hyponatremia</b> <i>hi-per-nah-TRE-me-ah</i>	Excess amount of sodium in the blood
<b>nephrotic syndrome</b> <i>nef-ROT-ik</i>	Condition that results from glomerular damage leading to loss of protein in the urine (proteinuria); there is low plasma protein (hypoproteinemia), edema, and increased blood lipids as the liver releases lipoproteins; also called nephrosis
<b>oliguria</b> <i>ol-ig-U-re-ah</i>	Elimination of small amounts of urine
<b>proteinuria</b> <i>pro-te-NU-re-ah</i>	Presence of protein, mainly albumin, in the urine
<b>pyelonephritis</b> <i>pi-eh-lo-neh-FRI-tis</i>	Inflammation of the renal pelvis and kidney, usually caused by infection
<b>pyuria</b> <i>pi-U-re-ah</i>	Presence of pus in the urine
<b>renal colic</b> <i>KOL-ik</i>	Radiating pain in the region of the kidney associated with the passage of a stone
<b>renal failure</b>	Loss of kidney function resulting from loss or damage to the kidney nephrons. May be chronic, developing over time, or acute, as a result of sudden damage, as by injury, shock, or toxins

**Terminology****Key Terms (Continued)**

<b>uremia</b> <i>u-RE-me-ah</i>	Presence of toxic levels of urea and other nitrogenous substances in the blood as a result of renal insufficiency
<b>urethritis</b> <i>u-re-THRI-tis</i>	Inflammation of the urethra, usually due to infection
<b>urinary stasis</b> <i>STA-sis</i>	Stoppage of urine flow; urinary stagnation
<b>Diagnosis and Treatment</b>	
<b>catheterization</b> <i>kath-eh-ter-ih-ZA-shun</i>	Introduction of a tube into a passage, such as through the urethra into the bladder for withdrawal of urine (see <b>FIG. 14-5</b> )
<b>cystoscope</b> <i>SIS-to-skope</i>	An instrument for examining the interior of the urinary bladder; also used for removing foreign objects, for surgery, and for other forms of treatment
<b>dialysis</b> <i>di-AL-ih-sis</i>	Separation of substances by passage through a semipermeable membrane; dialysis is used to rid the body of unwanted substances when the kidneys are impaired or missing; the two forms of dialysis are hemodialysis and peritoneal dialysis
<b>hemodialysis</b> <i>he-mo-di-AL-ih-sis</i>	Removal of unwanted substances from the blood by passage through a semipermeable membrane (see <b>FIG. 14-6</b> )
<b>intravenous pyelography (IVP)</b> <i>in-trab-VE-nus pi-eh-LOG-rah-fe</i>	Intravenous urography (see <b>FIG. 14-10</b> )
<b>intravenous urography (IVU)</b> <i>in-trab-VE-nus u-ROG-rah-fe</i>	Radiographic visualization of the urinary tract after intravenous administration of a contrast medium that is excreted in the urine; also called excretory urography or intravenous pyelography, although the latter is less accurate because the procedure shows more than just the renal pelvis
<b>lithotripsy</b> <i>LITH-o-trip-se</i>	Crushing of a stone (see <b>FIG. 14-7</b> )
<b>peritoneal dialysis</b> <i>per-ih-to-NE-al di-AL-ih-sis</i>	Removal of unwanted substances from the body by introduction of a dialyzing fluid into the peritoneal cavity followed by removal of the fluid (see <b>FIG. 14-6</b> )
<b>retrograde pyelography</b> <i>RET-ro-grade pi-eh-LOG-rah-fe</i>	Pyelography in which the contrast medium is injected into the kidneys from below by way of the ureters
<b>specific gravity (SG)</b>	The weight of a substance compared with the weight of an equal volume of water; the specific gravity of normal urine ranges from 1.015 to 1.025; this value may increase or decrease with disease
<b>urinalysis (UA)</b> <i>u-rih-NAL-ih-sis</i>	Laboratory study of the urine; physical and chemical properties and microscopic appearance are included
<b>Surgery</b>	
<b>cystectomy</b> <i>sis-TEK-to-me</i>	Surgical removal of all or part of the urinary bladder
<b>ileal conduit</b> <i>IL-e-al KON-du-it</i>	Diversion of urine by connection of the ureters to an isolated segment of the ileum; one end of the segment is sealed, and the other drains through an opening in the abdominal wall (see <b>FIG. 14-9</b> ); a procedure used when the bladder is removed or nonfunctional; also called ileal bladder
<b>lithotomy</b> <i>lith-OT-o-me</i>	Incision of an organ to remove a stone (calculus)
<b>renal transplantation</b>	Surgical implantation of a donor kidney into a patient

## Terminology

## Enrichment Terms

The terms listed below expand on the key terms to increase your knowledge of this chapter topic.

## Normal Structure and Function

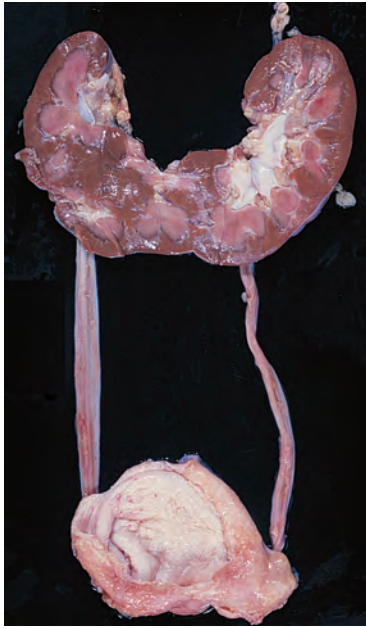<b>aldosterone</b> <i>al-DOS-ter-one</i>	A hormone secreted by the adrenal gland that regulates electrolyte excretion by the kidneys
<b>clearance</b>	The volume of plasma that the kidneys can clear of a substance per unit of time; renal plasma clearance
<b>creatinine</b> <i>kre-AT-in-in</i>	A nitrogenous byproduct of muscle metabolism; an increase in blood creatinine is a sign of renal failure
<b>detrusor muscle</b> <i>de-TRU-sor</i>	The muscle in the bladder wall
<b>glomerular filtration rate (GFR)</b>	The amount of filtrate formed per minute by both kidneys
<b>maximal transport capacity (T<sub>m</sub>)</b>	The maximum rate at which a given substance can be transported across the renal tubule; tubular maximum
<b>renal corpuscle</b> <i>KOR-pus-l</i>	The glomerular capsule and the glomerulus considered as a unit; the filtration device of the kidney
<b>Symptoms and Conditions</b>	
<b>anuresis</b> <i>an-u-RE-sis</i>	Lack of urination
<b>anuria</b> <i>an-U-re-ah</i>	Lack of urine formation
<b>azotemia</b> <i>az-o-TE-me-ah</i>	Presence of increased nitrogenous waste, especially urea, in the blood
<b>azoturia</b> <i>az-o-TU-re-ah</i>	Presence of increased nitrogenous compounds, especially urea, in the urine
<b>cystocele</b> <i>SIS-to-sele</i>	Herniation of the bladder into the vagina (see <b>FIG. 16-12</b> ); vesicocele
<b>dehydration</b> <i>de-hi-DRA-shun</i>	Excessive loss of body fluids
<b>diabetes insipidus</b> <i>di-ab-BE-teze in-SIP-id-us</i>	A condition caused by inadequate production of antidiuretic hormone, resulting in excessive excretion of dilute urine and extreme thirst
<b>enuresis</b> <i>en-u-RE-sis</i>	Involuntary urination, usually at night; bed-wetting
<b>epispadias</b> <i>ep-ih-SPA-de-as</i>	A congenital condition in which the urethra opens on the dorsal surface of the penis as a groove or cleft; anaspadias
<b>glycosuria</b> <i>gli-ko-SU-re-ah</i>	Presence of glucose in the urine, as in cases of diabetes mellitus
<b>horseshoe kidney</b>	A congenital union of the lower poles of the kidneys, resulting in a horseshoe-shaped organ ( <b>FIG. 14-11</b> )
<b>hydroureter</b> <i>hi-dro-u-RE-ter</i>	Distention of the ureter with urine due to obstruction
<b>hypospadias</b> <i>hi-po-SPA-de-as</i>	A congenital condition in which the urethra opens on the undersurface of the penis or into the vagina ( <b>FIG. 14-12</b> )
<b>hypovolemia</b> <i>hi-po-vo-LE-me-ah</i>	A decrease in blood volume
<b>neurogenic bladder</b> <i>nu-ro-JEN-ik</i>	Any bladder dysfunction that results from a central nervous system lesion

## Terminology

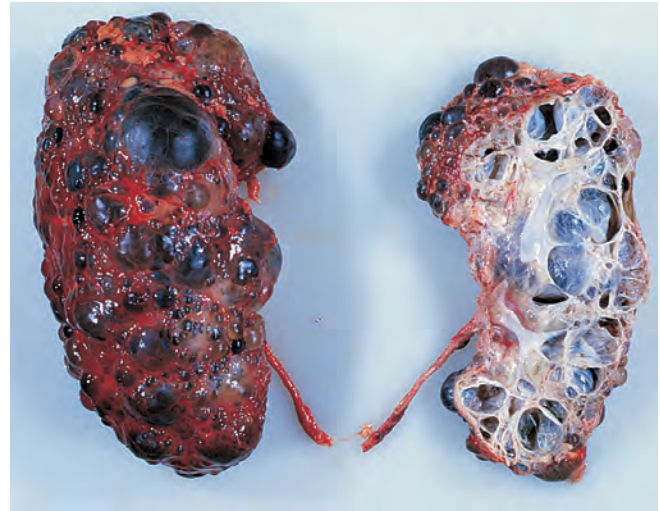## Enrichment Terms (Continued)

<b>nocturia</b> <i>nok-TU-re-ah</i>	Excessive urination at night (root: noct/o means “night”)
<b>polycystic kidney disease</b> <i>pol-e-SIS-tik</i>	A hereditary condition in which the kidneys are enlarged and contain many cysts (FIG. 14-13)
<b>polydipsia</b> <i>pol-e-DIP-se-ah</i>	Excessive thirst
<b>polyuria</b> <i>pol-e-U-re-ah</i>	Elimination of large amounts of urine, as in diabetes mellitus
<b>retention of urine</b>	Accumulation of urine in the bladder because of an inability to urinate
<b>staghorn calculus</b>	A kidney stone that fills the renal pelvis and calices to give a “staghorn” appearance (FIG. 14-14)
<b>ureterocele</b> <i>u-RE-ter-o-sele</i>	A cyst-like dilatation of the ureter near its opening into the bladder; usually results from a congenital narrowing of the ureteral opening (FIG. 14-15)
<b>urinary frequency</b>	A need to urinate often without an increase in average output
<b>urinary incontinence</b> <i>in-KON-tin-ens</i>	Inability to retain urine; may originate with a neurologic disorder, trauma to the spinal cord, weakness of the pelvic muscles, urinary retention, or impaired bladder function; in urgency incontinence, an urge causes sudden urination before one has enough time to reach a bathroom; in stress incontinence, urine leaks during a forceful activity such as coughing, sneezing, or exercise
<b>urinary urgency</b>	Sudden need to urinate
<b>water intoxication</b> <i>in-tok-sib-KA-shun</i>	Excess intake or retention of water with decrease in sodium concentration; may result from excess drinking, excess ADH, or replacement of a large amount of body fluid with pure water; causes an imbalance in the cellular environment, with edema and other disturbances; also called hyponatremia
<b>Wilms tumor</b>	A malignant kidney tumor that usually appears in children before the age of 5 years
<b>Diagnosis</b>	
<b>anion gap</b> <i>AN-i-on</i>	A measure of electrolyte imbalance
<b>blood urea nitrogen (BUN)</b>	Nitrogen in the blood in the form of urea; an increase in BUN indicates an increase in nitrogenous waste products in the blood and renal failure
<b>clean-catch specimen</b>	A urine sample obtained after thorough cleansing of the urethral opening and collection in midstream to minimize the chance of contamination
<b>cystometry</b> <i>sis-to-meh-TROG-rah-fe</i>	A study of bladder function in which the bladder is filled with fluid or air and the pressure exerted by the bladder muscle at varying degrees of filling is measured; the tracing recorded is a cystometrogram
<b>protein electrophoresis (PEP)</b>	Laboratory study of urinary proteins; used to diagnose multiple myeloma, systemic lupus erythematosus, and lymphoid tumor
<b>urinometer</b> <i>u-rib-NOM-eb-ter</i>	Device for measuring the specific gravity of urine
<b>Treatment</b>	
<b>indwelling Foley catheter</b>	A urinary tract catheter with a balloon at one end that prevents the catheter from leaving the bladder (see FIG. 14-5)
<b>lithotrite</b> <i>LITH-o-trite</i>	Instrument for crushing a bladder stone

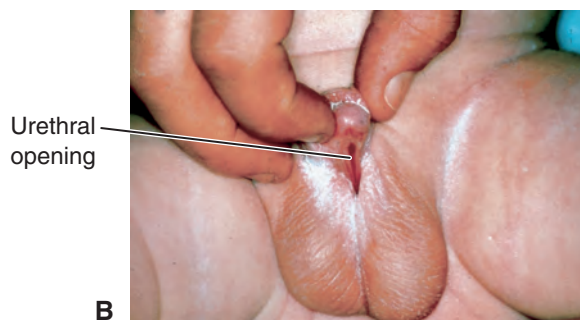
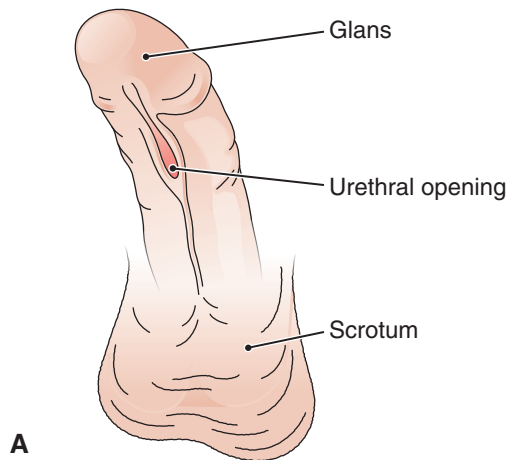




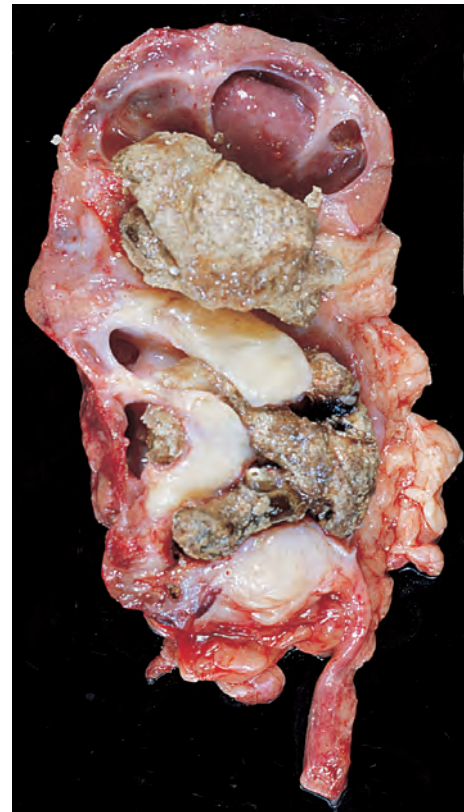**FIGURE 14-11 Horseshoe kidney.** The photograph shows the kidneys fused at the poles.



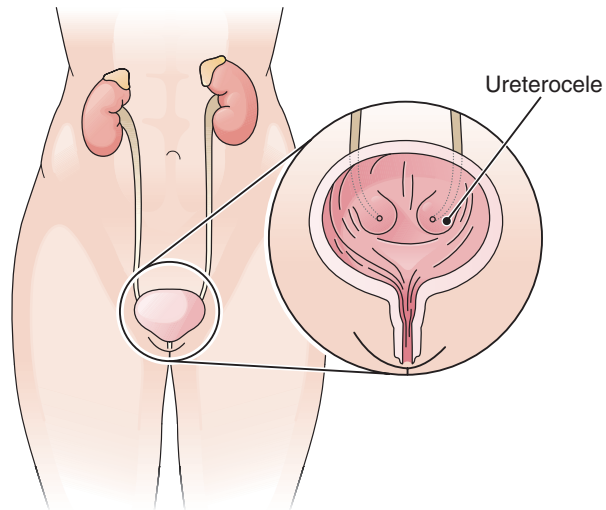
**FIGURE 14-13 Adult polycystic disease.** The kidney is enlarged, and the active tissue is almost entirely replaced by cysts of varying size. (Left) Surface view. (Right) Longitudinal section.



**FIGURE 14-12 Hypospadias.** **A.** The urethra is shown opening on the ventral surface of the penis. **B.** In this photo of a baby with hypospadias, the urethral opening is on the scrotum.



**FIGURE 14-14 Staghorn calculus.** The kidney shows hydronephrosis and stones that are casts of the dilated calyces.



**FIGURE 14-15 Ureterocele.** The ureter bulges into the bladder. The resulting obstruction causes urine to reflux into the ureter (hydroureter) and renal pelvis (hydronephrosis).

## Terminology

## Abbreviations

The abbreviations listed below are emphasized in this chapter. These are also found, collectively, with all chapter abbreviations in Appendix 2.

<b>ACE</b>	Angiotensin-converting enzyme
<b>ADH</b>	Antidiuretic hormone
<b>ARF</b>	Acute renal failure
<b>ATN</b>	Acute tubular necrosis
<b>BUN</b>	Blood urea nitrogen
<b>CAPD</b>	Continuous ambulatory peritoneal dialysis
<b>CCPD</b>	Continuous cyclic peritoneal dialysis
<b>CMG</b>	Cystometrography; cystometrogram
<b>CRF</b>	Chronic renal failure
<b>EPO</b>	Erythropoietin
<b>ESRD</b>	End-stage renal disease
<b>ESWL</b>	Extracorporeal shock-wave lithotripsy

<b>GFR</b>	Glomerular filtration rate
<b>GU</b>	Genitourinary
<b>IVP</b>	Intravenous pyelography
<b>IVU</b>	Intravenous urography
<b>K</b>	Potassium
<b>KUB</b>	Kidney–ureter–bladder (radiography)
<b>Na</b>	Sodium
<b>PEP</b>	Protein electrophoresis
<b>SG</b>	Specific gravity
<b>Tm</b>	Maximal transport capacity
<b>UA</b>	Urinalysis
<b>UTI</b>	Urinary tract infection

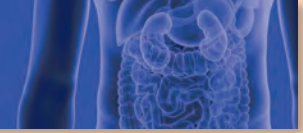## Case Study Revisited

### Jade's Follow-Up Study

At her 3-month follow-up appointment Jade had excellent results from the implanted autograft of her skeletal muscle stem cells. There was no retention of urine, and the incontinence and urgency had all but disappeared. Jade's urologist explained that the use of stem cells in the field of regenerative medicine has emerged in the last few years due to their capacity to restore and maintain normal function via direct effects on injured or dysfunctional tissues (as in Jade's case). The urologist further explained that the procedure that Jade received

via the clinical study was proving to be a viable option for improving issues surrounding urethral sphincter muscle deficiency and damage.

After a year, Jade continues to experience 95% success rate from her stress incontinence and her quality of life has improved. She regularly participates in her favorite athletic activities without the worry of stress incontinence. She continues to schedule her follow-up appointments with her urologist and follows the strict guidelines for her participation in the clinical research study.



This review tests your understanding of the content introduced in this chapter. Follow the instructions for each exercise and check your answers in Appendix 11.

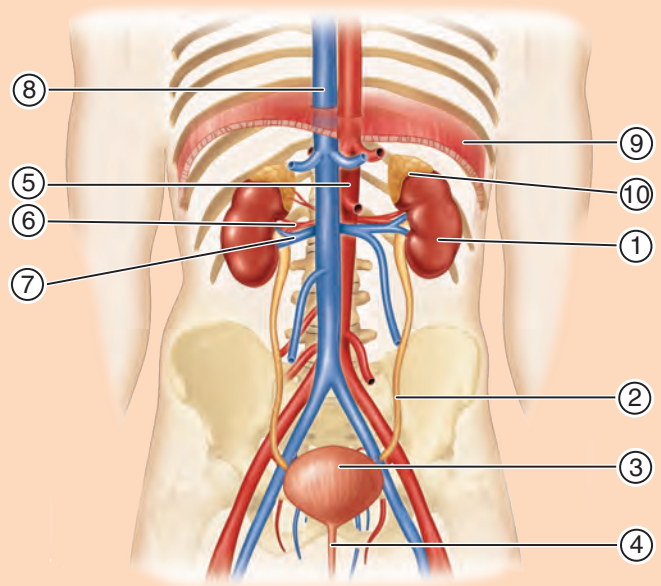
### LABELING EXERCISE

#### THE URINARY SYSTEM

Write the name of each numbered part on the corresponding line.

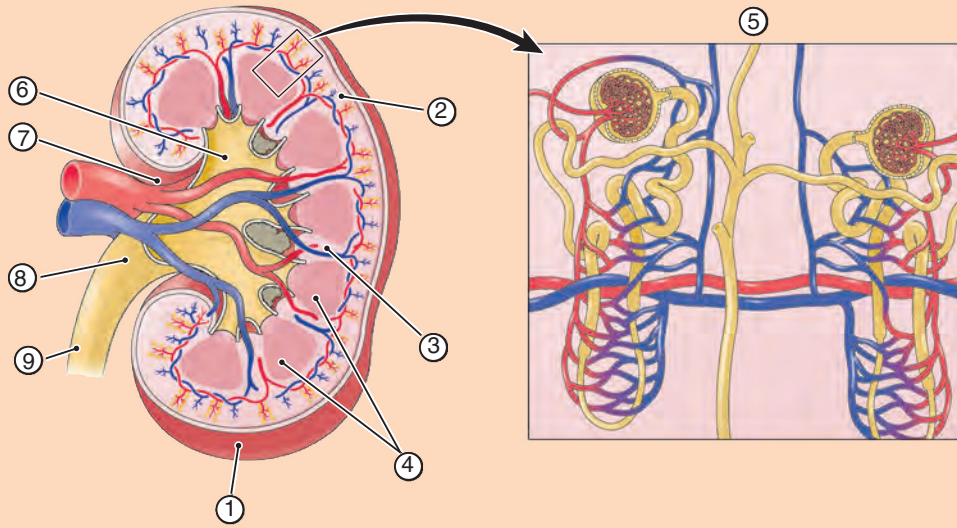
- |                    |                 |
|--------------------|-----------------|
| Adrenal gland      | Renal artery    |
| Aorta              | Renal vein      |
| Diaphragm          | Ureter          |
| Inferior vena cava | Urethra         |
| Kidney             | Urinary bladder |

1. \_\_\_\_\_
2. \_\_\_\_\_
3. \_\_\_\_\_
4. \_\_\_\_\_
5. \_\_\_\_\_
6. \_\_\_\_\_
7. \_\_\_\_\_
8. \_\_\_\_\_
9. \_\_\_\_\_
10. \_\_\_\_\_



**KIDNEY**

Write the name of each numbered part on the corresponding line.



- |          |                     |              |
|----------|---------------------|--------------|
| Calyx    | Pyramids of medulla | Renal pelvis |
| Hilum    | Renal capsule       | Renal cortex |
| Nephrons | Renal medulla       | Ureter       |

1. \_\_\_\_\_
2. \_\_\_\_\_
3. \_\_\_\_\_
4. \_\_\_\_\_
5. \_\_\_\_\_

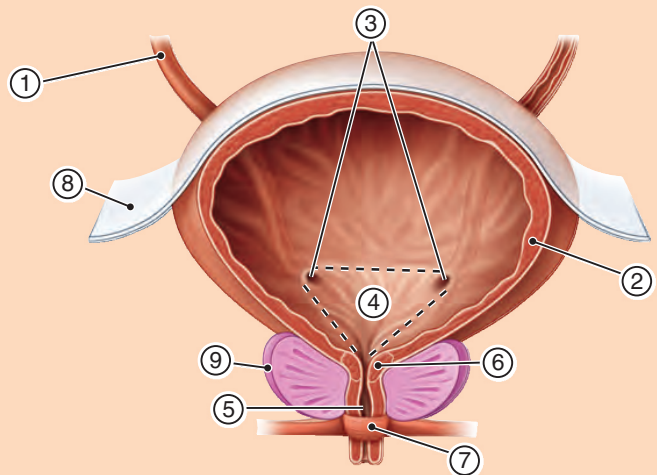
6. \_\_\_\_\_
7. \_\_\_\_\_
8. \_\_\_\_\_
9. \_\_\_\_\_

**URINARY BLADDER**

Write the name of each numbered part on the corresponding line.

- |                             |               |
|-----------------------------|---------------|
| External urethral sphincter | Smooth muscle |
| Internal urethral sphincter | Trigone       |
| Openings of ureters         | Ureter        |
| Peritoneum                  | Urethra       |
| Prostate                    |               |

1. \_\_\_\_\_
2. \_\_\_\_\_
3. \_\_\_\_\_
4. \_\_\_\_\_
5. \_\_\_\_\_
6. \_\_\_\_\_
7. \_\_\_\_\_
8. \_\_\_\_\_
9. \_\_\_\_\_



## TERMINOLOGY

### MATCHING

Match the following terms, and write the appropriate letter to the left of each number.

- |                       |  |
|-----------------------|--|
| _____ 1. hematuria    | a. blood in the urine                        |
| _____ 2. oliguria     | b. proteinuria                               |
| _____ 3. chromaturia  | c. elimination of small amounts of urine     |
| _____ 4. albuminuria  | d. abnormal color of urine                   |
| _____ 5. pyuria       | e. pus in the urine                          |
| _____ 6. renal cortex | a. absence of a bladder                      |
| _____ 7. nephron      | b. stagnation, as of urine                   |
| _____ 8. stasis       | c. deficiency of urine                       |
| _____ 9. acystia      | d. kidney's outer portion                    |
| _____ 10. uropenia    | e. microscopic functional unit of the kidney |

### Enrichment Terms

- |                                      |   |
|--------------------------------------|---|
| _____ 11. aldosterone                | a. amount of filtrate formed per minute by the kidney |
| _____ 12. diabetes insipidus         | b. condition caused by lack of ADH                    |
| _____ 13. incontinence               | c. nitrogenous metabolic waste                        |
| _____ 14. glomerular filtration rate | d. hormone that regulates electrolytes                |
| _____ 15. creatinine                 | e. inability to retain urine                          |
| _____ 16. polydipsia                 | a. excessive thirst                                   |
| _____ 17. enuresis                   | b. bed-wetting  |
| _____ 18. azoturia                   | c. presence of excess nitrogenous waste in the urine  |
| _____ 19. anuresis                   | d. congenital misplacement of the ureteral opening    |
| _____ 20. hypospadias                | e. lack of urination                                  |

### FILL IN THE BLANKS

Complete the sentence with the correct term(s).

21. Collection of urine in the renal pelvis is a result of obstruction \_\_\_\_\_.
22. The cluster of capillaries within the glomerular capsule is the \_\_\_\_\_.
23. An enzyme released by the kidneys that acts to increase blood pressure is \_\_\_\_\_.
24. Micturition is the scientific term for \_\_\_\_\_.
25. Laboratory study of the urine is a(n) \_\_\_\_\_.
26. The main nitrogenous waste product in urine is \_\_\_\_\_.

Refer to Jade's opening case study.

27. Jade's inability to retain urine is termed urinary \_\_\_\_\_.
28. A midstream urine sample collected after thorough cleansing of the urethral opening is called a(n) \_\_\_\_\_.
29. Endoscopic examination of the urinary bladder is termed \_\_\_\_\_.

**TRUE-FALSE**

Examine the following statements. If the statement is true, write T in the first blank. If the statement is false, write F in the first blank, and correct the statement by replacing the underlined word in the second blank.

	True or False	Correct Answer
30. A reniform structure is shaped like the <u>bladder</u> .	_____	_____
31. Pyelitis is inflammation of the <u>renal pelvis</u> .	_____	_____
32. A nephrotropic substance acts on the <u>kidney</u> .	_____	_____
33. The inner portion of the kidney is the <u>cortex</u> .	_____	_____
34. The tube that carries urine out of the body is the <u>ureter</u> .	_____	_____
35. EPO stimulates the production of <u>red blood cells</u> .	_____	_____
36. A lithotomy is an incision to remove a <u>calculus</u> .	_____	_____
37. Natriuresis refers to the excretion of <u>potassium</u> in the urine.	_____	_____

**DEFINITIONS**

Define the following words.

38. urethrostenosis (*u-re-thro-steh-NO-sis*) \_\_\_\_\_
39. polyuria (*pol-e-U-re-ah*) \_\_\_\_\_
40. nephrotoxic (*nef-ro-TOK-sik*) \_\_\_\_\_
41. juxtaglomerular (*juks-tah-glo-MER-u-lar*) \_\_\_\_\_
42. calicectomy (*kal-ih-SEK-to-me*) \_\_\_\_\_
43. pararenal (*par-ah-RE-nal*) \_\_\_\_\_

Write a word for the following definitions.

44. Physician who specializes in the kidney (nephro) \_\_\_\_\_
45. Dilatation of the renal pelvis and calices \_\_\_\_\_
46. Softening of a kidney (nephro) \_\_\_\_\_
47. Incision of the bladder (cyst/o) \_\_\_\_\_
48. Any disease of the kidney (nephro) \_\_\_\_\_
49. Radiograph of the bladder (cyst/o) and urethra \_\_\_\_\_
50. Plastic repair of a ureter and renal pelvis \_\_\_\_\_
51. Inflammation of the renal pelvis and the kidney \_\_\_\_\_
52. Surgical creation of an opening between a ureter and the sigmoid colon \_\_\_\_\_

**ELIMINATIONS**

*In each of the sets below, underline the word that does not fit in with the rest and explain the reason for your choice.*

53. capsule — cast — pyramid — nephron — cortex

---

54. nephron loop — distal convoluted tubule — glomerular capsule — calyx — proximal convoluted tubule

---

55. ileal conduit — specific gravity — dialysis — cystoscopy — lithotripsy

---

**OPPOSITES**

*Write a word that means the opposite of the following.*

56. dehydration

---

57. hypovolemia

---

58. diuretic

---

59. hyponatremia

---

60. uresis

---

**ADJECTIVES**

*Write the adjective form of the following.*

61. ureter

---

62. nephrology

---

63. uremia

---

64. diuresis

---

65. nephrosis

---

66. calyx

---

67. urethra

---

**PLURALS**

*Write the plural form of the following.*

68. pelvis

---

69. calyx

---

70. glomerulus

---

**FOLLOW THE FLOW**

*Describing the pathway of urine flow, put the following steps in the correct order by placing the letters “A” through “G” in the space provided.*

\_\_\_ 71. Fluid or glomerular filtrate enters the nephron

\_\_\_ 72. Urine flows into the collecting ducts to be eliminated

\_\_\_ 73. Urine flows from the ureters to the bladder

\_\_\_ 74. Tubular reabsorption, or return process of nutrients, water, and electrolytes, occurs

\_\_\_ 75. Blood flows through the glomerulus

\_\_\_ 76. Urine is drained from the renal pelvis to the ureters

\_\_\_ 77. Urine flows from the bladder to the urethra

**WORD BUILDING**

Write a word for the following definitions using the word parts given. Each word part can be used more than once.

graph-	ren/o	-al	intra-	vesic/o	-y	ur/o	inter-	lith	log	supra-
--------	-------	-----	--------	---------	----	------	--------	------	-----	--------

78. radiographic study of the urinary tract \_\_\_\_\_
79. pertaining to the kidney \_\_\_\_\_
80. within the kidney \_\_\_\_\_
81. radiographic study of the kidney \_\_\_\_\_
82. within the bladder \_\_\_\_\_
83. above the kidney \_\_\_\_\_
84. study of the urinary tract \_\_\_\_\_
85. between the kidneys \_\_\_\_\_
86. pertaining to the bladder \_\_\_\_\_
87. a urinary tract stone \_\_\_\_\_

**ABBREVIATIONS**

Write the meaning of the following abbreviations.

88. SG \_\_\_\_\_
89. ADH \_\_\_\_\_
90. EPO \_\_\_\_\_
91. IVP \_\_\_\_\_
92. Na \_\_\_\_\_
93. GFR \_\_\_\_\_
94. UA \_\_\_\_\_

**WORD ANALYSIS**

Define the following words, and give the meaning of the word parts in each. Use a dictionary if necessary.

95. hemodialysis (*he-mo-di-AL-ih-sis*)
  - a. hem/o \_\_\_\_\_
  - b. dia- \_\_\_\_\_
  - c. lysis \_\_\_\_\_
96. cystometrography (*sis-to-meh-TROG-rah-fe*)
  - a. cyst/o \_\_\_\_\_
  - b. metr/o \_\_\_\_\_
  - c. -graphy \_\_\_\_\_
97. ureteroneocystostomy (*u-re-ter-o-ne-o-sis-TOS-to-me*)
  - a. ureter/o \_\_\_\_\_
  - b. neo- \_\_\_\_\_
  - c. cyst/o \_\_\_\_\_
  - d. -stomy \_\_\_\_\_



## Additional Case Studies

### Case Study 14-1: Renal Calculi

Helen, a 48 y/o woman, was admitted to the inpatient unit from the ED with severe right flank pain unresponsive to analgesics. Her pain did not decrease with administration of 100 mg of IV meperidine. She had a 3-month history of chronic UTI. She had been prescribed calcium supplements for low bone density 6 months ago. Her gynecologist warned her that calcium could be a problem for people who are “stone formers.” Helen was unaware that she might be at risk. An IV urogram showed a right staghorn calculus. The diagnosis was further confirmed by a renal ultrasound. A renal flow scan showed normal perfusion and no obstruction. Kidney function was 37% on the right and 63% on the

left. The pain became intermittent, and Helen had no hematuria, dysuria, frequency, urgency, or nocturia. Urinalysis revealed no albumin, glucose, bacteria, or blood; there was evidence of cells, crystals, and casts.

Helen was transferred to surgery for a cystoscopic ureteral laser lithotripsy, insertion of a right retrograde ureteral catheter, and right percutaneous nephrolithotomy. A ureteral calculus was fragmented with a pulsed-dye laser. Most of the staghorn was removed from the renal pelvis with no remaining stone in the renal calices. She was discharged 2 days later and ordered to strain her urine for the next week for evidence of stones.

### Case Study 14-1 Questions

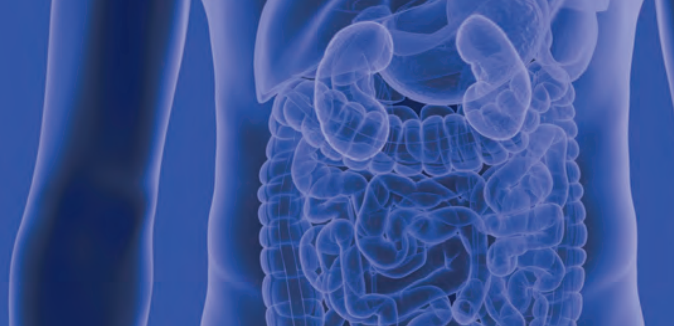**Multiple Choice.** Select the best answer, and write the letter of your choice to the left of each number.

- \_\_\_\_\_ 1. The term *perfusion* means
- a. metabolism
  - b. size
  - c. passage of fluid
  - d. surrounding tissue

- \_\_\_\_\_ 2. The term *percutaneous* means
- a. under the skin
  - b. on the surface
  - c. with a catheter
  - d. through the skin

Write a term from the case study with the following meanings.

3. Intravenous injection of contrast dye and radiographic study of the urinary tract \_\_\_\_\_
4. Presence of blood in the urine \_\_\_\_\_
5. Referring to endoscopy of the urinary bladder \_\_\_\_\_
6. Surgical incision for removal of a kidney stone \_\_\_\_\_
7. Getting up to go to the bathroom at night \_\_\_\_\_
8. Crushing a stone \_\_\_\_\_



## Case Study 14-2: End-Stage Renal Disease

Adrien, a 20 y/o part-time college student, has had chronic glomerulonephritis since age 7. He has been treated at home with CAPD for the past 16 months as he awaits kidney transplantation. His doctor advised him to go immediately to the ED when he reported chest pain, shortness of breath, and oliguria. On admission, Adrien was placed on oxygen and given a panel of blood tests and an ECG to rule out an acute cardiac episode. His hemoglobin was 8.2, and his hematocrit was 26%. He

had bilateral lung rales. ABGs were: pH, 7.0;  $Paco_2$ , 28;  $Pao_2$ , 50;  $HCO_3$ , 21. His BUN, serum creatinine, and BUN/creatinine ratio were abnormally high. His ECG and liver enzyme studies were normal. His admission diagnosis was ESRD, fluid overload, and metabolic acidosis. He was typed and crossed for blood; tested for HIV, hepatitis B antigen, and sexually transmitted disease; and sent for hemodialysis. A bed was reserved for him on the transplant unit.

14

### Case Study 14-2 Questions

**Multiple Choice.** Select the best answer, and write the letter of your choice to the left of each number.

- |  |  |
|--|--|
| <p>_____ 1. Adrien's chronic glomerulonephritis means that he has had</p> <ul style="list-style-type: none"><li>a. long-term kidney stones</li><li>b. an acute bout of kidney infection</li><li>c. short-term bladder inflammation</li><li>d. a long-term kidney infection</li></ul> | <p>_____ 2. Renal dialysis can be performed by shunting venous blood through a dialysis machine and returning the blood to the patient's arterial system. This procedure is called</p> <ul style="list-style-type: none"><li>a. hemodialysis</li><li>b. arteriovenous transplant</li><li>c. CAPD</li><li>d. glomerular filtration rate</li></ul> |
|--|--|

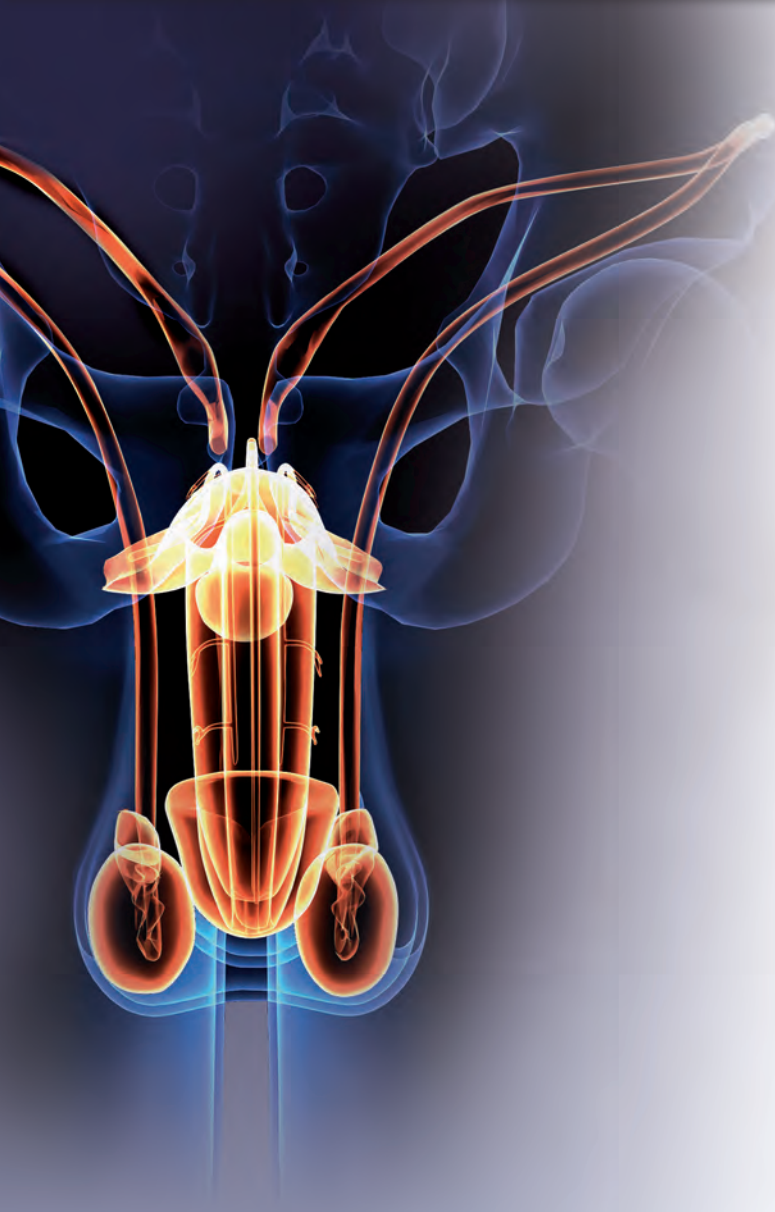
Write a term from the case study with the following meanings.

3. Production of a reduced amount of urine \_\_\_\_\_
4. Kidney replacement \_\_\_\_\_

Define the following abbreviations.

5. CAPD \_\_\_\_\_
6. BUN \_\_\_\_\_
7. ESRD \_\_\_\_\_
8. HIV \_\_\_\_\_

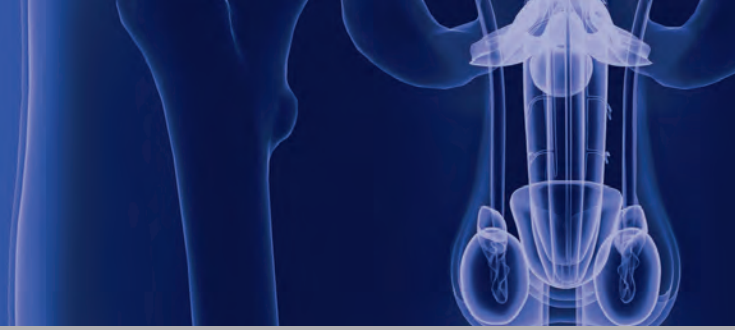# Male Reproductive System



## Pretest

**Multiple Choice.** Select the best answer, and write the letter of your choice to the left of each number. To check your answers go to Appendix 11.

- \_\_\_\_\_ 1. The male germ cell, or gamete, is the
  - a. ovum
  - b. testis
  - c. spermatozoon
  - d. semen
- \_\_\_\_\_ 2. Gametes develop in a gonad, which in males is called the
  - a. vas deferens
  - b. seminal vesicle
  - c. penis
  - d. testis
- \_\_\_\_\_ 3. The main male sex hormone is
  - a. testosterone
  - b. renin
  - c. estrogen
  - d. amylase
- \_\_\_\_\_ 4. The secretion that transports gametes in males is
  - a. bile
  - b. semen
  - c. urine
  - d. pepsin
- \_\_\_\_\_ 5. The gland below the bladder in males is the
  - a. scrotum
  - b. prostate
  - c. adrenal
  - d. parotid
- \_\_\_\_\_ 6. Orchitis is inflammation of the
  - a. bladder
  - b. kidney
  - c. penis
  - d. testis



## Learning Objectives

After careful study of this chapter, you should be able to:

- 1 Describe the organs of the male reproductive tract, and give the function of each part. **P490**
- 2 Follow spermatozoa from their development in the testis to their release. **P490**
- 3 Describe the contents and functions of semen. **P492**
- 4 Identify and use roots pertaining to the male reproductive system. **P494**
- 5 Describe six main disorders of the male reproductive system. **P496**
- 6 Interpret abbreviations used in referring to the male reproductive system. **P502**
- 7 Analyze medical terms in several case studies concerning the male reproductive system. **PP489, 508**



## Case Study: Dexter's Benign Prostatic Hyperplasia and TURP

### Chief Complaint

Dexter, a 60 y/o teacher, was having a decreased force of his urine stream and ejaculation, hesitancy, and sensation of incomplete bladder emptying. He had tried using prostate-health herbal supplements without any real benefit for 2 years. He decided to make an appointment with a urologist.

### Examination

The urologist took a history and examined the patient. Dexter reported no dysuria, hematuria, or flank pain. He had no history of UTI, epididymitis, prostatitis, renal disease, or renal calculi. His medical history was otherwise not significant to his urologic complaint.

Rectal examination revealed a 50-g prostate with slight firmness in the right prostatic lobe. The physician ordered a bladder ultrasound, which was performed later that week. The results indicated no intravesical lesions or prostate protrusion into the bladder base.

A transabdominal ultrasound was ordered and showed a residual urine volume of 120 mL. A urinalysis revealed normal values except for the following: WBC = 8; RBC = 10; bacteria = trace.

Dexter was diagnosed with benign prostatic hyperplasia (BPH) with bladder neck obstruction and was

scheduled for a transurethral resection of the prostate (TURP). His urologist explained the procedure and what to expect pre- and postoperatively. The office staff notified the hospital to schedule the surgery. The next day, the hospital admissions department called Dexter, went through normal admissions procedures, and scheduled a surgery date.

### Clinical Course

Dexter was NPO the night before the surgery. He was taken to the operating room and was given a spinal anesthetic for the procedure. It had already been explained to him that the surgery would take about an hour and that he would be awake during the procedure but would not feel any pain. A resectoscope was used to trim the enlarged prostatic tissue. At the end of the surgery, a Foley catheter was inserted into the bladder and left in place to drain the urine and permit irrigation of the bladder to remove any clots. Dexter tolerated the procedure well and was transferred to the recovery room and later to his hospital room. He was encouraged to drink plenty of fluids postoperatively.

**Case Study Revisited: Once you complete this chapter, please review the case follow-up on p. 502.**

## Ancillaries *At-A-Glance*

Visit the web resource to access the following resources.

### Learning Resources

- eBook
- A&P Module with Heart & Lung Sounds
- Image Bank

- TestPrep
- Animations
- Audio Pronunciation Glossary

## Introduction

The function of the **gonads** (sex glands) in both males and females is to produce the reproductive cells, the **gametes**, and to produce hormones. The gametes are generated by **meiosis**, a process of cell division that halves the chromosome number from 46 to 23. When male and female gametes unite in fertilization, the original chromosome number is restored.

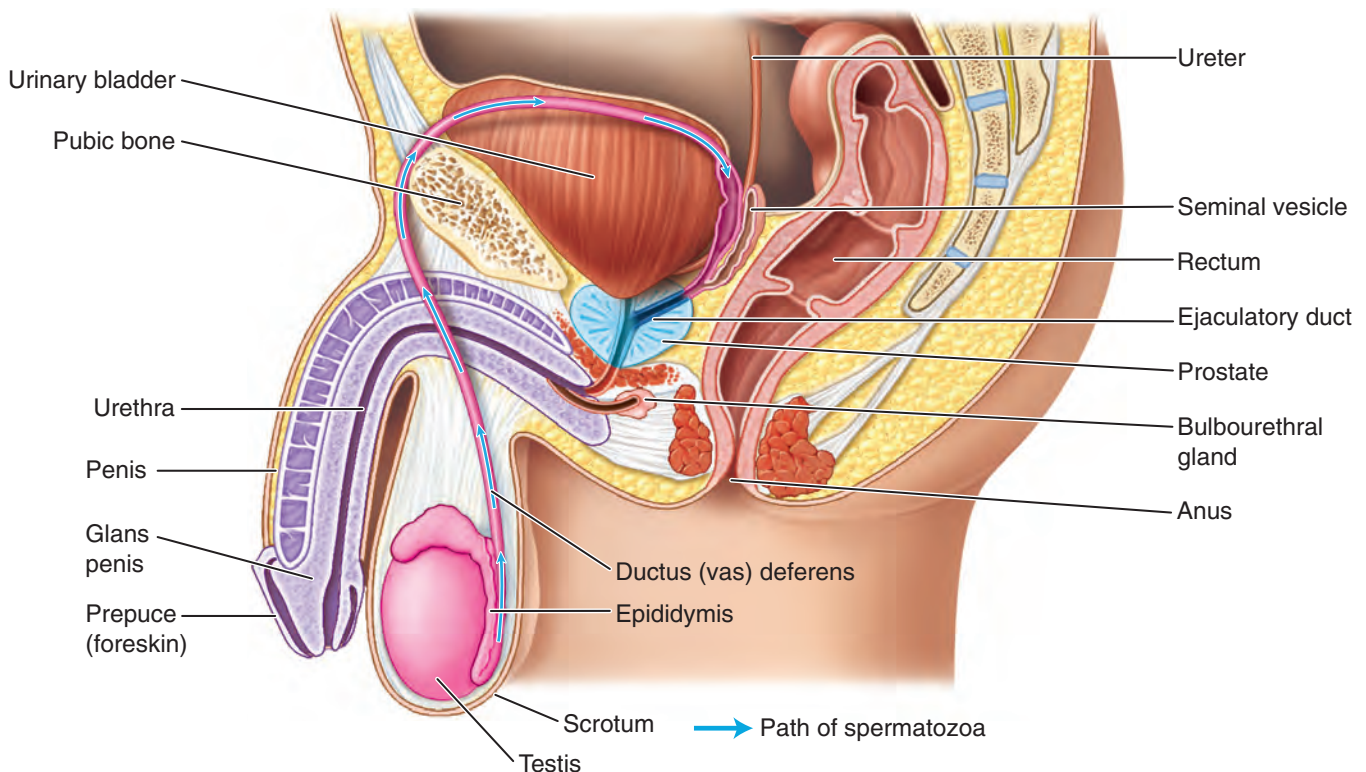
Sex hormones aid in the manufacture of gametes, function in pregnancy and lactation, and also produce the secondary sex characteristics such as the typical size, shape, body hair, and voice that we associate with the male and female genders.

The reproductive tract develops in close association with the urinary tract. In females, the two systems become completely separate, whereas the male reproductive and urinary tracts share a common passage, the **urethra**. Thus, the two systems are referred together as the genitourinary (GU) or urogenital (UG) tract, and urologists are called on to treat disorders of the male reproductive system as well as those of the urinary system.

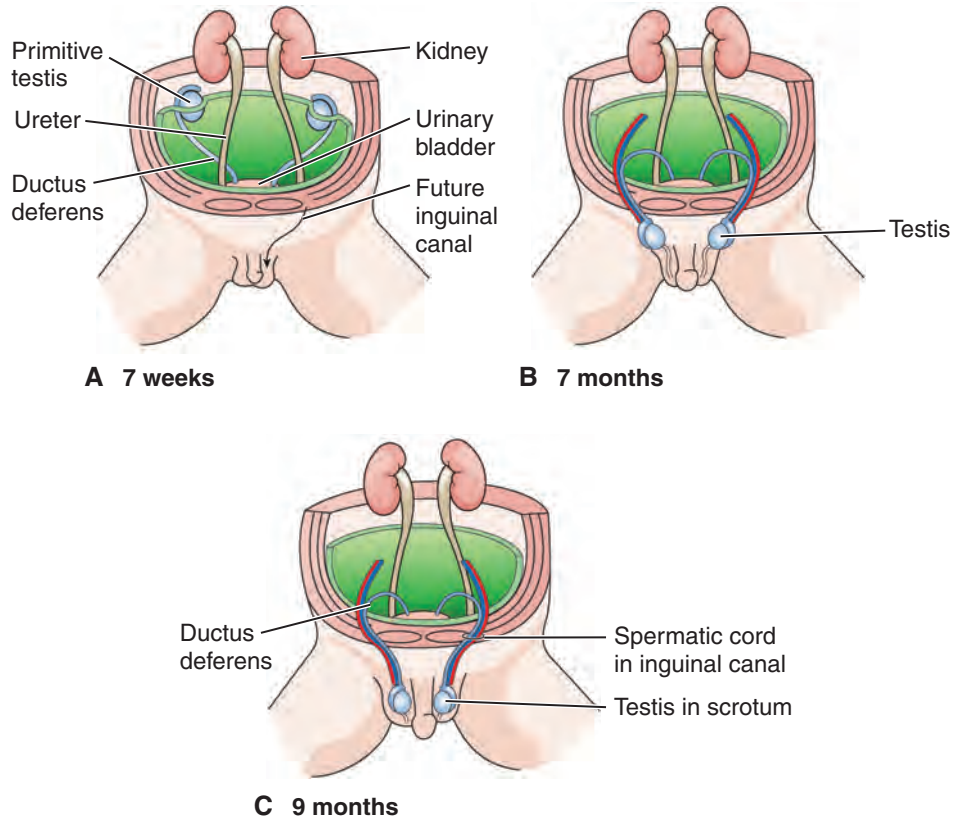
## The Testes

The male germ cells, the sperm cells or **spermatozoa** (singular: spermatozoon), are produced in the paired **testes** (singular: testis) that are suspended outside of the body in the **scrotum** (**FIG. 15-1**). Although the testes develop in the abdominal cavity, they normally descend through the **inguinal canal** into the scrotum before birth or shortly thereafter (**FIG. 15-2**).

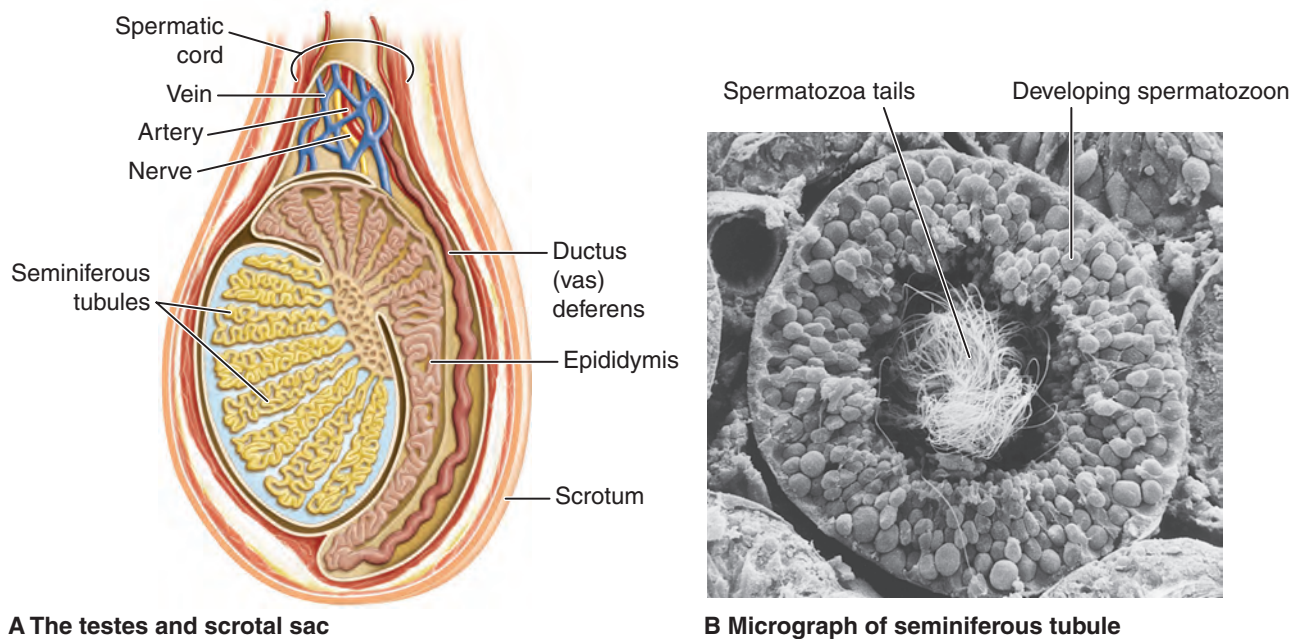
From the start of sexual maturation, or **puberty**, spermatozoa form continuously within the testes in coiled seminiferous tubules (**FIG. 15-3**). Their development requires the aid of special **Sertoli cells** and male sex hormones, or **androgens**, mainly **testosterone**. These hormones are manufactured in **interstitial cells** located between the tubules. In both males and females, the gonads are stimulated by **follicle-stimulating hormone (FSH)** and **luteinizing hormone (LH)**, released from the anterior **pituitary gland** beneath the brain. These hormones are chemically the same in males and females, although they are named for their actions in female reproduction. In males, FSH stimulates the Sertoli cells and promotes the formation of spermatozoa. LH stimulates the interstitial cells to produce testosterone.



**FIGURE 15-1 Male reproductive system.** Arrows show the path of spermatozoa. Parts of the urinary system and digestive system are also shown.



**FIGURE 15-2 Descent of the testes.** Drawings show formation of the inguinal canals and descent of the testes at three different times during fetal development. **A.** At 7 weeks, the testis is in the dorsal abdominal wall. **B.** At 7 months, the testis is passing through the inguinal canal. **C.** At 9 months, the testis is in the scrotum, suspended by the spermatic cord.



**FIGURE 15-3 The testis.** **A.** The testis in position in the scrotum showing the structure of the seminiferous tubules. The epididymis and spermatic cord are also shown. **B.** Spermatozoa develop within the seminiferous tubules in the testis.



## FOCUS ON WORDS

### Which Is It?

BOX 15-1

Some of the work of learning medical terminology is made more difficult by the fact that many structures and processes are known by two or even more names. This duplication may occur because different names have been assigned at different times or places or because the name is in a state of transition to another name, and the new one has not been universally accepted.

The tube that leads from the testis to the urethra in males was originally called the *vas deferens*, *vas* being a general term for *vessel*. To distinguish this tube from a blood vessel, efforts have been made to change the name to *ductus deferens*. However, the original name has lingered because the surgical

procedure used to sterilize a man is still called a *vasectomy* and not a “*ductusectomy*.”

Similar inconsistencies appear in other systems. Dorsal is also posterior; ventral could be anterior. Human growth hormone is also called *somatotropin*. ADH, a hormone that increases blood pressure, is also known as *vasopressin*.

In the nervous system, the little swellings at the ends of axons that contain neurotransmitters are variously called *end-feet*, *end-bulbs*, *terminal knobs*, *terminal feet*, and even other names. In a woman, the tube that carries the ovum from the ovary to the uterus is referred to as the *uterine tube*, or maybe the *Fallopian tube* ... or the *oviduct* ... or ...

## Transport of Spermatozoa

After their manufacture, sperm cells are stored in a much-coiled tube on the surface of each testis, the **epididymis** (see **FIGS. 15-1** and **15-3**). Here, they remain until **ejaculation** propels them into a series of ducts that lead out of the body. The first of these is the **ductus (vas) deferens**, which is contained in the **spermatic cord** along with nerves and blood vessels that supply the testis (see **FIGS. 15-2** and **15-3**). The spermatic cord ascends through the inguinal canal into the abdominal cavity, where the ductus deferens leaves the cord and travels behind the bladder. (See **BOX 15-1**, which discusses how alternative names can be a challenge to learning medical terminology.)

A short continuation of the ductus deferens, the **ejaculatory duct**, delivers spermatozoa to the urethra as it passes through the **prostate gland** below the bladder. Finally, the cells, now mixed with other secretions, travel in the urethra through the penis to be released (see **FIG. 15-1**).

## The Penis

The penile urethra transports both urine and **semen**. The **penis** is the male organ of sexual intercourse, or **coitus**. It is composed of three segments of spongy tissue, which become engorged with blood to produce an **erection**, a stiffening of the penis. As shown in **FIGURE 15-4**, the two **corpora cavernosa** are lateral bodies; the **corpus spongiosum**, through which the urethra travels, is in the center. The corpus spongiosum enlarges at the tip to form the **glans penis**, which is covered by loose skin—the **prepuce**, or **foreskin**. Surgery to remove the foreskin is **circumcision**. This may be performed for medical reasons but is most often performed electively in male infants for reasons of hygiene, cultural preferences, or religion.

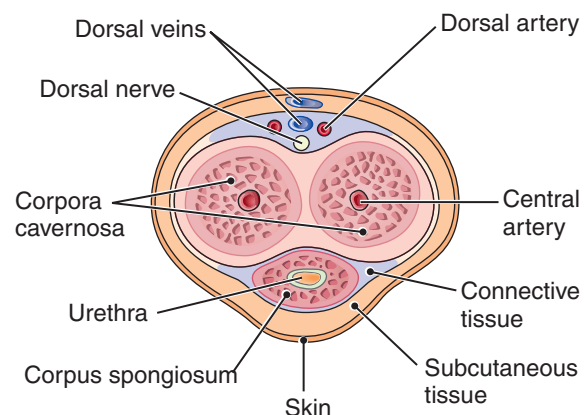
## Formation of Semen

Semen is the thick, whitish fluid that transports spermatozoa. It contains, in addition to sperm cells, secretions from

three types of accessory glands (see **FIG. 15-1**). Following the sequence of sperm transport, these are:

1. The paired **seminal vesicles**, which release their secretions into the ejaculatory duct on each side.
2. The prostate gland, which secretes into the first part of the urethra beneath the bladder. As men age, prostatic enlargement may compress the urethra and cause urinary problems.
3. The two **bulbourethral (Cowper) glands**, which secrete into the urethra just below the prostate gland.

Together, these glands produce a slightly alkaline mixture that nourishes and transports the sperm cells and also protects them by neutralizing the acidity of the female vaginal tract.



**FIGURE 15-4 The penis.** This cross-section shows the erectile bodies of the penis (corpora cavernosa and corpus spongiosum), the centrally located urethra, as well as blood vessels and a nerve.

## Terminology

## Key Terms

The terms listed below are emphasized in this chapter. Knowing them will help you organize and prioritize your learning. These boldface terms are also found, collectively, with all chapter key terms in the Glossary.

<b>androgen</b> <i>AN-dro-jen</i>	Any hormone that produces male characteristics (root <i>andr/o</i> means “male”)
<b>bulbourethral gland</b> <i>bul-bo-u-RE-thral</i>	A small gland beside the urethra below the prostate that secretes part of the seminal fluid; also called Cowper gland
<b>circumcision</b> <i>ser-kum-SIH-zhun</i>	Surgical removal of the end of the prepuce (foreskin)
<b>coitus</b> <i>KO-ih-tus</i>	Sexual intercourse
<b>ductus deferens</b> <i>DUK-tus DEF-er-enz</i>	The duct that conveys spermatozoa from the epididymis to the ejaculatory duct; also called vas deferens
<b>ejaculation</b> <i>e-jak-u-LA-shun</i>	Ejection of semen from the male urethra
<b>ejaculatory duct</b> <i>e-JAK-u-lab-tor-e</i>	The duct formed by union of the ductus deferens and the duct of the seminal vesicle; it carries spermatozoa and seminal fluid into the urethra
<b>epididymis</b> <i>ep-ih-DID-ih-mis</i>	A coiled tube on the surface of the testis that stores sperm until ejaculation (root: <i>epididym/o</i> )
<b>erection</b> <i>e-REK-shun</i>	The stiffening or hardening of the penis or the clitoris, usually because of sexual excitement
<b>follicle-stimulating hormone (FSH)</b>	A hormone secreted by the anterior pituitary that acts on the gonads; in males, FSH stimulates Sertoli cells and promotes sperm cell development; in females, it stimulates ripening of ova in the ovary
<b>gamete</b> <i>GAM-ete</i>	A mature reproductive cell, the spermatozoon in the male and the ovum in the female
<b>glans penis</b> <i>glanz PE-nis</i>	The bulbous end of the penis
<b>gonad</b> <i>GO-nad</i>	A sex gland; testis or ovary
<b>inguinal canal</b> <i>ING-gwin-al</i>	The channel through which the testis descends into the scrotum in the male
<b>interstitial cells</b> <i>in-ter-STISH-al</i>	Cells located between the seminiferous tubules of the testes that produce hormones, mainly testosterone; also called cells of Leydig ( <i>LI-dig</i> )
<b>luteinizing hormone (LH)</b> <i>LU-te-in-i-zing</i>	A hormone secreted by the anterior pituitary that acts on the gonads; in males, it stimulates the interstitial cells to produce testosterone; in females, it stimulates ovulation and corpus luteum formation.
<b>meiosis</b> <i>mi-O-sis</i>	The type of cell division that forms the gametes; it results in cells with 23 chromosomes, half the number found in other body cells (from the Greek word <i>meiosis</i> meaning “diminution”)
<b>penis</b> <i>PE-nis</i>	The male organ of copulation and urination (adjective: <i>penile</i> )
<b>pituitary gland</b> <i>pih-TU-ib-tar-e</i>	An endocrine gland at the base of the brain
<b>prepuce</b> <i>PRE-pus</i>	The fold of skin over the glans penis; the foreskin
<b>prostate gland</b> <i>PROS-tate</i>	A gland that surrounds the urethra below the bladder in males and contributes secretions to the semen (root: <i>prostat/o</i> )
<b>puberty</b> <i>PU-ber-te</i>	Period during which the ability for sexual reproduction is attained and secondary sex characteristics begin to develop

(continued)



## Terminology

## Key Terms (Continued)

<b>scrotum</b> <i>SKRO-tum</i>	A double pouch that contains the testes (root: osche/o)
<b>semen</b>	The thick secretion that transports spermatozoa (roots: semin, sperm/i, spermat/o)
<b>seminal vesicle</b> <i>SEM-ib-nal VES-ib-kl</i>	A sac-like gland behind the bladder that contributes secretions to the semen (root: vesicul/o)
<b>Sertoli cell</b> <i>ser-TO-le</i>	Cell in a seminiferous tubule that aids in the development of spermatozoa; sustentacular ( <i>sus-ten-TAK-u-lar</i> ) cell
<b>spermatic cord</b> <i>sper-MAT-ik</i>	Cord attached to the testis that contains the ductus deferens, blood vessels, and nerves enclosed within a fibrous sheath (see <b>FIG. 15-3</b> )
<b>spermatozoon</b> <i>sper-mah-to-ZO-on</i>	Mature male sex cell (plural: spermatozoa) (roots: sperm/i, spermat/o)
<b>testis</b> <i>TES-tis</i>	The male reproductive gland (roots: test/o, orchis/o, orchid/o); plural is testes ( <i>TES-teze</i> ); also called testicle
<b>testosterone</b> <i>tes-TOS-ter-one</i>	The main male sex hormone
<b>urethra</b> <i>u-RE-thrah</i>	The duct that carries urine out of the body and also transports semen in the male
<b>vas deferens</b> <i>DEF-er-enz</i>	The duct that conveys spermatozoa from the epididymis to the ejaculatory duct; also called ductus deferens

## Word Parts Pertaining to the Male Reproductive System

See **TABLE 15-1**.**Table 15-1** Roots for Male Reproduction

Root	Meaning	Example	Definition of Example
test/o	testis, testicle	testosterone <i>tes-TOS-teh-rone</i>	hormone produced in the testis
orchis/o, orchid/o	testis	anorchism <i>an-OR-kizm</i>	absence of a testis
osche/o	scrotum	oscheal <i>OS-ke-al</i>	pertaining to the scrotum
semin	semen	inseminate <i>in-SEM-ib-nate</i>	to introduce semen into a vagina
sperm/i, spermat/o	semen, spermatozoa	polyspermia <i>pol-e-SPER-me-ab</i>	secretion of excess semen
epididym/o	epididymis	epididymitis <i>ep-ib-did-ib-MI-tis</i>	inflammation of the epididymis
vas/o	vas deferens, ductus deferens; also vessel	vasostomy <i>vas-OS-to-me</i>	surgical creation of an opening in the ductus deferens
vesicul/o	seminal vesicle	vesiculogram <i>veh-SIK-u-lo-gram</i>	radiograph of a seminal vesicle
prostat/o	prostate	prostatometer <i>pros-tah-TOM-eh-ter</i>	instrument for measuring the prostate

**Exercise 15-1**

Complete the exercise. To check your answers go to Appendix 11.

Define the following words.

1. spermatogenesis (*sper-mah-to-JEN-eh-sis*) \_\_\_\_\_
2. prostatodynia (*pros-tah-to-DIN-e-ah*) \_\_\_\_\_
3. oscheoplasty (*os-ke-o-PLAS-te*) \_\_\_\_\_
4. epididymectomy (*ep-ih-did-ih-MEK-to-me*) \_\_\_\_\_
5. orchialgia (*or-ke-AL-je-ah*) \_\_\_\_\_
6. testopathy (*tes-TOP-ah-the*) \_\_\_\_\_
7. orchiepididymitis (*or-ke-ep-ih-did-ih-MI-tis*) \_\_\_\_\_

Use the root *orchi/o* to write a word for the following definitions. Each is also written with the root *orchid/o*.

8. surgical fixation of a testis \_\_\_\_\_
9. plastic repair of a testis \_\_\_\_\_
10. surgical removal of a testis \_\_\_\_\_

Use the root *spermat/o* to write a word for the following definitions.

11. Condition of having sperm in the urine (-uria) \_\_\_\_\_
12. Destruction (-lysis) of sperm \_\_\_\_\_
13. Excessive discharge (-rhea) of semen \_\_\_\_\_
14. Subnormal concentration of sperm in semen \_\_\_\_\_
15. A sperm-forming cell \_\_\_\_\_

The ending *-spermia* means “condition of sperm or semen.” Add a prefix to *-spermia* to form a word for the following definitions.

16. presence of blood in the semen \_\_\_\_\_
17. lack of semen \_\_\_\_\_
18. secretion of excess (poly-) semen \_\_\_\_\_
19. presence of pus in the semen \_\_\_\_\_

Write a word for the following definitions.

20. excision of the ductus deferens \_\_\_\_\_
21. tumor of the scrotum \_\_\_\_\_
22. suture of the vas deferens \_\_\_\_\_
23. excision of the prostate gland \_\_\_\_\_
24. radiographic study of a seminal vesicle \_\_\_\_\_
25. inflammation of a seminal vesicle \_\_\_\_\_
26. incision of the epididymis \_\_\_\_\_

## Clinical Aspects of the Male Reproductive System

### INFECTION

Most infections of the male reproductive tract are **sexually transmitted infections (STIs)**, listed in **BOX 15-2**. The most common STI in the United States is caused by the bacterium *Chlamydia trachomatis*, which mainly causes **urethritis** in males. This same organism also causes lymphogranuloma venereum, an STI associated with lymphadenopathy, which occurs most commonly in tropical regions. Both forms of these chlamydial infections respond to treatment with antibiotics.

Gonorrhea is caused by *Neisseria gonorrhoeae*, the gonococcus (GC). Infection usually centers in the urethra,

causing urethritis with burning, a purulent discharge, and dysuria. Untreated, the disease can spread through the reproductive system. Gonorrhea is treated with antibiotics, but gonococci can rapidly develop resistance to these drugs.

Another common STI is herpes infection, caused by a virus. Other STIs are discussed in Chapter 16. Sexually transmitted infections are some of the most common infectious diseases in the United States, affecting up to 20 million men and women each year. Anyone who is sexually active and not in a monogamous sexual relationship with an uninfected partner should have regular checkups for STIs.

Mumps is a nonsexually transmitted viral disease that can infect the testes and lead to **sterility**. Other microorganisms can infect the reproductive tract as well, causing urethritis, **prostatitis**, **orchitis**, or **epididymitis**.



### FOR YOUR REFERENCE Sexually Transmitted Infections

**BOX 15-2**

Disease	Organism	Description
<b>BACTERIAL</b>		
<b>chlamydial infection</b>	<i>Chlamydia trachomatis</i> types D to K	Ascending infection of reproductive and urinary tracts; may spread to pelvis in women, causing pelvic inflammatory disease (PID)
<b>lymphogranuloma venereum</b>	<i>Chlamydia trachomatis</i> type L	General infection with swelling of inguinal lymph nodes; scarring of genital tissue
<b>gonorrhea</b>	<i>Neisseria gonorrhoeae</i> ; gonococcus (GC)	Inflammation of reproductive and urinary tracts; urethritis in men; vaginal discharge and cervical inflammation (cervicitis) in women, leading to pelvic inflammatory disease (PID); possible systemic infection; may spread to newborns; treated with antibiotics
<b>bacterial vaginosis</b>	<i>Gardnerella vaginalis</i>	Vaginal infection with foul-smelling discharge
<b>syphilis</b>	<i>Treponema pallidum</i> (a spirochete)	Primary stage: chancre (lesion); secondary stage: systemic infection and syphilitic warts; tertiary stage: degeneration of other systems; cause of spontaneous abortions, stillbirths, and fetal deformities; treated with antibiotics
<b>VIRAL</b>		
<b>AIDS (acquired immunodeficiency syndrome)</b>	HIV (human immunodeficiency virus)	A disease that infects T cells of the immune system, weakening the host and leading to other diseases: usually fatal if untreated
<b>genital herpes</b>	herpes simplex virus (HSV)	Painful genital lesions; in women, may be a risk factor in cervical carcinoma; often fatal infections of newborns; no cure at present
<b>hepatitis B</b>	hepatitis B virus (HBV)	Causes liver inflammation, which may be acute or may develop into a chronic carrier state; linked to liver cancer
<b>condyloma acuminatum (genital warts)</b>	human papillomavirus (HPV)	Benign genital warts; in women, predisposes to cervical dysplasia and carcinoma; a vaccine against the most prevalent strains is available
<b>PROTOZOAL</b>		
<b>trichomoniasis</b>	<i>Trichomonas vaginalis</i>	Vaginitis; green, frothy discharge with itching, pain on intercourse (dyspareunia), and painful urination (dysuria)

## BENIGN PROSTATIC HYPERPLASIA

As men age, the prostate gland commonly enlarges, a condition known as **benign prostatic hyperplasia (BPH)**, as noted in Dexter’s opening case study. Although not cancerous, this overgrown tissue can press on the urethra near the bladder and interfere with urination. Urinary retention, infection, and other complications may follow if an obstruction is not corrected.

Medications to relax smooth muscle in the prostate and bladder neck are used to treat the symptoms of BPH. Alpha-adrenergic blocking agents interfere with sympathetic nervous stimulation in these regions to improve urinary flow rate. One example is tamsulosin (Flomax). Because testosterone stimulates enlargement of the prostate, drugs that interfere with prostatic testosterone activity may slow the disorder’s progress. One example is finasteride (Proscar). A herbal remedy that seems to act in this same manner is an extract of the berries of the saw palmetto, a low-growing palm tree. Saw palmetto has been found to delay the need for surgery in some cases of BPH.

In advanced cases of BPH, removal of the prostate, or **prostatectomy**, may be required. When this is performed through the urethra, the procedure is called a transurethral resection of the prostate (TURP) (FIG. 15-5A). The prostate may also be cut in a transurethral incision of the prostate (TUIP) to reduce pressure on the urethra (FIG. 15-5B). Surgeons also use a laser beam or heat to destroy prostatic tissue. BPH is diagnosed by digital rectal examination (DRE) or imaging studies.

## CANCER

### Cancer of the Prostate

Prostatic cancer is the most common malignancy among men in the United States. Only lung cancer and colon cancer cause more cancer-related deaths in men who are past

middle age. Physicians can often detect prostatic cancer by DRE. Blood tests for prostate-specific antigen (PSA) may also help in early detection. This protein is produced in increased amounts in cases of prostatic cancer, although it may increase in other prostatic disorders as well.

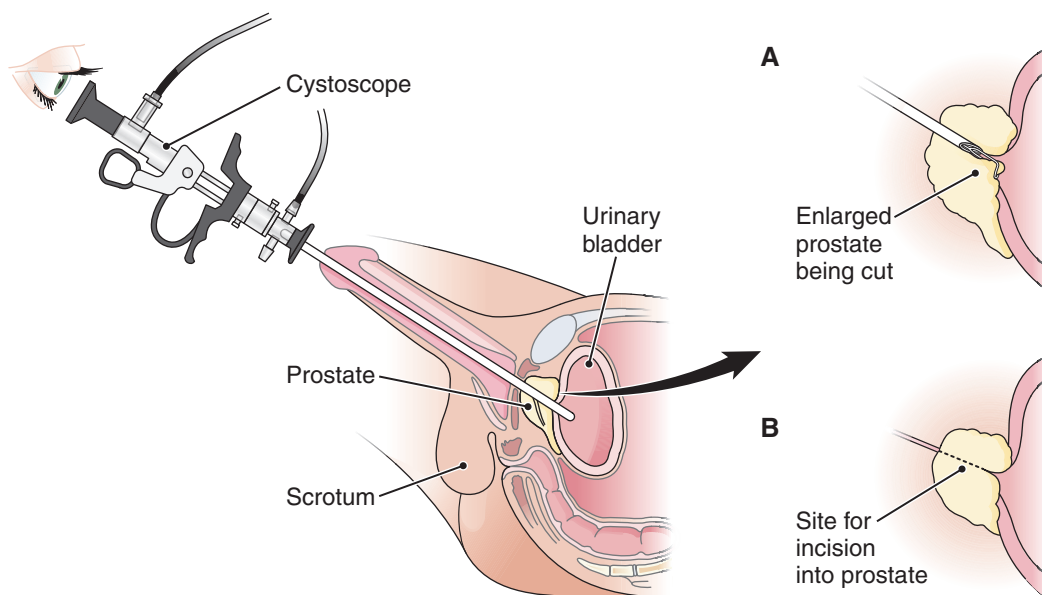
The TNM system for staging prostate cancer includes the following categories:

- T<sub>1</sub>: tumor not palpable by rectal examination; detected by biopsy or abnormal PSA
- T<sub>2</sub>: tumor palpable and confined to the prostate
- T<sub>3</sub>: tumor has spread locally beyond the prostate
- M: distant metastases

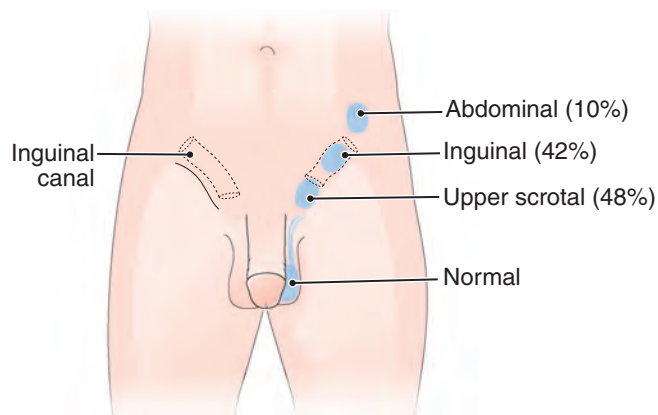
Treatment methods include surgery (prostatectomy); radiation; inhibition of male hormones (androgens), which stimulate prostatic growth; and chemotherapy. Radiation is usually delivered by implantation of radioactive seeds. Another approach is termed “watchful waiting” or deferred therapy, which consists of monitoring without therapy. Choice of this option is based on a man’s age, tumor invasiveness, and the probability that an untreated tumor will result in harm to a patient during his lifetime. A genetic test for tumor aggressiveness can help to evaluate risk and determine treatment decisions.

### Testicular Cancer

Cancer of the testis represents less than 1 percent of cancer in adult males. It usually appears between the ages of 25 and 45 years and shows no sign of genetic inheritance. This cancer typically originates in germ cells and can spread to abdominal lymph nodes. More than half of testicular tumors release markers that can be detected in the blood. Treatment may include removal of the testis (orchietomy), radiation, and chemotherapy.



**FIGURE 15-5** Prostate surgery procedures. **A.** Transurethral resection of the prostate (TURP). Portions of the prostate are removed at the bladder opening. **B.** Transurethral incision of the prostate (TUIP). One or two incisions are made in the prostate to reduce pressure on the urethra.



**FIGURE 15-6 Cryptorchidism.** The testis fails to descend into the scrotum. In most cases, the testis is retained in the upper part of the scrotal sac or in the inguinal canal. The percentages of different locations are shown.

## CRYPTORCHIDISM

It is fairly common that one or both testes will fail to descend into the scrotum by the time of birth (FIG. 15-6). This condition is termed **cryptorchidism**, literally hidden (*crypt/o*) testis (*orchid/o*). The condition usually corrects itself within the first year of life. If not, it must be corrected surgically to avoid sterility and an increased risk of cancer.

## INFERTILITY

An inability or a diminished ability to reproduce is termed **infertility**. Its causes may be hereditary, hormonal, disease-related, or the result of exposure to chemical or physical agents. The most common causes of infertility are STIs. A total inability to produce offspring may be termed sterility. Men may be voluntarily sterilized by cutting and sealing the vas deferens on both sides in a **vasectomy** (see FIG. 16-5 in Chapter 16).

## Erectile Dysfunction

**Erectile dysfunction (ED)**, also called **impotence**, is the inability of the male to perform intercourse because of failure to initiate or maintain an erection until ejaculation. About 10 to 20 percent of such cases are psychogenic, that is, caused by emotional factors, such as stress, depression, or emotional trauma. More often, ED has a physical cause, which may be:

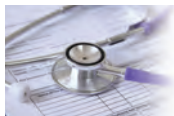- A vascular disorder such as arteriosclerosis, varicose veins, or damage caused by diabetes.
- A neurologic problem, as caused by a tumor, trauma, the effects of diabetes, or damage caused by radiation or surgery.
- A side effect of a drug, such as an antihypertensive agent, antiulcer medication, or appetite suppressant.

Drugs that are used to treat ED work by dilating arteries in the penis to increase blood flow to that organ. Nondrug approaches include corrective surgery; vacuum pumps to draw blood into the penis; penile injections to dilate blood vessels; and penile prostheses. **BOX 15-3** has more information on ED.

Physician assistants aid in patient examination and care in urology and many other medical and surgical fields. **BOX 15-4** describes careers in this specialty.

## INGUINAL HERNIA

The inguinal canal, through which the testis descends, may constitute a weakness in the abdominal wall that can lead to a hernia. In the most common form of **inguinal hernia** (FIG. 15-7), an abdominal organ, usually the intestine, enters the inguinal canal and may extend into the scrotum. This is an indirect, or external, inguinal hernia. In a direct, or internal, inguinal hernia, the organ protrudes through the abdominal wall into the scrotum. If blood supply to the organ is cut off, the hernia is said to be *strangulated*. Surgery to correct a hernia is a **herniorrhaphy**.



## CLINICAL PERSPECTIVES

### Treating Erectile Dysfunction

BOX 15-3

Approximately 25 million American men and their partners are affected by ED, the inability to achieve or maintain an erection. Although ED is more common in men over the age of 65, it can occur at any age and can have many causes.

Erection results from an interaction between the autonomic nervous system and penile blood vessels. Sexual arousal stimulates parasympathetic nerves in the penis to release a compound called nitric oxide (NO). This substance activates an enzyme in vascular smooth muscle that promotes vasodilation, increasing blood flow into the penis and causing erection. Physical factors that cause ED prevent these physiologic changes.

Drugs that target the physiologic mechanisms of erection are helping men who suffer from ED. These include sildenafil (trade name, Viagra), vardenafil (Levitra), and tadalafil (Cialis). These drugs prevent the breakdown of vasodilators, thus prolonging the effects of NO. Although effective in about 80 percent of ED cases, these drugs can cause some relatively minor side effects, including headache, nasal congestion, stomach upset, and blue-tinged vision. They should never be used by men who are taking nitrate drugs to treat angina. Because nitrates elevate NO levels, taking them with drugs for ED and prolonging the effects of NO can cause life-threatening hypotension. They are also contraindicated in men with low blood pressure and heart failure.



## HEALTH PROFESSIONS

### Physician Assistant

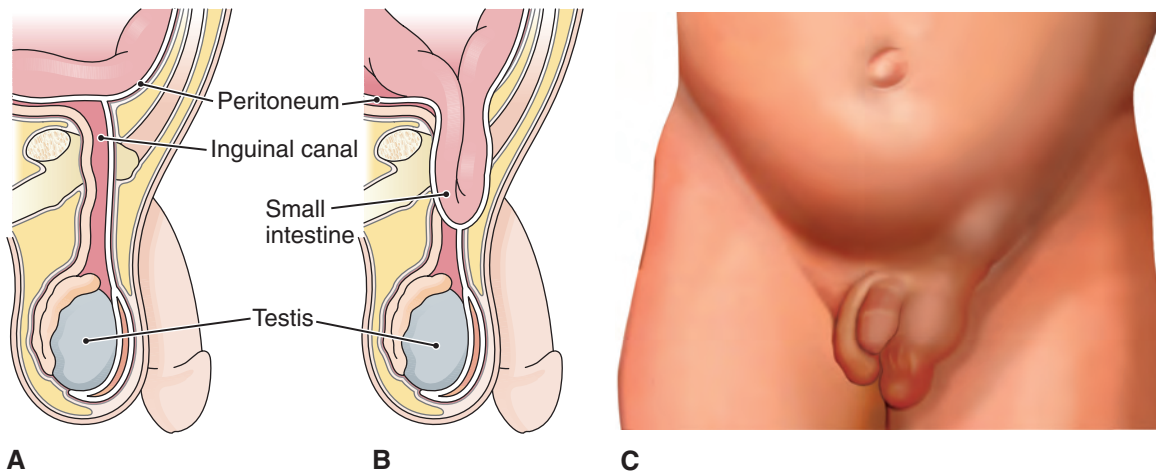
BOX 15-4

Physician assistants (PAs) practice medicine under the supervision of physicians and surgeons. They are trained in diagnosis, therapy, and preventive health care. They are also licensed to treat minor injuries. In almost all states, they are permitted to prescribe medications. Depending on the work setting, they may also manage a practice and supervise other medical personnel. In medically underserved areas, they may work under their own direction and confer with physicians as needed. Many PAs work in general, pediatric, or family medicine practices. If they specialize in surgery, they may provide patient care before and after an operation or assist in surgery.

A PA must complete a formal 6-year educational program: 4 years of undergraduate work and a 2-year master's degree. The majority of PA programs require candidates to enter with

a bachelor's degree, core science courses, and clinical experience either in the military or some other allied health field. After successful completion of a didactic year and a year of clinical rotations, PAs must be licensed by passing a national examination. They may also become certified (PA-C) through the National Commission on Certification of Physician Assistants (NCCPA) and maintain that certification by continuing education. The job outlook is very good, especially as hospitals are required to compensate for shorter medical residents' shifts by increasing staffing with PAs. Also, medical personnel can consult with ease via telecommunication, allowing for physical independence at certain practices. For additional information, contact the American Academy of Physician Assistants at [aapa.org](http://aapa.org).

15



**FIGURE 15-7** Inguinal hernia. **A.** Normal. **B.** Weakness in the abdominal wall allows the intestine or other abdominal contents to protrude into the inguinal canal. The hernial sac is a continuation of the peritoneum. **C.** An inguinal hernia can cause a visible bulge in the inguinal area and scrotum.

## Terminology

## Key Terms

The terms listed below are emphasized in this chapter. Knowing them will help you organize and prioritize your learning. These boldface terms are also found, collectively, with all chapter key terms in the Glossary.

### Disorders

<b>benign prostatic hyperplasia (BPH)</b> <i>be-NINE pros-TAT-ik hi-per-PLA-ze-ab</i>	Nonmalignant enlargement of the prostate; frequently develops with age
<b>cryptorchidism</b> <i>krip-TOR-kid-izm</i>	Failure of the testis to descend into the scrotum (see <b>FIG. 15-6</b> )
<b>epididymitis</b> <i>ep-ih-did-ih-MI-tis</i>	Inflammation of the epididymis; common causes are UTIs and STIs
<b>erectile dysfunction (ED)</b> <i>eh-REK-tile dis-FUNK-shun</i>	Inability of the male to perform intercourse because of failure to initiate or maintain an erection until ejaculation; impotence

(continued)

## Terminology

## Key Terms (Continued)

<b>impotence</b> <i>IM-po-tens</i>	Erectile dysfunction
<b>infertility</b> <i>in-fer-TIL-ih-te</i>	Decreased capacity to produce offspring
<b>inguinal hernia</b> <i>ING-gwin-al</i>	Protrusion of the intestine or other abdominal organ through the inguinal canal (see <b>FIG. 15-7</b> ) or through the wall of the abdomen into the scrotum
<b>orchitis</b> <i>or-KI-tis</i>	Inflammation of a testis; may be caused by injury, mumps virus, or other infections
<b>prostatitis</b> <i>pros-tab-TI-tis</i>	Inflammation of the prostate gland; often appears with UTI, STI, and a variety of other stresses
<b>sexually transmitted infection (STI)</b>	Infection spread through sexual activity (see <b>BOX 15-2</b> ); also called sexually transmitted disease (STD) and formerly venereal ( <i>veh-NE-re-al</i> ) disease (VD) (from Venus, the goddess of love)
<b>sterility</b> <i>steb-RIL-ih-te</i>	Complete inability to produce offspring
<b>urethritis</b> <i>u-re-THRI-tis</i>	Inflammation of the urethra; often caused by gonorrhea and chlamydia infections
<b>Surgery</b>	
<b>herniorrhaphy</b> <i>her-ne-OR-ab-fe</i>	Surgical repair of a hernia
<b>prostatectomy</b> <i>pros-tab-TEK-to-me</i>	Surgical removal of the prostate
<b>vasectomy</b> <i>vah-SEK-to-me</i>	Excision of the vas deferens; usually done bilaterally to produce sterility (see <b>FIG. 16-5</b> ); may be accomplished through the urethra (transurethral resection)

## Terminology

## Enrichment Terms

The terms listed below expand on the key terms to increase your knowledge of this chapter topic.

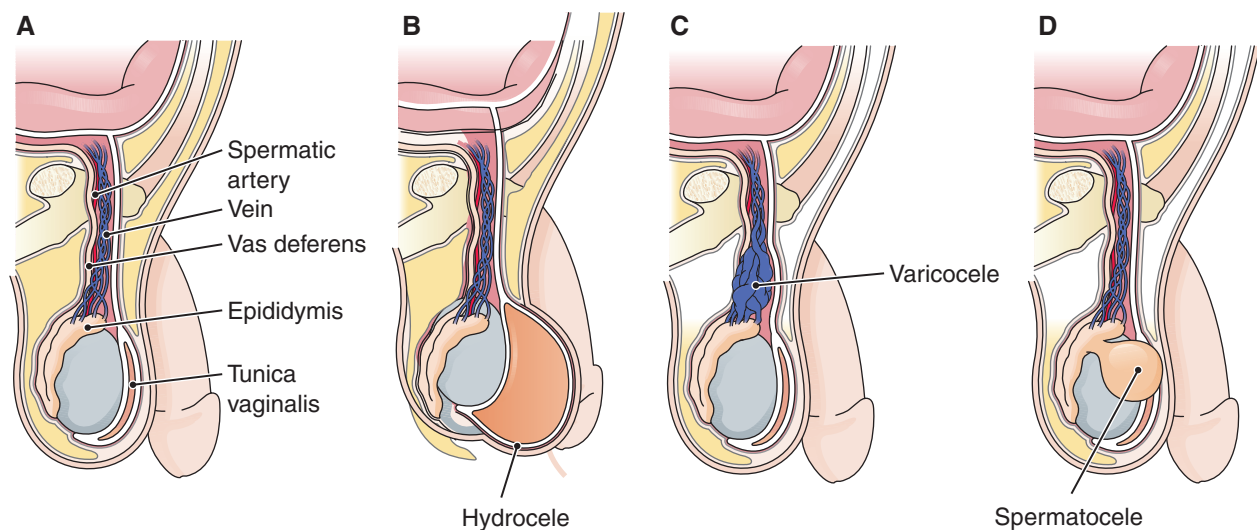
## Normal Structure and Function

<b>emission</b> <i>e-MISH-un</i>	The discharge of semen
<b>genitalia</b> <i>jen-ih-TA-le-ah</i>	The organs concerned with reproduction, divided into internal and external components
<b>insemination</b> <i>in-sem-ih-NA-shun</i>	Introduction of semen into a woman's vagina
<b>orgasm</b> <i>OR-gazm</i>	A state of physical and emotional excitement, especially that which occurs at the climax of sexual intercourse
<b>phallus</b> <i>FAL-us</i>	The penis (adjective: phallic)
<b>Disorders</b>	
<b>balanitis</b> <i>bal-ab-NI-tis</i>	Inflammation of the glans penis and mucous membrane beneath it (root balan/o means "glans penis")

## Terminology

## Enrichment Terms (Continued)

<b>bladder neck obstruction (BNO)</b>	Blockage of urine flow at the outlet of the bladder; the common cause is benign prostatic hyperplasia
<b>hydrocele</b> <i>HI-dro-sele</i>	The accumulation of fluid in a sac-like cavity, especially within the covering of the testis or spermatic cord ( <b>FIG. 15-8</b> )
<b>phimosis</b> <i>fi-MO-sis</i>	Narrowing of the prepuce's opening so that the foreskin cannot be pushed back over the glans penis
<b>priapism</b> <i>PRI-ab-pizm</i>	Abnormal, painful, continuous erection of the penis, as may be caused by drugs or specific damage to the spinal cord
<b>seminoma</b> <i>sem-ih-NO-mah</i>	A tumor of the testis
<b>spermatocele</b> <i>SPER-mah-to-sele</i>	An epididymal cyst containing spermatozoa (see <b>FIG. 15-8</b> )
<b>varicocele</b> <i>VAR-ih-ko-sele</i>	Enlargement of the veins of the spermatic cord (see <b>FIG. 15-8</b> )
<b>Diagnosis and Treatment</b>	
<b>brachytherapy</b> <i>brak-e-THER-ah-pe</i>	Radiation therapy by placement of encapsulated radiation sources, such as seeds, directly into a tumor or nearby tissue (from Greek <i>brachy</i> , meaning “short”)
<b>castration</b> <i>kas-TRA-shun</i>	Surgical removal of the testes or ovaries; hormones and drugs can inhibit the gonads to produce functional castration
<b>Gleason tumor grade</b> <i>GLE-son</i>	A system for assessing the severity of cancerous changes in the prostate; reported as a Gleason score
<b>resectoscope</b> <i>re-SEK-to-skope</i>	Endoscopic instrument for transurethral removal of tissue from the urinary bladder, prostate gland, uterus, or urethra
<b>Whitmore–Jewett staging</b> <i>WIT-more JEW-et</i>	A method for staging prostatic tumors; an alternate to TNM staging



**FIGURE 15-8** Scrotal abnormalities. **A.** Normal. **B.** Hydrocele. **C.** Varicocele. **D.** Spermatocele.



## Terminology *Abbreviations*

The abbreviations listed below are emphasized in this chapter. These are also found, collectively, with all chapter abbreviations in Appendix 2.

**AIDS** Acquired immunodeficiency syndrome

**BNO** Bladder neck obstruction

**BPH** Benign prostatic hyperplasia

**DRE** Digital rectal examination

**ED** Erectile dysfunction

**FSH** Follicle-stimulating hormone

**GC** Gonococcus

**GU** Genitourinary

**HBV** Hepatitis B virus

**HIV** Human immunodeficiency virus

**HSV** Herpes simplex virus

**LH** Luteinizing hormone

**NGU** Nongonococcal urethritis

**PSA** Prostate-specific antigen

**STD** Sexually transmitted disease

**STI** Sexually transmitted infection

**TPUR** Transperineal urethral resection

**TSE** Testicular self-examination

**TUIP** Transurethral incision of prostate

**TURP** Transurethral resection of prostate

**UG** Urogenital

**UTI** Urinary tract infection

**VD** Venereal disease (sexually transmitted infection)

**VDRL** Venereal Disease Research Laboratory (test for syphilis)

## Case Study Revisited

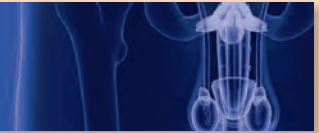### Dexter's Follow-Up

On the morning of the second postoperative day, the Foley catheter was removed, and Dexter was able to void on his own. He experienced dysuria and some burning when urinating, but otherwise did not have any postoperative complications. The urologist informed Dexter that it is normal to find urinating uncomfortable and difficult for at least a few days after the catheter is removed. He also explained that removing the extra prostate tissue help urination be easier and less frequent. Most men who have this surgery are back to their regular activities in 4 to 6 weeks.

Dexter remained in the hospital through the second day and was discharged home with specific

instructions. The nurse explained that during recovery there may be an urgent need to urinate, trouble controlling urination, pain during urination, problems getting and keeping an erection, and some small amounts of blood in the urine. The nurse said these surgery side effects should subside in time. Dexter was informed that he should call his urologist if these problems are still present several weeks after surgery.

At his 4-week follow-up appointment with the urologist, Dexter was cleared to continue with his normal activities such as playing tennis and lifting weights at his community gym.

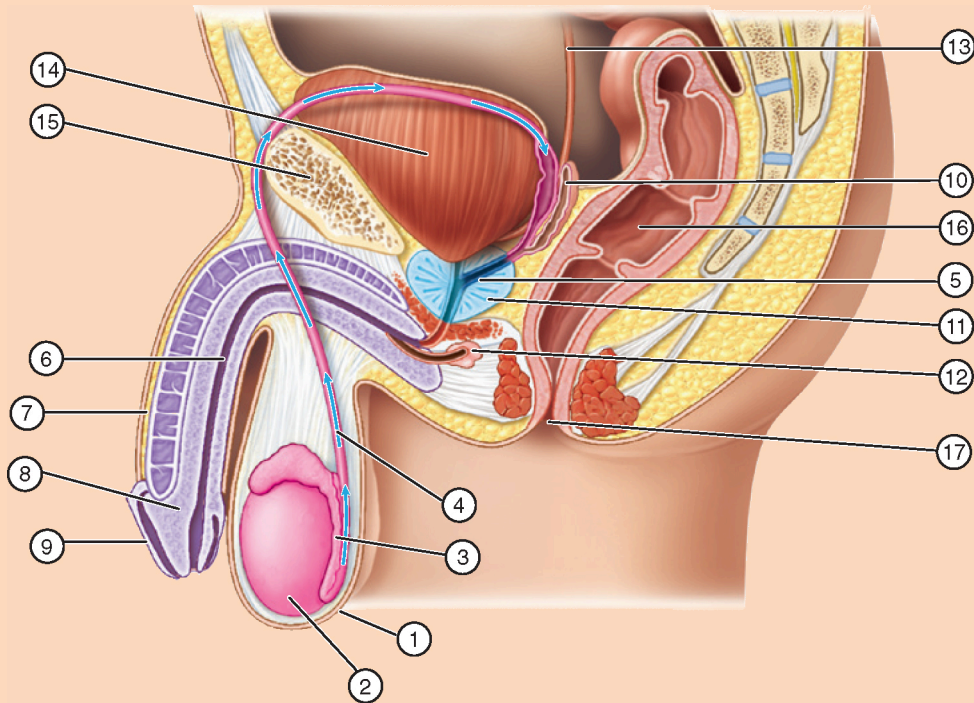


This review tests your understanding of the content introduced in this chapter. Follow the instructions for each exercise and check your answers in Appendix 11.

**LABELING EXERCISE**

**MALE REPRODUCTIVE SYSTEM**

Write the name of each numbered part on the corresponding line.



- |                       |                    |                 |                 |
|-----------------------|--------------------|-----------------|-----------------|
| Anus                  | Glans penis        | Rectum          | Ureter          |
| Bulbourethral gland   | Penis              | Scrotum         | Urethra         |
| Ductus (vas) deferens | Prepuce (foreskin) | Seminal vesicle | Urinary bladder |
| Ejaculatory duct      | Prostate           | Testis          |                 |
| Epididymis            | Pubic bone         |                 |                 |

- |          |           |
|----------|-----------|
| 1. _____ | 10. _____ |
| 2. _____ | 11. _____ |
| 3. _____ | 12. _____ |
| 4. _____ | 13. _____ |
| 5. _____ | 14. _____ |
| 6. _____ | 15. _____ |
| 7. _____ | 16. _____ |
| 8. _____ | 17. _____ |
| 9. _____ |           |

## TERMINOLOGY

### MATCHING

Match the following terms, and write the appropriate letter to the left of each number.

- |                       |   |
|-----------------------|---|
| _____ 1. gamete       | a. reproductive cell                          |
| _____ 2. androgen     | b. start of sexual maturity                   |
| _____ 3. gonad        | c. hormone that produces male characteristics |
| _____ 4. puberty      | d. cell division that forms the gametes       |
| _____ 5. meiosis      | e. sex gland                                  |
|                       |   |
| _____ 6. vasectomy    | a. excision of the ductus deferens            |
| _____ 7. circumcision | b. erectile dysfunction                       |
| _____ 8. impotence    | c. surgical removal of the foreskin           |
| _____ 9. glans        | d. end of the penis                           |
| _____ 10. coitus      | e. sexual intercourse                         |

### Enrichment Terms

- |                         |                                      |
|-------------------------|--------------------------------------|
| _____ 11. priapism      | a. narrowing of the foreskin opening |
| _____ 12. phallic       | b. prolonged erection of the penis   |
| _____ 13. genitalia     | c. tumor of the testis               |
| _____ 14. phimosis      | d. reproductive organs               |
| _____ 15. seminoma      | e. pertaining to the penis           |
|                         |                                      |
| _____ 16. spermatocele  | a. inflammation of the glans penis   |
| _____ 17. balanitis     | b. a form of radiation treatment     |
| _____ 18. castration    | c. discharge of semen                |
| _____ 19. emission      | d. removal of the testes             |
| _____ 20. brachytherapy | e. epididymal cyst                   |

### FILL IN THE BLANKS

Complete the sentence with the correct term(s).

21. The main male sex hormone is \_\_\_\_\_.
22. The two glands that secrete into the urethra just below the prostate gland are the \_\_\_\_\_.
23. The thick fluid that transports spermatozoa is \_\_\_\_\_.
24. The male gonad is the \_\_\_\_\_.
25. The channel through which the testis descends is the \_\_\_\_\_.
26. The sac that holds the testis is the \_\_\_\_\_.

### DEFINITIONS

Define the following terms.

27. vasorrhaphy (*vas-OR-ah-fe*) \_\_\_\_\_
28. anorchism (*an-OR-kizm*) \_\_\_\_\_
29. oscheoma (*os-ke-O-mah*) \_\_\_\_\_
30. vesiculography (*veh-sik-u-LOG-rah-fe*) \_\_\_\_\_
31. prostatometer (*pros-tab-TOM-eh-ter*) \_\_\_\_\_
32. hemospermia (*he-mo-SPER-me-ah*) \_\_\_\_\_

Write words for the following definitions.

33. surgical fixation of the testis \_\_\_\_\_
34. stone in the scrotum \_\_\_\_\_
35. surgical incision of the epididymis \_\_\_\_\_
36. plastic repair of the scrotum \_\_\_\_\_
37. surgical creation of an opening between two parts of a cut ductus deferens (done to reverse a vasectomy) \_\_\_\_\_

Find a word in Dexter's opening case study for each of the following definitions (see also Chapter 14).

38. blood in the urine \_\_\_\_\_
39. painful urination \_\_\_\_\_
40. within the urinary bladder \_\_\_\_\_
41. overdevelopment of tissue \_\_\_\_\_
42. instrument for excising tissue \_\_\_\_\_

### TRUE-FALSE

Examine the following statements. If the statement is true, write T in the first blank. If the statement is false, write F in the first blank, and correct the statement by replacing the underlined word in the second blank.

	True or False	Correct Answer
43. Any male sex hormone is an <u>androgen</u> .	_____	_____
44. The adjective <i>seminal</i> refers to the <u>seminal vesicle</u> .	_____	_____
45. The spirochete <i>Treponema pallidum</i> causes <u>syphilis</u> .	_____	_____
46. Herpes simplex is a <u>virus</u> .	_____	_____
47. The <u>ureter</u> carries both urine and semen in males.	_____	_____
48. FSH and LH are produced by the <u>pituitary gland</u> .	_____	_____
49. Spermatogenesis begins at <u>puberty</u> .	_____	_____

### ELIMINATIONS

In each of the sets below, underline the word that does not fit in with the rest, and explain the reason for your choice.

50. bulbourethral gland — prostate — testis — spermatic cord — seminal vesicle
- \_\_\_\_\_

51. FSH — semen — testosterone — androgen — LH
- \_\_\_\_\_

52. condyloma acuminatum — gonorrhea — hernia — AIDS — herpes
- \_\_\_\_\_

**ADJECTIVES**

Write the adjective form of the following words.

53. semen \_\_\_\_\_
54. prostate \_\_\_\_\_
55. penis \_\_\_\_\_
56. urethra \_\_\_\_\_
57. scrotum \_\_\_\_\_

**ABBREVIATIONS**

Write the meaning of the following abbreviations.

58. BPH \_\_\_\_\_
59. STI \_\_\_\_\_
60. ED \_\_\_\_\_
61. GC \_\_\_\_\_
62. PSA \_\_\_\_\_
63. GU \_\_\_\_\_
64. TURP \_\_\_\_\_

**FOLLOW THE FLOW**

Describing the pathway of semen flow, put the following steps in the correct order by placing the letters "A" through "F" in the spaces provided.

- \_\_\_\_\_ 65. ejaculatory duct delivers sperm to the urethra
- \_\_\_\_\_ 66. sperm cells, mixed with other secretions, travel through the prostate gland
- \_\_\_\_\_ 67. sperm cells mix with secretions from the seminal vesicle
- \_\_\_\_\_ 68. sperm is propelled through ductus deferens
- \_\_\_\_\_ 69. sperm cells are manufactured and stored in the epididymis
- \_\_\_\_\_ 70. cells travel in the urethra through the penis to be released

**WORD BUILDING**

Write a word for the following definitions using the word parts given. Each word part can be used more than once.

-ar	-tomy	-graphy	-genesis	spermat/o	vas/o	-plasty	-itis	-ic	-cyte	-lysis	vesicul/o
-----	-------	---------	----------	-----------	-------	---------	-------	-----	-------	--------	-----------

71. plastic repair of the ductus deferens \_\_\_\_\_
72. destruction of sperm cells \_\_\_\_\_
73. pertaining to the seminal vesicle \_\_\_\_\_
74. x-ray study of the vas deferens \_\_\_\_\_
75. inflammation of the seminal vesicle \_\_\_\_\_
76. pertaining to spermatozoa \_\_\_\_\_
77. cell that develops into a sperm cell \_\_\_\_\_
78. incision of the ductus deferens \_\_\_\_\_
79. formation of spermatozoa \_\_\_\_\_
80. radiographic study of the seminal vesicle \_\_\_\_\_

**WORD ANALYSIS**

Define the following words, and give the meaning of the word parts in each. Use a dictionary if necessary.

81. hydrocelectomy (*hi-dro-se-LEK-to-me*)

- a. hydr/o \_\_\_\_\_
- b. -cele \_\_\_\_\_
- c. ecto- \_\_\_\_\_
- d. tom/o \_\_\_\_\_
- e. -y \_\_\_\_\_

82. spermicidal (*sper-mih-SI-dal*)

- a. sperm/i \_\_\_\_\_
- b. -cide \_\_\_\_\_
- c. -al \_\_\_\_\_

83. cryptorchidism (*krip-TOR-kid-izm*)

- a. crypt- \_\_\_\_\_
- b. orchid/o \_\_\_\_\_
- c. -ism \_\_\_\_\_

84. vasovesiculitis (*vas-o-veh-sik-u-LI-tis*)

- a. vas/o \_\_\_\_\_
- b. vesicul/o \_\_\_\_\_
- c. -itis \_\_\_\_\_

85. polyspermia

- a. poly- \_\_\_\_\_
- b. sperm/o \_\_\_\_\_
- c. -ia \_\_\_\_\_

# Additional Case Studies

## Case Study 15-1: Herniorrhaphy and Vasectomy

Derek, a 48 y/o married dock worker with three children, had inguinal bulging and pain on exertion when he lifted heavy objects. An occupational health service advised a surgical referral. The surgeon diagnosed Derek with bilateral direct inguinal hernias and suggested that he not delay surgery, although he was not at high risk for a strangulated hernia. Derek asked the surgeon if he could also be sterilized at the same time. He was scheduled for bilateral inguinal herniorrhaphy and elective vasectomy.

During the herniorrhaphy procedure, an oblique incision was made in each groin. The incision continued through the muscle layers by either resecting or splitting the muscle fibers. The spermatic vessels and vas deferens were identified, separated, and gently retracted.

The spermatic cord was examined for an indirect hernia. Repair began with suturing the defect in the rectus abdominis muscles, transverse fascia, cremaster muscle, external oblique aponeurosis, and Scarpa fascia with heavy-gauge synthetic nonabsorbable suture material.

The vasectomy began with the identification of the vas deferens through the scrotal skin. An incision was made, and the vas was gently dissected and retracted through the opening. Each vas was clamped with a small hemostat, and a 1-cm length was resected. Both cut ends were coagulated with electrosurgery and tied independently with a fine-gauge absorbable suture material. The testicles were examined, and the scrotal incision was closed with an absorbable suture material.

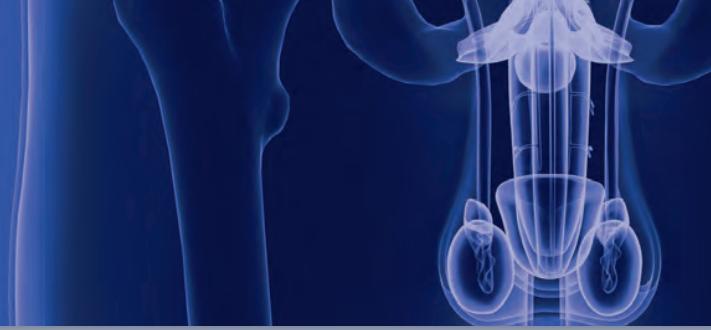### Case Study 15-1 Questions

**Multiple Choice.** Select the best answer, and write the letter of your choice to the left of each number.

- |   |  |
|---|--|
| <p>_____ 1. The term for male sterilization surgery is</p> <ul style="list-style-type: none"><li>a. herniorrhaphy</li><li>b. circumcision</li><li>c. vagotomy</li><li>d. vasectomy</li></ul> <p>_____ 2. An oblique surgical incision follows which direction?</p> <ul style="list-style-type: none"><li>a. slanted or angled</li><li>b. superior to inferior</li><li>c. lateral</li><li>d. circumferential</li></ul> | <p>_____ 3. When the ends of the vas were coagulated with electrosurgery, they were</p> <ul style="list-style-type: none"><li>a. dilated</li><li>b. sealed</li><li>c. sutured</li><li>d. clamped</li></ul> |
|---|--|

Write a term from the case study with the following meanings.

- 4. surgical repair of a weak abdominal muscle in the groin area on both sides \_\_\_\_\_
- 5. entrapment of a bowel loop in a hernia \_\_\_\_\_
- 6. inflammation of the glans penis \_\_\_\_\_
- 7. narrowing of the distal opening of the foreskin \_\_\_\_\_



## Case Study 15-2: Erectile Dysfunction

Diego, a 67 y/o attorney, was at his annual appointment with his internist when he decided to discuss what he considered an embarrassing subject, erectile dysfunction (ED). Diego was happily married with four grown children and had continued to enjoy an active sexual relationship with his wife, until recently. He was having difficulty sustaining an erection. He had seen so much media publicity on this subject that he decided to bring it up with his physician. At the conclusion of the appointment, the internist ruled out any psychogenic causes or adverse effects of medications, such as an antidepressant or an antihypertensive, that could predispose to ED. He recommended that Diego schedule a follow-up visit to his urologist to make certain there were no underlying physical factors that would contribute to his impotence.

Diego made an appointment with the urologist whom he had seen about 10 years ago when he was diagnosed with BPH. At that time, the physician had reviewed various therapies with Diego, so Diego felt comfortable discussing his present concerns.

The urologist's examination ruled out trauma, vascular disorders, or tumors. It was decided to have Diego try an ED medication. The physician explained that the impotence agents work by targeting the physiologic mechanisms of erection. They promote vasodilation to increase blood flow to the penis. Side effects of the medications were also discussed. Diego was relieved that he had no tumor or other disease condition. He understood the therapy plan and left with follow-up instructions.

15

### Case Study 15-2 Questions

**Multiple Choice.** Select the best answer, and write the letter of your choice to the left of each number.

- |  |   |
|--|---|
| <p>_____ 1. A urologist is a physician who treats health and disease conditions of the</p> <ul style="list-style-type: none"><li>a. male reproductive system</li><li>b. urinary system</li><li>c. digestive system</li><li>d. a and b</li></ul> <p>_____ 2. Impotence is a condition that</p> <ul style="list-style-type: none"><li>a. precedes a vasectomy</li><li>b. is synonymous with ED</li><li>c. refers to the inability to maintain penile erection</li><li>d. b and c</li></ul> | <p>_____ 3. BPH is a condition of the prostate gland that</p> <ul style="list-style-type: none"><li>a. is cancerous</li><li>b. causes impotence</li><li>c. requires vasodilation agents as treatment</li><li>d. may cause urinary retention and infection</li></ul> <p>_____ 4. The ED drugs Viagra and Cialis target the physiologic mechanisms of erection by</p> <ul style="list-style-type: none"><li>a. increasing urinary and semen flow</li><li>b. dilating arteries in the penis to increase blood flow</li><li>c. increasing neurotransmitters to treat underlying psychogenic causes</li><li>d. b and c</li></ul> |
|--|---|

Write a term from the case study with the following meanings.

- 5. originating in the mind \_\_\_\_\_
- 6. widening of blood vessels \_\_\_\_\_
- 7. drug for treatment of high blood pressure \_\_\_\_\_

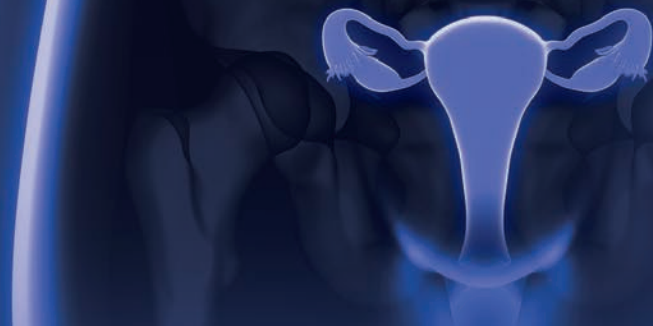

# Female Reproductive System; Pregnancy and Birth

## Pretest

**Multiple Choice.** Select the best answer, and write the letter of your choice to the left of each number. To check your answers go to Appendix 11.

- 
- \_\_\_\_\_ 1. The female gonad is the
    - a. uterus
    - b. cervix
    - c. ovary
    - d. testis
  - \_\_\_\_\_ 2. The two ovarian hormones are
    - a. testosterone and estrogen
    - b. estrogen and progesterone
    - c. thyroxine and progesterone
    - d. progesterone and testosterone
  - \_\_\_\_\_ 3. Use of artificial methods to prevent fertilization is termed
    - a. conception
    - b. coitus
    - c. contraception
    - d. gestation
  - \_\_\_\_\_ 4. During the first 2 months of growth, the developing offspring is called a(n)
    - a. neonate
    - b. embryo
    - c. zygote
    - d. fetus
  - \_\_\_\_\_ 5. The structure that nourishes the developing fetus is the
    - a. mammary gland
    - b. cervix
    - c. placenta
    - d. follicle
  - \_\_\_\_\_ 6. Production of milk is technically called
    - a. ovulation
    - b. lactation
    - c. corpus luteum
    - d. parturition
  - \_\_\_\_\_ 7. The roots *metr/o* and *hyster/o* mean
    - a. uterus
    - b. vagina
    - c. follicle
    - d. ovary
  - \_\_\_\_\_ 8. Any disorder present at birth is described as
    - a. hereditary
    - b. genetic
    - c. congenital
    - d. familial

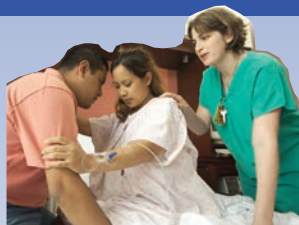

## Learning Objectives

After careful study of this chapter, you should be able to:

- 1 Describe the female reproductive tract, and give the function of each part. **P512**
- 2 Describe the structure and function of the mammary glands. **P514**
- 3 Outline the events in the menstrual cycle. **P514**
- 4 List three categories of contraception with examples of each. **P515**
- 5 Describe seven disorders of the female reproductive system. **P521**
- 6 Outline the major events that occur in the first 2 months after fertilization. **P528**
- 7 Describe the structure and function of the placenta. **P528**
- 8 Describe two adaptations in fetal circulation, and cite their purposes. **P530**
- 9 Describe the three stages of childbirth. **P531**
- 10 List the hormonal and nervous controls over lactation. **P532**
- 11 Identify and use roots pertaining to the female reproductive system, pregnancy, and birth. **PP518, 534**
- 12 Describe six disorders of pregnancy and birth. **P535**
- 13 Define two types of congenital disorders and give examples each. **P536**
- 14 Interpret abbreviations used in referring to reproduction. **PP528, 543**
- 15 Analyze the medical terms in several case studies concerning the female reproductive system, pregnancy, and birth. **PP511, 552**

## Case Study: Abigail's Cesarean Section



### Chief Complaint

Abigail is a 29 y/o gravida 2, para 1, at 39 weeks of gestation. Her first pregnancy resulted in a cesarean section. She had had an uneventful

pregnancy with good health, moderate weight gain, good fetal heart sounds, and no signs or symptoms of pregnancy-induced hypertension. Abigail went to the hospital when she realized she was going into labor.

### Examination

Abigail had been in active labor for several hours, fully effaced and dilated, yet unable to progress. Her obstetrician ordered an x-ray pelvimetry test that revealed cephalopelvic disproportion (CPD) with the fetus in the right occiput posterior position. Changes in fetal heart rate indicated fetal distress. Abigail was transported to the OR for an emergency C-section under spinal anesthesia.

### Clinical Course

After being placed in the supine position, Abigail had a urethral catheter inserted, and her abdomen was prepped

with antimicrobial solution. After draping, a transverse suprapubic incision was made. Dissection was continued through the muscle layers to the uterus, with care not to nick the bladder. The uterus was incised through the lower segment, 2 cm from the bladder. The fetal head was gently elevated through the incision while the assistant put gentle pressure on the fundus. The baby's mouth and nose were suctioned with a bulb syringe, and the umbilical cord was clamped and cut. The baby was handed off to an attending pediatrician and OB nurse and placed in a radiant neonate warmer bed. The Apgar score was 9/9. The placenta was gently delivered from the uterus, and the scrub nurse checked for three vessels and filled two sterile test tubes with cord blood for laboratory analysis. Abigail was given an injection of Pitocin to stimulate uterine contraction. The uterus and abdomen were closed, and Abigail was transported to the postanesthesia care unit (PACU).

**Case Study Revisited:** Once you complete this chapter, please review the case follow-up on p. 544.

## Ancillaries *At-A-Glance*

Visit the web resource to access the following resources.

### Learning Resources

- eBook
- A&P Module with Heart & Lung Sounds
- Image Bank

- TestPrep
- Animations
- Audio Pronunciation Glossary

## Introduction

As in males, the female reproductive tract consists of internal organs and external genitalia. The breasts, or mammary glands, although not part of the reproductive system, are usually included with a discussion of this system, as their purpose is to nourish an infant.

In contrast to the continuous gametogenesis in males, formation of the female gamete is cyclic, with an egg released midway in the menstrual cycle. Each month, the **uterus** is prepared to receive a fertilized egg. If fertilization occurs, the developing offspring is nourished and protected by the placenta and surrounding fluids until birth. If the released egg is not fertilized, the lining of the uterus is sloughed off in menstruation.

## The Female Reproductive System

### THE OVARIES

The female gonads are the paired **ovaries** (singular: ovary) that are held by ligaments in the pelvic cavity on either side of the uterus). These ligaments, as well as the ovaries and uterine tubes, are contained within the broad ligaments, folds of the peritoneum that anchor the uterus to the lateral body wall (**FIG. 16-1**). It is within the ovaries that the female gametes, the eggs or **ova** (singular: ovum), develop. Every month, several ova ripen, each within a cluster of cells called an **ovarian follicle**. At the time of **ovulation**, usually only one ovum is released from an ovary, and the remainder of the ripening ova degenerate. The follicle remains behind and continues to function for about 2 weeks if the ovum is not fertilized and for about 2 months if the ovum is fertilized.

### THE UTERINE TUBES, UTERUS, AND VAGINA

After ovulation, the ovum travels into a **uterine tube**, also called the **fallopian tube**, attached to the upper lateral portion of the uterus (see **FIG. 16-1**). This tube arches above the ovary and has finger-like projections called **fimbriae** that sweep the released ovum into the uterine tube. If fertilization takes place, it typically occurs in a uterine tube.

The uterus is the organ that nourishes the developing offspring. It is pear-shaped, with an upper rounded fundus, a triangular cavity, and a lower narrow **cervix** that projects into the **vagina**. The recess around the cervix in the superior vagina is the **fornix**. At the posterior cervix, the peritoneum dips downward to form a blind pouch, the **rectouterine pouch**, the lowest point of the peritoneal cavity. This region is also called the *cul-de-sac*, from French, meaning “bottom of the bag.” The innermost layer of the uterine wall, the **endometrium**, has a rich blood supply. It receives the fertilized ovum and becomes part of the placenta during pregnancy. The endometrium is shed during the menstrual period if no fertilization occurs. The muscle layer of the uterine wall is the **myometrium**.

The vagina is a muscular tube that receives the penis during intercourse, functions as a birth canal, and transports the menstrual flow out of the body (see **FIG. 16-1**).

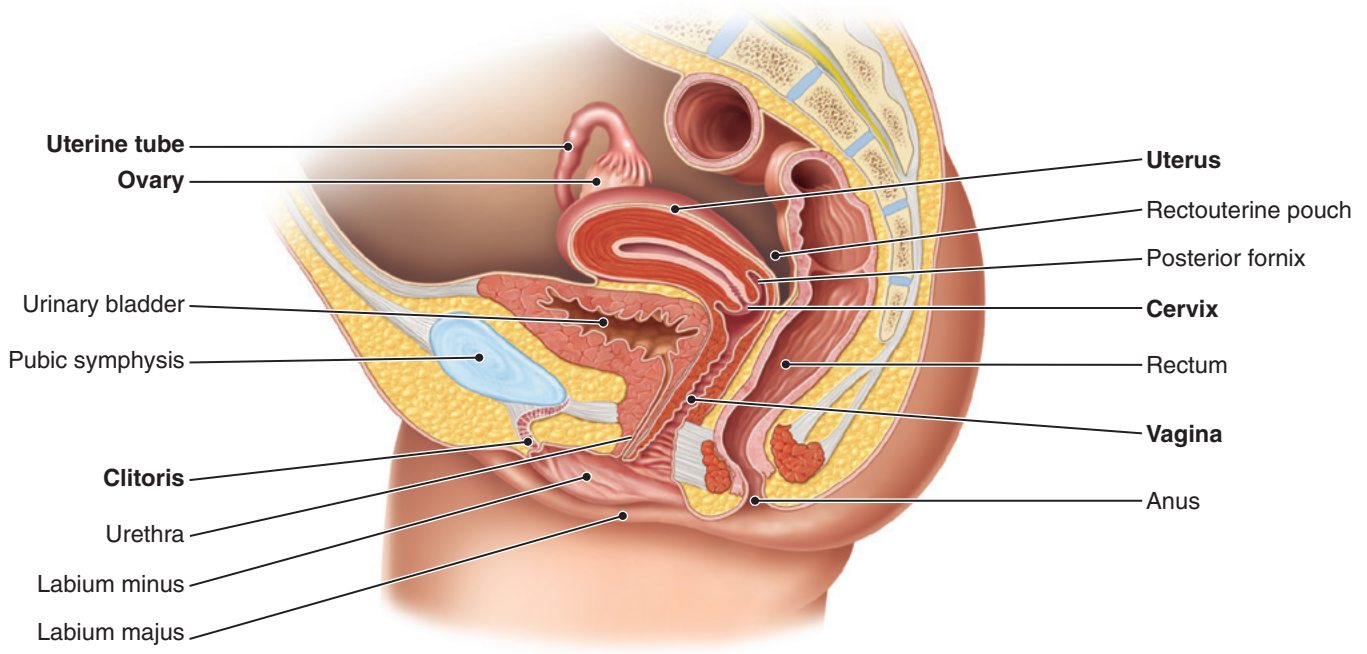
### THE EXTERNAL GENITAL ORGANS

All of the external female genitalia together are called the **vulva** (**FIG. 16-2**). This includes the large outer **labia majora** (singular: labium majus) and small inner **labia minora** (singular: labium minus) that enclose the vaginal and urethral openings. The **clitoris**, anterior to the urethral opening, is similar in developmental origin to the penis and responds to sexual stimulation. The vulva also includes the openings of ducts from two small glands on either side of the vagina that secrete mucus for lubrication during intercourse. These are the **greater vestibular glands** or *Bartholin glands*.

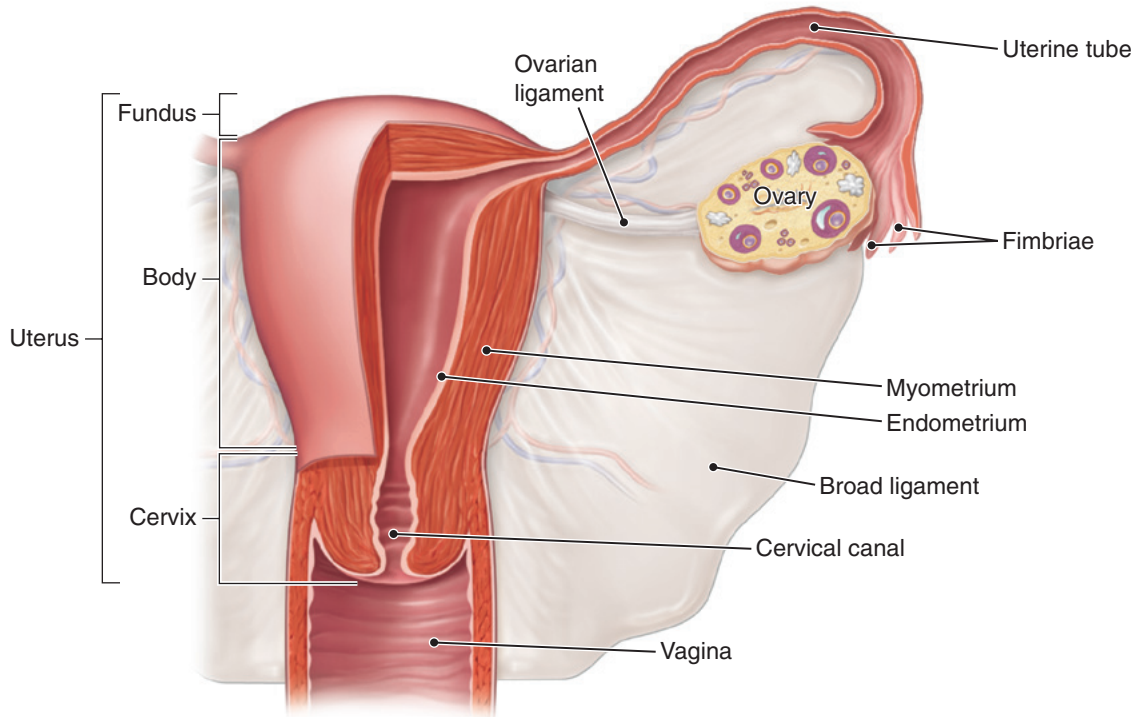
In both males and females, the region between the thighs from the external genital organs to the anus is the **perineum**. During childbirth, an incision may be made between the vagina and the anus to facilitate birth and prevent the tearing of tissue, a procedure called an *episiotomy*. (This procedure is actually a perineotomy, as the root *episi/o* means “vulva.”)

## The Mammary Glands

The **mammary glands**, or breasts, are not a part of the female reproductive system itself, but are included in this chapter as they function in providing infant nourishment after birth, as

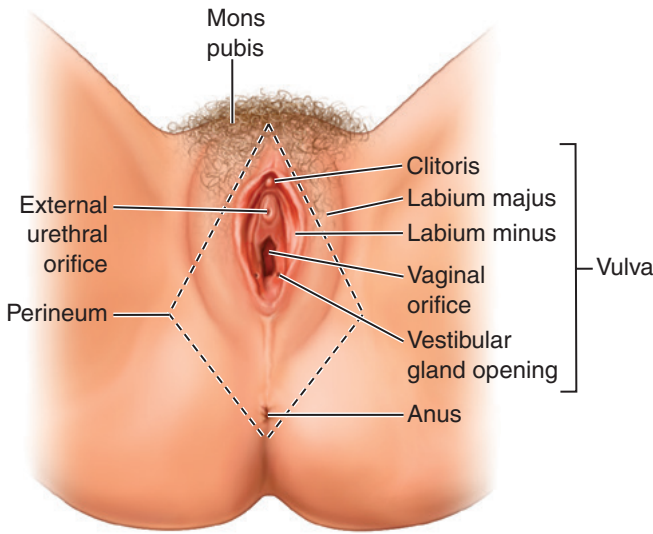


**A Sagittal view**



**B Frontal view**

**FIGURE 16-1 Female reproductive system.** **A.** As seen in sagittal section, the internal female genitalia are located between structures of the urinary and gastrointestinal systems, which are also shown. The reproductive structures are labeled in bold type. **B.** Ligaments hold the uterus and ovaries in place.

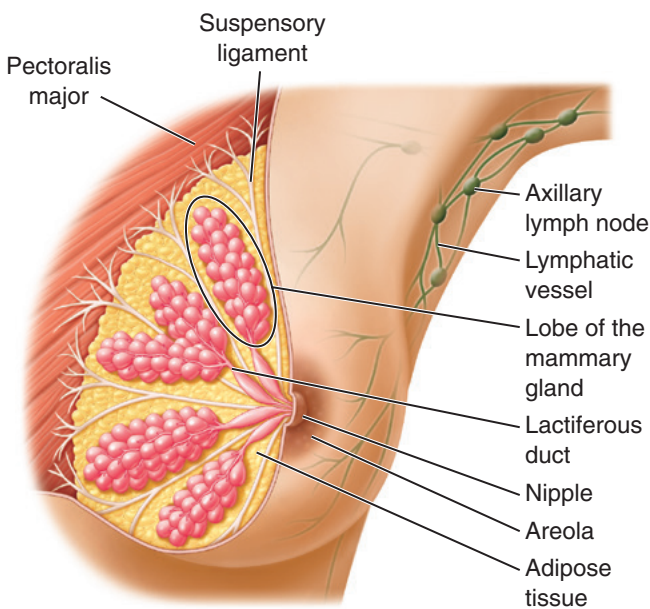


**FIGURE 16-2 The external female genitalia.** The vulva is shown along with nearby structures and the outlines of the perineum. The obstetrical perineum extends from the vagina to the anus.

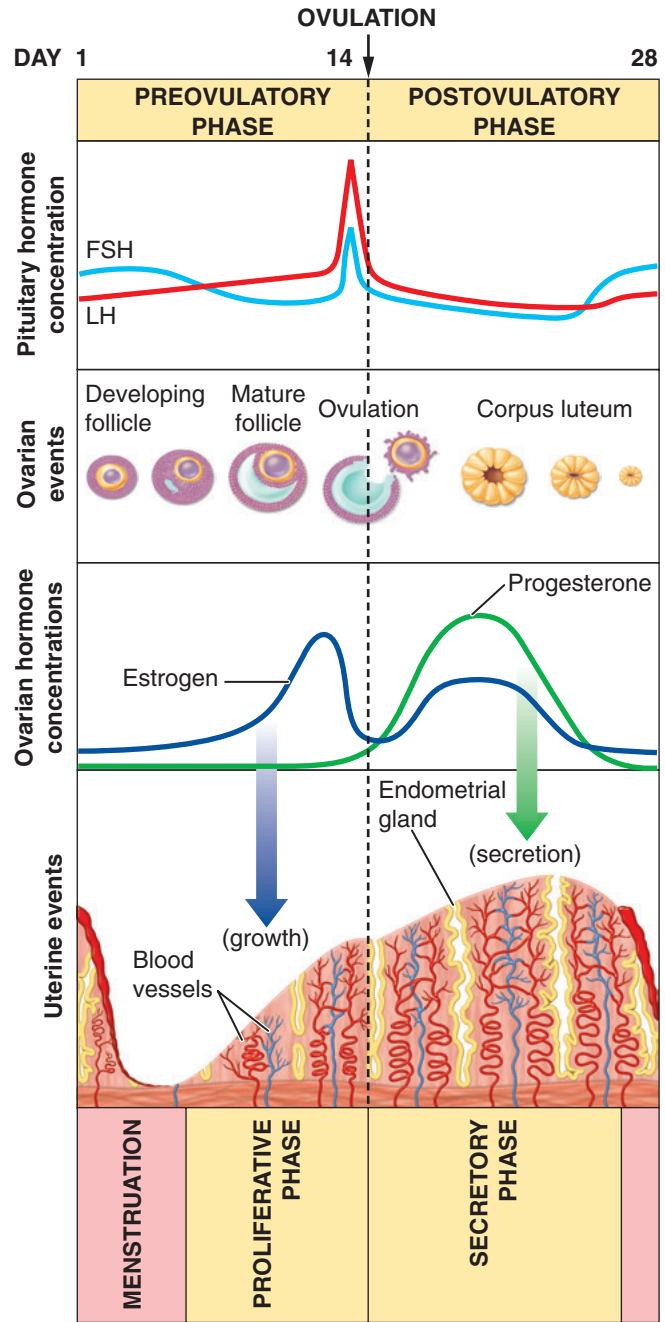
discussed later. The breasts are composed mainly of glandular tissue and fat (FIG. 16-3). The milk secreted by the lactiferous glands is carried in ducts to the nipple.

### The Menstrual Cycle

Female reproductive activity normally begins during puberty with **menarche**, the first menstrual period. Each month, the menstrual cycle is controlled, as is male reproductive activity, by hormones from the anterior pituitary gland.



**FIGURE 16-3 Section of the breast (mammary gland).** The lactiferous glands are divided into lobes containing milk ducts that converge at the nipple.



**FIGURE 16-4 The menstrual cycle.** Changes in pituitary and ovarian hormones, the ovary, and the uterus are shown during an average 28-day menstrual cycle with ovulation on day 14. Phases in the ovary are named for follicular development and formation of the corpus luteum. Phases in the uterus are named for changes in the endometrium.

**Follicle-stimulating hormone (FSH)** begins the cycle by causing the ovum to ripen in the ovarian follicle (FIG. 16-4). The follicle secretes **estrogen**, a hormone that starts endometrial development in preparation for the fertilized egg.

A second pituitary hormone, **luteinizing hormone (LH)**, triggers ovulation and conversion of the follicle to the **corpus luteum**. This structure, left behind in the ovary,

secretes **progesterone** and estrogen, which further the endometrial growth. If no fertilization occurs, hormone levels decline, and the endometrium sloughs off in the process of **menstruation**.

The average menstrual cycle lasts 28 days, with the first day of menstruation taken as day 1 and ovulation typically occurring on about day 14. Throughout the cycle, estrogen and progesterone feed back to the pituitary to regulate the production of FSH and LH. Hormonal birth control methods act by supplying estrogen and progesterone, which inhibit FSH and LH release from the pituitary and prevent ovulation while not interfering with menstruation. The menstrual period that follows withdrawal of the hormones is anovulatory (*an-OV-u-lah-tor-e*); that is, it is not preceded by ovulation.

**FIGURE 16-4** shows changes occurring simultaneously in the ovary and uterus during the course of one menstrual cycle under the effects of pituitary and ovarian hormones. The time before ovulation is described as the follicular phase in the ovary, because it encompasses development of the ovarian follicle. The uterus during this time is in the proliferative phase, marked by endometrial growth. After ovulation, the ovary is in the luteal phase with conversion of the follicle to the corpus luteum. The uterus is then in a secretory phase, as its glands are actively preparing the endometrium for possible implantation of a fertilized egg.

## MENOPAUSE

**Menopause** is the cessation of monthly menstrual cycles. This change generally occurs between the ages of 45 and 55 years. Reproductive hormone levels decline, and ovarian ova gradually degenerate. Some women experience unpleasant symptoms, such as hot flashes, headaches, insomnia, mood swings, and urinary problems. There is also some atrophy of the reproductive tract with vaginal dryness. Most importantly, the decline in estrogen levels is associated with bone weakening (osteoporosis).

Physicians may prescribe hormone replacement therapy (HRT) to alleviate menopausal symptoms. This treatment, also called menopausal hormone therapy (MHT), usually consists of administering estrogen in combination with progestin (*pro-JES-tin*), a synthetic progesterone, given to minimize the risk of endometrial cancer. Estrogen replacement reduces bone loss associated with aging. However, concerns about HRT safety have caused reconsideration of this therapy beyond the early postmenopausal years. Studies with the most widely used form of HRT showed an increased risk of endometrial cancer and breast cancer and an increased risk of thrombosis and embolism, especially in women who smoke. All these risks increase with the duration of therapy, so HRT should be given at the lowest effective dose for the shortest possible time. Women with a history or a family history of breast cancer or circulatory problems should not take HRT. Studies are ongoing on HRT safety and the use of estrogen alone for women who have no uterus.

Aside from HRT, antidepressants and vitamin E may help to relieve menopausal symptoms; locally applied estrogen and moisturizers relieve vaginal dryness. Nonhormonal drugs that increase bone density are also available if needed. As always, exercise and a balanced diet with adequate calcium are important in maintaining health throughout life.

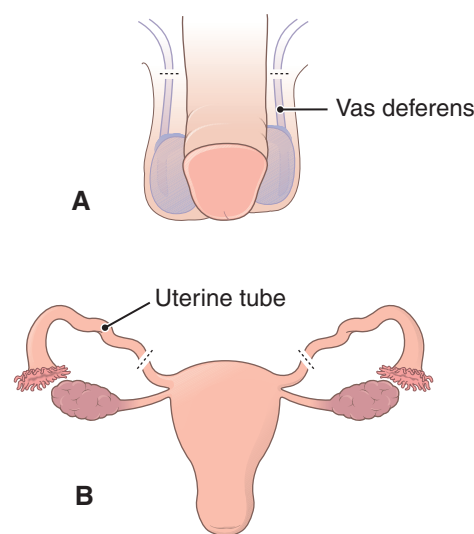
## Contraception

**Contraception** is the use of artificial methods to prevent fertilization of the ovum or its implantation in the uterus. It is the most common method of birth control. Temporary contraceptive methods function to:

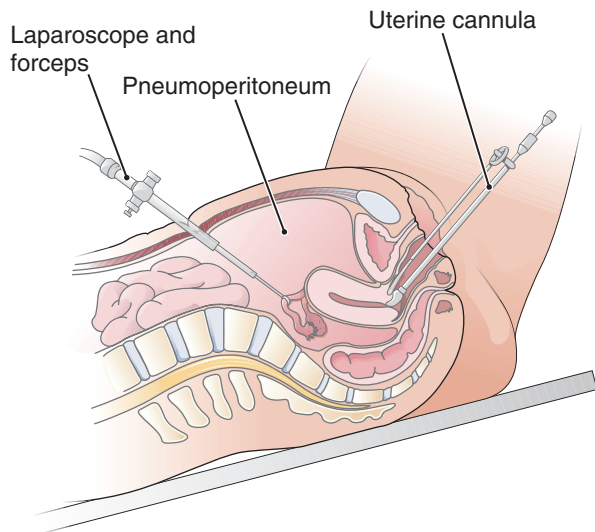
- Block sperm penetration of the uterus (e.g., condom, diaphragm).
- Prevent implantation of the fertilized egg (e.g., intrauterine device or IUD).
- Prevent ovulation (e.g., hormones). Hormonal methods differ in dosage and route of delivery, such as oral intake (the birth control pill), injection, skin patch, and vaginal ring.

The so-called “morning-after pill” is intended for emergency contraception. It considerably reduces the chance of pregnancy if taken within 72 hours after unprotected sexual intercourse. One such product, Plan B, consists of two progestin doses taken 12 hours apart.

Surgical sterilization provides the most effective and usually permanent contraception. In males, this procedure is a vasectomy; in females, surgical sterilization is a **tubal ligation**, in which uterine tubes are cut and tied on both sides (**FIG. 16-5**). Laparoscopic surgery through the abdominal



**FIGURE 16-5 Sterilization. A. Vasectomy. B. Tubal ligation.**



**FIGURE 16-6 Laparoscopic sterilization.** The peritoneal cavity is inflated (pneumoperitoneum), and the uterine tubes are cut laparoscopically through a small incision.

wall is the preferred method for performing the procedure (FIG. 16-6).

RU486 (mifepristone) is more widely used for birth control in other countries than in the United States. It terminates an early pregnancy by blocking progesterone, causing the endometrium to break down. Technically, RU486 is an abortion-causing agent (abortifacient), not a contraceptive.

**BOX 16-1** describes the main contraceptive methods currently in use. Each has advantages and disadvantages over other methods, but they are listed roughly in order of decreasing effectiveness. Note that only male and female condoms protect against the spread of STIs.



## FOR YOUR REFERENCE

BOX 16-1

### Main Methods of Birth Control Currently in Use

Method	Description
<b>SURGICAL</b>	
<b>vasectomy/tubal ligation</b>	cutting and tying the tubes that carry the gametes
<b>HORMONAL</b>	
<b>birth control pills</b>	estrogen and progesterin or progesterin alone taken orally to prevent ovulation
<b>birth control shot</b>	injection of synthetic progesterone every 3 months to prevent ovulation
<b>birth control patch</b>	adhesive patch placed on body that administers estrogen and progesterin through the skin; left on for 3 weeks and removed for a fourth week
<b>birth control ring</b>	flexible ring inserted into vagina that releases hormones internally; left in place for 3 weeks and removed for a fourth week
<b>BARRIER</b>	
<b>condom</b>	sheath that prevents sperm cells from contacting an ovum; a male condom fits over an erect penis; a female condom fits into the vagina and covers the cervix
<b>diaphragm (with spermicide)</b>	rubber cap that fits over cervix and prevents sperm entrance
<b>contraceptive sponge (with spermicide)</b>	soft, disposable foam disk containing spermicide, which is moistened with water and inserted into vagina
<b>intrauterine device (IUD)</b>	metal or plastic device inserted into uterus through vagina; prevents fertilization and implantation by release of copper or birth control hormones
<b>OTHER</b>	
<b>spermicide</b>	chemicals used to kill sperm; best when used in combination with a barrier method
<b>fertility awareness</b>	abstinence during fertile part of cycle as determined by menstrual history, basal body temperature, or quality of cervical mucus

## Terminology *Key Terms*

The terms listed below are emphasized in this chapter. Knowing them will help you organize and prioritize your learning. These boldface terms are also found, collectively, with all chapter key terms in the Glossary.

### Female Reproductive System

#### Normal Structure and Function

<b>cervix</b> <i>SER-viks</i>	Neck; usually means the lower narrow portion (neck) of the uterus (root: cervic/o); also called the cervix uteri ( <i>U-ter-i</i> )
<b>clitoris</b> <i>KLIT-o-ris</i>	A small erectile body anterior to the urethral opening that is similar in developmental origin to the penis (roots: clitor/o, clitorid/o)
<b>contraception</b> <i>kon-trab-SEP-shun</i>	The prevention of pregnancy
<b>corpus luteum</b> <i>KOR-pus LU-te-um</i>	The small yellow structure that develops from the ovarian follicle after ovulation and secretes progesterone and estrogen
<b>endometrium</b> <i>en-do-ME-tre-um</i>	The inner lining of the uterus
<b>estrogen</b> <i>ES-tro-jen</i>	A group of hormones that produce female characteristics and prepare the uterus for the fertilized egg; the most active of these is estradiol
<b>fallopian tube</b> <i>fah-LO-pe-an</i>	See uterine tube
<b>fimbriae</b> <i>FIM-bre-e</i>	The long finger-like extensions of the uterine tube that wave to capture the released ovum (see <b>FIG. 16-1</b> ) (singular: fimbria)
<b>follicle-stimulating hormone (FSH)</b>	A hormone secreted by the anterior pituitary that acts on the gonads; in males, FSH stimulates Sertoli cells and promotes sperm development; in females, it stimulates ripening of ova in the ovary
<b>fornix</b> <i>FOR-niks</i>	An arch-like space, such as the space between the uppermost wall of the vagina and the cervix (see <b>FIG. 16-1</b> ); from Latin meaning “arch”
<b>greater vestibular gland</b> <i>ves-TIB-u-lar</i>	A small gland that secretes mucus through a duct that opens near the vaginal orifice; also called Bartholin ( <i>BAR-to-lin</i> ) gland (see <b>FIG. 16-2</b> )
<b>labia majora</b> <i>LA-be-ab mah-JOR-ab</i>	The two large folds of skin that form the sides of the vulva (root labi/o means “lip”) (singular: labium majus)
<b>labia minora</b> <i>LA-be-ab mi-NOR-ab</i>	The two small folds of skin within the labia majora (singular: labium minus)
<b>luteinizing hormone (LH)</b> <i>LU-te-in-i-zing</i>	A hormone secreted by the anterior pituitary that acts on the gonads; in males, it stimulates the interstitial cells to produce testosterone; in females, it stimulates ovulation and corpus luteum formation
<b>mammary gland</b> <i>MAM-ab-re</i>	A specialized gland capable of secreting milk in the female (roots: mamm/o, mast/o); the breast
<b>menarche</b> <i>men-AR-ke</i>	The first menstrual period, which normally occurs during puberty
<b>menopause</b> <i>MEN-o-pawz</i>	Cessation of menstrual cycles in the female
<b>menstruation</b> <i>men-stru-A-shun</i>	The cyclic discharge of blood and mucosal tissues from the lining of the nonpregnant uterus (roots: men/o, mens); menstrual period, menses ( <i>MEN-seze</i> )
<b>myometrium</b> <i>mi-o-ME-tre-um</i>	The muscular wall of the uterus
<b>ovarian follicle</b> <i>o-VAR-e-an FOL-ib-kl</i>	The cluster of cells in which the ovum ripens in the ovary

(continued)



## Terminology

## Key Terms (Continued)

<b>ovary</b> <i>O-vah-re</i>	A female gonad (roots: <i>ovari/o</i> , <i>oophor/o</i> )
<b>ovulation</b> <i>ov-u-LA-shun</i>	The release of a mature ovum from the ovary (from <i>ovule</i> , meaning “little egg”)
<b>ovum</b> <i>O-vum</i>	The female gamete or reproductive cell (roots: <i>oo</i> , <i>ov/o</i> ) (plural: ova)
<b>perineum</b> <i>per-ih-NE-um</i>	The region between the thighs from the external genitalia to the anus (root: <i>perine/o</i> )
<b>progesterone</b> <i>pro-JES-ter-one</i>	A hormone produced by the corpus luteum and the placenta that maintains the endometrium for pregnancy
<b>rectouterine pouch</b> <i>rek-to-U-ter-in</i>	A blind pouch, such as the recess between the rectum and the uterus; the cul-de-sac or pouch of Douglas (see <b>FIG. 16-1</b> )
<b>tubal ligation</b> <i>TU-bal li-GA-shun</i>	Surgical constriction of the uterine tubes to produce sterilization (see <b>FIGS. 16-5</b> and <b>16-6</b> )
<b>uterine tube</b> <i>U-ter-in</i>	A tube extending from the upper lateral portion of the uterus that carries the ovum to the uterus (root: <i>salping/o</i> ); also called fallopian ( <i>fab-LO-pe-an</i> ) tube
<b>uterus</b> <i>U-ter-us</i>	The organ that receives the fertilized egg and maintains the developing offspring during pregnancy (roots: <i>uter/o</i> , <i>metr</i> , <i>hyster/o</i> ) ( <b>BOX 16-2</b> )
<b>vagina</b> <i>vah-JI-nah</i>	The muscular tube between the cervix and the vulva (roots: <i>vagin/o</i> , <i>colp/o</i> )
<b>vulva</b> <i>VUL-va</i>	The external female genital organs (roots: <i>vulv/o</i> , <i>episi/o</i> )



## FOCUS ON WORDS

## Crazy Ideas

BOX 16-2

Most women would be surprised to learn the origin of the root *hyster/o*, used for the uterus. It comes from the same root as the words hysterical and hysterics and was based on the very old belief that the womb was the source of mental disturbances in women.

A similar history lies at the origin of the word *hypochondriac*, a term for someone who has imaginary illnesses. The *hypochondriac* regions are in the upper portions of the abdomen, an area that the ancients believed was the seat of mental disorders.

## Roots Pertaining to the Female Reproductive System

See **TABLES 16-1** to **16-3**.

Table 16-1		Roots for Female Reproduction and the Ovaries	
Root	Meaning	Example	Definition of Example
<i>gyn/o</i> , <i>gynec/o<sup>a</sup></i>	woman	gynecology <i>gi-neh-KOL-o-je</i>	study of women's diseases
<i>men/o</i> , <i>mens</i>	month, menstruation	premenstrual <i>pre-MEN-stru-al</i>	before a menstrual period

Table 16-1

## Roots for Female Reproduction and the Ovaries (Continued)

Root	Meaning	Example	Definition of Example
oo	ovum, egg cell	oocyte <i>O-o-site</i>	cell that gives rise to an ovum
ov/o, ovul/o	ovum, egg cell	anovulatory <i>an-OV-u-lab-tore-e</i>	absence of egg ripening or of ovulation
ovari/o	ovary	ovariopexy <i>o-var-e-o-PEK-se</i>	surgical fixation of an ovary
oophor/o	ovary	oophorectomy <i>o-of-o-REK-to-me</i>	excision of an ovary

<sup>a</sup>Although the correct pronunciation of this root is *jine* (with a soft *g* and long *i*), it is commonly pronounced with a hard *g* as in *gine* and may also have a short *i*, as in *jin* or *gin*.

## Exercise 16-1

Complete the exercise. To check your answers go to Appendix 11.

Define the following words.

- gynecopathy (*gi-neh-KOP-ab-the*) \_\_\_\_\_
- intermenstrual (*in-ter-MEN-stru-al*) \_\_\_\_\_
- oogenesis (*o-o-JEN-eh-sis*) \_\_\_\_\_
- ovulation (*ov-u-LA-shun*) \_\_\_\_\_
- ovarian (*o-VAR-e-an*) \_\_\_\_\_
- oophoritis (*o-of-o-RI-tis*) \_\_\_\_\_

Write a word for the following definitions.

- rupture (-rhexis) of an ovary \_\_\_\_\_
- pertaining to ovulation \_\_\_\_\_
- profuse bleeding (-hagia) at the time of menstruation \_\_\_\_\_

The word menorrhagia means “menstruation.” Add a prefix to menorrhagia to form words for the following definitions.

- scanty menstrual flow \_\_\_\_\_
- absence of menstruation \_\_\_\_\_
- painful or difficult menstruation \_\_\_\_\_

Use the root *ovari/o* to write words for the following.

- incision into an ovary \_\_\_\_\_
- surgical puncture of an ovary \_\_\_\_\_
- hernia of an ovary \_\_\_\_\_

Use the root *oophor/o* to write words for the following.

- surgical repair of an ovary \_\_\_\_\_
- malignant tumor of the ovary \_\_\_\_\_

Table 16-2

## Roots for the Uterine Tubes, Uterus, and Vagina

Root	Meaning	Example	Definition of Example
salping/o	uterine tube, tube	salpingoplasty <i>sal-PING-o-plas-te</i>	plastic repair of a uterine tube
uter/o	uterus	intrauterine <i>in-trab-U-ter-in</i>	within the uterus
metr/o, metr/i	uterus	metrorrhea <i>me-tro-RE-ab</i>	abnormal uterine discharge
hyster/o	uterus	hysterotomy <i>his-ter-OT-o-me</i>	incision of the uterus
cervic/o	cervix, neck	endocervical <i>en-do-SER-vih-kal</i>	pertaining to the lining of the cervix
vagin/o	vagina	vaginometer <i>vaj-ih-NOM-eh-ter</i>	instrument for measuring the vagina
colp/o	vagina	colpostenosis <i>kol-po-sten-O-sis</i>	narrowing of the vagina

## Exercise 16-2

Complete the exercise. To check your answers go to Appendix 11.

Define the following terms.

1. hystero-graphy (*his-ter-OG-rah-fe*) \_\_\_\_\_
2. metromalacia (*me-tro-mah-LA-she-ah*) \_\_\_\_\_
3. vaginoplasty (*vaj-ih-no-PLAS-te*) \_\_\_\_\_
4. colpodynia (*kol-po-DIN-e-ah*) \_\_\_\_\_
5. salpingectomy (*sal-pin-JEK-to-me*) \_\_\_\_\_
6. uterovesical (*u-ter-o-VES-ih-kal*) \_\_\_\_\_
7. intracervical (*in-trab-SER-vih-kal*) \_\_\_\_\_

Write words for the following.

8. surgical fixation of a uterine tube \_\_\_\_\_
9. radiographic study of the uterine tube \_\_\_\_\_

The root *salping/o* is taken from the word *salpinx*, which means “tube.” Add a prefix to *salpinx* to write a word for the following.

10. collection of fluid in a uterine tube \_\_\_\_\_
11. presence of pus in a uterine tube \_\_\_\_\_

Note how the roots *salping/o* and *oophor/o* are combined to form *salpingo-oophoritis* (inflammation of a uterine tube and ovary). Write a word for the following.

12. surgical removal of a uterine tube and ovary \_\_\_\_\_

Use the roots indicated to write words for the following.

13. surgical fixation of the uterus (hyster/o) \_\_\_\_\_
14. pertaining to the uterus (uter/o) \_\_\_\_\_
15. narrowing of the uterus (metr/o) \_\_\_\_\_

**Exercise 16-2 (Continued)**

16. radiograph of the uterus (hyster/o) and uterine tubes \_\_\_\_\_
17. through the cervix \_\_\_\_\_
18. prolapse of the uterus (metr/o) \_\_\_\_\_
19. hernia of the vagina (colp/o) \_\_\_\_\_
20. inflammation of the vagina (vagin/o) \_\_\_\_\_

**Table 16-3 Roots for the Female Accessory Structures**

Root	Meaning	Example	Definition of Example
vulv/o	vulva	vulvar <i>VUL-var</i>	pertaining to the vulva
episi/o	vulva	epiotomy <i>eh-piz-e-OT-o-me</i>	incision of the vulva
perine/o	perineum	perineal <i>per-ih-NE-al</i>	pertaining to the perineum
clitor/o, clitorid/o	clitoris	clitorectomy <i>klib-to-REK-to-me</i>	excision of the clitoris
mamm/o	breast, mammary gland	mammoplasty <i>mam-o-PLAS-te</i>	plastic surgery of the breast
mast/o	breast, mammary gland	amastia <i>ah-MAS-te-ah</i>	absence of the breasts

**Exercise 16-3**

Complete the exercise. To check your answers go to Appendix 11.

Write a word for the following.

1. excision of the vulva (vulv/o) \_\_\_\_\_
2. suture of the vulva (episi/o) \_\_\_\_\_
3. pertaining to the vagina (vagin/o) and perineum \_\_\_\_\_
4. enlargement of the clitoris \_\_\_\_\_
5. radiographic record of the breast (mamm/o) \_\_\_\_\_
6. inflammation of the breast (mast/o) \_\_\_\_\_
7. excision of the breast \_\_\_\_\_

## Clinical Aspects of Female Reproduction

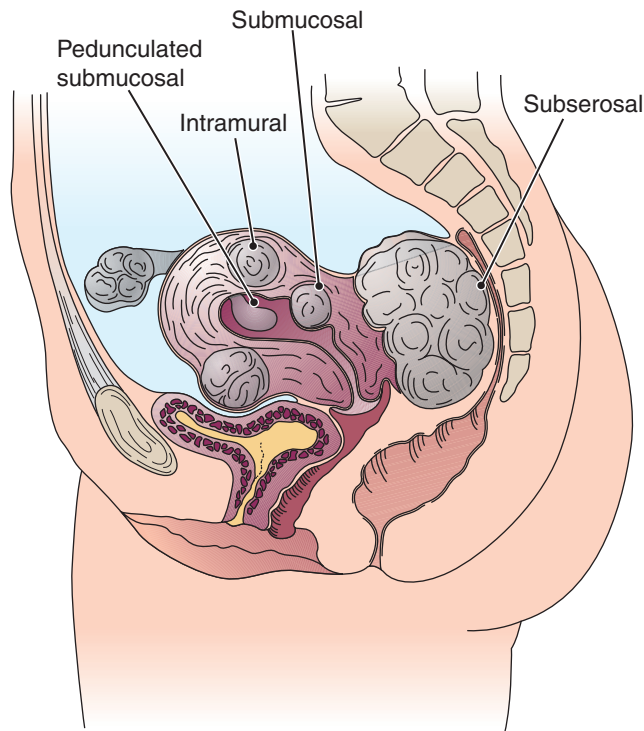
### INFECTION

The major organisms that cause sexually transmitted infections in both men and women are given in **BOX 16-2**.

Genital herpes is a presently incurable viral infection that affects over 25% of adults in the United States. Once infection occurs, the virus lives in the nervous system, causing intermittent outbreaks that may include genital sores,

itching, burning, and urinary problems. The virus is easily spread to sexual partners even if there are no active signs of the disease. Pregnant women can pass the virus to their babies during delivery, resulting in possible disabilities and even death. Some basic hygiene measures and condom use can reduce viral spread.

A fungus that infects the vulva and vagina is *Candida albicans*, causing **candidiasis**. The resultant **vaginitis**, inflammation of the vagina, causes itching and release of a thick, white, cheesy discharge. Pregnancy, diabetes mellitus, and use of antibiotics, steroids, or birth control pills predispose



**FIGURE 16-7 Uterine leiomyomas (fibroids).** Various possible locations are shown. They may be within the uterine wall (intramural), below the mucous membrane (submucosal), on a stalk (pedunculated), or below the outer serous membrane (subserosal). One tumor is shown compressing the urinary bladder and another the rectum.

to this infection. Antifungal agents (mycostatics) are used in treatment.

**Pelvic inflammatory disease (PID)** is the spread of infection from the reproductive organs into the pelvic cavity. It is most often caused by the gonorrhea organism or

by *Chlamydia*, although bacteria normally living in the reproductive tract may also be responsible when conditions allow. PID is a serious disorder that may result in septicemia or shock. Inflammation of the uterine tubes, called **salpingitis**, may close off these tubes and cause infertility.

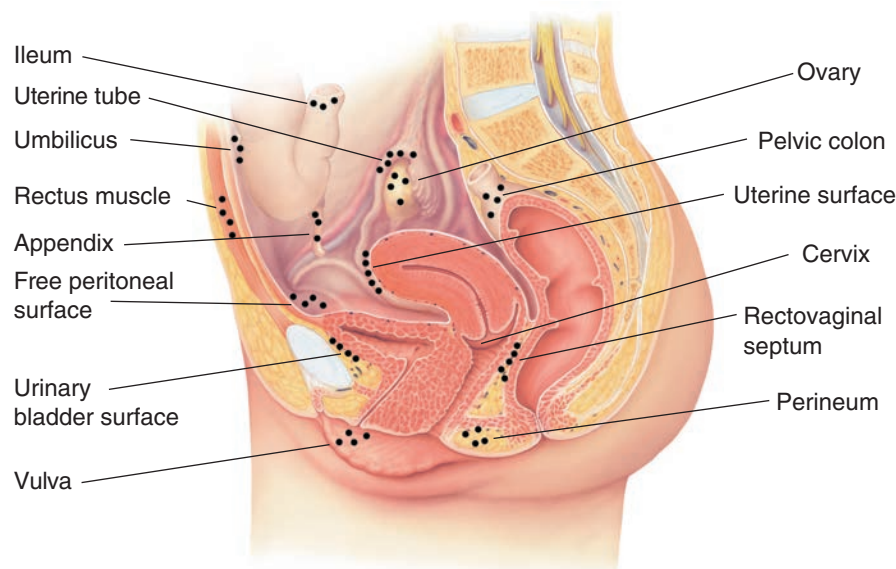
## FIBROIDS

A **fibroid** is a benign smooth muscle tumor usually occurring in the uterine wall, the myometrium (**FIG. 16-7**). This type of growth, technically called a **leiomyoma**, is one of the most common uterine disorders, but it usually causes no symptoms and requires no treatment. However, fibroids may cause heavy menstrual bleeding (menorrhagia) and rectal or bladder pressure. Treatments include:

- Suppression of hormones that stimulate fibroid growth.
- Surgical removal of the fibroids (myomectomy).
- Surgical removal of the uterus, or **hysterectomy**.
- Uterine fibroid embolization (UFE), a method that has reduced the need for hysterectomies. A specially trained radiologist uses a catheter to inject small synthetic particles into a uterine artery. These particles then block blood supply to the fibroid, causing it to shrink.

## ENDOMETRIOSIS

Growth of endometrial tissue outside the uterus is termed **endometriosis**. Commonly, the ovaries, uterine tubes, peritoneum, and other pelvic organs are involved (**FIG. 16-8**). Stimulated by normal hormones, the endometrial tissue causes inflammation, fibrosis, and adhesions in surrounding areas. The results may be pain, menstrual disorders, and infertility. Laparoscopy is used to diagnose endometriosis and also to remove the abnormal tissue.



**FIGURE 16-8 Endometriosis.** Endometrial tissue can grow outside the uterus almost anywhere in the peritoneal cavity, causing inflammation and other complications.

## DYSFUNCTIONAL UTERINE BLEEDING

Menstrual bleeding abnormalities include flow that is too scanty (oligomenorrhea) or too heavy (menorrhagia) and the absence of monthly periods (amenorrhea). **Dysmenorrhea**, painful or difficult menstruation, when it occurs, usually begins at the start of menstruation and lasts 1 to 2 days. **Metrorrhagia**, or intermenstrual bleeding, refers to uterine bleeding between normal menstrual periods, which may indicate a tumor. Together, these disorders are classified as dysfunctional uterine bleeding (DUB). These responses may be caused by hormone imbalances, systemic disorders, or uterine problems. They are most common in adolescence or near menopause. At other times, they are often related to life changes and emotional upset.

## PREMENSTRUAL SYNDROME

Premenstrual syndrome (PMS) describes symptoms that appear during the menstrual cycle's second half and includes emotional changes, fatigue, bloating, headaches, and appetite changes. Possible causes of PMS have been under study. Symptoms may be relieved by hormone therapy, antidepressants, or anti-anxiety medications. Exercise, dietary control, rest, and relaxation strategies may also be helpful. Avoiding caffeine and taking vitamin E supplements may relieve breast tenderness; one should also drink adequate water and limit salt intake.

## POLYCYSTIC OVARIAN SYNDROME

Polycystic ovarian syndrome (PCOS) is discussed here because the first-described symptoms of this disorder were enlarged ovaries with multiple cysts. These signs are not always present in PCOS, although the ovaries do show abnormalities. PCOS is an endocrine disorder involving increased androgen and estrogen secretion that interferes with normal secretion of pituitary FSH and LH. Some effects include:

- Anovulation and infertility
- Scant or absent menses (oligomenorrhea or amenorrhea)
- Excessive hair growth (hirsutism), caused by excess androgen (male hormone)
- Resistance to insulin, a hormone that lowers blood sugar, resulting in symptoms of diabetes mellitus
- Obesity

PCOS is treated with hormones to regulate hormonal imbalance, drugs to increase responsiveness to insulin, weight reduction (estrogen is produced in adipose tissue), and sometimes partial removal of the ovaries.

## CANCER OF THE FEMALE REPRODUCTIVE TRACT

### Endometrial Cancer

Cancer of the endometrium is the most common cancer of the female reproductive tract. Women at risk should have biopsies taken regularly because endometrial cancer is not always detected by **Pap** (Papanicolaou) **smear**, a simple

histologic test. Treatment consists of hysterectomy (removal of the uterus) and sometimes radiation therapy. A small percentage of cases occur after endometrial overgrowth (hyperplasia). This tissue can be removed by **dilation and curettage** (D&C), in which the cervix is widened and the lining of the uterus is scraped with a curette.

### Cervical Cancer

Almost all patients with cervical cancer have been infected with human papillomavirus (HPV), a virus that causes genital warts. Incidence is also related to high sexual activity and other sexually transmitted viral infections, such as herpes. A vaccine against the most prevalent HPV strains is available and is recommended for females at 11 to 12 years of age.

In the 1940s and 1950s, the synthetic steroid DES (diethylstilbestrol) was given to prevent miscarriages. A small percentage of daughters born to women treated with this drug have shown an increased risk for cancer of the cervix and vagina. These women need to be examined regularly.

Cervical carcinoma is often preceded by abnormal growth (dysplasia) of the epithelial cells lining the cervix. Growth is graded as CIN I, II, or III, depending on the depth of tissue involved. CIN stands for cervical intraepithelial neoplasia. Diagnosis of cervical cancer is by a Pap smear, examination with a **colposcope**, and biopsy. In a **cone biopsy**, a cone-shaped piece of tissue is removed from the lining of the cervix for study. Often in the procedure, all of the abnormal cells are removed as well. A newer procedure that can supplement or replace the Pap smear involves testing a cervical cell sample for the DNA of cancer-causing HPV strains.

### Ovarian Cancer

Cancer of the ovary has a high mortality rate because it usually causes no distinct early symptoms and there is no accurate routine screening test yet available. Women may overlook the vague possible signs of ovarian cancer, such as bloating, change in bowel habits, backache, urinary changes, abnormal bleeding, weight loss, and fatigue. Often by the time of diagnosis, the tumor has invaded the pelvis and abdomen. Removal of the ovaries, an **oophorectomy**, and uterine tubes, a **salpingectomy**, along with the uterus is required, in addition to chemotherapy and radiation therapy.

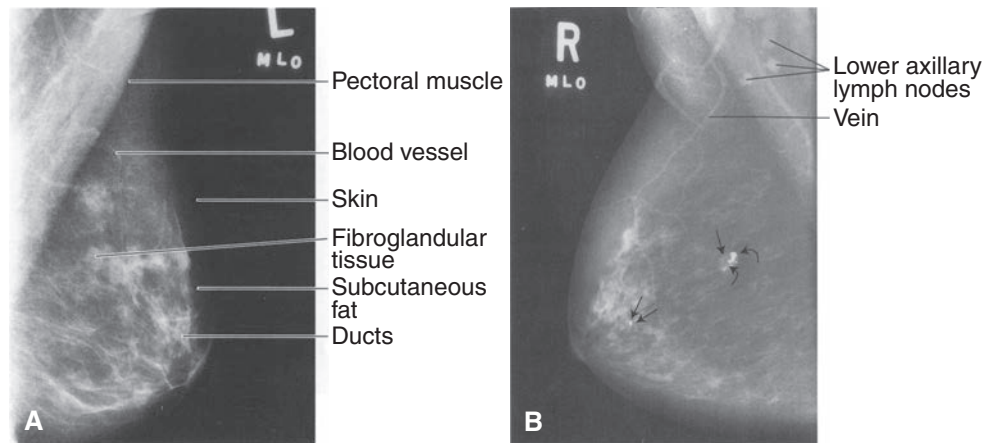
## BREAST CANCER

Carcinoma of the breast is second only to lung cancer in causing cancer-related deaths among women in the United States. This cancer metastasizes readily through the lymph nodes and blood to other sites such as the lung, liver, bones, and ovaries.

### Diagnosis

Palpation is a simple first step in breast cancer diagnosis. Regular breast self-examination (BSE) is of utmost importance, because many breast cancers are discovered by women themselves.

**Mammography**, which provides two-dimensional x-ray images of the breast, is still the standard diagnostic procedure for breast cancer (FIG. 16-9). Some health organizations recommend annual mammograms after the age of 40 years.



**FIGURE 16-9 Mammograms.** **A.** Normal mammogram, left breast. **B.** Mammogram of right breast showing lesions (*arrows*). In mammograms, fat tissue appears gray; breast tissue, calcium deposits, and benign or cancerous tumors appear white.

Other health professionals recommend waiting until age 50 unless a woman is in a high-risk group, such as having a family history of breast cancer. In digital mammography, x-ray images are stored on computers instead of on film. These images can be manipulated electronically to aid interpretation. They are more easily stored and retrieved or sent to other medical facilities.

While mammography remains the most commonly recommended choice in breast cancer screening, medical researchers are currently testing new technologies. These are aimed at addressing one of the major weaknesses of mammography, which is the detection of cancer in women with radiographically dense breasts. Current procedures in these women result in many false positives and frequent recalls for additional imaging. Improvements in screening have been recognized with the three-dimensional technique called digital **tomosynthesis**. This procedure is approved by the U.S. Food and Drug Administration to be used in conjunction with mammography but is not yet considered the standard of care for breast cancer screening.

Ultrasound and MRI studies are adjuncts to mammography. Ultrasound can show whether a lump seen on mammography is simply a benign cyst. MRI with a contrast medium can show abnormal blood vessel formation signifying a tumor.

Any suspicious breast tissue must be biopsied by needle aspiration or surgical excision for further study. In a **stereotactic biopsy**, a physician uses a computer-guided imaging system to locate suspicious tissue and remove samples with a needle. This method is less invasive than surgical biopsy.

Ductal carcinoma in situ (DCIS) is an abnormality of breast tissue that arises from an overgrowth of the cells lining a milk duct. It is initially confined to the duct, that is, it does not invade nearby tissue or metastasize, and it can usually be detected by mammography in its early stages. DCIS may unpredictably become metastatic, and treatment depends on tumor pathology as well as a patient's age and family history.

### Treatment

Treatment of breast cancer is usually some form of **mastectomy**, or removal of breast tissue:

- In a radical mastectomy, the entire breast is removed. Underlying muscle and axillary lymph nodes (in the armpit) are also removed.
- In a modified radical mastectomy, the breast and lymph nodes are removed, but muscles are left in place.
- In a segmental mastectomy, or “lumpectomy,” just the tumor itself is removed. When the tumor is small and surgery is followed by additional treatment, this procedure gives survival rates as high as those with more radical surgeries.

Surgeons can assess the extent of tumor spread and conserve lymphatic tissue using a **sentinel node biopsy**. A dye or radioactive tracer identifies the first lymph nodes that receive lymph from a tumor. Study of possible tumor spread to these “sentinel nodes” guides further treatment.

Often after breast surgery, a patient receives chemotherapy and/or radiation therapy. It is now possible in some cases to deliver radiation to just the tumor area (brachytherapy) instead of irradiating the whole breast. A radiation source is delivered through catheters or implanted in the breast tissue for a short time.

Progress in breast cancer treatment involves genetic studies and tumor analysis that allows therapy more specific to each particular case. About 8% of these cancers are linked to a defective gene (*BRCA1* or *BRCA2*) that is transmitted within families. Women with these genetic predispositions can be screened more carefully or treated prophylactically.

Some types of specific drug treatments for breast cancer, which may be given in combination, are:

- Drugs that block estrogen production or block estrogen receptors in breast tissue if a tumor responds to this hormone
- Drugs that inhibit tumor growth factors
- Drugs that inhibit growth of blood vessels that supply the tumor (antiangiogenesis agents)

These and other anticancer drugs are described in more detail in the list of enrichment terms.

## Terminology *Key Terms*

The terms listed below are emphasized in this chapter. Knowing them will help you organize and prioritize your learning. These boldface terms are also found, collectively, with all chapter key terms in the Glossary.

### Female Reproductive System

#### Disorders

<b>candidiasis</b> <i>kan-dih-DI-ab-sis</i>	Infection with the fungus <i>Candida</i> , a common cause of vaginitis
<b>dysmenorrhea</b> <i>DIS-men-o-re-ah</i>	Painful or difficult menstruation; a common disorder that may be caused by infection, use of an intrauterine device, endometriosis, overproduction of prostaglandins, or other factors
<b>endometriosis</b> <i>en-do-me-tre-O-sis</i>	Growth of endometrial tissue outside the uterus, usually in the pelvic cavity (see <b>FIG. 16-8</b> )
<b>fibroid</b> <i>FI-broyd</i>	Benign tumor of smooth muscle (see leiomyoma)
<b>leiomyoma</b> <i>li-o-mi-O-mah</i>	Benign tumor of smooth muscle, usually in the uterine wall (myometrium); in the uterus, may cause bleeding and pressure on the bladder or rectum; also called fibroid or myoma (see <b>FIG. 16-7</b> )
<b>metrorrhagia</b> <i>me-tro-RA-je-ab</i>	Uterine bleeding between normal menstrual periods
<b>pelvic inflammatory disease (PID)</b>	Condition caused by the spread of infection from the reproductive tract into the pelvic cavity; commonly caused by sexually transmitted gonorrhea and <i>Chlamydia</i> infections
<b>salpingitis</b> <i>sal-pin-JI-tis</i>	Inflammation of a uterine tube, typically caused by urinary tract infection or sexually transmitted infection; chronic salpingitis may lead to infertility or ectopic pregnancy (development of the fertilized egg outside of the uterus)
<b>vaginitis</b> <i>vaj-ih-NI-tis</i>	Inflammation of the vagina

#### Diagnosis and Treatment

<b>colposcope</b> <i>KOL-po-sko-pe</i>	Instrument for examining the vagina and cervix
<b>cone biopsy</b>	Removal of a cone of tissue from the cervical lining for cytologic examination; also called conization
<b>dilation and curettage (D&amp;C)</b> <i>ku-reb-TAJ</i>	Procedure in which the cervix is dilated (widened) and the uterine lining is scraped with a curette
<b>hysterectomy</b> <i>bis-ter-EK-to-me</i>	Surgical removal of the uterus; most commonly done because of tumors; often the uterine tubes and ovaries are removed as well
<b>mammography</b> <i>mam-OG-rah-fe</i>	Radiographic study of the breast for the detection of breast cancer; the image obtained is a mammogram (see <b>FIG. 16-9</b> )
<b>mastectomy</b> <i>mas-TEK-to-me</i>	Excision of breast tissue to eliminate malignancy
<b>oophorectomy</b> <i>o-of-o-REK-to-me</i>	Excision of an ovary
<b>Pap smear</b>	Study of cells collected from the cervix and vagina for early detection of cancer; also called Papanicolaou smear or Pap test
<b>salpingectomy</b> <i>sal-pin-JEK-to-e</i>	Surgical removal of the uterine tube
<b>sentinel node biopsy</b> <i>SEN-tih-nel</i>	Biopsy of the first lymph nodes to receive drainage from a tumor; used to determine spread of cancer in planning treatment
<b>stereotactic biopsy</b> <i>ster-e-o-TAK-tik BI-op-se</i>	Needle biopsy using a computer-guided imaging system to locate suspicious tissue and remove samples for study
<b>tomosynthesis</b> <i>tob-mo-SIN-theb-sis</i>	Three-dimensional x-ray imaging technique for detection of breast cancer; digital tomosynthesis



## Terminology

## Enrichment Terms

The terms listed below expand on the key terms to increase your knowledge of this chapter topic.

### Female Reproductive System

#### Normal Structure and Function

<b>adnexa</b> <i>ad-NEK-sah</i>	Appendages, such as the adnexa uteri—the ovaries, uterine tubes, and uterine ligaments
<b>areola</b> <i>ah-RE-o-lah</i>	A pigmented ring, such as the dark area around the nipple of the breast
<b>Graafian follicle</b> <i>GRAF-e-an</i>	A mature ovarian follicle
<b>hymen</b> <i>HI-men</i>	A fold of mucous membrane that partially covers the entrance of the vagina
<b>mons pubis</b> <i>monz PU-bis</i>	The rounded, fleshy elevation anterior to the pubic joint that is covered with hair after puberty (see <b>FIG. 16-2</b> )
<b>oocyte</b> <i>O-o-site</i>	An immature ovum
<b>perimenopause</b> <i>per-ih-MEN-o-pawz</i>	The period immediately before menopause; begins at the time of irregular menstrual cycles and ends 1 year after the last menstrual period; averages 3 to 4 years
<b>vestibule</b> <i>VES-tih-bule</i>	The space between the labia minora that contains the openings of the urethra, vagina, and ducts of the greater vestibular glands

#### Disorders

<b>cystocele</b> <i>SIS-to-sele</i>	Herniation of the urinary bladder into the wall of the vagina ( <b>FIG. 16-10</b> )
<b>dyspareunia</b> <i>dis-par-U-ne-ah</i>	Pain during sexual intercourse
<b>fibrocystic disease of the breast</b> <i>fi-bro-SIS-tik</i>	A condition in which there are palpable lumps in the breasts, usually associated with pain and tenderness; these lumps or “thickenings” change with the menstrual cycle and must be distinguished from malignant tumors by diagnostic methods
<b>hirsutism</b> <i>HIR-su-tizm</i>	Excess hair growth
<b>leukorrhea</b> <i>lu-ko-RE-ah</i>	White or yellowish discharge from the vagina; infection and other disorders may change the amount, color, or odor of the discharge
<b>microcalcification</b> <i>mi-kro-kal-sib-fih-KA-shun</i>	Small deposit of calcium that appears as a white spot on mammograms; most microcalcifications are harmless, but some might indicate breast cancer
<b>prolapse of the uterus</b>	Downward displacement of the uterus with the cervix sometimes protruding from the vagina
<b>rectocele</b> <i>REK-to-sele</i>	Herniation of the rectum into the wall of the vagina; also called proctocele (see <b>FIG. 16-10</b> )

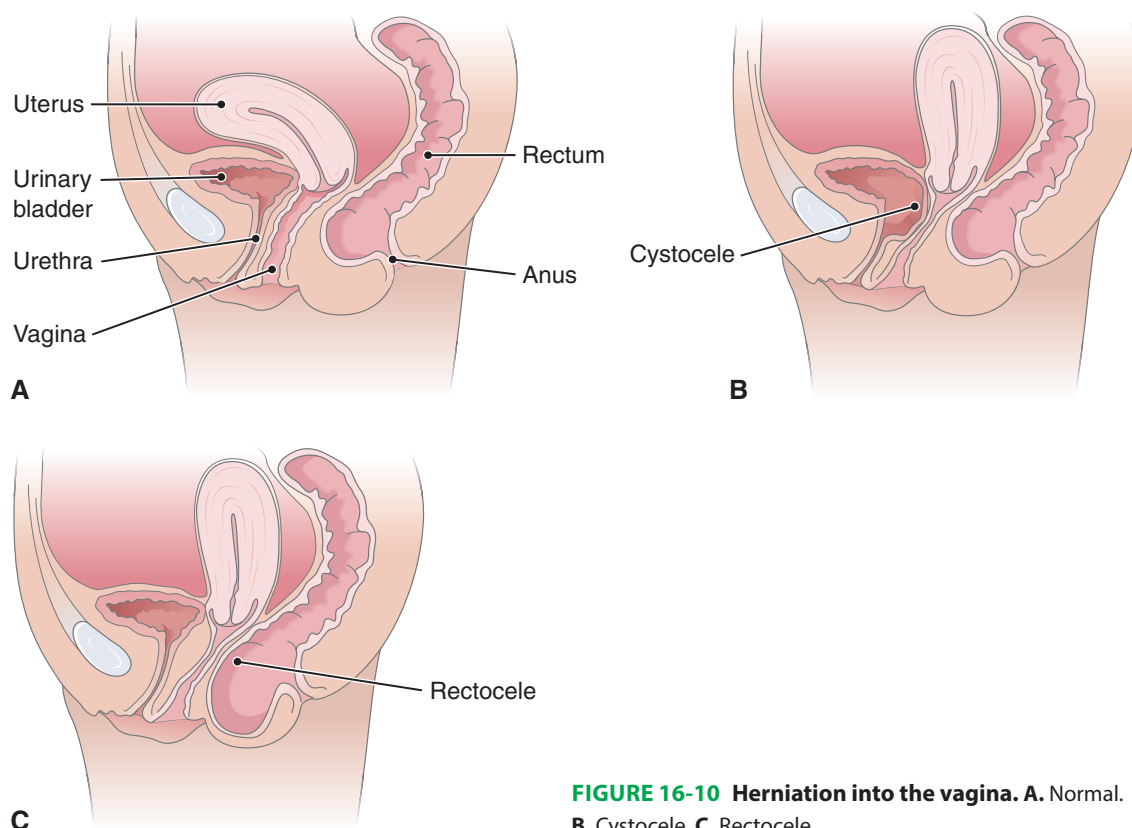
#### Diagnosis and Treatment

<b>culdcentesis</b> <i>kul-do-sen-TE-sis</i>	Puncture of the vaginal wall to sample fluid from the rectouterine space for diagnosis
<b>episiorrhaphy</b> <i>eh-pis-e-OR-ah-fe</i>	Suture of the vulva or suture of the perineum cut in an episiotomy (incision to ease childbirth)
<b>laparoscopy</b> <i>lap-ab-ROS-ko-pe</i>	Endoscopic examination of the abdomen; may include surgical procedures, such as tubal ligation (see <b>FIG. 16-6</b> )

## Terminology

## Enrichment Terms (Continued)

<b>myomectomy</b> <i>mi-o-MEK-to-me</i>	Surgical removal of a uterine leiomyoma (fibroid, myoma)
<b>speculum</b> <i>SPEK-u-lum</i>	An instrument used to enlarge the opening of a passage or cavity to allow examination (see FIG. 3-18)
<b>teletherapy</b> <i>tel-eh-THER-ab-pe</i>	Delivery of radiation to a tumor from an external beam source, as compared to implantation of radioactive material (brachytherapy) or systemic administration of radionuclide
<b>Drugs</b>	
<b>aromatase inhibitor (AI)</b> <i>ah-RO-mah-tase</i>	Agent that inhibits estrogen production; used for postmenopausal treatment of breast cancers that respond to estrogen; examples are exemestane (Aromasin), anastrozole (Arimidex), and letrozole (Femara)
<b>bisphosphonate</b> <i>bis-FOS-fo-nate</i>	Agent used to prevent and treat osteoporosis; increases bone mass by decreasing bone turnover; examples are alendronate (Fosamax) and risedronate (Actonel)
<b>HER2 inhibitor</b>	Drug used to treat breast cancers that show excess receptors (HER2) for human epidermal growth factor; example is trastuzumab (Herceptin)
<b>paclitaxel</b> <i>pak-lib-TAKS-el</i>	Antineoplastic agent derived from yew trees used mainly in treatment of breast and ovarian cancer; Taxol
<b>selective estrogen receptor modulator (SERM)</b>	Drug that acts on estrogen receptors; examples are tamoxifen (Nolvadex) and raloxifene (Evista), which is also used to prevent bone loss after menopause



**FIGURE 16-10** Herniation into the vagina. **A.** Normal. **B.** Cystocele. **C.** Rectocele.

## Terminology

## Abbreviations

The abbreviations listed below are emphasized in this chapter. These are also found, collectively, with all chapter abbreviations in Appendix 2.

<b>AI</b>	Aromatase inhibitor	<b>HRT</b>	Hormone replacement therapy
<b>BRCA1</b>	Breast cancer gene 1	<b>IUD</b>	Intrauterine device
<b>BRCA2</b>	Breast cancer gene 2	<b>LH</b>	Luteinizing hormone
<b>BSE</b>	Breast self-examination	<b>MHT</b>	Menopausal hormone therapy
<b>BSO</b>	Bilateral salpingo-oophorectomy	<b>NGU</b>	Nongonococcal urethritis
<b>BV</b>	Bacterial vaginosis	<b>PCOS</b>	Polycystic ovarian syndrome
<b>CIN</b>	Cervical intraepithelial neoplasia	<b>PID</b>	Pelvic inflammatory disease
<b>D&amp;C</b>	Dilation and curettage	<b>PMS</b>	Premenstrual syndrome
<b>DCIS</b>	Ductal carcinoma in situ	<b>SERM</b>	Selective estrogen receptor modulator
<b>DES</b>	Diethylstilbestrol	<b>STD</b>	Sexually transmitted disease
<b>DUB</b>	Dysfunctional uterine bleeding	<b>STI</b>	Sexually transmitted infection
<b>FSH</b>	Follicle-stimulating hormone	<b>TAH</b>	Total abdominal hysterectomy
<b>GC</b>	Gonococcus (cause of gonorrhea)	<b>TSS</b>	Toxic shock syndrome
<b>GYN</b>	Gynecology; Gynecologist	<b>UFE</b>	Uterine fibroid embolization
<b>HPV</b>	Human papillomavirus	<b>VD</b>	Venereal disease (sexually transmitted disease)

## Pregnancy and Birth

### FERTILIZATION AND EARLY DEVELOPMENT

Penetration of an ovulated egg cell by a spermatozoon results in **fertilization** (FIG. 16-11). This union normally occurs in the uterine tube. The nuclei of the sperm and ovum fuse, restoring the chromosome number to 46 and forming a **zygote**. As the zygote travels through the uterine tube toward the uterus, it divides rapidly. Within 6 to 7 days, the fertilized egg reaches the uterus and implants into the endometrium, and the **embryo** begins to develop.

During the first 8 weeks of growth, all of the major body systems are established. Embryonic tissue produces **human chorionic gonadotropin (hCG)**, a hormone that keeps the corpus luteum functional in the ovary to maintain the endometrium. (The presence of hCG in urine is the basis for the most commonly used tests for pregnancy.) After 2 months, placental hormones take over this function, and the corpus luteum degenerates. At this time, the embryo becomes a **fetus** (FIG. 16-12).

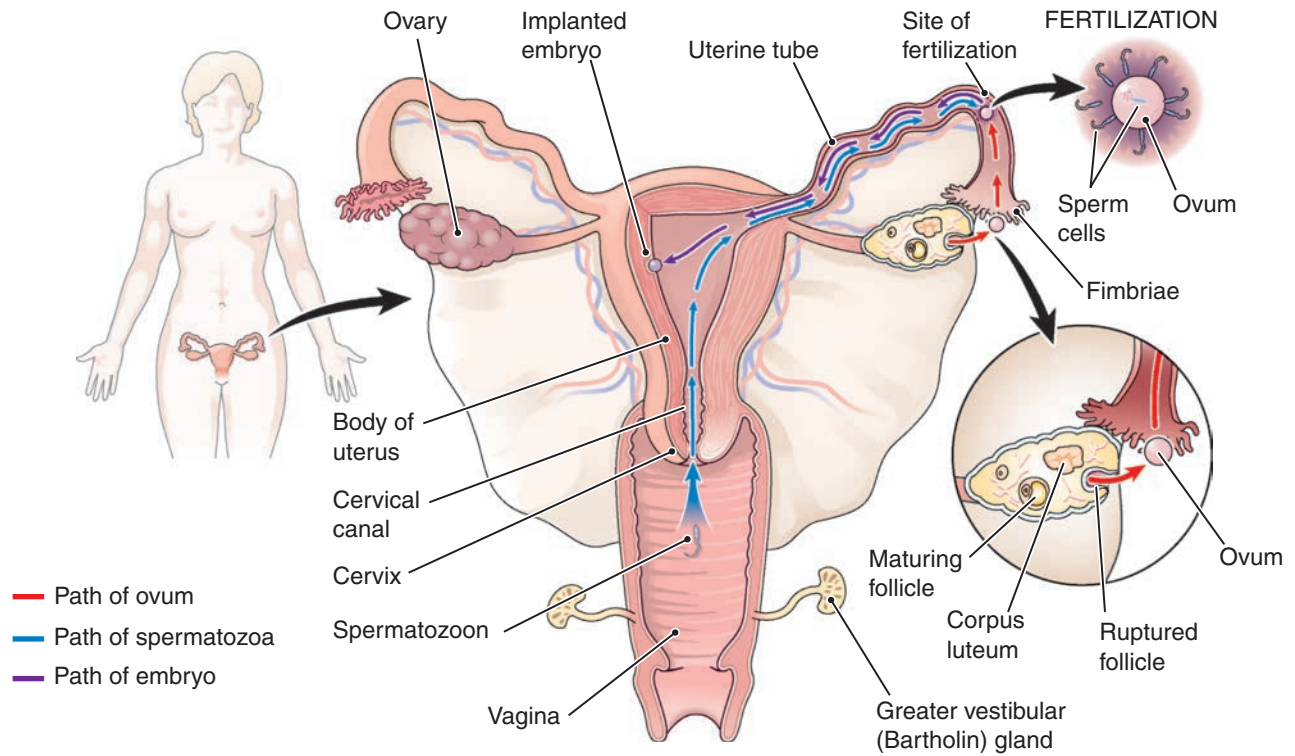
### THE PLACENTA

During development, the fetus is nourished by the **placenta**, an organ formed from the embryo's outermost layer, the **chorion**, and the endometrium, the innermost layer of the uterus (FIG. 16-13). Here, exchanges take place between the bloodstreams of the mother and the fetus through fetal capillaries.

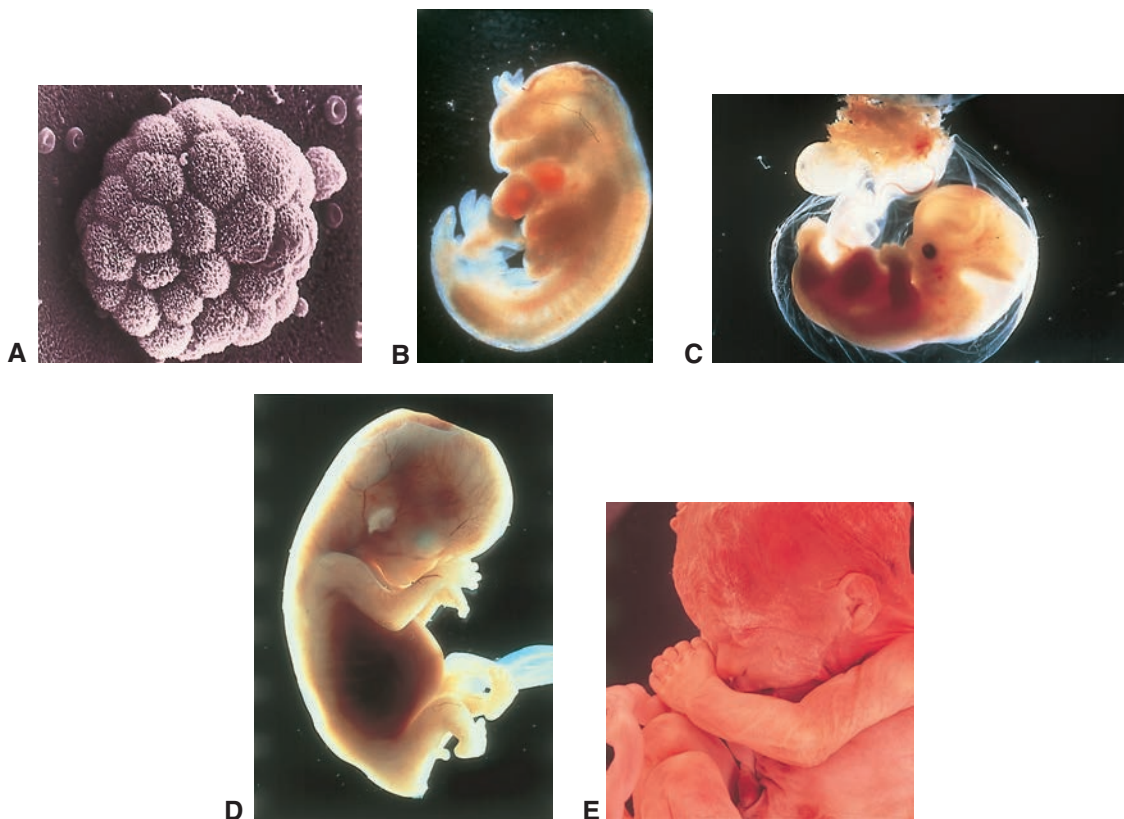
The **umbilical cord** contains the blood vessels that link the fetus to the placenta. Fetal blood is carried to the placenta in two umbilical arteries. While traveling through the placenta, the blood picks up nutrients and oxygen and gives up carbon dioxide and metabolic waste. Replenished blood is carried from the placenta to the fetus in a single umbilical vein.

Although the bloodstreams of the mother and the fetus do not mix and all exchanges take place through capillaries, some materials do manage to get through the placenta in both directions. For example, some viruses, such as HIV and rubella (German measles), as well as drugs, alcohol, and other harmful substances are known to pass from the mother to the fetus; fetal proteins can enter the mother's blood and cause immunologic reactions.

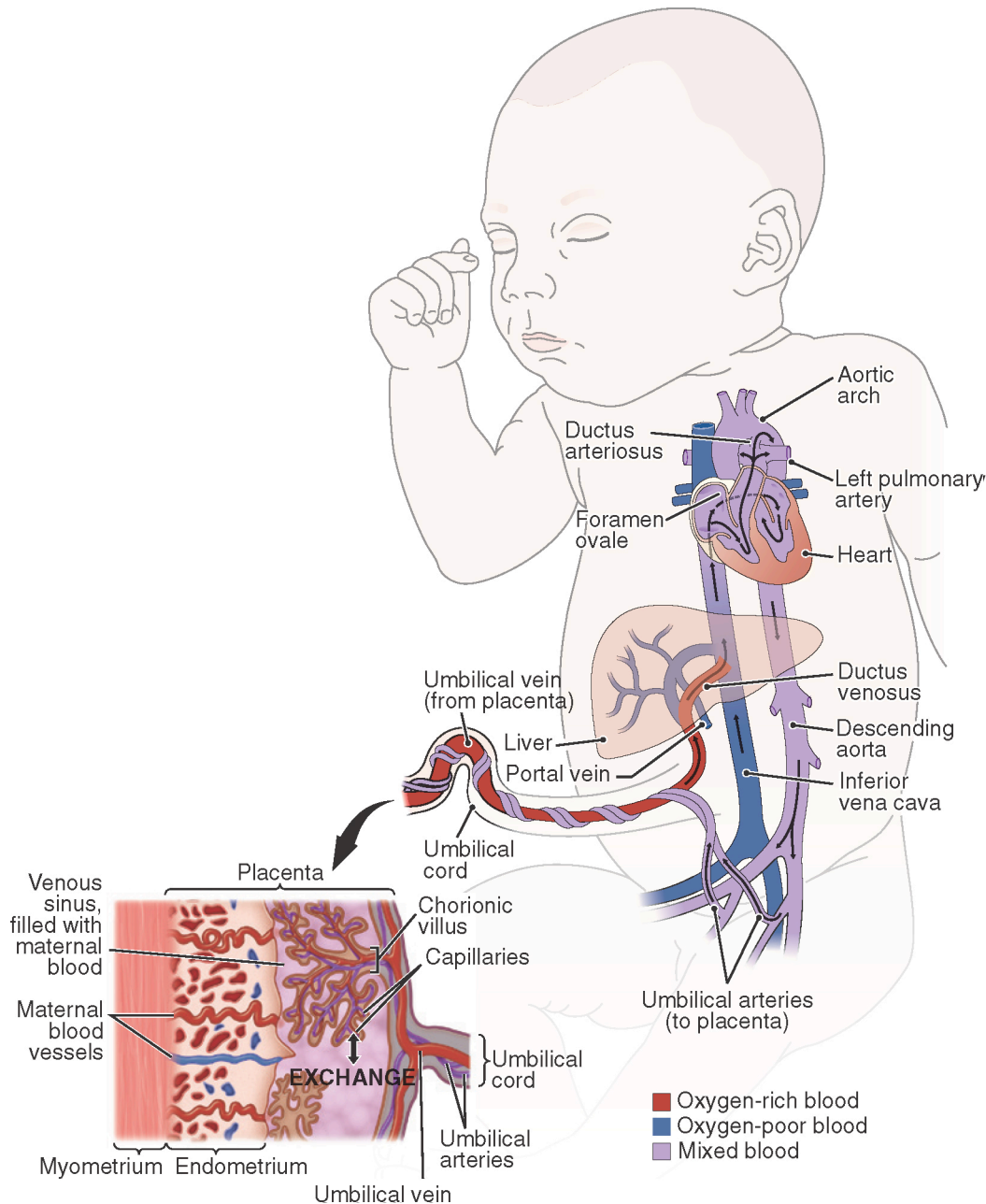
The placenta also produces hormones that promote fetal growth. One of these, chemically similar to pituitary growth hormone, is named placental growth hormone.



**FIGURE 16-11 Ovulation and fertilization.** Arrows show the pathway of spermatozoa and ovum. Fertilization occurs in the uterine tube, after which the zygote implants in the uterine lining.



**FIGURE 16-12 Human development.** Human embryos and an early fetus are shown. **A.** Implantation in the uterus 7 to 8 days after conception. **B.** Embryo at 32 days. **C.** At 37 days. **D.** At 41 days. **E.** Fetus at 12 to 15 weeks.



**FIGURE 16-13 Fetal circulation.** Colors show relative oxygen content of blood in the various vessels. Gases, waste products, and nutrients are exchanged between the fetus and the mother through capillaries in the placenta.

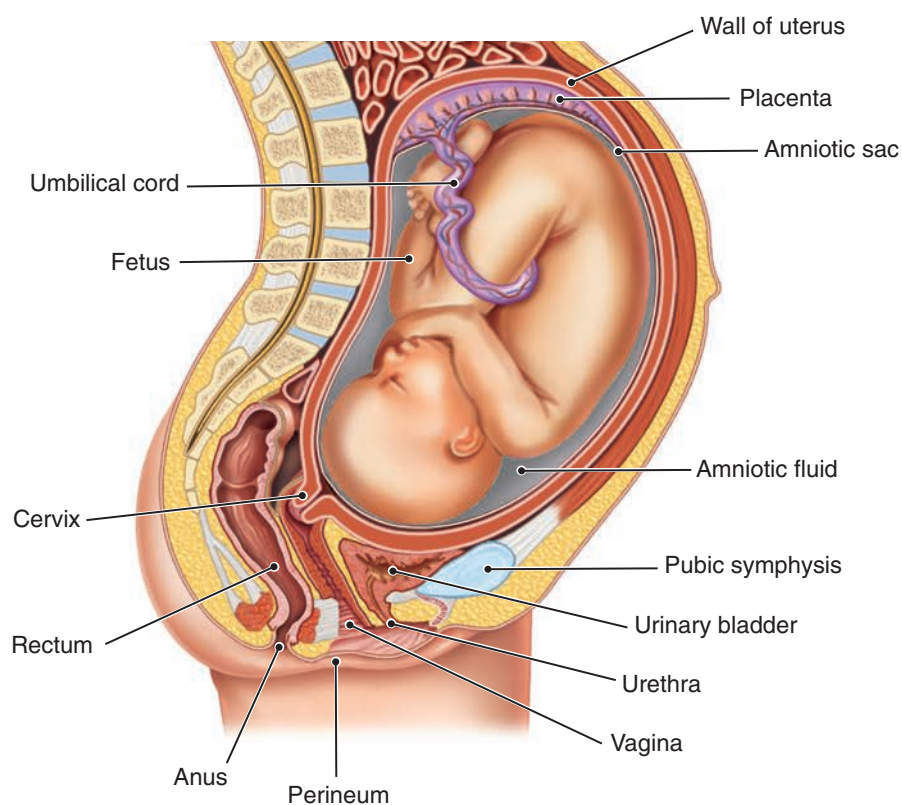
Another is human chorionic somatomammotropin (hCS). These hormones increase fatty acids and glucose availability for the fetus by modifying maternal metabolism.

During **gestation** (the period of development), the fetus is cushioned and protected by fluid contained in the **amniotic sac** (amnion) (FIG. 16-14), commonly called the “bag of waters.” This sac ruptures at birth.

## FETAL CIRCULATION

The fetus has several adaptations that serve to bypass the lungs, which are not needed to oxygenate the blood. When

blood coming from the placenta enters the right atrium, the **foramen ovale**, a small hole in the septum between the atria, allows some of the blood to go directly into the left atrium, thus bypassing the pulmonary artery. Further, blood pumped out of the right ventricle can shunt directly into the aorta through a short vessel, the **ductus arteriosus**, which connects the pulmonary artery with the descending aorta (see FIG. 16-13). Both of these passages close off at birth when the pulmonary circuit is established. Their failure to close taxes the heart and may require medical attention.



**FIGURE 16-14** Midsagittal section of a pregnant uterus with intact fetus.

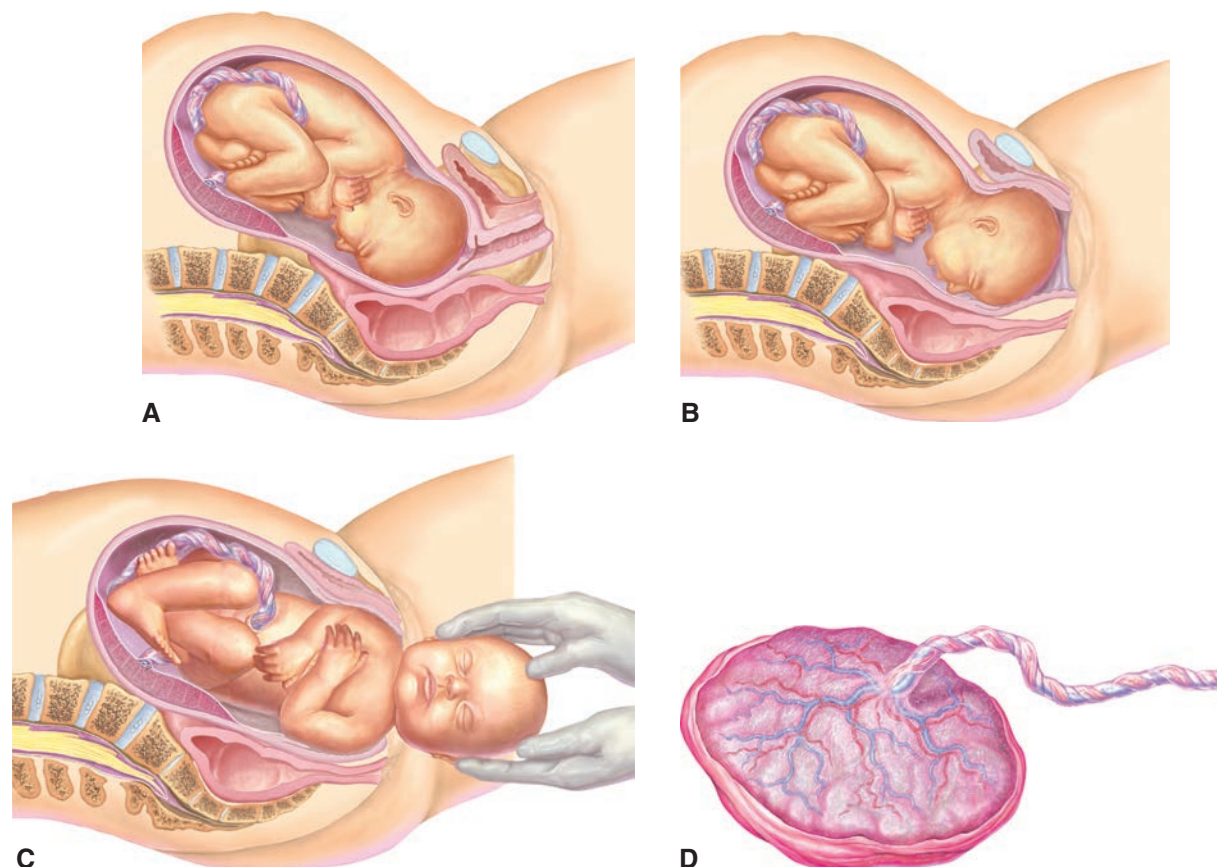
## CHILDBIRTH

The length of pregnancy, from fertilization of the ovum to birth, is about 38 weeks, or 266 days. In practice, it is calculated as approximately 280 days or 40 weeks from the first day of the last menstrual period (LMP). For study purposes, pregnancy is divided into 3-month periods (trimesters), during which defined changes can be observed in the fetus.

Childbirth, or **parturition**, occurs in three stages (**FIG. 16-15**):

1. Onset of regular uterine contractions and dilation of the cervix
2. Expulsion of the fetus
3. Delivery of the placenta and fetal membranes

The third stage of childbirth is followed by contraction of the uterus and control of bleeding. The factors that start labor are not completely understood, but it is clear that the hormone **oxytocin** from the posterior pituitary gland and other hormones called



**FIGURE 16-15** Stages of labor. The first stage (**A**) begins with the onset of uterine contractions. The second stage begins when the cervix is completely dilated (**B**) and ends with the birth of the baby (**C**). The third stage (**D**) ends with expulsion of the afterbirth.



## HEALTH PROFESSIONS

### Nurse-Midwives and Doulas

BOX 16-3

There are various titles associated with the term *midwife*, each having different academic preparation and certification. The name *midwife* literally means “with woman,” and the practice is termed midwifery (*mid-WIF-re* or *mid-WIF-er-e*). The role of a midwife in the United States varies based on education, credentials, and licensure.

A certified nurse-midwife (CNM) is educated in the disciplines of both nursing and midwifery. A certified midwife (CM) is educated solely in the discipline of midwifery. A master’s degree is required for both titles in order to take the American Midwifery Certification Board (AMCB) examination. Recertification is required every 5 years. CNMs and CMs provide primary health care to women from adolescence to beyond menopause. This includes routine gynecologic and reproductive health care, pregnancy, birth, and postpartum care, as well as perimenopause and menopause management. CNMs are licensed in all 50 U.S. states, Washington, D.C., and U.S. territories, and they have prescriptive authority in all U.S. jurisdictions. CMs are licensed in New York, New Jersey, and Rhode Island, and they may practice in Delaware and Missouri. They have prescriptive authority in New York. Most private insurances and Medicaid reimburse for CNM/CM services. The majority of CNM/CMs attend births in hospitals, but they may also attend home births and work in birth centers, clinics, and health departments. The American College of Nurse-Midwives at [acnm.org](http://acnm.org) has information on these careers.

A Certified Professional Midwife (CPM) is an independent midwifery provider who has met the standards for certification set by the North American Registry of Midwives (NARM). No college degree is required for this specialty. CPMs are regulated in 26 states, which vary in certification, licensure, and registration requirements. CPMs have no prescriptive authority. Private insurance in some states and Medicaid in 10 states reimburse CPMs for home and birth center births. CPMs provide care for women during pregnancy, birth, and the postpartum period and also provide newborn care. The professional associations for CPMs are the Midwives Alliance of North America (MANA) and National Association of Certified Professional Midwives (NACPM). Information is available at [mana.org](http://mana.org).

A doula (birth assistant) is someone who works with families during pregnancy, through labor, and after childbirth. Doulas provide emotional and physical support and education. They may help with prenatal preparation and early labor at home and continue with support throughout the hospital stay. Some doulas are trained in postpartum care and can give the family support at home after the birth. The name *doula* comes from Greek and refers to the most important female servant in the household, who probably assisted the lady of the house in childbearing. Doulas have a professional association that sets standards for training and certification. For more information visit [dona.org](http://dona.org).

prostaglandins are involved. **BOX 16-3** has career information on midwives and other birth assistants.

Hospitals use the **Apgar score** to assess a newborn’s health. Five features—heart rate, respiration, muscle tone, reaction to a nasal catheter, and skin color—are rated as 0, 1, or 2 at 1 and 5 minutes after birth. The maximum score in the test is 10. Infants with low scores require medical attention. (Although this test is named for a person, Virginia Apgar, an anesthesiologist, the title is often used as an acronym for the test components: appearance, pulse, grimace, activity, respiration.)

The term **gravida** refers to a pregnant woman. The term **para** refers to a woman who has given birth. This means the production of a viable infant (500 g or more or over 20 weeks of gestation) regardless of whether the infant is alive at birth or whether the birth is single or multiple. Prefixes are added to both terms to indicate the number of pregnancies or births, such as:

- nulli—none
- primi—one

- secundi—two
- tri or terci—three
- quadri—four
- multi—two or more

Alternatively, a number can be added after the term to indicate events, such as gravida 1, para 3, and so forth.

## LACTATION

The hormone prolactin from the anterior pituitary gland, as well as hormones from the placenta, start the secretion of milk from the breasts, called **lactation**. The baby’s suckling then stimulates milk release. The pituitary hormone oxytocin is needed for this release or “letdown” of milk. For the first few days after delivery, only **colostrum** is produced. This has a slightly different composition than milk, but like the milk, it has protective antibodies.

## Terminology

## Key Terms

The terms listed below are emphasized in this chapter. Knowing them will help you organize and prioritize your learning. These boldface terms are also found, collectively, with all chapter key terms in the Glossary.

## Pregnancy and Birth

## Normal Structure and Function

<b>amniotic sac</b> <i>am-ne-OT-ik</i>	The membranous sac filled with fluid that holds the fetus; also called amnion (root: amnio)
<b>Apgar score</b> <i>AP-gar</i>	A system of rating an infant's physical condition immediately after birth; five features are rated as 0, 1, or 2 at 1 and 5 minutes after delivery and sometimes thereafter; the maximum possible score at each test interval is 10; infants with low scores require medical attention
<b>chorion</b> <i>KOR-e-on</i>	The outermost layer of the embryo that, with the endometrium, forms the placenta (adjective: chorionic)
<b>colostrum</b> <i>ko-LOS-trum</i>	Breast fluid that is secreted in the first few days after giving birth before milk is produced
<b>ductus arteriosus</b> <i>DUK-tusar-tere-e-O-sus</i>	A fetal blood vessel that connects the pulmonary artery with the descending aorta, thus allowing blood to bypass the lungs
<b>embryo</b> <i>EM-bre-o</i>	The stage in development between the zygote and the fetus, extending from the second through the eighth week of growth in the uterus (root: embryo/o) (adjective: embryonic)
<b>fertilization</b> <i>fer-tih-lib-ZA-shun</i>	The union of an ovum and a spermatozoon
<b>fetus</b> <i>FE-tus</i>	The developing child in the uterus from the third month to birth (root: fet/o) (adjective: fetal)
<b>foramen ovale</b> <i>fo-RA-men o-VA-le</i>	A small hole in the interatrial septum in the fetal heart that allows blood to pass directly from the right to the left side of the heart
<b>gestation</b> <i>jes-TA-shun</i>	The period of development from conception to birth
<b>gravida</b> <i>GRAV-ih-da</i>	Pregnant woman
<b>human chorionic gonadotropin (hCG)</b> <i>kor-e-ON-ik GO-nah-do-tro-pin</i>	A hormone secreted by the embryo early in pregnancy that maintains the corpus luteum so that it will continue to secrete hormones
<b>lactation</b> <i>lak-TA-shun</i>	The secretion of milk from the mammary glands
<b>oxytocin</b> <i>ok-se-TO-sin</i>	A pituitary hormone that stimulates contractions of the uterus; it also stimulates release ("letdown") of milk from the breasts
<b>para</b>	Woman who has produced a viable infant; multiple births are considered as single pregnancies
<b>parturition</b> <i>par-tu-RIH-shun</i>	Childbirth (root: nat/i); labor (root: toc/o)
<b>placenta</b> <i>plah-SEN-tab</i>	The organ composed of fetal and maternal tissues that nourishes and maintains the developing fetus
<b>prostaglandins</b> <i>PROS-tab-glan-dinz</i>	A group of hormones produced throughout the body that have a variety of effects, including stimulation of uterine contractions and regulation of blood pressure, blood clotting, and inflammation
<b>umbilical cord</b> <i>um-BIL-ih-kal</i>	The structure that connects the fetus to the placenta; it contains vessels that carry blood between the mother and the fetus
<b>zygote</b> <i>ZI-gote</i>	The fertilized ovum



## Roots Pertaining to Pregnancy and Birth

See TABLE 16-4.

Table 16-4		Roots for Pregnancy and Birth	
Root	Meaning	Example	Definition of Example
amnio	amnion, amniotic sac	diamniotic <i>di-am-ne-OT-ik</i>	showing two amniotic sacs
embryo/o	embryo	embryonic <i>em-bre-ON-ik</i>	pertaining to the embryo
fet/o	fetus	fetometry <i>fe-TOM-eh-tre</i>	measurement of a fetus
toc/o	labor	dystocia <i>dis-TO-se-ah</i>	difficult labor
nat/i	birth	neonate <i>NE-o-nate</i>	newborn
lact/o	milk	lactose <i>LAK-tose</i>	sugar (-ose) found in milk
galact/o	milk	galactagogue <i>gab-LAK-to-gog</i>	agent that promotes (-agogue) the flow of milk
gravida	pregnant woman	nulligravida <i>nul-ih-GRAY-ih-dah</i>	woman who has never (nulli-) been pregnant
para	woman who has given birth	multipara <i>mul-TIP-ah-rah</i>	woman who has given birth two or more times

### Exercise 16-4

Complete the exercise. To check your answers go to Appendix 11.

Define the following words.

1. prenatal (*pre-NA-tal*) \_\_\_\_\_
2. embryogenesis (*em-bre-o-JEN-eh-sis*) \_\_\_\_\_
3. neonatal (*ne-o-NA-tal*) \_\_\_\_\_
4. fetoscopy (*fe-TOS-ko-pe*) \_\_\_\_\_
5. monoamniotic (*mon-o-am-ne-OT-ik*) \_\_\_\_\_
6. agalactia (*a-gab-LAK-she-ah*) \_\_\_\_\_
7. hypolactation (*hi-po-lak-TA-shun*) \_\_\_\_\_

Use the appropriate roots to write words for the following.

8. study of an embryo \_\_\_\_\_
9. after birth \_\_\_\_\_
10. incision of the amnion (to induce labor) \_\_\_\_\_
11. cell (-cyte) found in amniotic fluid \_\_\_\_\_
12. any disease of an embryo \_\_\_\_\_
13. instrument for endoscopic examination of the fetus \_\_\_\_\_
14. rupture of the amniotic sac \_\_\_\_\_
15. study of the newborn \_\_\_\_\_

**Exercise 16-4 (Continued)**

16. woman who is pregnant for the first time
17. woman who has been pregnant two or more times
18. woman who has never given birth
19. woman who has given birth to one child

---



---



---



---

Use the suffix *-tocia*, meaning “condition of labor,” to write words for the following.

20. dry labor
21. slow labor

---



---

Use the root *galact/o* to write words for the following.

22. discharge of milk
23. cystic enlargement (-cele) of a milk duct

---



---

## Clinical Aspects of Pregnancy and Birth

### INFERTILITY

About 10% to 15% of couples who want children are unable to conceive or to sustain a pregnancy. Some of the possible causes of infertility are discussed in Chapter 15 and in this section. In men, these causes include low sperm count, low sperm motility, blockage of the ducts that transport the sperm cells, and erectile dysfunction. In women they include:

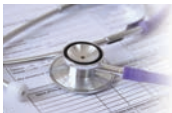- Lack of ovulation
- Blockage in the uterine tubes, as caused by infection or excess growth of tissue

- Uterine problems, such as tumors or abnormal growth of endometrial tissue
- Cervical scarring or infection
- Excess vaginal acidity, which harms spermatozoa, or antibodies to sperm cells
- Drugs, including temporary or permanent infertility following cessation of birth control pills

**BOX 16-4** describes some clinical approaches to helping infertile couples have children when all other diagnostic and therapeutic methods have failed.

### ECTOPIC PREGNANCY

Development of a fertilized egg outside of its normal position in the uterine cavity is termed an **ectopic pregnancy**.



## CLINICAL PERSPECTIVES

BOX 16-4

### Assisted Reproductive Technology: The “Art” of Conception

At least 1 in 10 American couples is affected by infertility. Assisted reproductive technologies such as in vitro fertilization (IVF), gamete intrafallopian transfer (GIFT), and zygote intrafallopian transfer (ZIFT) can help these couples have children.

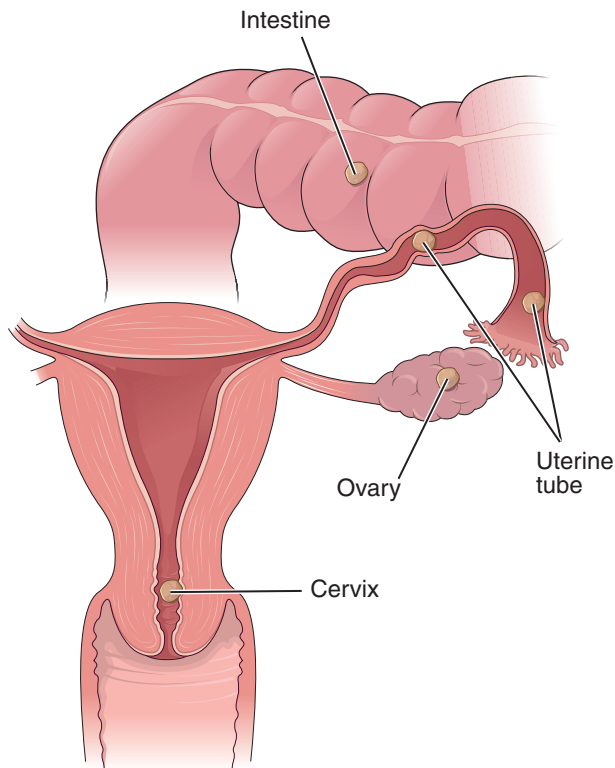
In vitro *fertilization* refers to fertilization of an egg outside the mother’s body in a laboratory dish, and it is often used when a woman’s fallopian tubes are blocked or when a man has a low sperm count. The woman participating in IVF is given hormones to cause ovulation of several eggs. These are then withdrawn with a needle and fertilized with the father’s sperm. After a few divisions, some of the fertilized eggs are placed in the uterus, thus bypassing the fallopian tubes. Additional fertilized eggs can be frozen to repeat the procedure in case of failure or for later pregnancies.

GIFT can be used when the woman has at least one normal fallopian tube and the man has an adequate sperm count. As in

IVF, the woman is given hormones to cause ovulation of several eggs, which are collected. Then, the eggs and the father’s sperm are placed into the fallopian tube using a catheter. Thus, in GIFT, fertilization occurs inside the woman, not in a laboratory dish.

ZIFT is a combination of IVF and GIFT. Fertilization takes place in a laboratory dish, and then the zygote is placed into the fallopian tube.

Because of a lack of guidelines or restrictions in the United States in the field of assisted reproductive technology, some problems have arisen. These issues concern the use of stored embryos and gametes, use of embryos without consent, and improper screening for disease among donors. In addition, the implantation of more than one fertilized egg has resulted in a high incidence of multiple births, even up to seven or eight offspring in a single pregnancy, a situation that imperils the survival and health of the babies.



**FIGURE 16-16 Ectopic pregnancy.** Possible sites where a fertilized ovum might develop outside the body of the uterus.

(FIG. 16-16). Although it may occur elsewhere in the abdominal cavity, an ectopic pregnancy usually occurs in the uterine tube, resulting in a tubal pregnancy. Salpingitis, endometriosis, and PID may lead to ectopic pregnancy by blocking the ovum's passage into the uterus. Continued growth will rupture the tube, causing dangerous hemorrhage. Symptoms of ectopic pregnancy are pain, tenderness, swelling, and shock. Diagnosis is by measurement of the hormone hCG and **ultrasonography**, confirmed by laparoscopic examination. Prompt surgery is required, sometimes including removal of the tube.

## PREECLAMPSIA

**Preeclampsia** is a serious disorder involving new-onset hypertension (high blood pressure) and proteinuria (protein in the urine) that develops after 20 weeks of pregnancy. Additional signs include general edema and sudden weight gain. Hypertension with proteinuria is known as **pregnancy-induced hypertension (PIH)**. Whereas PIH is not associated with adverse outcomes, it should be monitored to ensure that it does not develop into preeclampsia.

The cause of preeclampsia is not completely understood. Researchers currently believe that it results from a hormone imbalance that leads to constriction of placental blood vessels. The condition is most often seen in first pregnancies and in women whose nutritional state is poor, who are obese, and who have received little or no health care during pregnancy. If preeclampsia remains untreated, it may lead to **eclampsia** with onset of kidney failure, convulsions,

and coma during pregnancy or after birth. The result may be the death of both the mother and the infant.

## ABORTION

For a variety of reasons, a pregnancy may terminate before the fetus is capable of surviving outside the uterus. An **abortion** is loss of an embryo or fetus before the 20th week of pregnancy or before a weight of 500 g (1.1 lb). When this occurs spontaneously, it is commonly referred to as a miscarriage. Most spontaneous abortions occur within the first 3 months of pregnancy. Causes include poor maternal health, hormonal imbalance, cervical incompetence (weakness), immune reactions, tumors, and, most commonly, fetal abnormalities. If all gestational tissues are not eliminated, the abortion is described as incomplete, and a physician must remove the remaining tissue.

An induced abortion is the intentional termination of a pregnancy. A common method for inducing an abortion is **dilatation and evacuation (D&E)**, in which the cervix is dilated and the fetal tissue is removed by suction.

## Rh INCOMPATIBILITY

Incompatibility between the blood of a mother and her fetus is a problem in certain pregnancies. If a mother lacks the Rh blood antigen (see Chapter 11) and her baby is positive for that factor (inherited from the father), the mother's body may make Rh antibodies as her baby's blood crosses the placenta during pregnancy or enters the maternal bloodstream during childbirth. In a subsequent pregnancy with an Rh-positive fetus, the antibodies may enter the fetus and destroy its red cells. **Hemolytic disease of the newborn (HDN)** is prevented by giving the mother preformed Rh antibodies during pregnancy and shortly after delivery to remove these proteins from her blood.

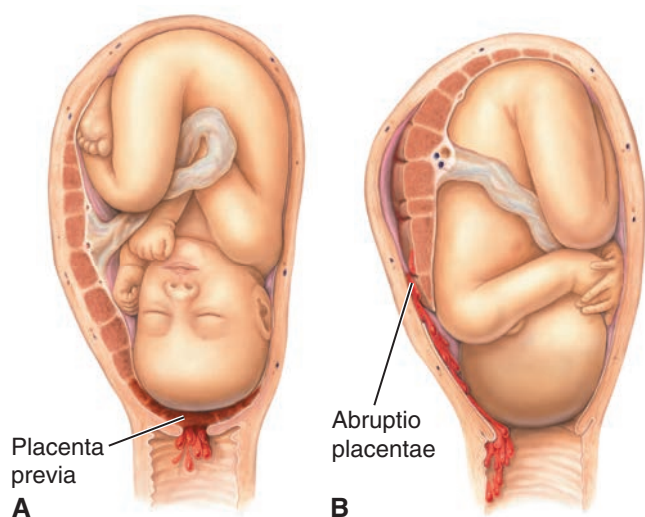
## PLACENTAL ABNORMALITIES

If the placenta attaches near or over the cervix instead of in the upper portion of the uterus, the condition is termed **placenta previa** (FIG. 16-17). This disorder may cause bleeding later in the pregnancy. If bleeding is heavy, it may be necessary to terminate the pregnancy.

**Placental abruption** (abruptio placentae) describes premature separation of the placenta from its point of attachment. The separation causes hemorrhage, which, if extensive, may result in fetal or maternal death or a need to end the pregnancy. Causative factors include injury, maternal hypertension, and advanced maternal age.

## MASTITIS

Inflammation of the breast, or **mastitis**, may occur at any time but usually occurs in the early weeks of breast-feeding. It is commonly caused by staphylococcal or streptococcal bacteria that enter through cracks in the nipple. The breast becomes red, swollen, and tender, and the patient may experience chills, fever, and general discomfort.



**FIGURE 16-17 Placental abnormalities.** If the placenta develops out of position or separates prematurely, bleeding and possible termination of pregnancy may occur. **A.** In placenta previa, the placenta attaches near the cervix instead of at the superior part of the uterus. **B.** In abruptio placentae, the placenta separates prematurely from the uterine wall.

## Congenital Disorders

**Congenital disorders** are those present at birth (birth defects). They fall into two categories:

- Developmental disorders that occur during fetal growth
- Hereditary (familial) disorders that can be passed from parents to children through the germ cells

A genetic disorder is caused by a **mutation** (change) in the genes or chromosomes of cells. Mutations may involve changes in the number or structure of the chromosomes or changes in single or multiple genes. The appearance and severity of genetic disorders may also involve abnormal genes interacting with environmental factors. Examples are the diseases that “run in families,” such as diabetes mellitus, heart disease, hypertension, and certain forms of cancer. **BOX 16-5** describes some of the most common genetic disorders.

A **carrier** of a genetic disorder is an individual who has a genetic defect that does not appear but that can be passed to offspring. Laboratory tests can identify carriers of some genetic disorders.



## FOR YOUR REFERENCE

### Genetic Disorders<sup>a</sup>

BOX 16-5

Disease	Cause	Description
<b>albinism</b> <i>AL-bih-nizm</i>	recessive gene mutation	lack of pigmentation
<b>cystic fibrosis</b> <i>sis-tik fi-BRO-sis</i>	recessive gene mutation	affects respiratory system, pancreas, and sweat glands; most common hereditary disease in white populations (see Chapter 12)
<b>Down syndrome</b>	extra chromosome 21	slanted eyes, short stature, mental retardation, and others ( <b>FIG. 16-18</b> ); incidence increases with increasing maternal age; trisomy 21 syndrome
<b>fragile X chromosome</b>	defect in an X (sex-determining) chromosome	reduced intellectual abilities, autism, hyperactivity; enlarged head and ears; passed from mothers to sons with the X chromosome (sex-linked)
<b>hemophilia</b> <i>he-mo-FIL-e-ah</i>	recessive gene mutation on the X chromosome	bleeding disease inherited with an X chromosome and usually passed from mothers to sons
<b>Huntington disease</b>	dominant gene mutation	altered metabolism destroys specific nerve cells; appears in adulthood and is fatal within about 10 years; causes motor and mental disorders
<b>Klinefelter syndrome</b>	extra X chromosome	lack of sexual development, lowered intelligence
<b>Marfan syndrome</b>	dominant gene mutation	disease of connective tissue with weakness of the aorta
<b>neurofibromatosis</b> <i>nu-ro-fi-bro-mah-TO-sis</i>	dominant gene mutation	multiple skin tumors containing nerve tissue

(continued)



## FOR YOUR REFERENCE (Continued)

### Genetic Disorders<sup>a</sup>

BOX 16-5

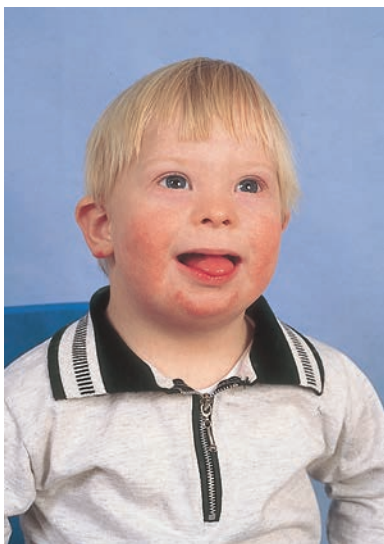Disease	Cause	Description
<b>phenylketonuria (PKU)</b> <i>fen-il-ke-to-NU-re-ah</i>	recessive gene mutation	lack of enzyme to metabolize an amino acid (phenylalanine); neurologic signs, mental retardation, lack of pigment; tested for at birth; special diet can prevent retardation
<b>sickle cell anemia</b>	recessive gene mutation	abnormally shaped red cells block blood vessels; mainly affects black populations
<b>Tay-Sachs disease</b> <i>ta-saks</i>	recessive gene mutation	an enzyme deficiency causes lipid to accumulate in nerve cells and other tissues; causes death in early childhood; carried in eastern European Jewish populations
<b>Turner syndrome</b>	single X chromosome	sexual immaturity, short stature, possible lowered intelligence

<sup>a</sup>A dominant gene is one for a trait that always appears if the gene is present; that is, it will affect the offspring even if inherited from only one parent. A recessive gene is one for a trait that will appear only if the gene is inherited from both parents.

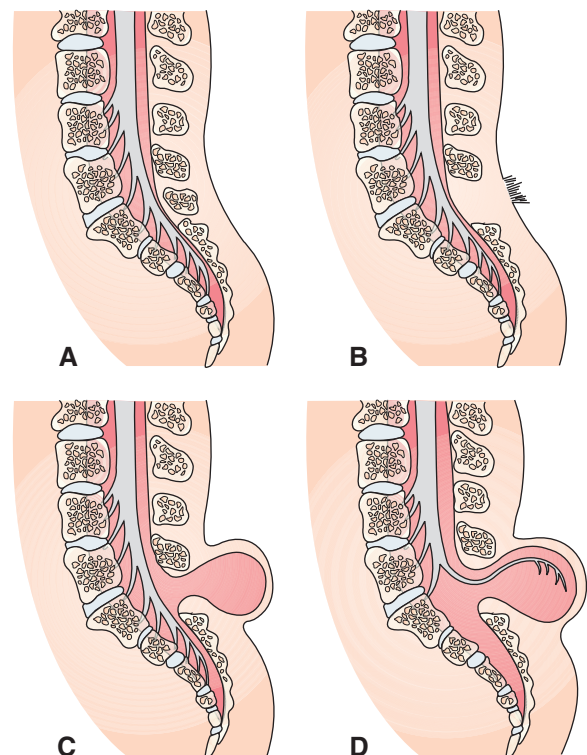
**Teratogens** are factors that cause malformations in the developing fetus. These include infections—such as rubella, herpes simplex, and syphilis—alcohol, drugs, chemicals, and radiation. The fetus is most susceptible to teratogenic effects during the first 3 months of pregnancy.

Examples of developmental disorders are **atresia** (absence or closure of a normal body opening), **anencephaly** (absence of a brain), **cleft lip**, **cleft palate**, and congenital heart disease. **Spina bifida** is incomplete closure of the spine, through which the spinal cord and its membranes may project (FIG. 16-19). This usually occurs in the lumbar region. If there is no herniation of tissue, the condition is spina bifida occulta. Protrusion of the meninges through the opening is a meningocele; in a myelomeningocele, both the spinal cord and membranes herniate

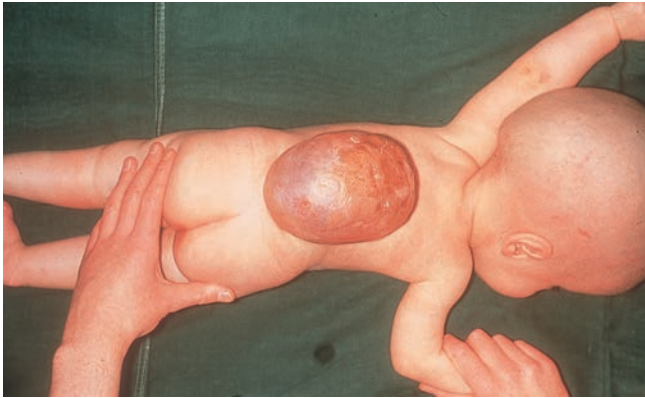
through the defect, as seen in FIGURES 16-19D and 16-20. Note that folic acid or folate, a B vitamin, can prevent embryonic spinal malformations, known as neural tube defects. This vitamin is found in vegetables, liver, legumes, and seeds, but it is now added to some commercial foods, including cereals and breads, to provide young women with this vitamin early on in case they become pregnant.



**FIGURE 16-18** Child with Down syndrome (trisomy 21). The typical facial features are visible in this photo.



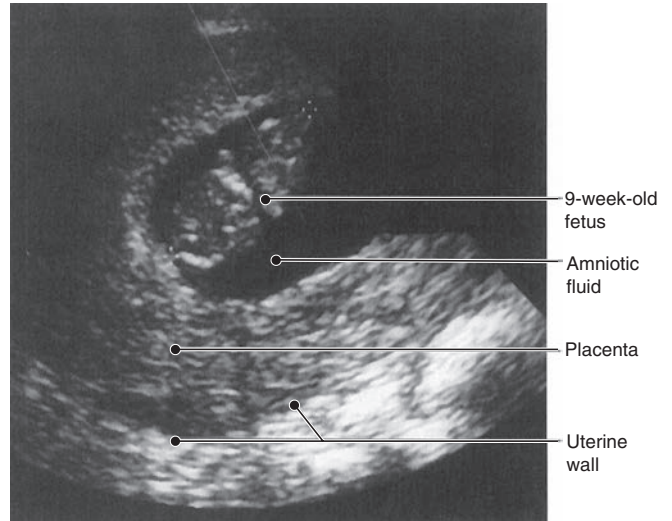
**FIGURE 16-19** Spinal defects. A. Normal spinal cord. B. Spina bifida occulta. C. Meningocele. D. Myelomeningocele.



**FIGURE 16-20** A myelomeningocele.

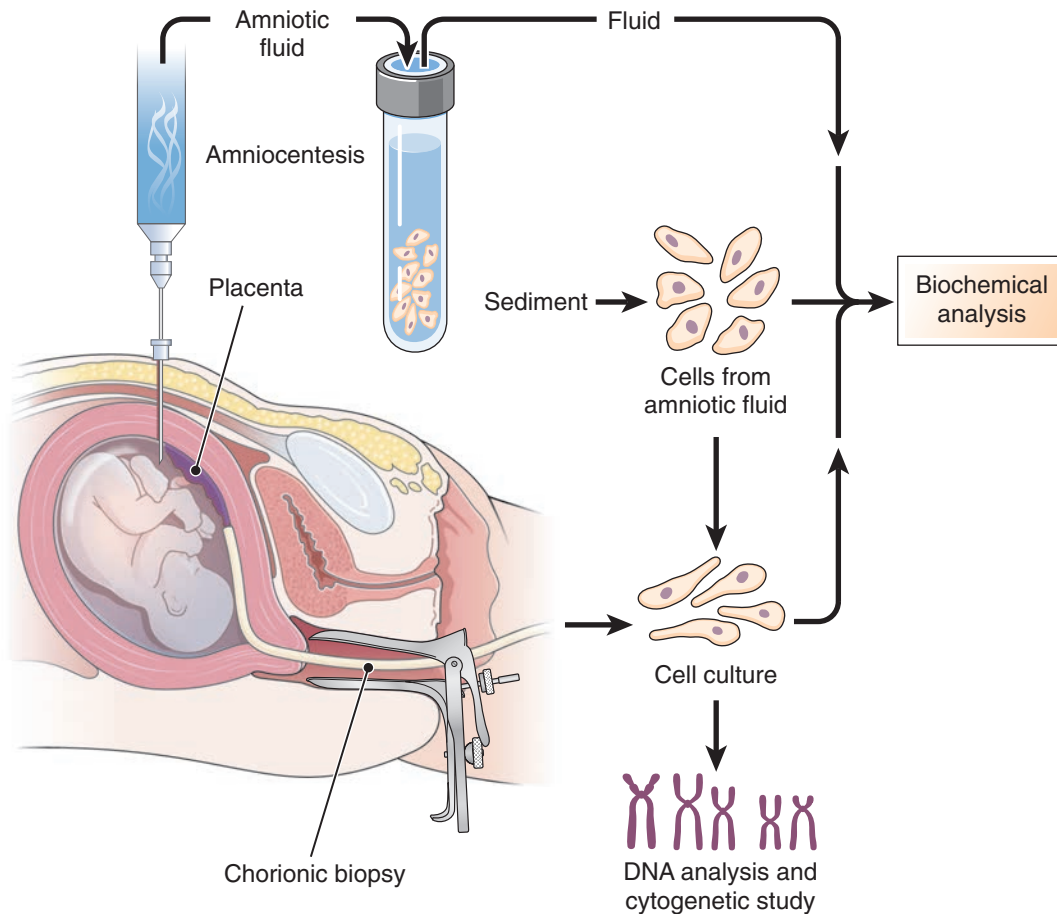
## DIAGNOSIS OF CONGENITAL DISORDERS

Many congenital disorders can now be detected before birth. Ultrasonography (**FIG. 16-21**), in addition to its use for monitoring pregnancies and determining fetal sex, can also reveal certain fetal abnormalities. In **amniocentesis** (**FIG. 16-22**), a sample is withdrawn from the amniotic cavity with a needle. The fluid obtained is analyzed for chemical abnormalities. The cells are grown in the laboratory and tested for biochemical disorders. A **karyotype** is prepared to study the genetic material (see **FIG. 2-10**).



**FIGURE 16-21** Sonogram. This transvaginal sonogram shows a 9-week-old fetus.

In **chorionic villus sampling** (CVS), biopsies of the membrane around the fetus are obtained through the cervix for analysis (see **FIG. 16-22**). This can be done at 8 to 10 weeks of pregnancy, in comparison with 14 to 16 weeks for amniocentesis.



**FIGURE 16-22** Prenatal testing. Specimens obtained by amniocentesis or chorionic villus sampling can be analyzed chemically and cells can be cultured for DNA analysis.

## Terminology

## Key Terms

The terms listed below are emphasized in this chapter. Knowing them will help you organize and prioritize your learning. These boldface terms are also found, collectively, with all chapter key terms in the Glossary.

## Pregnancy and Birth

## Disorders

<b>abortion</b> <i>ab-BOR-shun</i>	Termination of a pregnancy before the fetus is capable of surviving outside the uterus, usually at 20 weeks or 500 g; may be spontaneous or induced; a spontaneous abortion is commonly called a miscarriage
<b>anencephaly</b> <i>an-en-SEF-ab-le</i>	Congenital absence of a brain
<b>atresia</b> <i>ab-TRE-ze-ab</i>	Congenital absence or closure of a normal body opening
<b>carrier</b> <i>KAH-re-er</i>	An individual who has an unexpressed genetic defect that can be passed to his or her children
<b>cleft lip</b>	A congenital separation of the upper lip
<b>cleft palate</b>	A congenital split in the roof of the mouth
<b>congenital disorder</b> <i>kon-JEN-ib-tal</i>	A disorder that is present at birth; may be developmental or hereditary (familial)
<b>eclampsia</b> <i>eh-KLAMP-se-ab</i>	Convulsions and coma occurring during pregnancy or after delivery and associated with preeclampsia (see below) (adjective: eclamptic)
<b>ectopic pregnancy</b> <i>ek-TOP-ik</i>	Development of the fertilized ovum outside the body of the uterus; usually occurs in the uterine tube (tubal pregnancy) but may occur in other parts of the reproductive tract or abdominal cavity (see <b>FIG. 16-16</b> )
<b>hemolytic disease of the newborn (HDN)</b>	Disease that results from Rh incompatibility between the blood of a mother and her fetus; an Rh-negative mother produces antibody to Rh-positive fetal red cells that enter her circulation; these antibodies can destroy Rh-positive fetal red cells in a later pregnancy unless the mother is treated with antibodies to remove the Rh antigen; formerly called erythroblastosis fetalis
<b>mastitis</b> <i>mas-TI-tis</i>	Inflammation of the breast, usually associated with the early weeks of breast-feeding
<b>mutation</b> <i>mu-TA-shun</i>	A change in the genetic material of the cell; most mutations are harmful; if the change appears in the sex cells, it can be passed to future generations
<b>placental abruption</b> <i>ab-RUP-shun</i>	Premature separation of the placenta; <i>abruptio placentae</i>
<b>placenta previa</b> <i>PRE-ve-ab</i>	Placental attachment in the lower portion of the uterus instead of the upper portion, as is normal; may result in hemorrhage late in pregnancy
<b>preeclampsia</b> <i>pre-eh-KLAMP-se-ab</i>	A serious disorder involving new-onset hypertension and proteinuria that develops after 20 weeks of pregnancy. If untreated, may lead to eclampsia
<b>pregnancy-induced hypertension (PIH)</b>	New-onset hypertension without proteinuria that develops during pregnancy
<b>spina bifida</b> <i>SPI-nah BIF-ib-dah</i>	A congenital defect in the closure of the spinal column through which the spinal cord and its membranes may project (see <b>FIG. 16-19</b> )
<b>teratogen</b> <i>ter-AT-o-jen</i>	A factor that causes developmental abnormalities in the fetus (root <i>terat/o</i> means “malformed fetus”) (adjective: teratogenic)

## Terminology

## Key Terms (Continued)

## Diagnosis and Treatment

<b>amniocentesis</b> <i>am-ne-o-sen-TE-sis</i>	Transabdominal puncture of the amniotic sac to remove amniotic fluid for testing; tests on the cells and fluid obtained can reveal congenital abnormalities, blood incompatibility, and sex of the fetus (see FIG. 16-22)
<b>chorionic villus sampling (CVS)</b>	Removal of chorionic cells through the cervix for prenatal testing; can be done earlier in pregnancy than amniocentesis
<b>dilatation and evacuation (D&amp;E)</b>	Widening of the cervix and removal of conception products by suction
<b>karyotype</b> <i>KAR-e-o-tipe</i>	A picture of cellular chromosomes arranged in the order of decreasing size; can reveal abnormalities in the chromosomes themselves or in their number or arrangement (root kary/o means “nucleus”) (see FIG. 2-10)
<b>ultrasonography</b> <i>ul-trab-so-NOG-rab-fe</i>	The use of high-frequency sound waves to produce a photograph of an organ or tissue (see FIG. 16-21); used in obstetrics to diagnose pregnancy, multiple births, and abnormalities and also to study and measure the fetus; the image obtained is a sonogram or ultrasonogram

## Terminology

## Enrichment Terms

The terms listed below expand on the key terms to increase your knowledge of this chapter topic.

## Pregnancy and Birth

## Normal Structure and Function

<b>afterbirth</b>	The placenta and membranes delivered after birth of a child
<b>antepartum</b> <i>an-te-PAR-tum</i>	Before childbirth, with reference to the mother
<b>Braxton Hicks contractions</b>	Light uterine contractions that occur during pregnancy and increase in frequency and intensity during the third trimester; they strengthen the uterus for delivery
<b>chloasma</b> <i>klo-AZ-mah</i>	Brownish pigmentation that appears on the face during pregnancy; melasma
<b>fontanel</b> <i>fon-tan-EL</i>	A membrane-covered space between cranial bones in the fetus that later becomes ossified; a soft spot; also spelled fontanelle
<b>intrapartum</b> <i>in-trab-PAR-tum</i>	Occurring during childbirth
<b>linea nigra</b> <i>LIN-e-ah NI-grah</i>	A dark line on the abdomen from the umbilicus to the pubic region that may appear late in pregnancy
<b>lochia</b> <i>LO-ke-ah</i>	The mixture of blood, mucus, and tissue discharged from the uterus after childbirth
<b>meconium</b> <i>meh-KO-ne-um</i>	The first feces of the newborn
<b>peripartum</b> <i>per-ih-PAR-tum</i>	Occurring during the end of pregnancy or the first few months after delivery, with reference to the mother
<b>postpartum</b>	After childbirth, with reference to the mother
<b>premature</b>	Describing an infant born before the organ systems are fully developed; immature

(continued)



## Terminology

## Enrichment Terms (Continued)

<b>preterm</b>	Occurring before the 37th week of gestation; describing an infant born before the 37th week of gestation
<b>puerperium</b> <i>pu-er-PERE-e-um</i>	The first 42 days after childbirth, during which the mother's reproductive organs usually return to normal (root puer means "child")
<b>striae atrophicae</b> <i>STRI-e ab-TRO-fib-ke</i>	Pinkish or gray lines that appear where skin has been stretched, as in pregnancy; stretch marks, striae gravidarum
<b>umbilicus</b> <i>um-bih-LI-kus</i>	The scar in the middle of the abdomen that marks the attachment point of the umbilical cord to the fetus; the navel; also pronounced <i>um-BIL-ih-kus</i>
<b>vernix caseosa</b> <i>VER-niks ka-se-O-sah</i>	The cheese-like deposit that covers and protects the fetus (literally "cheesy varnish")
<b>Disorders</b>	
<b>cephalopelvic disproportion</b> <i>sef-ab-lo-PEL-vik</i>	The condition in which the head of the fetus is larger than the mother's pelvic outlet; also called fetopelvic disproportion
<b>choriocarcinoma</b> <i>kor-e-o-kar-sih-NO-mah</i>	A rare malignant neoplasm composed of placental tissue
<b>galactorrhea</b> <i>gab-lak-to-RE-ab</i>	Excessive secretion of milk or continued milk production after breast-feeding has ceased; often results from excess prolactin secretion and may signal a pituitary tumor
<b>hydatidiform mole</b> <i>bi-dab-TID-ih-form</i>	A benign overgrowth of placental tissue; the placenta dilates and resembles grape-like cysts; the neoplasm may invade the uterine wall, causing rupture; also called hydatid mole
<b>hydramnios</b> <i>hi-DRAM-ne-os</i>	An excess of amniotic fluid; also called polyhydramnios
<b>oligohydramnios</b> <i>ol-ih-go-bi-DRAM-ne-os</i>	A deficiency of amniotic fluid
<b>patent ductus arteriosus (PDA)</b> <i>PA-tent DUK-tusar-te-re-O-sus</i>	Persistence of the ductus arteriosus after birth so that blood continues to shunt from the pulmonary artery to the aorta
<b>puerperal infection</b> <i>pu-ER-per-al</i>	Infection of the genital tract after delivery
<b>Diagnosis and Treatment</b>	
<b>abortifacient</b> <i>a-bor-tih-FA-shent</i>	Agent that induces abortion
<b>alpha-fetoprotein (AFP)</b> <i>AL-fab-fe-to-PRO-tene</i>	A fetal protein that may be elevated in amniotic fluid and maternal serum in cases of certain fetal disorders
<b>artificial insemination (AI)</b>	Placement of active semen into the vagina or cervix for the purpose of impregnation; the semen can be from a husband, partner, or donor
<b>cesarean section</b> <i>seh-ZAR-e-an</i>	Incision of the abdominal wall and uterus for delivery of a fetus; also called cesarean birth
<b>endometrial ablation</b> <i>ab-LA-shun</i>	Selective destruction of the endometrium for therapeutic purpose; done to relieve excessive menstrual bleeding (menorrhagia)
<b>extracorporeal membrane oxygenation (ECMO)</b> <i>eks-trab-kor-PO-re-al</i>	A technique for pulmonary bypass in which deoxygenated blood is removed, passed through a circuit that oxygenates the blood, and then returned; used for selected newborn and pediatric patients in respiratory failure with an otherwise good prognosis

## Terminology

## Enrichment Terms (Continued)

<b>in vitro fertilization (IVF)</b>	Clinical procedure for achieving fertilization when it cannot be accomplished naturally; an oocyte (immature ovum) is removed, fertilized in the laboratory, and placed as a zygote into the uterus or fallopian tube (ZIFT, zygote intrafallopian transfer); alternatively, an ovum can be removed and placed along with sperm cells into the fallopian tube (GIFT, gamete intrafallopian transfer) (see <b>BOX 16-4</b> )
<b>obstetrics</b> <i>ob-STET-riks</i>	The branch of medicine that treats women during pregnancy, childbirth, and the puerperium; usually combined with the practice of gynecology
<b>pediatrics</b> <i>pe-de-AT-riks</i>	The branch of medicine that treats children and diseases of children (root ped/o means “child”)
<b>pelvimetry</b> <i>pel-VIM-eb-tre</i>	Measurement of the pelvis by manual examination or radiographic study to determine whether delivery of a fetus through the vagina will be possible
<b>Pitocin</b> <i>pib-TO-sin</i>	Trade name for oxytocin; used to induce and hasten labor
<b>presentation</b>	Term describing the part of the fetus that can be felt by vaginal or rectal examination; normally the head presents first (vertex presentation), but sometimes the buttocks (breech presentation), face, or other part presents first
<b>RhoGAM</b> <i>RO-gam</i>	Trade name for a preparation of antibody to the Rh(D) antigen; used to prevent hemolytic disease of the newborn in cases of Rh incompatibility

## Terminology

## Abbreviations

The abbreviations listed below are emphasized in this chapter. These are also found, collectively, with all chapter abbreviations in Appendix 2.

## Pregnancy and Birth

<b>AB</b>	Abortion
<b>AFP</b>	Alpha-fetoprotein
<b>AGA</b>	Appropriate for gestational age
<b>AI</b>	Artificial insemination
<b>ART</b>	Assisted reproductive technology
<b>C-section</b>	Cesarean section
<b>CPD</b>	Cephalopelvic disproportion
<b>CVS</b>	Chorionic villus sampling
<b>D&amp;E</b>	Dilatation and evacuation
<b>ECMO</b>	Extracorporeal membrane oxygenation
<b>EDC</b>	Estimated date of confinement
<b>FHR</b>	Fetal heart rate
<b>FHT</b>	Fetal heart tone
<b>FTND</b>	Full-term normal delivery
<b>FTP</b>	Full-term pregnancy
<b>GA</b>	Gestational age

<b>GIFT</b>	Gamete intrafallopian transfer
<b>hCG</b>	Human chorionic gonadotropin
<b>HDN</b>	Hemolytic disease of the newborn
<b>IVF</b>	In vitro fertilization
<b>LMP</b>	Last menstrual period
<b>NB</b>	Newborn
<b>NICU</b>	Neonatal intensive care unit
<b>OB</b>	Obstetrics, obstetrician
<b>PDA</b>	Patent ductus arteriosus
<b>PIH</b>	Pregnancy-induced hypertension
<b>PKU</b>	Phenylketonuria
<b>SVD</b>	Spontaneous vaginal delivery
<b>UC</b>	Uterine contractions
<b>UTP</b>	Uterine term pregnancy
<b>VBAC</b>	Vaginal birth after cesarean section
<b>ZIFT</b>	Zygote intrafallopian transfer

## Case Study Revisited

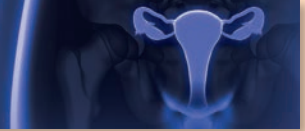### Abigail's Follow-Up Study

After a short stay in the PACU, Abigail was alert and oriented when she arrived at her private postpartum hospital room. Her healthy newborn daughter was immediately brought into the room and placed by Abigail's face, neck, and chest. Skin to skin contact is an important aspect to initial bonding with a newborn. Both parents held, stroked, kissed, and talked to their new daughter. The nurse explained that talking is important, as a newborn already knows its parents' voices and is soothed by the familiar sounds.

Abigail was fortunate that her hospital had "family-centered" care. The private postpartum room included a fold out bed for her husband. The healthy newborn was also able to stay in the room with mom and dad. Rooming-in, or having a baby with the parents at all times, is increasingly popular in hospitals. Both mom and newborn had frequent nurse checks around the clock.

Abigail was encouraged to get up and walk the next day. Her incision was healing well, and there were no signs of infection. She was able to tolerate a regular diet and required minimal medication for pain. Abigail experienced minor discomfort with breast-feeding initially, but she and the baby began to get into a routine, and the feeding progressed well. The nurse explained to Abigail that if she needed rest it was okay for her newborn to spend a few hours in the nursery while Abigail slept. Abigail would just need to tell the nurses whether they could give her newborn baby formula or would like her returned to Abigail for breast-feeding.

Abigail's husband offered needed support and encouragement and was very helpful with their 3 y/o son, who missed his mom. Both baby and mom were doing well and were discharged home. Abigail's mother was stopping by the house every day to take care of the "big brother," help with meals, and do some light house-keeping so Abigail could get some important rest.

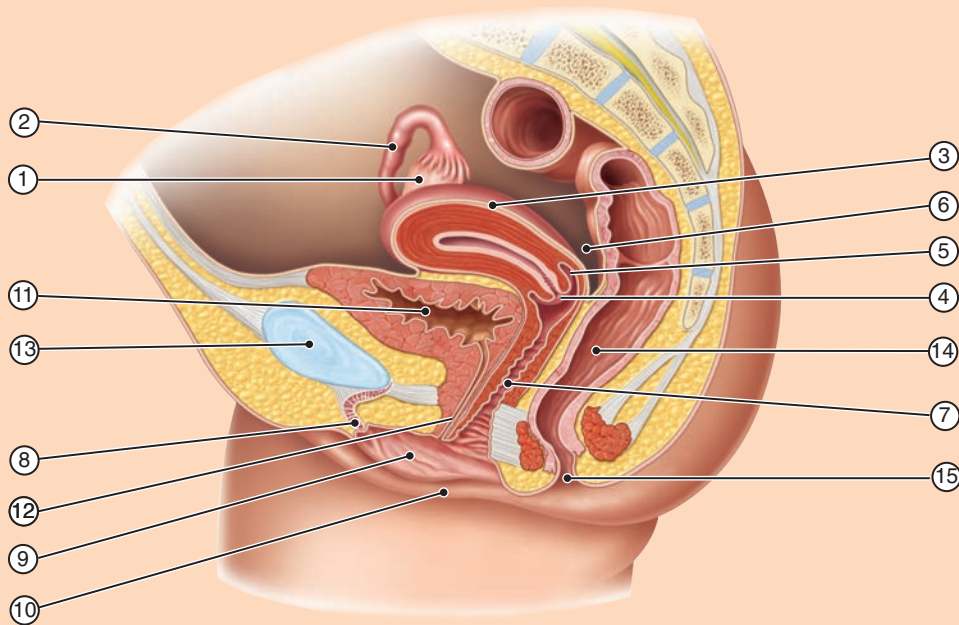


This review tests your understanding of the content introduced in this chapter. Follow the instructions for each exercise and check your answers in Appendix 11.

### LABELING EXERCISE

#### THE FEMALE REPRODUCTIVE SYSTEM

Write the name of each numbered part on the corresponding line.



- Anus
- Cervix
- Clitoris
- Labium majus
- Labium minus
- Ovary
- Posterior fornix
- Pubic symphysis

- Rectouterine pouch
- Rectum
- Urethra
- Urinary bladder
- Uterine tube
- Uterus
- Vagina

- 1. \_\_\_\_\_
- 2. \_\_\_\_\_
- 3. \_\_\_\_\_
- 4. \_\_\_\_\_
- 5. \_\_\_\_\_
- 6. \_\_\_\_\_
- 7. \_\_\_\_\_
- 8. \_\_\_\_\_

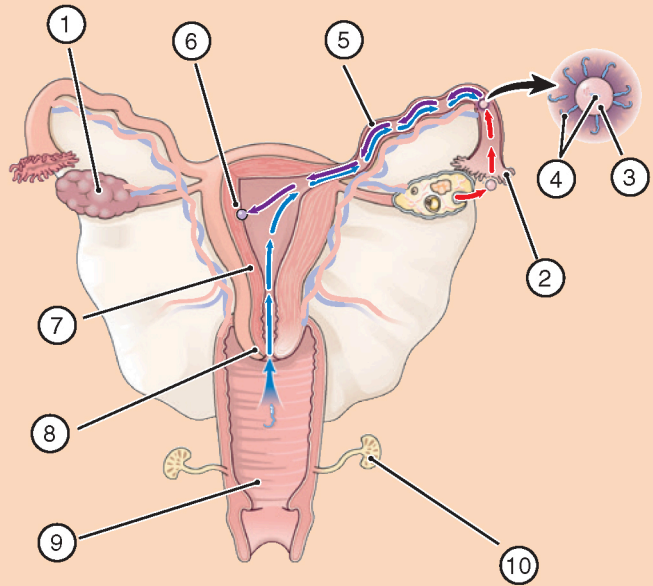
- 9. \_\_\_\_\_
- 10. \_\_\_\_\_
- 11. \_\_\_\_\_
- 12. \_\_\_\_\_
- 13. \_\_\_\_\_
- 14. \_\_\_\_\_
- 15. \_\_\_\_\_

**OVULATION AND FERTILIZATION**

Write the name of each numbered part on the corresponding line.

- |                                      |                           |
|--------------------------------------|---------------------------|
| Body of uterus                       | Ovary                     |
| Cervix                               | Ovum                      |
| Fimbriae                             | Sperm cells (spermatozoa) |
| Greater vestibular (Bartholin) gland | Uterine tube              |
| Implanted embryo                     | Vagina                    |

1. \_\_\_\_\_
2. \_\_\_\_\_
3. \_\_\_\_\_
4. \_\_\_\_\_
5. \_\_\_\_\_
6. \_\_\_\_\_
7. \_\_\_\_\_
8. \_\_\_\_\_
9. \_\_\_\_\_
10. \_\_\_\_\_



**TERMINOLOGY**

**MATCHING**

Match the following terms, and write the appropriate letter to the left of each number.

- |                        |   |
|------------------------|---|
| _____ 1. vulva         | a. fertilized egg                                 |
| _____ 2. gestation     | b. female erectile tissue                         |
| _____ 3. oxytocin      | c. external female genitalia                      |
| _____ 4. zygote        | d. period of development in the uterus            |
| _____ 5. clitoris      | e. hormone that stimulates labor                  |
| _____ 6. menostasis    | a. first menstrual period                         |
| _____ 7. metrorrhagia  | b. excess uterine bleeding                        |
| _____ 8. menarche      | c. suppression of menstruation                    |
| _____ 9. gynecogenic   | d. wasting of uterine tissue                      |
| _____ 10. metratrophia | e. producing female characteristics               |
| _____ 11. eclampsia    | a. fibroid  |
| _____ 12. mutation     | b. absence of a normal body opening               |
| _____ 13. teratogen    | c. genetic change                                 |
| _____ 14. atresia      | d. convulsions and coma associated with pregnancy |
| _____ 15. leiomyoma    | e. cause of fetal abnormality                     |

**Enrichment Terms**

- |                        |  |
|------------------------|--|
| ___ 16. puerperium     | a. uterine discharge after childbirth                      |
| ___ 17. linea nigra    | b. period after childbirth                                 |
| ___ 18. meconium       | c. first feces of the newborn                              |
| ___ 19. hymen          | d. membrane that covers the vaginal opening                |
| ___ 20. lochia         | e. dark line on the abdomen from umbilicus to pubic region |
| ___ 21. hirsutism      | a. excess of amniotic fluid                                |
| ___ 22. dyspareunia    | b. pain during intercourse                                 |
| ___ 23. vernix caseosa | c. whitish vaginal discharge                               |
| ___ 24. leukorrhea     | d. excess hair growth                                      |
| ___ 25. polyhydramnios | e. fetal protective covering                               |

**FILL IN THE BLANKS**

Complete the sentence with the correct term(s).

26. The instrument for examining the vagina and cervix is the \_\_\_\_\_.
27. The female gonad is the \_\_\_\_\_.
28. The herniation of the rectum into the vaginal wall is called \_\_\_\_\_.
29. The ovarian follicle encloses a developing \_\_\_\_\_.
30. The organ that nourishes and maintains the developing fetus is the \_\_\_\_\_.
31. The secretion of milk from the mammary glands is called \_\_\_\_\_.
32. Loss of an embryo or fetus before 20 weeks or 500 g is termed a(n) \_\_\_\_\_.
33. Parametritis (*par-ah-me-TRI-tis*) means inflammation of the tissue near the \_\_\_\_\_.
34. Polymastia (*pol-e-MAS-te-ah*) means the presence of more than one pair of \_\_\_\_\_.

**TRUE-FALSE**

Examine the following statements. If the statement is true, write T in the first blank. If the statement is false, write F in the first blank, and correct the statement by replacing the underlined word in the second blank.

- |   | True or False | Correct Answer |
|---|---------------|----------------|
| 35. Agalactia is the lack of <u>milk</u> production.                            | _____         | _____          |
| 36. For the first 2 months, the developing offspring is called a <u>fetus</u> . | _____         | _____          |
| 37. The muscular wall of the uterus is the <u>endometrium</u> .                 | _____         | _____          |
| 38. After ovulation, the ovarian follicle becomes a <u>fimbriae</u> .           | _____         | _____          |
| 39. Fertilization of an ovum occurs in the <u>uterus</u> .                      | _____         | _____          |
| 40. The Pap smear is a test for <u>cervical</u> cancer.                         | _____         | _____          |
| 41. Parturition is <u>childbirth</u> .  | _____         | _____          |
| 42. The fallopian tube is the <u>uterine tube</u> .                             | _____         | _____          |
| 43. A fontanel is the soft spot between the <u>cranial bones</u> .              | _____         | _____          |

**DEFINITIONS**

*Define the following terms.*

44. retrouterine (*reh-tro-U-ter-in*) \_\_\_\_\_
45. hysteropathy (*his-teh-ROP-ah-the*) \_\_\_\_\_
46. metromalacia (*me-tro-mah-LA-she-ah*) \_\_\_\_\_
47. pyosalpinx (*pi-o-SAL-pinx*) \_\_\_\_\_
48. colpostenosis (*kol-po-steh-NO-sis*) \_\_\_\_\_
49. vulvodynia (*vul-vo-DIN-e-ah*) \_\_\_\_\_
50. postnatal (*post-NA-tal*) \_\_\_\_\_
51. inframammary (*in-frah-MAM-ah-re*) \_\_\_\_\_
52. extraembryonic (*eks-trah-em-bre-ON-ik*) \_\_\_\_\_
53. tripara (*TRIP-ah-rah*) \_\_\_\_\_
54. teratogenic (*TER-at-o-jen-ik*) \_\_\_\_\_

*Write words for the following definitions.*

55. hernia of a uterine tube \_\_\_\_\_
56. suture of the vulva (episi/o) \_\_\_\_\_
57. narrowing of the uterus (metr/o) \_\_\_\_\_
58. surgical removal of the uterus (hyster/o) and uterine tubes \_\_\_\_\_
59. radiograph of the breast (mamm/o) \_\_\_\_\_
60. abnormal or difficult labor \_\_\_\_\_
61. rupture of the amniotic sac \_\_\_\_\_
62. study of the embryo \_\_\_\_\_
63. measurement of a fetus \_\_\_\_\_

*In Abigail's opening case study, find words for the following.*

64. term that refers to a pregnant woman \_\_\_\_\_
65. upper rounded portion of the uterus \_\_\_\_\_
66. measurement of the pelvis \_\_\_\_\_
67. above the pubic bone \_\_\_\_\_
68. test to measure the health of a newborn \_\_\_\_\_
69. newborn \_\_\_\_\_

**OPPOSITES**

*Write a word that means the opposite of the following.*

70. oligohydramnios \_\_\_\_\_
71. postnatal \_\_\_\_\_
72. dystocia \_\_\_\_\_
73. ovulatory \_\_\_\_\_
74. extrauterine \_\_\_\_\_

**ADJECTIVES**

*Write the adjective form of the following.*

75. cervix \_\_\_\_\_

76. uterus \_\_\_\_\_

77. perineum \_\_\_\_\_

78. vagina \_\_\_\_\_

79. embryo \_\_\_\_\_

80. amnion \_\_\_\_\_

**PLURALS**

*Write the plural form of the following.*

81. ovum \_\_\_\_\_

82. cervix \_\_\_\_\_

83. fimbria \_\_\_\_\_

84. labium \_\_\_\_\_

**ELIMINATIONS**

*In each of the sets below, underline the word that does not fit in with the rest, and explain the reason for your choice.*

85. amniocentesis — chorionic villus sampling — karyotype — ultrasonography — candidiasis

\_\_\_\_\_

86. hemophilia — albinism — measles — PKU — cystic fibrosis

\_\_\_\_\_

87. colostrum — progesterone — LH — estrogen — FSH

\_\_\_\_\_

88. umbilical cord — labia majora — amniotic fluid — chorion — placenta

\_\_\_\_\_

89. placental abruption — spina bifida — pregnancy-induced hypertension — placenta previa — eclampsia

\_\_\_\_\_

**FOLLOW THE PATH**

*Follow the path of an ovum from production to implantation. Place the letters “A” through “D” next to the terms on the space provided to put the terms in proper order.*

90. uterine tube \_\_\_\_\_

91. fimbriae \_\_\_\_\_

92. ovary \_\_\_\_\_

93. uterus \_\_\_\_\_



**WORD BUILDING**

Write a word for the following definitions using the word parts given. Each word part can be used more than once.

-graphy   episi/o   -plasty   intra-   cervic/o   mamm/o   -itis   -al   -tomy   trans-

94. plastic repair of the vulva \_\_\_\_\_
95. inflammation of the cervix \_\_\_\_\_
96. radiographic study of the breast \_\_\_\_\_
97. plastic repair of the breast \_\_\_\_\_
98. radiographic study of the cervix \_\_\_\_\_
99. incision of the vulva \_\_\_\_\_
100. within the cervix \_\_\_\_\_
101. plastic repair of the cervix \_\_\_\_\_
102. incision of the cervix \_\_\_\_\_
103. through the cervix \_\_\_\_\_

**ABBREVIATIONS**

Write the meaning of the following abbreviations.

104. hCG \_\_\_\_\_
105. DUB \_\_\_\_\_
106. LMP \_\_\_\_\_
107. FHR \_\_\_\_\_
108. GA \_\_\_\_\_
109. VBAC \_\_\_\_\_

**WORD ANALYSIS**

Define the following words, and give the meaning of the word parts in each. Use a dictionary if necessary.

110. antiangiogenesis (*an-te-an-je-o-JEN-eh-sis*)
- a. anti- \_\_\_\_\_
- b. angi/o \_\_\_\_\_
- c. gen \_\_\_\_\_
- d. e/sis \_\_\_\_\_
111. gynecomastia (*gi-neh-ko-MAS-te-ah*)
- a. gynec/o \_\_\_\_\_
- b. mast/o \_\_\_\_\_
- c. -ia \_\_\_\_\_
112. oxytocia (*ok-se-TO-se-ah*)
- a. oxy \_\_\_\_\_
- b. toc \_\_\_\_\_
- c. -ia \_\_\_\_\_

113. oligohydramnios (*ol-ih-go-hi-DRAM-ne-os*)

a. oligo- \_\_\_\_\_

b. hydr/o \_\_\_\_\_

c. amnio(s) \_\_\_\_\_

114. galactorrhea (*gab-LAK-tor-e-ah*)

a. galact/o \_\_\_\_\_

b. (r)rhea \_\_\_\_\_

115. anencephaly (*an-en-SEF-ah-le*)

a. an- \_\_\_\_\_

b. encephal/o \_\_\_\_\_

c. -y \_\_\_\_\_

# Additional Case Studies

## Case Study 16-1: Total Abdominal Hysterectomy With Bilateral Salpingo-oophorectomy

Naomi, a 60 y/o gravida 2, para 2, had spent 3 months under the care of her gynecologist (GYN) for treatment of postmenopausal bleeding and cervical dysplasia. She had had several vaginal examinations with Pap smears, a uterine ultrasound, colposcopy with endocervical biopsies, and a D&C with cone biopsy. She wanted to take hormone replacement therapy (HRT), but her doctor thought she was at too much risk with the abnormal cells on her cervix and the excessive bleeding.

She had a TAH and BSO under general anesthesia with no complications and an uneventful recovery. Her uterus had been prolapsed on abdominal examination, but there was no sign of malignancy or PID. The pathology report revealed several uterine leiomyomas and stenosis of the right uterine tube. She was discharged on the second postoperative day with few activity restrictions.

### Case Study 16-1 Questions

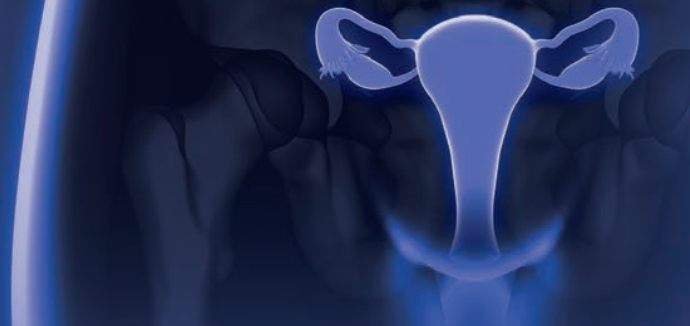Follow the instructions for each question and check your answers in Appendix 11.

**Multiple Choice.** Select the best answer, and write the letter of your choice to the left of each number.

- |   |  |
|---|--|
| <p>_____ 1. Naomi is a gravida 2, para 2. This means</p> <ul style="list-style-type: none"><li>a. she has four children from two pregnancies</li><li>b. she has had two pregnancies and two births</li><li>c. she has had four pregnancies and two births</li><li>d. she has one set of twins</li></ul> <p>_____ 2. An endocervical biopsy is</p> <ul style="list-style-type: none"><li>a. a cone-shaped tissue sample from the uterine fundus</li><li>b. a tissue sample from within the neck</li><li>c. a tissue sample from the lining of the cervix</li><li>d. a scraping of tissue cells from the vaginal wall</li></ul> | <p>_____ 3. A curettage is a(n)</p> <ul style="list-style-type: none"><li>a. suturing</li><li>b. scraping</li><li>c. incision</li><li>d. examination</li></ul> <p>_____ 4. A colposcopy is an endoscopic examination of the</p> <ul style="list-style-type: none"><li>a. vagina</li><li>b. fundus</li><li>c. intraperitoneal pelvic floor</li><li>d. uterus and uterine tubes</li></ul> <p>_____ 5. Another name for a leiomyoma is a(n)</p> <ul style="list-style-type: none"><li>a. ectopic pregnancy</li><li>b. uterine fibroid</li><li>c. myoma</li><li>d. b and c</li></ul> |
|---|--|

Define each of the following abbreviations.

- 6. D&C \_\_\_\_\_
- 7. BSO \_\_\_\_\_
- 8. HRT \_\_\_\_\_
- 9. TAH \_\_\_\_\_
- 10. GYN \_\_\_\_\_



## Case Study 16-2: In Vitro Fertilization

Ruth had worked as a technologist in the in vitro fertilization (IVF) laboratory at University Medical Center for 4 years. Her department was the advanced reproductive technology program. Although her work was primarily in the laboratory, she followed each patient through all five phases of the IVF and embryo transfer treatment cycle: follicular development, aspiration of the preovulatory follicles, sperm preparation, IVF, and embryo transfer. Her department does both gamete intrafallopian transfer (GIFT) and zygote intrafallopian transfer (ZIFT).

While the female patient is in surgery having an ultrasound-guided transvaginal oocyte retrieval, Ruth examines the recently donated sperm for motility and quantity. She prepares to inoculate the sample into the cytoplasm of the ova as soon as she receives the cells from the OR. After inoculation, she places the sterile petri dish with the fertilized oocytes into an incubator until they are ready to be introduced into the female patient.

16

### Case Study 16-2 Questions

Follow the instructions for each question and check your answers in Appendix 11.

*Write a term from the case study with each of the following meanings.*

1. cell produced by fertilization \_\_\_\_\_
2. an immature egg cell \_\_\_\_\_
3. pertaining to the structure in which an egg ripens \_\_\_\_\_

*Define each of the following abbreviations.*

4. IVF \_\_\_\_\_
5. ZIFT \_\_\_\_\_
6. GIFT \_\_\_\_\_

# Appendix 1

## Commonly Used Symbols

Commonly Used Symbols		
Symbol	Meaning	Chapter
1°	primary	3
2°	secondary (to)	3
$\Delta$	change (Greek delta)	3
Ⓕ	left	3
Ⓖ	right	3
↑	increase(d)	3
↓	decrease(d)	3
♂	male	3
♀	female	3
°	degree	3
^	above	3
v	below	3
=	equal to	3
≠	not equal to	3
±	doubtful, slight	3
~	approximately	3
×	times	3
#	number, pound	3

# Appendix 2

## Abbreviations and Their Meanings

Abbreviations and Their Meanings					
Abbreviation	Meaning	Chapter	Abbreviation	Meaning	Chapter
ā	before	3	AK	above the knee	5
A, Acc	accommodation	8	ALL	acute lymphoblastic (lymphocytic) leukemia	11
āā	of each	3	ALS	amyotrophic lateral sclerosis	6, 7
A1c	glycated hemoglobin	9	AMA	against medical advice	3
Ab	antibody	11	AMB	ambulatory	3
AB	abortion	16	AMD	age-related macular degeneration	8
ABC	aspiration biopsy cytology	3	AMI	acute myocardial infarction	10
ABCDE	asymmetry, uneven borders, different colors, diameter of more than 6 mm, and evolution (change)	4	AML	acute myeloblastic (myelogenous) leukemia	11
ABG(s)	arterial blood gas(es)	12	ANS	autonomic nervous system	7
ABR	auditory brainstem response	8	AP	anteroposterior	3
ac	before meals	3	APAP	acetaminophen	3
AC	air conduction	8	APC	atrial premature complex; antigen-presenting cell	10, 11
ACE	angiotensin-converting enzyme	10, 14	APTT	activated partial thromboplastin time	11
ACh	acetylcholine	6, 7	aq	water (Latin, <i>aqua</i> )	3
ACL	anterior cruciate ligament	5	AR	aortic regurgitation	10
ACTH	adrenocorticotrophic hormone	9	ARB	angiotensin receptor blocker	10
ad lib	as desired	3	ARC	abnormal retinal correspondence	8
AD	Alzheimer disease	7	ARDS	acute respiratory distress syndrome	12
ADH	antidiuretic hormone	9, 14	ARF	acute respiratory failure, shock lung; acute renal failure	12, 14
ADHD	attention-deficit/hyperactivity disorder	7	ART	assisted reproductive technology	16
ADL	activities of daily living	3	ASA	acetylsalicylic acid (aspirin)	3
AE	above the elbow	5	As, AST	astigmatism	8
AED	automated external defibrillator	10	AS	atrial stenosis; arteriosclerosis	10
AF	acid fast; atrial fibrillation	3, 10	ASCVD	arteriosclerotic cardiovascular disease	10
AFB	acid-fast bacillus	12	ASD	autism spectrum disorder; atrial septal defect	7, 10
AFP	alpha-fetoprotein	3, 16	ASF	anterior spinal fusion	5
Ag	antigen; also silver	11	ASHD	arteriosclerotic heart disease	10
AGA	appropriate for gestational age	16			
AI	artificial insemination; aromatase inhibitor	16			
AIDS	acquired immunodeficiency syndrome	11, 15			

(continued)

Abbreviations and Their Meanings (*Continued*)

Abbreviation	Meaning	Chapter	Abbreviation	Meaning	Chapter
ASHP	American Society of Health System Pharmacists	3	CAPD	continuous ambulatory peritoneal dialysis	14
AT	atrial tachycardia	10	CBC	complete blood count	11
ATN	acute tubular necrosis	14	CBD	common bile duct	13
AV	atrioventricular	10	CBF	cerebral blood flow	7
BAEP	brainstem auditory evoked potentials	7, 8	CBR	complete bed rest	3
BBB	bundle branch block	10	cc	with correction	8
BC	bone conduction	8	CC	chief complaint	3
BCG	bacille Calmette–Guérin (tuberculosis vaccine)	12	CCPD	continuous cyclic peritoneal dialysis	14
BE	below the elbow; barium enema (for radiographic study of the colon)	5, 13	CCU	coronary/cardiac care unit	10
bid, b.i.d.	twice a day (Latin, <i>bis in die</i> )	3	CF	cystic fibrosis	12
BK	below the knee	5	CFS	chronic fatigue syndrome	6
BM	bowel movement	13	CGL	chronic granulocytic leukemia	11
BMD	bone mineral density	5	CHD	coronary heart disease	10
BNO	bladder neck obstruction	15	CHF	congestive heart failure	10
BP	blood pressure	3, 10	Ci	Curie (unit of radioactivity)	3
BPH	benign prostatic hyperplasia (hypertrophy)	15	CIN	cervical intraepithelial neoplasia	16
bpm	beats per minute	3, 10	CIS	carcinoma in situ	3
BRCA1	breast cancer gene 1	16	CJD	Creutzfeldt–Jakob disease	7
BRCA2	breast cancer gene 2	16	CK	creatinine kinase	6
BRP	bathroom privileges	3	CK-MB	creatinine kinase MB	10
BS	bowel sounds; breath sounds; blood sugar	3, 9, 12	CLL	chronic lymphocytic leukemia	11
BSA	body surface area	4	cm	centimeter	Appendix 8
BSE	breast self-examination	16	CMG	cystometry, cystometry	14
BSO	bilateral salpingo-oophorectomy	16	CML	chronic myelogenous leukemia	11
BT	bleeding time	11	CNS	central nervous system; clinical nurse specialist	7
BUN	blood urea nitrogen	14	c/o, CO	complains (complaining) of	3
BV	bacterial vaginosis	16	Co	coccyx; coccygeal	5
bx	biopsy	3	CO <sub>2</sub>	carbon dioxide	12
Ā	with	3	COPD	chronic obstructive pulmonary disease	12
C	Celsius (centigrade); compliance; cervical vertebra	3, 5, 12	CP	cerebral palsy	7
C-section	cesarean section	16	CPAP	continuous positive airway pressure	12
CA, Ca	cancer	3	CPD	cephalopelvic disproportion	16
CABG	coronary artery bypass graft	10	CPR	cardiopulmonary resuscitation	10
CAD	coronary artery disease	10	CRF	chronic renal failure	14
CAM	complementary and alternative medicine	3	crit	hematocrit	11
cap	capsule	3	CRP	C-reactive protein	10
			C&S	culture and (drug) sensitivity (of bacteria)	3

## Abbreviations and Their Meanings (Continued)

Abbreviation	Meaning	Chapter	Abbreviation	Meaning	Chapter
CSF	cerebrospinal fluid	7	EBL	estimated blood loss	3
CSII	continuous subcutaneous insulin infusion	9	EBV	Epstein–Barr virus	11
CT	computed tomography	3	ECG (EKG)	electrocardiogram, electrocardiography	10
CTA	computed tomography angiography	10	ECMO	extracorporeal membrane oxygenation	16
CTE	chronic traumatic encephalopathy	7	ED	emergency department; erectile dysfunction	3, 15
CTS	carpal tunnel syndrome	6	EDC	estimated date of confinement	16
CVA	cerebrovascular accident	7, 10	EEG	electroencephalogram; electroencephalograph(y)	7
CVD	cardiovascular disease; cerebrovascular disease	10	EGD	esophagogastroduodenoscopy	13
CVI	chronic venous insufficiency	10	ELISA	enzyme-linked immunosorbent assay	11
CVP	central venous pressure	10	elix	elixir	3
CVS	chorionic villus sampling	16	Em	emmetropia	8
CXR	chest x-ray	12	EMG	electromyography, electromyogram	6
D&C	dilatation and curettage	16	ENG	electronystagmography	8
DAW	dispense as written	3	ENT	ear(s), nose, and throat	8
dB	decibel	8	EOM	extraocular movement, muscles	8
dc, D/C	discontinue	3	EOMI	extraocular muscles intact	3
DCIS	ductal carcinoma in situ	16	EPO, EP	erythropoietin	11, 14
D&E	dilation and evacuation	16	ERCP	endoscopic retrograde cholangiopancreatography	13
DES	diethylstilbestrol	16	ERG	electroretinography	8
DEXA	dual-energy x-ray absorptiometry (scan)	5	ERV	expiratory reserve volume	12
DIC	disseminated intravascular coagulation	11	ESR	erythrocyte sedimentation rate	11
DIFF	differential count	11	ESRD	end-stage renal disease	14
DIP	distal interphalangeal	5	ESWL	extracorporeal shock-wave lithotripsy	14
DJD	degenerative joint disease	5	ET	esotropia	8
dL	deciliter	Appendix 8	ETOH	alcohol, ethyl alcohol	3
DLE	discoid lupus erythematosus	4	F	Fahrenheit	3
DM	diabetes mellitus	9	FAP	familial adenomatous polyposis	13
DNR	do not resuscitate	3	FBG	fasting blood glucose	9
DOE	dyspnea on exertion	10	FBS	fasting blood sugar	9
DTaP	diphtheria, tetanus, acellular pertussis (vaccine)	12	FC	finger counting	8
DRE	digital rectal examination	15	FDA	Food and Drug Administration	3
DS	double strength	3	FEV	forced expiratory volume	12
DSM	<i>Diagnostic and Statistical Manual of Mental Disorders</i>	7	FFP	fresh frozen plasma	11
DTR	deep tendon reflexes	7	FHR	fetal heart rate	16
DUB	dysfunctional uterine bleeding	16	FHT	fetal heart tone	16
DVT	deep vein thrombosis	10	FMS	fibromyalgia syndrome	6
Dx	diagnosis	3	FPG	fasting plasma glucose	9

(continued)



## Abbreviations and Their Meanings (Continued)

Abbreviation	Meaning	Chapter	Abbreviation	Meaning	Chapter
FRC	functional residual capacity	12	HL	hearing level	8
FSH	follicle-stimulating hormone	9, 15, 16	HM	hand movements	8
FTI	free thyroxine index	9	HNP	herniated nucleus pulposus	5
FTND	full-term normal delivery	16	h/o	history of	3
FTP	full-term pregnancy	16	HPI	history of present illness	3
FTSG	full-thickness skin graft	4	HPS	<i>Hantavirus</i> pulmonary syndrome	12
FUO	fever of unknown origin	3	HPV	human papillomavirus	16
FVC	forced vital capacity	12	HR	heart rate	3
Fx	fracture	5	HRT	hormone replacement therapy	16
g	gram	Appendix 8	hs	at bedtime	3
GA	gestational age	16	hs-CRP	high sensitivity C-reactive protein (test)	10
GAD	generalized anxiety disorder	7	HSV	herpes simplex virus	15
GC	gonococcus	15, 16	Ht, Hct	hematocrit	11
GDM	gestational diabetes mellitus	9	HTN	hypertension	10
GERD	gastroesophageal reflux disease	13	Hx	history	3
GFR	glomerular filtration rate	14	Hz	Hertz	8
GH	growth hormone	9	<sup>131</sup> I	iodine-131 (radioactive iodine)	9
GI	gastrointestinal	13	I&D	incision and drainage	3
GIFT	gamete intrafallopian transfer	16	I&O	intake and output	3
Gm <sup>+</sup>	Gram positive	3	IABP	intra-aortic balloon pump	10
Gm <sup>-</sup>	Gram negative	3	IBD	inflammatory bowel disease	13
GU	genitourinary	14, 15	IBS	irritable bowel syndrome	13
GYN	gynecology	16	IC	inspiratory capacity	12
H&P	history and physical examination	3	ICD	implantable cardioverter defibrillator	10
HAV	hepatitis A virus	13	ICP	intracranial pressure	7
Hb, Hgb	hemoglobin	11	ICU	intensive care unit	3
HbA1c	hemoglobin A1c; glycated hemoglobin	9	ID	intra-dermal	3
HBV	hepatitis B virus	13, 15	IF	intrinsic factor	11
hCG	human chorionic gonadotropin	16	IFG	impaired fasting blood glucose	9
HCl	hydrochloric acid	13	Ig	immunoglobulin	11
Hct, Ht	hematocrit	11	IGRA	interferon gamma release assay (test for TB)	12
HCV	hepatitis C virus	13	IGT	impaired glucose tolerance	9
HDL	high-density lipoprotein	10	IM	intramuscular(ly); intramedullary	3, 5
HDN	hemolytic disease of the newborn	11, 16	INH	isoniazid (antituberculosis drug)	3, 12
HDV	hepatitis D virus	13	IOL	intraocular lens	8
HEV	hepatitis E virus	13	IOP	intraocular pressure	8
HEENT	head, eyes, ears, nose, and throat	3	IPPA	inspection, palpation, percussion, auscultation	3, 12
HIPAA	Health Insurance Portability and Accountability Act	3	IPPB	intermittent positive pressure breathing	12
HIV	human immunodeficiency virus	11, 15			

## Abbreviations and Their Meanings (Continued)

Abbreviation	Meaning	Chapter	Abbreviation	Meaning	Chapter
IPPV	intermittent positive pressure ventilation	12	LVH	left ventricular hypertrophy	10
IRV	inspiratory reserve volume	12	lytes	electrolytes	11
ITP	idiopathic thrombocytopenic purpura	11	m	meter	Appendix 8
IU	international unit	3	MAOI	monoamine oxidase inhibitor	7
IUD	intrauterine device	16	mcg	microgram	3, Appendix 8
IV	intravenous(ly)	3	MCH	mean corpuscular hemoglobin	11
IVCD	intraventricular conduction delay	10	MCHC	mean corpuscular hemoglobin concentration	11
IVDA	intravenous drug abuse	3	mcL	microliter	11, Appendix 8
IVF	in vitro fertilization	16	mcm	micrometer (µm)	11, Appendix 8
IVP	intravenous pyelography	14	MCP	metacarpophalangeal	5
IVU	intravenous urography	14	MCV	mean corpuscular volume	11
JVP	jugular venous pulse	10	MDR	multidrug resistant	3
K	potassium	14	MDS	myelodysplastic syndrome	11
kg	kilogram	Appendix 8	MED(s)	medicine(s), medication(s)	3
km	kilometer	Appendix 8	MEFR	maximal expiratory flow rate	12
KUB	kidney–ureter–bladder	14	MEN	multiple endocrine neoplasia	9
KVO	keep vein open	3	mEq	milliequivalent	11
L	lumbar vertebra (numbered L1 to L5); liter	5, Appendix 8	MET	metastasis	3
LA	long-acting	3	mg	milligram	3, Appendix 8
LAD	left anterior descending (coronary artery)	10	MG	myasthenia gravis	6
LAHB	left anterior hemiblock	10	MHT	menopausal hormone therapy	16
LDL	low-density lipoprotein	10	MI	myocardial infarction	10
LE	lupus erythematosus	4	MID	multi-infarct dementia	7
LES	lower esophageal sphincter	13	mL	milliliter	3, Appendix 8
LH	luteinizing hormone	9, 15, 16	mm	millimeter	Appendix 8
LL	left lateral	3	MMFR	maximum midexpiratory flow rate	12
LLE	left lower extremity	6	mm Hg	millimeters of mercury	10
LLL	left lower lobe (of lung)	12	MMT	manual muscle test(ing)	6
LLQ	left lower quadrant	2	MR	mitral regurgitation, reflux	10
LMN	lower motor neuron	7	MRI	magnetic resonance imaging	3
LMP	last menstrual period	16	MRSA	methicillin-resistant <i>Staphylococcus aureus</i>	3
LOC	level of consciousness	7	MS	multiple sclerosis; mitral stenosis	7, 10
LP	lumbar puncture	7	MTP	metatarsophalangeal	5
LUE	left upper extremity	6	MTBI	mild traumatic brain injury	7
LUL	left upper lobe (of lung)	12	MUGA	multigated acquisition (scan)	10
LUQ	left upper quadrant	2	MVP	mitral valve prolapse	10
LV	left ventricle	10	MVR	mitral valve replacement	10
LVAD	left ventricular assist device	10			
LVEDP	left ventricular end-diastolic pressure	10			

(continued)

Abbreviations and Their Meanings (*Continued*)

Abbreviation	Meaning	Chapter	Abbreviation	Meaning	Chapter
Na	sodium	14	p	after, post	3
NAA	nucleic acid amplification (test) (for TB)	12	P	pulse	3, 10
NAD	no apparent distress	3	PA	posteroanterior; physician assistant	3
NB	newborn	16	PAC	premature atrial contraction	10
NCCAM	National Center for Complementary and Alternative Medicine	3	PaCO <sub>2</sub>	arterial partial pressure of carbon dioxide	12
NG	nasogastric	13	PACU	postanesthesia care unit	3
NGU	nongonococcal urethritis	15, 16	PaO <sub>2</sub>	arterial partial pressure of oxygen	12
NHL	non-Hodgkin lymphoma	11	PAP	pulmonary arterial pressure	10
NICU	neonatal intensive care unit; neurologic intensive care unit	7, 16	pc	after meals (Latin, <i>post cibum</i> )	3
NKDA	no known drug allergies	3	PCA	patient-controlled analgesia	3
NMJ	neuromuscular junction	6	PCI	percutaneous coronary intervention	10
NPH	normal pressure hydrocephalus; neutral protamine Hagedorn (insulin)	7, 9	PCL	posterior cruciate ligament	5
NPO	nothing by mouth (Latin, <i>non per os</i> )	3	PCOS	polycystic ovarian syndrome	16
NRC	normal retinal correspondence	8	PCP	<i>Pneumocystis</i> pneumonia	12
NREM	nonrapid eye movement (sleep)	7	PCV	packed cell volume	11
NS, N/S	normal saline	3	PCWP	pulmonary capillary wedge pressure	10
NSAID(s)	nonsteroidal anti-inflammatory drug(s)	3, 5	PDA	patent ductus arteriosus	16
NSR	normal sinus rhythm	10	PDD	pervasive developmental disorder	7
NV	near vision	8	PDR	<i>Physicians' Desk Reference</i>	3
N&V	nausea and vomiting	13	PE	physical examination	3
N/V/D	nausea, vomiting, diarrhea	13	PEEP	positive end-expiratory pressure	12
O <sub>2</sub>	oxygen	12	PEFR	peak expiratory flow rate	12
OA	osteoarthritis	5	PEG	percutaneous endoscopic gastrostomy (tube)	13
OB	obstetrics, obstetrician	16	PEP	protein electrophoresis	14
OCD	obsessive–compulsive disorder	7	PE(R)RLA	pupils equal, (regular) react to light and accommodation	3
ODS	Office of Dietary Supplements	3	PET	positron emission tomography	3, 7
OGTT	oral glucose-tolerance test	9	PFT	pulmonary function test(s)	12
OI	osteogenesis imperfecta	5	pH	scale for measuring hydrogen ion concentration (acidity or alkalinity)	11
OL	otolaryngology	8	Ph	Philadelphia chromosome	11
OOB	out of bed	3	PICC	peripherally inserted central catheter	3
OM	otitis media	8	PID	pelvic inflammatory disease	16
OR	operating room	3	PIH	pregnancy-induced hypertension	16
ORIF	open reduction internal fixation	5	PIP	proximal interphalangeal (joint); peak inspiratory pressure	5, 12
ORL	otorhinolaryngology	8			
ortho, ORTH	orthopedics	5			
OT	occupational therapy/therapist	6			
OTC	over-the-counter	3			

## Abbreviations and Their Meanings (Continued)

Abbreviation	Meaning	Chapter	Abbreviation	Meaning	Chapter
PKU	phenylketonuria	16	QS	quantity sufficient	3
PMH	past medical history	3	R	respiration	3, 12
PMI	point of maximal impulse	10	RA	rheumatoid arthritis	5
PMN	polymorphonuclear (neutrophil)	11	RAIU	radioactive iodine uptake	9
PMS	premenstrual syndrome	16	RAS	reticular activating system	7
PND	paroxysmal nocturnal dyspnea	12	RATx	radiation therapy	3
PNS	peripheral nervous system	7	RBC	red blood cell; red blood (cell) count	11
po, PO	by mouth (Latin, <i>per os</i> )	3	RDS	respiratory distress syndrome	12
poly, polymorph	neutrophil	11	REM	rapid eye movement (sleep)	7
PONV	postoperative nausea and vomiting	13	RIA	radioimmunoassay	9
postop, post-op	postoperative	3	RICE	rest, ice, compression, elevation	6
pp	postprandial (after a meal)	3	RL	right lateral	3
PPD	purified protein derivative (tuberculin)	12	RLE	right lower extremity	6
PPI	proton pump inhibitor	13	RLL	right lower lobe (of lung)	12
preop, pre-op	preoperative	3	RLQ	right lower quadrant	2
PRL	prolactin	9	RLS	restless legs syndrome	6
prn	as needed	3	RML	right middle lobe (of lung)	12
PSA	prostate-specific antigen	15	R/O	rule out	3
PSF	posterior spinal fusion	5	ROM	range of motion	6
PSS	physiologic saline solution; progressive systemic sclerosis	3, 4	ROS	review of systems	3
PSVT	paroxysmal supraventricular tachycardia	10	RSI	repetitive strain injury	6
pt	patient	3	RSV	respiratory syncytial virus	12
PT	physical therapy/therapist	5	RTC	rotator cuff	6
PT, ProTime	prothrombin time; pro time	11	RUE	right upper extremity	6
PTCA	percutaneous transluminal coronary angioplasty	10	RUL	right upper lobe (of lung)	12
PTH	parathyroid hormone	9	RUQ	right upper quadrant	2
PTSD	posttraumatic stress disorder	7	RV	residual volume	12
PTT	partial thromboplastin time	11	Rx	drug, prescription, therapy	3
PUVA	psoralen ultraviolet A	4	̄	without	3
PVC	premature ventricular contraction	10	S	sacrum; sacral	5
PVD	peripheral vascular disease	10	S <sub>1</sub>	first heart sound	10
PYP	pyrophosphate (scan)	10	S <sub>2</sub>	second heart sound	10
qam	every morning (Latin, <i>quaque ante meridiem</i> )	3	SA	sustained action; sinoatrial	3, 10
qh	every hour (Latin, <i>quaque hora</i> )	3	SARS	severe acute respiratory syndrome	12
q __ h	every __ hours	3	SBE	subacute bacterial endocarditis	10
qid, q.i.d.	four times a day (Latin, <i>quater in die</i> )	3	sc	without correction	8
QNS	quantity not sufficient	3	SC, SQ, subcut.	subcutaneous(ly)	3
			SCLE	subacute cutaneous lupus erythematosus	4
			seg	neutrophil	11
			SERM	selective estrogen receptor modulator	5, 16

(continued)

## Abbreviations and Their Meanings (Continued)

Abbreviation	Meaning	Chapter	Abbreviation	Meaning	Chapter
SG	specific gravity	14	TBI	traumatic brain injury; thrombolytic brain infarction	7
SIADH	syndrome of inappropriate antidiuretic hormone (secretion)	9	<sup>99m</sup> Tc	technetium-99m	10
SIDS	sudden infant death syndrome	12	TCA	tricyclic antidepressant	7
SITS	supraspinatus, infraspinatus, teres minor, subscapularis (muscles)	6	TEE	transesophageal echocardiography	10
SK	streptokinase	10	TGV	thoracic gas volume	12
SL	sublingual	3	THA	total hip arthroplasty	5
SLE	systemic lupus erythematosus	4, 11	THP	total hip precautions	5
SPECT	single-photon emission computed tomography	3	THR	total hip replacement	5
SPF	sun protection factor	4	TIA	transient ischemic attack	7
SpO <sub>2</sub>	oxygen percent saturation	12	tid, t.i.d.	three times per day (Latin, <i>ter in die</i> )	3
SR	sustained release	3	tinct	tincture	3
$\overline{ss}$	half (Latin, <i>semis</i> )	3	TKA	total knee arthroplasty	5
SSEP	somatosensory evoked potentials	7	TKO	to keep open	3
SSRI	selective serotonin reuptake inhibitor	7	TLC	total lung capacity	12
ST	speech threshold	8	T <sub>m</sub>	maximal transport capacity; tubular maximum	14
staph	staphylococcus	3	TM	tympanic membrane	8
STAT	immediately	3	T <sub>n</sub>	troponin	10
STD	sexually transmitted disease	15, 16	TNM	(primary) tumor, (regional lymph) nodes, (distant) metastases	3
STI	sexually transmitted infection	15, 16	TMJ	temporomandibular joint	5
strep	streptococcus	3	tPA	tissue plasminogen activator	10
STSG	split-thickness skin graft	4	TPN	total parenteral nutrition	13
supp	suppository	3	TPR	temperature, pulse, respiration	3
susp	suspension	3	TPUR	transperineal urethral resection	15
SVD	spontaneous vaginal delivery	16	TSE	testicular self-examination	15
SVT	supraventricular tachycardia	10	TSH	thyroid-stimulating hormone	9
T	temperature; thoracic vertebra (numbered T1 to T12)	3, 5	TSS	toxic shock syndrome	16
T1DM	type 1 diabetes mellitus	9	T(C)T	thrombin (clotting) time	11
T2DM	type 2 diabetes mellitus	9	TTP	thrombotic thrombocytopenic purpura	11
T <sub>3</sub>	triiodothyronine	9	TTS	temporary threshold shift	8
T <sub>4</sub>	thyroxine; tetraiodothyronine	9	TUIP	transurethral incision of prostate	15
T <sub>7</sub>	free thyroxine index	9	TURP	transurethral resection of prostate	15
T&A	tonsils and adenoids; tonsillectomy and adenoidectomy	12	TV	tidal volume	12
tab	tablet	3	Tx	traction	5
TAH	total abdominal hysterectomy	16	U	units	3
TB	tuberculosis	12	UA	urinalysis	14
TBG	thyroxine-binding globulin	9	UC	uterine contractions	16
			UFE	uterine fibroid embolization	16

## Abbreviations and Their Meanings (Continued)

Abbreviation	Meaning	Chapter	Abbreviation	Meaning	Chapter
UG	urogenital	15	VF, v fib	ventricular fibrillation	10
UGI	upper gastrointestinal	13	VLDL	very low density lipoprotein	10
UMN	upper motor neuron	7	VPC	ventricular premature complex	10
ung	ointment	3	VRSA	vancomycin-resistant <i>Staphylococcus aureus</i>	3
URI	upper respiratory infection	12	VS	vital signs	3
USP	<i>United States Pharmacopeia</i>	3	VSD	ventricular septal defect	10
UTI	urinary tract infection	14, 15	VT	ventricular tachycardia	10
UTP	uterine term pregnancy	16	VTE	venous thromboembolism	10
UV	ultraviolet	3, 4	V <sub>TG</sub>	thoracic gas volume	12
UVA	ultraviolet A	4	vWF	von Willebrand factor	11
UVB	ultraviolet B	4	WBC	white blood cell; white blood (cell) count	11
VA	visual acuity	8	WD	well developed	3
VAC	vacuum-assisted closure	4	WNL	within normal limits	3
VAD	ventricular assist device	10	w/o	without	3
VBAC	vaginal birth after cesarean section	16	WPW	Wolff–Parkinson–White syndrome	10
VC	vital capacity	12	x	times	3
VD	venereal disease	15, 16	XT	exotropia	8
VDRL	Venereal Disease Research Laboratory	15	y/o, YO	years old, year-old	3
VEP	visual evoked potentials	7	ZIFT	zygote intrafallopian transfer	16
VF	visual field	8			

# Appendix 3

## Word Parts and Their Meanings

Word Parts and Their Meanings					
Word Part	Meaning	Reference Page	Word Part	Meaning	Reference Page
a-	not, without, lack of, absence	21	-ase	enzyme	50
ab-	away from	22	atel/o	imperfect	408
abdomin/o	abdomen	52	atlant/o	atlas	156
-ac	pertaining to	13	atri/o	atrium	324
acous, acus	sound, hearing	264	audi/o	hearing	264
acro-	extremity, end	58	auto-	self	239
ad-	toward, near	22	azot/o	nitrogenous compounds	369
aden/o	gland	47	bacill/i, bacill/o	bacillus	86
adip/o	fat	50	bacteri/o	bacterium	86
adren/o	adrenal gland, epinephrine	299	balan/o	glans penis	500
adrenal/o	adrenal gland	299	bar/o	pressure	98
adrenocortic/o	adrenal cortex	299	bi-	two, twice	18
aer/o	air, gas	98	bili	bile	435
-agogue	promoter, stimulator	534	bio	life	45
-al	pertaining to	13	blast/o, -blast	immature cell, productive cell, embryonic cell	49
alg/o, algi/o, algesi/o	pain	82, 112	blephar/o	eyelid	273
-algnesia	pain	84, 261	brachi/o	arm	58
-algia	pain	84	brachy-	short	501
ambly-	dim	280	brady-	slow	83
amnio	amnion	534	bronch/o, bronch/i	bronchus	399
amyl/o	starch	50	bronchiol	bronchiole	399
an-	not, without, lack of, absence	21	bucc/o	cheek	432
andr/o	male	493	burs/o	bursa	158
angi/o	vessel	326	calc/i	calcium	369
an/o	anus	430	cali/o, calic/o	calyx	466
ante-	before	25	-capnia	carbon dioxide (level of)	398
anti-	against	21, 112	carcin/o	cancer, carcinoma	82
aort/o	aorta	327	cardi/o	heart	326
-ar	pertaining to	13	cec/o	cecum	434
arter/o, arteri/o	artery	327	-cele	hernia, localized dilation	84
arteriol/o	arteriole	327	celi/o	abdomen	57
arthr/o	joint	158	centesis	puncture, tap	100
-ary	pertaining to	13	cephal/o	head	57
			cerebell/o	cerebellum	228

## Word Parts and Their Meanings (Continued)

Word Part	Meaning	Reference Page	Word Part	Meaning	Reference Page
cerebr/o	cerebrum	228	dent/o, dent/i	tooth, teeth	432
cervic/o	neck, cervix	57, 520	derm/o, dermat/o	skin	129
chem/o	chemical	112	-desis	binding, fusion	100
cheil/o	lip	446	dextr/o-	right	26
chir/o	hand	97	di-	two, twice	18
cholangi/o	bile duct	435	dia-	through	22
chol/e, chol/o	bile, gall	435	dilation, dilatation	expansion, widening	85
cholecyst/o	gallbladder	435	dipl/o-	double	18
choledoch/o	common bile duct	435	dis-	absence, removal, separation	21
chondr/o	cartilage	158	duoden/o	duodenum	433
chori/o, choroid/o	choroid	274	dynam/o	force, energy	203
chrom/o, chromat/o	color, stain	98	dys-	abnormal, painful, difficult	83
chron/o	time	98	ec-	out, outside	26
circum-	around	59	ectasia, ectasis	dilation, dilatation, distention	85
clasis, -clasia	breaking	84	ecto-	out, outside	26
clitor/o, clitorid/o	clitoris	521	-ectomy	excision, surgical removal	100
coccy, coccyg/o	coccyx	159	edema	accumulation of fluid, swelling	85
cochle/o	cochlea (of inner ear)	265	electr/o	electricity	98
col/o, colon/o	colon	434	embryo/o	embryo	534
colp/o	vagina	520	emesis	vomiting	443
contra-	against, opposite, opposed	21, 112	-emia	condition of blood	367
copro	feces	230	encephal/o	brain	228
cor/o, cor/e	pupil	280	end/o-	in, within	26
corne/o	cornea	274	endocrin/o	endocrine	299
cortic/o	outer portion, cerebral cortex	228	enter/o	intestine	433
cost/o	rib	159	epi-	on, over	59
counter-	against, opposite, opposed	112	epididym/o	epididymis	494
crani/o	skull, cranium	159	episi/o	vulva	521
cry/o	cold	98	equi-	equal, same	24
crypt/o	hidden	498	erg/o	work	98, 197
cus	sound, hearing	264	erythr/o-	red, red blood cell	20
cyan/o-	blue	20	erythrocyt/o	red blood cell	368
cycl/o	ciliary body, ciliary muscle (of eye)	274	esophag/o	esophagus	433
cyst/o	filled sac or pouch, cyst, bladder, urinary bladder	82	-esthesia, -esthesi/o	sensation	261, 271
-cyte, cyt/o	cell	47	eu-	true, good, easy, normal	24
dacry/o	tear, lacrimal apparatus	273	ex/o-	away from, outside	26
dacryocyst/o	lacrimal sac	273	extra-	outside	59
dactyl/o	finger, toe	58	fasci/o	fascia	197
de-	down, without, removal, loss	21	fer	to carry	225
			ferr/i, ferr/o	iron	369

(continued)



## Word Parts and Their Meanings (Continued)

Word Part	Meaning	Reference Page	Word Part	Meaning	Reference Page
fet/o	fetus	534	-iiatrics	medical specialty	11
fibr/o	fiber	47	-iatr/o	physician	9
-form	like, resembling	13	-iatry	medical specialty	11
galact/o	milk	534	-ic	pertaining to	13
gangli/o, ganglion/o	ganglion	227	-ical	pertaining to	13
gastr/o	stomach	433	-ics	medical specialty	11
gen, genesis	origin, formation	49	-ile	pertaining to	13
ger/e, ger/o	old age	12	ile/o	ileum	434
-geusia	sense of taste	261	ili/o	ilium	159
gingiv/o	gum, gingiva	432	im-	not	21
gli/o	neuroglia	227	immun/o	immunity, immune system	368
glomerul/o	glomerulus	466	in-	not	21
gloss/o	tongue	432	infra-	below	59
gluc/o	glucose	50	in/o	fiber, muscle fiber	197
glyc/o	sugar, glucose	50	insul/o	pancreatic islets	299
gnath/o	jaw	50	inter-	between	59
goni/o	angle	172, 281	intra-	in, within	59
-gram	record of data	99	ir, irit/o, irid/o	iris	274
-graph	instrument for recording data	99	-ism	condition of	10
-graphy	act of recording data	99	iso-	equal, same	24
gravida	pregnant woman	534	-ist	specialist	11
gyn/o, gynec/o	woman	518	-itis	inflammation	84
hem/o, hemat/o	blood	368	jejun/o	jejunum	433
hemi-	half, one side	18	juxta-	near, beside	59
-hemia	condition of blood	367	kali	potassium	369
hepat/o	liver	435	kary/o	nucleus	47
hetero-	other, different, unequal	24	kerat/o	cornea, keratin, horny layer of skin	129, 274
hidr/o	sweat, perspiration	129	kin/o, kine, kinesi/o, kinet/o	movement	197
hist/o, histi/o	tissue	47	labi/o	lip	432
homo-, homeo-	same, unchanging	24	labyrinth/o	labyrinth (inner ear)	465
hydr/o	water, fluid	50	lacrim/o	tear, lacrimal apparatus	273
hyper-	over, excess, increased, abnormally high	23	lact/o	milk	534
hypn/o	sleep	112	-lalia	speech, babble	230
hypo-	under, below, decreased, abnormally low	23	lapar/o	abdominal wall	57
hypophysi/o	pituitary, hypophysis	299	laryng/o	larynx	399
hyster/o	uterus	520	lent/i	lens	274
-ia	condition of	10	-lepsy	seizure	230
-ian	specialist	11	leuk/o-	white, colorless, white blood cell	20
-ia/sis	condition of	10	leukocyt/o	white blood cell	368
			-lexia	reading	230

## Word Parts and Their Meanings (Continued)

Word Part	Meaning	Reference Page	Word Part	Meaning	Reference Page
lingu/o	tongue	432	myel/o	bone marrow, spinal cord	158, 227, 368
lip/o	fat, lipid	50	my/o	muscle	197
-listhesis	slipping	169	myring/o	tympanic membrane	264
lith	calculus, stone	82	myx/o	mucus	47
-logy	study of	11	narc/o	stupor, unconsciousness	112, 228
lumb/o	lumbar region, lower back	57	nas/o	nose	399
lymphaden/o	lymph node	340	nat/i	birth	534
lymphangi/o	lymphatic vessel	340	natri	sodium	369
lymph/o	lymph, lymphatic system, lymphocyte	340	necrosis	death of tissue	85
lymphocyt/o	lymphocyte	368	neo-	new	24
-lysis	separation, loosening, dissolving, destruction	85	nephr/o	kidney	466
-lytic	dissolving, reducing, loosening	112	neur/o, neur/i	nervous system, nerve	227
macro-	large, abnormally large	24	noct/i	night	102
mal-	bad, poor	83	non-	not	21
malacia	softening	85	normo-	normal	24
mamm/o	breast, mammary gland	521	nucle/o	nucleus	47
-mania	excited state, obsession	230	nulli-	never	534
mast/o	breast, mammary gland	521	nyct/o	night, darkness	280
medull/o	inner part, medulla oblongata, spinal cord	228	ocul/o	eye	274
mega-, megal/o-	large, abnormally large	24	odont/o	tooth, teeth	432
-megaly	enlargement	84	-odynia	pain	84
melan/o-	black, dark, melanin	20	-oid	like, resembling	13
mening/o, meninge/o	meninges	227	olig/o-	few, scanty, deficiency of	23
men/o, mens	month, menstruation	518	-oma	tumor	84
mes/o-	middle	26	onc/o	tumor	82
met/a	change, after, beyond	81	onych/o	nail	129
-meter	instrument for measuring	99	oo	ovum	518
metr/o	measure	99, 276	oophor/o	ovary	518
metr/o, metr/i	uterus	520	ophthalm/o	eye	274
-metry	measurement of	99	-opia	condition of the eye, vision	276
micro-	small, one millionth	24	-opsia	condition of vision	276
-mimetic	mimicking, simulating	112	opt/o	eye, vision	274
mon/o-	one	18	orchid/o, orchi/o	testis	494
morph/o	form, structure	47	or/o	mouth	432
muc/o	mucus, mucous membrane	47	ortho-	straight, correct, upright	24
multi-	many	18	-ory	pertaining to	13
muscul/o	muscle	197	osche/o	scrotum	494
myc/o	fungus, mold	86	-ose	sugar	50
			-o/sis	condition of	10
			osm/o	smell	261
			-osmia	sense of smell	261

(continued)

Word Parts and Their Meanings (*Continued*)

Word Part	Meaning	Reference Page	Word Part	Meaning	Reference Page
oste/o	bone	158	plas, -plasia	formation, molding, development	49
ot/o	ear	264	-plasty	plastic repair, plastic surgery, reconstruction	100
-ous	pertaining to	13	-plegia	paralysis	230
ovari/o	ovary	519	pleur/o	pleura	400
ov/o, ovul/o	ovum	519	-pnea	breathing	398
-oxia	oxygen (level of)	398	pneum/o, pneumat/o	air, gas, lung, respiration	400
ox/y	oxygen, sharp, acute	369	pneumon/o	lung	400
pachy-	thick	83	pod/o	foot	58
palat/o	palate	432	-poiesis	formation, production	367
palpebr/o	eyelid	273	poikilo-	varied, irregular	24
pan-	all	23	poly-	many, much	18
pancreat/o	pancreas	435	post-	after, behind	25
papill/o	nipple	47	pre-	before, in front of	25
para-	near, beside, abnormal	59	presby-	old	271
para	woman who has given birth	534	prim/i-	first	18
parathyr/o, parathyroid/o	parathyroid	299	pro-	before, in front of	25
-paresis	partial paralysis, weakness	230	proct/o	rectum	434
path/o, -pathy	disease, any disease of	82, 84	prostat/o	prostate	494
ped/o	foot, child	58	prote/o	protein	50
pelvi/o	pelvis	159	pseudo-	false	24
-penia	decrease in, deficiency of	367	psych/o	mind	228
per-	through	22	ptosis	dropping, downward displacement, prolapse	85
peri-	around	59	ptysis	spitting	408
perine/o	perineum	521	puer	child	542
periton, peritone/o	peritoneum	57	pulm/o, pulmon/o	lung	400
-pexy	surgical fixation	100	pupill/o	pupil	274
phac/o, phak/o	lens	274	pyel/o	renal pelvis	466
phag/o	eat, ingest	49	pylor/o	pylorus	433
pharm, pharmac/o	drug, medicine	112	py/o	pus	82
pharyng/o	pharynx	399	pyr/o, pyret/o	fever, fire	82
-phasia	speech	230	quadr/i-	four	18
phil, -philic	attracting, absorbing	49	rachi/o	spine	159
phleb/o	vein	327	radicul/o	root of spinal nerve	227
-phobia	fear	230	radi/o	radiation, x-ray	98
phon/o	sound, voice	98	re-	again, back	24
-phonia	voice	398	rect/o	rectum	434
phot/o	light	98	ren/o	kidney	466
phren/o	diaphragm	400	reticul/o	network	47
phrenic/o	phrenic nerve	400	retin/o	retina	274
phyt/o	plant	107, 137			
pituitar/i	pituitary, hypophysis	299			

Word Parts and Their Meanings (*Continued*)

Word Part	Meaning	Reference Page	Word Part	Meaning	Reference Page
retro-	behind, backward	59	staphyl/o	grape-like cluster, <i>Staphylococcus</i>	86
rhabd/o	rod, muscle cell	203	stasis	suppression, stoppage	85
-rhage, -rhagia	bursting forth, profuse flow, hemorrhage	84	steat/o	fatty	50
-rhaphy	surgical repair, suture	100	stenosis	narrowing, constriction	85
-rhea	flow, discharge	84	steth/o	chest	97
-rhexis	rupture	84	sthen/o	strength	202
rhin/o	nose	399	stoma, stomat/o	mouth	432
sacchar/o	sugar	50	-stomy	surgical creation of an opening	100
sacr/o	sacrum	159	strept/o-	twisted chain, <i>Streptococcus</i>	86
salping/o	tube, uterine tube, auditory (eustachian) tube	264, 520	sub-	below, under	59
-schisis	fissure, splitting	84	super-	above, excess	23
scler/o	hard, sclera (of eye)	82, 274	supra-	above	59
sclerosis	hardening	85	syn-, sym-	together	26
-scope	instrument for viewing or examining	99	synov/i	synovial joint, synovial membrane	158
-scopy	examination of	99	tachy-	rapid	83
seb/o	sebum, sebaceous gland	129	tax/o	order, arrangement	202
semi-	half, partial	18	tel/e-, tel/o-	end, far, at a distance	26
semin	semen	494	ten/o, tendin/o	tendon	197
sept/o	septum, dividing wall, partition	410	terat/o	malformed fetus	540
sial/o	saliva, salivary gland, salivary duct	432	test/o	testis, testicle	494
sider/o	iron	369	tetra-	four	18
sigmoid/o	sigmoid colon	434	thalam/o	thalamus	428
sinistr/o	left	26	therm/o	heat, temperature	98
-sis	condition of	10	thorac/o	chest, thorax	58
skelet/o	skeleton	157	thromb/o	blood clot	368
somat/o	body	47	thrombocyt/o	platelet, thrombocyte	368
-some	body, small body	47	thym/o	thymus gland	340
somn/i, somn/o	sleep	228	thyr/o, thyroid/o	thyroid	299
son/o	sound, ultrasound	98	toc/o	labor	534
spasm	sudden contraction, cramp	85	-tome	instrument for incising (cutting)	100
sperm/i	semen, spermatozoa	494	-tomy	incision, cutting	100
spermat/o	semen, spermatozoa	494	ton/o	tone	197
-spermia	condition of semen	495	tonsil/o	tonsil	340
sphygm/o	pulse	325	tox/o, toxic/o	poison, toxin	82, 112
spir/o	breathing	400	toxin	poison	85
splen/o	spleen	340	trache/o	trachea	399
spondyl/o	vertebra	159	trans-	through	22
staped/o, stapedi/o	stapes	264	tri-	three	18

(continued)

Word Parts and Their Meanings (*Continued*)

Word Part	Meaning	Reference Page	Word Part	Meaning	Reference Page
trich/o	hair	129	vagin/o	sheath, vagina	520
-tripsy	crushing	100	valv/o, valvul/o	valve	326
trop/o	turning	281	varic/o	twisted and swollen vein, varix	336
trop, -tropic	act(ing) on, affect(ing)	49, 112	vascul/o	vessel	327
troph/o, -trophy, -trophia	feeding, growth, nourishment	49	vas/o	vessel, duct, vas deferens	85, 112, 327, 494
tympan/o	tympanic cavity (middle ear), tympanic membrane	264	ven/o, ven/i	vein	327
un-	not	21	ventricul/o	cavity, ventricle	228, 326
uni-	one	18	vertebr/o	vertebra, spinal column	159
-uresis	urination	468	vesic/o	urinary bladder	467
ureter/o	ureter	467	vesicul/o	seminal vesicle	494
urethr/o	urethra	467	vestibul/o	vestibule, vestibular apparatus (of ear)	467
-uria	condition of urine, urination	468	vir/o	virus	86
ur/o	urine, urinary tract	467	vulv/o	vulva	521
urin/o	urine	467	xanth/o-	yellow	20
uter/o	uterus	520	xen/o	foreign, strange	235
uve/o	uvea (of eye)	274	xer/o-	dry	83
uvul/o	uvula	432	-y	condition of	10

# Appendix 4

## Meanings and Their Corresponding Word Parts

### Meanings and Their Corresponding Word Parts

Meaning	Word Part(s)	Reference Page	Meaning	Word Part(s)	Reference Page
abdomen	abdomin/o, celi/o	57	artery	arter/o, arteri/o	327
abdominal wall	lapar/o	57	at a distance	tel/e, tel/o	26
abnormal	dys-, para-	59, 83	atlas	atlant/o	156
abnormally high	hyper-	23	atrium	atri/o	326
abnormally large	macro-, mega-, megal/o-	24	attract(ing)	phil-, -philic	49
abnormally low	hypo-	23	auditory (eustachian) tube	salping/o	264, 520
above	super-, supra-	23, 59	away from	ab-, ex/o-	22, 26
absence	a-, an-, dis-	21	babble	-lalia	230
absorb(ing)	phil-, -philic	49	bacillus	bacill/i, bacill/o	86
accumulation of fluid	edema	85	back	re-	24
act of recording data	-graphy	99	backward	retro-	59
act(ing) on	trop, -tropic	112	bacterium	bacteri/o	86
acute	ox/y	369	bad	mal-	83
adrenal gland	adren/o, adrenal/o	299	before	ante-, pre-, pro-	25
adrenaline	adren/o	299	behind	post-, retro-	25, 49
adrenal	adren/o	299	below	hypo-, infra-, sub-	23, 59
adrenal cortex	adrenocortic/o	299	beside	para-, juxta-	59
affect(ing)	trop, -tropic	49	between	inter-	59
after	post-, met/a	26, 81	beyond	met/a	81
again	re-	24	bile	bili, chol/e, chol/o	435
against	anti-, contra-, counter-	112	bile duct	cholangi/o	435
air	aer/o, pneumat/o	98, 400	binding	-desis	100
all	pan-	23	birth	nat/i	534
amnion, amniotic sac	amnio	534	black	melan/o-	20
angle	goni/o	172	bladder	cyst/o	82
anus	an/o	434	bladder (urinary)	cyst/o, vesic/o	82, 467
any disease of	-pathy	84	blood	hem/o, hemat/o	368
aorta	aort/o	327	blood (condition of)	-emia, -hemia	367
arm	brachi/o	58	blood clot	thromb/o	368
around	circum-, peri-	59	blue	cyan/o-	20
arrangement	tax/o	202	body	somat/o, -some	47
arteriole	arteriol/o	327	bone	oste/o	158

(continued)

### Meanings and Their Corresponding Word Parts (Continued)

Meaning	Word Part(s)	Reference Page	Meaning	Word Part(s)	Reference Page
bone marrow	myel/o	158, 227, 368	condition of	-ia, -ia/sis, -ism, -o/sis, -sis, -y	10
brain	encephal/o	228	condition of blood	-emia, -hemia	367
breaking	-clasis, -clasia	84	condition of the eye	-opia	276
breast	mamm/o, mast/o	521	condition of urine, urination	-uria	468
breathing	-pnea, spir/o	398, 400	condition of vision	-opia, -opsia	476
bronchiole	bronchiol	399	condition of semen	-spermia	495
bronchus	bronch/i, bronch/o	399	constriction	stenosis	85
bursa	burs/o	158	contraction (sudden)	spasm	85
bursting forth	-rhage, -rhagia	84	cornea	corne/o, kerat/o	274
calcium	calc/i	369	correct	ortho-	24
calculus	lith	82	cramp	spasm	85
calyx	cali/o, calic/o	466	cranium	crani/o	159
cancer	carcin/o	82	crushing	-tripsy	100
carbon dioxide	-capnia	398	cutting	-tomy	100
carcinoma	carcin/o	82	cutting instrument	-tome	100
carry	fer	225	cyst	cyst/o	82
cartilage	chondr/o	158	dark	melan/o-	20
cavity	ventricul/o	228, 326	darkness	nyct/o	102
cecum	cec/o	434	data	-gram	99
cell	-cyte, cyt/o	47	death of tissue	necrosis	85
cerebellum	cerebell/o	228	decreased, decrease in	hypo-, -penia	23, 367
cerebral cortex	cortic/o	228	deficiency of	oligo-, -penia	23, 367
cerebrum	cerebr/o	228	destruction	lysis	85
cervix	cervic/o	520	development	plas, -plasia	49
chain (twisted)	strept/o	86	diaphragm	phren/o	400
change	met/a	81	different	hetero-	24
cheek	bucc/o	432	difficult	dys-	83
chemical	chem/o	112	dilatation, dilation	ectasia, ectasis	85
chest	thorac/o, steth/o	57, 271	dim	ambly-	280
child	ped/o, puer	542	discharge	-rhea	84
choroid	chori/o, choroid/o	274	disease	path/o, -pathy	82
ciliary body	cycl/o	274	dissolving	lysis, -lytic	85, 112
ciliary muscle	cycl/o	274	distance (at a)	tel/e, tel/o	26
clitoris	clitor/o, clitorid/o	521	distention	ectasia, ectasis	85
clot	thromb/o	368	double	dipl/o-	18
coccyx	coccy, coccyg/o	159	down	de-	21
cochlea	cochle/o	265	dropping, downward displacement	ptosis	85
cold	cry/o	98			
colon	col/o, colon/o	434			
color	chrom/o, chromat/o	98			
colorless	leuk/o-	20			
common bile duct	choledoch/o	435			

## Meanings and Their Corresponding Word Parts (Continued)

Meaning	Word Part(s)	Reference Page	Meaning	Word Part(s)	Reference Page
drug	pharm, pharmac/o	112	fetus	fet/o	534
dry	xer/o-	83	fetus (malformed)	terat/o	540
duct	vas/o	112	fever	pyr/o, pyret/o	82, 112
ductus deferens	vas/o	494	few	oligo-	23
duodenum	duoden/o	433	fiber	fibr/o, in/o	47, 197
ear	ot/o	264	filled sac or pouch	cyst/o	82
easy	eu-	24	finger	dactyl/o	58
eat	phag/o	49	fire	pyr/o, pyret/o	82
egg cell	oo, ov/o, ovul/o	519	first	prim/i-	18
electricity	electr/o	98	fissure	-schisis	84
embryo	embryo/o	534	fixation (surgical)	-pexy	100
embryonic cell	-blast, blast/o	49	flow	-rhea	84
end	tel/e, tel/o, acro	26, 58	fluid	hydr/o	50
endocrine	endocrin/o	299	foot	ped/o, pod/o	58
energy	dynam/o	203	foreign	xen/o	235
enlargement	-megaly, megal/o	84	form	morph/o	47
enzyme	-ase	50	formation	gen, genesis, plas, -plasia, -poiesis	49, 367
epididymis	epididym/o	494	force	dynam/o	203
epinephrine	adren/o	299	four	quadr/i, tetra-	18
equal	iso-, equi-	24	fungus	myc/o	86
erythrocyte	erythr/o, erythrocyt/o	368	fusion	-desis	100
esophagus	esophag/o	433	gall	chol/e, chol/o	435
eustachian (auditory) tube	salping/o	264, 520	gallbladder	cholecyst/o	435
examination of	-scopy	99	ganglion	gangli/o, ganglion/o	227
excess	hyper-, super-	23	gas	aer/o, pneum/o, pneumon/o, pneumat/o	98, 400
excision	-ectomy	100	gingiva (gum)	gingiv/o	432
excited state	mania	230	gland	aden/o	47
expansion	dilation, dilatation, ectasia, ectasis	85	glans penis	balan/o	500
extremity	acro	58	glomerulus	glomerul/o	466
eye	ocul/o, ophthalm/o, opt/o, -opia	274, 276	glucose	gluc/o, glyc/o	50
eyelid	blephar/o, palpebr/o	273	good	eu-	24
fallopian tube	salping/o	264, 520	grape-like cluster	staphyl/o	86
false	pseudo-	24	growth	troph/o, -trophy, -trophia	49
far	tel/e, tel/o	26	gum, gingiva	gingiv/o	432
fascia	fasci/o	197	hair	trich/o	129
fat	adip/o, lip/o	50	half	hemi-, semi-	18
fatty	steat/o	50	hand	chir/o	97
fear	-phobia	230	hard	scler/o	82
feces	copro	230	hardening	sclerosis	85
feeding	troph/o, -trophy, -trophia	49	head	cephal/o	57

(continued)



### Meanings and Their Corresponding Word Parts (Continued)

Meaning	Word Part(s)	Reference Page	Meaning	Word Part(s)	Reference Page
hearing	acous, acus, audi/o, cus	264	lacrimal apparatus	dacry/o, lacrim/o	273
heart	cardi/o	326	lacrimal sac	dacryocyst/o	273
heat	therm/o	98	large	macro-, mega-, megal/o-	24
hemorrhage	-rhage, -rhagia	84	larynx	laryng/o	399
hernia	-cele	84	left	sinistr/o	26
hidden	crypt/o	498	lens	lent/i, phac/o, phak/o	274
horny layer of skin	kerat/o	129	leukocyte	leuk/o, leukocyt/o	368
hypophysis	hypophys/i/o, pituitar/i	299	level of carbon dioxide	-capnia	398
islets (pancreatic)	insul/o	299	level of oxygen	-oxia	398
ileum	ile/o	434	life	bio	45
ilium	ili/o	159	light	phot/o	98
immature cell	blast/o, -blast	49	like	-form, -oid	13
immune system	immun/o	368	lip	labi/o, cheil/o	432, 446
immunity	immun/o	368	lipid	lip/o	50
imperfect	atel/o	408	liver	hepat/o	435
in	end/o-, intra-	26, 59	localized dilation	-cele	84
in front of	pre-, pro-	25	loosening	lysis, -lytic	85, 112
incision of	-tomy	100	loss	de-	21
increased	hyper-	23	lumbar region, lower back	lumb/o	57
inflammation	-itis	84	lung, lungs	pneum/o, pneumat/o, pneumon/o, pulm/o, pulmon/o	400
ingest	phag/o	49	lymph, lymphatic system	lymph/o	340
inner ear	labyrinth/o	265	lymph node	lymphaden/o	340
instrument for incising (cutting)	-tome	100	lymphatic vessel	lymphangi/o	340
instrument for measuring	-meter	99	lymphocyte	lymph/o, lymphocyt/o	368
instrument for recording data	-graph	99	male	andr/o	493
instrument for viewing or examining	-scope	99	malformed fetus	terat/o	540
intestine	enter/o	433	mammary gland	mamm/o, mast/o	521
iris	ir, irid/o, irit/o	274	many	multi-, poly-	18
iron	ferr/i, ferr/o, sider/o	369	marrow	myel/o	158, 227, 368
irregular	poikilo-	24	measure	metr/o	99, 520
jaw	gnath/o	432	measuring instrument	-meter	99
jejunum	jejun/o	433	measurement of	-metry	99
joint	arthr/o	158	medical specialty	-ics, -iatics, iatry	11
keratin	kerat/o	129	medicine	pharm, pharmac/o	112
kidney	nephr/o, ren/o	466	medulla oblongata	medull/o	228
labor	toc/o	534	melanin	melan/o	20
labyrinth	labyrinth/o	265	meninges	mening/o, meninge/o	227
lack of	a-, an-	21	menstruation	men/o, mens	518

## Meanings and Their Corresponding Word Parts (Continued)

Meaning	Word Part(s)	Reference Page	Meaning	Word Part(s)	Reference Page
middle	meso-	26	opening (created surgically)	-stomy	101
middle ear	tympan/o	264	opposed	contra-, counter	112
milk	galact/o, lact/o	534	opposite	contra-, counter-	112
mimicking	-mimetic	112	order	tax/o	202
mind	psych/o	228	origin	gen, genesis	49
mold	myc/o	86	other	hetero-	24
molding	plas-, -plasia	49	out, outside	ec-, ecto-, ex/o, extra-	26, 59
month	men/o, mens	518	outer portion	cortic/o	228
mouth	or/o, stoma, stomat/o	432	ovary	ovari/o, oophor/o	519
movement	kin/o, kine, -kinesi/o, kinet/o	197	over	hyper-, epi-	23, 59
much	poly-	18	ovum	oo, ov/o, ovul/o	519
mucus	muc/o, myx/o	47	oxygen	ox/y, -oxia	369, 398
mucous membrane	muc/o	47	pain	-algia, -odynia	84
muscle	my/o, muscul/o	197	pain	-algesia, alg/o, algi/o, algesi/o	84, 12
muscle cell	rhabd/o	203	painful	dys-	83
muscle fiber	in/o	197	palate	palat/o	432
nail	onych/o	129	pancreas	pancreat/o	435
narrowing	stenosis	85	pancreatic islets	insul/o	299
near	ad-, juxta-, para-	22, 59	paralysis	-plegia	230
neck	cervic/o	57, 520	paralysis (partial)	-paresis	230
nerve, nervous system, nervous tissue	neur/o, neur/i	227	parathyroid	parathyr/o, parathyroid/o	299
network	reticul/o	47	partial	semi-	18
neuroglia	gli/o	227	partial paralysis	-paresis	230
never	nulli-	534	partition	sept/o	410
new	neo-	24	pelvis	pelvi/o	159
night	noct/i, nyct/o	102	perineum	perine/o	521
nipple	papill/o	47	peritoneum	periton, peritone/o	57
nitrogenous compounds	azot/o	369	perspiration	hidr/o	129
normal	eu-, normo-	24	pertaining to	-ac, -al, -ar, -ary, -ic, -ical, -ile, -ory, -ous	13
nose	nas/o, rhin/o	399	pharynx	pharyng/o	399
not	a-, an-, in-, im-, non-, un-	21	phrenic nerve	phrenic/o	400
nourishment	troph/o, -trophy, -trophia	49	physician	iatr/o	9
nucleus	kary/o, nucle/o	47	pituitary	pituitar/i, hypophysio/o	299
obsession	mania	230	plant	phyt/o	107, 137
old	presby-	276	plastic repair, plastic surgery	-plasty	100
old age	ger/e, ger/o	12	platelet	thrombocyt/o	368
on	epi-	59	pleura	pleur/o	400
one	mon/o-, uni-	18	poison	tox/o, toxic/o, toxin	82, 112
one side	hemi-	18	poor	mal-	83

(continued)

### Meanings and Their Corresponding Word Parts (Continued)

Meaning	Word Part(s)	Reference Page	Meaning	Word Part(s)	Reference Page
potassium	kali	369	saliva, salivary gland, salivary duct	sial/o	432
pouch (filled)	cyst/o, cyst/i	82	same	equi-, homo-, homeo-, iso-	24
pregnant woman	gravida	534	sclera (of eye)	scler/o	274
pressure	bar/o	98	scanty	oligo-	23
production	-poiesis	367	scrotum	osche/o	494
productive cell	blast/o, -blast	49	sebum, sebaceous gland	seb/o	129
profuse flow	-rhage, -rhagia	84	seizure	-lepsy	230
prolapse	ptosis	85	self	auto-	239
promotor	-agogue	534	semen	semin, sperm/i, spermat/o	494
prostate	prostat/o	494	semen, condition of	-spermia	495
protein	prote/o	50	seminal vesicle	vesicul/o	494
pulse	sphygm/o	271	sensation	-esthesia, esthesi/o	261
puncture	centesis	100	sense of smell	-osmia	261
pupil	pupill/o, cor/o, cor/e	274, 280	sense of taste	-geusia	261
pus	py/o	82	separation	dis-, -lysis	21, 85
pylorus	pylor/o	433	septum	sept/o	410
radiation	radi/o	98	sharp	ox/y	369
rapid	tachy-	83	short	brachy-	501
reading	-lexia	230	sigmoid colon	sigmoid/o	434
reconstruction	-plasty	100	simulating	-mimetic	112
record of data	-gram	99	skeleton	skelet/o	157
recording data (act of)	-graphy	99	skin	derm/o, dermat/o	129
rectum	rect/o, proct/o	434	skull	crani/o	159
red	erythr/o-	20	sleep	hypn/o, somn/o, somn/i	112, 228
red blood cell	erythr/o, erythrocyt/o	368	slipping	-listhesis	169
reducing	-lytic	112	slow	brady-	83
removal	de-, dis-	21	small	micro-	24
removal (surgical)	-ectomy	100	small body	-some	47
renal pelvis	pyel/o	466	smell	osm/o	261
repair (plastic)	-plasty	100	smell (sense of)	-osmia	261
repair (surgical)	-rhaphy	100	sodium	natri	369
respiration	pneum/o, pneumat/o	400	softening	malacia	85
resembling	-form, -oid	13	sound	phon/o, son/o, acous, acus, cus	98, 264
retina	retin/o	274	specialist	-ian, -ist, -logist	11
rib	cost/o	159	specialty	-ics, -iatics, -iatry	11
right	dextr/o-	26	speech	-phasia, -lalia	230
rod	rhabd/o	203	sperm, spermatozoa	sperm/i, spermat/o	494
root of spinal nerve	radicul/o	227			
rupture	-rhexis	84			
sac (filled)	cyst/o, cyst/i	82			
sacrum	sacr/o	159			

## Meanings and Their Corresponding Word Parts (Continued)

Meaning	Word Part(s)	Reference Page	Meaning	Word Part(s)	Reference Page
spinal column	vertebr/o	159	testicle	test/o	494
spinal cord	myel/o, medull/o	158, 228, 368	testis	test/o, orchid/o, orchi/o	494
spinal nerve root	radicul/o	227	thalamus	thalam/o	228
spine	rachi/o	159	thick	pachy-	83
spitting	-ptysis	408	thorax	thorac/o	57
spleen	splen/o	340	three	tri-	18
splitting	-schisis	84	thrombocyte	thrombocyt/o	368
stain	chrom/o, chromat/o	98	through	dia-, per-, trans-	22
stapes	staped/o, stapedi/o	264	thymus gland	thym/o	340
staphylococcus	staphyl/o	86	thyroid	thyr/o, thyroid/o	299
starch	amyl/o	50	time	chron/o	98
stimulator	-agogue	534	tissue	hist/o, histi/o	47
stomach	gastr/o	433	tissue death	necrosis	85
stone	lith	82	toe	dactyl/o	58
stoppage	stasis	85	together	syn-, sym-	26
straight	ortho-	24	tone	ton/o	197
strange	xen/o	235	tongue	gloss/o, lingu/o	432
strength	sthen/o	202	tonsil	tonsil/o	340
Streptococcus	strept/o	86	tooth	-dent/o, dent/i, odont/o	432
structure	morph/o	47	toward	ad-	22
study of	-logy	11	toxin	tox/o, toxic/o	82, 112
stupor	narc/o	112, 228	trachea	trache/o	399
sugar	glyc/o, sacchar/o, -ose	50	true	eu-	24
sudden contraction	spasm	85	tube	salping/o	264, 520
suppression	stasis	85	tumor	onc/o, -oma	82, 84
surgery (plastic)	-plasty	100	turning	trop/o	281
surgical creation of an opening	-stomy	100	twice	bi-, di-	18
surgical fixation	-pexy	100	twisted chain	strept/o	86
surgical removal	-ectomy	100	twisted and swollen vein	varic/o	336
surgical repair	-rhaphy	100	two	bi-, di-, dipl/o-	18
suture	-rhaphy	100	tympenic cavity	tympan/o	264
sweat	hidr/o	129	tympenic membrane	myring/o, tympan/o	264
swelling	edema	85	ultrasound	son/o	98
synovial fluid, joint, membrane	synov/i	158	unchanging	homo-, homeo-	24
tap	centesis	100	unconsciousness	narc/o	228
taste (sense of)	-geusia	261	under	hypo-, sub-	23, 59
tear	dacry/o, lacrim/o	273	unequal	hetero-	24
teeth	dent/o, dent/i, odont/o	432	upright	ortho-	24
temperature	therm/o	98	ureter	ureter/o	467
tendon	ten/o, tendin/o	197	urethra	urethr/o	467

(continued)

### Meanings and Their Corresponding Word Parts (Continued)

Meaning	Word Part(s)	Reference Page	Meaning	Word Part(s)	Reference Page
urinary bladder	cyst/o, vesic/o	467	vestibular apparatus, vestibule	vestibul/o	265
urination	-uresis	468	virus	vir/o	86
urine, urinary tract, urination	ur/o, -uria	467	vision	opt/o, -opia, -opsia	274, 276
urine	urin/o	467	voice	phon/o, -phonia	98, 398
uterine tube	salping/o	264, 520	vomiting	emesis	112
uterus	hyster/o, metr/o, metr/i, uter/o	520	vulva	episi/o, vulv/o	521
uvea	uve/o	274	wall, dividing wall	sept/o	410
uvula	uvul/o	432	water	hydr/o	50
vagina	colp/o, vagin/o	520	weakness	paresis	230
valve	valv/o, valvul/o	326	white	leuk/o-	20
varicose vein, varix	varic/o	336	white blood cell	leuk/o, leukocyt/o	368
varied	poikilo-	24	widening	ectasia, ectasis, dilation, dilatation	85
vas deferens	vas/o	112	within	end/o-, intra-	26, 59
vein	ven/o, ven/i, phleb/o	327	without	a-, an-, de-	21
vein (twisted, swollen)	varic/o	336	woman	gyn/o, gynec/o	518
ventricle	ventricul/o	228, 326	woman who has given birth	para	534
vertebra	spondyl/o, vertebr/o	159	work	erg/o	98, 197
vessel	angi/o, vas/o, vascul/o	326, 327	x-ray	radi/o	98
			yellow	xanth/o-	20

# Appendix 5

## Word Roots

Word Roots					
Root	Meaning	Reference Page	Root	Meaning	Reference Page
abdomin/o	abdomen	57	bronch/i, bronch/o	bronchus	399
acous, acus	sound, hearing	264	bronchiol	bronchiole	399
acro	extremity, end	58	bucc/o	cheek	432
aden/o	gland	47	burs/o	bursa	158
adip/o	fat	50	calc/i	calcium	369
adren/o	adrenal gland, epinephrine	299	cali/o, calic/o	calyx	466
adrenal/o	adrenal gland	299	carcin/o	cancer, carcinoma	82
adrenocortic/o	adrenal cortex	299	cardi/o	heart	326
aer/o	air, gas	98	cec/o	cecum	434
alg/o, algi/o, algesi/o	pain	82, 112	celi/o	abdomen	57
amnio	amnion	534	centesis	puncture, tap	100
amyl/o	starch	50	cephal/o	head	57
andr/o	male	493	cerebell/o	cerebellum	228
angi/o	vessel	327	cerebr/o	cerebrum	228
an/o	anus	434	cervic/o	neck, cervix	57, 520
aort/o	aorta	327	cheil/o	lip	446
arter/o, arteri/o	artery	327	chem/o	chemical	112
arteriol/o	arteriole	327	chir/o	hand	97
arthr/o	joint	158	cholangi/o	bile duct	435
atel/o	incomplete, imperfect	408	chol/e, chol/o	bile, gall	435
atlant/o	atlas	156	cholecyst/o	gallbladder	435
atri/o	atrium	326	choledoch/o	common bile duct	435
audi/o	hearing	264	chondr/o	cartilage	152
azot/o	nitrogenous compounds	369	chori/o, choroid/o	choroid	274
bacill/i, bacill/o	bacillus	86	chrom/o, chromat/o	color, stain	98
bacteri/o	bacterium	86	chron/o	time	98
balan/o	glans penis	500	clasis	breaking	84
bar/o	pressure	98	clitor/o, clitorid/o	clitoris	521
bili	bile	435	coccy, coccyg/o	coccyx	159
bio	life	45	cochle/o	cochlea (of inner ear)	265
blast/o	immature cell, productive cell, embryonic cell	49	col/o, colon/o	colon	434
blephar/o	eyelid	273	colp/o	vagina	520
brachi/o	arm	58			

(continued)

## Word Roots (Continued)

Root	Meaning	Reference Page	Root	Meaning	Reference Page
copro	feces	230	galact/o	milk	534
cor/o, cor/e	pupil	280	gangli/o, ganglion/o	ganglion	227
corne/o	cornea	274	gastr/o	stomach	433
cortic/o	outer portion, cerebral cortex	228	gen	origin, formation	49
cost/o	rib	159	ger/e, ger/o	old age	12
crani/o	skull, cranium	159	gingiv/o	gum, gingiva	432
cry/o	cold	98	gli/o	neuroglia	227
crypt/o	hidden	498	glomerul/o	glomerulus	466
cus	sound, hearing	264	gloss/o	tongue	432
cycl/o	ciliary body, ciliary muscle (of eye)	274	gluc/o	glucose	50
cyst/o	filled sac or pouch, cyst, bladder, urinary bladder	82, 467	glyc/o	sugar, glucose	50
cyt/o	cell	47	gnath/o	jaw	432
dacry/o	tear, lacrimal apparatus	273	goni/o	angle	172, 281
dacryocyst/o	lacrimal sac	273	gravida	pregnant woman	534
dactyl/o	finger, toe	58	gyn/o, gynec/o	woman	518
dent/o, dent/i	tooth, teeth	432	hem/o, hemat/o	blood	368
derm/o, dermat/o	skin	129	hepat/o	liver	435
dilation, dilatation	expansion, widening	85	hidr/o	sweat, perspiration	129
duoden/o	duodenum	433	hist/o, histi/o	tissue	47
dynam/o	force, energy	203	hydr/o	water, fluid	50
ectasia, ectasis	dilation, dilatation, distention	85	hypn/o	sleep	112
edema	accumulation of fluid, swelling	85	hypophysi/o	pituitary, hypophysis	299
electr/o	electricity	98	hyster/o	uterus	520
embryo/o	embryo	534	iatr/o	physician	9
emesis	vomiting	443	ile/o	ileum	434
encephal/o	brain	228	ili/o	ilium	159
endocrin/o	endocrine	299	immun/o	immunity, immune system	368
enter/o	intestine	433	in/o	fiber, muscle fiber	197
epididym/o	epididymis	494	insul/o	pancreatic islets	299
episi/o	vulva	521	ir, irit/o, irid/o	iris	274
erg/o	work	98, 197	jejun/o	jejunum	433
erythr/o-	red, red blood cell	20	kali	potassium	369
erythrocyt/o	red blood cell	368	kary/o	nucleus	47
esophag/o	esophagus	433	kerat/o	cornea, keratin, horny layer of skin	129, 274
fasci/o	fascia	197	kin/o, kine, kinesi/o, kinet/o	movement	197
fer	carry	225	labi/o	lip	432
ferr/i, ferr/o	iron	369	labyrinth/o	labyrinth (inner ear)	265
fet/o	fetus	534	lacrim/o	tear, lacrimal apparatus	273
fibr/o	fiber	47	lact/o	milk	534
			lapar/o	abdominal wall	57

## Word Roots (Continued)

Root	Meaning	Reference Page	Root	Meaning	Reference Page
laryng/o	larynx	399	neur/o, neur/i	nervous system, nerve	227
lent/i	lens	274	noct/i	night	102
leuk/o	white, colorless, white blood cell	20	nucle/o	nucleus	47
leukocyt/o	white blood cell	368	nyct/o	night, darkness	280
lingu/o	tongue	432	ocul/o	eye	274
lip/o	fat, lipid	50	odont/o	tooth, teeth	432
listhesis	slipping	169	onc/o	tumor	82
lith	calculus, stone	82	onych/o	nail	129
lumb/o	lumbar region, lower back	57	oo	ovum	519
lymphaden/o	lymph node	340	oophor/o	ovary	519
lymphangi/o	lymphatic vessel	340	ophthalm/o	eye	274
lymph/o	lymph, lymphatic system, lymphocyte	340	opt/o	eye, vision	274
lymph/o, lymphocyt/o	lymphocyte	368	orchid/o, orchi/o	testis	494
lysis	separation, loosening, dissolving, destruction	85	or/o	mouth	432
malacia	softening	85	osche/o	scrotum	494
mamm/o	breast, mammary gland	521	osm/o	smell	261
mania	excited state, obsession	230	oste/o	bone	158
mast/o	breast, mammary gland	521	ot/o	ear	264
medull/o	inner part, medulla oblongata, spinal cord	228	ovari/o	ovary	519
melan/o	dark, black, melanin	20	ov/o, ovul/o	ovum	519
mening/o, meninge/o	meninges	227	ox/y	oxygen, sharp, acute	369
men/o, mens	month, menstruation	518	palat/o	palate	432
metr/o	measure	99, 520	palpebr/o	eyelid	273
metr/o, metr/i	uterus	520	pancreat/o	pancreas	435
morph/o	form, structure	47	papill/o	nipple	47
muc/o	mucus, mucous membrane	47	para	woman who has given birth	534
muscul/o	muscle	197	parathyr/o, parathyroid/o	parathyroid	299
myc/o	fungus, mold	86	paresis	partial paralysis, weakness	230
myel/o	bone marrow, spinal cord	158, 227, 368	path/o	disease, any disease of	82
my/o	muscle	197	ped/o	foot, child	58, 543
myring/o	tympanic membrane	264	pelvi/o	pelvis	159
myx/o	mucus	47	perine/o	perineum	521
narc/o	stupor, unconsciousness	112, 228	periton, peritone/o	peritoneum	57
nas/o	nose	399	phac/o, phak/o	lens	274
nat/i	birth	534	phag/o	eat, ingest	49
natri	sodium	369	pharm, pharmac/o	drug, medicine	112
necrosis	death of tissue	85	pharyng/o	pharynx	399
nephr/o	kidney	466	phil	attracting, absorbing	49
			phleb/o	vein	327
			phobia	fear	230

(continued)



## Word Roots (Continued)

Root	Meaning	Reference Page	Root	Meaning	Reference Page
phon/o	sound, voice	98	seb/o	sebum, sebaceous gland	129
phot/o	light	98	semin	semen	494
phren/o	diaphragm	400	sept/o	septum, partition, dividing wall	410
phrenic/o	phrenic nerve	400	sial/o	saliva, salivary gland, salivary duct	432
phyt/o	plant	107, 137	sider/o	iron	369
pituitar/i	pituitary, hypophysis	299	sigmoid/o	sigmoid colon	434
plas	formation, molding, development	49	skelet/o	skeleton	157
pleur/o	pleura	400	somat/o	body	47
pneum/o, pneumat/o	air, gas, lung, respiration	400	somn/i, somn/o	sleep	228
pneumon/o	lung	400	son/o	sound, ultrasound	98
pod/o	foot	58	spasm	sudden contraction, cramp	85
proct/o	rectum	434	sperm/i	semen, spermatozoa	494
prostat/o	prostate	494	spermat/o	semen, spermatozoa	494
prote/o	protein	50	sphygm/o	pulse	325
psych/o	mind	228	spir/o	breathing	400
ptosis	dropping, downward displacement, prolapse	85	splen/o	spleen	340
ptysis	spitting	408	spondyl/o	vertebra	159
puer	child	542	staped/o, stapedi/o	stapes	264
pulm/o, pulmon/o	lung	400	stasis	suppression, stoppage	85
pupill/o	pupil	274	steat/o	fatty	50
pyel/o	renal pelvis	466	stenosis	narrowing, constriction	85
pylor/o	pylorus	433	steth/o	chest	97
py/o	pus	82	sthen/o	strength	202
pyr/o, pyret/o	fever, fire	82	stoma, stomat/o	mouth	432
rachi/o	spine	159	synov/i	synovial joint, synovial membrane	158
radicul/o	root of spinal nerve	227	tax/o	order, arrangement	202
radi/o	radiation, x-ray	98	ten/o, tendin/o	tendon	197
rect/o	rectum	434	terat/o	malformed fetus	540
ren/o	kidney	466	test/o	testis, testicle	494
reticul/o	network	47	thalam/o	thalamus	228
retin/o	retina	274	therm/o	heat, temperature	99
rhabd/o	rod, muscle cell	203	thorac/o	chest, thorax	57
rhin/o	nose	399	thromb/o	blood clot	368
sacchar/o	sugar	50	thrombocyt/o	platelet, thrombocyte	368
sacr/o	sacrum	159	thym/o	thymus gland	340
salping/o	tube, uterine tube, auditory (eustachian) tube	264, 520	thyr/o, thyroid/o	thyroid	299
schisis	fissure	84	toc/o	labor	534
scler/o	hard, sclera (of eye)	82, 274	ton/o	tone	197
sclerosis	hardening	85	tonsil/o	tonsil	340

## Word Roots (Continued)

Root	Meaning	Reference Page	Root	Meaning	Reference Page
tox/o, toxic/o	poison, toxin	82, 112	vagin/o	sheath, vagina	520
trache/o	trachea	399	valv/o, valvul/o	valve	326
trich/o	hair	129	varic/o	twisted and swollen vein, varix	336
trop/o	turning	281	vascul/o	vessel	327
trop	act(ing) on, affect(ing)	49	vas/o	vessel, duct, vas deferens	112, 327
troph/o	feeding, growth, nourishment	49	ven/o, ven/i	vein	327
tympan/o	tympanic cavity (middle ear), tympanic membrane	264	ventricul/o	cavity, ventricle	228, 326
ureter/o	ureter	467	vertebr/o	vertebra, spinal column	159
urethr/o	urethra	467	vesic/o	urinary bladder	467
ur/o	urine, urinary tract	467	vesicul/o	seminal vesicle	494
urin/o	urine	467	vestibul/o	vestibule, vestibular apparatus (of ear)	265
uter/o	uterus	520	vir/o	virus	86
uve/o	uvea (of eye)	274	vulv/o	vulva	521
uvul/o	uvula	432	xen/o	foreign, strange	235

# Appendix 6

## Suffixes

Suffixes					
Suffix	Meaning	Reference Page	Suffix	Meaning	Reference Page
-ac	pertaining to	13	-ian	specialist	11
-agogue	promoter, stimulator	534	-ia/sis	condition of	10
-al	pertaining to	13	-iatrics	medical specialty	11
-algnesia	pain	84, 261	-iatry	medical specialty	11
-algia	pain	84	-ic	pertaining to	13
-ar	pertaining to	13	-ical	pertaining to	13
-ary	pertaining to	13	-ics	medical specialty	11
-ase	enzyme	50	-ile	pertaining to	13
-blast	immature cell, productive cell, embryonic cell	49	-ism	condition of	10
-capnia	carbon dioxide (level of)	398	-ist	specialist	11
-cele	hernia, localized dilation	84	-itis	inflammation	84
-centesis	puncture, tap	100	-lalia	speech, babble	230
-clasis, -clasia	breaking	84	-lepsy	seizure	230
-cyte	cell	47	-lexia	reading	230
-desis	binding, fusion	100	-listhesis	slipping	169
-dilation, -dilatation	expansion, widening	85	-logy	study of	11
-ectasia, -ectasis	dilation, dilatation, distention	85	-lysis	separation, loosening, dissolving, destruction	85
-ectomy	excision, surgical removal	100	-lytic	dissolving, reducing, loosening	112
-edema	accumulation of fluid, swelling	85	-malacia	softening	85
-emia	condition of blood	367	-mania	excited state, obsession	230
-esthesia, -esthesi/o	sensation	261	-megaly	enlargement	84
-form	like, resembling	13	-meter	instrument for measuring	99
-gen, -genesis	origin, formation	49	-metry	measurement of	99
-geusia	sense of taste	261	-mimetic	mimicking, simulating	112
-gram	record of data	99	-necrosis	death of tissue	85
-graph	instrument for recording data	99	-odynia	pain	84
-graphy	act of recording data	99	-oid	like, resembling	13
-hemi	half, one side	18	-oma	tumor	84
-hemia	condition of blood	367	-opia	condition of the eye, vision	276
-ia	condition of	10	-opsia	condition of vision	276
			-ory	pertaining to	13
			-ose	sugar	50
			-o/sis	condition of	10

## Suffixes (Continued)

Suffix	Meaning	Reference Page	Suffix	Meaning	Reference Page
-osmia	sense of smell	261	-rhexis	rupture	84
-ous	pertaining to	13	-schisis	fissure, splitting	84
-oxia	oxygen (level of)	398	-sclerosis	hardening	85
-paresis	partial paralysis, weakness	230	-scope	instrument for viewing or examining	99
-pathy	disease, any disease of	84	-scopy	examination of	99
-penia	decrease in, deficiency of	367	-sis	condition of	10
-pexy	surgical fixation	100	-some	body, small body	47
-phasia	speech	230	-spasm	sudden contraction, cramp	85
-philic	attracting, absorbing	49	-stasis	suppression, stoppage	85
-phobia	fear	230	-spermia	condition of semen	494
-phonia	voice	398	-stenosis	narrowing, constriction	85
-plasia	formation, molding, development	49	-stomy	surgical creation of an opening	100
-plasty	plastic repair, plastic surgery, reconstruction	100	-tome	instrument for incising (cutting)	100
-plegia	paralysis	230	-tomy	incision, cutting	100
-pnea	breathing	398	-toxin	poison	85
-poiesis	formation, production	367	-tripsy	crushing	100
-ptosis	dropping, downward displacement, prolapse	85	-tropic	act(ing) on, affect(ing)	112
-rhage, -rhagia	bursting forth, profuse flow, hemorrhage	84	-trophy, -trophia	feeding, growth, nourishment	49
-rhaphy	surgical repair, suture	100	-uresis	urination	468
-rhea	flow, discharge	84	-uria	condition of urine, urination	468
			-y	condition of	10

# Appendix 7

## Prefixes

Prefixes					
Prefix	Meaning	Reference Page	Prefix	Meaning	Reference Page
a-	not, without, lack of, absence	21	hetero-	other, different, unequal	24
ab-	away from	22	homo-, homeo-	same, unchanging	24
acro-	extremity, end	58	hyper-	over, excess, increased, abnormally high	23
ad-	toward, near	22	hypo-	under, below, decreased, abnormally low	23
ambly-	dim	280	im-	not	21
an-	not, without, lack of, absence	21	in-	not	21
ante-	before	25	infra-	below	59
anti-	against	21, 112	inter-	between	59
atel/o-	incomplete	408	intra-	in, within	59
auto-	self	375	iso-	equal, same	24
bi-	two, twice	18	juxta-	near, beside	59
brachy-	short	501	leuk/o-	white, colorless, white blood cell	20
brady-	slow	83	macro-	large, abnormally large	24
circum-	around	59	mal-	bad, poor	83
contra-	against, opposite, opposed	21, 112	mega-, megal/o-	large, abnormally large	24
counter-	against, opposite, opposed	112	melan/o-	black, dark, melanin	20
cyan/o-	blue	20	mes/o-	middle	26
de-	down, without, removal, loss	21	met/a-	change, after, beyond	81
dextr/o-	right	26	micro-	small, one millionth	24
di-	two, twice	18	mon/o-	one	18
dia-	through	22	multi-	many	18
dipl/o-	double	18	neo-	new	24
dis-	absence, removal, separation	21	non-	not	21
dys-	abnormal, painful, difficult	83	normo-	normal	24
ec-	out, outside	26	nulli-	never	534
ecto-	out, outside	26	olig/o-	few, scanty, deficiency of	23
end/o-	in, within	26	ortho-	straight, correct, upright	24
epi-	on, over	59	pachy-	thick	83
equi-	equal, same	24	pan-	all	23
erythr/o-	red	20	para-	near, beside, abnormal	59
eu-	true, good, easy, normal	24	per-	through	22
ex/o-	away from, outside	26			
extra-	outside	59			
hemi-	half, one side	18			

## Prefixes (Continued)

Prefix	Meaning	Reference Page	Prefix	Meaning	Reference Page
peri-	around	59	strept/o-	twisted chain, Streptococcus	86
poikilo-	varied, irregular	24	sub-	below, under	59
poly-	many, much	18	super-	above, excess	23
post-	after, behind	25	supra-	above	59
pre-	before, in front of	25	syn-, sym-	together	26
presby-	old	276	tachy-	rapid	83
prim/i-	first	18	tel/e-, tel/o-	end, far, at a distance	26
pro-	before, in front of	25	tetra-	four	18
pseudo-	false	24	trans-	through	22
quadr/i-	four	18	tri-	three	18
re-	again, back	24	un-	not	21
retro-	behind, backward	59	uni-	one	18
semi-	half, partial	18	xanth/o-	yellow	20
sinistr/o-	left	26	xer/o-	dry	83
staphyl/o-	grape-like cluster, Staphylococcus	86			

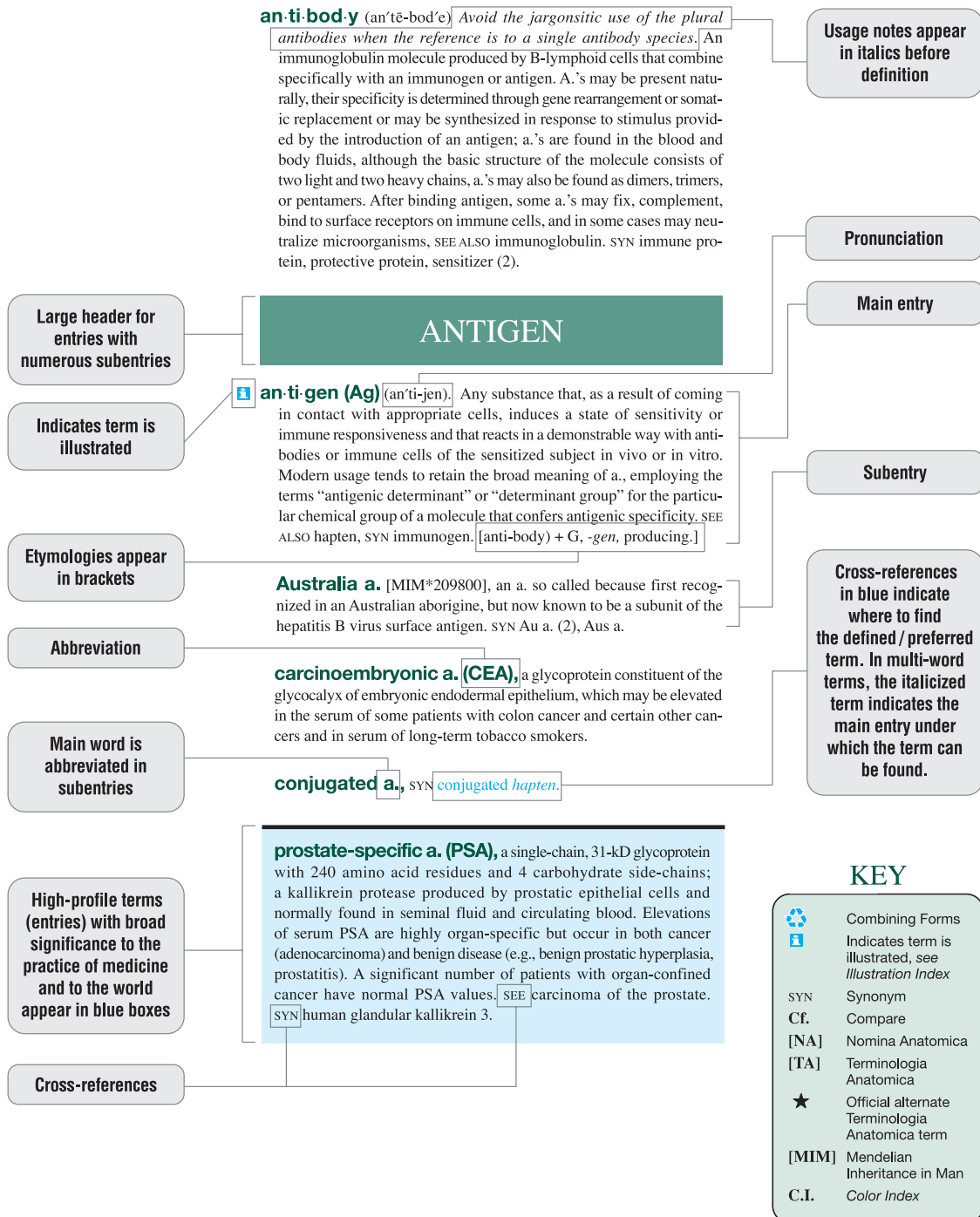
# Appendix 8

## Metric Measurements

Appendix 8-1	Metric Measurements		
Unit	Abbreviation	Metric Equivalent	U.S. Equivalent
<b>Units of Length</b>			
kilometer	km	1,000 m	0.62 mi; 1.6 km/mi
meter*	m	100 cm; 1,000 mm	39.4 in; 1.1 yards
centimeter	cm	1/100 m; 0.01 m	0.39 in; 2.5 cm/in
millimeter	mm	1/1,000 m; 0.001 m	0.039 in; 25 mm/in
micrometer	μm (mcm)	1/1,000 mm; 0.001 mm	
<b>Units of Weight</b>			
kilogram	kg	1,000 g	2.2 lb
gram*	g	1,000 mg	0.035 oz; 28.5 g/oz
milligram	mg	1/1,000 g; 0.001 g	
microgram	mcg	1/1,000 mg; 0.001 mg	
<b>Units of Volume</b>			
liter*	L	1,000 mL	1.06 qt
deciliter	dL	1/10 L; 0.1 L	
milliliter	mL	1/1,000 L; 0.001 L	0.034 oz; 29.4 mL/oz
microliter	μL (mcL)	1/1,000 mL; 0.001 mL	
*Basic unit.			

Appendix 8-2	Metric Prefixes
Prefix	Meaning of Prefix
kilo-	1,000
deci-	1/10; one tenth
centi-	1/100; one hundredth
milli-	1/1,000; one thousandth
micro-	1/1,000,000; one millionth

## Stedman's Medical Dictionary at a Glance





# Appendix 10

## Drugs

Appendix 10-1		Commercial Drugs and Their Actions	
Category	Actions; Applications	Generic Name	Brand Name(s)
<b>adrenergics</b> <i>ad-ren-ER-jiks</i> (sympathomimetics [sim-pah-tho-mih-MET-iks])	Mimic the action of the sympathetic nervous system, which responds to stress; used to treat bronchospasms, allergic reactions, hypotension	epinephrine phenylephrine pseudoephedrine dopamine	Bronkaid Neo-Synephrine Sudafed Intropin
<b>analgesics</b> <i>an-al-JE-siks</i>	Alleviate pain by altering the perception of nociceptive stimuli without producing anesthesia or loss of consciousness		
narcotics <i>nar-KOH-tiks</i>	Decrease pain sensation in central nervous system; chronic use may lead to physical dependence	codeine morphine meperidine oxycodone hydrocodone	Demerol OxyContin, Percocet Vicodin, Lortab
nonnarcotics <i>non-nar-KOH-tiks</i>	Act peripherally to inhibit prostaglandins (local hormones); they may also be anti-inflammatory and antipyretic (reduce fever); Cox-2 inhibitors limit an enzyme that causes inflammation without affecting a related enzyme that protects the stomach lining	aspirin (acetylsalicylic acid; ASA) acetaminophen (APAP) ibuprofen celecoxib (Cox-2 inhibitor)	Tylenol Motrin, Advil Celebrex
<b>anesthetics</b> <i>an-es-THET-iks</i>	Reduce or eliminate sensation (esthesi/o). Compounds that reversibly depress neuronal function, which produces loss of ability to perceive pain and other sensations	local: lidocaine bupivacaine general: nitrous oxide midazolam thiopental	Xylocaine Marcaine Versed Pentothal
<b>anticoagulants</b> <i>an-te-ko-AG-u-lants</i>	Prevent coagulation and formation of blood clots by blocking various steps in the blood clotting process	heparin warfarin apixaban dabigatran rivaroxaban	Coumadin Eliquis Pradaxa Xarelto
<b>anticonvulsants</b> <i>an-te-kon-VUL-sants</i>	Suppress or reduce the number and/or intensity of seizures	phenobarbital phenytoin carbamazepine valproic acid	Dilantin Tegretol Depakene
<b>antidiabetics</b> <i>an-te-di-ab-BET-iks</i>	Counteract diabetes by decreasing blood sugar. Prevent or alleviate diabetes	insulin glyburide linagliptin glipizide metformin	Humulin (injected) Diabeta Tradjenta Glucotrol Glucophage
<b>antiemetics</b> <i>an-te-eb-MET-iks</i>	Relieve symptoms of nausea and prevent vomiting (emesis)	ondansetron dimenhydrinate prochlorperazine scopolamine promethazine	Zofran Dramamine Compazine TRANSDERM-SCOP Phenergan

Appendix 10-1		Commercial Drugs and Their Actions ( <i>Continued</i> )	
Category	Actions; Applications	Generic Name	Brand Name(s)
<b>antihistamines</b> <i>an-te-HIS-tah-menes</i>	Prevent responses mediated by histamine on either H <sub>1</sub> or H <sub>2</sub> receptors: counteract allergic and inflammatory reactions	diphenhydramine fexofenadine loratadine cetirizine	Benadryl Allegra Claritin Zyrtec
<b>antihypertensives</b> <i>an-te-hi-per-TEN-sivs</i>	Lower blood pressure by reducing cardiac output, dilating vessels, or promoting excretion of water by the kidneys. ACE inhibitors block production of a substance that raises blood pressure; ARBs interfere with the action of that substance. See also calcium-channel blockers and beta-blockers under cardiac drugs; diuretics	amlodipine atenolol clonidine prazosin minoxidil captopril enalapril lisinopril losartan valsartan	Norvasc Tenormin Catapres Minipress Loniten Capoten Vasotec Zestril, Prinivil Cozaar Diovan
<b>anti-inflammatory drugs</b> <i>an-te-in-FLAM-ah-to-re</i>	Reduce inflammation and swelling by acting on body responses, without directly antagonizing the causative agent		
corticosteroids <i>kor-tih-ko-STER-oyds</i>	Hormones from the cortex of the adrenal gland (adrenal corticoid). A corticoid containing a steroid; used for allergy, respiratory and blood diseases, injury, and malignancy; suppress the immune system	dexamethasone cortisone prednisone hydrocortisone	Decadron Cortone Deltasone Hydrocortone, Cortef, Solu-Cortef Flonase
nonsteroidal anti-inflammatory drugs (NSAIDs) <i>non-ster-OYD-al</i>	Reduce inflammation and pain by interfering with synthesis of prostaglandins; also antipyretic	aspirin ibuprofen indomethacin naproxen celecoxib	Motrin, Advil Indocin Naprosyn, Aleve Celebrex
<b>anti-infective agents</b> <i>an-te-in-FEK-tiv</i>	Kill or prevent the growth of infectious organisms		
antibacterials <i>an-te-bak-TE-re-als</i> ; antibiotics <i>an-te-bi-OT-iks</i>	Effective against bacteria	amoxicillin penicillin V erythromycin vancomycin gentamicin cephalexin tetracycline ciprofloxacin (for ulcer-causing <i>Helicobacter pylori</i> ) isoniazid (INH) (tuberculosis)	Polymox Pen-Vee K Erythrocin Vancocin Garamycin Keflex Achromycin Cipro
antifungals <i>an-te-FUNG-gals</i>	Effective against fungi	amphotericin B miconazole nystatin	Fungizone Monistat Nilstat
antiparasitics <i>an-te-par-ah-SIT-iks</i>	Effective against parasites—protozoa, worms	iodoquinol (amebae) quinacrine	Yodoxin Atabrine
antivirals <i>an-te-VI-rals</i>	Effective against viruses	acyclovir zanamivir (influenza) zidovudine (HIV) indinavir (HIV protease inhibitor)	Zovirax Relenza Retrovir Crixivan
<b>antineoplastics</b> <i>an-te-ne-o-PLAS-tiks</i>	Destroy cancer cells; they are toxic for all cells but have greater effect on cells that are actively growing and dividing; hormones and hormone inhibitors also are used to slow tumor growth	cyclophosphamide doxorubicin methotrexate vincristine tamoxifen (estrogen inhibitor)	Cytoxan Adriamycin  Oncovin Nolvadex

(continued)

Appendix 10-1		Commercial Drugs and Their Actions ( <i>Continued</i> )	
Category	Actions; Applications	Generic Name	Brand Name(s)
<b>cardiac drugs</b> <i>KAR-de-ak</i>	Act on the heart		
antiarrhythmics <i>an-te-ah-RITH-miks</i>	Correct or prevent abnormalities of heart rhythm	quinidine lidocaine digoxin	Quinidex Xylocaine Lanoxin
beta-adrenergic blockers (beta-blockers) <i>ba-tah-ad-ren-ER-jik</i>	Inhibit sympathetic nervous system; reduce rate and force of heart contractions	propranolol metoprolol atenolol	Inderal Toprol-XL Tenormin
calcium-channel blockers <i>KAL-se-um</i>	Dilate coronary arteries, slow heart rate, reduce contractions	diltiazem nifedipine verapamil	Cardizem Procardia Verelan, Calan
hypolipidemics <i>hi-po-lip-ih-DE-miks</i>	Lower cholesterol in patients with high serum levels that cannot be controlled with diet alone; hypocholesterolemics, statins	lovastatin pravastatin atorvastatin simvastatin	Mevacor Pravachol Lipitor Zocor
nitrates <i>NI-trates</i> ; antianginal agents <i>an-tih-AN-ji-nal</i>	Dilate coronary arteries and reduce heart's workload by lowering blood pressure and reducing venous return	nitroglycerin isosorbide	Nitrostat Isordil
<b>CNS stimulants</b>	Stimulate the central nervous system	methylphenidate amphetamine (chronic use may lead to drug dependence)	Ritalin Adderall, Dexedrine
<b>diuretics</b> <i>di-u-RET-iks</i>	Promote excretion of water, sodium, and other electrolytes by the kidneys; used to reduce edema and blood pressure; loop diuretics act on the kidney tubules (see Chapters 10 and 14)	furosemide ethacrynic acid mannitol hydrochlorothiazide (HCTZ) triamterene + HCTZ	Lasix Edecrin Osmitrol HydroDIURIL Dyazide
<b>gastrointestinal drugs</b> <i>gas-tro-in-TES-tin-al</i>	Act on the digestive tract		
antidiarrheals <i>an-te-di-ah-RE-als</i>	Treat or prevent diarrhea by reducing intestinal motility or absorbing irritants and soothing the intestinal lining	diphenoxylate+ atropine loperamide attapulgite	Lomotil Imodium Kaopectate
histamine H <sub>2</sub> antagonists <i>HIS-tah-mene</i>	Decrease stomach acid secretion by interfering with the action of histamine at H <sub>2</sub> receptors; used to treat ulcers and other gastrointestinal problems	famotidine ranitidine	Pepcid Zantac
laxatives <i>LAK-sab-tivs</i>	Promote elimination from the large intestine; types include: stimulants hyperosmotics (retain water) stool softeners bulk-forming agents	bisacodyl lactulose docusate psyllium	Dulcolax Constilac, Chronulac Colace, Surfak Metamucil
proton pump inhibitors <i>PRO-ton</i>	Reduce stomach acidity by blocking transport of hydrogen ions (protons) into the stomach	esomeprazole lansoprazole omeprazole	Nexium Prevacid Prilosec
<b>muscle relaxants</b> <i>re-LAK-sants</i>	Depress nervous system stimulation of skeletal muscles; used to control muscle spasms and pain	baclofen carisoprodol methocarbamol	Lioresal Soma Robaxin

Appendix 10-1		Commercial Drugs and Their Actions (Continued)	
Category	Actions; Applications	Generic Name	Brand Name(s)
<b>psychotropics</b> <i>si-ko-TROP-iks</i>	Affect the mind, altering mental activity, mental state, or behavior		
antianxiety agents <i>an-te-ang-ZI-eh-te</i>	Reduce or dispel anxiety; tranquilizers; anxiolytic agents	lorazepam chlordiazepoxide diazepam hydroxyzine alprazolam buspirone	Ativan Librium Valium Atarax Xanax BuSpar
antidepressants <i>an-te-de-PRES-sants</i>	Relieve depression by raising brain levels of neurotransmitters (chemicals active in the nervous system)	amitriptyline imipramine fluoxetine paroxetine sertraline	Elavil Tofranil Prozac Paxil Zoloft
antipsychotics <i>an-te-si-KOT-iks</i>	Act on nervous system to relieve symptoms of psychoses	chlorpromazine haloperidol risperidone olanzapine	Thorazine Haldol Risperdal Zyprexa
<b>respiratory drugs</b>	Act on the respiratory system		
antitussives <i>an-te-TUS-sivs</i>	Suppress coughing	dextromethorphan	Benlyn DM
asthma maintenance drugs; bronchodilators <i>brong-ko-di-LA-tors</i>	Used for prevention of asthma attacks and chronic treatment of asthma; prevent or eliminate spasm of the bronchi (breathing tubes) by relaxing bronchial smooth muscle; used to treat asthma attacks and bronchitis	fluticasone montelukast albuterol metaproterenol tiotropium	Flovent Singulair Proventil Alupent Spiriva
expectorants <i>ek-SPEK-to-rants</i>	Induce productive coughing to eliminate respiratory secretions	guaifenesin	Robitussin
mucolytics <i>mu-ko-LIT-iks</i>	Loosen mucus to promote its elimination	acetylcysteine	Mucomyst
<b>sedatives/hypnotics</b> <i>SED-ab-tivs/hip-NOT-iks</i>	Induce relaxation and sleep; lower (sedative) doses promote relaxation leading to sleep; higher (hypnotic) doses induce sleep; antianxiety agents also used	phenobarbital zolpidem	Ambien

Appendix 10-2		Therapeutic Uses of Herbal Medicines
Name	Part Used	Therapeutic Uses
aloe <i>AL-o</i>	leaf	treatment of burns and minor skin irritations
black cohosh <i>KO-hosh</i>	root	reduction of menopausal hot flashes
chamomile <i>KAM-o-mile</i>	flower	anti-inflammatory, gastrointestinal antispasmodic, sedative
echinacea <i>eh-kib-NA-she-ab</i>	all	may reduce severity and duration of colds, may stimulate the immune system, used topically for wound healing
evening primrose oil <i>PRIM-roze</i>	seed	source of essential fatty acids important for the health of the cardiovascular system; treatment of premenstrual syndrome (PMS), rheumatoid arthritis, skin disorders
flax	seed	source of fatty acids important in maintaining proper lipids (e.g., cholesterol) in the blood
ginger <i>JIN-jer</i>	root	relief of nausea and motion sickness, treatment of colds and sore throat
ginkgo <i>GING-ko</i>	leaf	improves blood circulation in and function of the brain, improves memory, used to treat dementia, antianxiety agent, protects the nervous system
ginseng <i>JIN-seng</i>	root	stress reduction, lowers blood cholesterol and blood sugar
green tea	leaf	antioxidant, acts against cancer of the gastrointestinal tract and skin, oral antimicrobial agent, reduces dental caries
kava <i>KAH-vah</i>	root	antianxiety agent, sedative
milk thistle <i>thisl</i>	seeds	protects the liver against toxins, antioxidant
saw palmetto <i>pal-MET-o</i>	berries	used to treat benign prostatic hyperplasia (BPH)
slippery elm	bark	as lozenge for throat irritation, for gastrointestinal irritation and upset, protects irritated skin
soy	bean	rich source of nutrients; protective estrogenic effects in menopausal symptoms, osteoporosis, cardiovascular disease, cancer prevention
St. John's wort	flower	treatment of anxiety and depression, has antibacterial and antiviral properties (note: this product can interact with a variety of drugs)
tea tree oil	leaf	antimicrobial; used to heal cuts, skin infections, burns
valerian <i>vah-LE-re-an</i>	root	sedative, sleep aid

# Appendix 11

## Answer Key

### Chapter 1

#### PRETEST

1. c
2. d
3. c
4. a
5. a
6. c
7. c
8. b

#### CHAPTER EXERCISES

##### Exercise 1-1

1. -ia
2. -sis, -iasis
3. -ism
4. -y
5. -ia
6. -ism
7. -sis, -osis
8. -y
9. -sis, -esis

##### Exercise 1-2

1. -ist
2. -logy
3. -iatics
4. -logy
5. -ian
6. -ist
7. anatomist
8. pediatrician
9. radiologist
10. psychologist
11. technologist; also, technician
12. obstetrician

##### Exercise 1-3

1. -ary
2. -al
3. -ic
4. -ous
5. -form
6. -oid
7. -al, -ical
8. -ile
9. -ic

10. -al, -ical
11. -ar
12. -ary
13. -ory
14. -ic
15. -ar

##### Exercise 1-4

1. patellae (*pab-TEL-e*)
2. phenomena (*feb-NOM-eb-nah*)
3. omenta (*o-MEN-tab*)
4. prognoses (*prog-NO-seze*)
5. apices (*AP-ih-seze*)
6. ova (*O-vah*)
7. spermatozoa (*sper-mah-to-ZO-ab*)
8. meninges (*meh-NIN-jeze*)
9. emboli (*EM-bo-li*)
10. protozoon (*pro-to-ZO-on*)
11. appendix (*ab-PEN-diks*)
12. adenoma (*ad-eh-NO-mah*)
13. fungus (*FUN-gus*)
14. pelvis (*PEL-vis*)
15. foramen (*fo-RA-men*)
16. curriculum (*kur-RIK-u-lum*)
17. index (*IN-deks*)
18. alveolus (*al-VE-o-lus*)

##### Exercise 1-5

1. uni-; bi-; tri-; tetra-
2. two
3. four
4. one
5. half
6. two
7. four
8. three
9. one
10. bi-
11. multi-
12. semi-
13. uni-

##### Exercise 1-6

1. d
2. c
3. a
4. b
5. e

##### Exercise 1-7

1. a-; not, without, lack of, absence
2. anti-; against
3. a-; not, without (root *mnem/o* means “memory”)
4. dis-; absence, removal, separation
5. contra-; against, opposite, opposed
6. in-; not
7. de-; down, without, removal, loss
8. non-; not
9. unconscious
10. insignificant
11. disinfect
12. unusual
13. nonspecific
14. decongestant
15. incompatible

##### Exercise 1-8

1. dia-; through
2. per-; through
3. ad-; toward, near
4. ab-; away from
5. dia-; through
6. trans-; through

##### Exercise 1-9

1. c
2. e
3. d
4. b
5. a

##### Exercise 1-10

1. d
2. e
3. c
4. b
5. a
6. homeo-; same, unchanging
7. equi-; equal, same
8. ortho-; straight, correct, upright
9. re-; again, back
10. eu-; true, good, easy, normal
11. neo-; new
12. mega-; large, abnormally large
13. iso-; equal, same
14. normo-; normal

15. heterogeneous (*het-er-o-JE-ne-us*)  
 16. microscopic (*mi-kro-SKOP-ik*)

### Exercise 1-11

1. e
2. a
3. b
4. c
5. d
6. pre-; before, in front of
7. post-; after, behind
8. pro-; before, in front of
9. pre-; before, in front of
10. ante-; before

### Exercise 1-12

1. e
2. c
3. a
4. b
5. d
6. sym-; together
7. ex-; away from, outside
8. ecto-; out, outside
9. syn-; together
10. endo-; in, within
11. endogenous (*en-DOJ-eh-nus*)
12. sinistromanual (*sin-is-tro-MAN-u-al*)
13. endoderm (*EN-do-derm*)

## CHAPTER REVIEW

1. b
2. d
3. d
4. b
5. c
6. b
7. a
8. combining form
9. diarrhea
10. alcohol, ethyl alcohol
11. examination of
12. cardiology
13. pertaining to
14. increase(d)
15. one
16. three
17. left
18. two
19. opposite
20. four
21. -ism
22. -ia
23. -sis, -osis
24. -y
25. -sis, -osis
26. -ia
27. -iatry
28. -ics
29. -ist
30. -ian
31. -ian
32. dermatologist
33. pediatrician
34. physiologist
35. gynecologist
36. -ous
37. -oid
38. -al
39. -ic
40. -ary
41. -al
42. -oid
43. -ile
44. -ar
45. -ory
46. gingivae (*JIN-jih-ve*)
47. testes (*TES-teze*)
48. criteria (*kri-TIR-e-ab*)
49. lumina (*LU-mih-nah*)
50. loci (*LO-si*)
51. ganglia (*GANG-le-ab*)
52. larynges (*lah-RIN-jeze*)
53. nuclei (*NU-kle-i*)
54. thrombus (*THROM-bus*)
55. vertebra (*VER-teh-bra*)
56. bacterium (*bak-TE-re-um*)
57. alveolus (*al-VE-o-lus*)
58. apex (*A-peks*)
59. foramen (*fo-RA-men*)
60. diagnosis (*di-ag-NO-sis*)
61. carcinoma (*kar-sih-NO-mah*)
62. hyper-; over, excess, abnormally high, increased
63. trans-; through
64. post-; after
65. re-; again, back
66. ex-; away from, outside
67. ad-; toward, near
68. un-; not
69. de-; removal, without
70. semi-; half, partial
71. pre-; before, in front of
72. per-; through
73. dia-; through
74. anti-; against
75. micro-; small
76. dis-; absence, removal, separation
77. endo-; in, within
78. sym-; together
79. pro-; before, in front of
80. in-; not
81. dehumidify
82. impermeable
83. homogeneous
84. endotoxin
85. macroscopic
86. hypoventilation
87. presynaptic
88. aseptic
89. hypersensitivity
90. macrocyte
91. prenatal
92. equilateral
93. T
94. F; one cell
95. T
96. F; four
97. F; right
98. F; three
99. T
100. *dis-LEK-se-ab*
101. *RU-mah-tizm*
102. *nu-MAT-ik*
103. *KEM-ist*
104. *FAR-mah-se*
105. cardiac
106. hydrogen
107. ocular
108. rheumatic
109. e
110. d
111. c
112. b
113. a
114. d
115. c
116. a
117. b
118. e
119. e
120. a
121. b
122. c
123. d
124. gastritis (*gas-TRI-tis*)
125. neurology (*nu-ROL-o-je*)
126. nephroptosis (*nef-rop-TO-sis*)
127. nephrology (*nef-ROL-o-je*)
128. neuritis (*nu-RI-tis*)
129. cardiopptosis (*kar-de-op-TO-sis*)
130. microcytic
131. ectocardia
132. monocytic
133. dextrocardia
134. endocardial
135. macrocytic
136. microcardia

137. pertaining to the kidney and stomach  
 a. kidney  
 b. stomach  
 c. pertaining to
138. Specialist in care of the aged:  
 a. old, old age  
 b. physician  
 c. pertaining to  
 d. specialist
139. of equal dimensions  
 a. equal, same  
 b. measure  
 c. pertaining to
140. association of two or more organisms  
 a. together  
 b. life  
 c. condition of

## CASE STUDY QUESTIONS

### Case Study 1-1

- c
- d
- a
- b
- anterior cruciate ligament
- complains (complaining) of
- over, excess, abnormally high, increased
- as needed
- a. excess  
b. fat  
c. condition of blood
- a. straight  
b. foot/child
- between

### Case Study 1-2

- c
- b
- b
- c
- a
- (in any order)
  - pulmonologist
  - stylist
  - manicurist
  - therapist
- (in any order)
  - ic: bronchoscopic, antibiotic
  - ory: respiratory
  - ile: febrile
  - ary: pulmonary
  - ical, -al: chemical

### Case Study 1-3

- pre-; before, in front of
- an-; not, without, lack of, absence
- dis-; absence, removal, separation
- re-; again, back
- bi-; two, twice
- hemi-; half, one side
- de-; down, without, removal, loss
- condition of
- pertaining to
- preoperative
- postoperative
- abduction

## Chapter 2

### PRETEST

- c
- c
- b
- a
- d
- d
- d
- a

## CHAPTER EXERCISES

### Exercise 2-1

- cells
- fiber
- tissues
- forms
- nucleus
- nucleus
- gland
- nipple
- mucus
- network
- mucus
- body
- morphology (*mor-FOL-o-je*)
- cytology (*si-TOL-o-je*)
- histology (*his-TOL-o-je*)

### Exercise 2-2

- d
- c
- e
- b
- a
- d
- c
- e
- b
- a
- gen; origin, formation

- phag/o; eat, ingest
- blast; immature cell, productive cell, embryonic cell
- plas; formation, molding, development
- troph; feeding, growth, nourishment

### Exercise 2-3

- sugars
- sugar
- water
- starch
- lipid, fat
- glucose
- fat, lipid
- steat/o; fatty
- lip/o; lipid, fat
- glyc/o; sugar, glucose
- gluc/o; glucose

### Exercise 2-4

- thoracic (*tho-RAS-ik*)
- cephalic (*seh-FAL-ik*)
- cervical (*SER-vih-kal*)
- abdominal (*ab-DOM-ih-nal*)
- lumbar (*LUM-bar*)
- peritoneum
- abdomen
- abdominal wall

### Exercise 2-5

- extremities (hands and feet)
- arms
- finger or toe
- arm and head
- foot

### Exercise 2-6

- circumoral
- subscapular
- circumvascular
- infracostal
- periorbital
- infrapatellar
- intracellular
- suprascapular
- extrathoracic
- near the nose
- behind the peritoneum
- above the abdomen
- within the uterus
- around the navel (umbilicus)
- between the buttocks
- above the ankle
- within the eye
- near the sacrum



**CHAPTER REVIEW****Labeling Exercise****Directional Terms**

1. superior (cranial)
2. inferior (caudal)
3. anterior (ventral)
4. posterior (dorsal)
5. medial
6. lateral
7. proximal
8. distal

**Planes of Division**

1. frontal (coronal) plane
2. sagittal plane
3. transverse (horizontal) plane

**Body Cavities, Lateral View**

1. dorsal cavity
2. cranial cavity
3. spinal cavity (canal)
4. ventral cavity
5. thoracic cavity
6. diaphragm
7. abdominopelvic cavity
8. abdominal cavity
9. pelvic cavity

**The Nine Regions of the Abdomen**

1. epigastric (*ep-i-GAS-trik*) region
2. umbilical (*um-BIL-i-kal*) region
3. hypogastric (*hi-po-GAS-trik*) region
4. right hypochondriac (*hi-po-KON-dre-ak*) region
5. left hypochondriac region
6. right lumbar (*LUM-bar*) region
7. left lumbar region
8. right iliac (*IL-e-ak*) region; also inguinal (*ING-gwi-nal*) region
9. left iliac region; also, inguinal region

**Terminology**

1. c
2. d
3. e
4. a
5. b
6. a
7. c
8. b
9. e
10. d
11. d
12. a

13. b
14. c
15. e
16. e
17. a
18. b
19. c
20. d
21. a
22. e
23. b
24. d
25. c
26. b
27. c
28. d
29. e
30. a
31. e
32. c
33. a
34. d
35. b
36. d
37. a
38. c
39. b
40. e
41. histology
42. epithelial, connective, muscle, and nervous tissue
43. metabolism
44. lymphatic system
45. glucose
46. mucus
47. enzyme
48. water
49. morphology
50. abdomen
51. finger or toe
52. base of skull
53. wrist
54. neck
55. arm
56. instrument for viewing the peritoneal cavity through the abdominal wall
57. above the pubis
58. below the umbilicus (navel)
59. under the tongue
60. behind the peritoneum
61. having two feet
62. dorsal
63. periocular
64. inframammary
65. anterior
66. megacephaly, macrocephaly
67. superficial

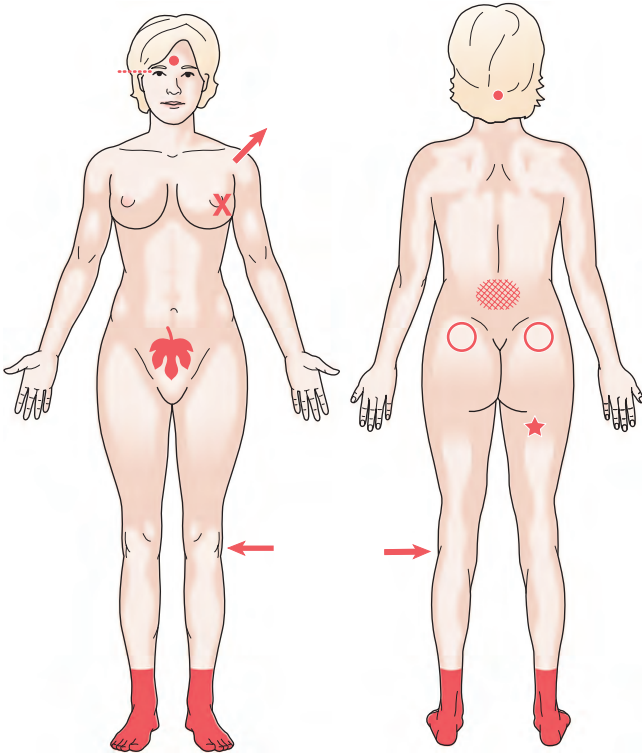
68. distal
69. suprascapular
70. intracellular
71. inferior
72. cervical region; *Cervical* refers to the neck; the others are abdominal regions.
73. transverse; *Transverse* refers to a plane of division; the others are body positions.
74. spinal cavity; The *spinal cavity* is a dorsal cavity; the others are ventral cavities.
75. T
76. F; lipid, fat
77. T
78. F; dorsal
79. T
80. F; distal
81. F; frontal, coronal
82. T
83. T
84. adenoid
85. leukoblast
86. lipase
87. mucoid
88. histioblast
89. amylase
90. amyloid
91. dactylospasm
92. infrathoracic
93. intrathoracic
94. polydactyly
95. syndactyly
96. cephalothoracic
97. adactyly
98. intracephalic
99. acephaly
100. a state of internal balance
  - a. same, unchanging
  - b. standing still, unchanging
  - c. condition of
101. destruction and disposal of damaged organelles in the cell
  - a. self
  - b. to eat
  - c. condition of
102. bluish discoloration of the hands or feet
  - a. extremity
  - b. blue
  - c. condition of
103. pertaining to the forearm
  - a. before
  - b. arm
  - c. pertaining to

**CASE STUDY QUESTIONS****Case Study 2-1**

1. a
2. d
3. a-; not, without, lack of, absence
4. bi-; two
5. meta-; change, after, beyond
6. morphologic
7. histologic
8. cytoplasm, lymphocytes, lymphocytic

**Case Study 2-2**

1. b
  2. b
  3. d
  4. c
  5. a
- 6–15. See diagrams.

**Chapter 3****PRETEST**

1. c
2. b
3. a
4. d
5. b
6. b
7. c
8. d

**CHAPTER EXERCISES****Exercise 3-1**

1. toxic/o; poison
2. py/o; pus
3. lith/o; stone
4. path/o; disease
5. hardening
6. calculus, stone
7. bladder
8. disease
9. cancer, carcinoma
10. toxin, poison
11. pus
12. pain
13. tumor
14. fever

**Exercise 3-2**

1. e
2. a
3. d
4. b
5. c
6. xero-; dry
7. dys-; abnormal, painful, difficult
8. mal-; bad, poor

**Exercise 3-3**

1. a
2. d

3. b
4. e
5. c
6. b
7. d
8. a
9. c
10. e
11. pain in a muscle
12. any disease of muscle
13. rupture of a muscle
14. pain in a muscle
15. tumor of muscle

**Exercise 3-4**

1. e
2. d
3. b
4. a
5. c
6. softening of the spleen
7. dropping or prolapse of the spleen
8. substance poisonous or harmful to the spleen

**Exercise 3-5**

1. bacteria
2. fungus
3. bacilli
4. chain
5. cluster
6. mycology (*mi-KOL-o-je*)
7. virology (*vi-ROL-o-je*)
8. bacteriology (*bak-tere-e-OL-o-je*)

**Exercise 3-6**

1. a
2. c
3. d
4. e
5. b
6. son/o; sound
7. chron/o; time
8. therm/o; heat, temperature
9. erg/o; work
10. aer/o; air (oxygen)
11. chrom/o; color
12. electricity
13. light
14. cold
15. pressure
16. sound

**Exercise 3-7**

1. e
2. c
3. d
4. a

5. b
6. c
7. e
8. d
9. a
10. b

### Exercise 3-8

1. b
2. e
3. a
4. d
5. c
6. cystotomy (*sis-TOT-o-me*)
7. cystopexy (*SIS-to-pek-e*)
8. cystoplasty (*SIS-to-plas-te*)
9. cystorrhaphy (*sis-TOR-ah-fe*)
10. cystostomy (*sis-TOS-to-me*)
11. arthroplasty (*AR-thro-plas-te*)
12. arthrotome (*AR-thro-tome*)
13. arthrotomy (*ar-THROT-o-me*)
14. arthrocentesis (*ar-thro-sen-TE-sis*)
15. arthrodesis (*ar-THROD-eh-sis*)
16. tracheotomy (*tra-ke-OT-o-me*)
17. gastrorrhaphy (*gas-TROR-ah-fe*)
18. colostomy (*ko-LOS-to-me*)

### Exercise 3-9

1. -lytic; dissolving, reducing, loosening
2. -tropic; acting on
3. -mimetic; mimicking, simulating
4. antibacterial (*an-te-bak-TERE-e-al*)
5. contralateral (*kon-trah-LAT-er-al*)
6. antiseptic (*an-te-SEP-tik*)
7. counteract (*COWN-ter-act*)
8. antiemetic (*an-te-eh-MET-ik*)
9. antipyretic (*an-te-pi-RET-ik*)
10. narc/o; stupor
11. chem/o; chemical
12. algesi/o; pain
13. toxic/o; poison
14. hypn/o; sleep
15. dilation (widening) of a vessel
16. study of drugs
17. dissolving mucus
18. acting on the gonads (sex glands)

## CHAPTER REVIEW

1. d
2. c
3. b
4. e
5. a
6. e
7. c
8. d
9. b
10. a
11. c
12. b
13. d
14. a
15. e
16. a
17. c
18. b
19. d
20. e
21. c
22. d
23. b
24. e
25. a
26. e
27. d
28. c
29. a
30. b
31. d
32. e
33. a
34. c
35. b
36. d
37. b
38. e
39. c
40. a
41. a
42. c
43. e
44. b
45. d
46. inflammation
47. neoplasm
48. metastasis
49. hernia
50. necrosis
51. tumor
52. worm
53. palpation
54. prognosis (*prog-NO-sis*)
55. edematous (*eh-DEM-ah-tus*)
56. therapy (*THER-ah-pe*)
57. light
58. gastroplasty (*GAS-tro-plas-te*)
59. arthrodesis (*ar-THROD-eh-sis*)
60. colostomy (*ko-LOS-to-me*)
61. skin
62. tolerance
63. vein
64. potentiation
65. diuretic
66. antiemetic
67. pain
68. psychotropic
69. fatty acids
70. leaf
71. hepatotomy (*hep-ah-TOT-o-me*)
72. hepatectomy (*hep-ah-TEK-to-me*)
73. hepatopepy (*HEP-ah-to-pek-se*)
74. hepatorrhaphy (*hep-ah-TOR-ah-fe*)
75. carcinogenesis (*kar-sin-o-JEN-e-sis*)
76. pathogenesis (*path-o-JEN-eh-sis*)
77. pyogenesis (*pi-o-JEN-eh-sis*)
78. oncogenesis (*ong-ko-JEN-eh-sis*)
79. bronchorrhea (*brong-ko-RE-ah*)
80. bronchitis (*brong-KI-tis*)
81. bronchostenosis (*brong-ko-steno-sis*)
82. bronchospasm (*BRONG-kospazm*)
83. osteodynia, ostealgia (*os-te-o-DIN-e-ah, os-te-AL-je-ah*)
84. osteonecrosis (*os-te-o-ne-KRO-sis*)
85. osteoma (*os-te-O-mah*)
86. osteoclasts (*os-te-OK-la-sis*)
87. osteomalacia (*os-te-o-mah-LA-she-ah*)
88. F; fungus
89. T
90. F; acute
91. T
92. F; bradycardia
93. F; ear
94. F; radiograph
95. T
96. helminths; *Helminths* are worms, the others are types of bacteria.
97. metastatic; *Metastatic* refers to the spread of cancer; the others are terms describing infections.
98. remission; *Remission* is the lessening of disease symptoms; the others are examining methods.
99. syncope; *Syncope* is fainting; the others are examination instruments.
100. tablet; A *tablet* is a solid dosage form, a pill; the others are forms of liquid solutions.
101. nephrotoxic (*nef-ro-TOKS-ik*)
102. pyogenic (*pi-o-JEN-ik*)
103. nephroma (*nef-RO-mah*)
104. pathology (*pa-THOL-o-je*)

105. pyrogenic (*pi-ro-JEN-ik*)
106. nephrology (*nef-ROL-o-je*)
107. pathogenic (*path-o-JEN-ik*)
108. nephropathy (*nef-ROP-a-the*)
109. nephrogenic (*nef-ro-JEN-ik*)
110. neurotripsy (*nu-ro-TRIP-se*)
111. cystorrhaphy (*sis-TOR-ah-fe*)
112. cystopexy (*SIS-to-pek-se*)
113. neurorrhaphy (*nu-ROR-ah-fe*)
114. lithotripsy (*LITH-o-trip-se*)
115. cystolith (*SIS-to-lith*)
116. cystoscopy (*sis-TOS-ko-pe*)
117. neurotome (*NU-ro-tome*)
118. cystotome (*SIS-to-tome*)
119. ingestion of organisms or small particles by a cell
  - a. to eat
  - b. cell
  - c. condition of
120. counteracting fever
  - a. against
  - b. fever
  - c. pertaining to
121. hardening of the arteries
  - a. artery
  - b. hard
  - c. condition of
122. uneven, not symmetrical or of the same measurement
  - a. not
  - b. together
  - c. measure
  - d. pertaining to

## CASE STUDY QUESTIONS

### Case Study 3-1

1. b
2. a
3. d
4. c
5. electrocardiogram
6. transesophageal echocardiogram
7. subacute bacterial endocarditis
8. idiopathic hypertrophic subaortic stenosis

### Case Study 3-2

1. b
2. a
3. c
4. c
5. d
6. a
7. by mouth
8. milligram
9. microgram
10. intravenous(ly)

## Chapter 4

### PRETEST

1. c
2. b
3. a
4. b
5. d
6. c

### CHAPTER EXERCISES

#### Exercise 4-1

1. derm/o; skin
2. seb/o; sebum
3. melan/o; melanin
4. kerat/o; keratin, horny layer of the skin
5. hidr/o; sweat
6. trich/o; hair
7. onych/o; nail
8. skin
9. horny (keratinous) layer
10. melanin
11. hair
12. nail
13. sweat, perspiration
14. skin
15. dermatolysis (*der-mah-TOL-ih-sis*); dermolysis (*der-MOL-ih-sis*)
16. dermatology (*der-mah-TOL-o-je*)
17. onychomalacia (*on-ih-ko-mah-LA-she-ah*)
18. hyperhidrosis (*hi-per-hi-DRO-sis*)
19. trichology (*trik-OL-o-je*)
20. dermatome (*DER-mah-tome*)
21. keratogenesis (*ker-ah-to-JEN-eh-sis*)
22. melanoma (*mel-ah-NO-mah*)
23. scleroderma (*skle-ro-DER-mah*)
24. pyoderma (*pi-o-DER-mah*)

### CHAPTER REVIEW

#### Labeling Exercise

##### Cross-Section of the Skin

1. epidermis
2. stratum basale (growing layer)
3. stratum corneum
4. dermis
5. skin
6. subcutaneous layer
7. adipose tissue
8. hair follicle
9. hair
10. arrector pili muscle
11. artery
12. vein
13. nerve

14. nerve endings
15. sweat gland
16. pore (opening of sweat gland)
17. sebaceous (oil) gland
18. touch receptor
19. pressure receptor

#### Terminology

1. e
2. a
3. d
4. b
5. c
6. d
7. c
8. a
9. e
10. b
11. e
12. b
13. c
14. a
15. d
16. a
17. b
18. e
19. d
20. c
21. melanin
22. sebaceous glands
23. sweat, perspiration
24. skin
25. skin
26. keratin
27. nail
28. decubitus ulcer, bed sore, pressure sore
29. touch
30. débridement
31. skin graft, full-thickness skin graft
32. ischemia
33. plastic surgeon
34. dryness of the skin
35. abnormal keratin production
36. excess flow of sebum
37. thickening of the skin
38. infection of a nail and nail bed
39. excess melanin production
40. through the skin
41. producing keratin
42. seborrheic (*seb-o-RE-ik*)
43. hyperkeratosis (*hi-per-ker-ah-TO-sis*)
44. dermatome (*DER-mah-tome*)
45. melanoma (*mel-ah-NO-mah*)
46. melanocyte (*MEL-ah-no-site*)
47. scleroderma; dermatosclerosis (*skle-ro-DER-mah; der-mah-to-skle-RO-sis*)

48. anhidrosis (*an-hi-DRO-sis*)
49. hyperhidrosis (*hi-per-hi-DRO-sis*)
50. chromhidrosis (*krome-hi-DRO-sis*)
51. bullae
52. ecchymoses
53. fungi
54. comedones
55. staphylococci
56. T
57. T
58. T
59. T
60. F; hair
61. dermatolysis (*der-mah-TOL-ih-sis*)
62. onychomycosis (*on-ih-ko-my-KO-sis*)
63. trichoid (*TRIK-oyd*)
64. trichology (*tri-KOL-o-je*)
65. onycholysis (*on-ih-KOL-ih-sis*)
66. dermatoid (*DER-mah-toyd*)
67. onychopathy (*on-ih-KOP-ab-the*)
68. trichomycosis (*trik-o-mi-KO-sis*)
69. dermatopathy (*der-mah-TOP-ab-the*)
70. dermatology (*der-mah-TOL-o-je*)
71. keloid; A *keloid* is a raised, thickened scar; the others are types of skin lesions.
72. escharotomy; *Escharotomy* is removal of scab tissue; the others are types of skin diseases.
73. BSA; *BSA* is an abbreviation for body surface area; the others are abbreviations for skin diseases.
74. fungal infection of the skin
  - a. skin
  - b. plant
  - c. condition of
75. benign tumor of a sweat gland
  - a. sweat
  - b. gland
  - c. tumor
76. ingrown toenail
  - a. nail
  - b. hidden
  - c. condition of
77. lack of color or graying of the hair
  - a. lack of
  - b. color
  - c. hair
  - d. condition of

## CASE STUDY QUESTIONS

### Case Study 4-1

1. b
2. c

3. d
4. d
5. dermabrasion
6. nodule
7. dermatologist
8. subcutaneous tissue
9. full-thickness skin graft
10. sun protection factor

### Case Study 4-2

1. a
2. c
3. b
4. c
5. a
6. erythroderma
7. hyperkeratosis
8. at bedtime
9. twice per day
10. as needed

## Chapter 5

### PRETEST

1. d
2. a
3. d
4. b
5. c
6. d
7. a
8. c

## CHAPTER EXERCISES

### Exercise-5-1

1. joint
2. bone marrow
3. bone, bone tissue
4. cartilage
5. bursa
6. surgical puncture of a joint
7. formation of bone marrow
8. pain in cartilage
9. pertaining to or resembling bone
10. inflammation of a bursa
11. pertaining to synovial fluid, joint, or membrane
12. osteomyelitis (*os-te-o-mi-eh-LI-tis*)
13. osteoblast (*OS-te-o-blast*)
14. chondroid (*KON-droyd*); also chondral, cartilaginous
15. arthropathy (*ar-THROP-ab-the*)
16. synovitis (*sib-no-VI-tis*)
17. myelography (*mi-eh-LOG-rah-fe*)
18. bursotomy (*bur-SOT-o-me*)

19. myeloma (*mi-eh-LO-mah*)
20. arthroscope (*AR-thro-skope*)
21. hyperostosis (*hi-per-os-TO-sis*)
22. dysostosis (*dis-os-TO-sis*)

### Exercise 5-2

1. cranial
2. costal
3. pelvic
4. iliac
5. vertebral
6. sacral
7. incision of the cranium (skull)
8. before or in front of the spinal column or vertebra
9. pain in a vertebra
10. measurement of the pelvis
11. cranioschisis (*kra-ne-OS-kih-sis*)
12. suprapelvic (*su-prah-PEL-vik*)
13. craniosacral (*kra-ne-o-SA-kral*)
14. sacroiliac (*sa-kro-IL-e-ak*)
15. rachiocentesis (*ra-ke-o-sen-TE-sis*); also, rachicentesis (*ra-ke-sen-TE-sis*)
16. costectomy (*kos-TEK-to-me*)
17. vertebroplasty (*ver-teh-bro-PLAS-te*)
18. spondylitis (*spon-dih-LI-tis*)
19. perisacral (*per-ih-SA-kral*)
20. infracostal (*in-frah-KOS-tal*); subcostal (*sub-KOS-tal*)
21. iliococcygeal (*il-e-o-kok-SIJ-e-al*)
22. coccygectomy (*kok-sih-JEK-to-me*)

## CHAPTER REVIEW

### Labeling Exercise

#### The Skeleton

1. cranium
2. facial bones
3. mandible
4. vertebral column
5. sacrum
6. sternum
7. ribs
8. clavicle
9. scapula
10. humerus
11. radius
12. ulna
13. carpals
14. metacarpals
15. phalanges
16. pelvis
17. ilium
18. femur
19. patella

20. fibula
21. tibia
22. tarsals
23. calcaneus
24. metatarsals

#### Skull from the Left

1. frontal
2. parietal
3. occipital
4. temporal
5. sphenoid
6. lacrimal
7. nasal
8. zygomatic
9. maxilla
10. mandible
11. hyoid

#### Vertebral Column

1. cervical vertebrae
2. thoracic vertebrae
3. lumbar vertebrae
4. sacrum
5. coccyx
6. intervertebral disk
7. body of vertebra

#### The Pelvic Bones

1. ilium
2. ischium
3. pubis
4. pubic symphysis
5. acetabulum
6. sacrum

#### Structure of a Long Bone

1. proximal epiphysis (*eh-PIF-ih-sis*)
2. diaphysis (*di-AF-ih-sis*)
3. distal epiphysis
4. cartilage
5. epiphyseal line (growth line)
6. spongy bone (containing red marrow)
7. compact bone
8. medullary (marrow) cavity
9. artery and vein
10. yellow marrow
11. periosteum (*per-e-OS-te-um*)

#### Terminology

1. d
2. e
3. a
4. c
5. b
6. e
7. a

8. d
9. c
10. b
11. c
12. b
13. e
14. a
15. d
16. d
17. b
18. a
19. c
20. e
21. tendon
22. cartilage
23. orthopedics
24. sacrum
25. cartilage
26. synovial fluid; synovia
27. bursa
28. bone marrow
29. joint, joint cavity
30. vertebrae
31. spine
32. inflammation of the bone marrow
33. formation of bone tissue
34. fusion of a joint
35. excision of a synovial membrane
36. cartilage cell
37. below a rib
38. pain in the coccyx
39. inflammation of a vertebra
40. pertaining to many joints
41. within bone
42. around a bursa
43. chondrogenesis (*kon-dro-JEN-eh-sis*)
44. arthrodesis (*ar-THROD-eh-sis*)
45. pelvimetry (*pel-VIM-eh-tre*)
46. osteochondroma (*os-te-o-kon-DRO-mah*)
47. arthrostenosis (*ar-thro-steh-NO-sis*)
48. osteonecrosis (*os-te-o-neh-KRO-sis*)
49. bursolith (*BUR-so-lith*)
50. craniotomy (*kra-ne-OT-o-me*)
51. parasacral (*par-ab-SA-kral*)
52. sacroiliac (*sak-ro-IL-e-ak*)
53. coccygectomy (*kok-sih-JEK-to-me*)
54. arthroscopy (*ar-THROS-ko-pe*)
55. idiopathic
56. scapula
57. ilium
58. thorax
59. osteotomies
60. scoliosis

61. sacral
62. vertebral
63. coccygeal
64. pelvic
65. iliac
66. F; metaphysis
67. T
68. T
69. F; appendicular
70. T
71. T
72. F; red
73. F; lordosis
74. T
75. hyoid; The *hyoid* is the bone below the mandible (lower jaw); the others are bone markings.
76. lambdoid; *Lambdoid* refers to a skull suture; the others are bones of the skull.
77. cost/o; *Cost/o* refers to a rib; the others are roots pertaining to the spine.
78. sciatic; *Sciatic* refers to the sciatic nerve that travels through the leg; the others are types of bone fractures.
79. OA; OA is an abbreviation for osteoarthritis; the others are abbreviations for spinal regions.
80. arthrodynia
81. spondylolysis
82. spondylodynia
83. arthrololysis
84. osteotome
85. arthroplasty
86. osteodynia
87. arthrotome
88. osteolysis
89. osteoplasty
90. disease of the (cartilaginous) growth center in children
  - a. bone
  - b. cartilage
  - c. condition of
91. surgical fusion (ankylosis) between vertebrae
  - a. vertebra
  - b. together
  - c. fusion, binding
92. bony outgrowth from a bone
  - a. out
  - b. bone
  - c. condition of
93. decreased growth of cartilage in the growth plate of long bones resulting in dwarfism
  - a. lack of

- b. cartilage
  - c. formation, molding
  - d. condition of
94. reduction in bone density
- a. bone
  - b. pore(s)
  - c. condition of

## CASE STUDY QUESTIONS

### Case Study 5-1

1. b
2. b
3. c
4. zygomatic
5. periosteum
6. meniscus
7. arthroplasty
8. degenerative joint disease
9. normal saline
10. temporomandibular joint
11. estimated blood loss

### Case Study 5-2

1. d
2. c
3. osteogenesis
4. fracture
5. congenital
6. femur
7. osteogenesis imperfecta
8. open reduction internal fixation
9. operating room
10. intramedullary
11. postanesthesia care unit

## Chapter 6

### PRETEST

1. b
2. c
3. d
4. d
5. a
6. b
7. c
8. a

## CHAPTER EXERCISES

### Exercise 6-1

1. pertaining to muscle
2. pertaining to fascia
3. pertaining to movement
4. pertaining to a tendon
5. pertaining to tone
6. myotomy (*mi-OT-o-me*)

7. myotenositis (*mi-o-ten-o-SI-tis*)
8. kinesiology (*ki-ne-se-OL-o-je*)
9. fasciectomy (*fash-e-EK-to-me*)
10. tenalgia, tenodynia (*teh-NAL-je-ah, ten-o-DIN-e-ah*)
11. muscle
12. fibers
13. fascia
14. tone
15. work
16. movement, motion
17. muscle
18. muscle, smooth muscle
19. excess muscle tone
20. suture of fascia
21. inflammation of a tendon
22. pertaining to a muscle and tendon
23. binding or fusion of a tendon
24. pain in a muscle
25. treatment using movement
26. abnormality of movement
27. lack of muscle tone
28. producing or generating work
29. pertaining to muscle and fascia
30. inflammation of a muscle and a tendon

## CHAPTER REVIEW

### Labeling Exercise

#### Superficial Muscles, Anterior View

1. frontalis
2. temporalis
3. orbicularis oculi
4. orbicularis oris
5. masseter
6. sternocleidomastoid
7. trapezius
8. deltoid
9. pectoralis major
10. serratus anterior
11. brachialis
12. biceps brachii
13. brachioradialis
14. flexor carpi
15. extensor carpi
16. external oblique
17. internal oblique
18. rectus abdominis
19. intercostals
20. sartorius
21. adductors of thigh
22. quadriceps femoris
23. gastrocnemius
24. soleus
25. fibularis longus
26. tibialis anterior

#### Superficial Muscles, Posterior View

1. sternocleidomastoid
2. trapezius
3. deltoid
4. teres minor
5. teres major
6. latissimus dorsi
7. triceps brachii
8. gluteus medius
9. gluteus maximus
10. hamstring group
11. gastrocnemius
12. fibularis longus

### Terminology

1. a
2. c
3. b
4. d
5. e
6. b
7. c
8. d
9. e
10. a
11. e
12. b
13. c
14. a
15. d
16. c
17. e
18. d
19. b
20. a
21. e
22. c
23. d
24. a
25. b
26. b
27. e
28. a
29. c
30. d
31. tendon
32. muscle, muscle tissue
33. three
34. extensor
35. acetylcholine
36. Achilles tendon
37. adduction
38. fascia
39. arm
40. supraspinatus
41. neck
42. pertaining to muscle and fascia
43. plastic repair of a tendon

44. decreased muscle tone
45. abnormally increased movement
46. acting on (muscle) fibers
47. inflammation of muscle
48. fasciorrhaphy
49. myonecrosis
50. kinesiology
51. atony
52. tenotomy
53. myology
54. fasciectomy
55. tendinous
56. antagonist
57. insertion
58. adduction
59. supination
60. flexion
61. ataxic
62. athetotic
63. spastic, spasmodic
64. clonic
65. F; axon
66. F; voluntary
67. F; four
68. T
69. F; posterior
70. T
71. F; insertion
72. T
73. osteoblast; An *osteoblast* is a bone cell; the others are related to muscle structure.
74. soleus; The *soleus* is a calf muscle; the others are muscles of the arm.
75. intercostals; The *intercostals* are between the ribs; the others are quadriceps muscles in the anterior thigh.
76. actin; *Actin* is a type of muscle filament involved in contraction; the others are types of movement.
77. EMG; *EMG* is electromyography, a method for studying the electric energy in muscles; the others are diseases that involve muscles.
78. rest, ice, compression, elevation
79. rotator cuff
80. carpal tunnel syndrome
81. neuromuscular junction
82. electromyogram
83. fasciitis
84. tenodesis
85. tenalgia
86. myolysis
87. fasciodesis
88. myoblast
89. tenolysis
90. fascial
91. myalgia
92. nonspecific term or pain, tenderness, and stiffness in muscles and joints
  - a. fiber
  - b. muscle
  - c. inflammation
93. muscular weakness
  - a. muscle
  - b. lack of
  - c. strength
  - d. condition of
94. lack of smooth or accurate muscle movement because coordination between muscle components is lacking
  - a. abnormal
  - b. together
  - c. work
  - d. condition of
95. pertaining to muscle wasting, atrophy
  - a. lack of
  - b. muscle
  - c. nourishment
  - d. pertaining to

4. c
5. a
6. c
7. b
8. d

## CHAPTER EXERCISES

### Exercise 7-1

1. pertaining to a nerve or the nervous system
2. pertaining to neuroglia, glial cells
3. pertaining to a spinal nerve root
4. pertaining to the meninges
5. pertaining to a ganglion
6. meninges
7. nervous system, nervous tissue
8. meninges
9. spinal cord
10. surgical removal of a ganglion
11. inflammation of many spinal nerve roots
12. destruction of a nerve or nervous tissue
13. nerve pain due to irritation of the sensory nerve root
14. radiographic study of the spinal cord
15. glioma (*gli-O-mah*)
16. myelogram (*MI-eh-lo-gram*)
17. neuralgia (*nu-RAL-je-ah*)
18. myelitis (*mi-eh-LI-tis*)
19. neuropathy (*nu-ROP-ah-the*)

### Exercise 7-2

1. sleep
2. cerebrum, brain
3. thalamus
4. mind
5. stupor, unconsciousness
6. brain
7. cerebrum, brain
8. psychic (*SI-kik*)
9. cortical (*KOR-tib-kal*)
10. thalamic (*thah-LAM-ik*)
11. cerebral (*SER-eh-bral*)
12. ventricular (*ven-TRIK-u-lar*)
13. any disease of the brain
14. lack of sleep, inability to sleep
15. study of the mind
16. pertaining to the brain and spinal cord
17. outside the medulla
18. incision of a ventricle
19. ventriculogram (*ven-TRIK-u-lo-gram*)
20. corticothalamic (*kor-tib-ko-thah-LAM-ik*)

## CASE STUDY QUESTIONS

### Case Study 6-1

1. b
2. c
3. d
4. a
5. b
6. d
7. orthopedic
8. laxity
9. physical therapy
10. range of motion

### Case Study 6-2

1. b
2. d
3. c
4. c
5. d
6. flexion
7. plantar flexion
8. somatosensory evoked potentials
9. postanesthesia care unit

## Chapter 7

### PRETEST

1. b
2. a
3. d



21. intracerebellar (*in-trah-ser-eh-BEL-ar*)
22. encephalitis (*en-sef-ah-LI-tis*)
23. supracerebral (*su-prah-SER-eh-bral*)

### Exercise 7-3

1. seizures
2. read
3. speech
4. tetraplegia (*tet-rah-PLÉ-je-ah*)
5. partial paralysis, weakness
6. paralysis of the hand
7. lack of speech communication
8. inability to comprehend the written or printed word
9. obsession with fire
10. fear of women
11. partial paralysis or weakness of all four limbs
12. photophobia (*fo-to-FO-be-ah*)
13. noctiphobia (*nok-tih-FO-be-ah*); also, nyctophobia (*nik-to-FO-be-ah*)
14. hemiplegia (*hem-ih-PLÉ-je-ah*)
15. bradylalia (*brad-e-LA-le-ah*)

## CHAPTER REVIEW

### Labeling Exercise

#### Anatomic Divisions of the Nervous System

1. central nervous system
2. brain
3. spinal cord
4. peripheral nervous system
5. cranial nerves
6. spinal nerves

#### Motor Neuron

1. cell body
2. nucleus
3. dendrites
4. axon covered with myelin sheath
5. node
6. myelin
7. axon branch
8. muscle

#### External Surface of the Brain

1. sulci
2. gyri
3. frontal lobe
4. parietal lobe
5. occipital lobe
6. temporal lobe
7. pons
8. medulla oblongata

9. cerebellum
10. spinal cord

#### Spinal Cord, Lateral View

1. brain
2. brainstem
3. spinal cord
4. cervical enlargement
5. lumbar enlargement
6. cervical nerves
7. thoracic nerves
8. lumbar nerves
9. sacral nerves
10. coccygeal nerve

#### Spinal Cord, Cross-Section

1. white matter
2. gray matter
3. dorsal horn
4. ventral horn
5. central canal
6. dorsal root
7. dorsal root ganglion
8. sensory (afferent) signals
9. ventral root
10. motor (efferent) signals
11. spinal nerve

#### Reflex Pathway

1. receptor
2. sensory neuron
3. spinal cord (CNS)
4. motor neuron
5. effector

#### Terminology

1. e
2. a
3. d
4. c
5. b
6. e
7. c
8. d
9. a
10. b
11. b
12. a
13. e
14. c
15. d
16. e
17. d
18. c
19. b
20. a
21. c
22. e
23. a

24. d
25. b
26. b
27. a
28. e
29. c
30. d
31. cerebrum
32. cerebrospinal fluid (CSF)
33. neuroglia, glial cells
34. synapse
35. neuron
36. meninges
37. reflex
38. autonomic nervous system (ANS)
39. neurotransmitter
40. cerebellum
41. dura mater
42. pertaining to the cerebral cortex and thalamus
43. inflammation of many nerves
44. absence of a brain
45. partial paralysis of half the body
46. pertaining to a spinal nerve root
47. treatment of mental disorders
48. total paralysis
49. softening of the brain
50. sleep disorder
51. neurology
52. meningomyelitis
53. ganglionectomy; gangliectomy
54. neuropathy
55. ventriculostomy
56. hemiplegia
57. intracerebellar
58. dyslexia
59. hydrophobia
60. monoplegia
61. T
62. F; peripheral
63. T
64. F; white
65. T
66. F; dendrite
67. T
68. T
69. T
70. intramedullary
71. contralateral
72. preganglionic
73. bradylalia
74. sensory
75. ventral
76. efferent
77. ganglionic
78. thalamic
79. dural

80. meningeal
81. psychotic
82. ganglia
83. ventricles
84. meninges
85. emboli
86. lumbar puncture; *Lumbar puncture* is a diagnostic procedure for sampling CSF; the others are vascular disorders.
87. hematoma; *Hematoma* is a local collection of clotted blood; the others are neoplasms.
88. mania; *Mania* is a state of elation; the others are parts of the brain.
89. CNS; CNS is the central nervous system; the others are behavioral disorders.
90. myeloplegia
91. aphasia
92. hemiparesis
93. myoparesis
94. dysphasia
95. ganglioplegia
96. tetraplegia
97. myelitis
98. bradyphasia
99. hemiplegia
100. gangliitis
101. hemorrhage into the spinal cord
  - a. blood
  - b. spinal cord
  - c. condition of
102. abnormal development of the spinal cord
  - a. spinal cord
  - b. abnormal
  - c. development
  - d. condition of
103. inflammation of many nerves and nerve roots
  - a. many
  - b. nerve
  - c. spinal nerve root
  - d. inflammation of
104. disturbance of muscle coordination
  - a. abnormal, difficult
  - b. together
  - c. work
  - d. condition of
4. ischemic
5. meningitis
6. subdural hematoma
7. aphasia
8. hemiparesis
9. Glasgow Coma Scale
10. computed tomography
11. neurological intensive care unit (also means neonatal intensive care unit)
12. cerebrovascular accident
13. transient ischemic attack

### Case Study 7-2

1. d
2. b
3. lethargic
4. psychiatrist
5. neuroleptics
6. paranoia
7. antispasmodic
8. diaphoresis

## Chapter 8

### PRETEST

1. b
2. a
3. d
4. c
5. c
6. b
7. a
8. d

### CHAPTER EXERCISES

#### Exercise 8-1

1. loss of pain
2. abnormal sense of smell
3. lack of taste sensation
4. myesthesia (*mi-es-THE-ze-ah*)
5. pseudogeusia (*su-do-GU-ze-ah*)
6. thermesthesia (*ther-mes-THE-ze-ah*)
7. hyperalgesia (*hi-per-al-JE-ze-ah*)
8. dysgeusia (*dis-GU-ze-ah*)
9. anesthesia (*an-es-THE-ze-ah*)

#### Exercise 8-2

1. hearing
2. sound
3. ear
4. pertaining to the stapes
5. pertaining to the cochlea
6. pertaining to the vestibule or vestibular apparatus

7. pertaining to hearing
8. pertaining to the labyrinth (inner ear)
9. pertaining to the ear
10. otalgia (*o-TAL-je-ah*); otodynia (*o-to-DIN-e-ah*)
11. labyrinthotomy (*lab-ih-rin-THOT-o-me*)
12. salpingoscope (*sal-PING-go-skope*)
13. otoscope (*O-to-skope*)
14. endocochlear (*en-do-KOK-le-ar*); intracochlear (*in-trah-KOK-le-ar*)
15. vestibulocochlear (*ves-tib-u-lo-KOK-le-ar*)
16. audiometry (*aw-de-OM-eh-tre*)
17. tympanoplasty (*tim-PAN-o-plas-te*)
18. stapedectomy (*sta-pe-DEK-to-me*)
19. inflammation of the eardrum (tympanic membrane)
20. instrument used to measure hearing
21. any disease of the vestibule or vestibular apparatus
22. pertaining to the auditory tube and pharynx
23. procedure to surgically fix the tympanic membrane (eardrum) to the stapes

#### Exercise 8-3

1. pertaining to the nose and lacrimal apparatus
2. between the eyelids
3. surgical repair of the eyelid
4. excision of a lacrimal sac
5. blepharoplegia (*blef-ah-ro-PLÉ-je-ah*)
6. dacryolith (*DAK-re-o-lith*)
7. dacryocystitis (*dak-re-o-sis-TI-tis*)

#### Exercise 8-4

1. ophthalmologist
2. lens
3. eye
4. vision
5. lens
6. cornea
7. opt/o; eye, vision
8. ophthalm/o; eye
9. pupil/o; pupil
10. lent/i; lens
11. irid/o; iris
12. uve/o; uvea
13. phac/o; lens
14. uveoscleritis (*u-ve-o-skleh-RI-tis*)

### CASE STUDY QUESTIONS

#### Case Study 7-1

1. c
2. d
3. a

15. phacosclerosis (*fak-o-skle-RO-sis*)
16. corneal (*KOR-ne-al*)
17. retinopexy (*ret-ih-no-PEK-se*)
18. cyclitis (*si-KLI-tis*)
19. ophthalmoscope (*of-THAL-mo-sko-pe*)
20. ophthalmology (*of-thal-MOL-o-je*)
21. iridectomy (*ir-ih-DEK-to-me*)
22. iridoplegia (*ir-id-o-PLA-je-ah*)
23. pertaining to the right eye
24. pertaining to the lens
25. inflammation of the iris and ciliary body
26. pertaining to the choroid and retina
27. inflammation of the cornea
28. incision of the ciliary muscle
29. pertaining to the eye or vision
30. instrument used to incise the sclera
31. splitting of the retina

### Exercise 8-5

1. macropsia (*mah-KROP-se-ah*)
2. achromatopsia (*ah-kro-mah-TOP-se-ah*)
3. diplopia (*dip-LO-pe-ah*)
4. presbyopia (*pres-be-O-pe-ah*)
5. amblyopia (*am-ble-O-pe-ah*)
6. ametropia (*am-eh-TRO-pe-ah*)
7. heterometropia (*het-er-o-meh-TRO-pe-ah*); also, anisometropia (*an-i-so-meh-TRO-pe-ah*)

## CHAPTER REVIEW

### Labeling Exercise

#### The Ear

1. outer ear
2. pinna
3. external auditory canal
4. tympanic membrane
5. middle ear
6. malleus
7. incus
8. stapes
9. inner ear
10. semicircular canals
11. vestibule
12. cochlea
13. vestibular nerve
14. cochlear nerve
15. vestibulocochlear nerve (VIII)
16. auditory tube
17. pharynx
18. cerumen
19. temporal bone

#### The Eye

1. retina
2. choroid
3. sclera
4. ciliary body
5. suspensory ligaments
6. cornea
7. iris
8. pupil
9. lens
10. aqueous humor
11. vitreous body
12. fovea
13. optic disc
14. blood vessels
15. optic nerve

#### Terminology

1. c
2. a
3. e
4. d
5. b
6. d
7. e
8. a
9. c
10. b
11. e
12. c
13. d
14. b
15. a
16. e
17. c
18. b
19. a
20. d
21. d
22. c
23. a
24. b
25. e
26. d
27. e
28. a
29. c
30. b
31. tympanic membrane
32. sensorineural
33. stapes
34. sclera
35. refraction
36. retina
37. cornea
38. proprioception
39. specialist in the study and treatment of hearing disorders

40. instrument for measuring the eye
41. absence of a lens
42. below the sclera
43. incision of the iris
44. instrument used to examine the tympanic membrane (eardrum)
45. around the lens
46. excess flow of tears
47. loss of hearing caused by aging
48. inflammation of the cornea and iris
49. phacomalacia
50. pupillometry
51. stapedectomy
52. blepharoptosis
53. otoplasty
54. vestibulocochlear
55. retinopathy
56. analgesia
57. lacrimal
58. cyclectomy
59. salpingoscopy
60. hyperopia
61. cochlear
62. palpebral
63. choroidal
64. uveal
65. corneal
66. scleral
67. pupillary
68. hypoesthesia, hypesthesia
69. hyperalgesia
70. sc
71. myopia
72. miosis
73. exotropia
74. pseudosmia
75. myringoplasty
76. retinoscopy
77. salpingoscopy
78. anosmia
79. retinoschisis
80. myringoscopy
81. subretinal
82. retinopexy
83. keratoscopy
84. F; cochlea
85. T
86. T
87. T
88. F; taste
89. F; constrict
90. F; tympanic membrane
91. F; tears
92. smell; *Smell* is a special sense; the others are general senses.
93. pinna; The *pinna* is part of the outer ear; the others are parts of the inner ear.

94. incus; The *incus* is an ossicle of the ear; the others are structures that protect the eye.
95. presbycusis; *Presbycusis* is loss of hearing due to age; the others are disorders of the eye.
96. weakness or tiring of the eyes
  - a. lack of
  - b. strength
  - c. eye
  - d. condition of
97. condition in which a cataractous lens has been removed and replaced with a plastic lens implant
  - a. false
  - b. lens
  - c. condition of
98. a cyst-like mass containing cholesterol
  - a. bile (here, cholesterol, found in bile)
  - b. fat
  - c. tumor, neoplasm
99. a type of strabismus (squint) in which the eye deviates outward
  - a. out
  - b. turning
  - c. condition of
100. unequal refractive power in the two eyes, heterometropia
  - a. not, without
  - b. equal, same
  - c. measure
  - d. eye
  - e. condition of

## CASE STUDY QUESTIONS

### Case Study 8-1

1. c
2. b
3. d
4. b
5. suprathreshold
6. aural
7. tympanogram
8. acoustic
9. tinnitus
10. hertz
11. brainstem auditory evoked potentials

### Case Study 8-2

1. b
2. d
3. ophthalmologist
4. conjunctival peritomy
5. intraocular

6. miosis
7. subconjunctival
8. intraocular lens

## Chapter 9

### PRETEST

1. d
2. b
3. a
4. c
5. d
6. d
7. b
8. c

## CHAPTER EXERCISES

### Exercise 9-1

1. condition of underactivity of the adrenal gland
2. acting on the thyroid gland
3. excision of the pituitary gland (hypophysis)
4. study of the endocrine glands or hormones
5. tumor of the pancreatic islets
6. hyperthyroidism (*hi-per-THI-royd-izm*)
7. hypoparathyroidism (*hi-po-par-ah-THI-royd-izm*)
8. hyperadrenalism (*hi-per-ah-DRE-nal-izm*)
9. hyperadrenocorticism (*hi-per-ah-dre-no-KOR-tih-sizm*)
10. hypopituitarism (*hi-po-pih-TU-ih-tah-rizm*)
11. adrenomegaly (*ah-dre-no-MEG-ah-le*)
12. thyroidectomy (*thi-roy-DEK-to-me*)
13. adrenalopathy (*ah-dre-nah-LOP-ah-the*); also, adrenopathy (*ah-dre-NOP-ah-the*)
14. endocrinologist (*en-do-krib-NOL-o-jist*)
15. insulinitis (*in-su-LI-tis*)

## CHAPTER REVIEW

### Labeling Exercise

#### Glands of the Endocrine System

1. pineal
2. hypothalamus
3. pituitary (hypophysis)
4. thyroid
5. parathyroids

6. adrenals
7. pancreatic islets
8. ovaries
9. testes

### Terminology

1. b
2. e
3. c
4. d
5. a
6. d
7. b
8. a
9. c
10. e
11. b
12. d
13. e
14. c
15. a
16. c
17. e
18. d
19. a
20. b
21. b
22. a
23. e
24. c
25. d
26. pituitary (hypophysis)
27. thyroid
28. adrenals
29. diabetes mellitus
30. hyperglycemia
31. incision into the thyroid gland
32. condition caused by underactivity of the pituitary gland
33. acting on the hypophysis (pituitary)
34. any disease of the adrenal gland
35. enlargement of the adrenal gland
36. physician who specializes in the study and treatment of endocrine disorders
37. insuloma
38. thyrolytic
39. adrenocortical
40. thyroiditis
41. hemithyroidectomy
42. parathyroidectomy
43. hyperadrenalism
44. thyrotropic
45. thyroptosis
46. thyroopathy
47. F; ADH, antidiuretic hormone
48. T

49. F; cortex
50. F; calcium
51. F; thyroid
52. T
53. T
54. T
55. T
56. T
57. PTH; *PTH* is a parathyroid hormone from the parathyroid gland; the others are hormones produced by the anterior pituitary.
58. dwarfism; *Dwarfism* is caused by hyposecretion of growth hormone; the others are caused by hypersecretion of hormones.
59. TBG; *TBG* is a test of thyroid function; the others are abbreviations associated with diabetes mellitus.
60. spleen; The *spleen* is part of the immune system; the others are endocrine glands.
61. thyropathy
62. adrenotropic
63. thyromegaly
64. adrenal
65. adrenomegaly
66. insuloma
67. thyrolytic
68. adrenopathy
69. thyrotropic
70. insular
71. benign tumor of the pituitary gland
  - a. cranium
  - b. pharynx (the tumor arises from tissue that forms the roof of the mouth)
  - c. tumor, neoplasm
72. condition of complete underactivity of the pituitary gland
  - a. all
  - b. under, abnormally low
  - c. pituitary gland
  - d. condition of
73. usually benign tumor of the adrenal medulla or any cells that stain with chromium salts (chromaffin cells)
  - a. dark, dusky
  - b. color
  - c. cell
  - d. tumor, neoplasm
74. a toxic condition caused by hyperactivity of the thyroid gland
  - a. thyroid

- b. poisonous
  - c. condition of
75. condition marked by enlargement of the extremities
    - a. extremity
    - b. enlargement
    - c. condition of
  76. pancreas (pancreatic islets)
  77. adrenal cortex
  78. thyroid
  79. parathyroid
  80. anterior pituitary

## CASE STUDY QUESTIONS

### Case Study 9-1

1. a
2. c
3. d
4. nephrectomy
5. adenoma
6. ampule
7. hypertension
8. within normal limits

### Case Study 9-2

1. a
2. b
3. c
4. a
5. hyperglycemia
6. bolus
7. neutral protamine Hagedorn
8. continuous subcutaneous insulin infusion

## Chapter 10

### PRETEST

1. c
2. c
3. b
4. d
5. d
6. b
7. c
8. a

## CHAPTER EXERCISES

### Exercise 10-1

1. valve
2. atrium
3. ventricles
4. heart
5. atrial (*A-tre-al*)
6. myocardial (*mi-o-KAR-de-al*)
7. cardiac (*KAR-de-ak*)

8. valvular (*VAL-vu-lar*); also valvar (*VAL-var*)
9. ventricular (*ven-TRIK-u-lar*)
10. pericardial (*per-ih-KAR-de-al*)
11. pericarditis (*per-ih-kar-DI-tis*)
12. endocarditis (*en-do-kar-DI-tis*)
13. myocarditis (*mi-o-kar-DI-tis*)
14. cardiogenic (*kar-de-o-JEN-ik*)
15. valvotomy (*val-VOT-o-me*); also, valvulotomy (*val-vu-LOT-o-me*)
16. atrioventricular (*a-tre-o-ven-TRIK-u-lar*)
17. interatrial (*in-ter-A-tre-al*)
18. cardiology (*kar-de-OL-o-je*)

### Exercise 10-2

1. vessels
2. vessel
3. aorta
4. artery
5. arteriole
6. vein
7. vessels
8. rupture of an artery
9. within the aorta
10. inflammation of a vessel or vessels
11. inflammation of a vein
12. pertaining to the heart and vessels
13. angiogram
14. aortogram
15. phlebogram; venogram
16. angioplasty (*AN-je-o-plas-te*)
17. angiopathy (*an-je-OP-ab-the*)
18. angiectasis (*an-je-EK-tab-sis*); also, hemangiectasis (*he-man-je-EK-tab-sis*)
19. angiogenesis (*an-je-o-JEN-eh-sis*)
20. phlebectomy (*fleh-BEK-to-me*); venectomy (*ve-NEK-to-me*)
21. aortosclerosis (*a-or-to-skleh-RO-sis*)
22. intravenous (*in-trah-VE-nus*)
23. arteriotomy (*ar-tere-e-OT-o-me*)

### Exercise 10-3

1. tonsil
2. thymus
3. lymph node
4. lymph
5. lymphatic vessels
6. spleen
7. lymphangi/o; lymphatic vessel
8. splen/o; spleen
9. lymphaden/o; lymph node
10. tonsill/o; tonsil
11. thym/o; thymus
12. splenomegaly (*sple-no-MEG-ab-le*)
13. tonsillitis (*ton-sih-LI-tis*)

14. lymphadenopathy (*lim-fad-eh-NOP-ab-the*)
15. lymphangitis (*lim-fan-JI-tis*); also, lymphangiitis (*lim-fan-je-I-tis*)
16. thymic (*THI-mik*)
17. lymphoma (*lim-FO-mah*)

## CHAPTER REVIEW

### Labeling Exercise

#### The Cardiovascular System

1. right atrium
2. right ventricle
3. left pulmonary artery
4. left lung
5. right lung
6. left pulmonary vein
7. left atrium
8. left ventricle
9. aorta
10. head and arms
11. superior vena cava
12. internal organs
13. legs
14. inferior vena cava

#### The Heart and Great Vessels

1. superior vena cava
2. inferior vena cava
3. right atrium
4. right atrioventricular (tricuspid) valve
5. right ventricle
6. pulmonary valve
7. pulmonary trunk
8. right pulmonary artery
9. left pulmonary artery
10. left pulmonary veins
11. left atrium
12. left atrioventricular (bicuspid) valve
13. left ventricle
14. aortic valve
15. ascending aorta
16. aortic arch
17. apex
18. interventricular septum
19. endocardium
20. myocardium
21. epicardium

#### Location of Lymphoid Organs and Tissue

1. tonsils
2. thymus
3. spleen
4. Peyer patches
5. appendix

### Terminology

1. e
2. a
3. b
4. d
5. c
6. b
7. c
8. e
9. a
10. d
11. d
12. b
13. e
14. a
15. c
16. b
17. d
18. c
19. a
20. e
21. b
22. e
23. d
24. a
25. c
26. myocardium
27. capillary
28. atrium
29. sinoatrial (SA) node
30. aorta
31. vein
32. varicose vein, varix
33. thymus
34. right atrium
35. common iliac (*IL-e-ak*) arteries
36. common carotid (*kab-ROT-id*) artery
37. inferior vena cava
38. subclavian veins
39. Holter monitor
40. atrial fibrillation
41. ablation
42. F; mitral (bicuspid)
43. F; heart
44. F; arm
45. T
46. T
47. T
48. F; pulmonary circuit
49. F; vein
50. T
51. T
52. T
53. apex; The *apex* is the pointed lower region of the heart; the others are part of the heart's conduction system.
54. murmur; A *murmur* is an abnormal heart sound; the others are terms associated with blood pressure.
55. S<sub>1</sub>; S<sub>1</sub> symbolizes the first heart sound; the others are waves of the ECG.
56. cusp; A *cusp* is a flap of a heart valve; the others are lymphoid tissue.
57. without vessels
58. incision of an atrium
59. surgical removal of the spleen
60. above a ventricle
61. dilatation of a vein
62. valvotome; valvulotome (*VAL-vo-tome*; *VAL-vu-lo-tome*)
63. aortorrhaphy (*a-or-TOR-ab-fe*)
64. lymphadenectomy (*lim-fad-eh-NEK-to-me*)
65. cardiologist (*kar-de-OL-o-jist*)
66. lymphostasis (*lim-FOS-tah-sis*)
67. splenopexy (*SPL-no-pek-se*)
68. aortostenosis (*a-or-to-steh-NO-sis*)
69. aortoptosis (*a-or-top-TO-sis*)
70. aortogram (*a-OR-to-gram*)
71. preaortic (*pre-a-OR-tik*)
72. ventricular
73. septal
74. valvular, valvar
75. thymic
76. sclerotic
77. splenic; splenetic
78. thrombi
79. varices
80. stenoses
81. septa
82. automated external defibrillator
83. left ventricular assist device
84. deep vein thrombosis
85. ventricular fibrillation
86. bundle branch block
87. percutaneous transluminal coronary angioplasty
88. phlebitis
89. lymphadenopathy
90. lymphoma
91. angioplasty
92. lymphangiitis; lymphangitis
93. angiopathy
94. lymphadenitis
95. phleboplasty
96. lymphadenoma
97. angioma
98. recording of the heart's sounds
  - a. sound
  - b. heart
  - c. act of recording

99. excision of the inner layer of an artery thickened by atherosclerosis
  - a. within
  - b. artery
  - c. out
  - d. to cut
100. permanent dilation of small blood vessels causing small, local red lesions
  - a. end
  - b. vessel
  - c. dilation
101. inflammation of lymphatic vessels and veins
  - a. lymphatic system
  - b. vessel
  - c. vein
  - d. inflammation

## CASE STUDY QUESTIONS

### Case Studies 10-1A and 10-1B

1. d
2. b
3. c
4. d
5. a
6. c
7. a
8. dyspnea
9. murmur
10. stress test
11. cardiovascular
12. endarterectomies
13. sublingual
14. cyanosis
15. diaphoresis
16. interatrial
17. substernal
18. electrocardiogram
19. acute myocardial infarction
20. coronary artery disease
21. left anterior descending
22. congestive heart failure
23. transesophageal echocardiogram
24. mitral valve replacement
25. coronary/cardiac care unit

## Chapter 11

### PRETEST

1. c
2. d
3. b
4. b
5. c
6. a

## CHAPTER EXERCISES

### Exercise 11-1

1. a decreased number of platelets in the blood
2. presence of bacteria in the blood
3. deficiency of leukocytes (white blood cells)
4. production of erythrocytes (red blood cells)
5. presence of toxins (poisons) in the blood
6. decreased protein in the blood
7. excess albumin in the blood
8. viremia (*vi-RE-me-ah*)
9. leukemia (*lu-KE-me-ah*)
10. pyemia (*pi-E-me-ah*)

### Exercise 11-2

1. leuk/o; leukocytes; white blood cells
2. hem/o; blood
3. immun/o; immunity
4. hemat/o; blood
5. thromb/o; blood clot
6. myel/o; bone marrow
7. lymphocytes
8. blood
9. blood
10. bone marrow
11. erythrocytes; red blood cells
12. immunity
13. platelets; thrombocytes
14. leukocytes; white blood cells
15. leukopenia (*lu-ko-PE-ne-ah*)
16. myeloma (*mi-eh-LO-mah*)
17. lymphoblast (*LIM-fo-blast*)
18. thrombolysis (*throm-BOL-ih-sis*)
19. myelopoiesis (*mi-eh-lo-poy-E-sis*)
20. granulocytosis (*gran-u-lo-si-TO-sis*)
21. lymphocytosis (*lim-fo-si-TO-sis*)
22. erythrocytosis (*eh-rith-ro-si-TO-sis*)
23. monocytosis (*mon-o-si-TO-sis*)
24. thrombocytosis (*throm-bo-si-TO-sis*)

### Exercise 11-3

1. iron
2. potassium
3. nitrogenous compounds
4. oxygen
5. iron
6. calcium
7. natremia (*na-TRE-me-ah*)
8. azotemia (*az-o-TE-me-ah*)
9. kalemia (*kab-LE-me-ah*)
10. calcemia (*kal-SE-me-ah*)

## CHAPTER REVIEW

### Labeling Exercise

#### Blood Cells

1. platelet
2. leukocyte
3. erythrocyte

#### Leukocytes (White Blood Cells)

1. neutrophil
2. eosinophil
3. basophil
4. lymphocyte
5. monocyte

### Terminology

1. c
2. d
3. e
4. b
5. a
6. b
7. c
8. e
9. a
10. d
11. d
12. c
13. a
14. b
15. e
16. e
17. d
18. b
19. c
20. a
21. b
22. c
23. a
24. e
25. d
26. phagocytosis
27. hemoglobin
28. electrolyte
29. platelets (thrombocytes)
30. blood cells
31. oxygen
32. blood
33. anemia
34. bone marrow
35. immunoglobulin
36. c
37. a
38. c
39. b
40. b
41. F; white blood cell

42. T  
 43. T  
 44. T  
 45. F; neutrophil  
 46. T  
 47. increase in leukocytes (white blood cells) in the blood  
 48. increase in eosinophils in the blood  
 49. increase in erythrocytes (red blood cells) in the blood  
 50. increase in thrombocytes (platelets) in the blood  
 51. increase in neutrophils in the blood  
 52. increase in monocytes in the blood  
 53. erythroblast; erythrocytoblast  
 54. thrombocytopenia; thrombopenia  
 55. pyemia  
 56. immunologist  
 57. hemorrhage  
 58. destruction of red blood cells  
 59. deficiency of neutrophils  
 60. substance that is toxic (poisonous) to bone marrow  
 61. immunity to one's own tissue  
 62. presence of viruses in the blood  
 63. hemolytic (*he-mo-LIT-ik*)  
 64. leukemic (*lu-KE-mik*)  
 65. basophilic (*ba-so-FIL-ik*)  
 66. septicemic (*sep-tib-SE-mik*)  
 67. thrombotic (*throm-BOT-ik*)  
 68. lymphocytic (*lim-fo-SIT-ik*)  
 69. thrombolysis; *Thrombolysis* is destruction of a blood clot; the others pertain to formation of a blood clot.  
 70. EPO; *EPO* is erythropoietin, a hormone that stimulates red cell production in the bone marrow; the others are abbreviations for blood tests.  
 71. reticulocyte; *A reticulocyte* is an immature red blood cell; the others are types of leukocytes.  
 72. gamma globulin; *Gamma globulin* is the fraction of the blood plasma that contains antibodies; the others are terms associated with exaggerated immune responses.  
 73. erythrocytic  
 74. leukoblast  
 75. myeloid  
 76. myelogenic  
 77. myeloblast  
 78. leukemia  
 79. leukopenia; leukocytopenia  
 80. myeloma  
 81. erythropoiesis; erythrocytopoiesis  
 82. myelocytic  
 83. overall decrease in blood cells  
 a. all  
 b. cell  
 c. deficiency  
 84. increase in the number of red cells in the blood; erythremia, erythrocythemia  
 a. many  
 b. cell  
 c. blood  
 d. condition of  
 85. unequal distribution of hemoglobin in red cells  
 a. without  
 b. same, equal  
 c. color  
 d. condition of  
 86. pertaining to dysfunctional bone marrow  
 a. bone marrow  
 b. abnormal  
 c. formation  
 d. condition of

## CASE STUDY QUESTIONS

### Case Study 11-1

- d
- d
- c
- a
- c
- d
- prothrombin time
- partial thromboplastin time
- fresh frozen plasma
- disseminated intravascular coagulation

### Case Study 11-2

- b
- b
- c
- d
- d
- b
- a
- hemoglobin
- hematocrit
- red blood cell

## Chapter 12

### PRETEST

- c
- b
- d

- a
- d
- c
- c
- b

## CHAPTER EXERCISES

### Exercise 12-1

- orthopnea (*or-THOP-ne-ab*)
- bradypnea (*brad-ip-NE-ab*)
- eupnea (*upe-NE-ab*)
- dyspnea (*disp-NE-ab*)
- orthopneic (*or-THOP-NE-ik*)
- bradypneic (*brad-ip-NE-ik*)
- eupneic (*upe-NE-ik*)
- dyspneic (*disp-NE-ik*)
- dysphonia (*dis-FO-ne-ab*)
- hypocapnia (*hi-po-KAP-ne-ab*)
- anoxia (*an-OK-se-ab*)
- hypercapnia (*hi-per-KAP-ne-ab*)

### Exercise 12-2

- rhinorrhea (*ri-no-RE-ab*)
- laryngeal (*lah-RIN-je-al*)
- bronchitis (*brong-KI-tis*)
- pharyngoscopy (*far-ing-GOS-ko-pe*)
- laryngoplasty (*lah-RING-go-plas-te*)
- tracheotomy (*tra-ke-OT-o-me*)
- tracheostenosis (*tra-ke-o-steh-NO-sis*)
- bronchiolitis (*brong-ke-o-LI-tis*)
- pertaining to the bronchioles
- near the nose
- around a bronchus
- within the trachea
- pertaining to the nose and pharynx
- dilatation of a bronchus

### Exercise 12-3

- pain in the pleura
- within the lungs
- surgical removal of a lung or lung tissue
- plastic repair of a lung
- study of the lungs
- absence of a lung
- surgical incision of the phrenic nerve
- intrapleural (*in-trah-PLU-ral*)
- supraphrenic (*su-prah-FREN-ik*)
- pleurocentesis (*plu-ro-sen-TE-sis*)
- pneumonopathy (*nu-mo-NOP-ab-the*)



12. phrenictripty (fren-ib-ko-TRIP-se)
13. spirogram (SPI-ro-gram)

## CHAPTER REVIEW

### Labeling Exercise

#### The Respiratory System

1. frontal sinus
2. sphenoidal sinus
3. nasal cavity
4. oral cavity
5. nasopharynx
6. oropharynx
7. laryngopharynx
8. pharynx
9. epiglottis
10. larynx
11. esophagus
12. trachea
13. right bronchus
14. left bronchus
15. bronchioles
16. right lung
17. left lung
18. mediastinum
19. diaphragm
20. terminal bronchiole
21. smooth muscle
22. alveolar duct
23. alveoli
24. capillaries

### Terminology

1. e
2. a
3. b
4. c
5. d
6. b
7. a
8. e
9. c
10. d
11. d
12. a
13. c
14. e
15. b
16. b
17. c
18. a
19. d
20. e
21. b
22. a
23. e
24. d

25. c
26. bronchus
27. diaphragm
28. carbon dioxide
29. pleura
30. alveoli
31. smell, olfaction
32. lungs
33. tuberculosis
34. spirometer
35. vital capacity
36. pleural cavity
37. coughing
38. mucus
39. apnea
40. bronchodilator
41. T
42. F; inhalation
43. F; larynx
44. T
45. T
46. T
47. phrenicotomy (fren-ib-KOT-o-me)
48. hypopnea (hi-POP-ne-ah)
49. pharyngitis (far-in-JI-tis)
50. bronchiolitis (brong-ke-o-LI-tis)
51. tracheostomy (tra-ke-OS-to-me)
52. accumulation of air or gas in the pleural space
53. accumulation of fluid in the pleural space
54. accumulation of pus in the pleural space
55. accumulation of blood in the pleural space
56. narrowing of the trachea
57. spitting of blood
58. deficiency of oxygen in the tissues
59. any disease of the lungs
60. rapid rate of respiration
61. dilatation of a bronchus
62. plastic repair of the nose
63. pain in the pleura
64. rhin/o; nose
65. pulmon/o; lung
66. spir/o; breathing
67. phrenic/o; phrenic nerve
68. pneum/o; pertaining to air or gas
69. tachypnea
70. hypercapnia
71. inspiration
72. intrapulmonary
73. intubation
74. laryngeal
75. alveolar
76. nasal
77. tracheal
78. pleural
79. bronchial
80. nares
81. pleurae
82. alveoli
83. conchae
84. bronchi
85. tonsil; A *tonsil* is lymphatic tissue in the pharynx; the others are parts of the nose.
86. sinus; A *sinus* is a cavity or channel; the others are parts of the larynx.
87. asthma; *Asthma* is a chronic breathing problem caused by allergy and other factors; the others are infectious diseases.
88. URI; *URI* is an abbreviation for upper respiratory infection; the others are abbreviations for lobes of the lung.
89. RDS; *RDS* is respiratory distress syndrome; the others are breathing volumes or capacities.
90. aphonia
91. hypercapnia
92. dysphonia
93. hyperpnea
94. oximetry
95. dyspnea
96. hypoxia
97. eupnea
98. tachypnea
99. hyperphonia
100. device for measuring air flow
  - a. air
  - b. rapid, swift
  - c. measure
101. incomplete expansion of the alveoli
  - a. incomplete
  - b. expansion, dilation
102. presence of air or gas in a blood vessel of the heart
  - a. air, gas
  - b. heart
  - c. condition of
103. respiratory disease caused by inhalation of dust particles
  - a. lung
  - b. dust
  - c. condition of

## CASE STUDY QUESTIONS

### Case Study 12-1

1. c
2. d

3. lobectomy
4. diaphoresis
5. thoracotomy
6. thoracoscopy
7. hemithorax
8. mediastinoscopy

### Case Study 12-2

1. b
2. d
3. d
4. chronic obstructive pulmonary disease
5. arterial blood gas
6. acute respiratory distress syndrome
7. do not resuscitate

## Chapter 13

### PRETEST

1. a
2. c
3. c
4. b
5. b
6. d
7. c
8. a

### CHAPTER EXERCISES

#### Exercise 13-1

1. gingival (*JIN-jih-val*)
2. lingual (*LING-gwal*); glossal (*GLOS-sal*)
3. dental (*DEN-tal*)
4. buccal (*BUK-al*)
5. labial (*LA-be-al*)
6. oral (*OR-al*); stomal (*STO-mal*)
7. teeth
8. jaw
9. teeth
10. mouth
11. mouth
12. tongue
13. salivary
14. pertaining to the cheek and pharynx
15. plastic repair or reconstruction of the gingiva
16. under the tongue
17. pertaining to the lip and teeth
18. dropping of the uvula
19. under the tongue
20. suture of the palate

#### Exercise 13-2

1. pyloric (*pi-LOR-ik*)
2. colic (*KOL-ik*); also colonic (*ko-LON-ik*)
3. gastric (*GAS-trik*)
4. enteric (*en-TER-ik*)
5. rectal (*REK-tal*)
6. jejunal (*jeh-JUN-al*)
7. ileal (*IL-e-al*)
8. cecal (*SE-kal*)
9. anal (*A-nal*)
10. gastroduodenal (*gas-tro-du-o-DE-nal*)
11. esophagitis (*e-sof-ah-JI-tis*)
12. enterostomy (*en-ter-OS-to-me*)
13. gastroenterology (*gas-tro-en-ter-OL-o-je*)
14. gastroscopy (*gas-TROS-ko-pe*)
15. pyloroptosis (*pi-lor-o-TO-sis*)
16. jejunoileitis (*jeh-ju-no-il-e-I-tis*)
17. ileectomy (*il-e-EK-to-me*)
18. anorectal (*a-no-REK-tal*)
19. colitis (*ko-LI-tis*)
20. colostomy (*ko-LOS-to-me*)
21. colopexy (*KO-lo-pek-se*)
22. colocentesis (*ko-lo-sen-TE-sis*)
23. colonopathy (*ko-lo-NOP-ah-the*)
24. colonoscopy (*ko-lon-OS-ko-pe*)
25. esophagogastrostomy (*e-sof-ah-go-gas-TROS-to-me*)
26. gastroenterostomy (*gas-tro-en-ter-OS-to-me*)
27. jejunojejunostomy (*jeh-ju-no-jeh-ju-NOS-to-me*)
28. duodenoileostomy (*du-o-de-no-il-e-OS-to-me*)
29. sigmoidoproctostomy (*sig-moy-do-prok-TOS-to-me*)

#### Exercise 13-3

1. hepatic (*beh-PAT-ik*)
2. cholecystic (*ko-le-SIS-tik*)
3. pancreatic (*pan-kre-AT-ik*)
4. hepatography (*hep-ab-TOG-rah-fe*)
5. cholecystography (*ko-le-sis-TOG-rah-fe*)
6. cholangiography (*ko-lan-je-OG-rah-fe*)
7. pancreatography (*pan-kre-ab-TOG-rah-fe*)
8. choledocholithiasis (*ko-led-o-ko-lib-THI-ab-sis*)
9. pancreatolithiasis (*pan-kre-ab-to-lib-THI-ab-sis*)
10. hepatitis (*hep-ab-TI-tis*)
11. bile
12. gallstone; biliary calculus

13. common bile duct
14. gallbladder
15. liver
16. bile duct
17. pancreas

### CHAPTER REVIEW

#### Labeling Exercise

##### The Digestive System

1. mouth
2. tongue
3. teeth
4. salivary glands
5. pharynx
6. esophagus
7. stomach
8. duodenum (of small intestine)
9. small intestine
10. appendix
11. cecum
12. ascending colon
13. transverse colon
14. descending colon
15. sigmoid colon
16. rectum
17. anus
18. liver
19. gallbladder
20. pancreas

##### Accessory Organs of Digestion

1. liver
2. common hepatic duct
3. gallbladder
4. cystic duct
5. common bile duct
6. pancreas
7. pancreatic duct
8. duodenum
9. diaphragm

#### Terminology

1. d
2. c
3. b
4. e
5. a
6. c
7. a
8. d
9. b
10. e
11. b
12. c
13. d
14. e
15. a

16. c
17. a
18. d
19. e
20. b
21. d
22. b
23. a
24. c
25. e
26. c
27. a
28. e
29. b
30. d
31. bariatric surgery
32. cecum
33. liver
34. gallbladder
35. peritoneum
36. tongue
37. palate
38. tooth
39. cheek
40. intestine
41. liver
42. bile
43. hiatal hernia
44. dysphagia
45. stomach acid
46. hepatomegaly
47. periodontist
48. gastrectomy
49. palatorrhaphy
50. pylorostenosis
51. pancreatitis
52. gastroenterologist
53. colostomy
54. gastroduodenostomy
55. intrahepatic
56. diverticula
57. gingivae
58. calculi
59. anastomoses
60. hiatal hernia
61. dyspepsia
62. inguinal hernia
63. icterus
64. pyloric stenosis
65. diarrhea
66. F; above
67. F; jejunum
68. F; saliva
69. T
70. T
71. T
72. F; vomiting
73. T

74. villus; A *villus* is a tiny projection in the lining of the small intestine that aids in absorption of nutrients; the others are parts of the mouth.
75. spleen; The *spleen* is a lymphoid organ; the others are parts of the large intestine.
76. pylorus; The *pylorus* is the distal portion of the stomach; the others are accessory digestive organs.
77. amylase; *Amylase* is a starch-digesting enzyme; the others are disorders of the digestive tract.
78. nausea and vomiting
79. nasogastric
80. total parenteral nutrition
81. gastroesophageal reflux disease
82. esophagogastroduodenoscopy
83. gastrointestinal
84. hydrochloric acid
85. proton pump inhibitor
86. percutaneous endoscopic gastrostomy (tube)
87. hepatitis A virus
88. cecitis
89. proctorrhaphy
90. cecopexy
91. proctocele
92. ileocecal
93. ileopexy
94. proctitis
95. cecorrhaphy
96. ileitis
97. pertaining to the muscular layer of the intestine
  - a. muscle
  - b. intestine
  - c. pertaining to
98. radiography of the biliary tract and gallbladder using radionuclides
  - a. bile
  - b. spark (radiation)
  - c. act of recording data
99. referring to any route other than the alimentary canal
  - a. beside
  - b. intestine
  - c. pertaining to
100. pertaining to the nose and stomach
  - a. nose
  - b. stomach
  - c. pertaining to
101. pertaining to a dry mouth
  - a. dry

- b. mouth
- c. pertaining to

## CASE STUDY QUESTIONS

### Case Study 13-1

1. c
2. b
3. b
4. a
5. d
6. a
7. endoscopic retrograde cholangiopancreatography
8. right upper quadrant
9. nasogastric
10. cholelithiasis
11. laparoscopic cholecystectomy
12. cholecystitis
13. cholangiogram

### Case Study 13-2

1. b
2. b
3. b
4. d
5. a
6. d
7. b
8. inflammatory bowel disease
9. barium enema
10. irritable bowel syndrome
11. anal sphincter
12. biopsy
13. dysphagia

## Chapter 14

### PRETEST

1. d
2. c
3. c
4. a
5. c
6. d
7. d
8. b

## CHAPTER EXERCISES

### Exercise 14-1

1. prerenal (*pre-RE-nal*)
2. postrenal (*post-RE-nal*)
3. suprarenal (*su-prah-RE-nal*)
4. perirenal (*per-ih-RE-nal*); circumrenal (*sir-kum-RE-nal*)
5. nephrologist (*neh-FROL-o-jist*)

6. nephropathy (*neh-FROP-ah-the*)
7. nephrotoxic (*neh-ro-TOK-sik*)
8. nephromalacia (*neh-ro-mah-LAshe-ab*)
9. nephromegaly (*neh-fro-MEG-ah-le*)
10. nephrotomy (*neh-FROT-o-me*)
11. pyelonephritis (*pi-eh-lo-neh-RI-tis*)
12. pyeloplasty (*pi-eh-lo-PLAS-te*)
13. pyelogram (*PI-eh-lo-gram*)
14. glomerulitis (*glo-mer-u-LI-tis*)
15. calicotomy (*kal-ih-KOT-o-me*); caliotomy (*ka-le-OT-o-me*)
16. glomerulosclerosis (*glo-mer-u-lo-skleh-RO-sis*)
17. caliectasis (*ka-le-EK-tab-sis*); calicectasis (*kal-ih-SEK-tab-sis*)

### Exercise 14-2

1. uropathy (*u-ROP-ah-the*)
2. urography (*u-ROG-rah-fe*)
3. urolith (*U-ro-lith*)
4. uremia (*u-RE-me-ah*)
5. anuria (*an-U-re-ah*)
6. pyuria (*pi-U-re-ah*)
7. nocturia (*nokt-U-re-ah*)
8. dysuria (*dis-U-re-ah*)
9. hematuria (*he-mah-TU-re-ah*)
10. diuresis (*di-u-RE-sis*)
11. anuresis (*an-u-RE-sis*)
12. natriuresis (*na-tre-u-RE-sis*)
13. kaliuresis (*ka-le-u-RE-sis*)
14. urethropexy (*u-RE-thro-pek-se*)
15. ureterostomy (*u-re-ter-OS-to-me*)
16. urethrorrhaphy (*u-re-THROR-ah-fe*)
17. urethroscopy (*u-re-THROS-ko-pe*)
18. ureterocele (*u-RE-ter-o-sele*)
19. cystitis (*sis-TI-tis*)
20. cystography (*sis-TOG-rah-fe*)
21. cystoscopy (*SIS-to-skope*)
22. cystotomy (*sis-TOT-o-me*)
23. cystorrhoea (*sis-to-RE-ah*)
24. supravescical (*su-prah-VES-ih-kal*)
25. urethrovesical (*u-re-thro-VES-ih-kal*)
26. pain in the urinary bladder
27. surgical incision of the ureter
28. through the urethra
29. formation of urine

## CHAPTER REVIEW

### Labeling Exercise

#### The Urinary System

1. kidney
2. ureter

3. urinary bladder
4. urethra
5. aorta
6. renal artery
7. renal vein
8. inferior vena cava
9. diaphragm
10. adrenal gland

#### Kidney

1. renal capsule
2. renal cortex
3. renal medulla
4. pyramids of medulla
5. nephrons
6. calyx
7. hilum
8. renal pelvis
9. ureter

#### Urinary Bladder

1. ureter
2. smooth muscle
3. openings of ureters
4. trigone
5. urethra
6. internal urethral sphincter
7. external urethral sphincter
8. peritoneum
9. prostate

#### Terminology

1. a
2. c
3. d
4. b
5. e
6. d
7. e
8. b
9. a
10. c
11. d
12. b
13. e
14. a
15. c
16. a
17. b
18. c
19. e
20. d
21. hydronephrosis
22. glomerulus
23. renin
24. urination; voiding of urine
25. urinalysis
26. urea

27. incontinence; stress incontinence
28. clean-catch specimen
29. cystoscopy
30. F; kidney
31. T
32. T
33. F; medulla
34. F; urethra
35. T
36. T
37. F; sodium
38. narrowing of the urethra
39. elimination of large amounts of urine
40. toxic or poisonous to the kidney
41. near the glomerulus
42. surgical removal of a calyx
43. near the kidney
44. nephrologist
45. pyelocaliectasis; pyelocalicectasis
46. nephromalacia
47. cystectomy
48. nephropathy
49. cystourethrogram
50. ureteropyeloplasty
51. pyelonephritis
52. ureterosigmoidostomy
53. cast; A *cast* is a solid mold of a renal nephron; the others are parts of the kidney.
54. calyx; A *calyx* is a collecting region for urine in the kidney; the others are parts of a nephron.
55. specific gravity; *Specific gravity* is a measure of density; the others are treatment procedures for the urinary system.
56. hydration
57. hypervolemia
58. antidiuretic
59. hypernatremia
60. anuresis
61. ureteral
62. nephrologic
63. uremic
64. diuretic
65. nephrotic
66. caliceal; calyceal
67. urethral
68. pelvis
69. calyces
70. glomeruli
71. b
72. d
73. f
74. c
75. a
76. e

77. g
78. urography
79. renal
80. intrarenal
81. renography
82. intravesical
83. suprarenal
84. urology
85. interrenal
86. vesical
87. urolith
88. specific gravity
89. antidiuretic hormone
90. erythropoietin
91. intravenous pyelography
92. sodium
93. glomerular filtration rate
94. urinalysis
95. removal of substances from the blood by passage through a semipermeable membrane
  - a. blood
  - b. through
  - c. separation
96. test that measures and records bladder function
  - a. urinary bladder
  - b. measure
  - c. act of recording data
97. surgical creation of a new passage between a ureter and the bladder
  - a. ureter
  - b. new
  - c. bladder
  - d. surgical creation of an opening

## CASE STUDY QUESTIONS

### Case Study 14-1

1. c
2. d
3. IV urogram
4. hematuria
5. cystoscopic
6. nephrolithotomy
7. nocturia
8. lithotripsy

### Case Study 14-2

1. d
2. a
3. oliguria
4. kidney transplantation
5. continuous ambulatory peritoneal dialysis
6. blood urea nitrogen
7. end-stage renal disease
8. human immunodeficiency virus

## Chapter 15

### PRETEST

1. c
2. d
3. a
4. b
5. b
6. d

### CHAPTER EXERCISES

#### Exercise 15-1

1. formation (-genesis) of spermatozoa
2. pain in the prostate
3. plastic repair of the scrotum
4. excision of the epididymis
5. pain in the testis
6. any disease of a testis
7. inflammation of the testis and epididymis
8. orchiopexy (*or-ke-o-PEK-se*); also, orchidopexy (*or-kih-do-PEK-se*)
9. orchioplasty (*OR-ke-o-plas-te*); also, orchidoplasty (*OR-kih-do-plas-te*)
10. orchiectomy (*or-ke-EK-to-me*); also, orchidectomy (*or-kih-DEK-to-me*)
11. spermaturia (*sper-mah-TU-re-ah*)
12. spermatolysis (*sper-mah-TOL-ih-sis*)
13. spermatorrhea (*sper-mah-to-RE-ah*)
14. oligospermia (*ol-ih-go-SPER-me-ah*)
15. spermatocyte (*sper-MAH-to-site*)
16. hemospermia (*he-mo-SPER-me-ah*); also, hematospermia (*he-mah-to-SPER-me-ah*)
17. aspermia (*ab-SPER-me-ah*)
18. polyspermia (*pol-e-SPER-me-ah*)
19. pyospermia (*pi-o-SPER-me-ah*)
20. vasectomy (*vah-SEK-to-me*)
21. oscheoma (*os-ke-O-mah*)
22. vasorrhaphy (*vas-OR-ah-fe*)
23. prostatectomy (*pros-tah-TEK-to-me*)
24. vesiculography (*veh-sik-u-LOG-rah-fe*)
25. vesiculitis (*veh-sik-u-LI-tis*)
26. epididymotomy (*ep-ih-did-ih-MOT-o-me*)

## CHAPTER REVIEW

### Labeling Exercise

#### Male Reproductive System

1. scrotum
2. testis
3. epididymis
4. ductus (vas) deferens
5. ejaculatory duct
6. urethra
7. penis
8. glans penis
9. prepuce (foreskin)
10. seminal vesicle
11. prostate
12. bulbourethral gland
13. ureter
14. urinary bladder
15. pubic bone
16. rectum
17. anus

### Terminology

1. a
2. c
3. e
4. b
5. d
6. a
7. c
8. b
9. d
10. e
11. b
12. e
13. d
14. a
15. c
16. e
17. a
18. d
19. c
20. b
21. testosterone
22. bulbourethral glands
23. semen
24. testis
25. inguinal canal
26. scrotum
27. suture of the vas (ductus) deferens
28. absence of a testis
29. tumor of the scrotum
30. radiographic study of the seminal vesicles
31. instrument for measuring the prostate
32. presence of blood in the semen
33. orchiopexy; orchidopexy

34. oscheolith
35. epididymotomy
36. oscheoplasty
37. vasovasostomy
38. hematuria
39. dysuria
40. intravesical
41. hyperplasia
42. resectoscope
43. T
44. F; semen
45. T
46. T
47. F; urethra
48. T
49. T
50. spermatic cord; The *spermatic cord* suspends the testis in the scrotum and contains the ductus deferens, nerves, and vessels; the others are the glands that contribute to semen.
51. semen; *Semen* is the secretion that transports spermatozoa; the others are hormones active in reproduction.
52. hernia; A *hernia* is a protrusion of tissue through an abnormal body opening; the others are sexually transmitted infections.
53. seminal
54. prostatic
55. penile
56. urethral
57. scrotal
58. benign prostatic hyperplasia
59. sexually transmitted infection
60. erectile dysfunction
61. gonococcus
62. prostate-specific antigen
63. genitourinary
64. transurethral resection of prostate
65. d
66. e
67. c
68. b
69. a
70. f
71. vasoplasty
72. spermatolysis
73. vesicular
74. vasography
75. vesiculitis
76. spermatic
77. spermatocyte
78. vasotomy
79. spermatogenesis
80. vesiculography
81. removal of a hydrocele by fluid drainage or partial excision
  - a. fluid, water
  - b. hernia, localized dilatation
  - c. out
  - d. cut
  - e. condition of
82. destructive to sperm cells
  - a. sperm
  - b. agent that kills
  - c. pertaining to
83. undescended testis
  - a. hidden
  - b. testis
  - c. condition of
84. inflammation of the ductus deferens and seminal vesicle
  - a. vas (ductus) deferens
  - b. seminal vesicle
  - c. inflammation
85. abnormally profuse spermatic secretion
  - a. many
  - b. sperm
  - c. condition of

## CASE STUDY QUESTIONS

### Case Study 15-1

1. d
2. a
3. b
4. bilateral inguinal herniorrhaphy
5. strangulated hernia
6. balanitis
7. phimosis

### Case Study 15-2

1. d
2. d
3. d
4. b
5. psychogenic
6. vasodilation
7. antihypertensive

## Chapter 16

### PRETEST

1. c
2. b
3. c
4. b
5. c
6. b
7. a
8. c

## CHAPTER EXERCISES

### Exercise 16-1

1. any disease of women
2. between menstruation periods
3. formation of an ovum
4. release of an ovum from the ovary
5. pertaining to an ovary
6. inflammation of an ovary
7. ovariorrhexis (*o-var-e-o-REK-sis*)
8. ovulatory (*OV-u-lah-to-re*)
9. menorrhagia (*men-o-RA-je-ab*)
10. oligomenorrhea (*ol-ih-go-men-o-RE-ab*)
11. amenorrhea (*ah-men-o-RE-ab*)
12. dysmenorrhea (*DIS-men-o-re-ab*)
13. ovariectomy (*o-var-e-OT-o-me*)
14. ovariocentesis (*o-var-e-o-sen-TE-sis*)
15. ovariocele (*o-VAR-e-o-sele*)
16. oophoroplasty (*o-of-or-o-PLAS-te*)
17. oophoroma (*o-of-o-RO-mah*)

### Exercise 16-2

1. radiographic examination of the uterus
2. softening of the uterus
3. plastic repair of the vagina
4. pain in the vagina
5. excision of a uterine tube, fallopian tube
6. pertaining to the uterus and urinary bladder
7. within the cervix
8. salpingopexy (*sal-PING-go-pek-se*)
9. salpingography (*sal-ping-GOG-rah-fe*)
10. hydrosalpinx (*hi-dro-SAL-pinx*)
11. pyosalpinx (*pi-o-SAL-pinx*)
12. salpingo-oophorectomy (*sal-ping-go-o-of-o-REK-to-me*); also, salpingo-ovariectomy (*sal-ping-go-o-var-e-EK-to-me*)
13. hysteropexy (*his-ter-o-PEK-se*)
14. uterine (*U-ter-in*)
15. metrostenosis (*me-tro-steb-NO-sis*)
16. hysterosalpingogram (*his-ter-o-sal-PING-go-gram*)
17. transcervical (*trans-SER-vih-kal*)
18. metroptosis (*me-trop-TO-sis*)
19. colpocele (*KOL-po-sele*)
20. vaginitis (*vaj-ih-NI-tis*)

### Exercise 16-3

1. vulvectomy (*vul-VEK-to-me*)
2. episiorrhaphy (*eh-piz-e-OR-ab-fe*)

3. vaginoperineal (*vaj-ih-no-per-ih-NE-al*)
4. clitoromegaly (*klit-or-o-MEG-ab-le*)
5. mammogram (*MAM-o-gram*)
6. mastitis (*mas-TI-tis*)
7. mastectomy (*mas-TEK-to-me*); also, mammectomy (*mah-MEK-to-me*)

### Exercise 16-4

1. before birth
2. formation of an embryo
3. pertaining to a newborn
4. endoscopic examination of the fetus
5. developing in, or pertaining to, one amniotic sac
6. lack of milk production
7. decreased secretion of milk
8. embryology (*em-bre-OL-o-je*)
9. postnatal (*post-NA-tal*)
10. amniotomy (*am-ne-OT-o-me*)
11. amniocyte (*AM-ne-o-site*)
12. embryopathy (*em-bre-OP-ab-the*)
13. fetoscope (*FE-to-skope*)
14. amniorrhexis (*am-ne-o-REK-sis*)
15. neonatology (*ne-o-na-TOL-o-je*)
16. primigravida (*prib-mih-GRAV-ih-dab*)
17. multigravida (*mul-tih-GRAV-ih-dab*)
18. nullipara (*nul-IP-ab-rah*)
19. primipara (*prib-MIP-ab-rah*)
20. xerotocia (*ze-ro-TO-se-ab*)
21. bradytocia (*brad-e-TO-se-ab*)
22. galactorrhhea (*gab-lak-to-RE-ab*); also, lactorrhhea (*lak-to-RE-ab*)
23. galactocele (*ga-hLAK-to-sele*); also, lactocele (*LAK-to-sele*)

## CHAPTER REVIEW

### Labeling Exercise

#### The Female Reproductive System

1. ovary
2. uterine tube
3. uterus
4. cervix
5. posterior fornix
6. rectouterine pouch
7. vagina
8. clitoris
9. labium minus
10. labium majus
11. urinary bladder
12. urethra
13. pubic symphysis
14. rectum
15. anus

#### Ovulation and Fertilization

1. ovary
2. fimbriae
3. ovum
4. sperm cells (spermatozoa)
5. uterine tube
6. implanted embryo
7. body of uterus
8. cervix
9. vagina
10. greater vestibular (Bartholin) gland

#### Terminology

1. c
2. d
3. e
4. a
5. b
6. c
7. b
8. a
9. e
10. d
11. d
12. c
13. e
14. b
15. a
16. b
17. e
18. c
19. d
20. a
21. d
22. b
23. e
24. c
25. a
26. colposcope
27. ovary
28. rectocele
29. ovum (egg cell)
30. placenta
31. lactation
32. abortion
33. uterus
34. breasts (mammary glands)
35. T
36. F; embryo
37. F; myometrium
38. F; corpus luteum
39. F; uterine tube
40. T

41. T
42. T
43. T
44. behind the uterus
45. any disease of the uterus
46. softening of the uterus
47. pus in the uterine tube (fallopian tube)
48. narrowing of the vagina
49. pain in the vulva
50. after birth
51. below the mammary gland (breast)
52. outside the embryo
53. woman who has given birth three times
54. causing fetal abnormalities
55. salpingocele
56. episiorrhaphy
57. metrostenosis
58. hysterosalpingectomy
59. mammogram
60. dystocia
61. amniorrhexis
62. embryology
63. fetometry
64. gravida
65. fundus
66. pelvimetry
67. suprapubic
68. Apgar score
69. neonate
70. polyhydramnios
71. prenatal
72. eutocia
73. anovulatory
74. intrauterine
75. cervical
76. uterine
77. perineal
78. vaginal
79. embryonic
80. amniotic
81. ova
82. cervix
83. fimbriae
84. labia
85. candidiasis; *Candidiasis* is a fungal infection; the others are procedures used to diagnose fetal abnormalities.
86. measles; *Measles* is an infectious disease; the others are hereditary disorders.
87. colostrum; *Colostrum* is the breast fluid released before milk is produced; the others are hormones involved in reproduction.

88. labia majora; The *labia majora* are part of the vulva; the others are associated with pregnancy.
89. spina bifida; *Spina bifida* is a congenital spinal defect; the others are disorders of pregnancy.
90. c
91. b
92. a
93. d
94. episioectomy
95. cervicitis
96. mammography
97. mammoplasty
98. cervicography
99. episiotomy
100. intracervical
101. cervicoplasty
102. cervicotomy
103. transcervical
104. human chorionic gonadotropin
105. dysfunctional uterine bleeding
106. last menstrual period
107. fetal heart rate
108. gestational age
109. vaginal birth after cesarean section
110. prevention of blood vessel formation
- a. against
- b. vessel
- c. origin, formation
- d. condition of
111. excessive development of the mammary glands in the male, even to the secretion of milk
- a. woman
- b. breast
- c. condition of
112. extreme rapidity of labor
- a. sharp, acute
- b. labor
- c. condition of
113. a deficiency of amniotic fluid
- a. few, scanty
- b. fluid
- c. amnion
114. flow of milk from the breast other than normal lactation
- a. milk
- b. flow or discharge
115. congenital absence of a brain
- a. without
- b. brain
- c. pertaining to

## CASE STUDY QUESTIONS

### Case Study 16-1

- b
- c
- b
- a
- b
- dilatation and curettage
- bilateral salpingo-oophorectomy
- hormone replacement therapy
- total abdominal hysterectomy
- gynecologist

### Case Study 16-2

- zygote
- oocyte
- follicular
- in vitro fertilization
- zygote intrafallopian transfer
- gamete intrafallopian transfer



# Glossary

## A

**abdominal cavity** (ab-DOM-ih-nal) The large ventral cavity below the diaphragm and above the pelvic cavity

**abdominopelvic cavity** (ab-dom-ih-no-PEL-vik) The large ventral cavity between the diaphragm and pelvis that includes the abdominal and pelvic cavities

**ablation** (ab-LA-shun) Removal or destruction. In cardiac ablation, a catheter is used to destroy a portion of the heart's conduction pathway to correct an arrhythmia

**abortion** (ah-BOR-shun) Termination of a pregnancy before the fetus is capable of surviving outside the uterus, usually at 20 weeks or 500 g; may be spontaneous or induced; a spontaneous abortion is commonly called a miscarriage

**accommodation** (ah-kom-o-DA-shun) Adjustment of the lens's curvature to allow for vision at various distances

**acetabulum** (as-eh-TAB-u-lum) The bony socket in the hip bone that holds the head of the femur (from the Latin word for vinegar because it resembles the base of a vinegar cruet)

**acetylcholine** (ACh) (as-eh-til-KO-lene) A neurotransmitter that stimulates contraction of skeletal muscles

**acidosis** (as-ih-DO-sis) Excessive acidity of body fluids

**acoustic neuroma** (ah-KU-stik nu-RO-mah) A tumor of the eighth cranial nerve sheath; although benign, it can press on surrounding tissue and produce symptoms; also called an acoustic or vestibular schwannoma or acoustic neurilemmoma

**acquired immunodeficiency syndrome (AIDS)** (ah-KWI-erd im-u-no-de-FISH-en-se SIN-drome) Immune system failure caused by infection with HIV (human immunodeficiency virus); the virus infects certain T cells and thus interferes with immunity

**acromegaly** (ak-ro-MEG-ah-le) Overgrowth of bone and soft tissue, especially in the hands, feet, and face, caused by excess growth hormone in an adult; the name comes from acro meaning "extremity" and megal/o meaning "enlargement"

**acronym** (AK-ro-nim) An abbreviation formed from the first letter of each word in a phrase

**actin** (AK-tin) One of the two contractile proteins in muscle cells; the other is myosin

**acupuncture** (AK-u-punk-chur) An ancient Chinese method of inserting thin needles into the body at specific points to relieve pain, induce anesthesia, or promote healing; similar effects can be obtained by using firm finger pressure at the surface of the body in the technique of acupressure

**acute** (ah-KUTE) Sudden, severe; having a short course

**acute respiratory distress syndrome (ARDS)** Pulmonary edema that can lead rapidly to fatal respiratory failure; causes include trauma, aspiration into the lungs, viral pneumonia, and drug reactions; shock lung

**acute rhinitis** (ri-NI-tis) Inflammation of the nasal mucosa with sneezing, tearing, and profuse secretion of watery mucus, as seen in the common cold

**Addison disease** A disease resulting from deficiency of adrenocortical hormones; it is marked by darkening of the skin, weakness, and alterations in salt and water balance

**adenoids** (AD-eh-noyds) Lymphoid tissue located in the nasopharynx; the pharyngeal tonsils

**adenoma** (ad-eh-NO-mah) A neoplasm of a gland

**adenosine triphosphate (ATP)** (ah-DEN-o-sene tri-FOS-fate) The energy compound of the cell that stores energy needed for cell activities

**adrenal gland** (ah-DRE-nal) A gland on the superior surface of the kidney; the outer region (cortex) secretes steroid hormones; the inner region (medulla) secretes epinephrine (adrenaline) in response to stress (root: adren/o)

**adrenaline** (ah-DREN-ah-lin) See epinephrine

**adult hypothyroidism** (hi-po-THI-royd-izm) A condition caused by hypothyroidism in an adult; there is dry, waxy swelling, most notable in the face; formerly called myxedema (miks-eh-DE-mah)

**afferent** (AF-er-ent) Carrying toward a given point, such as the sensory neurons and nerves that carry impulses toward the CNS (root fer means "to carry")

**age-related macular degeneration (AMD)** (MAK-u-lar de-jen-er-A-shun) Deterioration of the macula associated with aging; macular degeneration impairs central vision

**agonist** A muscle that carries out a given movement (from Greek agon meaning "contest," "struggle")

**agranulocyte** (A-gran-u-lo-site) A white blood cell that does not have visible granules in its cytoplasm; agranulocytes include lymphocytes and monocytes

**albumin** (al-BU-min) A simple protein found in blood plasma

**alkaline phosphatase** (AL-kah-lin FOS-fah-tase) An enzyme needed in the formation of bone; serum activity of this enzyme is useful in diagnosis

**alkalosis** (al-kah-LO-sis) Abnormal alkalinity of body fluids; respiratory alkalosis is caused by abnormally low carbon dioxide levels

**allergen** (AL-er-jen) A substance that causes an allergic response

**allergy** (AL-er-je) Hypersensitivity

**alveoli** (al-VE-o-li) The tiny air sacs in the lungs through which gases are exchanged between the atmosphere

and the blood in respiration (singular: alveolus); an alveolus, in general, is a small hollow or cavity; the term also applies to the bony socket for a tooth

**Alzheimer disease (AD)** (ALTS-hi-mer) A form of dementia caused by atrophy of the cerebral cortex; presenile dementia

**amniocentesis** (am-ne-o-sen-TE-sis) Transabdominal puncture of the amniotic sac to remove amniotic fluid for testing; tests on the cells and fluid obtained can reveal congenital abnormalities, blood incompatibility, and sex of the fetus

**amniotic sac** (am-ne-OT-ik) The membranous sac filled with fluid that holds the fetus; also called amnion (root: amnio)

**amyloid** (AM-ih-loyd) A starch-like substance of unknown composition that accumulates in the brain in Alzheimer and other diseases

**amyotrophic lateral sclerosis (ALS)** (ah-mi-o-TROF-ik) A disease caused by motor neuron degeneration resulting in muscular weakness and atrophy; Lou Gehrig disease

**anaphylactic reaction** (an-ah-fih-LAK-tik) An exaggerated allergic reaction to a foreign substance; it may lead to death caused by circulatory collapse and respiratory distress if untreated; also called anaphylaxis (from Greek phylaxis, meaning “protection”)

**anaphylaxis** (an-ah-fih-LAK-sis) An extreme allergic reaction that can lead to respiratory distress, circulatory collapse, and death

**anastomosis** (ah-nas-to-MO-sis) A passage or communication between two vessels or organs; may be normal or pathologic or may be created surgically

**anatomic position** (an-ah-TOM-ik) Standard position for anatomic studies, in which the body is erect and facing forward, the arms are at the sides with palms forward, and the feet are parallel

**androgen** (AN-dro-jen) Any hormone that produces male characteristics (root *andr/o* means “male”)

**anemia** (ah-NE-me-ah) A deficiency in the amount of hemoglobin in the blood; may result from blood loss, malnutrition, a hereditary defect, environmental factors, and other causes

**anencephaly** (an-en-SEF-ah-le) Congenital absence of a brain

**anesthesia** (an-es-THE-ze-ah) Loss of the ability to feel pain, as by administration of a drug

**aneurysm** (AN-u-rizm) A localized abnormal dilation of a blood vessel that results from weakness of the vessel wall, usually of an artery; may eventually burst

**angina pectoris** (an-JI-nah PEK-to-ris) A feeling of constriction around the heart or pain that may radiate to the left arm or shoulder, usually brought on by exertion; caused by insufficient blood supply to the heart

**angioedema** (an-je-o-eh-DE-mah) A localized edema with large hives (wheals) similar to urticaria but involving deeper layers of the skin and subcutaneous tissue

**angioplasty** (AN-je-o-plas-te) A procedure that reopens a narrowed vessel and restores blood flow; commonly accomplished by surgically removing plaque, inflating a balloon within the vessel, or installing a device (stent) to keep the vessel open

**angiotensin** (an-je-o-TEN-sin) A substance that increases blood pressure; activated in the blood by renin, an enzyme produced by the kidneys

**ankylosing spondylitis** (ang-kih-LO-sing spon-dih-LI-tis) A chronic, progressive inflammatory disease involving the spinal joints and surrounding soft tissue, most common in young males; also called rheumatoid spondylitis

**ankylosis** (ang-kih-LO-sis) Immobility and fixation of a joint

**antagonist** (an-TAG-o-nist) The muscle that opposes an agonist; it must relax when the agonist contracts; also a substance that interferes with or opposes the action of a drug

**antibody** (AN-tih-bod-e) A protein produced in response to and interacting specifically with an antigen

**antidiuretic hormone (ADH)** (an-te-di-u-RET-ik) A hormone released from the pituitary gland that causes water reabsorption in the kidneys, thus concentrating the urine

**antigen** (AN-tih-jen) A substance that induces the formation of an antibody

**antigen-presenting cell (APC)** Immune cell that takes in a foreign antigen, processes it, and presents it on the cell surface in combination with the body’s own proteins, thus activating a T cell; examples are dendritic cells and macrophages, which are descendants of monocytes

**antiinflammatory agent** Drug that reduces inflammation; includes steroids, such as hydrocortisone, and nonsteroidal antiinflammatory drugs (NSAIDs)

**anus** (A-nus) The distal opening of the digestive tract (root: *an/o*)

**anxiety** (ang-ZI-eh-te) A feeling of fear, worry, uneasiness, or dread

**aorta** (a-OR-tah) The largest artery; it receives blood from the left ventricle and branches to all parts of the body (root: *aort/o*)

**aortic valve** (a-OR-tik) The valve at the entrance to the aorta

**apex** (A-peks) The point of a cone-shaped structure (adjective: *apical*); the apex of the heart is formed by the left ventricle and is pointed toward the inferior and left

**Apgar score** (AP-gar) A system of rating an infant’s physical condition immediately after birth; five features are rated as 0, 1, or 2 at 1 and 5 minutes after delivery and sometimes thereafter; the maximum possible score at each test interval is 10; infants with low scores require medical attention

**aphasia** (ah-FA-ze-ah) Specifically, loss or defect in speech communication (from Greek *phasis*, meaning “speech”); in practice, the term is applied more broadly to a range of language disorders, both spoken and written, that may affect the ability to understand speech (receptive aphasia) or the ability to produce speech (expressive aphasia); both forms are combined in global aphasia

**aplastic anemia** (a-PLAS-tik) Anemia caused by bone marrow failure resulting in deficient blood cell production, especially of red cells; pancytopenia

**appendicitis** (ah-pen-dih-SI-tis) Inflammation of the appendix

**appendix** (ah-PEN-diks) An appendage; usually means the narrow tube of lymphatic tissue attached to the cecum, the vermiform (worm-like) appendix

- aqueous humor** (AK-we-us) Fluid that fills the eye anterior to the lens
- arachnoid mater** (ah-RAK-noyd) The middle layer of the meninges (from the Greek word for spider, because this tissue resembles a spider web)
- arrhythmia** (ah-RITH-me-ah) Any abnormality in the rate or rhythm of the heartbeat (literally “without rhythm”; note doubled r); also called dysrhythmia
- arterial blood gases (ABGs)** The concentrations of gases, specifically oxygen and carbon dioxide, in arterial blood; reported as the partial pressure (P) of the gas in arterial (a) blood, such as PaO<sub>2</sub> or PaCO<sub>2</sub>; these measurements are important in measuring the acid–base balance
- arteriole** (ar-TE-re-ole) A small vessel that carries blood from the arteries into the capillaries (root: arteriol/o)
- arteriosclerosis** (ar-tere-e-o-skler-O-sis) Hardening (sclerosis) of the arteries, with loss of capacity and loss of elasticity, as from fatty deposits (plaque), deposit of calcium salts, or scar tissue formation
- artery** (AR-teh-re) A vessel that carries blood away from the heart; all except the pulmonary and umbilical arteries carry oxygenated blood (roots: arter, arteri/o)
- arthritis** (ar-THRI-tis) Inflammation of a joint
- arthrocentesis** (ar-thro-sen-TE-sis) Aspiration of fluid from a joint by needle puncture
- arthrodesis** (ar-THROD-eh-sis) Surgical immobilization (fusion) of a joint; artificial ankylosis
- arthroplasty** (AR-thro-plas-te) Partial or total replacement of a joint with a prosthesis
- arthroscopy** (ar-THROS-ko-pe) Use of an endoscope to examine the interior of a joint or to perform surgery on the joint; the instrument used is an arthroscope
- articulation** (ar-tik-u-LA-shun) A joint (adjective: articular)
- artificial pacemaker** A battery-operated device that generates electrical impulses to regulate the heartbeat; it may be external or implanted, may be designed to respond to need, and may have the capacity to prevent tachycardia
- ascites** (ah-SI-teze) Accumulation of fluid in the abdominal cavity; a form of edema; may be caused by heart disease, lymphatic or venous obstruction, cirrhosis, or changes in blood plasma composition
- aspiration** (as-pih-RA-shun) The accidental inhalation of food or other foreign material into the lungs; also means the withdrawal of fluid from a cavity by suction
- asthma** (AZ-mah) A disease characterized by dyspnea and wheezing caused by spasm of the bronchial tubes or swelling of their mucous membranes
- astigmatism** (ah-STIG-mah-tizm) An error of refraction caused by irregularity in the curvature of the cornea or lens
- astrocytoma** (as-tro-si-TO-mah) A neuroglial tumor composed of astrocytes
- atelectasis** (at-eh-LEK-tah-sis) Incomplete expansion of a lung or part of a lung; lung collapse; may be present at birth (as in respiratory distress syndrome) or be caused by bronchial obstruction or compression of lung tissue (prefix atel/o means “imperfect”)
- atherosclerosis** (ath-er-o-skler-O-sis) The development of fatty, fibrous patches (plaques) in the lining of arteries, causing narrowing of the lumen and hardening of the vessel wall; the most common form of arteriosclerosis (hardening of the arteries) (root ather/o means “porridge” or “gruel”)
- atlas** (AT-las) The first cervical vertebra (root: atlant/o)
- atopic dermatitis** (ah-TOP-ik der-mah-TI-tis) Hereditary, allergic, chronic skin inflammation with pruritus (itching); eczema
- atresia** (ah-TRE-ze-ah) Congenital absence or closure of a normal body opening
- atrioventricular (AV) node** (a-tre-o-ven-TRIK-u-lar) A small mass in the lower septum of the right atrium that passes impulses from the sinoatrial (SA) node toward the ventricles
- atrioventricular (AV) valve** A valve between the atrium and ventricle on the right and left sides of the heart; the right AV valve is the tricuspid valve; the left is the mitral valve
- atrium** (A-tre-um) An entrance chamber, one of the two upper receiving chambers of the heart (root: atri/o)
- attention deficit hyperactivity disorder (ADHD)** A condition that begins in childhood and is characterized by attention problems, easy boredom, impulsive behavior, and hyperactivity
- auditory tube** (aw-dih-TO-re) The tube that connects the middle ear with the nasopharynx and serves to equalize pressure between the outer and middle ear (root: salping/o); pharyngotympanic tube; originally called the eustachian (u-STA-shen) tube
- auscultation** (aws-kul-TA-shun) Listening for sounds within the body, usually within the chest or abdomen
- autism** (AW-tizm) A disorder of unknown cause consisting of self-absorption, lack of response to social contact and affection, preoccupations, stereotyped behavior, and resistance to change (from auto-, “self,” and -ism, “condition of”)
- autism spectrum disorder (ASD)** A disability that falls within a range of neurodevelopmental impairments that appears early in life and affects social interactions and communications skills
- autoimmune disease** (aw-to-ih-MUNE) A condition in which the immune system produces antibodies against an individual’s own tissues (prefix auto means “self”)
- autonomic nervous system (ANS)** (aw-to-NOM-ik) The division of the nervous system that regulates involuntary activities, controlling smooth muscles, cardiac muscle, and glands; the visceral nervous system
- AV bundle** A band of fibers that transmits impulses from the atrioventricular (AV) node to the top of the interventricular septum; it divides into the right and left bundle branches, which descend along the two sides of the septum; the bundle of His
- axis** (AK-sis) The second cervical vertebra
- axon** (AK-son) The fiber of a neuron that conducts impulses away from the cell body
- B**
- B cell** A lymphocyte that matures in bone marrow and is active in producing antibodies; B lymphocyte (LIM-fo-site)

- bacteriuria** (bak-te-re-U-re-ah) Presence of bacteria in the urine
- band cell** An immature neutrophil with a nucleus in the shape of a band; also called a stab cell; band cell counts are used to trace infections and other diseases
- barium study** (BAH-re-um) Use of barium sulfate as a liquid contrast medium for fluoroscopic or radiographic study of the digestive tract; can show obstruction, tumors, ulcers, hiatal hernia, and motility disorders, among other conditions
- Barrett syndrome** (BAH-ret) Condition resulting from chronic esophagitis, as caused by gastroesophageal reflux disease; inflammatory injury can lead to esophageal spasms, scarring, strictures, and increased risk of cancer; also called Barrett esophagus
- basal cell carcinoma** (BA-sal) An epithelial tumor that rarely metastasizes and has a high cure rate with surgical removal
- basophil** (BA-so-fil) A granular leukocyte that stains strongly with basic dyes; active in allergic reactions
- benign** (be-NINE) Not recurrent or malignant, favorable for recovery, describing a tumor that does not spread (metastasize) to other tissues
- benign prostatic hyperplasia (BPH)** (be-NINE pros-TAT-ik hi-per-PLA-ze-ah) Nonmalignant enlargement of the prostate; frequently develops with age
- bile** The fluid secreted by the liver that emulsifies fats and aids in their absorption (roots: chol/e, bili)
- biliary colic** (BIL-e-ar-e KOL-ik) Acute abdominal pain caused by gallstones in the bile ducts
- bilirubin** (bil-ih-RU-bin) A pigment released in the breakdown of hemoglobin from red blood cells; mainly excreted by the liver in bile
- biofeedback** (bi-o-FEDE-bak) A method for learning control of involuntary physiologic responses by using electronic devices to monitor bodily changes and feeding this information back to a person
- biopsy** (BI-op-se) Removal of a small amount of tissue for microscopic examination
- bipolar disorder** (bi-PO-lar) A form of depression with episodes of mania (a state of elation); manic depressive illness
- bisphosphonate** (bis-FOS-fo-nate) Agent used to prevent and treat osteoporosis; increases bone mass by decreasing bone turnover; examples are alendronate (Fosamax), risedronate (Actonel), and ibandronate (Boniva)
- blood** (blud) The fluid that circulates in the cardiovascular system (roots: hem/o, hemat/o)
- blood pressure** The force exerted by blood against the wall of a vessel
- B lymphocyte** See B cell
- bone** A calcified form of dense connective tissue; osseous tissue; also an individual unit of the skeleton made of such tissue (root: oste/o)
- bone marrow** The soft material that fills bone cavities; yellow marrow fills the central cavity of the long bones; blood cells are formed in red bone marrow, which is located in spongy bone tissue (root: myel/o)
- bradycardia** (brad-e-KAR-de-ah) A slow heart rate of less than 60 bpm
- brain** (brane) The nervous tissue contained within the cranium; consists of the cerebrum, diencephalon, brainstem, and cerebellum (root: encephal/o)
- brainstem** The part of the brain that consists of the midbrain, pons, and medulla oblongata
- brand name** The trade or proprietary name of a drug, a registered trademark of the manufacturer; written with an initial capital letter
- bronchiectasis** (brong-ke-EK-tah-sis) Chronic dilatation of a bronchus or bronchi
- bronchiole** (BRONG-ke-ole) One of the smaller subdivisions of the bronchial tubes (root: bronchiol/o)
- bronchitis** (brong-KI-tis) Inflammation of a bronchus
- bronchoscope** (BRONG-ko-skope) An endoscope used to examine the tracheobronchial passageways. Also allows access for tissue biopsy or removal of a foreign object
- bronchus** (BRONG-kus) One of the larger air passageways in the lungs; the bronchi begin as two branches of the trachea and then subdivide within the lungs (plural: bronchi) (root: bronch/o)
- bulbourethral gland** (bul-bo-u-RE-thral) A small gland beside the urethra below the prostate that secretes part of the seminal fluid; also called Cowper gland
- bundle branches** Branches of the AV bundle that divide to the right and left sides of the interventricular septum
- bursa** (BUR-sah) A fluid-filled sac that reduces friction near a joint (root: burs/o)
- ## C
- calyx** (KA-lik) A cup-like cavity in the pelvis of the kidney; also calix (plural: calices) (roots: cali/o, calic/o)
- candidiasis** (kan-dih-DI-ah-sis) Infection with the fungus *Candida*, a common cause of vaginitis
- capillary** (KAP-ih-lar-e) A microscopic blood vessel through which materials are exchanged between the blood and the tissues
- carbohydrates** (kar-bo-HI-drates) The category of organic compounds that includes sugars and starches
- carbon dioxide (CO<sub>2</sub>)** (KAR-bon di-OK-side) A gas produced by energy metabolism in cells and eliminated through the lungs
- carbonic acid** (kar-BON-ik) An acid formed when carbon dioxide dissolves in water; H<sub>2</sub>CO<sub>3</sub>
- carcinoma** (kar-sih-NO-mah) A malignant neoplasm composed of epithelial cells (from Greek root *carcino*, meaning “crab”) (adjective: carcinomatous)
- cardiac muscle** (KAR-de-ak) Involuntary muscle that makes up the heart wall
- cardiopulmonary resuscitation (CPR)** (kar-de-o-PUL-mo-nar-e re-sus-ih-TA-shun) Restoration of cardiac output and pulmonary ventilation after cardiac arrest using artificial respiration and chest compression or cardiac massage
- cardiovascular system** (kar-de-o-VAS-ku-lar) The part of the circulatory system that consists of the heart and the blood vessels
- cardioversion** (KAR-de-o-ver-zhun) Correction of an abnormal cardiac rhythm; may be accomplished pharmacologically, with antiarrhythmic drugs, or by application of electric current (see defibrillation)

- caries** (KAR-eze) Tooth decay
- carotid endarterectomy** (end-ar-ter-EK-to-me) Surgical removal of the lining of the carotid artery, the large artery in the neck that supplies blood to the brain
- carrier** (KAH-re-er) An individual who has an unexpressed genetic defect that can be passed to his or her children
- cartilage** (KAR-tih-lij) A type of dense connective tissue that is found in the skeleton, larynx, trachea, and bronchi; it is the precursor to most bone tissue (root: chondr/o)
- cast** A solid mold of a renal tubule found in the urine
- cataract** (KAT-ah-rakt) Opacity of the lens of the eye
- catheterization** (kath-eh-ter-ih-ZA-shun) Introduction of a tube into a passage, such as through the urethra into the bladder for withdrawal of urine
- cautery** (KAW-ter-e) Destruction of tissue by a damaging agent, such as a harmful chemical, heat, or electric current (electrocautery); cauterization
- CD4+ T lymphocyte count** A count of the T cells that have the CD4 receptors for the AIDS virus (HIV); a count of less than 200/mcL of blood signifies severe immunodeficiency
- cecum** (SE-kum) A blind pouch at the beginning of the large intestine (root: cec/o)
- celiac disease** (SE-le-ak) Inability to absorb foods containing gluten, a protein found in wheat and some other grains; caused by an excess immune response to gluten
- cell** (sel) The basic structural and functional unit of the living organism, a microscopic unit that combines with other cells to form tissues (root: cyt/o)
- central nervous system (CNS)** The brain and spinal cord
- cerebellum** (ser-eh-BEL-um) The posterior portion of the brain dorsal to the pons and medulla; helps to coordinate movement and to maintain balance and posture (cerebellum means “little brain”) (root: cerebell/o)
- cerebral angiography** (SER-eh-bral an-je-OG-rah-fe) Radiographic study of the brain’s blood vessels after injection of a contrast medium
- cerebral contusion** (kon-TU-zhun) A bruise to the surface of the brain following a blow to the head
- cerebral cortex** (SER-eh-bral) The cerebrum’s thin surface layer of gray matter (the cortex is the outer region of an organ) (root: cortic/o)
- cerebrospinal fluid (CSF)** (ser-eh-bro-SPI-nal) The watery fluid that circulates in and around the brain and spinal cord for protection
- cerebrovascular accident (CVA)** (ser-eh-bro-VAS-ku-lar) Sudden damage to the brain resulting from reduction of cerebral blood flow; possible causes are atherosclerosis, thrombosis, or a ruptured aneurysm; commonly called stroke
- cerebrum** (SER-eh-brum) The large upper portion of the brain; it is divided into two hemispheres by the longitudinal fissure (root: cerebr/o)
- cerumen** (seh-RU-men) The brownish, wax-like secretion formed in the external ear canal to protect the ear and prevent infection (adjective: ceruminous [seh-RU-mih-nus])
- cervix** (SER-viks) Neck; usually means the lower narrow portion (neck) of the uterus (root: cervic/o); also called the cervix uteri (U-ter-i)
- chemotherapy** (ke-mo-THER-ah-pe) Use of chemicals to treat disease; the term is often applied specifically to the treatment of cancer with chemicals
- chiropractic** (ki-ro-PRAK-tik) A science that stresses the condition of the nervous system in diagnosis and treatment of disease; often, the spine is manipulated to correct misalignment; most patients consult for musculoskeletal pain and headaches (from Greek cheir, meaning “hand”)
- cholecystectomy** (ko-le-sis-TEK-to-me) Surgical removal of the gallbladder
- cholecystitis** (ko-le-sis-TI-tis) Inflammation of the gallbladder
- cholelithiasis** (ko-le-lih-THI-ah-sis) The condition of having stones in the gallbladder; also used to refer to stones in the common bile duct
- chondrosarcoma** (kon-dro-sar-KO-mah) A malignant tumor of cartilage
- chorion** (KOR-e-on) The outermost layer of the embryo that, with the endometrium, forms the placenta (adjective: chorionic)
- chorionic villus sampling (CVS)** Removal of chorionic cells through the cervix for prenatal testing; can be done earlier in pregnancy than amniocentesis
- choroid** (KOR-oyd) The dark, vascular, middle layer of the eye (roots: chori/o, choroid/o); part of the uvea
- chromosome** (KRO-mo-some) A thread-like body in a cell’s nucleus that contains genetic information
- chronic** (KRON-ik) Of long duration, progressing slowly
- chronic fatigue syndrome (CFS)** (KRON-ik fah-TEGE SINDROME) A disease of unknown cause that involves persistent fatigue along with muscle and joint pain and other symptoms; may be virally induced
- chronic obstructive pulmonary disease (COPD)** Any of a group of chronic, progressive, and debilitating respiratory diseases, which includes emphysema, asthma, bronchitis, and bronchiectasis
- cicatrization** (sik-ah-trih-ZA-shun) The process of scar formation; a scar is a cicatrix (SIK-ah-triks)
- ciliary body** (SIL-e-ar-e) The muscular portion of the uvea that surrounds the lens and adjusts its shape for near and far vision (root: cycl/o)
- circumcision** (ser-kum-SIH-zhun) Surgical removal of the end of the prepuce (foreskin)
- cirrhosis** (sir-RO-sis) Chronic liver disease with degeneration of liver tissue
- cleft lip** A congenital separation of the upper lip
- cleft palate** A congenital split in the roof of the mouth
- clitoris** (KLIT-o-ris) A small erectile body anterior to the urethral opening that is similar in developmental origin to the penis (roots: clitor/o, clitorid/o)
- clubbing** (KLUB-ing) Enlargement of the ends of the fingers and toes caused by growth of the soft tissue around the nails; seen in a variety of diseases in which there is poor peripheral circulation

- coagulation** (ko-ag-u-LA-shun) Blood clotting
- coarctation of the aorta** (ko-ark-TA-shun) Localized narrowing of the aorta with restriction of blood flow
- cochlea** (KOK-le-ah) The coiled portion of the inner ear that contains the receptors for hearing (root: cochle/o)
- coitus** (KO-ih-tus) Sexual intercourse
- colon** (KO-lon) The major portion of the large intestine; extends from the cecum to the rectum and is formed by ascending, transverse, and descending portions (roots: col/o, colon/o)
- colostrum** (ko-LOS-trum) Breast fluid that is secreted in the first few days after giving birth before milk is produced
- colposcope** (KOL-po-skope) Instrument for examining the vagina and cervix
- coma** (KO-mah) State of deep unconsciousness from which one cannot be roused
- combining forms** (kom-BI-ning) A word root combined with a vowel that links the root with another word part, such as a suffix or another root; combining forms are shown with a slash between the root and the vowel, as in neur/o
- common bile duct** The duct that carries bile into the duodenum; formed by the union of the cystic duct and the common hepatic duct (root: choledoch/o)
- compliance** (kom-PLI-ans) A measure of how easily the lungs expand under pressure; compliance is reduced in many types of respiratory disorders
- compound word** (KOM-pownd) A word that contains more than one root
- concussion** (kon-KUSH-un) Injury resulting from a violent blow or shock; a brain concussion usually results in loss of consciousness
- conductive hearing loss** Hearing impairment that results from blockage of sound transmission to the inner ear
- cone** A specialized cell in the retina that responds to light; cones have high visual acuity, function in bright light, and respond to colors
- cone biopsy** Removal of a cone of tissue from the cervical lining for cytologic examination; also called conization
- confusion** (kon-FU-zhun) A state of reduced comprehension, coherence, and reasoning ability resulting in inappropriate responses to environmental stimuli
- congenital disorder** (kon-JEN-ih-tal) A disorder that is present at birth; may be developmental or hereditary (familial)
- congenital hypothyroidism** (kon-JEN-ih-tal hi-po-THI-royd-izm) A condition caused by lack of thyroid secretion during development and marked by arrested physical and mental growth; also called infantile hypothyroidism
- conjunctiva** (kon-junk-TI-vah) The mucous membrane that lines the eyelids and covers the eyeball's anterior surface
- conjunctivitis** (kon-junk-tih-VI-tis) Inflammation of the conjunctiva; pink eye
- contraception** (kon-trah-SEP-shun) The prevention of pregnancy
- contraindication** (kon-trah-in-dih-KA-shun) A factor that makes the use of a drug undesirable or dangerous
- contrecoup injury** (kon-treh-KU) Damage to the brain on the side opposite the point of a blow as a result of the brain hitting the skull (from French, meaning "counterblow")
- convergence** (kon-VER-jens) Coordinated movement of the eyes toward fixation on the same point
- convulsion** (kon-VUL-shun) A series of violent, involuntary muscle contractions; a tonic convulsion involves prolonged muscle contraction; in a clonic convulsion, there is alternation of contraction and relaxation; both forms appear in grand mal epilepsy
- Cooley anemia** A form of thalassemia (hereditary anemia) that affects production of the  $\beta$  (beta)-hemoglobin chain; thalassemia major
- cornea** (KOR-ne-ah) The clear, anterior portion of the sclera (roots: corne/o, kerat/o)
- coronary angiography** (KOR-o-na-re an-je-OG-rah-fe) Radiographic study of the coronary arteries after introduction of an opaque dye by means of a catheter threaded through blood vessels into the heart
- coronary artery bypass graft (CABG)** Surgical creation of a shunt to bypass a blocked coronary artery; the aorta is connected to a point past the obstruction with another vessel or a piece of another vessel, usually the left internal mammary artery or part of the leg's saphenous vein
- coronary calcium scan** Method for visualizing vessel-narrowing calcium deposits in coronary arteries; useful for diagnosing coronary artery disease in people at moderate risk or those who have undiagnosed chest pain; also known as a heart scan
- coronary circulation** (KOR-o-na-re) The blood vessels in the heart that provide oxygen and nourishment and remove waste products from the myocardium
- corpus luteum** (KOR-pus LU-te-um) The small yellow structure that develops from the ovarian follicle after ovulation and secretes progesterone and estrogen
- cranial cavity** (KRA-ne-al) The dorsal cavity that contains the brain
- cranial nerves** The 12 pairs of nerves that are connected to the brain
- C-reactive protein (CRP)** Protein produced during systemic inflammation, which may contribute to atherosclerosis; high CRP levels can indicate cardiovascular disease and its prognosis
- creatine kinase (CK)** (KRE-ah-tin KI-nase) An enzyme found in muscle tissue; the serum CK level increases in cases of muscle damage; creatine phosphokinase (CPK)
- creatine kinase MB (CK-MB)** (KRE-ah-tin KI-naze) Enzyme released in increased amounts from cardiac muscle cells following myocardial infarction (MI); serum assays help diagnose MI and determine the extent of muscle damage
- Crohn disease** (krone) A chronic inflammatory disease of the gastrointestinal tract usually involving the ileum and colon
- cross-matching** Testing the compatibility of donor and recipient blood in preparation for a transfusion; donor red cells are mixed with recipient serum to look for an

immunologic reaction; similar tests are done on tissues before transplantation

**croup** (krupe) A childhood disease usually caused by a viral infection that involves upper airway inflammation and obstruction; croup is characterized by a barking cough, difficulty breathing, and laryngeal spasm

**cryptorchidism** (krip-TOR-kid-izm) Failure of the testis to descend into the scrotum

**CT angiography (CTA)** (an-je-OG-rah-fe) Computed tomography scan used to visualize vessels in the heart and other organs; requires only a small amount of dye injected into the arm; can rule out blocked coronary arteries that may cause a myocardial infarction (heart attack) in people with chest pain or abnormal stress tests

**curvature of the spine** (KER-vah-chure) An exaggerated spinal curve, such as scoliosis, lordosis, or kyphosis

**Cushing disease** Overactivity of the adrenal cortex resulting from excess production of ACTH by the pituitary

**Cushing syndrome** A condition resulting from an excess of hormones from the adrenal cortex; it is associated with obesity, weakness, hyperglycemia, hypertension, and hirsutism (excess hair growth)

**cutaneous** (ku-TA-ne-us) Pertaining to the skin (from Latin *cutis*, meaning “skin”)

**cyanosis** (si-ah-NO-sis) Bluish discoloration of the skin caused by lack of oxygen in the blood (adjective: cyanotic)

**cyst** (sist) An abnormal filled sac or pouch; used as a root meaning a normal bladder or sac, such as the urinary bladder or gallbladder (root: cyst/o)

**cystectomy** (sis-TEK-to-me) Surgical removal of all or part of the urinary bladder

**cystic fibrosis (CF)** (SIS-tik fi-BRO-sis) An inherited disease that affects the pancreas, respiratory system, and sweat glands; characterized by mucus accumulation in the bronchi causing obstruction and leading to infection

**cystitis** (sis-TI-tis) Inflammation of the urinary bladder, usually as a result of infection

**cystoscope** (SIS-to-skope) An instrument for examining the interior of the urinary bladder; also used for removing foreign objects, for surgery, and for other forms of treatment

**cytology** (si-TOL-o-je) Study of cells

**cytoplasm** (SI-to-plazm) The fluid that fills a cell and holds the organelles

## D

**debridement** (da-brede-MON) Removal of dead or damaged tissue, as from a wound

**deep vein thrombosis (DVT)** (throm-BO-sis) Thrombophlebitis involving the deep veins

**defibrillation** (de-fib-rih-LA-shun) Use of an electronic device (defibrillator) to stop fibrillation by delivering a brief electric shock to the heart; the shock may be delivered to the surface of the chest, as by an automated external defibrillator (AED), or directly into the heart through wire leads, using an implantable cardioverter defibrillator (ICD)

**degenerative joint disease (DJD)** Osteoarthritis

**dehiscence** (de-HIS-ens) Splitting or bursting, as when the layers of a wound separate

**delayed hypersensitivity reaction** An allergic reaction involving T cells that takes at least 12 hours to develop; examples are various types of contact dermatitis, such as poison ivy or poison oak; the tuberculin reaction (test for TB); and rejections of transplanted tissue

**delusion** (de-LU-zhun) A false belief inconsistent with knowledge and experience

**dementia** (de-MEN-she-ah) A gradual and usually irreversible loss of intellectual function

**dendrite** (DEN-drite) A fiber of a neuron that conducts impulses toward the cell body

**deoxyribonucleic acid (DNA)** (de-ok-se-ri-bo-nu-KLE-ik) The genetic compound of the cell, makes up the genes

**depolarization** (de-po-lar-ih-ZA-shun) A change in electrical charge from the resting state in nerves or muscles

**depression** (de-PRESH-un) A mental state characterized by profound feelings of sadness, emptiness, hopelessness, and lack of interest or pleasure in activities

**derma** (DER-mah) Skin (from Greek)

**dermatitis** (der-mah-TI-tis) Inflammation of the skin, often associated with redness and itching; may be caused by allergy, irritants (contact dermatitis), or a variety of diseases

**dermatology** (der-mah-TOL-o-je) Study of the skin and diseases of the skin

**dermatome** (DER-mah-tome) Instrument for cutting thin skin sections for grafting

**dermatomyositis** (der-mah-to-mi-o-SI-tis) A disease of unknown origin involving muscular inflammation as well as dermatitis and skin rashes

**dermis** (DER-mis) The layer of the skin between the epidermis and the subcutaneous tissue; the true skin or corium

**diabetes insipidus** (di-ah-BE-teze in-SIP-ih-dus) A disorder caused by insufficient release of ADH from the posterior pituitary; it results in excessive thirst and production of large amounts of very dilute urine; insipidus means “tasteless,” referring to the dilution of the urine

**diabetes mellitus (DM)** (MEL-ih-tus) A disorder of glucose metabolism caused by deficiency of insulin production or inadequate tissue response to insulin; type 1 results from autoimmune destruction of pancreatic islet cells; it generally appears in children and requires insulin administration; type 2 generally occurs in obese adults; it is treated with diet, exercise, and drugs to improve insulin production or activity, and sometimes insulin; mellitus comes from the Latin root for honey, referring to the urine’s glucose content

**diabetic retinopathy** (ret-ih-NOP-ah-the) Degenerative changes in the retina associated with diabetes mellitus

**diagnosis** (di-ag-NO-sis) The process of determining the cause and nature of an illness

**dialysis** (di-AL-ih-sis) Separation of substances by passage through a semipermeable membrane; dialysis is used to rid the body of unwanted substances when the kidneys

are impaired or missing; the two forms of dialysis are hemodialysis and peritoneal dialysis

**diaphoresis** (di-ah-fo-RE-sis) Profuse sweating

**diaphragm** (DI-ah-fram) The dome-shaped muscle under the lungs that flattens during inspiration (root: phren/o)

**diaphragm** (DI-ah-fram) The muscle that separates the thoracic from the abdominal cavity

**diaphysis** (di-AF-ih-sis) The shaft of a long bone

**diarrhea** (di-ah-RE-ah) The frequent passage of watery bowel movements

**diarthrosis** (di-ar-THRO-sis) A freely movable joint; also called a synovial joint (adjective: diarthrotic)

**diastole** (di-AS-to-le) The relaxation phase of the heartbeat cycle (adjective: diastolic)

**diencephalon** (di-en-SEF-ah-lon) The part of the brain that contains the thalamus, hypothalamus, and pituitary gland; located between the cerebrum and the brainstem

**dilatation and evacuation (D&E)** Widening of the cervix and removal of conception products by suction

**dilation and curettage (D&C)** (ku-reh-TAJ) Procedure in which the cervix is dilated (widened) and the uterine lining is scraped with a curette

**diphtheria** (dif-THERE-e-ah) Acute infectious disease, usually limited to the upper respiratory tract, characterized by the formation of a surface pseudomembrane composed of cells and coagulated material

**discectomy** (dis-KEK-to-me) Surgical removal of a herniated intervertebral disk; also spelled discectomy

**dissecting aneurysm** An aneurysm in which blood enters the arterial wall and separates the layers; usually involves the aorta

**disseminated intravascular coagulation (DIC)** Widespread clot formation in the microscopic vessels; may be followed by bleeding caused by depletion of clotting factors

**diuresis** (di-u-RE-sis) Excretion of urine; usually meaning increased urinary excretion

**diuretic** (di-u-RET-ik) A substance that increases the excretion of urine; pertaining to diuresis

**diverticulitis** (di-ver-tik-u-LI-tis) Inflammation of diverticula (small pouches) in the wall of the digestive tract, especially in the colon

**diverticulosis** (di-ver-tik-u-LO-sis) The presence of diverticula, especially in the colon

**drug** A substance that alters body function

**ductus arteriosus** (DUK-tus ar-tere-e-O-sus) A fetal blood vessel that connects the pulmonary artery with the descending aorta, thus allowing blood to bypass the lungs

**ductus deferens** (DUK-tus DEF-er-enz) The duct that conveys spermatozoa from the epididymis to the ejaculatory duct; also called vas deferens

**Dukes classification** A system for staging colorectal cancer based on degree of bowel wall penetration and lymph node involvement; severity is graded from A to C

**duodenum** (du-o-DE-num) The first portion of the small intestine (root: duoden/o); also pronounced du-OD-eh-num

**dura mater** (DU-rah MA-ter) The strong, fibrous outermost layer of the meninges

**dyslipidemia** (dis-lip-ih-DE-me-ah) Disorder in serum lipid levels, which is an important factor in the development

of atherosclerosis; includes hyperlipidemia (high lipids), hypercholesterolemia (high cholesterol), and hypertriglyceridemia (high triglycerides)

**dysmenorrhea** (DIS-men-o-re-ah) Painful or difficult menstruation; a common disorder that may be caused by infection, use of an intrauterine device, endometriosis, overproduction of prostaglandins, or other factors

**dysphagia** (dis-FA-je-ah) Difficulty in swallowing

**dyspnea** (disp-NE-ah) Difficult or labored breathing (-pnea), sometimes with pain; “air hunger”

**dysthymia** (dis-THI-me-ah) A mild form of depression that usually develops in response to a serious life event (from dys- and Greek thymos, meaning “mind, emotion”)

**dysuria** (dis-U-re-ah) Painful or difficult urination

## E

**ecchymosis** (ek-ih-MO-sis) A collection of blood under the skin caused by leakage from small vessels (root chym means “juice”)

**echocardiography** (ek-o-kar-de-OG-rah-fe) A noninvasive method that uses ultrasound to visualize internal cardiac structures

**eclampsia** (eh-KLAMP-se-ah) Convulsions and coma occurring during pregnancy or after delivery and associated with preeclampsia (see below) (adjective: eclamptic)

**ectopic pregnancy** (ek-TOP-ik) Development of the fertilized ovum outside the body of the uterus; usually occurs in the uterine tube (tubal pregnancy) but may occur in other parts of the reproductive tract or abdominal cavity

**eczema** (EK-ze-mah) A general term for skin inflammation with redness, lesions, and itching; atopic dermatitis

**edema** (eh-DE-mah) Accumulation of fluid in the tissues, swelling; adjective: edematous (eh-DE-mah-tus)

**edema** (eh-DE-mah) Swelling of body tissues caused by the presence of excess fluid; causes include cardiovascular disturbances, kidney failure, inflammation, and malnutrition

**efferent** (EF-er-ent) Carrying away from a given point, such as the motor neurons and nerves that carry impulses away from the CNS (root fer means “to carry”)

**efficacy** (EF-ih-kah-se) The power to produce a specific result; effectiveness

**ejaculation** (e-jak-u-LA-shun) Ejection of semen from the male urethra

**ejaculatory duct** (e-JAK-u-lah-tor-e) The duct formed by union of the ductus deferens and the duct of the seminal vesicle; it carries spermatozoa and seminal fluid into the urethra

**electrocardiography (ECG)** (e-lek-tro-kar-de-OG-rah-fe) Study of the electrical activity of the heart as detected by electrodes (leads) placed on the surface of the body; also abbreviated EKG from the German electrocardiography

**electroencephalography (EEG)** (e-lek-tro-en-sef-ah-LOG-rah-fe) Amplification, recording, and interpretation of the brain's electric activity

**electrolyte** (e-LEK-tro-lite) A substance that separates into charged particles (ions) in solution; a salt; term also applied to ions in body fluids



- electromyography (EMG)** (e-lek-tro-mi-OG-rah-fe) Study of the electrical activity of muscles during contraction
- embolism** (EM-bo-lizm) Obstruction of a blood vessel by a blood clot or other matter carried in the circulation
- embolus** (EM-bo-lus) A mass carried in the circulation; usually a blood clot, but also may be air, fat, bacteria, or other solid matter from within or from outside the body
- embryo** (EM-bre-o) The stage in development between the zygote and the fetus, extending from the second through the eighth week of growth in the uterus (root: embryo/o) (adjective: embryonic)
- emesis** (EM-eh-sis) Vomiting
- emphysema** (em-fih-SE-mah) A chronic pulmonary disease characterized by enlargement and destruction of the alveoli
- empyema** (em-pi-E-mah) Accumulation of pus in a body cavity, especially the pleural space; pyothorax
- encephalitis** (en-sef-ah-LI-tis) Inflammation of the brain
- endocardium** (en-do-KAR-de-um) The thin membrane that lines the chambers of the heart and covers the valves
- endocrine** (EN-do-krin) Pertaining to a ductless gland that secretes hormones into the blood
- endometriosis** (en-do-me-tre-O-sis) Growth of endometrial tissue outside the uterus, usually in the pelvic cavity
- endometrium** (en-do-ME-tre-um) The inner lining of the uterus
- endoscope** (EN-do-skope) An instrument for examining the inside of an organ or cavity through a body opening or small incision; most endoscopes use fiber optics for viewing
- endoscopic retrograde cholangiopancreatography (ERCP)** (ko-lan-je-o-pan-kre-ah-TOG-rah-fe) A technique for viewing the pancreatic and bile ducts and for performing certain techniques to relieve obstructions; contrast medium is injected into the biliary system from the duodenum before radiographs are taken
- endoscopy** (en-DOS-ko-pe) Use of a fiberoptic endoscope for direct visual examination; GI studies include esophago-gastroduodenoscopy, proctosigmoidoscopy (rectum and distal colon), and colonoscopy (all regions of the colon)
- enzyme** (EN-zime) An organic substance that speeds the rate of a chemical reaction
- eosinophil** (e-o-SIN-o-fil) A granular leukocyte that stains strongly with acidic dyes; active in allergic reactions and defense against parasites
- epicardium** (ep-ih-KAR-de-um) The thin outermost layer of the heart wall
- epidermis** (ep-ih-DER-mis) The outermost layer of the skin (from epi-, meaning “upon or over” and derm, meaning “skin”)
- epididymis** (ep-ih-DID-ih-mis) A coiled tube on the surface of the testis that stores sperm until ejaculation (root: epididym/o)
- epididymitis** (ep-ih-did-ih-MI-tis) Inflammation of the epididymis; common causes are UTIs and STIs
- epidural hematoma** (he-mah-TO-mah) Accumulation of blood in the epidural space (between the dura mater and the skull)
- epiglottis** (ep-ih-GLOT-is) A leaf-shaped cartilage that covers the larynx during swallowing to prevent food from entering the trachea
- epilepsy** (EP-ih-lep-se) A chronic disease involving periodic sudden bursts of electric activity from the brain, resulting in seizures
- epinephrine** (ep-ih-NEF-rin) A powerful stimulant produced by the adrenal gland and sympathetic nervous system; activates the cardiovascular, respiratory, and other systems needed to meet stress; used as a drug to treat severe allergic reactions and shock; also called adrenaline
- epiphyseal plate** (ep-ih-FIZ-e-al) The growth region of a long bone; located in the metaphysis, between the diaphysis and epiphysis; when bone growth ceases, this area appears as the epiphyseal line; also spelled epiphysal
- epiphysis** (eh-PIF-ih-sis) The irregularly shaped end of a long bone
- equilibrium** (e-kwih-LIB-re-um) The sense of balance
- erectile dysfunction (ED)** (eh-REK-tile dis-FUNK-shun) Inability of the male to perform intercourse because of failure to initiate or maintain an erection until ejaculation; impotence
- erection** (e-REK-shun) The stiffening or hardening of the penis or the clitoris, usually because of sexual excitement
- erythema** (er-ih-THE-mah) Diffuse redness of the skin
- erythrocyte** (eh-RITH-ro-site) A red blood cell (roots: erythr/o, erythrocyt/o)
- erythropoietin (EPO)** (eh-rith-ro-POY-eh-tin) A hormone produced in the kidneys that stimulates red blood cell production in the bone marrow; this hormone is now made by genetic engineering for clinical use
- escharotomy** (es-kar-OT-o-me) Removal of scab tissue resulting from burns or other skin injuries; a scab or crust is an eschar (ES-kar)
- esophagus** (e-SOF-ah-gus) The muscular tube that carries food from the pharynx to the stomach
- estrogen** (ES-tro-jen) A group of hormones that produce female characteristics and prepare the uterus for the fertilized egg; the most active of these is estradiol
- etiology** (e-te-OL-o-je) The cause of a disease
- evisceration** (e-vis-er-A-shun) Protrusion of internal organs (viscera) through an opening, as through a wound
- excision** (ek-SIZH-un) Removal by cutting (suffix: -ectomy)
- exophthalmos** (ek-sof-THAL-mos) Protrusion of the eyeballs, as seen in Graves disease
- expectoration** (ek-spek-to-RA-shun) The act of coughing up material from the respiratory tract; also the material thus released; sputum
- expiration** (ek-spih-RA-shun) The act of breathing out or expelling air from the lungs; exhalation
- external auditory canal** (aw-dih-TO-re) Tube that extends from the pinna of the ear to the tympanic membrane; external auditory meatus
- exudate** (EKS-u-date) Material, which may include fluid, cells, pus, or blood, that escapes from damaged tissue

**F**

- fallopian tube** (fah-LO-pe-an) See uterine tube
- fascia** (FASH-e-ah) The fibrous sheath of connective tissue that covers a muscle; called deep fascia to differentiate it from the superficial fascia that underlies the skin (root: fasci/o) (plural: fasciae)
- fascicle** (FAS-ih-kl) A small bundle, as of muscle or nerve fibers
- feces** (FE-seze) The waste material eliminated from the intestine (adjective: fecal); stool
- fertilization** (fer-tih-lih-ZA-shun) The union of an ovum and a spermatozoon
- fetus** (FE-tus) The developing child in the uterus from the third month to birth (root: fet/o) (adjective: fetal)
- fibrillation** (fih-brih-LA-shun) Spontaneous, quivering, and ineffectual contraction of muscle fibers, as in the atria or the ventricles
- fibrin** (FI-brin) The protein that forms a clot in the blood coagulation process
- fibrinogen** (fi-BRIN-o-jen) The inactive precursor of fibrin
- fibroid** (FI-broyd) Benign tumor of smooth muscle (see leiomyoma)
- fibromyalgia syndrome (FMS)** (fi-bro-mi-AL-je-ah) A disorder associated with widespread muscular aches and stiffness and having no known cause
- fimbriae** (FIM-bre-e) The long finger-like extensions of the uterine tube that wave to capture the released ovum (singular: fimbria)
- fistula** (FIS-tu-lah) An abnormal passageway between two organs such as between the rectum and anus (anorectal fistula), or from an organ to the body surface
- fixation** (fik-SA-shun) Holding or fastening a structure in a firm position (suffix: -pexy)
- follicle-stimulating hormone (FSH)** A hormone secreted by the anterior pituitary that acts on the gonads; in males, FSH stimulates Sertoli cells and promotes sperm cell development; in females, it stimulates ripening of ova in the ovary
- foramen ovale** (fo-RA-men o-VA-le) A small hole in the interatrial septum in the fetal heart that allows blood to pass directly from the right to the left side of the heart
- formed elements** The cellular components of blood
- fornix** (FOR-niks) An arch-like space, such as the space between the uppermost wall of the vagina and the cervix; from Latin meaning “arch”
- fovea** (FO-ve-ah) The tiny depression in the retina that is the point of sharpest vision; fovea centralis, central fovea
- fracture** (FRAK-chure) A break in a bone; in a closed or simple fracture, the broken bone does not penetrate the skin; in an open fracture, there is an accompanying wound in the skin
- frontal (coronal) plane** (FRUHN-tal) Plane of section that separates the body into anterior (front) and posterior (back) portions
- functional murmur** Any sound produced as the heart functions normally

**G**

- gallbladder** A sac on the undersurface of the liver that stores bile (root: cholecyst/o)
- gamete** (GAM-ete) A mature reproductive cell, the spermatozoon in the male and the ovum in the female
- gamma globulin** (GLOB-u-lin) The fraction of the blood plasma that contains antibodies; given for passive transfer of immunity
- ganglion** (GANG-gle-on) A collection of neuron cell bodies outside the CNS (plural: ganglia) (roots: gangli/o, ganglion/o)
- gastroenteritis** (gas-tro-en-ter-I-tis) Inflammation of the stomach and intestine
- gastroesophageal reflux disease (GERD)** (gas-tro-e-sof-ah-JE-al) Condition caused by reflux of gastric juices into the esophagus resulting in heartburn, regurgitation, inflammation, and possible damage to the esophagus; caused by weakness of the lower esophageal sphincter (LES)
- gene** (jene) A hereditary unit composed of DNA and combined with other genes to form the chromosomes
- generic name** (jeh-NER-ik) The nonproprietary name of a drug; that is, a name that is not privately owned or trademarked; usually a simplified version of the chemical name; not capitalized
- gestation** (jes-TA-shun) The period of development from conception to birth
- gigantism** (JI-gan-tizm) Overgrowth caused by excess growth hormone from the pituitary during childhood; also called gigantism
- glans penis** (glanz PE-nis) The bulbous end of the penis
- glaucoma** (glaw-KO-mah) An eye disease caused by increased intraocular pressure that damages the optic disk and causes vision loss; usually results from faulty fluid drainage from the anterior eye
- glioma** (gli-O-mah) A tumor of neuroglial cells
- glomerular capsule** (glo-MER-u-lar KAP-sule) The cup-shaped structure at the beginning of the nephron that surrounds the glomerulus and receives material filtered out of the blood; Bowman (BO-man) capsule
- glomerular filtrate** (glo-MER-u-lar FIL-trate) The fluid and dissolved materials that filter out of the blood and enter the nephron through the glomerular capsule
- glomerulonephritis** (glo-mer-u-lo-nef-RI-tis) Inflammation of the kidney, primarily involving the glomeruli; the acute form usually occurs after an infection elsewhere in the body; the chronic form varies in cause and usually leads to renal failure
- glomerulus** (glo-MER-u-lus) The cluster of capillaries within the glomerular capsule (plural: glomeruli) (root: glomerul/o)
- glottis** (GLOT-is) The opening between the vocal folds
- glucose** (GLU-kose) A simple sugar that circulates in the blood, the main energy source for metabolism (roots: gluc/o, glyc/o)
- glycated hemoglobin (HbA1c) test** (GLI-ka-ted) A test that measures the binding of glucose to hemoglobin during the lifespan of a red blood cell; it reflects the average

blood glucose level over 2 to 3 months and is useful in evaluating long-term therapy for diabetes mellitus; also called A1c test

- glycosuria** (gli-ko-SU-re-ah) Excess glucose in the urine
- goiter** (GOY-ter) Enlargement of the thyroid gland; a simple (nontoxic) goiter is caused by iodine deficiency
- gonad** (GO-nad) A sex gland; testis or ovary
- gout** (gowt) A form of acute arthritis, usually beginning in the knee or foot, caused by deposit of uric acid salts in the joints
- grading** (GRA-ding) A method for evaluating a tumor based on microscopic examination of the cells
- Gram stain** A laboratory staining procedure that divides bacteria into two groups: Gram-positive, which stain purple, and Gram-negative, which stain red
- granulocyte** (GRAN-u-lo-site) A white blood cell that has visible granules in its cytoplasm; granulocytes include neutrophils, basophils, and eosinophils
- Graves disease** An autoimmune disease resulting in hyperthyroidism; a prominent symptom is exophthalmos (protrusion of the eyeballs); also called diffuse toxic goiter
- gravida** (GRAV-ih-da) Pregnant woman
- gray matter** Unmyelinated tissue of the nervous system
- greater vestibular gland** (ves-TIB-u-lar) A small gland that secretes mucus through a duct that opens near the vaginal orifice; also called Bartholin (BAR-to-lin) gland
- gustation** (gus-TA-shun) The sense of taste (Latin *geusis* means “taste”)
- gyrus** (JI-rus) A raised convolution of the surface of the cerebrum (plural: gyri)

## H

- hair** (har) A thread-like keratinized outgrowth from the skin (root: trich/o)
- hair follicle** (FOL-ih-kl) The sheath in which a hair develops
- hallucination** (hah-lu-sih-NA-shun) A false perception unrelated to reality or external stimuli
- hearing** (HERE-ing) The sense or perception of sound
- heart** (hart) The muscular organ with four chambers that contracts rhythmically to propel blood through vessels to all parts of the body (root: cardi/o)
- heart block** An interference in the electrical conduction system of the heart resulting in arrhythmia
- heart failure** A condition caused by the inability of the heart to maintain adequate blood circulation
- heart rate** The number of times the heart contracts per minute; recorded as beats per minute (bpm)
- heart sounds** Sounds produced as the heart functions: the two loudest sounds are produced by alternate closing of the valves and are designated S1 and S2
- heartburn** (HART-bern) A warm or burning sensation felt behind the sternum and radiating upward; commonly associated with gastroesophageal reflux; medical name is pyrosis (pyr/o means “heat”)
- hematuria** (he-mat-U-re-ah) Presence of blood in the urine
- hemiparesis** (hem-ih-pah-RE-sis) Partial paralysis or weakness of one side of the body
- hemiplegia** (hem-ih-PLÉ-je-ah) Paralysis of one side of the body
- hemodialysis** (he-mo-di-AL-ih-sis) Removal of unwanted substances from the blood by passage through a semi-permeable membrane
- hemoglobin (Hb, Hgb)** (HE-mo-glo-bin) The iron-containing pigment in red blood cells that transports oxygen
- hemolysis** (he-MOL-ih-sis) The rupture of red blood cells and the release of hemoglobin (adjective: hemolytic)
- hemolytic disease of the newborn (HDN)** Disease that results from Rh incompatibility between the blood of a mother and her fetus; an Rh-negative mother produces antibody to Rh-positive fetal red cells that enter her circulation; these antibodies can destroy Rh-positive fetal red cells in a later pregnancy unless the mother is treated with antibodies to remove the Rh antigen; formerly called erythroblastosis fetalis
- hemophilia** (he-mo-FIL-e-ah) A hereditary blood disease caused by lack of a clotting factor resulting in abnormal bleeding
- hemoptysis** (he-MOP-tih-sis) The spitting of blood from the mouth or respiratory tract (ptysis means “spitting”)
- hemorrhagic anemia** (hem-o-RAJ-ik) Anemia that results from blood loss, as from an injury or internal bleeding
- hemorrhoids** (HEM-o-roydz) Varicose veins in the rectum associated with pain, bleeding, and sometimes rectal prolapse; piles
- hemostasis** (he-mo-STA-sis) The stoppage of bleeding
- hemothorax** (he-mo-THOR-aks) Presence of blood in the pleural space
- hepatic portal system** A special circulatory pathway that brings blood directly from the abdominal organs to the liver for processing (also called simply the portal system); the vessel that enters the liver is the hepatic portal vein (portal vein)
- hepatitis** (hep-ah-TI-tis) Inflammation of the liver; commonly caused by a viral infection
- hepatomegaly** (hep-ah-to-MEG-ah-le) Enlargement of the liver
- hernia** (HER-ne-ah) Protrusion of an organ through an abnormal opening; commonly called a rupture
- herniated disk** (HER-ne-a-ted) Protrusion of the center (nucleus pulposus) of an intervertebral disk into the spinal canal; ruptured or “slipped” disk
- herniorrhaphy** (her-ne-OR-ah-fe) Surgical repair of a hernia
- hiatal hernia** (hi-A-tal) A protrusion of the stomach through the opening (hiatus) in the diaphragm through which the esophagus passes
- histology** (his-TOL-o-je) Study of tissues
- Hodgkin lymphoma** A neoplastic disease of B cells that involves the lymph nodes, spleen, liver, and other tissues; characterized by the presence of giant Reed–Sternberg cells
- holistic health care** (ho-LIS-tik) Practice of treating a person as a whole entity with physical, emotional, social, and spiritual needs; it stresses comprehensive care, involvement in one’s own care, and the maintenance of good health rather than the treatment of disease
- homeopathy** (ho-me-OP-ah-the) A philosophy of treating disease by administering drugs in highly diluted form

along with promoting healthy life habits and a healthy environment (from *home/o*, meaning “same,” and *path/o*, meaning “disease”)

**homeostasis** (ho-me-o-STA-sis) A steady state, a condition of internal stability and constancy

**hormone** (HOR-mone) A secretion of an endocrine gland; a substance that travels in the blood and has a regulatory effect on tissues, organs, or glands

**human chorionic gonadotropin (hCG)** (kor-e-ON-ik GO-nah-do-tro-pin) A hormone secreted by the embryo early in pregnancy that maintains the corpus luteum so that it will continue to secrete hormones

**human immunodeficiency virus (HIV)** The virus that causes AIDS

**hydrocephalus** (hi-dro-SEF-ah-lus) Increased accumulation of CSF in or around the brain as a result of obstructed flow; may be caused by tumor, inflammation, hemorrhage, or congenital abnormality

**hydronephrosis** (hi-dro-nef-RO-sis) Collection of urine in the renal pelvis caused by obstruction; results in distention and renal atrophy

**hydrothorax** (hi-dro-THOR-aks) Presence of fluid in the pleural space

**hyperglycemia** (hi-per-gli-SE-me-ah) Excess glucose in the blood

**hyperkalemia** (hi-per-kah-LE-me-ah) Excess amount of potassium in the blood

**hyponatremia** (hi-per-nah-TRE-me-ah) Excess amount of sodium in the blood

**hyperopia** (hi-per-O-pe-ah) A refractive error in which light rays focus behind the retina and objects can be seen clearly only when far from the eye; farsightedness; also called hypermetropia

**hypersensitivity** (hi-per-sen-sih-TIV-ih-te) An immunologic reaction to a substance that is harmless to most people; allergy

**hypertension** (hi-per-TEN-shun) A condition of higher-than-normal blood pressure; essential (primary, idiopathic) hypertension has no known cause

**hyperventilation** (hi-per-ven-tih-LA-shun) Increase in the rate and depth of breathing to above optimal levels, with blood carbon dioxide decreasing to levels below normal

**hypoglycemia** (hi-po-gli-SE-me-ah) Abnormally low level of glucose in the blood

**hypokalemia** (hi-po-kah-LE-me-ah) Deficiency of potassium in the blood

**hyponatremia** (hi-po-nah-TRE-me-ah) Deficiency of sodium in the blood

**hypophysis** (hi-POF-ih-sis) The pituitary gland; named from *hypo*, meaning “below,” and *physis*, meaning “growing,” because the gland develops below the hypothalamus (root: *hypophysi/o*)

**hypoproteinemia** (hi-po-pro-te-NE-me-ah) Decreased amount of protein in the blood; may be caused by kidney damage resulting in protein loss

**hypothalamus** (hi-po-THAL-ah-mus) A portion of the brain that controls the pituitary gland, produces hormones, and is active in maintaining homeostasis

**hypothalamus** (hi-po-THAL-ah-mus) The part of the brain that controls the pituitary gland and maintains homeostasis

**hypoventilation** (hi-po-ven-tih-LA-shun) Condition in which the amount of air entering the alveoli is insufficient to meet metabolic needs and blood carbon dioxide increases to levels above normal

**hysterectomy** (his-ter-EK-to-me) Surgical removal of the uterus; most commonly done because of tumors; often the uterine tubes and ovaries are removed as well

## I

**icterus** (IK-ter-us) Jaundice

**ileal conduit** (IL-e-al KON-du-it) Diversion of urine by connection of the ureters to an isolated segment of the ileum; one end of the segment is sealed, and the other drains through an opening in the abdominal wall; a procedure used when the bladder is removed or non-functional; also called ileal bladder

**ileum** (IL-e-um) The terminal portion of the small intestine (root: *ile/o*)

**ileus** (IL-e-us) Intestinal obstruction; may be caused by lack of peristalsis (adynamic, paralytic ileus) or by contraction (dynamic ileus); intestinal matter and gas may be relieved by insertion of a drainage tube

**ilium** (IL-e-um) The large, flared, superior portion of the pelvic bone (root: *ili/o*) (adjective: *iliac*)

**immunity** (ih-MU-nih-te) The state of being protected against a disease (root: *immun/o*)

**immunodeficiency** (im-u-no-de-FISH-en-se) A congenital or acquired failure of the immune system to protect against disease

**immunoglobulin (Ig)** (im-u-no-GLOB-u-lin) An antibody; immunoglobulins fall into five classes, each abbreviated with a capital letter: IgG, IgM, IgA, IgD, IgE

**immunotherapy** (im-u-no-THER-ah-pe) Treatment that involves stimulation or suppression of the immune system, either specifically or nonspecifically

**impotence** (IM-po-tens) Erectile dysfunction

**incision** (in-SIZH-un) A cut, as for surgery; also the act of cutting (suffix: *-tomy*)

**incus** (ING-kus) The middle ossicle of the ear

**infarct** (in-FARKT) An area of localized tissue necrosis (death) resulting from a blockage or a narrowing of the artery that supplies the area

**inferior vena cava** (VE-nah KA-vah) The large inferior vein that brings blood low in oxygen back to the right atrium of the heart from the lower body

**infertility** (in-fer-TIL-ih-te) Decreased capacity to produce offspring

**inflammation** (in-flah-MA-shun) A localized response to tissue injury characterized by heat, pain, redness, and swelling

**influenza** (in-flu-EN-zah) An acute, contagious respiratory infection causing fever, chills, headache, and muscle pain; “flu”

**inguinal canal** (ING-gwin-al) The channel through which the testis descends into the scrotum in the male

**inguinal hernia** (ING-gwin-al) Protrusion of the intestine or other abdominal organ through the inguinal canal or through the wall of the abdomen into the scrotum

**insertion** (in-SER-shun) In a given movement, the point where a muscle is attached to a moving part of the skeleton

**insomnia** (in-SOM-nee-ah) Insufficient or nonrestorative sleep despite ample opportunity to sleep

**inspection** (in-SPEK-shun) Visual examination of the body

**inspiration** (in-spih-RA-shun) The act of drawing air into the lungs; inhalation

**insulin shock** A condition resulting from an overdose of insulin, causing hypoglycemia

**integumentary system** (in-teg-u-MEN-tah-re) The skin and its associated glands, hair, and nails

**interneuron** (in-ter-NU-ron) Any neuron located between a sensory and a motor neuron in a neural pathway, such as the neurons that transmit impulses within the CNS

**interstitial cells** (in-ter-STISH-al) Cells located between the seminiferous tubules of the testes that produce hormones, mainly testosterone; also called cells of Leydig (LI-dig)

**intestine** (in-TES-tin) The portion of the digestive tract between the stomach and the anus; it consists of the small and large intestines; it functions in digestion, absorption, and elimination of waste (root: enter/o); the bowel (BOW-el)

**intravenous pyelography (IVP)** (in-trah-VE-nus pi-eh-LOG-rah-fe) Intravenous urography

**intravenous urography (IVU)** (in-trah-VE-nus u-ROG-rah-fe) Radiographic visualization of the urinary tract after intravenous administration of a contrast medium that is excreted in the urine; also called excretory urography or intravenous pyelography, although the latter is less accurate because the procedure shows more than just the renal pelvis

**intrinsic factor** (in-TRIN-sik) A substance produced in the stomach that aids in the intestinal absorption of vitamin B<sub>12</sub>, necessary for the manufacture of red blood cells; lack of intrinsic factor causes pernicious anemia

**intussusception** (in-tuh-suh-SEP-shun) Slipping of one intestinal segment into another part below it; occurs mainly in male infants in the ileocecal region; may be fatal if untreated for more than 1 day

**iris** (I-ris) The muscular colored ring between the lens and the cornea; regulates the amount of light that enters the eye by altering the size of the pupil at its center (roots: ir, irid/o, irit/o) (plural: irides [IR-ih-deze])

**ischemia** (is-KE-me-ah) Local deficiency of blood supply caused by circulatory obstruction (root: hem/o)

## J

**jaundice** (JAWN-dis) A yellowish color of the skin, mucous membranes, and whites of the eye caused by bile pigments in the blood (from French *jaune* meaning “yellow”); the main pigment is bilirubin, a byproduct of erythrocyte destruction

**jejunum** (jeh-JU-num) The middle portion of the small intestine (root: jejun/o)

**joint** The junction between two bones; articulation (root: arthr/o)

## K

**Kaposi sarcoma** (KAP-o-se) Cancerous lesion of the skin and other tissues, seen most often in patients with AIDS

**karyotype** (KAR-e-o-tipe) A picture of cellular chromosomes arranged in the order of decreasing size; can reveal abnormalities in the chromosomes themselves or in their number or arrangement (root kary/o means “nucleus”)

**keloid** (KE-loyd) A raised, thickened scar caused by tissue overgrowth during scar formation

**keratin** (KER-ah-tin) A protein that thickens and toughens the skin and makes up hair and nails (root: kerat/o)

**ketoacidosis** (ke-to-as-ih-DO-sis) Acidosis (increased acidity of body fluids) caused by excess ketone bodies, as in diabetes mellitus; diabetic acidosis

**kidney** (KID-ne) An organ of excretion (roots: ren/o, nephro/); the two kidneys filter the blood and form urine, which contains metabolic waste products and other substances as needed to regulate the water, electrolyte, and pH balance of body fluids

**kyphosis** (ki-FO-sis) An exaggerated curve of the spine in the thoracic region; hunchback, humpback

## L

**labia majora** (LA-be-ah mah-JOR-ah) The two large folds of skin that form the sides of the vulva (root labi/o means “lip”) (singular: labium majus)

**labia minora** (LA-be-ah mi-NOR-ah) The two small folds of skin within the labia majora (singular: labium minus)

**labyrinth** (LAB-ih-rinth) The inner ear, named for its complex structure, which resembles a maze

**lacrimal gland** (LAK-rih-mal) A gland above the eye that produces tears (roots: lacrim/o, dacry/o)

**lactation** (lak-TA-shun) The secretion of milk from the mammary glands

**lacteal** (lak-TELE) A lymphatic capillary in a villus of the small intestine; lacteals absorb digested fats into the lymph

**large intestine** (in-TES-tin) The terminal portion of the digestive tract, consisting of the cecum, colon, rectum, and anus; it stores and eliminates undigested waste material (feces)

**larynx** (LAR-inks) The enlarged, superior portion of the trachea that contains the vocal folds (root: laryng/o)

**laser** (LA-zer) A device that transforms light into a beam of intense heat and power; used for surgery and diagnosis

**L-dopa** (DO-pah) A drug used in the treatment of parkinsonism; levodopa

**left AV valve** The valve between the left atrium and the left ventricle; the mitral valve or bicuspid valve

**leiomyoma** (li-o-mi-O-mah) Benign tumor of smooth muscle, usually in the uterine wall (myometrium); in the uterus, may cause bleeding and pressure on the bladder or rectum; also called fibroid or myoma

- lens** (lenz) The transparent, biconvex structure in the anterior portion of the eye that refracts light and functions in accommodation (roots: lent/i, phak/o)
- lesion** (LE-zhun) A distinct area of damaged tissue, an injury, or wound
- leukemia** (lu-KE-me-ah) Malignant overgrowth of immature white blood cells; may be chronic or acute; may affect bone marrow (myelogenous leukemia) or lymphoid tissue (lymphocytic leukemia)
- leukocyte** (LU-ko-site) A white blood cell (roots: leuk/o, leukocyt/o)
- leukoplakia** (lu-ko-PLA-ke-ah) White patches on mucous membranes, as on the tongue or cheeks, often resulting from smoking or other irritants; may be precancerous
- levodopa** See L-dopa
- ligament** (LIG-ah-ment) A strong band of connective tissue that joins one bone to another
- lingual tonsils** (LING-gwal) Small mounds of lymphoid tissue at the posterior of the tongue
- lipid** (LIP-id) A category of organic compounds that includes fats (root: lip/o)
- lipoprotein** (lip-o-PRO-tene) A compound of protein with lipid; lipoproteins are classified according to density as very low-density (VLDL), low-density (LDL), and high-density (HDL); relatively higher levels of HDLs have been correlated with cardiovascular health
- lithotomy** (lith-OT-o-me) Incision of an organ to remove a stone (calculus)
- lithotripsy** (LITH-o-trip-se) Crushing of a stone
- liver** (LIV-er) The large gland in the upper right abdomen; in addition to many other functions, it secretes bile needed for digestion and absorption of fats (root: hepat/o)
- lordosis** (lor-DO-sis) An exaggerated curve of the spine in the lumbar region; swayback
- lower esophageal sphincter (LES)** (e-sof-ah-JE-al SFINK-ter) Muscle tissue at the distal end of the esophagus (gastroesophageal junction) that prevents stomach contents from refluxing into the esophagus; also called the cardiac sphincter
- lumbar puncture** Puncture of the subarachnoid space in the lumbar region of the spinal cord to remove spinal fluid for diagnosis or to inject anesthesia; spinal tap
- lung** A cone-shaped, spongy respiratory organ contained within the thorax (roots: pneum/o, pulm/o)
- lung scan** Study based on the accumulation of radioactive isotopes in lung tissue; a ventilation scan measures ventilation after inhalation of radioactive material; a perfusion scan measures blood supply to the lungs after injection of radioactive material; also called a pulmonary scintiscan
- lupus erythematosus (LE)** (LU-pus er-ih-the-mah-TO-sis) A chronic, inflammatory, autoimmune disease of connective tissue that often involves the skin; types include the more widespread systemic lupus erythematosus (SLE) and a discoid form (DLE) that involves only the skin
- luteinizing hormone (LH)** (LU-te-in-i-zing) A hormone secreted by the anterior pituitary that acts on the gonads; in males, it stimulates the interstitial cells to produce testosterone; in females, it stimulates ovulation and corpus luteum formation
- lymph** (limf) The thin, plasma-like fluid that drains from the tissues and is transported in lymphatic vessels (root: lymph/o)
- lymph node** A small mass of lymphoid tissue along the path of a lymphatic vessel that filters lymph (root: lymphaden/o)
- lymphadenitis** (lim-fad-eh-NI-tis) Inflammation and enlargement of lymph nodes, usually as a result of infection
- lymphadenopathy** (lim-fad-eh-NOP-ah-the) Any disease of the lymph nodes
- lymphangitis** (lim-fan-JI-tis) Inflammation of lymphatic vessels as a result of bacterial infection; appears as painful red streaks under the skin
- lymphatic system** (lim-FAT-ik) The system that drains fluid and proteins from the tissues and returns them to the bloodstream; this system also participates in immunity and aids in absorption of fats from the digestive tract
- lymphedema** (lim-feh-DE-mah) Swelling of tissues with lymph caused by obstruction or excision of lymphatic vessels
- lymphocyte** (LIM-fo-site) An agranular leukocyte active in immunity (T and B cells); found in both the blood and in lymphoid tissue (roots: lymph/o, lymphocyt/o)
- lymphoma** (lim-FO-mah) Any neoplastic disease of lymphoid tissue

## M

- macula** (MAK-u-lah) A small spot or colored area; used alone to mean the yellowish spot in the retina that contains the fovea
- malignant** (mah-LIG-nant) Growing worse, harmful, tending to cause death, describing an invasive tumor that can spread (metastasize) to other tissues
- malleus** (MAL-e-us) The ossicle of the middle ear that is in contact with the tympanic membrane and the incus
- mammary gland** (MAM-ah-re) Specialized gland capable of secreting milk in the female (roots: mamm/o, mast/o); the breast
- mammography** (mam-OG-rah-fe) Radiographic study of the breast for the detection of breast cancer; the image obtained is a mammogram
- mania** (MA-ne-ah) A state of elation, which may include agitation, hyperexcitability, or hyperactivity (adjective: manic)
- massage** (ma-SAHJ) Manipulation of the body or portion of the body to calm, relieve tension, increase circulation, and stimulate muscles
- mastectomy** (mas-TEK-to-me) Excision of breast tissue to eliminate malignancy
- mastication** (mas-tih-KA-shun) Chewing
- mastitis** (mas-TI-tis) Inflammation of the breast, usually associated with the early weeks of breast-feeding
- mediastinum** (me-de-as-TI-num) The space between the lungs together with the organs contained in this space
- meditation** (med-ih-TA-shun) Process of clearing the mind by concentrating on the inner self while controlling

breathing and perhaps repeating a word or phrase (mantra)

**medulla oblongata** (meh-DUL-lahob-long-GAH-tah) The portion of the brain that connects with the spinal cord; it has vital centers for control of respiration, heart rate, and blood pressure (root: medull/o); often called simply medulla

**megakaryocyte** (meg-ah-KAR-e-o-site) A large bone marrow cell that fragments to release platelets

**meiosis** (mi-O-sis) The type of cell division that forms the gametes; it results in cells with 23 chromosomes, half the number found in other body cells (from the Greek word meiosis meaning “diminution”)

**melanin** (MEL-ah-nin) A dark pigment that gives color to the hair and skin and protects the skin against the sun’s radiation (root: melan/o)

**melanoma** (mel-ah-NO-mah) A metastasizing pigmented skin tumor that arises from melanocytes; malignant melanoma

**membrane** (MEM-brane) A simple, very thin, and pliable sheet of tissue that might cover an organ, line a cavity, or separate structures

**menarche** (men-AR-ke) The first menstrual period, which normally occurs during puberty

**Ménière disease** (men-NYARE) A disease associated with increased fluid pressure in the inner ear and characterized by hearing loss, vertigo, and tinnitus

**meninges** (men-IN-jeze) The three membranes that cover the brain and spinal cord (singular: meninx) (roots: mening/o, meninge/o)

**meningioma** (men-nin-je-O-mah) Tumor of the meninges

**meningitis** (men-in-JI-tis) Inflammation of the meninges

**menopause** (MEN-o-pawz) Cessation of menstrual cycles in the female

**menstruation** (men-stru-A-shun) The cyclic discharge of blood and mucosal tissues from the lining of the non-pregnant uterus (roots: men/o, mens); menstrual period, menses (MEN-seze)

**metabolic syndrome** A state of hyperglycemia caused by cellular resistance to insulin, as seen in type 2 diabetes, in association with other metabolic disorders; also called syndrome X or insulin resistance syndrome

**metabolism** (meh-TAB-o-lizm) The sum of all the physical and chemical reactions that occur within an organism

**metaphysis** (meh-TAF-ih-sis) The region of a long bone between the diaphysis (shaft) and epiphysis (end); during development, the growing region of a long bone

**metastasis** (meh-TAS-tah-sis) Spread from one part of the body to another, characteristic of cancer; verb is metastasize (meh-TAS-tah-size), adjective: metastatic (met-ah-STAT-ik); from Greek met/a (beyond, change) + stasis (stand)

**metrorrhagia** (me-tro-RA-je-ah) Uterine bleeding between normal menstrual periods

**microorganism** (mi-kro-OR-gan-izm) An organism too small to be seen without the aid of a microscope

**micturition** (mik-tu-RISH-un) The voiding of urine; urination

**midbrain** The part of the brainstem between the diencephalon and the pons; contains centers for coordination of reflexes for vision and hearing

**mitosis** (mi-TO-sis) Cell division

**mitral valve** (MI-tral) The valve between the left atrium and the left ventricle; the left AV valve or bicuspid valve

**monocyte** (MON-o-site) An agranular phagocytic leukocyte

**motor** Producing movement; describes efferent neurons and nerves that carry impulses away from the CNS

**mouth** The oral cavity; contains the tongue and teeth; used to take in and chew food, mix it with saliva, and move it toward the throat to be swallowed

**mucus** (MU-kus) A thick fluid secreted by cells in membranes and glands that lubricates and protects tissues (roots: muc/o, myx/o); the adjective is mucous

**multi-infarct dementia (MID)** Dementia caused by chronic cerebral ischemia (lack of blood supply) as a result of multiple small strokes; there is progressive loss of cognitive function, memory, and judgment as well as altered motor and sensory function

**multiple myeloma** (mi-eh-LO-mah) A tumor of the blood-forming tissue in bone marrow

**multiple sclerosis (MS)** A chronic, progressive disease involving loss of myelin in the CNS

**murmur** An abnormal heart sound

**muscle** (MUS-el) An organ that produces movement by contracting; also the tissue that composes such organs (roots: my/o, muscul/o)

**muscular dystrophy** (DIS-tro-fe) A group of hereditary muscular disorders marked by progressive weakness and muscular atrophy

**mutation** (mu-TA-shun) A change in the genetic material of the cell; most mutations are harmful; if the change appears in the sex cells, it can be passed to future generations

**myasthenia gravis (MG)** (mi-as-THE-ne-ah GRAH-vis) A disease characterized by progressive muscular weakness; an autoimmune disease affecting the neuromuscular junction

**myelin** (MI-eh-lin) A whitish, fatty substance that surrounds certain axons of the nervous system

**myocardial infarction (MI)** (mi-o-KAR-de-al in-FARK-shun) Localized necrosis (death) of cardiac muscle tissue resulting from blockage or narrowing of the coronary artery that supplies that area; myocardial infarction is usually caused by formation of a thrombus (clot) in a vessel

**myocardium** (mi-o-KAR-de-um) The thick middle layer of the heart wall composed of cardiac muscle

**myometrium** (mi-o-ME-tre-um) The muscular wall of the uterus

**myopia** (mi-O-pe-ah) A refractive error in which light rays focus in front of the retina and objects can be seen clearly only when very close to the eye; nearsightedness

**myosin** (MI-o-sin) One of the two contractile proteins in muscle cells; the other is actin

**myringotomy** (mir-in-GOT-o-me) Surgical incision of the tympanic membrane; performed to drain the middle ear

cavity or to insert a tube into the tympanic membrane for drainage

## N

- nail** (nale) A plate-like keratinized outgrowth of the skin that covers the dorsal surface of the terminal phalanges (root: onych/o)
- narcolepsy** (NAR-ko-lep-se) Brief, uncontrollable episodes of sleep during the day
- naturopathy** (na-chur-OP-ah-the) A therapeutic philosophy of helping people heal themselves by developing healthy lifestyles; naturopaths may use some of the methods of conventional medicine (from nature and path/o, meaning “disease”)
- nausea** (NAW-zhah) An unpleasant sensation in the upper abdomen that often precedes vomiting; typically occurs in digestive upset, motion sickness, and sometimes early pregnancy
- necrosis** (neh-KRO-sis) Death of tissue (root necr/o means “death”); adjective: necrotic (neh-KROT-ik)
- neoplasia** (ne-o-PLA-ze-ah) An abnormal and uncontrolled growth of tissue; from prefix neo- meaning “new” and root plasm meaning “formation”
- neoplasm** (NE-o-plazm) A tumor, or abnormal growth, which may be benign or malignant (root onc/o and suffix -oma refer to neoplasms)
- nephron** (NEF-ron) A microscopic functional unit of the kidney; working with blood vessels, the nephron filters the blood and balances the composition of urine
- nephrotic syndrome** (nef-ROT-ik) Condition that results from glomerular damage leading to loss of protein in the urine (proteinuria); there is low plasma protein (hypoproteinemia), edema, and increased blood lipids as the liver releases lipoproteins; also called nephrosis
- nerve** A bundle of neuron fibers outside the CNS (root: neur/o)
- neurilemmoma** (nu-rih-lem-O-mah) A tumor of a peripheral nerve sheath (neurilemma); schwannoma
- neuroglia** (nu-ROG-le-ah) The support cells of the nervous system; also called glial cells (from glia meaning “glue”) (root: gli/o)
- neuromuscular junction (NMJ)** (nu-ro-MUS-ku-lar JUNK-shun) The point of contact, or synapse, between a branch of a motor neuron and a muscle cell
- neuron** (NU-ron) The basic unit of the nervous system; a nerve cell
- neurotransmitter** (nu-ro-TRANS-mit-er) A chemical that transmits energy across a synapse; examples are norepinephrine (nor-ep-ih-NEF-rin), acetylcholine (ah-setil-KO-lene), serotonin (ser-o-TO-nin), and dopamine (DO-pah-mene)
- neutrophil** (NU-tro-fil) A granular leukocyte that stains weakly with both acidic and basic dyes; the most numerous of the white blood cells; a type of phagocyte
- non-Hodgkin lymphoma (NHL)** A widespread malignant disease of lymph nodes that involves lymphocytes; it differs from Hodgkin disease in that giant Reed–Sternberg cells are absent
- nonsteroidal antiinflammatory drug (NSAID)** Drug that reduces inflammation but is not a steroid; examples include aspirin and ibuprofen and other inhibitors of prostaglandins, naturally produced substances that promote inflammation
- nose** The organ of the face used for breathing and housing receptors for the sense of smell; includes an external portion and an internal nasal cavity (roots: nas/o, rhin/o)
- nucleus** (NU-kle-us) The cell’s control center; directs all cellular activities based on the information contained in its chromosomes (roots: nucle/o, kary/o)
- nutritional anemia** (nu-TRISH-un-al) Anemia resulting from a dietary deficiency, usually of iron, vitamin B<sub>12</sub>, or folate

## O

- obsessive–compulsive disorder (OCD)** (ob-SES-iv kom-PUL-siv) A condition associated with recurrent and intrusive thoughts, images, and repetitive behaviors performed to relieve anxiety
- occlusion** (o-KLU-zhun) A closing off or obstruction, as of a vessel
- occult blood** (o-KULT) Blood present in such small amounts that it can be detected only microscopically or chemically; in the feces, a sign of intestinal bleeding (occult means “hidden”)
- olfaction** (ol-FAK-shun) The sense of smell (root osm/o means “smell”)
- oliguria** (ol-ig-U-re-ah) Elimination of small amounts of urine
- oophorectomy** (o-of-o-REK-to-me) Excision of an ovary
- ophthalmia neonatorum** (of-THAL-me-ah ne-o-na-TOR-um) Severe conjunctivitis usually caused by infection with gonococcus during birth
- ophthalmoscope** (of-THAL-mo-skope) An instrument for examining the interior of the eye
- optic disk** The point where the optic nerve joins the retina; at this point, there are no rods or cones; also called the blind spot or optic papilla
- orbit** (OR-bit) The bony cavity that contains the eyeball
- orchitis** (or-KI-tis) Inflammation of a testis; may be caused by injury, mumps virus, or other infections
- organ** (OR-gan) A part of the body with a specific function, a component of a body system
- organelle** (OR-gah-nel) A specialized structure in the cytoplasm of a cell
- origin** (OR-ih-jin) In a given movement, the point where a muscle is attached to a stable part of the skeleton
- orthopedics** The study and treatment of disorders of the skeleton, muscles, and associated structures; literally “straight” (ortho) “child” (ped); also spelled orthopaedics
- ossicles** (OS-ih-klz) The small bones of the middle ear; the malleus, incus, and stapes
- ossification** (os-ih-fih-KA-shun) The formation of bone tissue (from Latin os, meaning “bone”)
- osteoarthritis (OA)** (os-te-o-ar-THRI-tis) Progressive deterioration of joint cartilage with growth of new bone and soft tissue in and around the joint; the most common form of arthritis; results from wear and tear,



injury, or disease; also called degenerative joint disease (DJD)

**osteoblast** (OS-te-o-blast) A cell that produces bone tissue

**osteoclast** (OS-te-o-clast) A cell that destroys bone tissue

**osteocyte** (OS-te-o-site) A mature bone cell that nourishes and maintains bone tissue

**osteogenic sarcoma** (os-te-o-JEN-ik) A malignant bone tumor; osteosarcoma

**osteomalacia** (os-te-o-mah-LA-she-ah) A softening and weakening of the bones due to vitamin-D deficiency or other disease

**osteomyelitis** (os-te-o-mi-eh-LI-tis) Inflammation of bone and bone marrow caused by infection, usually bacterial

**osteopathy** (os-te-OP-ah-the) A system of therapy based on the theory that the body can overcome disease when it has normal structure, a favorable environment, and proper nutrition; osteopaths use standard medical practices for diagnosis and treatment but stress the identification and correction of faulty body structure (from oste/o, meaning “bone,” and path/o, meaning “disease”)

**osteopenia** (os-te-o-PE-ne-ah) A lower-than-average bone density, which may foreshadow osteoporosis

**osteoporosis** (os-te-o-po-RO-sis) A condition characterized by reduction in bone density, most common in white women past menopause; predisposing factors include poor diet, inactivity, and low estrogen levels

**ostomy** (OS-to-me) An opening into the body; generally refers to an opening created for elimination of body waste; also refers to the operation done to create such an opening (see stoma)

**otitis externa** (o-TI-tis ex-TER-nah) Inflammation of the external auditory canal; swimmer’s ear

**otitis media** (o-TI-tis ME-de-ah) Inflammation of the middle ear with accumulation of serous (watery) or mucoid fluid

**otosclerosis** (o-to-skleh-RO-sis) Formation of abnormal and sometimes hardened bony tissue in the ear; it usually occurs around the oval window and the footplate (base) of the stapes, causing immobilization of the stapes and progressive hearing loss

**otoscope** (O-to-sko-pe) Instrument used to examine the ears

**ovarian follicle** (o-VAR-e-an FOL-ih-kl) The cluster of cells in which the ovum ripens in the ovary

**ovary** (O-vah-re) A female gonad (roots: ovari/o, oophor/o)

**ovulation** (ov-u-LA-shun) The release of a mature ovum from the ovary (from ovule, meaning “little egg”)

**ovum** (O-vum) The female gamete or reproductive cell (roots: oo, ov/o) (plural: ova)

**oxygen (O<sub>2</sub>)** (OK-sih-jen) The gas needed by cells to release energy from food during metabolism

**oxytocin** (ok-se-TO-sin) A pituitary hormone that stimulates contractions of the uterus; it also stimulates release (“letdown”) of milk from the breasts

## P

**Paget disease** (PAJ-et) Skeletal disease of the elderly characterized by bone thickening and distortion with bowing of long bones; osteitis deformans

**palate** (PAL-at) The roof of the mouth; the partition between the mouth and nasal cavity; consists of an anterior portion formed by bone, the hard palate, and a posterior portion formed of tissue, the soft palate (root: palat/o)

**palatine tonsils** (PAL-ah-tine) The paired masses of lymphoid tissue located on either side of the oropharynx; usually meant when the term tonsils is used alone

**palliative therapy** (PAL-e-ah-tiv) Providing relief but not cure; a treatment that provides such relief

**palpation** (pal-PA-shun) Examining by placing the hands or fingers on the surface of the body to determine characteristics such as texture, temperature, movement, and consistency

**palpebra** (PAL-peh-brah) An eyelid; a protective fold (upper or lower) that closes over the anterior surface of the eye (roots: palpebr/o, blephar/o) (adjective: palpebral) (plural: palpebrae [pal-PE-bre])

**pancreas** (PAN-kre-as) A large, elongated gland posterior to the stomach; it produces hormones that regulate sugar metabolism and also produces digestive enzymes (root: pancreat/o)

**pancreatic islet** (I-let) Cluster of endocrine cells in the pancreas that secretes hormones to regulate glucose metabolism; also called islet of Langerhans or islet cells (root insul/o means “island”)

**pancreatitis** (pan-kre-ah-TI-tis) Inflammation of the pancreas

**panhypopituitarism** (pan-hi-po-pih-TU-ih-tah-rism) Underactivity of the entire pituitary gland

**panic disorder** A form of anxiety disorder marked by episodes of intense fear

**Pap smear** Study of cells collected from the cervix and vagina for early detection of cancer; also called Papanicolaou smear or Pap test

**para** Woman who has produced a viable infant; multiple births are considered as single pregnancies

**paralysis** (pah-RAL-ih-sis) Temporary or permanent loss of function; flaccid paralysis involves loss of muscle tone and reflexes and muscular degeneration; spastic paralysis involves excess muscle tone and reflexes but no degeneration

**paranoia** (par-ah-NOY-ah) A mental state characterized by jealousy, delusions of persecution, or perceptions of threat or harm

**parasite** (PAR-ah-site) An organism that grows on or in another organism (the host), causing damage to it

**parasympathetic nervous system** (par-ah-sim-pah-THET-ik) The part of the autonomic nervous system that reverses the response to stress and restores homeostasis; it slows heart rate and respiration rate and stimulates digestive, urinary, and reproductive activities

**parathyroid gland** (par-ah-THI-royd) A small endocrine gland on the posterior thyroid that acts to increase blood calcium levels; there are usually four to six parathyroid glands (roots: parathyr/o, parathyroid/o); the name literally means “near the thyroid”

**parkinsonism** (PAR-kin-son-izm) A disorder originating in the brain’s basal ganglia (nuclei) and characterized by

slow movements, tremor, rigidity, and mask-like face; also called Parkinson disease

**parturition** (par-tu-RIH-shun) Childbirth (root: nat/i); labor (root: toc/o)

**patent ductus arteriosus** (PA-tent DUK-tus ar-tere-e-O-sus) Persistence of the ductus arteriosus after birth; the ductus arteriosus is a vessel that connects the pulmonary artery to the descending aorta in the fetus to bypass the lungs

**pathogen** (PATH-o-jen) An organism capable of causing disease (root path/o means “disease”)

**pelvic cavity** (PEL-vik) The ventral cavity that is below the abdominal cavity

**pelvic inflammatory disease (PID)** Condition caused by the spread of infection from the reproductive tract into the pelvic cavity; commonly caused by sexually transmitted gonorrhea and Chlamydia infections

**pelvis** (PEL-vis) The large ring of bone at the inferior trunk formed of the two hip bones (ossa coxae) joined to the sacrum and coccyx; each os coxae is formed of three bones: the superior, flared ilium (IL-e-um); ischium (IS-ke-um); and pubis (PU-bis) (plural: pelves [PEL-veze])

**pemphigus** (PEM-fih-gus) An autoimmune disease of the skin characterized by sudden, intermittent formation of bullae (blisters); may be fatal if untreated

**penis** (PE-nis) The male organ of copulation and urination (adjective: penile)

**peptic ulcer** (PEP-tik UL-ser) A lesion in the mucous membrane of the esophagus, stomach, or duodenum caused by the action of gastric juice

**percussion** (per-KUSH-un) Tapping the body lightly but sharply to assess the condition of the underlying tissue by the sounds obtained

**percutaneous transluminal coronary angioplasty (PTCA)** Dilatation of a sclerotic blood vessel by means of a balloon catheter inserted into the vessel and then inflated to flatten plaque against the arterial wall

**pericardium** (per-ih-KAR-de-um) The fibrous sac that surrounds the heart

**perineum** (per-ih-NE-um) The region between the thighs from the external genitalia to the anus (root: perine/o)

**periosteum** (per-e-OS-te-um) The fibrous membrane that covers a bone’s surface

**peripheral nervous system (PNS)** (per-IF-er-al) The portion of the nervous system outside the CNS

**peristalsis** (per-ih-STAL-sis) Wave-like contractions of an organ’s walls; moves material through an organ or duct

**peritoneal dialysis** (per-ih-to-NE-al di-AL-ih-sis) Removal of unwanted substances from the body by introduction of a dialyzing fluid into the peritoneal cavity followed by removal of the fluid

**peritoneum** (per-ih-to-NE-um) The large serous membrane that lines the abdominal cavity and supports the abdominal organs

**peritonitis** (per-ih-to-NI-tis) Inflammation of the peritoneum, the membrane that lines the abdominal cavity and covers the abdominal organs; may result from perforation of an ulcer, ruptured appendix, or reproductive tract infection, among other causes

**pernicious anemia** (per-NISH-us) Anemia caused by failure of the stomach to produce intrinsic factor, a substance needed for the absorption of vitamin B<sub>12</sub>; this vitamin is required for the formation of erythrocytes

**pertussis** (per-TUS-is) An acute, infectious disease characterized by a cough ending in a whooping inspiration; whooping cough

**petechiae** (pe-E-ke-e) Pinpoint, flat, purplish-red spots caused by bleeding within the skin or mucous membrane (singular: petechia)

**Peyer patches** (PI-er) Aggregates of lymphoid tissue in the lining of the intestine

**phacoemulsification** (fak-o-e-MUL-sih-fih-ka-shun) Removal of a cataract by ultrasonic destruction and extraction of the lens

**phagocytosis** (fag-o-si-TO-sis) The ingestion of organisms, such as invading bacteria or small particles of waste material by a cell (root phag/o means “to eat”); the phagocytic cell, or phagocyte, then destroys the ingested material

**pharynx** (FAR-inks) The throat; a common passageway for food entering the esophagus and air entering the larynx (root: pharyng/o)

**Philadelphia chromosome (Ph)** An abnormal chromosome found in the cells of most individuals with chronic granulocytic (myelogenous) leukemia

**phlebitis** (fleh-BI-tis) Inflammation of a vein

**phobia** (FO-be-ah) An extreme, persistent fear of a specific object or situation

**phrenic nerve** (FREN-ik) The nerve that activates the diaphragm (root: phrenic/o)

**phytochemistry** (fi-to-MED-ih-sin) Another name for herbal medicine (root phyt/o meaning “plant”)

**pia mater** (PE-ah MA-ter) The innermost layer of the meninges

**pineal gland** (PIN-e-al) A small gland in the brain; appears to regulate mood, daily rhythms, and sexual development in response to environmental light; secretes the hormone melatonin

**pinna** (PIN-ah) The projecting part of the outer ear; auricle (AW-rih-kl)

**pituitary gland** (pih-TU-ih-tar-e) A small endocrine gland at the base of the brain; the anterior lobe secretes growth hormone and hormones that stimulate other glands; the posterior lobe releases ADH and oxytocin manufactured in the hypothalamus (root: pituitar/i); hypophysis

**pituitary gland** (pih-TU-ih-tar-e) An endocrine gland at the base of the brain

**placenta** (plah-SEN-tah) The organ composed of fetal and maternal tissues that nourishes and maintains the developing fetus

**placenta previa** (PRE-ve-ah) Placental attachment in the lower portion of the uterus instead of the upper portion, as is normal; may result in hemorrhage late in pregnancy

**placental abruption** (ab-RUP-shun) Premature separation of the placenta; abruptio placentae

- plaque** (plak) A patch; with regard to the cardiovascular system, a deposit of fatty material and other substances on a vessel wall that impedes blood flow and may block the vessel; atheromatous plaque
- plasma** (PLAZ-mah) The liquid portion of the blood
- plasma cell** A mature form of a B cell that produces antibodies
- platelet** (PLATE-let) A formed element of the blood that is active in hemostasis; a thrombocyte (root: thrombocyt/o)
- pleura** (PLURE-ah) A double-layered membrane that lines the thoracic cavity (parietal pleura) and covers the lungs (visceral pleura) (root: pleur/o)
- pleural effusion** (PLURE-al eh-FU-zhun) Accumulation of fluid in the pleural space; the fluid may contain blood (hemothorax) or pus (pyothorax or empyema)
- pleural space** The thin, fluid-filled space between the two layers of the pleura; pleural cavity
- pleurisy** (PLURE-ih-se) Inflammation of the pleura; pleuritis; a symptom of pleurisy is sharp pain on breathing
- pneumoconiosis** (nu-mo-ko-ne-O-sis) Disease of the respiratory tract caused by inhalation of dust particles; named more specifically by the type of dust inhaled, such as silicosis, anthracosis, asbestosis
- pneumonia** (nu-MO-ne-ah) Inflammation of the lungs generally caused by infection; may involve the bronchioles and alveoli (bronchopneumonia) or one or more lobes of the lung (lobar pneumonia)
- pneumonitis** (nu-mo-NI-tis) Inflammation of the lungs; may be caused by infection, asthma, allergy, or inhalation of irritants
- pneumothorax** (nu-mo-THOR-aks) Accumulation of air or gas in the pleural space; may result from injury or disease or may be produced artificially to collapse a lung
- polymyositis** (pol-e-mi-o-SI-tis) A disease of unknown cause involving muscular inflammation and weakness
- polyp** (POL-ip) A tumor that grows on a stalk and bleeds easily
- polysomnography** (pol-e-som-NOG-rah-fe) Simultaneous monitoring of a variety of physiologic functions during sleep to diagnose sleep disorders
- pons** (ponz) A rounded area on the ventral surface of the brainstem; contains fibers that connect brain regions (adjective: pontine [PON-tene])
- portal hypertension** An abnormal pressure increase in the hepatic portal system; may be caused by cirrhosis, infection, thrombosis, or a tumor
- posttraumatic stress disorder (PTSD)** Persistent emotional disturbances that follow exposure to life-threatening, catastrophic events, such as trauma, abuse, natural disasters, and warfare
- potentiation** (po-ten-she-A-shun) Increased potency created by two drugs acting together
- Pott disease** Inflammation of the vertebrae, usually caused by tuberculosis
- preeclampsia** (pre-eh-KLAMP-se-ah) A serious disorder involving new-onset hypertension and proteinuria that develops after 20 weeks of pregnancy. If untreated, may lead to eclampsia
- prefix** (PRE-fix) A word part added before a root to modify its meaning
- pregnancy-induced hypertension (PIH)** New-onset hypertension without proteinuria that develops during pregnancy
- prepuce** (PRE-pus) The fold of skin over the glans penis; the foreskin
- presbyopia** (prez-be-O-pe-ah) Changes in the eye that occur with age; the lens loses elasticity and the ability to accommodate for near vision
- prescription (Rx)** (pre-SKRIP-shun) Written and signed order for a drug with directions for its administration
- pressure ulcer** An ulcer caused by pressure to an area of the body, as from a bed or chair; decubitus (de-KU-bih-tus) ulcer, bedsore, pressure sore
- prime mover** The main muscle involved in a given movement
- progesterone** (pro-JES-ter-one) A hormone produced by the corpus luteum and the placenta that maintains the endometrium for pregnancy
- prognosis** (prog-NO-sis) Prediction of a disease's course and outcome
- prolapse** (PRO-laps) A dropping or downward displacement of an organ or part, ptosis
- proprioception** (pro-pre-o-SEP-shun) The awareness of posture, movement, and changes in equilibrium; receptors are located in muscles, tendons, and joints
- prostaglandins** (pros-tah-GLAN-dinz) A group of hormones produced throughout the body that have a variety of effects, including stimulation of uterine contractions and regulation of blood pressure, blood clotting, and inflammation
- prostate gland** (PROS-tate) A gland that surrounds the urethra below the bladder in males and contributes secretions to the semen (root: prostat/o)
- prostatectomy** (pros-tah-TEK-to-me) Surgical removal of the prostate
- prostatitis** (pros-tah-TI-tis) Inflammation of the prostate gland; often appears with UTI, STI, and a variety of other stresses
- protein** (PRO-tene) A category of organic compounds that includes structural materials, enzymes, and some hormones
- proteinuria** (pro-te-NU-re-ah) Presence of protein, mainly albumin, in the urine
- pruritus** (pru-RI-tus) Severe itching
- psoriasis** (so-RI-ah-sis) A chronic hereditary dermatitis with red lesions covered by silvery scales
- psychosis** (si-KO-sis) A mental disorder extreme enough to cause gross misperception of reality with delusions and hallucinations
- puberty** (PU-ber-te) Period during which the ability for sexual reproduction is attained and secondary sex characteristics begin to develop
- pulmonary artery** (PUL-mo-nar-e) The vessel that carries blood from the right side of the heart to the lungs
- pulmonary circuit** (SER-kit) The system of vessels that carries blood from the right side of the heart to the lungs to be oxygenated and then back to the left side of the heart

- pulmonary function tests** Tests done to assess breathing, usually by spirometry
- pulmonary valve** The valve at the entrance to the pulmonary artery
- pulmonary veins** The vessels that carry blood from the lungs to the left side of the heart
- pulmonary ventilation** (PUL-mo-nare-e ven-tih-LA-shun) The movement of air into and out of the lungs
- pulse** (puls) The wave of increased pressure produced in the vessels each time the ventricles contract
- pulse oximetry** (ok-SIM-eh-tre) Determination of the oxygen saturation of arterial blood by means of a photoelectric apparatus (oximeter), usually placed on the finger or the ear; reported as SpO<sub>2</sub> in percent
- pupil** (PU-pil) The opening at the center of the iris (root: pupil/o)
- Purkinje fibers** (pur-KIN-je) The terminal fibers of the cardiac conducting system; they carry impulses through the walls of the ventricles
- purpura** (PUR-pu-rah) A condition characterized by hemorrhages into the skin, mucous membranes, internal organs, and other tissues (from Greek word meaning “purple”); thrombocytopenic purpura is caused by a deficiency of platelets
- pus** A product of inflammation consisting of fluid and white blood cells (root: py/o)
- pyelonephritis** (pi-eh-lo-neh-FRI-tis) Inflammation of the renal pelvis and kidney, usually caused by infection
- pyloric stenosis** (pi-LOR-ik) Narrowing of the opening between the stomach and the duodenum; pylorostenosis
- pylorus** (pi-LOR-us) The stomach’s distal opening into the duodenum (root: pylor/o); the opening is controlled by a ring of muscle, the pyloric sphincter
- pyothorax** (pi-o-THOR-aks) Accumulation of pus in the pleural space; empyema
- pyuria** (pi-U-re-ah) Presence of pus in the urine
- R**
- radiography** (ra-de-OG-rah-fe) Use of x-rays passed through the body to make a visual record (radiograph) of internal structures either on specially sensitized film or digitally; roentgenography (rent-geh-NOG-rah-fe)
- receptor** (re-SEP-tor) A site on the cell membrane or within the cell to which a substance, such as a hormone, attaches
- rectouterine pouch** (rek-to-U-ter-in) A blind pouch, such as the recess between the rectum and the uterus; the cul-de-sac or pouch of Douglas
- rectum** (REK-tum) The distal portion of the large intestine; it stores and eliminates undigested waste (roots: rect/o, proct/o)
- reduction of a fracture** Return of a fractured bone to a normal position; may be closed (not requiring surgery) or open (requiring surgery)
- Reed-Sternberg cells** (rede SHTERN-berg) Giant cells that are characteristic of Hodgkin disease; they usually have two large nuclei and are surrounded by a halo
- reflex** (RE-fleks) A simple, rapid, and automatic response to a stimulus
- refraction** (re-FRAK-shun) The bending of light rays as they pass through the eye to focus on a specific point on the retina; also the determination and correction of ocular refractive errors
- regurgitation** (re-gur-jih-TA-shun) A backward flowing, such as the backflow of undigested food
- remission** (re-MISH-un) Lessening of disease symptoms; the period during which this decrease occurs or the period when no sign of a disease exists
- renal colic** (KOL-ik) Radiating pain in the region of the kidney associated with the passage of a stone
- renal cortex** (RE-nal KOR-tex) The kidney’s outer portion; contains portions of the nephrons
- renal failure** Loss of kidney function resulting from loss or damage to the kidney nephrons. May be chronic, developing over time, or acute, as a result of sudden damage, as by injury, shock, or toxins
- renal medulla** (meh-DUL-lah) The kidney’s inner portion; contains portions of the nephrons and ducts that transport urine toward the renal pelvis
- renal pelvis** (PEL-vis) The expanded upper end of the ureter that receives urine from the kidney (Greek root pyel/o means “basin”)
- renal pyramid** (PERE-ah-mid) A triangular structure in the renal medulla; composed of the nephrons’ loops and collecting ducts
- renal transplantation** Surgical implantation of a donor kidney into a patient
- renin** (RE-nin) An enzyme produced by the kidneys that activates angiotensin in the blood
- repetitive strain injury (RSI)** Tissue damage caused by repeated motion, usually overuse of the arm or hand in occupational activities such as writing, typing, painting, or using hand tools; also called repetitive motion injury, cumulative trauma injury, overuse syndrome
- repolarization** (re-po-lar-ih-ZA-shun) A return of electrical charge to the resting state in nerves or muscles
- resorption** (re-SORP-shun) Removal of bone by breakdown and absorption into the circulation
- respiratory distress syndrome (RDS)** A respiratory disorder that affects premature infants born without enough surfactant in the lungs; it is treated with respiratory support and surfactant administration
- reticulocyte counts** (re-TIK-u-lo-site) Blood counts of reticulocytes, a type of immature red blood cell; reticulocyte counts are useful in diagnosis to indicate the rate of erythrocyte formation
- retina** (RET-ih-nah) The innermost, light-sensitive layer of the eye; contains the rods and cones, the specialized receptor cells for vision (root: retin/o)
- retinal detachment** Separation of the retina from its underlying layer
- retrograde pyelography** (RET-ro-grade pi-eh-LOG-rah-fe) Pyelography in which the contrast medium is injected into the kidneys from below by way of the ureters
- rheumatic heart disease** (ru-MAT-ik) Damage to heart valves after infection with a type of Streptococcus (group A hemolytic Streptococcus); the antibodies produced in

response to the infection produce valvular scarring usually involving the mitral valve

**rheumatoid arthritis (RA)** (RU-mah-toyd) A chronic autoimmune disease of unknown origin resulting in inflammation of peripheral joints and related structures; more common in women than in men

**rheumatoid factor** A group of antibodies found in the blood in cases of rheumatoid arthritis and other systemic diseases

**ribonucleic acid (RNA)** (ri-bo-nu-KLE-ik) An organic compound involved in the manufacture of proteins within cells

**rickets** (RIK-ets) Faulty bone formation in children, usually caused by a deficiency of vitamin D

**right AV valve** The valve between the right atrium and right ventricle; the tricuspid valve

**right lymphatic duct** The lymphatic duct that drains fluid from the body's upper right side

**rod** A specialized cell in the retina that responds to light; rods have low visual acuity, function in dim light, and do not respond to color

**root** (rute) The fundamental unit of a word. A branch of a spinal nerve that connects with the spinal cord; the dorsal (posterior) root joins the spinal cord's dorsal gray horn; the ventral (anterior) root joins the spinal cord's ventral gray horn (root: radicul/o)

**rule of nines** A method for estimating the extent of body surface area involved in a burn by assigning percentages in multiples of nine to various body regions

## S

**sagittal plane** (SAJ-ih-tal) Plane that divides the body into right and left portions

**saliva** (sah-LI-vah) The clear secretion released into the mouth that moistens food and contains a starch-digesting enzyme (root: sial/o); saliva is produced by three pairs of glands: the parotid, submandibular, and sublingual glands

**salpingectomy** (sal-pin-JEK-to-e) Surgical removal of the uterine tube

**salpingitis** (sal-pin-JI-tis) Inflammation of a uterine tube, typically caused by urinary tract infection or sexually transmitted infection; chronic salpingitis may lead to infertility or ectopic pregnancy (development of the fertilized egg outside of the uterus)

**sarcoma** (sar-KO-mah) A malignant neoplasm arising from connective tissue (from Greek root sarco, meaning "flesh"); adjective: sarcomatous

**schizophrenia** (skiz-o-FRE-ne-ah) A poorly understood group of severe mental disorders with features of psychosis, delusions, hallucinations, and withdrawn or bizarre behavior (schizo means "split," and phren/o means "mind")

**sciatica** (si-AT-ih-kah) Severe pain in the leg along the course of the sciatic nerve, usually related to spinal nerve root irritation

**sclera** (SKLE-rah) The tough, white, fibrous outermost layer of the eye; the white of the eye (root: scler/o)

**scleroderma** (sklere-o-DER-mah) A chronic disease that is characterized by thickening and tightening of the skin

and that often involves internal organs in a form called progressive systemic sclerosis (PSS)

**scoliosis** (sko-le-O-sis) A sideways curvature of the spine in any region

**scrotum** (SKRO-tum) A double pouch that contains the testes (root: osche/o)

**sebaceous gland** (se-BA-shus) A skin gland that produces sebum; usually associated with a hair follicle (root: seb/o)

**sebum** (SE-bum) A fatty secretion of the sebaceous glands that lubricates the hair and skin (root: seb/o)

**seizure** (SE-zhur) A sudden attack, as seen in epilepsy; the most common forms of seizure are tonic-clonic, or grand mal (gran mal) (from French, meaning "great illness"); absence seizure, or petit mal (pet-E mal), meaning "small illness"; and psychomotor seizure

**selective estrogen receptor modulator (SERM)** Drug that acts on estrogen receptors; raloxifene (Evista) is used to prevent bone loss after menopause; other SERMs are used to prevent and treat estrogen-sensitive breast cancer

**semen** The thick secretion that transports spermatozoa (roots: semin, sperm/i, spermat/o)

**semicircular canals** The three curved channels of the inner ear that hold receptors for equilibrium

**seminal vesicle** (SEM-ih-nal VES-ih-kl) A sac-like gland behind the bladder that contributes secretions to the semen (root: vesicul/o)

**sensorineural hearing loss** (sen-so-re-NU-ral) Hearing impairment that results from damage to the inner ear, eighth cranial nerve, or auditory pathways in the brain

**sensory** (SEN-so-re) Pertaining to the senses or sensation; describing afferent neurons and nerves that carry impulses toward the CNS

**sensory receptor** (re-SEP-tor) A sensory nerve ending or a specialized structure associated with a sensory nerve that responds to a stimulus

**sentinel node biopsy** (SEN-tih-nel) Biopsy of the first lymph nodes to receive drainage from a tumor; used to determine spread of cancer in planning treatment

**sepsis** (SEP-sis) The presence of harmful microorganisms or their toxins in the blood or other tissues; adjective: septic

**septal defect** (SEP-tal) An opening in the septum between the atria or ventricles; a common cause is persistence of the foramen ovale (for-A-men o-VAL-e), an opening between the atria that bypasses the lungs in fetal circulation

**septum** (SEP-tum) A wall dividing two cavities, such as two chambers of the heart

**Sertoli cell** (ser-TO-le) Cell in a seminiferous tubule that aids in the development of spermatozoa; sustentacular (sus-ten-TAK-u-lar) cell

**serum** (SERE-um) The fraction of the plasma that remains after blood coagulation; it is the equivalent of plasma without its clotting factors (plural: sera, serums)

**sexually transmitted infection (STI)** Infection spread through sexual activity; also called sexually transmitted disease (STD) and formerly venereal (veh-NE-re-al) disease (VD) (from Venus, the goddess of love)

- shingles** An acute viral infection that follows nerve pathways causing small lesions on the skin; caused by reactivation of the virus that also causes chickenpox (varicella-zoster virus); also called herpes zoster (HER-peze ZOS-ter)
- shock** Circulatory failure resulting in an inadequate blood supply to the tissues; cardiogenic shock is caused by heart failure; hypovolemic shock is caused by a loss of blood volume; septic shock is caused by bacterial infection
- sickle cell anemia** (SIK-l) A hereditary anemia caused by the presence of abnormal hemoglobin; red blood cells become sickle-shaped when they give up oxygen and interfere with normal blood flow to the tissues; most common in black populations of West African descent
- side effect** A result of drug therapy or other therapy that is unrelated to or an extension of its intended effect; usually applies to an undesirable effect of treatment
- sideroblastic anemia** (sid-eh-ro-BLAS-tik) Anemia caused by inability to use available iron to manufacture hemoglobin; the excess iron precipitates in normoblasts (developing red blood cells)
- sigmoid colon** Distal S-shaped portion of the large intestine located between the descending colon and the rectum
- sign** (sine) Objective evidence of disease that can be observed or tested; examples are fever, rash, high blood pressure, and blood or urine abnormalities; an objective symptom
- sinoatrial (SA) node** (si-no-A-tre-al) A small mass in the upper part of the right atrium that initiates the impulse for each heartbeat; the pacemaker
- sinus** (SI-nus) A cavity or channel; the paranasal sinuses are located near the nose and drain into the nasal cavity
- sinus rhythm** (SI-nus RITH-um) Normal heart rhythm
- Sjögren syndrome** (SHO-gren) An autoimmune disease involving dysfunction of the exocrine glands and affecting secretion of tears, saliva, and other body fluids; deficiency leads to dry mouth, tooth decay, corneal damage, eye infections, and difficulty in swallowing
- skeletal muscle** (SKEL-eh-tal) Voluntary muscle that moves the skeleton and maintains posture
- skeleton** (SKEL-eh-ton) The body's bony framework, consisting of 206 bones; the axial portion (80 bones) is composed of the skull, spinal column, ribs, and sternum; the appendicular skeleton (126 bones) contains the bones of the arms and legs, shoulder girdle, and pelvis (root: skelet/o)
- skin** The tissue that covers the body; the integument (roots: derm/o, dermat/o)
- sleep apnea** (ap-NE-ah) Brief periods of breathing cessation during sleep
- small intestine** (in-TES-tin) The portion of the intestine between the stomach and the large intestine; comprised of the duodenum, jejunum, and ileum; accessory organs secrete into the small intestine, and almost all digestion and absorption occur there
- smooth muscle** Involuntary muscle that makes up the wall of hollow organs, vessels, and ducts; visceral muscle
- somatic nervous system** (so-MAT-ik) The division of the nervous system that controls skeletal (voluntary) muscles
- specific gravity (SG)** The weight of a substance compared with the weight of an equal volume of water; the specific gravity of normal urine ranges from 1.015 to 1.025; this value may increase or decrease in disease
- spermatic cord** (sper-MAT-ik) Cord attached to the testis that contains the ductus deferens, blood vessels, and nerves enclosed within a fibrous sheath
- spermatozoon** (sper-mah-to-ZO-on) Mature male sex cell (plural: spermatozoa) (roots: sperm/i, spermat/o)
- sphygmomanometer** (sfig-mo-mah-NOM-eh-ter) Instrument for determining arterial blood pressure; pressure is read in millimeters of mercury (mm Hg) when the heart is contracting (systolic pressure) and when the heart is relaxing (diastolic pressure) and is reported as systolic/diastolic; (root sphygm/o means "pulse"). Blood pressure apparatus or blood pressure cuff
- spina bifida** (SPI-nah BIF-ih-dah) A congenital defect in the closure of the spinal column through which the spinal cord and its membranes may project
- spinal cavity (canal)** (SPI-nal) Dorsal cavity that contains the spinal cord
- spinal cord** The nervous tissue contained within the spinal column; extends from the medulla oblongata to the second lumbar vertebra (root: myel/o)
- spinal nerves** The 31 pairs of nerves that connect with the spinal cord
- spiral organ** (SPI-ral) The hearing receptor, which is located in the cochlea of the inner ear; organ of Corti (KOR-te)
- spirometer** (spi-ROM-eh-ter) An apparatus used to measure breathing volumes and capacities; record of test is a spirogram
- spleen** A large reddish-brown organ in the upper left region of the abdomen; it filters blood and destroys old red blood cells (root: splen/o)
- splenomegaly** (sple-no-MEG-ah-le) Enlargement of the spleen
- spondylolisthesis** (spon-dih-lo-lis-THE-sis) A forward displacement of one vertebra over another (-listhesis means "a slipping"); also pronounced spon-dih-lo-LIS-theh-sis
- spondylolysis** (spon-dih-LOL-ih-sis) Degeneration of the articulating portions of a vertebra allowing for spinal distortion, specifically in the lumbar region
- sprain** (sprane) Injury to a ligament caused by abnormal or excessive force at a joint, but without bone dislocation or fracture
- sputum** (SPU-tum) The substance released by coughing or clearing the throat; expectoration; it may contain a variety of materials from the respiratory tract
- squamous cell carcinoma** (SKWA-mus) An epidermal cancer that may invade deeper tissues but tends not to metastasize
- staging** (STA-jing) The process of classifying malignant tumors for diagnosis, treatment, and prognosis
- stapedectomy** (sta-pe-DEK-to-me) Surgical removal of the stapes; it may be combined with insertion of a prosthesis to correct otosclerosis
- stapes** (STA-peze) The ossicle that is in contact with the inner ear (roots: stapedi/o)

- stenosis** (steh-NO-sis) Constriction or narrowing of an opening
- stent** A small metal device in the shape of a coil or slotted tube that is placed inside an artery to keep the vessel open, for example, after balloon angioplasty
- stereotactic biopsy** (ster-e-o-TAK-tik BI-op-se) Needle biopsy using a computer-guided imaging system to locate suspicious tissue and remove samples for study
- sterility** (steh-RIL-ih-te) Complete inability to produce offspring
- steroid hormone** (STER-oyd) A hormone made from lipids; includes the sex hormones and the hormones of the adrenal cortex
- stethoscope** (STETH-o-skope) An instrument used for listening to sounds produced within the body (from the Greek root steth/o, meaning “chest”)
- stoma** (STO-mah) A surgically created opening to the body surface or between two organs (literally “mouth”)
- stomach** (STUM-ak) A muscular sac-like organ below the diaphragm that stores food and secretes juices that digest proteins (root: gastr/o)
- strain** (strane) Trauma to a muscle because of overuse or excessive stretch; if severe, may involve muscular tearing, bleeding, separation of a muscle from its tendon, or tendon separation from a bone
- stress test** Evaluation of physical fitness by continuous ECG monitoring during exercise; in a thallium stress test, a radioactive isotope of thallium is administered to trace blood flow through the heart during exercise
- stroke** Sudden interference with blood flow in one or more cerebral vessels leading to oxygen deprivation and necrosis of brain tissue; caused by a blood clot in a vessel (ischemic stroke) or rupture of a vessel (hemorrhagic stroke); cerebrovascular accident (CVA)
- subcutaneous layer** (sub-ku-TA-ne-us) The layer of tissue beneath the skin; also called the hypodermis
- subdural hematoma** (sub-DU-ral he-mah-TO-mah) Accumulation of blood beneath the dura mater
- substance dependence** A condition that may result from chronic use of a drug, in which a person has a chronic or compulsive need for a drug regardless of its adverse effects; dependence may be psychological or physical
- sudden infant death syndrome (SIDS)** The sudden and unexplained death of an apparently healthy infant; crib death
- suffix** (SUH-fix) A word part added to the end of a root to modify its meaning
- sulcus** (SUL-kus) A shallow furrow or groove, as on the surface of the cerebrum (plural: sulci)
- superior vena cava** (VE-nah KA-vah) The large superior vein that brings blood low in oxygen back to the right atrium from the upper body
- surfactant** (sur-FAK-tant) A substance that decreases surface tension within the alveoli and eases lung expansion
- surgery** (SUR-jer-e) A method for treating disease or injury by manual operations
- suture** (SU-chur) To unite parts by stitching them together; also the thread or other material used in that process or the seam formed by surgical stitching (suffix: -rhaphy). In the skeletal system, an immovable joint, such as a joint between skull bones
- sweat gland** (swet) A gland that releases a watery fluid (perspiration) to the skin surface in order to cool the body. Certain sweat glands, located mainly in the armpits and groin area, release secretions with some cellular material in response to stress. A sudoriferous (sudor-IF-er-us) gland (root: hidr/o)
- sympathetic nervous system** (sim-pah-THET-ik) The part of the autonomic nervous system that mobilizes a response to stress, increases heart rate and respiration rate, and delivers more blood to skeletal muscles
- symphysis** (SIM-fih-sis) A slightly movable joint
- symptom** (SIMP-tum) Any evidence of disease; sometimes limited to subjective evidence of disease as experienced by the individual, such as pain, dizziness, and weakness
- synapse** (SIN-aps) The junction between two neurons; also the junction between a motor neuron and a muscle or gland
- syncope** (SIN-ko-pe) A temporary loss of consciousness caused by inadequate blood flow to the brain; fainting
- synergist** (SIN-er-jist) A muscle that assists a prime mover to produce a given movement
- synergy** (SIN-er-je) Combined action of two or more drugs working together to produce an effect greater than any of the drugs could produce when acting alone; also called synergism (SIN-er-jizm); adjective: synergistic (sin-er-JIS-tik)
- synovial fluid** (sih-NO-ve-al) The fluid contained in a freely movable (diarthrotic) joint; synovia (root: synov/i)
- synovial joint** A freely movable joint; has a joint cavity containing synovial fluid; a diarthrosis
- systemic circuit** (sis-TEM-ik SER-kit) The system of vessels that carries oxygenated blood from the left side of the heart to all tissues except the lungs and returns deoxygenated blood to the right side of the heart
- systemic lupus erythematosus** (LU-pus er-ih-the-mah-TO-sus) Inflammatory connective tissue disease affecting the skin and multiple organs; patients are sensitive to light and may have a red butterfly-shaped rash over the nose and cheeks
- systemic sclerosis** A diffuse connective tissue disease that may involve any system causing inflammation, degeneration, and fibrosis; also called scleroderma because it causes thickening of the skin
- systole** (SIS-to-le) The contraction phase of the heartbeat cycle (adjective: systolic)
- T**
- T cell** A lymphocyte that matures in the thymus and attacks foreign cells directly; T lymphocyte
- tachycardia** (tak-ih-KAR-de-ah) An abnormally rapid heart rate, usually over 100 bpm
- tactile** (TAK-til) Pertaining to the sense of touch
- target tissue** The specific tissue on which a hormone acts; may also be called the target organ

- tendinitis** (ten-dih-NI-tis) Inflammation of a tendon, usually caused by injury or overuse; the shoulder, elbow, and hip are common sites; also spelled tendonitis
- tendon** (TEN-dun) A fibrous band of connective tissue that attaches a muscle to a bone (roots: ten/o, tendin/o)
- tenosynovitis** (ten-o-sin-o-VI-tis) Inflammation of a tendon and its sheath
- teratogen** (ter-AT-o-jen) A factor that causes developmental abnormalities in the fetus (root terat/o means “malformed fetus”) (adjective: teratogenic)
- testis** (TES-tis) The male reproductive gland (roots: test/o, orchi/o, orchid/o); plural is testes (TES-teze); also called testicle
- testosterone** (tes-TOS-ter-one) The main male sex hormone
- tetany** (TET-ah-ne) Irritability and spasms of muscles; may be caused by low blood calcium and other factors
- thalamus** (THAL-ah-mus) The part of the brain that receives all sensory impulses, except those for the sense of smell, and directs them to the proper portion of the cerebral cortex (root: thalam/o)
- thalassemia** (thal-ah-SE-me-ah) A group of hereditary anemias mostly found in populations of Mediterranean descent (the name comes from the Greek word for “sea”)
- therapy** (THER-ah-pe) Treatment, intervention
- thoracentesis** (thor-ah-sen-TE-sis) Surgical puncture of the chest for removal of air or fluids, such as may accumulate after surgery or as a result of injury, infection, or cardiovascular problems; also called thoracocentesis
- thoracic cavity** (tho-RAS-ik) The ventral cavity above the diaphragm, the chest cavity
- thoracic duct** The lymphatic duct that drains fluid from the upper left side of the body and all of the lower body; left lymphatic duct
- thorax** (THO-raks) The upper part of the trunk between the neck and the abdomen; formed by the 12 pairs of ribs and sternum
- thrombocyte** (THROM-bo-site) A blood platelet (root: thrombocyt/o)
- thrombocytopenia** (throm-bo-si-to-PE-ne-ah) A deficiency of thrombocytes (platelets) in the blood
- thrombophlebitis** (throm-bo-fleh-BI-tis) Inflammation of a vein associated with formation of a blood clot
- thrombosis** (throm-BO-sis) Development of a blood clot within a vessel
- thrombus** (THROM-bus) A blood clot that forms within a blood vessel (root: thromb/o)
- thymus** (THI-mus) A lymphoid organ in the upper part of the chest beneath the sternum; it functions in immunity (root: thym/o)
- thyroid gland** An endocrine gland on either side of the larynx and upper trachea; it secretes hormones that affect metabolism and growth (roots: thyr/o, thyroid/o)
- tinnitus** (TIN-ih-tus) A sensation of noises, such as ringing or tinkling, in the ear; also pronounced tih-NI-tus
- tissue** (TISH-u) A group of cells that acts together for a specific purpose (roots: hist/o, histi/o); types include epithelial tissue, connective tissue, muscle tissue, and nervous tissue
- tolerance** A condition in which chronic use of a drug results in loss of effectiveness and the dose must be increased to produce the original response
- tomosynthesis** (toh-mo-SIN-theh-sis) Three-dimensional x-ray imaging technique for detection of breast cancer; digital tomosynthesis
- tonsil** (TON-sil) Small mass of lymphoid tissue located in region of the throat (pharynx)
- tonus** (TO-nus) A state of steady, partial muscle contraction that maintains firmness; muscle tone (root: ton/o)
- toxin** (TOKS-in) A poison; adjective: toxic (roots: tox/o, toxic/o)
- trachea** (TRA-ke-ah) The air passageway that extends from the larynx to the bronchi (root: trache/o)
- trachoma** (trah-KO-mah) An infection caused by *Chlamydia trachomatis* leading to inflammation and scarring of the cornea and conjunctiva; a common cause of blindness in underdeveloped countries
- tract** (trakt) A bundle of neuron fibers within the CNS
- traction** (TRAK-shun) The process of drawing or pulling, such as traction of the head in the treatment of injuries to the cervical vertebrae
- transverse (horizontal) plane** (trans-VERS) Plane that divides the body into superior (upper) and inferior (lower) portions
- trauma** (TRAW-mah) A physical or psychological wound or injury
- tremor** (TREM-or) A shaking or involuntary movement
- trigone** (TRI-gone) A triangle at the base of the bladder formed by the openings of the two ureters and the urethra
- troponin (Tn)** (tro-PO-nin) A protein in muscle cells that regulates contraction; increased serum levels, primarily in the forms TnT and TnI, indicate recent myocardial infarction (MI)
- tubal ligation** (TU-bal li-GA-shun) Surgical constriction of the uterine tubes to produce sterilization
- tuberculin test** (tu-BER-ku-lin) A skin test for tuberculosis; tuberculin (PPD), the test material made from products of the tuberculosis organism, is injected below the skin; a hard, raised lump appearing within 48 to 72 hours indicates an active or inactive TB infection; also called the Mantoux (man-TOO) test
- tuberculosis** (tu-ber-ku-LO-sis) An infectious disease caused by the tubercle bacillus, *Mycobacterium tuberculosis*; often involves the lungs but may involve other parts of the body as well; miliary (MIL-e-ar-e) tuberculosis is an acute generalized form of the disease with formation of minute tubercles that resemble millet seeds
- tubular reabsorption** (TUBE-u-lar re-ab-SORP-shun) The return of substances from the glomerular filtrate to the blood through the peritubular capillaries
- turbinates** (TUR-bih-nate) The bony projections in the nasal cavity that contain receptors for the sense of smell; also called conchae (KON-ke) (singular: concha [KON-kah])



**tympanic membrane** (tim-PAN-ik) The membrane between the external auditory canal and the middle ear (tympanic cavity); the eardrum; it serves to transmit sound waves to the ossicles of the middle ear (roots: myring/o, tympan/o)

## U

**ulcerative colitis** (UL-ser-ah-tiv ko-LI-tis) Chronic ulceration of the rectum and colon; the cause is unknown, but may involve autoimmunity

**ultrasonography** (ul-trah-so-NOG-rah-fe) The use of high-frequency sound waves to produce a photograph of an organ or tissue; used in obstetrics to diagnose pregnancy, multiple births, and abnormalities and also to study and measure the fetus; the image obtained is a sonogram or ultrasonogram

**umbilical cord** (um-BIL-ih-kal) The structure that connects the fetus to the placenta; it contains vessels that carry blood between the mother and the fetus

**urea** (u-RE-ah) The main nitrogenous (nitrogen-containing) waste product in the urine

**uremia** (u-RE-me-ah) Presence of toxic levels of urea and other nitrogenous substances in the blood as a result of renal insufficiency

**ureter** (U-re-ter) The tube that carries urine from the kidney to the bladder (root: ureter/o)

**urethra** (u-RE-thrah) The duct that carries urine out of the body and also transports semen in the male (root: urethr/o)

**urethritis** (u-re-THRI-tis) Inflammation of the urethra; often caused by gonorrhea and chlamydia infections

**urinalysis (UA)** (u-rih-NAL-ih-sis) Laboratory study of the urine; physical and chemical properties and microscopic appearance are included

**urinary bladder** (u-rih-NAR-e BLAD-der) The organ that stores and eliminates urine excreted by the kidneys (roots: cyst/o, vesic/o)

**urinary stasis** (STA-sis) Stoppage of urine flow; urinary stagnation

**urination** (u-rih-NA-shun) The voiding of urine; micturition

**urine** (U-rin) The fluid excreted by the kidneys; it consists of water, electrolytes, urea, other metabolic wastes, and pigments; a variety of other substances may appear in urine in cases of disease (root: ur/o)

**urticaria** (ur-tih-KAR-e-ah) A skin reaction consisting of round, raised eruptions (wheals) with itching; hives

**uterine tube** (U-ter-in) A tube extending from the upper lateral portion of the uterus that carries the ovum to the uterus (root: salping/o); also called fallopian (fah-LO-pe-an) tube

**uterus** (U-ter-us) The organ that receives the fertilized egg and maintains the developing offspring during pregnancy (roots: uter/o, metr, hyster/o)

**uvea** (U-ve-ah) The middle, vascular layer of the eye (root: uve/o); consists of the choroid, ciliary body, and iris

**uvula** (U-vu-lah) The fleshy mass that hangs from the soft palate; aids in speech production (literally “little grape”) (root: uvul/o)

## V

**vagina** (vah-JI-nah) The muscular tube between the cervix and the vulva (roots: vagin/o, colp/o)

**vaginitis** (vaj-ih-NI-tis) Inflammation of the vagina

**valve** (valv) A structure that keeps fluid flowing in a forward direction (roots: valv/o, valvul/o)

**varicose vein** (VAR-ih-kose) A twisted and swollen vein resulting from breakdown of the valves, pooling of blood, and chronic dilatation of the vessel (root: varic/o); also called varix (VAR-iks) or varicosity (var-ih-KOS-ih-te)

**vas deferens** (DEF-er-enz) The duct that conveys spermatozoa from the epididymis to the ejaculatory duct; also called ductus deferens

**vasectomy** (vah-SEK-to-me) Excision of the vas deferens; usually done bilaterally to produce sterility; may be accomplished through the urethra (transurethral resection)

**vein** (vane) A vessel that carries blood back to the heart. All except the pulmonary and umbilical veins carry blood low in oxygen (roots: ven/o, phleb/o)

**ventricle** (VEN-trik-l) A small cavity, such as one of the cavities in the brain in which CSF is formed. One of the two lower pumping chambers of the heart (root: ventricul/o)

**venule** (VEN-ule) A small vessel that carries blood from the capillaries to the veins

**vertigo** (VER-tih-go) An illusion of movement, as of the body moving in space or the environment moving about the body; usually caused by disturbances in the vestibular apparatus; used loosely to mean dizziness or lightheadedness

**vessel** (VES-el) Tube or duct to transport fluid (roots: angi/o, vas/o, vascul/o)

**vestibular apparatus** (ves-TIB-u-lar) The portion of the inner ear that is concerned with the sense of equilibrium; it consists of the vestibule and the semicircular canals (root: vestibul/o)

**vestibule** (VES-tih-bule) The chamber in the inner ear that holds some of the receptors for equilibrium

**vestibulocochlear nerve** (ves-tib-u-lo-KOK-le-ar) The nerve that transmits impulses for hearing and equilibrium from the ear to the brain; eighth cranial nerve; auditory or acoustic nerve

**villi** (VIL-i) Tiny projections in the lining of the small intestine that absorb digested foods into the circulation (singular: villus)

**visceral nervous system** (VIS-er-al) The autonomic nervous system

**vision** (VIZH-un) The sense by which the shape, size, and color of objects are perceived by means of the light they give off

**visual acuity** (ah-KU-ih-te) Sharpness of vision

**vital signs** (VI-tal) Measurements that reflect basic functions necessary to maintain life

**vitreous body** (VIT-re-us) The transparent jelly-like mass that fills the eyeball’s main cavity; also called vitreous humor

**vocal folds** (VO-kal) Membranous folds on either side of the larynx that are important in speech production; also called vocal cords

**volvulus** (VOL-vu-lus) Twisting of the intestine resulting in obstruction; usually involves the sigmoid colon and occurs most often in children and in the elderly; may be caused by congenital malformation, a foreign body, or adhesion; failure to treat immediately may result in death

**vulva** (VUL-va) The external female genital organs (roots: vulv/o, episi/o)

## W

**white matter** Myelinated tissue of the nervous system

**withdrawal** A condition that results from abrupt cessation or reduction of a drug that has been used regularly

## Z

**zygote** (ZI-gote) The fertilized ovum

# Figure Credits

## Chapter 1

- Figure 1-3.** Cohen B, Hull K. *Memmler's The Human Body in Health and Disease*. 14th ed. Baltimore, MD: Wolters Kluwer Health; 2019.
- Figure 1-4.** Cohen B, Hull K. *Memmler's The Human Body in Health and Disease*. 14th ed. Baltimore, MD: Wolters Kluwer Health; 2019.
- Figure 1-5.** Smeltzer SC, et al. *Medical-Surgical Nursing*. 12th ed. Philadelphia, PA: Wolters Kluwer Health; 2010.
- Figure 1-6.** Taylor C, et al. *Fundamentals of Nursing*. 7th ed. Philadelphia, PA: Lippincott Williams & Wilkins; 2011.
- Figure 1-7.** Taylor C, et al. *Fundamentals of Nursing*. 7th ed. Philadelphia, PA: Lippincott Williams & Wilkins; 2011.
- Figure 1-8.** Cohen B, Hull K. *Memmler's The Human Body in Health and Disease*. 14th ed. Baltimore, MD: Lippincott Williams & Wilkins; 2019.
- Figure 1-9.** Cormack DH. *Essential Histology*. 2nd ed. Philadelphia, PA: Lippincott Williams & Wilkins; 2001.
- Figure 1-10.** Cohen B, Hull K. *Memmler's The Human Body in Health and Disease*. 14th ed. Baltimore, MD: Lippincott Williams & Wilkins; 2019.
- Figure 1-11.** Cohen B, Hull K. *Memmler's The Human Body in Health and Disease*. 14th ed. Baltimore, MD: Lippincott Williams & Wilkins; 2019.
- Figure 1-12.** Cormack DH. *Essential Histology*. 2nd ed. Philadelphia, PA: Lippincott Williams & Wilkins; 2001.
- Figure 1-13.** Cohen B, Hull K. *Memmler's The Human Body in Health and Disease*. 14th ed. Baltimore, MD: Lippincott Williams & Wilkins; 2019.
- Figure 1-14.** Cohen B, Hull K. *Memmler's The Human Body in Health and Disease*. 14th ed. Baltimore, MD: Lippincott Williams & Wilkins; 2019.
- Figure 1-15.** Cohen B, Hull K. *Memmler's The Human Body in Health and Disease*. 14th ed. Baltimore, MD: Lippincott Williams & Wilkins; 2019.
- Figure 1-16.** Koneman EW, et al. *Diagnostic Microbiology*. 6th ed. Philadelphia, PA: Lippincott Williams & Wilkins; 2005.
- Figure 1-17.** Bickley LS. *Bates' Guide to Physical Examination and History Taking*. 10th ed. Philadelphia, PA: Lippincott Williams & Wilkins; 2009.
- Figure 1-18.** Cohen B, Hull K. *Memmler's The Human Body in Health and Disease*. 14th ed. Baltimore, MD: Lippincott Williams & Wilkins; 2019.
- Figure 1-19.** Taylor C, et al. *Fundamentals of Nursing*. 7th ed. Philadelphia, PA: Lippincott Williams & Wilkins; 2011.
- Figure 1-20.** Cohen B, Hull K. *Memmler's The Human Body in Health and Disease*. 14th ed. Baltimore, MD: Lippincott Williams & Wilkins; 2019.
- Figure 1-21.** Cohen B, Hull K. *Memmler's The Human Body in Health and Disease*. 14th ed. Baltimore, MD: Lippincott Williams & Wilkins; 2019.

## Chapter 2

- Figure 2-1.** Cohen B, Hull K. *Memmler's The Human Body in Health and Disease*. 14th ed. Baltimore, MD: Lippincott Williams & Wilkins; 2019.
- Figure 2-2.** Cohen B, Hull K. *Memmler's The Human Body in Health and Disease*. 14th ed. Baltimore, MD: Lippincott Williams & Wilkins; 2019.
- Figure 2-3.** Courtesy Wenda S. Long, Thomas Jefferson University, Philadelphia, PA.
- Figure 2-4.** Cohen B, Hull K. *Memmler's The Human Body in Health and Disease*. 14th ed. Baltimore, MD: Lippincott Williams & Wilkins; 2019.
- Figure 2-5.** Cormack DH. *Essential Histology*. 2nd ed. Baltimore, MD: Lippincott Williams & Wilkins; 2001.
- Figure 2-6. Parts A and B:** Mills SE. *Histology for Pathologists*. 3rd ed. Philadelphia, PA: Lippincott Williams & Wilkins; 2006. **Part C:** Gartner LP, Hiatt JL. *Color Atlas of Histology*. 5th ed. Baltimore, MD: Lippincott Williams & Wilkins; 2009.
- Figure 2-7. Part A:** Cormack DH. *Essential Histology*. 2nd ed. Baltimore, MD: Lippincott Williams & Wilkins; 2001. **Part B:** Gartner LP, Hiatt JL. *Color Atlas of Histology*. 5th ed. Baltimore, MD: Lippincott Williams & Wilkins; 2009.
- Figure 2-8.** Cormack DH. *Essential Histology*. 2nd ed. Baltimore, MD: Lippincott Williams & Wilkins; 2001.
- Figure 2-9.** McConnell T, Hull K. *Human Form, Human Function*. Philadelphia, PA: Lippincott Williams & Wilkins; 2011.
- Figure 2-10.** Courtesy Wenda S. Long, Thomas Jefferson University, Philadelphia, PA.
- Figure 2-11.** Cohen B, Hull K. *Memmler's The Human Body in Health and Disease*. 14th ed. Baltimore, MD: Lippincott Williams & Wilkins; 2019.
- Figure 2-12.** Cohen B, Hull K. *Memmler's The Human Body in Health and Disease*. 14th ed. Baltimore, MD: Lippincott Williams & Wilkins; 2019.
- Figure 2-13.** Cohen B, Hull K. *Memmler's The Human Body in Health and Disease*. 14th ed. Baltimore, MD: Lippincott Williams & Wilkins; 2019.
- Figure 2-14.** Cohen B, Hull K. *Memmler's The Human Body in Health and Disease*. 14th ed. Baltimore, MD: Lippincott Williams & Wilkins; 2019.
- Figure 2-15.** McConnell T, Hull K. *Human Form, Human Function*. Philadelphia, PA: Lippincott Williams & Wilkins; 2011.
- Figure 2-16.** McConnell T, Hull K. *Human Foundations*. Philadelphia, PA: Lippincott Williams & Wilkins; 2011.
- Figure 2-17.** Cohen B, Hull K. *Memmler's The Human Body in Health and Disease*. 14th ed. Baltimore, MD: Lippincott Williams & Wilkins; 2019.

## Chapter 3

**Figure 3-1.** A: Koneman EW, et al. *Color Atlas and Textbook of Diagnostic Microbiology*. 6th ed. Philadelphia, PA: Lippincott Williams & Wilkins; 2008. B: Harvey RA, Comelissen CN. *Lippincott Illustrated Reviews, Microbiology*. Philadelphia, PA: Lippincott Williams & Wilkins; 2012. C: Koneman EW, et al. *Color Atlas and Textbook of Diagnostic Microbiology*. 6th ed. Philadelphia, PA: Lippincott Williams & Wilkins; 2008. D: Image courtesy of the Centers for Disease Control (CDC). E: Volk WA, et al. *Essentials of Medical Microbiology*. 5th ed. Philadelphia, PA: Lippincott-Raven; 1996.

**Figure 3-2.** Bickley LS. *Bates' Guide to Physical Examination and History Taking*. 10th ed. Philadelphia, PA: Lippincott Williams & Wilkins; 2009.

**Figure 3-3.** A: Cohen B, Hull K. *Memmler's The Human Body in Health and Disease*. 14th ed. Baltimore, MD: Lippincott Williams & Wilkins; 2019. B: McConnell T, Hull K. *Human Form, Human Function*. Philadelphia, PA: Lippincott Williams & Wilkins; 2011.

**Figure 3-4.** A: McConnell T, Hull K. *Human Form, Human Function*. Philadelphia, PA: Lippincott Williams & Wilkins; 2011. B: Anatomical Chart Company Atlas of Pathophysiology. 3rd ed. Philadelphia, PA: Lippincott Williams & Wilkins; 2011.

**Figure 3-6.** Taylor C, et al. *Fundamentals of Nursing*. 7th ed. Philadelphia, PA: Lippincott Williams & Wilkins; 2011.

**Figure 3-7.** Taylor C, et al. *Fundamentals of Nursing*. 6th ed. Philadelphia, PA: Lippincott Williams & Wilkins; 2006.

**Figure 3-8.** Taylor C, et al. *Fundamentals of Nursing*. 7th ed. Philadelphia, PA: Lippincott Williams & Wilkins; 2006.

**Figure 3-9.** Taylor C, et al. *Fundamentals of Nursing*. 7th ed. Philadelphia, PA: Lippincott Williams & Wilkins; 2011.

**Figure 3-10.** Taylor C, et al. *Fundamentals of Nursing*. 6th ed. Philadelphia, PA: Lippincott Williams & Wilkins; 2006.

**Figure 3-11.** Taylor C, et al. *Fundamentals of Nursing*. 7th ed. Philadelphia, PA: Lippincott Williams & Wilkins; 2011.

**Figure 3-13.** Erkonen WE, Smith WL. *Radiology 101*. 3rd ed. Philadelphia, PA: Lippincott Williams & Wilkins; 2010.

**Figure 3-14.** Erkonen WE, Smith WL. *Radiology 101*. 3rd ed. Philadelphia, PA: Lippincott Williams & Wilkins; 2010.

**Figure 3-15.** A: Pilleteri A. *Maternal and Child Health Nursing*. 6th ed. Philadelphia, PA: Lippincott Williams & Wilkins; 2009. B: Bushberg JT, et al. *Essential Physics of Medical Imaging*. 3rd ed. Philadelphia, PA: Lippincott Williams & Wilkins; 2011.

**Figure 3-17.** Taylor C, et al. *Fundamentals of Nursing*. 7th ed. Philadelphia, PA: Lippincott Williams & Wilkins; 2011.

**Figure 3-18.** Smeltzer SC, et al. *Medical-Surgical Nursing*. 12th ed. Philadelphia, PA: Lippincott Williams & Wilkins; 2010.

**Figure 3-19.** Taylor C, et al. *Fundamentals of Nursing*. 6th ed. Philadelphia, PA: Lippincott Williams & Wilkins; 2006.

**Figure 3-20.** Taylor C, et al. *Fundamentals of Nursing*. 7th ed. Philadelphia, PA: Lippincott Williams & Wilkins; 2011.

**Figure 3-21.** Rosdahl CB, Kowalski MT. *Textbook of Basic Nursing*. 9th ed. Philadelphia, PA: Lippincott Williams & Wilkins; 2007.

**Figure 3-23.** A: Taylor C, et al. *Fundamentals of Nursing*. 6th ed. Philadelphia, PA: Lippincott Williams & Wilkins; 2006.

## Chapter 4

**Figure 4-1.** Cohen B, Hull K. *Memmler's The Human Body in Health and Disease*. 14th ed. Baltimore, MD: Lippincott Williams & Wilkins; 2019.

**Figure 4-2.** A: Bickley LS. *Bates' Guide to Physical Examination and History Taking*. 10th ed. Philadelphia, PA: Lippincott Williams & Wilkins; 2009.

**Figure 4-2.** B: Cohen B, Hull K. *Memmler's The Human Body in Health and Disease*. 14th ed. Baltimore, MD: Lippincott Williams & Wilkins; 2019.

**Figure 4-3.** Rubin R, Strayer DS. *Rubin's Pathology*. 6th ed. Baltimore, MD: Lippincott Williams & Wilkins; 2012.

**Figure 4-4.** Cohen B, Hull K. *Memmler's The Human Body in Health and Disease*. 13th ed. Baltimore, MD: Lippincott Williams & Wilkins; 2015.

**Figure 4-5.** Hall JC. *Sauer's Manual of Skin Diseases*. 9th ed. Philadelphia, PA: Lippincott Williams & Wilkins; 2006.

**Figure 4-6.** Bickley LS. *Bates' Guide to Physical Examination and History Taking*. 10th ed. Philadelphia, PA: Lippincott Williams & Wilkins; 2009.

**Figure 4-7.** Nettina SM. *Lippincott Manual of Nursing Practice*. 9th ed. Philadelphia, PA: Lippincott Williams & Wilkins; 2009.

**Figure 4-8.** Hall JC. *Sauer's Manual of Skin Diseases*. 9th ed. Baltimore, MD: Lippincott Williams & Wilkins; 2006.

**Figure 4-9.** Bickley LS. *Bates' Guide to Physical Examination and History Taking*. 10th ed. Philadelphia, PA: Lippincott Williams & Wilkins; 2009.

**Figure 4-10.** Bickley LS. *Bates' Guide to Physical Examination and History Taking*. 10th ed. Philadelphia, PA: Lippincott Williams & Wilkins; 2009.

**Figure 4-11.** The American Cancer Society, American Academy of Dermatology.

**Figure 4-12.** Bickley LS. *Bates' Guide to Physical Examination and History Taking*. 10th ed. Philadelphia, PA: Lippincott Williams & Wilkins; 2009.

**Figure 4-13.** Smeltzer SC, Bare B. *Medical-Surgical Nursing*. 11th ed. Philadelphia, PA: Wolters Kluwer Health; 2009.

**Figure 4-14.** Goodheart HP. *Photoguide of Common Skin Disorders*. 2nd ed. Philadelphia, PA: Lippincott Williams & Wilkins; 2003.

**Figure 4-15.** Bickley LS. *Bates' Guide to Physical Examination and History Taking*. 10th ed. Philadelphia, PA: Lippincott Williams & Wilkins; 2009.

**Figure 4-16.** Hall JC. *Sauer's Manual of Skin Diseases*. 8th ed. Philadelphia, PA: Lippincott Williams & Wilkins; 1999.

**Figure 4-17.** Bickley LS. *Bates' Guide to Physical Examination and History Taking*. 10th ed. Philadelphia, PA: Lippincott Williams & Wilkins; 2009.

**Figure 4-18.** Smeltzer SC, Bare B. *Medical-Surgical Nursing*. 11th ed. Philadelphia, PA: Wolters Kluwer Health; 2009.

**Figure 4-19.** Bickley LS. *Bates' Guide to Physical Examination and History Taking*. 10th ed. Philadelphia, PA: Lippincott Williams & Wilkins; 2009.

## Chapter 5

**Figure 5-1.** Cohen B, Hull K. *Memmler's The Human Body in Health and Disease*. 14th ed. Baltimore, MD: Lippincott Williams & Wilkins; 2019.

**Figure 5-2.** Cohen B, Hull K. *Memmler's The Human Body in Health and Disease*. 14th ed. Baltimore, MD: Lippincott Williams & Wilkins; 2019.

**Figure 5-3.** Cohen B, Hull K. *Memmler's The Human Body in Health and Disease*. 14th ed. Baltimore, MD: Lippincott Williams & Wilkins; 2019.

**Figure 5-4.** Cohen B, Hull K. *Memmler's The Human Body in Health and Disease*. 14th ed. Baltimore, MD: Lippincott Williams & Wilkins; 2019.

**Figure 5-5.** Cohen B, Hull K. *Memmler's The Human Body in Health and Disease*. 14th ed. Baltimore, MD: Lippincott Williams & Wilkins; 2019.

**Figure 5-6.** Rubin R, Strayer DS. *Rubin's Pathology*. 6th ed. Baltimore, MD: Lippincott Williams & Wilkins; 2012.

**Figure 5-7.** Cohen B, Hull K. *Memmler's The Human Body in Health and Disease*. 14th ed. Baltimore, MD: Lippincott Williams & Wilkins; 2019.

**Figure 5-8.** Erkonen WE, Smith WL. *Radiology 101*. 3rd ed. Philadelphia, PA: Wolters Kluwer Health; 2010.

**Figure 5-10.** Rubin R, Strayer DS. *Rubin's Pathology*. 6th ed. Baltimore, MD: Lippincott Williams & Wilkins; 2012.

**Figure 5-11. A:** Erkonen WE, Smith WL. *Radiology 101*. 3rd ed. Philadelphia, PA: Lippincott Williams & Wilkins; 2010. **B:** Becker KL, et al. *Principles and Practice of Endocrinology and Metabolism*. 3rd ed. Philadelphia, PA: Wolters Kluwer Health; 2001.

**Figure 5-12.** Rubin R, Strayer DS. *Rubin's Pathology*. 6th ed. Baltimore, MD: Lippincott Williams & Wilkins; 2012.

**Figure 5-13.** Cohen B, Hull K. *Memmler's The Human Body in Health and Disease*. 14th ed. Baltimore, MD: Lippincott Williams & Wilkins; 2019.

**Figure 5-14.** Rubin R, Strayer DS. *Rubin's Pathology*. 6th ed. Baltimore, MD: Lippincott Williams & Wilkins; 2012.

**Figure 5-16.** Daffner RH. *Clinical Radiology the Essentials*. 3rd ed. Philadelphia, PA: Lippincott Williams & Wilkins; 2007.

**Figure 5-17.** Erkonen WE, Smith WL. *Radiology 101*. 3rd ed. Philadelphia, PA: Lippincott Williams & Wilkins; 2010.

**Figure 5-18. B:** Erkonen WE. *Radiology 101*. 2nd ed. Philadelphia, PA: Lippincott Williams & Wilkins; 2004.

**Figure 5-20.** McConnell T, Hull K. *Human Form, Human Function*. Philadelphia, PA: Lippincott Williams & Wilkins; 2011.

**Case Study 5-2.** Rubin R, Strayer DS. *Rubin's Pathology*. 6th ed. Philadelphia, PA: Wolters Kluwer Health; 2012.

## Chapter 6

**Figure 6-1.** McConnell T, Hull K. *Human Form, Human Function*. Philadelphia, PA: Wolters Kluwer Health; 2011.

**Figure 6-2.** Cohen B, Hull K. *Memmler's The Human Body in Health and Disease*. 14th ed. Baltimore, MD: Lippincott Williams & Wilkins; 2019.

**Figure 6-3.** Cohen B, Hull K. *Memmler's The Human Body in Health and Disease*. 14th ed. Baltimore, MD: Lippincott Williams & Wilkins; 2019.

**Figure 6-4.** Bucci C. *Condition-Specific Massage Therapy*. Baltimore, MD: Wolters Kluwer Health; 2012.

**Figure 6-5.** Cohen B, Hull K. *Memmler's The Human Body in Health and Disease*. 14th ed. Baltimore, MD: Lippincott Williams & Wilkins; 2019.

**Figure 6-6.** Cohen B, Hull K. *Memmler's The Human Body in Health and Disease*. 14th ed. Baltimore, MD: Lippincott Williams & Wilkins; 2019.

**Figure 6-7.** Cohen B, Hull K. *Memmler's The Human Body in Health and Disease*. 14th ed. Baltimore, MD: Lippincott Williams & Wilkins; 2019.

**Figure 6-8.** Adapted from Frontera WR, Silver JS. *Essentials of Physical Medicine and Rehabilitation*. 2nd ed. Philadelphia, PA: Hanley and Belfus; 2008.

**Figure 6-9.** *Stedman's Medical Dictionary*. 28th ed. Baltimore, MD: Lippincott Williams & Wilkins; 2006.

## Chapter 7

**Figure 7-1.** Cohen B, Hull K. *Memmler's The Human Body in Health and Disease*. 14th ed. Baltimore, MD: Lippincott Williams & Wilkins; 2019.

**Figure 7-2.** Cohen B, Hull K. *Memmler's The Human Body in Health and Disease*. 14th ed. Baltimore, MD: Lippincott Williams & Wilkins; 2019.

**Figure 7-3.** Cohen B, Hull K. *Memmler's The Human Body in Health and Disease*. 14th ed. Baltimore, MD: Lippincott Williams & Wilkins; 2019.

**Figure 7-4.** Cohen B, Hull K. *Memmler's The Human Body in Health and Disease*. 14th ed. Baltimore, MD: Lippincott Williams & Wilkins; 2019.

**Figure 7-5.** McConnell T, Hull K. *Human Form, Human Function*. Philadelphia, PA: Wolters Kluwer Health; 2011.

**Figure 7-6.** McConnell T, Hull K. *Human Form, Human Function*. Philadelphia, PA: Wolters Kluwer Health; 2011.

**Figure 7-7.** Cohen B. *Memmler's The Human Body in Health and Disease*. 12th ed. Baltimore, MD: Wolters Kluwer Health; 2013.

**Figure 7-8. A:** McConnell T, Hull K. *Human Form, Human Function*. Philadelphia, PA: Wolters Kluwer Health; 2011. **B:** Mills SE. *Histology for Pathologists*. 3rd ed. Philadelphia, PA: Lippincott Williams & Wilkins; 2006.

**Figure 7-9.** Cohen B. *Memmler's The Human Body in Health and Disease*. 12th ed. Baltimore, MD: Wolters Kluwer Health; 2013.

**Figure 7-10.** Cohen B, Hull K. *Memmler's The Human Body in Health and Disease*. 14th ed. Baltimore, MD: Lippincott Williams & Wilkins; 2019.

**Figure 7-11.** Rubin E, Farber JL. *Pathology*. 4th ed. Philadelphia, PA: Lippincott Williams & Wilkins; 2005.

**Figure 7-13. A:** Wallover J. *Lippincott Procedures*. Baltimore, MD: Wolters Kluwer Health; 2014. **B:** Smeltzer SC, et al. *Medical-Surgical Nursing*. 12th ed. Philadelphia, PA: Lippincott Williams & Wilkins; 2010.

**Figure 7-14.** Erkonen WE, Smith WL. *Radiology 101*. 3rd ed. Philadelphia, PA: Lippincott Williams & Wilkins; 2010.

**Figure 7-15.** Rubin E, Farber JL. *Pathology*. 5th ed. Philadelphia, PA: Lippincott Williams & Wilkins; 2007.

**Figure 7-16.** Rubin R, Strayer DS. *Rubin's Pathology*. 6th ed. Baltimore, MD: Wolters Kluwer Health; 2012.

**Figure 7-17.** Bickley LS. *Bates' Guide to Physical Examination and History Taking*. 10th ed. Philadelphia, PA: Lippincott Williams & Wilkins; 2009.

**Figure 7-18.** Erkonen WE, Smith WL. *Radiology 101*. 3rd ed. Philadelphia, PA: *Rubin's Pathology*; 2010.

## Chapter 8

**Figure 8-1.** Cohen B, Hull K. *Memmler's The Human Body in Health and Disease*. 13th ed. Baltimore, MD: Lippincott Williams & Wilkins; 2015.

**Figure 8-2.** Cohen B, Hull K. *Memmler's The Human Body in Health and Disease*. 14th ed. Baltimore, MD: Lippincott Williams & Wilkins; 2019.

**Figure 8-3.** Cohen B. *Memmler's The Human Body in Health and Disease*. 12th ed. Baltimore, MD: Lippincott Williams & Wilkins; 2013.

**Figure 8-4.** Smeltzer SC, Bare B. *Medical-Surgical Nursing*. 11th ed. Philadelphia, PA: Lippincott Williams & Wilkins; 2009.

**Figure 8-5.** Smeltzer SC, Bare B. *Medical-Surgical Nursing*. 11th ed. Philadelphia, PA: Lippincott Williams & Wilkins; 2009.

**Figure 8-6.** McConnell T, Hull K. *Human Form, Human Function*. Philadelphia, PA: Lippincott Williams & Wilkins; 2011.

**Figure 8-7.** Cohen B, Hull K. *Memmler's The Human Body in Health and Disease*. 13th ed. Baltimore, MD: Lippincott Williams & Wilkins; 2015.

**Figure 8-8.** Cohen B. *Memmler's The Human Body in Health and Disease*. 14th ed. Baltimore, MD: Lippincott Williams & Wilkins; 2019.

**Figure 8-9.** Cohen B. *Memmler's The Human Body in Health and Disease*. 12th ed. Baltimore, MD: Lippincott Williams & Wilkins; 2013.

**Figure 8-10.** Moore KL, Dalley AF. *Clinically Oriented Anatomy*. 6th ed. Philadelphia, PA: Lippincott Williams & Wilkins; 2009.

**Figure 8-11.** Cohen B, Hull K. *Memmler's The Human Body in Health and Disease*. 13th ed. Baltimore, MD: Lippincott Williams & Wilkins; 2015.

**Figure 8-12.** Smeltzer SC, Bare B. *Medical-Surgical Nursing*. 11th ed. Philadelphia, PA: Lippincott Williams & Wilkins; 2009.

**Figure 8-13.** National Eye Institute, Bethesda, MD.

## Chapter 9

**Figure 9-1.** Cohen B, Hull K. *Memmler's The Human Body in Health and Disease*. 14th ed. Baltimore, MD: Lippincott Williams & Wilkins; 2019.

**Figure 9-2.** McConnell T, Hull K. *Human Form, Human Function*. Philadelphia, PA: Lippincott Williams & Wilkins; 2010.

**Figure 9-3.** Cohen B, Hull K. *Memmler's The Human Body in Health and Disease*. 14th ed. Baltimore, MD: Lippincott Williams & Wilkins; 2019.

**Figure 9-4.** Courtesy of Dana Morse Bittus and B. J. Cohen.

**Figure 9-5.** Courtesy of Sandoz Pharmaceutical Corporation, Princeton.

**Figure 9-6.** Rubin R, Strayer DS. *Rubin's Pathology*. 6th ed. Baltimore, MD: Lippincott Williams & Wilkins; 2012.

## Chapter 10

**Figure 10-2.** McConnell T, Hull K. *Human Form, Human Function*. Philadelphia, PA: Lippincott Williams & Wilkins; 2011.

**Figure 10-3.** Cohen B, Hull K. *Memmler's The Human Body in Health and Disease*. 14th ed. Baltimore, MD: Lippincott Williams & Wilkins; 2019.

**Figure 10-5.** Smeltzer SC, et al. *Medical-Surgical Nursing*. 12th ed. Philadelphia, PA: Lippincott Williams & Wilkins; 2010.

**Figure 10-6.** McConnell T, Hull K. *Human Form, Human Function*. Philadelphia, PA: Lippincott Williams & Wilkins; 2011.

**Figure 10-7.** McConnell T, Hull K. *Human Form, Human Function*. Philadelphia, PA: Lippincott Williams & Wilkins; 2011.

**Figure 10-8.** McConnell T, Hull K. *Human Foundations*. Philadelphia, PA: Lippincott Williams & Wilkins; 2011.

**Figure 10-9.** Wingerd B. *Human Body*. 3rd ed. Philadelphia, PA: Wolters Kluwer Health; 2013.

**Figure 10-11.** Baim DS. *Grossman's Cardiac Catheterization, Angiography and Intervention*. 7th ed. Philadelphia, PA: Lippincott Williams & Wilkins; 2006.

**Figure 10-12.** McArdle WD, et al. *Exercise Physiology*. 8th ed. Philadelphia, PA: Wolters Kluwer Health; 2013.

**Figure 10-14.** Smeltzer SC, et al. *Brunner and Suddarth's Textbook of Medical Surgical Nursing*. 12th ed. Philadelphia, PA: Lippincott Williams & Wilkins; 2009.

**Figure 10-17.** Porth CM, Matfin G. *Pathophysiology*. 8th ed. Philadelphia, PA: Lippincott Williams & Wilkins; 2009.

**Figure 10-18.** Bickley LS. *Bates' Guide to Physical Examination and History Taking*. 10th ed. Philadelphia, PA: Lippincott Williams & Wilkins; 2009.

**Figure 10-19.** McConnell T, Hull K. *Human Form, Human Function*. Philadelphia, PA: Lippincott Williams & Wilkins; 2011.

**Figure 10-21.** McConnell T, Hull K. *Human Form, Human Function*. Philadelphia, PA: Lippincott Williams & Wilkins; 2011.

**Figure 10-22. A:** Matz Paul S. In: Chung EK, et al. *Visual Diagnosis and Treatment in Pediatrics*. 2nd ed. Philadelphia, PA: Lippincott Williams & Wilkins; 2010. **B:** Rajagopalan S, et al. *Manual of Vascular Diseases*. Philadelphia, PA: Wolters Kluwer Health; 2012.

**Figure 10-23.** Bickley LS. *Bates' Guide to Physical Examination and History Taking*. 10th ed. Philadelphia, PA: Lippincott Williams & Wilkins; 2009.

## Chapter 11

**Figure 11-1.** Cohen B. *Memmler's The Human Body in Health and Disease*. 14th ed. Baltimore, MD: Lippincott Williams & Wilkins; 2019.

**Figure 11-2.** Cohen B. *Memmler's The Human Body in Health and Disease*. 14th ed. Baltimore, MD: Lippincott Williams & Wilkins; 2019.

**Figure 11-3.** Cohen B. *Memmler's The Human Body in Health and Disease*. 14th ed. Baltimore, MD: Lippincott Williams & Wilkins; 2019.

**Figure 11-4.** Gartner LP, Hiatt JL. *Color Atlas of Histology*. 5th ed. Philadelphia, PA: Lippincott Williams & Wilkins; 2009.

**Figure 11-5.** Gartner LP, Hiatt JL. *Color Atlas of Histology*. 5th ed. Philadelphia, PA: Lippincott Williams & Wilkins; 2009.

**Figure 11-6. A and C:** McConnell TH, Hull KH. *Human Form, Human Function*. Philadelphia, PA: Lippincott Williams & Wilkins; 2011.

**Figure 11-7.** Cohen B. *Memmler's The Human Body in Health and Disease*. 14th ed. Baltimore, MD: Lippincott Williams & Wilkins; 2019.

**Figure 11-10.** McConnell T, Hull K. *Human Form, Human Function*. Philadelphia, PA: Lippincott Williams & Wilkins; 2011.

**Figure 11-11.** Rubin R, Strayer DS. *Rubin's Pathology*. 6th ed. Philadelphia, PA: Lippincott Williams & Wilkins; 2012.

**Figure 11-12.** Rubin R, Strayer DS. *Rubin's Pathology: Clinicopathologic Foundations of Medicine*. 5th ed. Baltimore, MD: Lippincott Williams & Wilkins; 2007.

**Figure 11-13. A:** McClatchey KD. *Clinical Laboratory Medicine*. 2nd ed. Philadelphia, PA: Lippincott Williams & Wilkins; 2002. **B:** Rubin R, Strayer DS. *Rubin's Pathology*. 5th ed. Philadelphia, PA: Lippincott Williams & Wilkins; 2008.

**Figure 11-14.** Rubin E, Farber JL. *Pathology*. 5th ed. Philadelphia, PA: Lippincott Williams & Wilkins; 2007.

**Figure 11-15.** Rubin R, Strayer DS. *Rubin's Pathology*. 6th ed. Philadelphia, PA: Lippincott Williams & Wilkins; 2012.

## Chapter 12

**Figure 12-1.** Cohen B, Hull K. *Memmler's The Human Body in Health and Disease*. 14th ed. Baltimore, MD: Lippincott Williams & Wilkins; 2019.

**Figure 12-2. A, B:** McConnell T, Hull K. *Human Form, Human Function*. Philadelphia, PA: Lippincott Williams & Wilkins; 2011.

**Figure 12-3.** Archer P, Nelson LA. *Applied Anatomy and Physiology for Manual Therapists*. Philadelphia, PA: Lippincott Williams & Wilkins; 2012.

**Figure 12-4.** Cohen B, Hull K. *Memmler's The Human Body in Health and Disease*. 14th ed. Baltimore, MD: Lippincott Williams & Wilkins; 2019.

**Figure 12-5.** Cohen B, Hull K. *Memmler's The Human Body in Health and Disease*. 14th ed. Baltimore, MD: Lippincott Williams & Wilkins; 2019.

**Figure 12-6.** Cohen B, Hull K. *Memmler's The Human Body in Health and Disease*. 14th ed. Baltimore, MD: Lippincott Williams & Wilkins; 2019.

**Figure 12-7.** Cohen B, Hull K. *Memmler's The Human Body in Health and Disease*. 14th ed. Baltimore, MD: Lippincott Williams & Wilkins; 2019.

**Figure 12-8.** *Lippincott's Visual Nursing*. 2nd ed. Philadelphia, PA: Lippincott Williams & Wilkins; 2011.

**Figure 12-9.** Rubin R, Strayer DS. *Rubin's Pathology*. 6th ed. Philadelphia, PA: Lippincott Williams & Wilkins; 2012.

**Figure 12-10.** Anatomical Chart Company. *Diseases and Disorders*. Philadelphia, PA: Lippincott Williams & Wilkins; 2008.

**Figure 12-11.** Paul P, et al. *Brunner and Suddarth's Canadian Textbook of Medical Surgical Nursing*. 3rd ed. Philadelphia, PA: Wolters Kluwer Health; 2015.

**Figure 12-12.** Labus D, Cohen A, Lippincott Advisor, Lippincott Williams & Wilkins; 2016.

**Figure 12-13.** Moore KL, et al. *Clinically Oriented Anatomy*. 7th ed. Philadelphia, PA: Wolters Kluwer Health; 2014.

**Figure 12-14.** Taylor C, et al. *Fundamentals of Nursing*. 5th ed. Philadelphia, PA: Lippincott Williams & Wilkins; 2005.

**Figure 12-15.** Cohen B, Hull K. *Memmler's The Human Body in Health and Disease*. 14th ed. Baltimore, MD: Lippincott Williams & Wilkins; 2019.

**Figure 12-16. B:** Reprinted courtesy of E.D. Andersen.

**Figure 12-17.** Carter PJ. *Lippincott Textbook for Nursing Assistants*. 3rd ed. Baltimore, MD: Lippincott Williams & Wilkins; 2011.

**Figure 12-19.** Rosdahl CB, Kowalski MT. *Textbook of Basic Nursing*. 11th ed. Philadelphia, PA: Wolters Kluwer Health; 2016.

## Chapter 13

**Figure 13-1.** McConnell T, Hull K. *Human Form, Human Function*. Philadelphia, PA: Lippincott Williams & Wilkins; 2011.

**Figure 13-2.** McConnell T, Hull K. *Human Form, Human Function*. Philadelphia, PA: Lippincott Williams & Wilkins; 2011.

**Figure 13-3.** McConnell T, Hull K. *Human Form, Human Function*. Philadelphia, PA: Lippincott Williams & Wilkins; 2011.

**Figure 13-4.** Cohen B, Hull K. *Memmler's The Human Body in Health and Disease*. 14th ed. Baltimore, MD: Lippincott Williams & Wilkins; 2019.

**Figure 13-5.** McConnell T, Hull K. *Human Form, Human Function*. Philadelphia, PA: Lippincott Williams & Wilkins; 2011.

**Figure 13-6.** *Memmler's The Human Body in Health and Disease*. 13th ed. Baltimore, MD: Lippincott Williams & Wilkins; 2015.

**Figure 13-8. C:** Mulholland MW, et al. *Greenfields Surgery Scientific Principles and Practice*. 4th ed. Philadelphia, PA: Lippincott Williams & Wilkins; 2006.

**Figure 13-11.** Anatomical Chart Company. *Atlas of Pathophysiology*. 3rd ed. Baltimore, MD: *Rubin's Pathology*; 2010.

**Figure 13-12.** Rubin R, Strayer DS. *Rubin's Pathology*. 6th ed. Philadelphia, PA: Wolters Kluwer Health; 2012.

**Figure 13-13.** Erkonen WE. *Radiology 101*. 2nd ed. Philadelphia, PA: Lippincott Williams & Wilkins; 2004.

**Figure 13-14.** Bickley LS. *Bates' Guide to Physical Examination and History Taking*. 10th ed. Philadelphia, PA: Lippincott Williams & Wilkins; 2009.

**Figure 13-15. A:** McConnell TH. *The Nature of Disease*. 2nd ed. Baltimore, MD: Lippincott Williams & Wilkins; 2013. **B:** Erkonen WE, Smith WS. *Radiology 101*. 3rd ed. Philadelphia, PA: Lippincott Williams & Wilkins; 2010.

**Figure 13-18.** *Stedman's Medical Dictionary for the Health Professions and Nursing*. 6th ed. Baltimore, MD: Lippincott Williams & Wilkins; 2008.

**Figure 13-19. B:** Erkonen WE. *Radiology 101*. 2nd ed. Philadelphia, PA: Lippincott Williams & Wilkins; 2004.

## Chapter 14

**Figure 14-1.** McConnell T, Hull K. *Human Form, Human Function*. Philadelphia, PA: Lippincott Williams & Wilkins; 2010.

**Figure 14-2.** Cohen B, Hull K. *Memmler's The Human Body in Health and Disease*. 14th ed. Baltimore, MD: Lippincott Williams & Wilkins; 2019.

**Figure 14-3.** Cohen B, Hull K. *Memmler's The Human Body in Health and Disease*. 14th ed. Baltimore, MD: Lippincott Williams & Wilkins; 2019.

**Figure 14-4.** McConnell T, Hull K. *Human Form, Human Function*. Philadelphia, PA: Lippincott Williams & Wilkins; 2010.

**Figure 14-6. A and B:** Premkumar K. *The Massage Connection*. 2nd ed. Baltimore, MD: Lippincott Williams & Wilkins; 2004. **C:** Porth C. *Essentials of Pathophysiology*. 2nd ed. Philadelphia, PA: Lippincott Williams & Wilkins; 2006.

**Figure 14-7.** Nath JL. *Using Medical Terminology*. Philadelphia, PA: Lippincott Williams & Wilkins; 2006.

**Figure 14-8. B:** Dunnick R, et al. *Textbook of Uroradiology*. 5th ed. Philadelphia, PA: Wolters Kluwer Health; 2012.

**Figure 14-10.** Erkonen WE. *Radiology 101*. 2nd ed. Philadelphia, PA: Lippincott Williams & Wilkins; 2004.

**Figure 14-11.** Rubin R, Strayer DS. *Rubin's Pathology*. 6th ed. Baltimore, MD: Lippincott Williams & Wilkins; 2012.

**Figure 14-12. B:** Schaaf CP, et al. *Human Genetics*. Philadelphia, PA: Lippincott Williams & Wilkins; 2011.

**Figure 14-13.** Rubin R, Strayer DS. *Rubin's Pathology*. 6th ed. Baltimore, MD: Lippincott Williams & Wilkins; 2012.

**Figure 14-14.** Rubin R, Strayer DS. *Rubin's Pathology*. 6th ed. Baltimore, MD: Lippincott Williams & Wilkins; 2012.

## Chapter 15

**Figure 15-1.** McConnell T, Hull K. *Human Form, Human Function*. Philadelphia, PA: Lippincott Williams & Wilkins; 2011.

**Figure 15-3. A:** McConnell T, Hull K. *Human Form, Human Function*. Philadelphia, PA: Lippincott Williams & Wilkins; 2010.

**Figure 15-4.** Cohen B, Hull K. *Memmler's The Human Body in Health and Disease*. 14th ed. Baltimore, MD: Lippincott Williams & Wilkins; 2019.

**Figure 15-6.** Rubin R, Strayer DS. *Rubin's Pathology*. 6th ed. Baltimore, MD: Lippincott Williams & Wilkins; 2012.

**Figure 15-7. C:** Kyle T, Carman S. *Essentials of Pediatric Nursing*. 2nd ed. Philadelphia, PA: Lippincott Williams & Wilkins; 2012.

## Chapter 16

**Un-Figure 16-1.** Taylor C, et al. *Fundamentals of Nursing*. 7th ed. Philadelphia, PA: Lippincott Williams & Wilkins; 2006.

**Figure 16-1.** McConnell T, Hull K. *Human Form, Human Function*. Philadelphia, PA: Lippincott Williams & Wilkins; 2011.

**Figure 16-2.** McConnell T, Hull K. *Human Form, Human Function*. Philadelphia, PA: Lippincott Williams & Wilkins; 2011.

**Figure 16-3.** McConnell TH. *The Nature of Disease*. Philadelphia, PA: Lippincott Williams & Wilkins; 2011.

**Figure 16-4.** McConnell T, Hull K. *Human Form, Human Function*. Philadelphia, PA: Lippincott Williams & Wilkins; 2011.

**Figure 16-7.** Rubin R, Strayer DS. *Rubin's Pathology*. 6th ed. Baltimore, MD: Lippincott Williams & Wilkins; 2012.

**Figure 16-8.** Anatomical Chart Company. *Infertility Anatomical Chart*. Baltimore, MD: Lippincott Williams & Wilkins; 2008.

**Figure 16-9.** Erkonen WE, Smith WL. *Radiology 101*. 3rd ed. Philadelphia, PA: Lippincott Williams & Wilkins; 2010.

**Figure 16-11.** Cohen B. *Memmler's The Human Body in Health and Disease*. 14th ed. Baltimore, MD: Lippincott Williams & Wilkins; 2019.

**Figure 16-12.** Pilletteri A. *Maternal and Child Health Nursing*. 6th ed. Philadelphia, PA: Lippincott Williams & Wilkins; 2009.

**Figure 16-13.** Cohen B. *Memmler's The Human Body in Health and Disease*. 14th ed. Baltimore, MD: Lippincott Williams & Wilkins; 2019.

**Figure 16-14.** McConnell TH. *The Nature of Disease*. Philadelphia, PA: Wolters Kluwer Health; 2011.

**Figure 16-15.** Anatomical Chart Company. *OB/GYN Disorders*. Philadelphia, PA: Lippincott Williams & Wilkins; 2008.

**Figure 16-17.** Anatomical Chart Company. *OB/GYN Disorders*. Philadelphia, PA: Lippincott Williams & Wilkins; 2008.

**Figure 16-18.** Pilletteri A. *Maternal and Child Health Nursing*. 6th ed. Philadelphia, PA: Lippincott Williams & Wilkins; 2009.

**Figure 16-19.** Pilletteri A. *Maternal and Child Health Nursing*. 6th ed. Philadelphia, PA: Lippincott Williams & Wilkins; 2009.

**Figure 16-20.** Pilletteri A. *Maternal and Child Health Nursing*. 6th ed. Philadelphia, PA: Lippincott Williams & Wilkins; 2009.

**Figure 16-21.** Erkonen WE, Smith WL. *Radiology 101*. 3rd ed. Philadelphia, PA: Lippincott Williams & Wilkins; 2010.

**Figure 16-22.** McConnell TH. *The Nature of Disease*. 2nd ed. Philadelphia, PA: Lippincott Williams & Wilkins; 2013.



# Index of Boxes

## Clinical Perspectives

- Laboratory Study of Tissues 45
- Medical Imaging 91
- Medication Patches: No Bitter Pill to Swallow 126
- Arthroplasty: Bionic Parts for a Better Life 166
- Anabolic Steroids: Winning at All Costs? 191
- Psychoactive Drugs: Adjusting Neurotransmitters to Alter Mood 236
- Eye Surgery: A Glimpse of the Cutting Edge 277
- Growth Hormone: Its Clinical Use Is Growing 296
- Seasonal Affective Disorder: Some Light on the Subject 306
- Hemodynamic Monitoring: Measuring Blood Pressure from Within 323
- Lymphedema: When Lymph Stops Flowing 341
- Use of Reticulocytes in Diagnosis 372
- Tonsillectomy: A Procedure Reconsidered 394
- Endoscopy 437
- Sodium and Potassium: Causes and Consequences of Imbalance 470
- Treating Erectile Dysfunction 498
- Assisted Reproductive Technology: The “Art” of Conception 535

## For Your Reference

- Silent Letters and Unusual Pronunciations 7
- Cell Structures 41
- Anatomic Directions 53
- Body Positions 55
- Common Infectious Organisms 77
- Imaging Techniques 92
- Surgical Instruments 94
- Routes of Drug Administration 108
- Drug Preparations 110
- Terms Pertaining to Injectable Drugs 111
- Types of Skin Lesions 130
- Bones of the Skeleton 154
- Types of Fractures 162
- Bone Markings 173
- Types of Movement 192
- The Cranial Nerves 222
- Endocrine Glands and Their Hormones 295
- Disorders Associated with Endocrine Dysfunction 300
- Blood Cells 359
- Leukocytes (White Blood Cells) 360

- Common Blood Tests 370
- Coagulation Tests 373
- Organisms That Infect the Respiratory System 401
- Volumes and Capacities (Sums of Volumes) Used in Pulmonary Function Tests 407
- Organs of the Digestive Tract 427
- The Accessory Organs 430
- Sexually Transmitted Infections 496
- Main Methods of Birth Control Currently in Use 516
- Genetic Disorders 537

## Focus on Words

- Meaningful Suffixes 9
- Name That Disease 77
- The French Connection 132
- Names That Are Like Pictures 161
- Some Colorful Musculoskeletal Terms 199
- Phobias and Manias 235
- The Greek Influence 271
- Are You in a Good Humor? 294
- Name That Structure 320
- Acronyms 359
- Don't Breathe a Word 404
- Homonyms 428
- Words That Serve Double Duty 463
- Which Is It? 492
- Crazy Ideas 518

## Health Professions

- Health Information Technicians 4
- Radiologic Technologist 51
- Emergency Medical Technicians 77
- Nurse Practitioners 131
- Careers in Physical Therapy 161
- Careers in Exercise and Fitness 193
- Careers in Occupational Therapy 235
- Audiologists 266
- Dietitians and Nutritionists 303
- Vascular Technologists 334
- Careers in Hematology 371
- Careers in Respiratory Therapy 407
- Dental Hygienist 428
- Hemodialysis Technician 472
- Physician Assistant 499
- Nurse-Midwives and Doulas 532

Note: Page numbers followed by f indicate figures, t indicate tables, and b indicate boxes, respectively.

## A

- Abbreviations
  - blood, 380–381
  - cardiovascular system, 346–347
  - digestive system, 449
  - for drugs, 113–114
  - ear, 269
  - eye and vision, 282
  - for immunity, 380–381
  - integumentary system, 141
  - male reproductive system, 502
  - nervous system, 245
  - phrase abbreviations, 8
  - skeleton system, 174
  - symbols, 8
  - urinary system, 479
- ABCDE factors, 135
- Abdomen
  - nine regions, 54f
  - quadrants of, 56f
- Abdominal cavity, 54, 56
- Abdominal regions, 54–55
- Abdominopelvic cavity, 56
- ABGs. *See* arterial blood gases
- Ablation, 332, 336
- Abortifacient, 542
- Abortion, 540
- Abscess, 88
- Accessory organs, 429–430, 429f, 430b, 430f, 435t, 440–442
- Accommodation, 270, 270f, 272
- ACE inhibitors (angiotensin-converting enzyme inhibitors), 462
- Acetabulum, 153, 156
- Acetylcholine (ACh), 190, 196, 240
- ACh. *See* acetylcholine
- Achalasia, 445
- Achilles tendinitis, 201
- Achlorhydria, 445
- Achondroplasia, 171
- Acid-fast stain, 87
- Acidosis, 401, 408, 470, 474
- Acne, 137
- Acoustic neuroma, 233, 238, 266, 267
- Acquired immunodeficiency syndrome (AIDS), 374–375
- Acromegaly, 300, 303
- Acronym, 8
- Acronyms, 359
- Acrophobia, 235b
- ACTH. *See* adrenocorticotropic hormone
- Actin, 190, 196
- Actinic, 137
- Acupuncture, 95, 97
- Acute disease, 76, 80
- Acute lymphoblastic leukemia (ALL), 373
- Acute myeloblastic leukemia (AML), 373
- Acute renal failure (ARF), 470
- Acute respiratory distress syndrome (ARDS), 405, 408
- Acute rhinitis, 404, 408
- Acute tubular necrosis (ATN), 470
- AD. *See* Alzheimer disease
- Adaptive immunity, 80, 364–365, 364f, 368
  - artificial, 365
  - natural, 365
- Addison disease, 301, 303
- Adenocarcinoma, 80
- Adenoidectomy, 413
- Adenoids, 393, 393f, 397
- Adenoma, 300, 303
- Adenosine triphosphate (ATP), 46
- ADH. *See* antidiuretic hormone
- ADHD. *See* attention deficit hyperactivity disorder
- Adhesion, 88
- Adjective suffixes, 12, 13t
- Adnexa, 526
- Adrenal cortex, 295b
- Adrenal glands, 294, 295b, 297, 297f, 298, 301–302
- Adrenaline, 377
- Adrenal medulla, 295b
- Adrenocorticotropic hormone (ACTH), 295b
- Adrenogenital syndrome, 305
- Adult hypothyroidism, 301, 304
- Advil, 106
- AEDs. *See* automated external defibrillators
- Aerosol therapy, 412
- Afferent neuron. *See* sensory neuron
- AFP. *See* alpha-fetoprotein
- Afterbirth, 541
- Age-related macular degeneration (AMD), 277–278, 278f, 279
- Agglutination, 377
- Agonist, 196
- Agoraphobia, 235b
- Agranulocytes, 360b, 361, 365
- Agranulocytosis, 378
- AI. *See* aromatase inhibitor; artificial insemination
- AIDS. *See* acquired immunodeficiency syndrome
- Albinism, 137
- Albumin, 358, 365
- Aldosterone, 295b, 297, 300b, 476
- Alkaline phosphatase, 160, 169
- Alkalosis, 401, 408
- ALL. *See* acute lymphoblastic leukemia
- Allergens, 374, 375
- Allergy, 373, 374, 375
- Allograft, 172
- Aloe, 141
- Alopecia, 137
- Alpha-fetoprotein (AFP), 102, 542
- ALS. *See* amyotrophic lateral sclerosis
- Alternative medicine, 95, 97–98
- Alveoli, 395, 397
- Alzheimer disease (AD), 233–234, 234f, 237
- Amblyopia, 259, 280, 282
- AMD. *See* age-related macular degeneration
- American Society of Health System Pharmacists (ASHP), 106
- Amino acids, 51
- AML. *See* acute myeloblastic leukemia
- Amnesia, 241
- Amniocentesis, 541
- Amyloid, 234, 237
- Amyotrophic lateral sclerosis (ALS), 199, 201, 241
- Anabolic steroids, 191b
- Anabolism, 51t
- Anaphylactic reaction, 374, 375
- Anaphylactic shock, 332
- Anaphylaxis, 106, 107
- Anaplasia, 88
- Anastomosis, 438–439, 444
- Anatomic directions, 53b
- Anatomic position, 56
- Androgens, 490, 493
- Anemia, 370–372, 375, 470
  - aplastic, 371
  - Cooley anemia, 372
  - hemorrhagic, 372
  - to loss/destruction of red cells, 372, 372f
  - nutritional, 371–372, 372f
  - pernicious, 372
  - and red cells, 371–372, 371f
  - sickle cell anemia, 372, 372f
  - sideroblastic, 372
- Anencephaly, 540
- Anesthesia, 95, 96
- Aneurysm, 231, 231f, 237, 329, 329f, 334
- Angina pectoris, 330, 334
- Angioedema, 374, 375
- Angioplasty, 330, 330f, 336
- Angiotensin, 462, 465
- Angiotensin-converting, 345
- Angiotensin receptor blocker (ARB), 345
- Anion gap, 477
- Anisocoria, 280
- Ankylosing spondylitis, 166, 166f, 168
- Ankylosis, 165, 166f, 168
- Annulus fibrosus, 170
- Anorexia, 445
- Anoxia, 411

- ANS. *See* autonomic nervous system  
 Antacid, 447  
 Antagonists, 106, 107, 191, 196  
 Antepartum, 541  
 Anterior pituitary, 295b  
 Antianxiety agent, 244  
 Antiarrhythmic agent, 345  
 Antibodies, 364, 365  
 Anticoagulants, 380  
 Antidepressants, 244  
 Antidiarrheal, 447  
 Antidiuretic hormone (ADH), 295b, 296, 300b, 464, 465  
 Antiemetic, 447  
 Antiflatulent, 447  
 Antigen, 364, 365  
 Antigen presenting cells (APCs), 364, 365  
 Antihistamine, 380, 414  
 Anti-inflammatory agents, 165, 170, 204  
 Antipruritic, 141  
 Antispasmodic, 447  
 Antitussive, 414  
 Anuresis, 476  
 Anuria, 476  
 Anus, 426, 426f, 430  
 Anxiety disorders, 235–236, 235b, 239  
 Aorta, 317, 318f, 324  
 Aortic valve, 318, 324  
 APCs. *See* antigen presenting cells  
 Apex, 324  
 Aphagia, 445  
 Aphasia, 231, 237  
 Apheresis, 380  
 Aphthous ulcer, 445  
 Apical pulse, 342  
 Aplastic anemia, 371, 375  
 Appendectomy, 446  
 Appendicitis, 436, 442  
 Appendix, 339, 429, 430  
 Apraxia, 241  
 Aqueous humor, 271, 272  
 Arachnoid mater, 220, 221f, 225  
 ARB. *See* angiotensin receptor blocker  
 ARDS. *See* acute respiratory distress syndrome  
 Areola, 526  
 ARF. *See* acute renal failure  
 Aromatase inhibitor (AI), 527  
 Arrhythmia, 315, 331–332, 332f, 334, 347  
 Arterial blood gases (ABGs), 406, 409  
 Arteries, 321, 321f, 324  
 Arterioles, 321, 321f, 324  
 Arteriosclerosis, 328, 334  
 Arthritis, 164–165, 165f, 168  
 Arthrocentesis, 165, 169  
 Arthroclasia, 172  
 Arthrodesis, 166, 169  
 Arthroplasty, 166b, 169  
 Arthroscopy, 165–166, 166f, 169  
 Articulation, 156  
 Artificial insemination (AI), 542  
 Artificial pacemaker, 332, 332f  
 Ascites, 88, 440, 442  
 ASD. *See* autism spectrum disorder  
 Aseptic meningitis, 233  
 ASHP. *See* American Society of Health System Pharmacists  
 Asphyxia, 271b, 411  
 Aspiration, 172, 401, 408  
 Asterixis, 202  
 Asthenia, 202  
*Asthenia*, 271b  
 Asthma, 405, 408  
   case study, 121  
   maintenance drug, 414  
 Astigmatism, 276, 277f, 279  
 Astrocytoma, 233, 237  
 Ataxia, 202, 241  
 Atelectasis, 405, 408  
 Atherectomy, 345  
 Atherosclerosis, 328, 329f, 334  
 Athetosis, 202, 241  
 Athletic trainers, 193b  
 Atlas, 153f, 156  
 ATN. *See* acute tubular necrosis  
 ATP. *See* adenosine triphosphate  
 Atopic dermatitis, 133, 133f, 135  
 Atresia, 540  
 Atria, 317, 324  
 Atrioventricular (AV) bundle, 319, 319f, 324  
 Atrioventricular (AV) node, 319, 319f, 324  
 Atrioventricular (AV) valves, 317, 318f, 324  
 Atrophy, 203  
 Attention deficit hyperactivity disorder (ADHD), 236–237, 239  
 Audiologists, 266b  
 Audiometry, 268  
 Auditory tube, 263  
 Aural, 267  
 Auscultation, 89, 89f, 96  
 Autism spectrum disorder (ASD), 237, 239  
 Autograft, 172  
 Autoimmune diseases, 134, 375  
 Autologous blood, 380  
 Automated external defibrillators (AEDs), 332  
 Autonomic nervous system (ANS), 218, 224, 224f, 225  
 AV bundle. *See* atrioventricular bundle  
 AV node. *See* atrioventricular node  
 Avulsion, 203  
 AV valves. *See* atrioventricular valves  
 Axial skeleton, 153, 154b  
 Axis, 153f  
 Axons, 218, 225  
 Azotemia, 476  
 Azoturia, 476
- B**  
 Babinski reflex, 243, 244f  
 Bacilli, 77b  
 Bacillus Calmette–Guérin vaccine, 403  
 Bacteria, 77b, 78, 78f  
 Bacteriuria, 469, 474  
 Baker cyst, 171  
 Balanitis, 500  
 Band cell, 361, 361f, 365  
 Bariatrics, 447  
 Bariatric surgery, 447  
 Barium study, 437, 444  
 Barium sulfate, 91b  
 Barrett syndrome, 439, 442  
 Bartholin glands, 512  
 Basal cell carcinoma, 134, 134f, 135, 148  
 Basal ganglia, 240  
 Basophils, 360, 360b, 365  
 B cells (B lymphocytes), 364–365, 365f  
 Beau lines, 137, 137f  
 Bedsore, 133  
 Behavioral disorders, 235  
   anxiety disorders, 235–236, 235b  
   attention deficit hyperactivity disorder, 236–237  
   autism spectrum disorder, 237  
   mood disorders, 236  
   treatment, drugs used in, 237  
 Bell palsy, 241  
 Bence Jones protein, 379  
 Benign, 80  
 Benign neoplasm, 80  
 Benign prostatic hyperplasia (BPH), 489, 497, 497f, 499, 502  
 Berry aneurysm, 241  
 Beta-adrenergic blocking, 345  
 Bile, 430  
 Biliary colic, 441, 442  
 Bilirubin, 377, 440, 442  
 Billroth operations, 447  
 Biofeedback, 95, 97  
 Biopsy, 91, 96  
 Biot respirations, 411  
 Bipolar disorder, 236, 240  
 Bisphosphonates, 162–163, 170, 527  
 Bladder neck obstruction (BNO), 501  
 Blepharoptosis, 85t, 86f, 280  
 Blood, 358, 365  
   abbreviations for, 380–381  
   case studies  
     blood replacement, 388  
     latex allergy, 357, 381  
     myelofibrosis, 389  
   cells, 358, 358f, 359b  
     erythrocytes, 358, 359, 359b, 359f  
     leukocytes, 358, 359–361, 359b, 360b  
   clinical aspects of  
     anemia, 370–372  
     coagulation disorders, 373  
     neoplasms, 373–374  
   clotting (coagulation), 362f, 365  
   composition of, 358f  
   formed elements, 358, 358f, 366  
   plasma, 358, 358f  
   roots for, 368t, 369t  
   suffixes for, 367t  
   tests, 370b  
   types, 362–363, 363f  
 Blood–brain barrier, 240  
 Blood pressure (BP), 90, 90f, 321–323, 323b, 323f, 324  
 Blood replacement, 388  
 Blood urea nitrogen (BUN), 477  
 BNO. *See* bladder neck obstruction  
 Body structure  
   abdominal regions, 54–55, 54f  
   body cavities, 54, 54f  
     abdominal cavity, 54  
     abdominopelvic cavity, 54, 56  
     pelvic cavity, 54  
     spinal cavity, 54

- directional terms, 52, 52f  
 frontal plane, 53, 53f  
 positions, 55b–56b  
 sagittal plane, 53, 53f  
 transverse plan, 53f
- roots  
 enrichment terms, 60t  
 extremities, 58t  
 head and trunk, 57t  
 position and direction, 55, 59t
- Body surface area (BSA), 132, 132f
- Bolus, 445
- Bone marrow, 156
- Bones, 156  
 in human adult, 152  
 long, 155, 155f  
 markings, 173  
 metabolic diseases, 162–164, 163f, 164f  
 pelvic, 153f  
 roots for, 158t  
 of skeleton, 154b
- Bougie, 94b
- Bowleg, 161b
- BP. *See* blood pressure
- BPH. *See* benign prostatic hyperplasia
- Brachytherapy, 501
- Bradycardia, 331, 334
- Bradypnea, 411
- Brain, 218, 218f, 219–221, 225, 245f  
 external surface of, 220f  
 meninges, 220, 221f, 226  
 protection, 220, 221f  
 roots for, 228t  
 sagittal section, 219f  
 tumor, 233f  
 ventricles, 220, 221f
- Brainstem, 219, 219f, 220, 225
- Brand name, drugs, 106, 107
- Braxton Hicks contractions, 541
- Breast cancer, 523
- Breathing, 395–396  
 expiration, 395, 396  
 inspiration, 395, 396, 396f  
 roots for, 400t
- Broca area, 240
- Bromhidrosis, 137
- Bronchial system, 395
- Bronchiectasis, 408
- Bronchioles, 395, 397
- Bronchitis, 408
- Bronchodilator, 414
- Bronchopneumonia, 402
- Bronchoscope, 405, 409, 410f
- Bronchospasm, 411
- Bronchus, 395, 397
- Bruit, 102, 343
- Bruxism, 446
- BSA. *See* body surface area
- Bubonic plague, 77b
- Bulbourethral glands, 492, 493
- Bulimia, 446
- BUN. *See* blood urea nitrogen
- Bundle branches, 324
- Bunion, 171, 199b
- Burns, 132, 132f
- Bursa, 156, 156f
- Bursitis, 161b, 171
- Byssinosis, 411
- C**
- CABG. *See* coronary artery bypass graft
- Cachexia, 446
- CAD. *See* coronary artery disease
- Calcium, 160
- Calcium-channel blocker, 345
- Cali-*, 271b
- Calisthenics*, 271b
- Calvaria, 170
- Calyx, 463, 465
- Cancer, 80, 95–96  
 digestive tract, 437–439, 438f  
 grading, 95, 96  
 lung, 405  
 methods for treatment, 96  
 of prostate, 497  
 skin, 134–135  
 staging, 95–96, 97  
 of testis, 497  
 of urinary system, 472–473, 473f
- Candida albicans*, 375
- Candidiasis, 525
- Cannula, 94b
- Canthotomy, 281
- Canthus, 280
- Capillaries, 321, 321f, 324
- Carbohydrates, 46
- Carbon dioxide, 392, 397
- Carbonic acid, 396, 397
- Carbuncle, 137
- Carcinoma, 80
- Carcinoma in situ (CIS), 87
- Cardia, 445
- Cardiac catheterization, 344
- Cardiac muscle, 190, 190f, 196
- Cardiac output, 342
- Cardiac tamponade, 343
- Cardiogenic shock, 332
- Cardiopulmonary resuscitation (CPR), 332, 337
- Cardiovascular system, 316, 316f, 324  
 abbreviations, 346–347  
 case studies  
 arrhythmia, 315, 347  
 echocardiogram, 354  
 mitral valve replacement, 354  
 percutaneous transluminal coronary angioplasty, 354  
 clinical aspects of  
 aneurysm, 329, 329f  
 arrhythmia, 331–332, 332f  
 atherosclerosis, 328, 329f  
 congenital heart disease, 332–333, 333f  
 coronary artery disease, 330–331, 330f  
 embolism, 328–329, 329f  
 hypertension, 329–330  
 myocardial infarction, 331  
 rheumatic heart disease, 333  
 thrombosis, 328–329, 329f  
 veins, disorders of, 333–334, 333f  
 heart, 317–320, 317f  
 blood flow, 317–318, 318f  
 chambers of, 317  
 disease, 330–333  
 electrical conduction system, 319f  
 electrocardiography, 319, 320f  
 failure, 332  
 heartbeat, 318–319  
 layers, 317, 317f  
 myocardium, blood supply to, 318, 318f  
 rate, 319  
 roots for, 326f  
 sounds, 318  
 vascular system, 321–323  
 blood pressure, 321–323, 323f  
 disorders of, 333–334, 333f  
 roots for, 327t
- Cardioversion, 332, 337
- Caries, 436, 442
- Carina, 410
- Carotid endarterectomy, 231, 239
- Carpal tunnel syndrome (CTS), 171, 200–201, 200f
- Carrier, 540
- Cartilage, 156
- Cast, 474
- Castration, 501
- Casts, 469
- Cataract, 278, 278f, 279, 279f
- Cataract extraction surgeries, 279f
- Catarrh, 404b
- Catatonias, 241
- Catheter, 102, 103f, 111f
- Catheterization, 469, 469f, 475
- Cautery/cauterization, 94, 96, 141
- CD4+ T lymphocyte counts, 375, 377
- Cecum, 429, 430
- Celiac disease, 440, 442
- Cell, 46
- Cells, 41  
 division, 43  
 human karyotype, 48t  
 roots for, 47t–48t  
 structures, 41–42  
 types of tissues, 43
- Cellulitis, 88
- Central nervous system (CNS), 218, 218f, 225
- Central venous pressure (CVP), 344
- Cephalopelvic disproportion, 542
- Cerebellum, 219, 219f, 220, 225
- Cerebral angiography, 231, 239
- Cerebral arterial circle, 240
- Cerebral concussion, 231, 238
- Cerebral contusion, 231, 237
- Cerebral cortex, 219, 219f, 225
- Cerebral palsy, 241
- Cerebrospinal fluid (CSF), 220, 225
- Cerebrovascular accident (CVA), 231, 238, 256, 329, 334
- Cerebrum, 219–220, 219f, 220f
- Cerumen, 262, 263
- Cesarean section, 542
- CF. *See* cystic fibrosis
- CFS. *See* chronic fatigue syndrome
- Chalazion, 280
- Cheilosis, 446
- Chemotherapy, 96
- Cheyne–Stokes respiration, 411
- CHF. *See* congestive heart failure
- Childbirth, 531–532

- Chiropractic, 95, 97  
 Chlamydia, 78, 78b  
*Chlamydia trachomatis*, 276, 496  
 Chloasma, 541  
 Cholecystectomy, 441, 444, 456  
 Cholecystitis, 441, 442  
 Cholelithiasis (gallstones), 441, 441f, 442  
 Cholestasis, 446  
 Cholesteatoma, 267  
 Chondroitin, 172  
 Chondroma, 171  
 Chondrosarcoma, 164, 168  
 Chorea, 241  
 Choriocarcinoma, 542  
 Chorionic villus sampling (CVS), 539, 541  
 Choroid, 269, 270f, 272  
 Chromosome, 46  
 Chronic diseases, 76, 80  
 Chronic fatigue syndrome (CFS), 199, 201  
 Chronic lymphocytic leukemia (CLL), 373  
 Chronic myelogenous leukemia, 373, 374f  
 Chronic obstructive pulmonary disease (COPD), 404–405, 404f, 408  
 Chronic renal failure, 470, 471f  
 Chvostek sign, 203  
 Chyme, 445  
 Cicatrization, 131, 135  
 Cigarette smoking, 405  
 Cilia, 392  
 Ciliary body, 270, 270f, 272  
 Cineangiocardiology, 344  
 Cineradiography, 92b  
 Circumcision, 492, 493  
 Cirrhosis, 440–441, 442  
 CIS. *See* carcinoma in situ  
 CK. *See* creatine kinase  
 CK-MB. *See* creatine kinase MB  
 Clamp, 94b  
 Claustrophobia, 242  
 Clavus, 199b  
 Clean-catch specimen, 477  
 Clearance, 476  
 Cleft palate, 540  
 CLL. *See* chronic lymphocytic leukemia  
 Clonus, 203  
 Closed fractures, 162b, 163f  
 Clubbing, 101, 103f, 333, 335  
 Clysis, 102  
 CNS. *See* central nervous system  
 Coagulation  
   blood, 362f, 365  
   disorders, 373  
   tests, 373b  
 Coarctation of aorta, 333, 333f, 335  
 Cocci, 77b  
 Cochlea, 263  
 Coitus, 492, 493  
 Colic, 101  
 Collagen, 51t  
 Colles, 162b, 163f  
 Colon, 429, 430  
 Colonoscopy, 438, 438f  
   with biopsy, 457  
 Colposcope, 525  
 Coma, 232, 238  
 Combining forms, 5–6  
 Comedo, 137  
 Comminuted fractures, 162b, 163f  
 Commissurotomy, 345  
 Common bile duct, 430  
 Common cold, 404  
 Communicable diseases, 87  
 Complement, 377  
 Complementary medicine, 95, 97–98  
 Compliance, 342, 396  
 Compression fractures, 162b, 163f  
 Compulsion, 242  
 Computed tomography (CT), 91b, 92b, 92f  
 Conductive hearing loss, 266, 267  
 Condyle, 173  
 Cone biopsy, 525  
 Cones, 270, 270f, 272  
 Confusion, 232, 238  
 Congenital disorder, 537–539, 540  
 Congenital heart disease, 332–333, 333f  
 Congenital hypothyroidism, 301, 304  
 Congestive heart failure (CHF), 332  
 Conjunctiva, 269, 272  
 Conjunctivitis, 276, 279  
 Conn syndrome, 305  
 Constipation, 446  
 Continuous bladder irrigation, 103f  
 Continuous positive airway pressure (CPAP), 412  
 Continuous subcutaneous insulin infusion (CSII), 302  
 Contraception, 515–516  
 Contracture, 203  
 Contraindication, 106, 107  
 Contralateral, 240  
*Contrecoup*, 132b  
 Contrecoup injury, 231, 238  
 Convergence, 271, 272  
 Convulsion, 234, 238  
 Cooley anemia, 77b, 372, 375  
 Coombs test, 379  
 COPD. *See* chronic obstructive pulmonary disease  
 Cornea, 269, 272  
 Coronary angiography, 330, 330f, 337  
 Coronary artery bypass graft (CABG), 331, 331f, 337  
 Coronary artery disease (CAD), 330–331, 330f  
 Coronary calcium scan, 330, 337  
 Coronary circulation, 318, 324  
 Cor pulmonale, 411  
 Corpus callosum, 241  
 Corpuscle, 377  
 Cortex, 51t  
 Corticosteroids, 165, 414  
 Cortisol (hydrocortisone), 295b, 297, 300b  
 Coryza, 411  
 Coumadin, 345  
 Coxa, 170  
 COX-2 inhibitor, 204  
 CPR. *See* cardiopulmonary resuscitation  
 Cranial cavity, 56  
 Cranial nerves, 220, 221f, 222b, 225  
 Craniopharyngioma, 305  
 Cranium, 154b  
 C-reactive protein (CRP), 330, 335  
 Creatine, 202  
 Creatine kinase (CK), 198, 202, 331  
 Creatine kinase MB (CK-MB), 331, 337  
 Creatinine, 476  
 Crest, 173  
 Creutzfeldt–Jakob disease (CJD), 242  
 Crib death. *See* sudden infant death syndrome (SIDS)  
 Crohn disease, 77b, 439, 442  
 Cross-matching, blood, 363, 365  
 Croup, 403–404, 408  
 CRP. *See* C-reactive protein  
 Cruciate ligaments, 170  
 Cryoprecipitate, 380  
 Cryptorchidism, 498, 498f, 499  
*Cryptosporidium*, 375  
 CSF. *See* cerebrospinal fluid  
 CSII. *See* continuous subcutaneous insulin infusion  
 CT. *See* computed tomography  
 CTA. *See* CT angiography  
 CT angiography (CTA), 330, 337  
 CTS. *See* carpal tunnel syndrome  
 Culdocentesis, 526  
 Curet (curette), 94b, 95f  
 Curvatures of spine, 167–168, 168f  
 Cushing disease, 302, 304  
 Cushing syndrome, 301–302, 302f, 304  
 Cutaneous, 126, 128  
 Cutaneous lymphoma, case study, 149  
 CVA. *See* cerebrovascular accident  
 CVP. *See* central venous pressure  
 CVS. *See* chorionic villus sampling  
 Cyanosis, 101, 332, 335, 405, 408  
*Cyclo*, 271b  
 Cystectomy, 472, 473f, 475  
 Cystic fibrosis (CF), 405, 408  
 Cystitis, 469, 474  
 Cystocele, 526, 476  
 Cystometrography, 477  
 Cystoscope, 472, 473f, 475  
 Cystostome, 281  
 Cysts, 80  
 Cytology, 46  
 Cytoplasm, 46
- D**  
 D&E. *See* dilatation and evacuation  
 Debridement, 131, 136  
 Decibel (dB), 267  
 Decongestant, 414  
 Decubitus ulcer, 133  
 Deep touch, 260  
 Deep vein thrombosis (DVT), 334, 335  
 Defecation, 445  
 Defibrillation, 332, 337  
 Degenerative diseases, 76, 233–234, 234f  
 Degenerative joint disease (DJD), 165, 165f, 168  
 Deglutition, 445  
 Dehiscence, 131, 136  
 Dehydration, 470, 476  
 Delayed hypersensitivity reaction, 374, 375  
 Delirium, 242  
 Delusions, 236, 240  
 Dementia, 238  
 Dendrite, 218, 225  
 Dental hygienists, 428b  
 Deoxyribonucleic acid (DNA), 46

- Depolarization, 319, 324  
 Depression, 236, 240  
 Derma, 126, 128  
 Dermabrasion, 141  
 Dermatitis, 133, 133f, 136  
 Dermatology, 130, 136  
 Dermatome, 136, 241  
 Dermatomyositis, 199, 201  
 Dermatophytosis, 137  
 Dermatoplasty, 141  
 Dermis, 126, 128  
 Desensitization, 380  
 Detrusor muscle, 476  
 Deviated septum, 411  
 Diabetes insipidus, 300, 304, 476  
 Diabetes mellitus (DM), 300–301, 302–303, 304, 313  
   diagnosis, 302  
   T1DM, 302  
   T2DM, 302  
   treatment, 302–303  
   types of, 302  
 Diabetic retinopathy, 278, 278f, 279  
 Diagnosis, medical, 89–91, 96  
   abbreviations, 105  
   auscultation, 89, 89f, 96  
   biopsy, 91, 96  
   blood pressure, 90, 90f  
   imaging techniques for, 91–93, 91b, 92b–93b  
   inspection, 89, 89f, 96  
   palpation, 89, 89f, 97  
   percussion, 89, 89f, 97  
   pulse rate, 90, 90f  
   roots, physical forces, 98t  
   suffixes for, 99t  
   vital signs, 90, 97  
 Dialysis, 470, 471f, 475  
 Diaphoresis, 101, 137, 335  
 Diaphragm, 57  
 Diaphragm, 396, 397  
 Diaphysis, 157  
 Diarrhea, 436, 443  
 Diarthrosis, 156  
 Diascopy, 141  
 Diastole, 318, 324  
 DIC. *See* disseminated intravascular coagulation  
 Diencephalon, 219, 219f, 225  
 Dietitians, 303b  
 Diffuse toxic goiter. *See* Graves disease  
 Digestion, 426, 426f  
 Digestive system, 426, 426f  
   abbreviations, 449  
   accessory organs, 429–430, 429f, 430b, 430f, 435t  
   case studies  
     cholecystectomy, 456  
     colonoscopy with biopsy, 457  
     erosive esophagitis, 425, 429  
     gastroesophageal reflux disease, 425, 429  
   clinical aspects of  
     accessory organs, 440–442  
     digestive tract, 436–440  
   digestion, 426, 426f  
   digestive tract, 426–429, 426f  
     large intestine, 429  
     mouth to stomach, 427–428, 427f  
     organs of, 427b  
     roots for, 433t–434t  
     small intestine, 428–429  
     roots for, 432t, 433t–434t, 435t  
     supplementary terms for, 445–447  
 Digestive tract, 426–429, 426f, 436–440  
   cancer, 437–439, 438f  
   gastroesophageal reflux disease, 439, 439f  
   infection, 436  
   inflammatory intestinal disease, 439–440  
   large intestine, 429  
   mouth to stomach, 427–428, 427f  
   obstructions, 439, 439f  
   organs of, 427b  
   roots for, 433t–434t  
   small intestine, 428–429  
   ulcers, 436–437  
 Digit, 60  
 Digitalis, 345  
 Dilatation and evacuation (D&E), 541  
 Diopter, 280  
 Diphtheria, 401, 408  
 Discoid lupus erythematosus (DLE), 134, 134f  
 Diseases, 76  
   abbreviations, 89  
   acute, 76, 80  
   alternative and complementary medicine for, 95  
   benign, 80  
   case studies, 114  
     asthma, 121  
     endocarditis, 120  
   cause, 76  
   chronic, 76, 80  
   degenerative, 76  
   diagnosis, 89–93, 105  
   etiology, 76, 80  
   hormonal disorders, 76  
   immune disorders, 76  
   infectious, 76–78  
   mental and emotional disorders, 76  
   metabolic disorders, 76  
   names, 77b  
   neoplasia, 76, 80  
   prefixes for, 83t  
   responses to  
     immunity, 79–80  
     inflammation, 79, 79f  
     phagocytosis, 79, 79f  
   roots for, 82t  
   suffixes, 84t, 85t  
   supplementary, 87–90  
   surgery for, 93–95, 94b, 97  
   symptoms, 89  
   treatment, 93–95, 105  
   types of, 76  
 Diskectomy, 167, 170  
 Dissecting aneurysm, 335  
 Disseminated intravascular coagulation (DIC), 373, 375  
 Diuresis, 464, 465  
 Diuretic, 345, 464, 465  
 Diuretic drugs, 330  
 Diverticulitis, 440, 443  
 Diverticulosis, 440, 443  
 DJD. *See* degenerative joint disease  
 DLE. *See* discoid lupus erythematosus  
 DM. *See* diabetes mellitus  
 DNA. *See* deoxyribonucleic acid  
 Doppler echocardiography, 344  
 Drain, 103  
 Drugs, 106, 107  
   abbreviations for, 113–114  
   administration, 107  
     roots of, 108  
   adverse effects, 106  
   information, 106  
   inhalation of, 108, 109f  
   injectable, terms pertaining to, 111  
   instillation of, 108, 109f  
   names, 106  
   prefixes for, 112  
   preparations, 110  
   roots for, 112  
   suffixes for, 112  
 Drusen, 280  
 Duchenne muscular dystrophy, 198  
 Ductless glands. *See* endocrine glands  
 Ductus (vas) deferens, 492, 493  
 Dukes classification, 437, 444  
 Duodenal bulb, 445  
 Duodenal papilla, 445  
 Duodenum, 428, 431  
 Dura mater, 220, 221f, 225  
 DVT. *See* deep vein thrombosis  
 Dynamometer, 203  
 Dysarthria, 242  
 Dyskeratosis, 137  
 Dyslipidemia, 328, 335  
 Dysmenorrhea, 525  
 Dysmetria, 242  
 Dyspareunia, 526  
 Dyspepsia, 446  
 Dysphagia, 439, 443  
 Dyspnea, 330, 335, 405, 408  
 Dysthymia, 236, 240  
 Dysuria, 469, 474  
**E**  
 Ear, 262–263, 262f–263f  
   abbreviations, 269  
   disorders, 267  
   roots, 264t–265t  
   treatment, 267  
 Eardrum. *See* tympanic membrane  
 Ebola, 77b  
 Ecchymoses, 137, 373, 375  
 ECG. *See* electrocardiography  
 Echocardiogram, 354  
 Echocardiography, 330, 337  
 Eclampsia, 540  
 ECMO. *See* extracorporeal membrane oxygenation  
 Ectopic beat, 343  
 Ectopic pregnancy, 540  
 Eczema, 133, 133f, 136  
 ED. *See* erectile dysfunction  
 Edema, 79, 79f, 80, 332, 335, 470  
 Ectopic pregnancy, 535–536  
 EEG. *See* electroencephalography

- Efferent neuron. *See* sensory neuron  
 Efficacy, 107  
 Effusion, 88  
 Ejaculation, 492, 493  
 Ejaculatory duct, 492, 493  
 Electrocardiography (ECG), 319, 320f, 324, 330  
 Electroencephalography (EEG), 232, 239  
 Electrolyte imbalance, 470, 470b  
 Electrolytes, 358, 366  
 Electromyography (EMG), 198, 202  
 Electronystagmography (ENG), 268  
 Electrophoresis, 379  
 Electroretinography (ERG), 281  
 Elevator, 94b  
 ELISA, 379  
 Embolectomy, 345  
 Embolism, 231, 238, 328–329, 329f, 335  
 Embolus, 328–329, 335  
 Emergency medical technicians (EMTs), 77b  
 Emesis, 436, 443  
 Emetic, 447  
 EMG. *See* electromyography  
 Emission, 500  
 Emmetropia, 280  
 Emphysema, 404–405, 404f, 408  
 Empyema, 406, 408  
 EMTs. *See* emergency medical technicians  
 Encephalitis, 233, 238  
 Endemic diseases, 87  
 Endocarditis, 120  
 Endocardium, 317, 324  
 Endocrine glands, 294–297, 294f, 295b, 298  
 Endocrine system, 294, 298  
   abbreviations, 307  
   case studies  
     diabetes, 313  
     Graves disease, 293, 307  
     hyperparathyroidism, 312  
   clinical aspects of, 300–303  
     adrenals, 301–302  
     diabetes, 302–303  
     pancreas, 302–303  
     parathyroids, 301  
     pituitary, 300–301  
     thyroid, 301  
   endocrine glands, 294–297, 294f, 295b  
     adrenal glands, 295b, 297, 297f, 298, 301–302  
     pancreas, 297, 297f  
     parathyroid glands, 295b, 296f, 297, 301  
     pituitary gland, 295b, 296  
     thyroid gland, 295b, 296–297, 296f  
   endocrine tissues, 297–298  
   hormones, 294, 295b, 298  
   roots for, 299t  
   supplementary terms for, 305–306  
 Endocrine tissues, 297–298  
 Endometrial ablation, 542  
 Endometriosis, 525  
 Endoscope, 90, 90f, 96  
 Endoscopic retrograde  
   cholangiopancreatography (ERCP), 441, 442f, 444  
 Endoscopy, 437, 437b, 437f, 444  
 Endotracheal intubation, 413f  
 End-stage renal disease, 487  
 ENG. *See* electronystagmography  
 Enucleation, 281  
 Enuresis, 476  
 Enzyme, 46  
 Enzymes, 426, 431  
 Eosinophils, 360, 360b, 366  
 Epicardium, 317, 324  
 Epicondyle, 173  
 Epicondylitis, 199–200  
 Epidermis, 126, 127f, 128  
 Epididymis, 492, 493  
 Epididymitis, 496, 499  
 Epidural hematoma, 231, 232f, 238  
 Epigastrium, 60  
 Epiglottis, 394, 397  
 Epiglottitis, 411  
 Epilepsy, 232, 234, 238  
 Epinephrine (adrenaline), 374, 377  
 Epiphyseal plate, 157  
 Epiphysis, 157  
 Episiorrhaphy, 526  
 Episiotomy, 512  
 Epispadias, 476  
 Epistaxis, 411  
 EPO. *See* erythropoietin  
 Eponym, 320b  
 Equilibrium receptors, 261  
 ERCP. *See* endoscopic retrograde cholangiopancreatography  
 Erectile dysfunction (ED), 498, 498b, 499, 509  
 Erection, 492, 493  
 ERG. *See* electroretinography  
 Erosive esophagitis, 425, 429  
 Eructation, 446  
 Erysipelas, 137  
 Erythema, 133, 136  
 Erythema nodosum, 138  
 Erythrocytes, 358, 359, 359b, 359f, 366  
 Erythrocytosis, 378  
 Erythropoietin (EPO), 359, 366, 462, 465  
 Escharotomy, 131, 136  
*Escherichia coli*, 232, 469  
 Esophagus, 428, 431  
*Esthesilo*, 271b  
 Estrogen, 295b  
 Euphoria, 242  
 Eustachian tube. *See* auditory tube  
 Evisceration, 131, 136  
 Evoked potentials, 243  
 Ewing tumor, 171  
 Exacerbation, 87  
 Exanthema, 138  
 Excision, 94, 96  
 Excoriation, 138  
 Exercise and fitness, careers in, 193b  
 Exercise physiologists, 193b  
 Exophthalmos, 301, 304  
 Exostosis, 171  
 Expectorant, 414  
 Expectoration, 395, 397  
 Expiration (exhalation), 395, 396, 397  
 External auditory canal (meatus), 262, 263  
 Extracorporeal membrane oxygenation (ECMO), 542  
 Extrasystole, 343  
 Extubation, 412  
 Exudate, 88, 131  
 Eye and vision  
   abbreviations for, 282  
   clinical aspects of, 276–279  
     cataract, 278, 278f, 279f  
     glaucoma, 278  
     infection, 276  
     refraction, errors of, 276, 277f  
     retina, disorders of, 276–278, 277f, 278f  
   roots for, 273t, 274t  
   suffixes for, 276t  
   supplementary terms for, 280–281  
   surgery, 277b  
 Eyebrows, 269, 269f  
 Eyelashes, 269, 269f  
**F**  
 Facet, 173  
 Facial bones, 154b  
 Facies, 102  
 Fallopian tube, 512  
 Familial adenomatous polyposis (FAP), 446  
 Fanconi syndrome, 378  
 FAP. *See* familial adenomatous polyposis  
 Farsightedness. *See* hyperopia  
 Fascia, 190, 190f, 196  
 Fascicles, 190, 190f, 196  
 Fasciculation, 203  
 Fasting plasma glucose (FPG), 306  
 FDA. *See* Food and Drug Administration  
 Febrile, 102  
 Feces, 429, 431  
 Female reproductive system  
   abbreviations, 528  
   case study, 544  
   clinical aspects  
     cancer (*see* Female reproductive tract)  
     endometriosis, 522–523  
     fibroids, 522  
     polycystic ovarian syndrome, 523  
   enrichment terms, 541–543  
   menopause, 515  
   menstrual cycle, 514–515  
   ovaries, 512  
 Fetal circulation, 530  
 Fibrillation, 332, 335  
 Fibrin, 361, 366  
 Fibrinogen, 361, 366  
 Fibrocystic disease of breast, 526  
 Fibroid, 514, 525  
 Fibromyalgia syndrome (FMS), 199, 201, 375  
 Fibromyositis, 203  
 Fibrositis, 203  
 Fimbriae, 512  
 Fissure, 88  
 Fistula, 88, 439, 443  
 Fitness workers, 193b  
 Fixation, 96  
 Flatulence, 446  
 Flatus, 446  
 Floater, 280  
 Fluoroscopy, 92b  
 Flutter, 343  
 FMS. *See* fibromyalgia syndrome

- Follicle-stimulating hormone (FSH), 295b, 490, 493, 514
- Folliculitis, 138
- Fontanel, 541
- Food and Drug Administration (FDA), 106
- Foramen, 173
- Forceps, 94b, 95f
- Formed elements, blood, 358, 358f
- Fossa, 173
- Fovea, 271, 272
- FPG. *See* fasting plasma glucose
- Fractures, 162, 168
  - reduction of, 162, 170
  - types of, 162b, 163f
- Free thyroxine index (FTI), 306
- Fremitus, 411
- FSH. *See* follicle-stimulating hormone
- FTI. *See* free thyroxine index
- FTSG. *See* full-thickness skin graft
- Fulguration, 141
- Full-thickness skin graft (FTSG), 132
- Functional murmur, 318, 324
- Fundus, 60
- Fundus, 280, 463b
- Fungi, 78b
- Furuncle, 138
- G**
- GAD. *See* generalized anxiety disorder
- Galactorrhea, 542
- Gallbladder, 430, 431
- Gallstones, 441, 441f
- Gametes, 490, 493
- Gamma globulin, 365, 366
- Ganglion, 219, 225
- Gangrene, 88
- Gas transport, 396
- Gastric bypass, 448f
- Gastroduodenostomy*, 4, 4f
- Gastroenteritis, 436, 443
- Gastroesophageal reflux disease (GERD), 425, 429, 439, 439f, 443
- Gastrojejunostomy, 448f
- Gavage, 447
- GDM. *See* gestational diabetes mellitus
- Gene, 46
- Generalized anxiety disorder (GAD), 235
- Generic name, drugs, 106, 107
- Genitalia, 500
- Genitourinary (GU) tract, 490
- Genu, 170
- Genu varum, 161b
- GERD. *See* gastroesophageal reflux disease
- Gestational diabetes mellitus (GDM), 302
- GFR. *See* glomerular filtration rate
- GH. *See* growth hormone
- Giant cell tumor, 171
- Gigantism, 300, 304
- Gigli saw, 94b
- Glans penis, 492, 493
- Glasgow Coma Scale, 243
- Glaucoma, 278, 279
- Gleason tumor grade, 501
- Glenoid cavity, 170
- Glioblastoma, 242
- Gliomas, 233, 238
- Glomerular capsule, 463, 465
- Glomerular filtrate, 463–464, 465
- Glomerular filtration rate (GFR), 476
- Glomerulonephritis, 375, 469–470, 474
- Glomerulus, 463, 465
- Glottis, 394, 397
- Glucagon, 295b
- Glucosamine, 172
- Glucose, 46
- Glycated hemoglobin (HbA1c) test, 303, 304
- Glycogen, 51t
- Glycogen, 202
- Glycosuria, 302, 304, 476
- Goiter, 304
- Golfer's elbow, 200
- Gonads, 298, 490, 493
- Goniometer, 172
- Gonioscopy, 281
- Gonorrhea, 276, 496
- Gout, 165, 168
- Graafian follicle, 526
- Grading, cancer, 95, 96
- Graft *versus* host reaction (GVHR), 378
- Gram stain, 80
- Granulocytes, 360, 360b, 366
- Graves disease, 293, 301, 301f, 304, 307, 375
- Gray matter, of nervous system, 218, 225
- Greater omentum, 445
- Greenstick fractures, 162b, 163f
- Grippe, 404b
- Growth hormone (GH), 295b, 296b, 300b
- Guillain-Barré syndrome, 242
- Gustation (taste), 260, 261
- GVHR. *See* graft *versus* host reaction
- Gyrus, 219, 220f, 225
- H**
- Haemophilus influenzae*, 232
- Hair, 127, 127f, 128
- Hair follicle, 127, 127f, 128
- Hairy cell leukemia, 378
- Hallucinations, 236, 240
- Hallux, 170
- Hallux valgus, 199b
- Hammertoe, 171
- Hamstring strain, 201
- Hantavirus fever, 77b
- Hashimoto disease, 305
- HAV. *See* hepatitis A virus
- HBV. *See* hepatitis B virus
- HCL. *See* hydrochloric acid
- HDN. *See* hemolytic disease of the newborn
- Head injury, 231–232
- Healing, wounds, 131–132
- Hearing
  - clinical aspects of
    - acoustic neuroma, 266
    - hearing loss, 266
    - Ménière disease, 266
    - otitis, 266
    - otosclerosis, 266
  - loss, 266
  - receptors, 261
- Heart, 317–320, 317f, 324
  - blood flow, 317–318, 318f
  - chambers of, 317
  - disease, 330–333
  - electrical conduction system, 319f
  - electrocardiography, 319, 320f
  - failure, 332, 335
  - heartbeat, 318–319
  - layers, 317, 317f
  - myocardium, blood supply to, 318, 318f
  - rate, 319, 325
  - roots for, 326t
  - sounds, 318, 325
- Heartbeat, 318–319
- Heart block, 331–332, 332f, 335
- Heartburn, 439, 443
- Heberden nodes, 171
- Helicobacter pylori*, 436
- Helminths, 78b
- Hemangioma, 138
- Hemarthrosis, 171
- Hematemesis, 446
- Hematocrit, 370b, 371f
- Hematologists, 371b
- Hematoma, 378
- Hematomyelia, 242
- Hematuria, 469, 474
- Hemiballism, 242
- Hemiparesis, 231, 238
- Hemiplegia, 231, 238
- Hemodialysis, 470, 475
- Hemodialysis technician, 472b
- Hemoglobin, 359, 366, 396, 397
- Hemolysis, 372, 376
- Hemolytic disease of the newborn (HDN), 378, 540
- Hemophilia, 373, 376
- Hemopoietic stem cell, 377
- Hemoptysis, 403, 408
- Hemorrhagic anemia, 372, 376
- Hemorrhoids, 334, 335, 439, 443
- Hemosiderosis, 378
- Hemostat, 94b, 95f, 366
- Hemothorax, 406, 408
- Heparin, 329, 345, 377
- Hepatic flexure, 445
- Hepatic portal system, 430, 431
- Hepatitis, 440, 443
- Hepatitis A virus (HAV), 440
- Hepatitis B virus (HBV), 440
- Hepatitis C, 440
- Hepatitis D, 440
- Hepatitis E, 440
- Hepatomegaly, 440, 443
- Herbal medicines, 106–107
- HER2 inhibitor, 527
- Hernia, 76, 80, 81f
- Herniated disk, 166–167, 167f, 168
- Herniorrhaphy, 498, 500, 508
- Herpes simplex, 138
- Herpes virus, 233
- Hertz (Hz), 267
- Hiatal hernia, 439, 443
- High functioning autism, 237
- Hilum, 410
- Hirsutism, 138, 536
- Histamine H<sub>2</sub> antagonist, 447
- HIV. *See* human immunodeficiency virus
- Hodgkin disease, 77b



- Hodgkin lymphoma, 373–374, 374f, 376  
 Holistic health care, 95, 97  
 Holter monitor, 344  
 Homeopathy, 95, 97  
 Homeostasis, 46  
 Homocysteine, 344  
 Homologous blood, 380  
 Homonyms, 428b  
 Hordeolum, 280  
 Hormonal disorders, 76  
 Hormonal imbalances, 235  
 Hormone replacement therapy (HRT), 162  
 Hormones, 294, 295b, 298  
 Horseshoe kidney, 476, 478f  
 Housemaid's knee, 161b  
 HRT. *See* hormone replacement therapy  
 HTN. *See* hypertension  
 Human adult skeleton, 152  
 Human immunodeficiency virus (HIV), 233, 374–375, 376  
 Humoral immunity, 294b, 364–365, 364f  
 Humors, 294b  
 Hunchback, 168  
 Huntington disease, 242  
 Hydatidiform mole, 542  
 Hydramnios, 542  
 Hydrocele, 501  
 Hydrocephalus, 233, 233f, 238  
 Hydrochloric acid (HCl), 428  
 Hydronephrosis, 472, 474  
 Hydrophobia, 235b  
 Hydrothorax, 406, 408  
 Hydroureter, 476  
 Hymen, 526  
 Hyoid, 154b  
 Hyperglycemia, 302, 304  
 Hyperkalemia, 470b, 474  
 Hypernatremia, 470b, 474  
 Hyperopia, 276, 277f, 279  
 Hyperparathyroidism, 312  
 Hyperplasia, 88  
 Hyperpnea, 410  
 Hypersensitivity, 374, 376  
 Hypertension (HTN), 329–330, 335, 470  
 Hypertrophy, 88  
 Hyperventilation, 401, 409  
 Hypochondriasis, 242  
 Hypochondrium, 60  
 Hypoglycemia, 303, 304  
 Hypokalemia, 470b, 474  
 Hypolipidemic agent, 345  
 Hyponatremia, 470b, 474  
 Hypophysis. *See* pituitary gland  
 Hypopnea, 410  
 Hypoproteinemia, 470, 474  
 Hypospadias, 476, 478f  
 Hypotension, 343  
 Hypothalamus, 219f, 220, 225, 296, 298  
 Hypoventilation, 401, 409  
 Hypovolemia, 476  
 Hypovolemic shock, 332  
 Hysterectomy, 525  
 Hz. *See* hertz
- I  
 IABP. *See* intraaortic balloon pump  
 Iatrogenic diseases, 87  
 IBD. *See* inflammatory bowel disease  
 Ibuprofen, 106  
 ICD. *See* implantable cardioverter defibrillator  
 Ichthyosis, 138  
 Icterus, 440, 441f, 443  
 Ictus, 242  
 Idiopathic adolescent scoliosis, 151  
 Idiopathic diseases, 87  
 Idiopathic thrombocytopenic purpura (ITP), 378  
 IF. *See* intrinsic factor  
 IGT. *See* impaired glucose tolerance  
 Ileal conduit, 472, 473f, 475  
 Ileocecal valve, 445  
 Ileum, 428, 431  
 Ileus, 439, 443  
 Ilium, 153, 153f, 157  
 Imaging techniques, 91–93, 91b, 92b–93b  
 Immune disorders, 76  
 Immune serum, 365  
 Immunity, 79–80, 364, 364f, 366  
 abbreviations for, 380–381  
 adaptive, 364–365, 364f, 368  
 clinical aspects of  
 autoimmune diseases, 375  
 hypersensitivity, 374  
 immunodeficiency, 374–375  
 innate, 364  
 roots for, 368t  
 Immunodeficiency, 374–375, 376  
 Immunoglobulins (Ig), 364, 364f, 366  
 Immunology, 365  
 Immunosuppression, 380  
 Immunotherapy, 96  
 Impacted fractures, 162b, 163f  
 Impaired glucose tolerance (IGT), 305  
 Impetigo, 138, 138f  
 Implantable cardioverter defibrillator (ICD), 332  
 Impotence, 498, 500  
 Incision, 96  
 Incus (anvil), 262, 262f, 264  
 Induration, 88  
 Indwelling Foley catheter, 477  
 Infarct, 331, 335  
 Infectious diseases, 76, 77b–78b, 78  
 prefixes, 86t  
 roots, 86t  
 Infectious mononucleosis, 378  
 Infectious organisms, 77b–78b, 401b–402b  
 Inferior vena cava, 317, 318f, 325  
 Infertility, 535  
 Infertility, 497f, 498, 500  
 Inflammation, 79, 79f, 80  
 Inflammatory bowel disease (IBD), 77b, 439–440  
 Inflammatory intestinal disease, 439–440  
 Influenza, 403, 409  
 Inguinal canal, 490, 491f, 493  
 Inguinal hernia, 498, 499f, 500  
 INH. *See* isoniazid  
 Injectable drugs  
 materials, 111f  
 terms pertaining to, 111  
 Injection, 108, 109f  
 Innate immunity, 364  
 Insemination, 500  
 Insertion, 192, 196  
 Insomnia, 234, 238  
 Inspection, 89, 89f, 96  
 Inspiration (inhalation), 395, 396, 396f, 397  
 Insulin, 295b, 300b  
 Insulin shock, 303, 304  
 Integumentary system, 126, 128  
 abbreviations, 141  
 case studies  
 basal cell carcinoma, 148  
 cutaneous lymphoma, 149  
 clinical aspects of, 130–131  
 autoimmune disorders, 134, 134f  
 dermatitis, 133, 133f  
 nurse practitioners, 131b  
 psoriasis, 133, 133f  
 skin cancer, 134–135  
 types, 130b  
 wounds, 131–133  
 enrichment terms, 137–140  
 key terms, 135–136  
 medication patches, 126b  
 pressure ulcer, 125  
 roots, 129  
 Intermittent claudication, 343  
 Intermittent positive pressure breathing (IPPB), 412  
 Intermittent positive pressure ventilation (IPPV), 412  
 Interneurons, 218, 225  
 Interstitial, 51t  
 Interstitial cells, 490, 493  
 Intestinal obstructions, 439, 439f  
 Intestine, 428, 431  
 Intraaortic balloon pump (IABP), 345  
 Intraocular lens (IOL), 278  
 Intraocular lens implant,  
 phacoemulsification with, 291  
 Intrapartum, 541  
 Intravenous pyelography (IVP), 473, 473f, 475  
 Intravenous urography (IVU), 473, 473f, 475  
 Intrinsic factor (IF), 372, 376  
 Intubation, 413  
 Intussusception, 439, 439f, 443  
 In vitro fertilization (IVF), 542  
 IOL. *See* intraocular lens  
 Iontophoresis, 172  
 IPPB. *See* intermittent positive pressure breathing  
 IPPV. *See* intermittent positive pressure ventilation  
 Ipsilateral, 241  
 Iris, 270, 270f, 272  
 Irrigation, 102  
 Irritable bowel syndrome (IBS), 446  
 Ischemia, 328, 335  
 Ischium, 153, 153f  
 Isometric, 202  
 Isoniazid (INH), 414  
 Isotonic, 202  
 ITP. *See* idiopathic thrombocytopenic purpura  
 IVF. *See* in vitro fertilization

IVP. *See* intravenous pyelography

IVU. *See* intravenous urography

## J

Jaundice, 440, 441f, 443

JCAHO. *See* Joint Commission on Accreditation of Healthcare Organizations

Jejunum, 428, 431

Joint Commission on Accreditation of Healthcare Organizations (JCAHO), 8

Joints, 152, 156, 156f, 157

disorders, 164–166

repair, 165–166

roots for, 158t

## K

Kaposi sarcoma, 135, 136, 375, 376

Karyotype, 541

Keloids, 131, 131f, 136

Keratin, 126, 128

Keratoconus, 280

Keratometer, 281

Keratosis, 138

Ketoacidosis, 302, 304

Ketosis, 305

Kidneys, 462–463, 463f, 465

blood supply to, 463

location and structure, 462–463, 463f

nephrons, 463, 464f

roots for, 465t

Kinesthesia, 202

*Klebsiella pneumoniae*, 402

Kleptomania, 235b

Knee joint, 156, 156f

Knock-knee, 161b

Korotkoff sounds, 342

Kussmaul respiration, 411

Kyphosis, 168

## L

Labyrinth, 263, 263f, 264

Labyrinthitis, 268

Lacrimal (tear) glands, 269, 272

Lactate, 202

Lactation, 532

Lacteals, 429, 431

Laminectomy, 173

Laparoscopy, 526

Large intestine, 429, 431

Laryngopharynx, 393

Larynx, 393, 394, 394f, 397

Laser, 96

Laser in situ keratomileusis. *See* LASIK

Laser trabeculoplasty, 277b

LASIK (laser in situ keratomileusis), 277b

Latex allergy, 357, 381

Lavage, 102, 132b, 447

Laxative, 447

LCA. *See* left coronary artery

L-dopa (levodopa), 233, 239

LE. *See* lupus erythematosus

Left anterior descending (LAD) artery, 318

Left AV valve, 318, 318f, 325

Left bundle branch, 319, 319f

Left coronary artery (LCA), 318

Legg–Calvé–Perthes disease, 171

Leiomyoma, 525

Lens, 270, 270f, 272

Leptomeninges, 241

LES. *See* lower esophageal sphincter

Lesions, 76, 77, 80

Lethargy, 242

Leukemias, 373, 376

Leukocytes, 358, 359–361, 359b, 360b, 366

Leukoplakia, 437, 443

Leukorrhea, 526

Leukotriene antagonist, 414

LH. *See* luteinizing hormone

Lichenification, 138, 138f

Lidocaine, 345

Ligaments, 156, 157

Ligature, 103

Linea nigra, 541

Lingual tonsils, 393, 393f, 397

Lipid, 46

Lipoproteins, 328, 337

Liquid biopsy, 91

Lithotomy, 472, 475

Lithotripsy, 472, 472f, 475

Lithotrite, 477

Liver, 430, 431

Lobar pneumonia, 402

Lobectomy, 413

Lochia, 541

Long bone, 155, 155f

Loop diuretic, 345

Lordosis, 168, 169

Lower esophageal sphincter (LES), 428, 431

Lower extremity bones, 153, 154b

Lumbar puncture, 232–233, 232f, 239

Lumen, 60

Lungs, 392, 395, 395f, 397

cancer, 405

giant cell sarcoma, case study, 422

roots for, 400t

scans, 406, 409

Lupus erythematosus (LE), 77b, 134, 136

Luteinizing hormone (LH), 295b, 490, 493

Lyme disease, 77b

Lymph, 337, 339

Lymphadenitis, 341, 342

Lymphadenopathy, 373, 376

Lymphangitis, 341, 342

Lymphatic system, 337, 338f, 339, 339f

clinical aspects of, 341

roots for, 340t

Lymphedema, 341b, 342, 342f

Lymph nodes, 339, 339f

Lymphocytes, 360b, 361, 366

Lymphocytic leukemia, 373

Lymphocytosis, 378

Lymphoma, 341, 342

## M

Macula, 271, 271f, 272, 463b

Magnetic resonance imaging (MRI), 91b, 92b, 92f

Malaise, 102

Male reproductive system, 490, 490f

abbreviations, 502

case studies

benign prostatic hyperplasia, 489, 502

erectile dysfunction, 509

herniorrhaphy, 508

transurethral resection of prostate, 489, 502

vasectomy, 508

clinical aspects of, 496–499

benign prostatic hyperplasia, 497, 497f

cryptorchidism, 498, 498f

erectile dysfunction, 498, 498b

infection, 496, 496b

infertility, 497f, 498

inguinal hernia, 498, 499f

prostatic cancer, 497

testicular cancer, 497

penis, 492, 492f

roots for, 494t

semen, 492

spermatozoa, transport of, 491f, 492

supplementary terms for, 500–501

testes, 490, 491f, 492

Malignant neoplasm, 80, 81

Malleolus, 170

Malleus (hammer), 262, 262f, 264

Malnutrition, 76

Mammary glands, 512–513

Mammography, 523, 525

Manias, 235b, 236, 240

Manometry, 447

MAOI. *See* monoamine oxidase inhibitor

Massage, 95, 98

Mastectomy, 525

Mastication, 427, 431

Mastitis, 536–537, 540

Mastoiditis, 268

Mastoid process, 267

Maximal transport capacity (Tm), 476

Meatus, 173

Meconium, 541

Mediastinoscopy, 412

Mediastinum, 395, 397

Medical technologists, 371b

Medical terminology

abbreviations, 8

combining forms, 5–6

medical dictionaries, 8–9

prefixes, 18–26

pronunciation, 6–7

suffix, 9–10

unusual pronunciations, 7, 7b

word derivations, 6, 6f

suffixes beginning with *rh*, 6

words ending in *x*, 6

word parts, 4–6

Meditation, 95, 98

Medulla, 51t

Medulla, 463b

Medulla oblongata, 219f, 220, 226

Megacolon, 446

Megakaryocytes, 361, 366

Meibomian gland, 280

- Meiosis, 428b, 490, 493  
 Melanoma, 80, 135, 135f, 136  
 Melatonin, 295b  
 Melena, 446  
 Membrane, 46  
 Membranes, 45  
 MEN. *See* multiple endocrine neoplasia  
 Ménière disease, 266, 267  
 Meninges, brain, 220, 221f, 226  
 Meningioma, 233, 238  
 Meningitis, 232–233, 238  
 Meningococcus (*Neisseria meningitidis*), 232  
 Meniscectomy, 173  
 Meniscus, 170  
 Menopause, 515  
 Menstrual bleeding abnormalities, 523  
 Menstrual cycle, 514–515  
 Mental and emotional disorders, 76  
 Mesentery, 445  
 Mesocolon, 445  
 Metabolic bone diseases, 162–164, 163f, 164f  
 Metabolic disorders, 76  
 Metabolic syndrome, 302, 304  
 Metabolism, 46  
 Metaphysis, 157  
 Metaplasia, 88  
 Metastasis, 80, 81  
 Metrorrhagia, 525  
 MG. *See* myasthenia gravis  
 MI. *See* myocardial infarction  
 Microcalcification, 526  
 Microorganism, 81  
 Micturition, 465  
 MID. *See* multi-infarct dementia  
 Midbrain, 219f, 220, 226  
 Migraine, 242  
 Mild traumatic brain injury (MTBI), 231  
 Miliary tuberculosis, 403, 403f  
 Miosis, 280, 428b  
 Mitosis, 46  
 Mitral valve, 318, 318f, 325  
 Mitral valve prolapse, 343  
 Mitral valve replacement (MVR), 354  
 Mixed nerves, 219  
 Molar tooth, 427, 427f  
 Monoamine oxidase inhibitor (MAOI), 244  
 Monoclonal antibody, 379  
 Monocytes, 360b, 361, 366  
 Mons pubis, 526  
 Mood disorders, 236  
 Motor neuron, 218, 219f, 226  
 Motor unit, 202  
 Motrin, 106  
 Mouth, 426, 426f, 427, 427f, 431, 432t  
 MRI. *See* magnetic resonance imaging  
 MS. *See* multiple sclerosis  
 MTB. *See* mycobacterium tuberculosis  
 MTBI. *See* mild traumatic brain injury  
 Mucolytic, 414  
 Mucus, 46  
 Multi-infarct dementia (MID), 234, 238  
 Multiple endocrine neoplasia (MEN), 305  
 Multiple myeloma, 171, 374, 376  
 Multiple sclerosis (MS), 233, 238  
 Murmur, 333, 335  
 Murphy sign, 447  
 Muscle  
   relaxant, 204  
   strain, 199, 201  
   tone, 190  
 Muscular dystrophy, 198, 201  
 Muscular system, 190, 196  
   abbreviations, 204  
   action, 190–191, 191f, 192f  
   case studies  
     brachial plexus injury, 189, 205  
     rotator cuff tear, 212  
     “wake-up” test during spinal fusion surgery, 214  
   clinical aspects of, 198–201  
     multiple-system disorders, 198–199  
     muscular dystrophy, 198  
     stress injuries, 199–201  
   movement, types of, 192b, 193f  
   naming, 194, 194f, 195f  
   roots, 197t  
   structure, 190, 190f  
   supplementary terms, 202–204  
   types of  
     cardiac, 190, 190f  
     skeletal, 190, 190f  
     smooth, 190, 190f  
 Mutation, 540  
 MVR. *See* mitral valve replacement  
 Myasthenia gravis (MG), 199, 201, 375  
 Mycobacterium tuberculosis (MTB), 403  
 Mycosis fungoides, 139  
 Mydriasis, 280  
 Mydriatic, 281  
 Myelin, 218, 226  
 Myelinated axons, 218  
 Myelodysplastic syndrome, 378  
 Myelofibrosis, 378, 389  
 Myelogenous leukemia, 373  
 Myelogram, 173  
 Myocardial infarction (MI), 331, 332, 335  
 Myocardium, 317  
   blood supply to, 318, 318f  
 Myoglobin, 202  
 Myomectomy, 527  
 Myopia, 276, 277f, 279  
 Myosin, 190, 196  
 Myringotomy, 266, 267
- N**  
 Nails, 127, 127f, 128  
 Narcolepsy, 234, 238  
 Nares, 410  
 Nasal cannula, 412, 412f  
 Nasal septum, 410  
 Nasogastric (NG) tube, 447, 448f  
 Nasopharynx, 393  
 National Center for Complementary and Alternative Medicine (NCCAM), 95  
 National Institutes of Health (NIH), 95  
 Naturopathy, 95, 98  
 Nausea, 436, 443  
 NCCAM. *See* National Center for Complementary and Alternative Medicine  
 Nearsightedness. *See* myopia  
 Necrosis (death of tissue), 76, 81  
 Negative prefixes, 21t  
*Neisseria gonorrhoeae*, 496  
 Neoplasia, 76, 80, 81  
 Neoplasms, 80, 81, 233, 233f, 373–374  
 Nephrology technician, 472b  
 Nephrons, 463, 464f, 465  
 Nephrotic syndrome, 470, 474  
 Nerves, 219, 226  
 Nervous system, 218  
   abbreviations, 245  
   autonomic, 224, 224f  
   behavioral disorders, 235  
     anxiety disorders, 235–236, 235b  
     attention deficit hyperactivity disorder, 236–237  
     autism spectrum disorder, 237  
     mood disorders, 236  
     treatment, drugs used in, 237  
 brain, 219–221  
   external surface of, 220f  
   protection, 220, 221f  
   roots for, 228t  
   sagittal section, 219f  
 case studies  
   cerebrovascular accident, 256  
   diving accident, 217, 246  
   neuroleptic malignant syndrome, 257  
   spinal cord injury, 217, 246  
 clinical aspects of  
   coma, 232  
   confusion, 232  
   degenerative diseases, 233–234, 234f  
   epilepsy, 234  
   head injury, 231–232  
   hormonal imbalances, 235  
   infection, 232–233  
   neoplasms, 233, 233f  
   sleep disturbances, 234  
   vascular disorders, 231  
 gray matter, 218  
 organization of, 218–219, 218f  
 nerves, 219  
 neuron, 218–219, 219f  
 roots for, 227t  
 spinal cord, 222, 223f  
   reflexes, 222, 223f  
   roots for, 227t  
   spinal nerves, 222, 223f  
   suffixes for, 230t  
   supplementary terms, 240–244  
   white matter of, 218  
*Neurasthenia*, 271b  
 Neurilemmoma. *See* acoustic neuroma  
 Neurofibromatosis, 242  
 Neurogenic arthropathy, 171  
 Neurogenic bladder  
 Neuroglia, 218, 226  
 Neuroleptic malignant syndrome, 257  
 Neuroleptics, 237, 244  
 Neuromuscular junction (NMJ), 190, 191f, 196  
 Neuron, 218–219, 219f, 226  
 Neurosis, 242  
 Neurotransmitters, 219, 226

- Neutropenia, 378  
 Neutrophils, 360, 360b, 366  
 Nevus, 139  
 NHL. *See* Non-Hodgkin lymphoma  
 NIH. *See* National Institutes of Health  
 Nitroglycerin, 346  
 NMJ. *See* neuromuscular junction  
 Nocturia, 477  
 Nocturnal, 102  
 Nodes, 218  
 Non-Hodgkin lymphoma (NHL), 374, 376  
 Nonrapid eye movement (NREM) sleep, 234  
 Nonsteroidal anti-inflammatory drugs (NSAIDs), 165, 170, 204  
 Norepinephrine, 241  
 Normal saline (NS), 102  
 Nose, 392–393, 393f, 397  
 Nosocomial, 87  
 Noun suffixes, 9–10  
 NP. *See* nurse practitioner  
 NS. *See* normal saline  
 NSAIDs. *See* nonsteroidal anti-inflammatory drugs  
 Nuclear medicine, 102  
 Nucleus, 47  
 Nucleus, 241  
 Nucleus pulposus, 171  
 Nurse practitioner (NP), 131b  
 Nutritional anemia, 371–372, 372f, 376  
 Nutritionists, 303b  
 Nyctalopia, 280  
 Nystagmus, 280
- O**
- OA. *See* osteoarthritis  
 Oblique fractures, 162b, 163f  
 Obsessive–compulsive disorder (OCD), 236, 240  
 Obstetrics, 543  
 Obstipation, 446  
 Occlusion, 331, 336  
 Occlusive vascular disease, 343  
 Occult blood, 437, 443  
 Occupational therapy (OT), 203  
   careers in, 235b  
 OCD. *See* obsessive–compulsive disorder  
 ODS. *See* Office of Dietary Supplements  
 Office of Dietary Supplements (ODS), 106  
 OGTT. *See* oral glucose tolerance test  
 OI. *See* osteogenesis imperfecta  
 Olecranon, 171  
 Olfaction (smell), 260, 261  
 Oligohydramnios, 542  
 Oliguria, 469, 474  
 OMeatus, 60  
 Oncologists, 95  
 One-way valves, heart, 317, 318f  
 Oocyte, 526  
 Oophorectomy, 523  
 Open fractures, 162b, 163f  
 Ophthalmia neonatorum, 276, 279  
 Ophthalmoscope, 90, 90f, 96  
 Opportunistic diseases, 87  
 Optic disk, 272  
 Oral glucose tolerance test (OGTT), 306  
 Orbit, 269, 269f, 272  
 Orchitis, 496, 500  
 Organ, 47  
 Organelle, 47  
 Organs and organ systems  
   digestive system, 45–46, 45f  
 Orgasm, 500  
 Orifice, 60  
 Origin, 192, 196  
 ORL. *See* otorhinolaryngology  
 Oropharynx, 393  
 Orthopedics, 160, 170  
 Orthopneic position, 412  
 Os, 171  
 Osgood–Schlatter disease, 172  
 Osseous, 171  
 Ossicles, 154b, 262, 262f, 264  
 Ossification, 157  
 Osteoarthritis (OA), 165, 165f, 169  
 Osteoblast, 157  
 Osteochondroma, 172  
 Osteochondrosis, 172  
 Osteoclast, 157  
 Osteocyte, 157  
 Osteodystrophy, 172  
 Osteogenesis imperfecta (OI), 172, 186  
 Osteogenic sarcoma, 164, 169  
 Osteoma, 172  
 Osteomalacia, 163–164, 169  
 Osteomyelitis, 162, 169  
 Osteopathy, 95, 98  
 Osteopenia, 163, 169  
 Osteoplasty, 173  
 Osteoporosis, 162–163, 163f, 169  
 Ostomy surgery, 438, 438f, 444  
 Otitis, 266  
   externa, 266, 267  
   media, 266, 267  
 Otorhinolaryngology (ORL), 268  
 Otosclerosis, 266, 267  
 Otoscope, 90, 90f, 96, 268  
 Ovaries, 512, 513f  
 Ovaries, 295b, 298  
 Over-the-counter (OTC) drugs, 106  
 Oxygen (O<sub>2</sub>), 393f, 395, 397  
 Oxytocin, 295b, 296
- P**
- Pacemaker, 319, 336  
 Paclitaxel, 527  
 Paget disease, 164, 164f, 169  
 Pain, 260  
 Palate, 427, 431  
 Palatine tonsils, 393, 393f, 397  
 Palliative therapy, 93, 96  
 Pallor, 102  
 Palpation, 89, 89f, 97  
 Palpebrae, 269, 269f, 272  
 Palpitation, 343  
 Pancreas, 297, 297f, 302–303, 430, 431  
 Pancreatic islets, 297, 297f, 298  
 Pancreatitis, 441, 443  
 Pancytopenia, 378  
 Pandemic diseases, 87  
 Panhypopituitarism, 300, 304  
 Panic disorder, 235, 240  
 Papilla of Vater rugae, 445  
 Papilledema, 280  
 Paracentesis, 102  
 Paralysis, 231, 239  
 Paranoia, 236, 240  
 Paraplegia, 242  
 Parasite, 81  
 Parasomnia, 242  
 Parasympathetic nervous system, 224, 226  
 Parathyroid glands, 295b, 296f, 297, 301  
 Parathyroid hormone (PTH), 295b, 297, 300b  
 Parathyroids, 301  
 Parenchyma, 51t  
 Parenteral hyperalimentation, 447  
 Parietal, 51t  
 Parkinsonism, 233, 239  
 Paronychia, 139, 139f  
 PAs. *See* physician assistants  
 Patent ductus arteriosus, 333, 333f, 336  
 Patent ductus arteriosus (PDA), 542  
 Pathogen, 81  
 PCOS. *See* polycystic ovarian syndrome  
 PCP. *See* *Pneumocystis pneumonia*  
 PCWP. *See* pulmonary capillary wedge pressure  
 PDA. *See* patent ductus arteriosus  
 PDR. *See* *physicians' Desk Reference*  
 Pediatrics, 543  
 Pediculosis, 139  
 PEEP. *See* positive end-expiratory pressure  
 Pelvic bones, 153, 153f, 154b  
 Pelvic cavity, 57  
 Pelvic inflammatory disease (PID), 522, 525  
 Pelvimetry, 543  
 Pelvis, 153, 153f, 157  
 Pemphigus, 134, 134f, 136  
 Penis, 492, 492f, 493  
 PEP. *See* protein electrophoresis  
 Pepsin, 428  
 Peptic ulcers, 436, 444  
 Percussion, 89, 89f, 97  
 Percutaneous endoscopic gastrostomy (PEG) tube, 447, 448f  
 Percutaneous transluminal coronary angioplasty (PTCA), 330, 330f, 337, 354  
 Perfusion, 342  
 Pericardium, 317, 325  
 Perimenopause, 526  
 Periosteum, 157  
 Peripartum, 541  
 Peripherally inserted central catheter (PICC), 111f  
 Peripheral nervous system (PNS), 218, 226  
 Peristalsis, 426, 426f, 431  
 Peritoneal dialysis, 470, 475  
 Peritoneum, 57  
 Peritoneum, 431  
 Peritonitis, 436, 444  
 Pernicious anemia, 372, 376, 446  
 Pertussis, 401, 409  
 PET. *See* positron emission tomography  
 Petchiae, 139, 373, 376  
 Peyer patches, 339  
 PH, 379  
 Phacoemulsification, 277b, 278, 279, 279f  
 Phagocytosis, 79, 79f, 81, 361, 366

- Phallus, 500  
 Pharynx (throat), 392, 393–394, 393f, 398, 428, 431  
 Pheochromocytoma, 305  
 Philadelphia chromosome (Ph), 373, 376  
 Phimosis, 501  
 Phlebitis, 334, 336  
 Phlebotomist, 344, 371b  
 Phlyctenule, 280  
 Phobia, 235, 235b, 240  
 Phonocardiography, 344  
 Phorometer, 281  
 Photosensitization, 139  
 Phrase abbreviations, 8  
 Phrenic nerve, 396, 398  
 Physical examination, 89, 104  
 Physical therapists (PTs), 161b  
 Physical therapy (PT), 161b, 204  
 Physician assistants (PAs), 499b  
*Physicians' Desk Reference* (PDR), 106  
 Phytomedicine, 106, 107  
 Pia mater, 220, 221f  
 PICC. *See* peripherally inserted central catheter  
 PID. *See* pelvic inflammatory disease  
 PIH. *See* pregnancy-induced hypertension  
 Pilonidal cyst, 446  
 Pineal gland, 294f, 295b, 297, 298  
 Pinna (auricle), 262, 264  
 Pitocin, 543  
 Pitting edema, 343, 343f  
 Pituitary apoplexy, 305  
 Pituitary gland, 219f, 220, 295b, 296, 298, 300–301, 493  
 Placental abnormalities, 536  
 Placental abruption, 540  
 Placenta previa, 540  
 Plaque, 328, 336  
 Plasma  
   blood, 358, 358f, 366  
   cells, 364, 366  
 Plasmin, 378  
 Platelets, 358, 359, 361, 361f, 366  
 Plethysmography, 344, 412  
 Pleura, 395, 395f, 398  
 Pleural disorders, 405–406, 405f, 406f  
 Pleural effusion, 406, 406f, 409  
 Pleural friction rub, 411  
 Pleural space, 395, 395f, 398  
 Pleurisy, 405, 409  
 Plexus, 241  
 Plural formation, 15, 15t  
 PMNs. *See* poly morphonuclear leukocytes  
 Pneumoconiosis, 405, 409  
*Pneumocystis jirovecii*, 375  
*Pneumocystis pneumonia* (PCP), 403  
 Pneumonia, 402–403, 402f, 409  
 Pneumonitis, 403, 409  
 Pneumoplasty, 413  
 Pneumotachometer, 412  
 Pneumothorax, 405, 406f, 409  
 PNS. *See* peripheral nervous system  
 Poisons. *See* toxins  
 Poliovirus, 233  
 Polyarteritis nodosa, 344  
 Polycystic kidney disease, 477, 478f  
 Polycystic ovarian syndrome (PCOS), 523  
 Polycythemia, 378  
 Polycythemia vera, 378  
 Polydipsia, 477  
 Poly morphonuclear leukocytes (PMNs), 361, 361f  
 Polymorphs, 361  
 Polymyositis, 198–199, 201  
 Polyps, 88, 437, 444  
 Polysomnography, 234, 239  
 Polyuria, 477  
 Pons, 219f, 220, 226  
 Popeye's shoulder, 161b  
 Portal hypertension, 441, 444  
 Positive end-expiratory pressure (PEEP), 413  
 Positron emission tomography (PET), 93b, 243  
 Postconcussion syndrome, 231  
 Posterior pituitary gland, 295b  
 Posttraumatic stress disorder (PTSD), 236, 240  
 Postural drainage, 413  
 Potassium, in body fluids, 470b  
 Potentiation, 106, 107  
 Pott disease, 162, 162b, 163f, 169  
 PPI. *See* proton pump inhibitor  
 Precordium, 342  
 Preeclampsia, 536, 540  
 Prefixes, 18–19  
   for colors, 20t  
   for degree, 23t  
   for direction, 22t  
   negative, 21t  
   for numbers, 18t  
   position, 25t, 26t  
   for size and comparison, 24t  
   for time, 25t  
 Prefixes  
   for disease, 83t  
   for drugs, 112  
 Pregnancy and birth  
   childbirth, 531–532  
   clinical aspects  
     abortion, 540  
     ectopic pregnancy, 535–536  
     mastitis, 536–537  
     placental abnormalities, 536, 537f  
     preeclampsia, 536  
     Rh incompatibility, 536  
   enrichment terms, 541–543  
   fertilization and early development, 528, 529f  
   lactation, 532–533  
   placenta, 528, 530f  
   roots for, 534t–535t  
 Pregnancy-induced hypertension (PIH), 540  
 Prehypertension, 329  
 Prepuce, 492, 493  
*Presby*, 271b  
*Presbycusis*, 268  
*Presbycusis*, 271b  
 Presbyopia, 271b, 276, 279  
 Prescription (Rx) drugs, 106, 107  
 Pressure ulcers, 125, 133, 136  
 Priapism, 501  
 Prime mover, 191, 196  
 Process, 173  
 Prodrome, 102  
 Progesterone, 295b  
 Prognosis, 93, 97  
 Progressive systemic sclerosis (PSS), 134  
 Prolactin, 295b  
 Prolapse, 81, 95  
 Pronunciation, 6–7  
 Prophylaxis, 103  
 Proprioception, 260, 261  
 Prostaglandins, 298  
 Prostatectomy, 497, 500  
 Prostate gland, 492, 493  
 Prostatic cancer, 497  
 Prostatitis, 496, 500  
 Prosthesis, 173  
 Protease inhibitor, 380  
 Protein, 47  
 Protein electrophoresis (PEP), 477  
 Proteinuria, 469, 470, 474  
 Proton pump inhibitor (PPI), 447  
 Protozoa, 78b  
 Prozac, 106, 236b  
 Pruritus, 133, 136  
 Pseudophakia, 281  
 Psoriasis, 133, 133f, 136  
 PSS. *See* progressive systemic sclerosis  
 Psychoactive drugs, 236b  
 Psychosis, 240  
 PTCA. *See* percutaneous transluminal coronary angioplasty  
 PTH. *See* parathyroid hormone  
 PTs. *See* physical therapists  
 PTSD. *See* posttraumatic stress disorder  
 Puberty, 490, 493  
 Pubis, 153, 153f  
 Puerperium, 542  
 Pulmonary artery, 317, 318f, 325  
 Pulmonary capillary wedge pressure (PCWP), 323b, 344  
 Pulmonary circuit, 317, 317f, 325  
 Pulmonary function tests, 406, 407b, 409  
 Pulmonary valve, 318, 325  
 Pulmonary veins, 317, 318f, 325  
 Pulmonary ventilation, 395, 396f, 398  
 Pulse, 319, 325  
   pressure, 343  
   rate, 90, 90f, 325  
 Pulse oximetry, 406, 406f, 409  
 Pupil, 270, 270f, 272  
 Purkinje fibers, 319, 319f, 325  
 Purpura, 139, 373, 376  
 Pुरulent, 88  
 Pus, 79, 81  
 Pyelonephritis, 469, 474  
 Pyloric stenosis, 439, 444  
 Pylorus, 428, 431  
 Pyothorax, 406, 409  
 Pyramidal tracts, 241  
 Pyuria, 469, 474

**Q**

- Quadriplegia, 242  
 Quinsy, 404b

**R**

- RA. *See* rheumatoid arthritis
- Rabies virus, 233
- Radiation therapy, 96
- Radioactive iodine uptake test (RAIU), 306
- Radiography, 91, 91b, 91f, 93b, 97
- Radioimmunoassay (RIA), 306
- Radiology, 102
- Radionuclide, 102
- Radionuclide heart scan, 344
- RAIU. *See* radioactive iodine uptake test
- Rales, 411
- Rapid eye movement (REM) sleep, 234
- RAS. *See* reticular activating system
- Rasp, 94b
- Raynaud disease, 134, 344
- RBCs. *See* red blood cells
- RDS. *See* respiratory distress syndrome
- Receptors, 294, 298
- Rectocele, 526
- Rectum, 429, 431
- Red blood cells (RBCs), 358, 359, 359b, 359f
- Reed–Sternberg cells, 374, 374f, 377
- Reflexes, 222, 223f, 226
- Refraction, 270f, 271, 272  
errors of, 276, 277f
- Regurgitation, 344, 439, 444
- Reiter syndrome, 172
- Remission, 97
- Remission of diseases, 88
- Renal calculi, 486
- Renal colic, 472, 474
- Renal corpuscle, 476
- Renal cortex, 463, 465
- Renal failure, 474
- Renal insufficiency, 470
- Renal medulla, 463, 465
- Renal pelvis, 463, 465
- Renal pyramids, 463, 465
- Renal technician, 472b
- Renal transplantation, 470, 475
- Renin, 462, 466
- Repetitive strain injury (RSI), 199, 201
- Repolarization, 319, 325
- Resection, 103
- Resectoscope, 501
- Resorption, 157
- Respiration, 392, 392f
- Respiratory distress syndrome (RDS), 405, 409
- Respiratory syncytial virus (RSV), 403
- Respiratory system, 392, 392f, 393f  
abbreviations, 414–415  
breathing, 395–396  
expiration, 395, 396  
inspiration, 395, 396, 396f  
roots for, 400t  
case studies  
giant cell sarcoma of the lung, 422  
preoperative respiratory testing for  
asthma, 391, 415  
terminal dyspnea, 423  
clinical aspects of, 401–407  
asthma, 405  
cystic fibrosis, 405  
emphysema, 404–405, 404f  
infections, 401–404  
lung cancer, 405  
pleural disorders, 405–406, 405f, 406f  
pneumoconiosis, 405  
respiratory disorders, diagnosis of, 406, 406f, 407f  
respiratory distress syndrome, 405  
sudden infant death syndrome, 405  
gas transport, 396  
infectious organisms for, 401b–402b  
bronchial system, 395  
larynx, 394, 394f  
trachea, 394–395  
lungs, 395, 395f  
roots for, 400t  
roots for, 399t  
suffixes for, 398t  
upper respiratory passageways, 392  
nose, 392–393, 393f  
pharynx (throat), 392, 393–394, 393f
- Respiratory therapy, careers in, 407f
- Restless legs syndrome (RLS), 203
- Retention of urine, 477
- Reticular activating system (RAS), 241
- Reticulocyte counts, 372, 377
- Reticulocytes, 372b
- Retina, 270, 270f, 272
- Retina, disorders of, 276–278, 277f, 278f
- Retinal detachment, 276–278, 277f, 279
- Retinitis, 281
- Retinitis pigmentosa, 281
- Retinoblastoma, 281
- Retinoscope, 281
- Retractor, 94b, 95f
- Retrograde pyelography, 473, 473f, 475
- Reye syndrome, 243
- Rhabdomyolysis, 203
- Rhabdomyoma, 203
- Rhabdomyosarcoma, 203
- Rheumatic heart disease, 333, 336, 375
- Rheumatism, 203
- Rheumatoid arthritis (RA), 165, 165f, 169
- Rheumatoid factor, 165, 169
- Rheumatology, 204
- Rh incompatibility, 536
- RhoGAM, 543
- Rhonchi, 411
- RIA. *See* radioimmunoassay
- Ribonucleic acid (RNA), 47
- Ricketts, 163–164, 164f, 169
- Rickettsia, 78, 78b
- Rifampin (rifampicin), 414
- Rift Valley fever, 77b
- Right AV valve, 318, 318f, 325
- Right bundle branch, 319, 319f
- Right coronary artery (RCA), 318
- Right lymphatic duct, 337, 339
- Rinne test, 268, 268f
- Rods, 270, 270f, 272
- Romberg sign, 243
- Rongeur, 94b
- Roots, 222, 223f, 226  
for accessory organs, 435t  
for blood, 368t, 369t  
for bones, 158t  
for brain, 228t  
for breathing, 400t  
for digestive system, 432t, 433t–434t, 435t  
for digestive tract, 433t–434t  
for disease, 82t  
of drug administration, 108  
for drugs, 112  
ear, 264t–265t  
for endocrine system, 299t  
for eye and vision, 273t, 274t  
for heart, 326t  
for immunity, 368t  
for infectious disease, 86t  
for integumentary system, 129  
for joints, 158t  
for lungs, 400t  
for lymphatic system, 340t  
for male reproductive system, 494t  
for mouth, 432t  
for muscular system, 197t  
for nervous system, 227t  
for physical forces, 98t  
for respiratory system, 399t  
for skeleton system, 159t  
for spinal cord, 227t  
for urinary system, 465t, 467t  
for urinary tract, 467t  
for vascular system, 327t
- Rosacea, 139
- Rotator cuff (RTC) injury, 199, 200f
- Rotator cuff tear, 212
- RSI. *See* repetitive strain injury
- RSV. *See* respiratory syncytial virus
- Rubella, 77b
- Rule of nines, 132f, 136

**S**

- SAD. *See* seasonal affective disorder
- Sagittal plane, 57
- Saliva, 427, 432
- Salivary glands, 429–430, 429f
- Salpingectomy, 523, 525
- Salpingitis, 525
- Sarcoma, 80, 81
- Scabies, 139
- Scalpel, 94b, 95f
- Scarlet fever, 77b
- Schilling test, 379
- Schizophrenia, 236, 240
- Schwann cells, 241
- Schwannoma. *See* acoustic neuroma
- Sciatica, 243
- Scintigraphy, 93b
- Scissors, 94b
- Sclera, 269, 273
- Scleroderma, 126, 134, 136
- Scoliosis, 168, 169
- Scotoma, 281
- Scrotal abnormalities, 501f
- Scrotum, 490, 490f, 494
- Seasonal affective disorder (SAD), 305, 306b

- Sebacous glands, 126, 128  
 Sebum, 126, 128  
 Seizures, 233, 239  
 Selective estrogen receptor modulators (SERMs), 162, 170  
 Selective serotonin reuptake inhibitor (SSRI), 244  
 Sella turcica, 305  
 Semen, 492, 494  
 Semicircular canals, 263, 264  
 Semilunar valves, 318  
 Seminal vesicles, 492, 494  
 Seminoma, 501  
 Senile lentiginos, 139  
 Senses, 260–261  
 Sensorineural hearing loss, 266, 267  
 Sensory neuron, 218, 226  
 Sensory receptors, 260, 261  
 Sensory system, 260–261  
   case studies  
     amblyopia, 259, 282  
     audiology report, 290  
     intraocular lens implant, phacoemulsification with, 291  
 ear, 262–263, 262f–263f  
   abbreviations, 269  
   disorders, 267  
   roots, 264t–265t  
   treatment, 267  
 eye and vision, 269–271  
   abbreviations for, 282  
   clinical aspects of, 276–279  
   roots for, 273t, 274t  
   suffixes for, 276t  
   supplementary terms for, 280–281  
 hearing, clinical aspects of  
   acoustic neuroma, 266  
   hearing loss, 266  
   Ménière disease, 266  
   otitis, 266  
   otosclerosis, 266  
   suffixes for, 261t  
 Sentinel node biopsy, 525  
 Sepsis, 78, 82  
 Septal defect, 332–333, 333f, 336  
 Septicemia, 88, 379  
 Septic shock, 332  
 Septum, 60  
 Septum, 317, 325  
 Sequela, 102  
 SERMs. *See* selective estrogen receptor modulators  
 Seroconversion, 379  
 Sertoli cells, 490, 494  
 Serum, 361, 367  
 Sex hormones, 295b, 297  
 Sexually transmitted infections (STIs), 496, 496b, 500  
 SG. *See* specific gravity  
 Shingles, 139, 233, 239  
 Shin-splint, 201  
 Shock, 332, 336  
 Shoulder girdle, 154b  
 Sickle cell anemia, 372, 372f, 376  
 Side effects, drugs, 106, 107  
 Sideroblastic anemia, 372, 376  
 SIDS. *See* sudden infant death syndrome  
 Sigmoid colon, 429, 432  
 Sign, 97  
 Simmonds disease, 305  
 Single-photon emission computed tomography (SPECT), 93b  
 Sinoatrial (SA) node, 319, 319f, 325  
 Sinuses, 60, 173, 174f, 392, 398  
 Sinus rhythm, 319, 325  
 Sjögren syndrome, 375, 376  
 SK. *See* streptokinase  
 Skeletal muscle, 190, 190f, 196  
 Skeleton, 157  
 Skeleton system  
   abbreviations, 174  
   bones, 154b  
     formation, 155  
     long, 155, 155f  
   case studies  
     arthroplasty of right TMJ, 184  
     idiopathic adolescent scoliosis, 151, 175  
     osteogenesis imperfecta, 186  
   clinical aspects of, 160–168  
     fractures, 162, 162b, 163f  
     infection, 162  
     joint disorders, 164–166  
     metabolic bone diseases, 162–164, 163f, 164f  
     neoplasms, 164  
     spine, disorders of, 166–168  
   divisions of, 152–153, 152f, 153f  
   human, 152  
   joints, 156, 156f  
   roots for, 159t  
   structure and function, terms for, 156–157  
   supplementary terms, 170–173  
 Skin, 126, 128  
   anatomy of, 126, 127f  
   burns, 132  
   cancer, 134–135  
   case studies, 148–149  
   clinical aspects of, 130–131  
     autoimmune disorders, 134, 134f  
     dermatitis, 133, 133f  
     psoriasis, 133, 133f  
     wounds, 131–133  
   cross-section of, 127f  
   lesions, types of, 130b  
   medication patches, 126b  
   receptors for general senses in, 260, 260f  
   structures, 126–128  
 Skin turgor, 141  
 Skull, 152, 152f  
 SLE. *See* systemic lupus erythematosus  
 Sleep apnea, 234, 239, 412  
 Sleep disturbances, 234  
 Slit-lamp biomicroscope, 281  
 Small cell carcinoma, 412  
 Small intestine, 428–429, 432  
 Smooth (visceral) muscle, 190, 190f, 196  
 Snellen chart, 281  
 Sodium, in body fluids, 470b  
 Somatic nervous system, 218, 226  
 Somatoform disorders, 243  
 Somatotropin, 295b, 492b  
 Somnambulism, 243  
 Sound, 94b, 95f  
 Spasm, 203  
 Spasticity, 203  
 Specific gravity (SG), 473, 475  
 SPECT. *See* single-photon emission computed tomography  
 Speculum, 102, 103f, 527  
 Spermatocord, 492, 494  
 Spermatocoele, 501  
 Spermatozoa, transport of, 490, 491f, 492  
 Spermatozoon, 494  
 Sphenoid bone, 305  
 Spherocytic anemia, 379  
 Sphincter, 60  
 Sphincter of Oddi, 445  
*Sphygmlo*, 271b  
 Sphygmomanometer, 90, 97, 271b, 322, 323f, 325  
 Spina bifida, 540  
 Spinal cavity, 57  
 Spinal cord, 218, 218f, 222, 223f, 226  
   reflexes, 222, 223f  
   spinal nerves, 222, 223f  
 Spinal nerves, 222, 223f, 226  
 Spine, 173  
   curvatures of, 167–168, 168f  
   disorders of, 166–168  
 Spiral fractures, 162b, 163f  
 Spiral organ (organ of Corti), 263, 264  
 Spirochetes, 77b  
 Spirogram, 407f  
 Spirometer, 406, 410  
 Spleen, 339  
 Splenic flexure, 445  
 Splenomegaly, 373, 377, 441, 444  
 Split-thickness skin graft (STSG), 132  
 Spondee, 268  
 Spondylolisthesis, 166, 167f, 169  
 Spondylolysis, 166, 169  
 Spondylosis, 172  
 Sprain, 201  
 Sputum, 392, 398  
 Squamous cell carcinoma, 134, 135f, 136  
 SSRI. *See* selective serotonin reuptake inhibitor  
 Staghorn calculus, 477, 478f  
 Staging, cancer, 95–96, 97  
 Stapedectomy, 266, 267  
 Stapedius, 267  
 Stapes (stirrup), 262, 262f  
 Stapling, 103  
 Stasis, 344  
 Statins, 346  
 Stem cell, 51t  
 Stenosis, 333, 336  
 Stents, 330, 331f, 337  
 Stereotactic biopsy, 525  
 Sterility, 496, 500  
 Steroid hormones, 294, 298  
 Steroids, 165, 191b  
*Stethlo*, 271b  
 Stethoscope, 90, 97  
*-sthenlo*, 271b  
 Stimulants, 244  
 STIs. *See* sexually transmitted infections  
 Stoma, 438, 444

- Stomach, 428, 432  
 Strabismus, 281  
*Streptococcus pneumoniae*, 232, 402  
 Streptokinase (SK), 346  
 Stress incontinence, 461, 479  
 Stress injuries, 199–201  
 Stress tests, 330, 337  
 Striae atrophicae, 542  
 Stridor, 411  
 Stroke, 231, 239, 329, 336  
 Stroke volume, 343  
 STSG. *See* split-thickness skin graft  
 Student's elbow, 161b  
 Stupor, 243  
 Subacute bacterial endocarditis (SBE), 344  
 Subcutaneous layer, skin, 126, 128  
 Subdural hematoma, 231, 232f, 239  
 Subluxation, 172  
 Substance dependence, 106, 107  
 Substance withdrawal, 106, 107  
 Sudden infant death syndrome (SIDS), 405, 409  
 Suffixes  
   adjective, 13t  
   for blood, 367t  
   condition of, 10t  
   for diagnosis, medical, 99t  
   for disease, 84t  
   for drugs, 112  
   for eye and vision, 276t  
   for nervous system, 230t  
   noun, 9–10  
   for respiratory system, 398t  
   for sensory system, 261t  
   for surgery, 100t  
 Sulcus, 219, 220f, 226  
 Superior vena cava, 317, 318f, 325  
 Suppuration, 88  
 Surfactant, 396, 398  
 Surgeon, 103  
 Surgery, 93–95, 94b, 97  
   instruments for, 94b  
   purposes of, 94–95  
   suffixes for, 100t  
 Surgical fixation, 94  
 Surgical instruments, 94b  
 Suture, 97, 156, 157  
 Swan–Ganz catheter, 323b, 344  
 Swayback, 168  
 Sweat (sudoriferous) glands, 126, 128  
 Symbols, 104  
 Symbols, medical terminology, 8  
 Sympathectomy, 243  
 Sympathetic nervous system, 224, 226  
 Symphysis, 156, 157  
 Symphysis pubis, 171  
 Symptoms, 89, 97  
 Synapse, 219, 226  
 Syncope (fainting), 102, 332, 336  
 Syndrome, 102  
 Synechia, 281  
 Synergist, 192, 196  
 Synergy, 106, 107  
 Synovial fluid, 156, 157  
 Synovial joint, 156, 157  
 Syringomyelia, 243  
 Systemic circuit, 317, 317f  
 Systemic diseases, 88  
 Systemic lupus erythematosus (SLE), 134, 375, 377  
 Systemic sclerosis, 375, 377  
 Systole, 318, 325  
**T**  
 Tabes dorsalis, 243  
 Tachycardia, 331, 336  
 Tachypnea, 410  
 Tactile sense, 260, 261  
 Tailor's bottom, 161b  
 Talipes, 172  
 Target tissue, 294, 298  
 Tarsorrhaphy, 281  
 Tarsus, 280  
 TB. *See* tuberculosis  
 TBG. *See* thyroxine-binding globulin  
 TCA. *See* tricyclic antidepressant  
 T cells (T lymphocytes), 364, 367  
 Teletherapy, 527  
 Temperature, 260  
 Tendinitis, 199, 201  
 Tendons, 156, 157, 190, 190f, 196  
 Tennis elbow, 161b, 200  
 Tenosynovitis, 199, 202  
 Teratogen, 540  
 Testes, 295b, 298, 490, 491f, 492  
 Testicular cancer, 497  
 Testis, 494  
 Testosterone, 494  
 Testosterone, 295b, 490  
 Tetanus, 203  
 Tetany, 203, 301, 304  
 Tetralogy of Fallot, 344  
 TGV. *See* thoracic gas volume  
 Thalamus, 219f, 220, 227  
 Thalassemia, 372, 377  
 Therapy, 93, 97  
 Thoracentesis, 406, 406f, 410  
 Thoracic cavity, 57  
 Thoracic duct, 337, 340  
 Thoracic gas volume (TGV), 413  
 Thoracoscopy, 412  
 Thorax, 153, 154b, 157  
 Thrombin, 378  
 Thromboangiitis obliterans, 344  
 Thrombocytes, 358, 359b, 361, 361f, 367  
 Thrombocytopenia, 373, 377  
 Thrombophlebitis, 334, 336  
 Thrombosis, 231, 239, 328–329, 329f, 336  
 Thrombotic thrombocytopenic purpura (TTP), 379  
 Thrombus, 328–329, 336  
 Thrush, 446  
 Thymus, 297–298, 339, 340  
 Thyroid, 301  
   gland, 295b, 296–297, 296f, 298  
   scan, 306  
 Thyroid-stimulating hormone (TSH), 295b, 300b  
 Thyroid storm, 305  
 Thyrotoxicosis, 305  
 Thyroxine, 295b  
 Thyroxine-binding globulin (TBG) test, 297, 306  
 TIA. *See* transient ischemic attack  
 Tic, 243  
 Tic douloureux, 243  
 Tick- and mosquito-borne viruses, 233  
 Tinea, 139, 139f  
 Tinea versicolor, 139  
 Tinnitus (ringing in ears), 266, 267  
 Tissue plasminogen, 346  
 Tn. *See* troponin  
 TNM system, 96  
 Tolerance, 106, 107  
 Tomosynthesis, 525  
 Tonometer, 281  
 Tonsillectomy, 394b  
 Tonsillitis, 394b  
 Tonsils, 339, 340, 393, 393f  
 Tonus, 190, 196  
 Torticollis, 203  
 Tourette syndrome, 243  
 Toxins, 78, 82  
 Trachea, 394–395, 398  
 Tracheostomy, 413  
 Tracheostomy tube, 413f  
 Tracheotomy, 413  
 Trachoma, 276, 279  
 Traction, 162, 170  
 Tracts, 222, 227  
 Transdermal (TD) patches, 126b  
 Transesophageal, 345  
 Transient ischemic attack (TIA), 243  
 Transsphenoidal adenomectomy, 306  
 Transurethral incision of prostate (TUIP), 497, 497f  
 Transurethral resection of prostate (TURP), 489, 497, 497f, 502  
 Transverse fractures, 162b, 163f  
 Transverse plane, 57  
 Trauma, 76, 82  
 Tremor, 233, 239  
 Trephination, 243  
 Trichotillomania, 235b  
 Tricuspid valve. *See* right AV valve  
 Tricyclic antidepressant (TCA), 244  
 Triglyceride, 345  
 Trigone, 464f, 465, 466  
 Triiodothyronine, 295b  
 Trocar, 94b  
 Trochanter, 173  
 Troponin (Tn), 331, 337  
 Trousseau sign, 204  
 TSH. *See* thyroid-stimulating hormone  
 TTP. *See* thrombotic thrombocytopenic purpura  
 Tubercles, 77b, 173  
 Tuberculin test, 403, 410  
 Tuberculosis (TB), 77b, 162, 403, 403f, 409  
 Tuberosity, 173  
 Tubular reabsorption, 464, 466  
 TUIP. *See* transurethral incision of prostate  
 Tumors, of nervous tissue, 233  
 Turbinate bones, 392, 398  
 TURP. *See* transurethral resection of prostate  
 Tussis, 411  
 Tylenol, 106  
 Tympanic membrane, 262, 264



Type 1 diabetes mellitus (T1DM), 302  
 Type 2 diabetes mellitus (T2DM), 302

**U**

UA. *See* urinalysis  
 UFE. *See* uterine fibroid embolization  
 Ulcerative colitis, 439–440, 440f, 444  
 Ulcers, 436–437  
 Ultrasonography, 539, 539f, 541  
 Ultrasonography, 93b, 93f  
 Umbilicus, 542  
 United States Pharmacopeia (USP), 106  
 Urea, 464, 466  
 Uremia, 470, 475  
 Ureter, 463, 466  
 Ureterocele, 477, 478f  
 Urethra, 464f, 465, 466, 490, 492b, 494  
 Urethritis, 469, 475, 496, 500  
 Urinalysis (UA), 473, 475  
 Urinary bladder, 464–465, 464f, 466  
 Urinary frequency, 477  
 Urinary incontinence, 465, 477  
 Urinary lithiasis, 472  
 Urinary stasis, 469, 475  
 Urinary system, 462, 462f  
   abbreviations, 479  
   case studies  
     end-stage renal disease, 487  
     renal calculi, 486  
     stress incontinence, 461, 479  
   clinical aspects of, 469–473  
     cancer, 472–473, 473f  
     chronic renal failure, 470, 471f  
     glomerulonephritis, 469–470  
     infections, 469  
     nephrotic syndrome, 470  
     urinalysis, 473  
     urinary lithiasis, 472  
   kidneys, 462–463, 463f  
     blood supply to, 463  
     location and structure, 462–463, 463f  
     nephrons, 463, 464f  
     roots for, 465t  
     roots for, 465t, 467t  
     supplementary terms for, 476–477  
     urine formation, 463–464  
     transport and removal of, 464–465, 464f  
 Urinary tract infections (UTIs), 469  
 Urinary urgency, 477  
 Urination, 465, 466  
 Urine, 466  
   formation, 463–464  
   transport and removal of, 464–465, 464f  
 Urinometer, 477  
 Urogenital (UG) tract, 490

Urticaria, 140, 140f, 374, 377  
 USP. *See* United States Pharmacopeia  
 Uterine fibroid embolization (UFE), 522  
 Uterine tube, 492b  
 UTIs. *See* urinary tract infections  
 Uvea, 269–270, 270f, 273  
 Uvula, 427, 432

**V**

VAC. *See* vacuum-assisted closure  
 Vacuum-assisted closure (VAC), 131  
 VAD. *See* ventricular assist device  
 Vaginal speculum, 103f  
 Vaginitis, 525  
 Vagotomy, 447  
 Valgus, 172  
 Valsalva maneuver, 343  
 Valves, 325  
 Varicella-zoster virus, 233  
 Varicocele, 501  
 Varicose veins, 333–334, 333f, 336  
 Varus, 172  
 Vascular disorders, 231  
 Vascular system, 321–323  
   blood pressure, 321–323, 323f  
   roots for, 327t  
 Vascular technologists, 334b  
 Vas deferens, 492b, 494  
 Vasectomy, 492b, 498, 500, 508  
 Vasodilator, 346  
 Vegetation, 344  
 Veins, 321, 322f, 325  
   disorders of, 333–334, 333f  
   varicose, 333–334, 333f  
 Venous stasis ulcer, 140, 140f  
 Ventricles, 220, 221f, 227, 317, 326, 463b  
 Ventricular assist device (VAD), 345  
 Ventriculography, 345  
 Venules, 321, 321f, 326  
 Vernix caseosa, 542  
 Verruca, 140  
 Vertebral column, 152, 153f, 154b  
 Vertigo (dizziness), 266, 267  
 Vessel, 326  
 Vestibular apparatus, 263, 264  
 Vestibule, 263, 264, 526  
 Vestibulocochlear nerve, 263, 264  
 Vibrios, 77b  
 Villi, 429, 429f, 432  
 Vincent disease, 446  
 Viruses, 78b  
 Visceral, 51t  
 Visceral nervous system. *See* autonomic nervous system (ANS)  
 Vision receptors, 261  
 Visual acuity, 270, 270f, 273  
 Vital signs (VS), 90, 97

Vitiligo, 140, 140f  
 Vitreous body, 270f, 271, 273  
 Vocal folds, 394, 398  
 Voice box, 394  
 Vulvulus, 439, 439f, 444  
 Von Recklinghausen disease, 172, 305  
 Von Willebrand disease, 379  
 VS. *See* vital signs

**W**

Waiter's tip position, 161b  
 "Wake-up" test during spinal fusion surgery, 214  
 Wallerian degeneration, 243  
 Warfarin, 329  
 Water intoxication, 477  
 WBCs. *See* white blood cells  
 Weber test, 268, 268f  
 Wernicke area, 241  
 Western blot assay, 379  
 West Nile disease, 77b  
 West Nile virus, 233  
 Wheeze, 411  
 Whiplash, 243  
 White blood cells (WBCs), 358, 359–361, 359b  
 White matter, of nervous system, 218, 227  
 White of eye. *See* sclera  
 Whitmore–Jewett staging, 501  
 WHO. *See* World Health Organization  
 Wilms tumor, 477  
 Windpipe, 394  
 Withdrawal, substance, 106, 107  
 Wolff–Parkinson–White, 344  
 Wood lamp, 141  
 Word components  
   prefix, 5  
   root, 4  
   suffix, 4  
 Word derivations, 6, 6f  
 World Health Organization (WHO), 77b  
 Wounds, 131–133  
   healing, 131–132  
   skin, 131–133  
 Wright stain, 379

**X**

Xanthoma, 281  
 Xenophobia, 235b  
 Xeroderma, 126  
 Xeroderma pigmentosum, 140

**Y**

Yellow fever, 77b

**Z**

Zonule, 280